

5607

RECORD
COPY

OTS: 60-41,409

MAIN FILE

JPRS: 5607

21 September 1960

PR

THE CLINICAL ASPECTS OF CYSTICALLY-DEGENERATED

NEURINOMAS OF THE VIII NERVE

By N. S. Blagoveshchenskaya
and
G. P. Korniyanskiy

DISTRIBUTION STATEMENT A
Approved for Public Release
Distribution Unlimited

- U S S R -

RETURN TO MAIN FILE

20000621 061

Distributed by:

OFFICE OF TECHNICAL SERVICES
U. S. DEPARTMENT OF COMMERCE
WASHINGTON 25, D. C.

U. S. JOINT PUBLICATIONS RESEARCH SERVICE
205 EAST 42nd STREET, SUITE 300
NEW YORK 17, N. Y.

Reproduced From
Best Available Copy

JPRS: 5607
CSO: 4572-N

THE CLINICAL ASPECTS OF CYSTICALLY-DEGENERATED
NEURINOMAS OF THE VIII NERVE

[Following is the translation of an article by N. S. Blagoveshchenskaya and G. P. Kornyskiy entitled Klinika Kistozno-Pererozhdenykh Nevrinom VIII Nerva (English version above), in Voprosy Neyrokhirurgii (Problems of Neurosurgery), Vol. XXIV, No. 3, Moscow, 1960, pages 48-52.]

The accumulation of a large number of observations of VIII nerve tumors at the Institute has made it possible to distinguish cystic forms of acoustic nerve neurinomas, which, in connection with the characteristics of morphological structure of the tumor, have a distinct clinical course.

In this work we are analyzing 16 observations on patients with cystic neurinomas of the VIII nerve, which in five cases were checked by operation, and in 12, by autopsy. We gained the impression that cystic neurinomas are encountered on the operating table more frequently than has been noted in the literature, because the proper attention has not been fixed on cyst-formation in neurinomas.

According to the data of the majority of authors (Verocay, B. G. Yegorov, L. I. Smirnov, E. O. Morgenshtern, Ye. E. Krasovskiy), the microscopic structure of neurinomas is distinguished by its great variety. B. G. Yegorov points out that the fascicular tissue is the main tissue of the neurinomas. In the study of the neurinomas on total sections he

succeeded in showing the great degree of polymorphism and the presence of the most varied histological forms in the same tumor nodule. Such a variety of histological structure, in his opinion, is brought about by phenomena of regressive metamorphosis in connection with a disturbance in

blood supply, spinal fluid circulation and metabolism in the tumor tissue.

The main mass of the neurinoma usually has the appearance of a tumor nodule of varying density on section without any cysts visible macroscopically. However, on microscopic examination frequently very small cystic cavities are found. In a number of patients whom we observed with neurinomas the cysts within the tumors were surrounded by a rim consisting of hemorrhages and necroses which attained one centimeter in width. This confirms the viewpoint of B. G. Yegorov of the significance of blood supply disturbances, of nutrition and metabolism in the tumor tissue for the occurrence of cyst formation. However, while the formation of microscopic cysts in tissues of the neurinomas is encountered frequently, the formation of large cysts visible macroscopically is a quite rare phenomenon.

Cystic neurinomas in our observations had many distinct features. Even on external examination of the tumor during operation or at autopsy it could be noted that cystically-degenerated neurinomas have a nodular surface as a result of protrusion of the cysts. The tumor cysts were included in the neurinoma tissue and were always covered with a tumor capsule, even when the cysts were located at the periphery. Sometimes, when the cysts were located peripherally they could be seen through the

capsule; when large cysts were located within the depth of the tumor it was impossible to suspect cyst formation by the external examination of the capsule.

Solitary large cysts may be located in the center of the tumor or at the periphery, in the posterior or in the anterior portions of the tumor.

On section cystically-degenerated neurinomas consisted of a multitude of cystic cavities of different sizes separated from one another by thin or porous septa. In other observations they consisted of a multitude of small cysts (alveolar-cystic structure of the tumor) with a simultaneous inclusion of one large cyst in the tumor. Cases were also encountered where the neurinoma tissue was occupied by a single large cyst (3.5x3 centimeters) with a smooth inner surface. The cysts were usually filled with contents of a colloidal type of yellowish, yellowish-green or yellowish-red color. The sizes of the large cysts in the neurinoma tissue varied within broad limits (1.5x2 centimeters; 2.5x3 centimeters; 3x3.5 centimeters). Sometimes, in connection with cyst formation the tumor had a sac-like appearance with thin walls three to four millimeters in thickness (Fig. 1, 2).

In contrast to subarachnoid cysts, which frequently accompany neurinomas, tumor cysts are always located within the tumor tissue under its capsule. In some observations simultaneously there were both subarachnoid cysts and cysts in the neurinoma tissue; however, the contents of the arachnoid cysts were usually transparent and colorless.

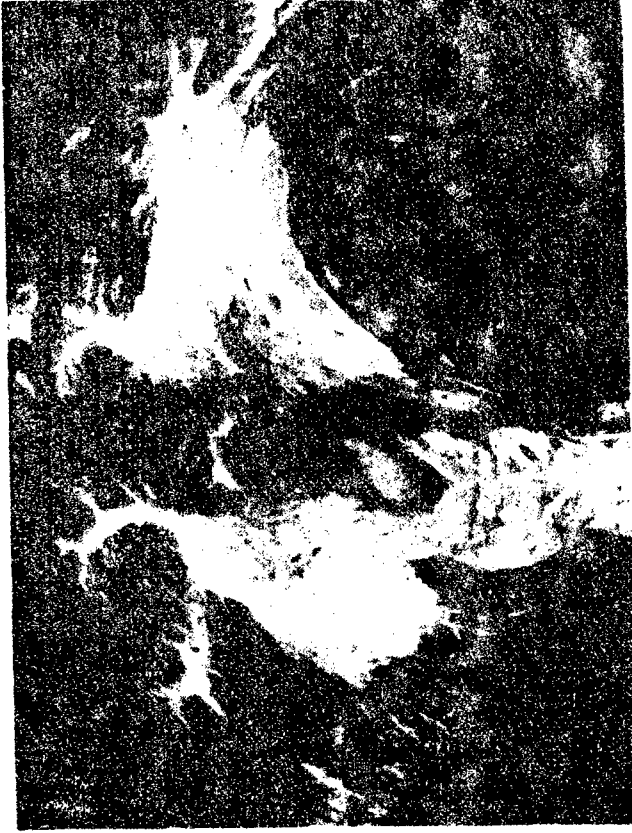

Fig. 1. Neurinoma of the Right Lateral Fontine Cistern. On Transverse Section (View from Eebind), the Tumor with Multiple Cysts and with a Single Large Smooth-Walled Cyst at the Anterior Pole of the Tumor (Dimensions of the Cyst 2.5x 3 cm). The right cerebellar hemisphere and pons are markedly compressed.




Fig. 2. Tissue of VIII nerve neurofibroma on section consists of a multitude of different-sized cysts.

Neurinomas of the lateral pontine cistern with cystic-degeneration grew out into the middle fossa or grew into the upper portions of the lateral pontine cistern more frequently than the usual neurinomas; this was noted in seven patients (in two observations it was verified at autopsy). In two cases, at autopsy it was shown that the tumors grew into the middle fossa, compressing the temporal lobes of the brain; in one of them the tumor formed a deep impression in the temporal lobe, compressing the III nerve in a ribbon-like fashion. Possibly such a spread was explained by the soft consistency of the tumors, in connection with which they could "squeeze out" into the fissure of Bichat, and spread supratentorially into the basal-temporal portions of the brain.

Cystic neurinomas produce gross compressions of the surrounding structures (cerebellar hemispheres, pons and medulla) as well as pronounced displacements of them which were not distinguished by any characteristics from the same displacements and compressions produced in ordinary VIII nerve neurinomas.

Does the cystic nature of the VIII nerve neurinomas have an influence on the clinical course of the disease?

There are very few data on this problem in the literature.

L. T. Pirogova points out that the consistency of angle tumors is of great importance for the degree of expression of the clinical signs. K. S. Blagoveshchenskaya noted that in arachnoid endotheliomas of the lateral pontine cistern symptoms of displacement on the opposite side were considerably more marked than in the case of neurinomas and cholesteatomas; this is associated with the great density of the arachnoid endotheliomas.

According to our data, the cystic nature of the tumors created the bases for an atypical clinical course, which sometimes gave rise to diagnostic errors.

The characteristics of the clinical manifestation of cystic neurinomas were very varied and depended on the combination of many factors (size, direction of tumor growth, degree of expression of the phenomena of hydrocephaly and increased intracranial pressure). The fact attracts attention that in neurinomas occurring without cyst formation, vestibular dizziness is not encountered as a rule. Nevertheless, in cystic neurinomas the patients very frequently complained of severe vestibular dizziness, which was observed in nine patients. Sometimes, the patients preferred to lie in a position in which the dizziness was less pronounced; usually, dizziness was reduced when the patient lay on the side of the tumor. In one patient there were attacks of severe dizziness, during which a distinct irritative nystagmus occurred which was directed toward the side of the focus. This patient could lie only on his left side during the attack (the tumor was on the left). In another patient the first sign of the disease was dizziness, which had occurred ten years before being admitted to the Institute.

The most severe and torturous cases of dizziness are produced by processes which cause acute changes in the vestibular structures with incomplete loss of their function. For this reason, of the tumors of the posterior fossa severe dizziness is most typical of the cystic tumors of the cerebellum (anglioreticulomas, astrocytomas) and of the relatively

mobile tumors of the fourth ventricle (chorioid papillomas, ependymomas, cysticerci).

The cystic neurinomas were also accompanied by definite dizziness. In patients with cystic and mobile tumors a severe acute irritation of the vestibular structures sometimes occurs on changing position, which is uncompensated because of its development. In cystic neurinomas the disease began more frequently with signs of increased intracranial pressure; there is usually no dizziness in solid neurinomas but it may be encountered when there is cyst formation in them. Of the patients who were under our observations the disease began with headache in six; with loss of hearing in six; in one, with vestibular dizziness; in one patient, with neuralgic pains in the face; in one patient, with involvement of the VII nerve; and in one patient, with involvement of the V nerve and staggering.

In the cystic neurinomas an obligatory position of the head was found ^{more often} and in a more pronounced form than in the ordinary neurinomas. This was observed in five patients (three of them preferred to lie on the side of the focus; one, on the healthy side; one patient could only lie on his side -- right or left). The obligatory position of the head was brought about chiefly by marked headaches, less often, by vestibular-type dizziness (first observation).

Signs of increased intracranial pressure in the cystic neurinomas were more distinct in the great majority of observations than in the case of neurinomas occurring without cyst formation. In 11 patients

there were distinct signs of increased intracranial pressure, whereby in six of them papilledema was pronounced with a transition to atrophy and a considerable loss of vision. The signs of increased intracranial pressure in the cystic neurinomas develop more acutely and more rapidly than in the solid neurinomas, in this respect approaching the cerebellar tumors and tumors of the fourth ventricle.

Focal symptoms in the cystic neurinomas were very distinctive in connection with their soft consistency, change in the configuration of the tumor and the influence of the tumor on the spinal fluid pathways when the patient changed his position. Despite the gross expression of pressures and displacements of the surrounding cerebral tissue and cranial nerves, the focal symptoms in the cystic neurinomas not uncommonly were expressed to a very mild degree. Frequently, the mild manifestations of local symptoms were not at all in accordance with the gross morphological changes, which obviously was explained by the soft consistency of these tumors.

The mildness of the local symptoms in the cystic neurinomas was expressed in the fact that with them there was usually no complete loss of hearing or of vestibular excitability on the side of the tumor, and after the operation the functions of the VIII nerve which had been disturbed were usually restored. Thus, of 16 patients hearing was partially preserved or completely preserved in four patients on the side of the tumor. In addition, in one patient before the operation there was complete deafness on the side of the tumor. After the operation

hearing improved considerably. Vestibular excitability was preserved on the side of the tumor in five patients, whereby in two of them neither hearing nor vestibular excitability were lost completely. In others, with complete loss of hearing and of the vestibular function on the side of the focus there were extremely mild expressions of involvement of the adjacent portions of the brain: there were no cerebellar disturbances or brain-stem symptoms (spontaneous nystagmus was either absent or was slight; optokinetic nystagmus was preserved, and sometimes the corneal reflexes were maintained; other brain-stem symptoms were absent). The adjacent cranial nerves were involved to a considerably lesser degree. Thus, in one observation with growth of the VIII nerve neurinoma into the middle fossa, at autopsy the III nerve was compressed into a ribbon-like form by the tumor cyst; however, there were no clinical signs of involvement of it. In another patient on the side of the tumor there was a loss of hearing and vestibular excitability, but there were absolutely no signs of involvement of neighboring cranial nerves.

Spontaneous nystagmus in the cystic neurinomas was sometimes absent or did not show the rules and regulations which were characteristic of the solid neurinomas, and sometimes was expressed to a greater extent on the side of the tumor.

A variation in the intensity of the symptoms during the disease as well as a relationship of them to the change in the position of the head was characteristic of the cystic neurinomas. In six patients, on change of position, attacks of severe vegetative disturbances of the

Bruns type occurred and even a sudden stoppage of respiration and cardiac activity, which is more characteristic of tumors of the fourth ventricle; in four patients sudden death occurred from stoppage of respiration and of cardiac activity.

The cystic neurinomas, having a tendency to spread into the middle fossa and to grow into the upper portions of the lateral pontine cisterns, frequently produced destruction and porosity of the apex of the petrous pyramid. In four patients there were clinical signs of spread of cystic neurinomas to the upper portions. In one of them there were pronounced signs of involvement of the Gasserian ganglion (marked neuralgic pains in the face, involvement of the motor portion of the V nerve), involvement of the III nerve on the side of the tumor, which made it possible clinically to suspect the growth of tumor into the middle fossa.

In the majority of observations on the X-ray films there were local changes of the temporal bones, whereby in nine patients these changes were characteristic of VIII nerve neurinomas. Only in one patient did the distinctive changes in the petrous pyramid give grounds for suspecting the presence of an arachnoid cyst. In two patients on X-ray a cholesteatoma and a tumor taking its origin from the meninges of the cerebellopontine angle were suspected. In the spinal fluid the same changes were found as in the solid neurinomas.

The atypical clinical course of cystic neurinomas of the VIII nerve not uncommonly leads to an erroneous diagnosis. Most often,

the cystic neurinomas had to be differentiated from tumors of the lateral recess of the fourth ventricle; less often, from tumors of the cerebellar hemisphere. An incomplete loss of hearing and of vestibular function on the side of the focus, severe vestibular dizziness, variability of the symptoms on change of position, severe vegetative attacks associated with a change in the patient's position, mildness of the focal symptomatology contributed to this. In six patients the diagnosis fluctuated between tumor of the lateral pontine cistern and tumor of the lateral recess of the fourth ventricle, tumor of the cerebellar hemisphere, cholesteatoma or arachnoid endothelioma of the olfactory pit. The patient had marked signs of increased intracranial pressure, loss of the sense of smell on both sides, unilateral deafness and a loss of the vestibular excitability, which were considered a post-traumatic neuritis of the VIII nerve. The cerebellar and posterior cranial brain stem signs were absent, and there was no involvement of the adjacent cranial nerves. Signs of increased intracranial pressure increased. Afterwards, despite the atypical course, the suspicion of the possibility of an VIII nerve neurinoma was given an otoneurological basis, which was confirmed on X-ray; a cystic neurinoma of the VIII nerve was removed.

The cystic neurinomas are easily removed and give a very favorable results; after the operation a rapid regression of all the symptoms is observed.

When there is a suspicion of fourth ventricle tumor, particularly in ^{its} lateral recess, and in case none is found there, it is

necessary to examine the area of the lateral pontine cistern, because cystic neurinoma of the VIII nerve can give a clinical picture very similar to that of tumors of the lateral recess of the fourth ventricle.

Bibliography

1. Blagoveshchenskaya N. S. Auditory and Vestibular Disturbances in the Clinic of Tumors of the Posterior Fossa. Self-Referenced Doctoral Dissertation. Moscow, 1959.
2. Yegorov B. G. VIII Nerve Neurinoma. Moscow, 1949.
3. Kornyskiy G. P. Tumors of the Fourth Ventricle of the Brain. Doctoral Dissertation. Moscow, 1948.
4. Krasovskiy Ye. B. Pathology of Brain Diseases. Moscow, 1957.
5. Morgenshtern Z. O. In The Book: "Neurosurgical Council. First Session". Moscow -- Leningrad, 1937, page 215.
6. Pirogova L. T. Council of Neuropsychiatrists, 1933, No. 2, page 102.
7. Smirnov L. I. Histogenesis, Histology and Topography of Brain Tumors. Moscow, 1951, Vol. 1; 1959, Vol. 2.
8. Verocay J. Beitr. Path. Anat., 1910, Vol. 48, page 1.

Received 7 January 1960

FOR REASONS OF SPEED AND ECONOMY
THIS REPORT HAS BEEN REPRODUCED
ELECTRONICALLY DIRECTLY FROM OUR
CONTRACTOR'S TYPESCRIPT

THIS PUBLICATION WAS PREPARED UNDER CONTRACT TO THE
UNITED STATES JOINT PUBLICATIONS RESEARCH SERVICE
A FEDERAL GOVERNMENT ORGANIZATION ESTABLISHED
TO SERVICE THE TRANSLATION AND RESEARCH NEEDS
OF THE VARIOUS GOVERNMENT DEPARTMENTS