

PR

5586

RECORD
COPY

OTS: 60-41,388

JPRS: 5586

14 November 1960

THE VECTORCARDIOGRAM IN MYOCARDIAL HYPERTROPHY
OF THE LEFT VENTRICLE

MAIN FILE

By M. I. Kechker

- USSR -

Reproduced From
Best Available Copy

20000621 067

MAIN FILE

DISTRIBUTION STATEMENT A
Approved for Public Release
Distribution Unlimited

Distributed by:

OFFICE OF TECHNICAL SERVICES
U. S. DEPARTMENT OF COMMERCE
WASHINGTON 25, D. C.

U. S. JOINT PUBLICATIONS RESEARCH SERVICE
1636 CONNECTICUT AVE., N. W.
WASHINGTON 25, D. C.

JPRS: 5586

GSC: 4595-N

THE VECTORCARDIOGRAM IN MYOCARDIAL HYPERTROPHY OF THE
LEFT VENTRICLE

[Following is the translation of an article by M. I. Kechker entitled "Vektorkardiogramma pri Gipertrofii Miokarda Levogo Zheludochka Serdtsa" (English version above) in Klinicheskaya Meditsina (Clinical Medicine), Vol. XLI, No. 6, Moscow, 1960, pages 53-60.]

Department I of Therapy of the Central Institute for the Advanced Training of Physicians (Director - active member of the Academy of Medical Sciences USSR, distinguished scientific worker, Prof. M. S. Vovsi) and the Electrophysiology Laboratory (Director - candidate of medical sciences Ye. I. Borisova) of the Hospital imeni S. P. Botkin (head physician - Prof. A. N. Shabanov)

The hypertrophied muscle fiber produces an intensified electrical potential. During the movement of the wave of stimulation through the region of hypertrophied myocardium, the amplitude of the vectors corresponding to the increase in potential of this region must be greater than normal. Wenger remarks on the increase in amplitude of the vectorcardiogram in a series of cases of myocardial hypertrophy. He points out that, due to the increase in the QRS loop, the vectorcardiogram is capable of demonstrating very early changes of hypertrophy of the myocardium. An opinion concerning the possibility of vectorcardiographic supplementation of electrocardiographic data in myocardial hypertrophy is also expressed

by Sodi-Fallares, Klepzig, Doll, Reidell, and others.

However, the numerous vectorcardiographic studies of the hypertrophied myocardium have not invariably yielded the anticipated results. The demonstrated changes have been distinguished by an extreme inconstancy. Thus, an increase in the size of the QRS loop has been seen only in a small number of cases. It is possible that, in taking the vectorcardiogram by the cube and tetrahedral methods, the cause of failure has been an insufficient sensitivity of the electrodes and the levelling out of small changes by the non-uniformity of resistance in the conducting tissues between the heart and the electrodes. Mougain, Milovanovich, and Pouret, as well as Rilyan, have observed that approximation of the electrodes to the heart, with consequent increase in their sensitivity, is of great importance for obtaining suitable data on the distribution of stimulation within the myocardium.

In connection with the above, and also taking into account that an evaluation of myocardial hypertrophy of the left ventricle is of considerable clinical importance and offers great difficulties for the existing modes of diagnosis, we have attempted to use the method of precordial vectorcardiography to obtain additional data on the presence and extent of myocardial hypertrophy.

Studies were made of 59 patients in whom it was possible to suspect the presence of left ventricular hypertrophy. The ages of the patients were from 20 to 69 years. The degree of hypertrophy in the patients studied by us varied. In some patients there was evidence of myogenic dilatation of the heart due to the spread of fibrosis in the myocardium or to dystrophy of the bulk of the myocardium. This modified the magnitude, form, and orientation of the QRS loop due to reduction in the mass of electrically active myocardium.

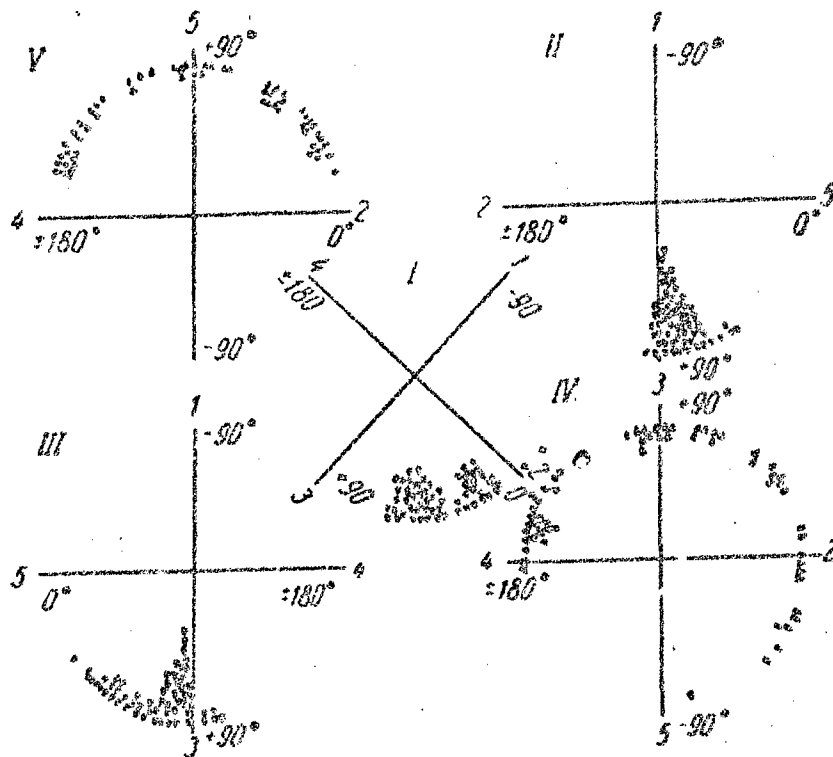
The patients were divided into three groups. The first group included 13 patients with the early stages of left ventricular hypertrophy, without increase or with only negligible increase in the size of the X-ray shadow of the heart. They had suffered for brief periods with hypertension, chronic nephritis, or rheumatic aortic valvular disease. In these patients there were no signs of cardiac failure. In the second group were 30 patients with unquestionable hypertrophy of the left ventricle (longer duration of the disease, heaving apical impulse,

rounding up of the apex of the left ventricle on X-ray, and slight extension of the left heart border to the left and posteriorly). Some of these patients suffered dyspnea upon rapid walking and slight physical exertion. The third group comprised 16 patients in whom, against a background of left ventricular hypertrophy, there was considerable dilatation of the chambers of the heart. Objective studies showed a diffuse epical impulse; X-ray examination showed the heart to be closely applied to the diaphragm, with the heart shadow enlarged to the left and sometimes slightly to the right as well. In all of these patients there was left ventricular or total cardiac decompensation, stage II or III, which responded poorly to treatment with cardiac glycosides.

ECG's were taken on all patients from 12 leads (six limb leads and six chest leads) and precordial vectorcardiograms by the rectangular pyramid method of I. T. Akulinichev. Vectorcardiograms and ECG's were taken with the VEKS-01 apparatus at an amplification of one mv = ten mm. Parallel recordings of the vectorcardiogram were taken by the cube method with the "Vektorvizokard" apparatus at an amplification of one mv = 30 mm.

For demonstration of the characteristic vectorcardiographic changes of left ventricular hypertrophy, we first analyzed the vectorcardiograms of the patients in group II. In these patients there was clear-cut hypertrophy of the left ventricle without clinical evidence of dilatation. Hence, it must be supposed that the basic pathologic changes discovered in the vectorcardiograms of such patients are due primarily to the hypertrophic process in the left ventricle.

The QRS loop of the vectorcardiogram in patients of group II was oriented, in the majority of cases, horizontally or slightly to the left, inferiorly, and markedly posteriorly. Figure 1 shows the orientation of the maximum vectors of projections of the QRS loops of vectorcardiograms taken by the system of precordial leads in the 30 patients of group II and in 30 healthy controls.



1 - Direction of the maximum vector of the QRS loop of the vectorcardiograms of healthy subjects.

2 - Direction of the maximum vector of the QRS loop of vectorcardiograms of patients with left ventricular hypertrophy.

Figure 1

It should be noted that the directions of the maximum vectors of the frontal projections, taken by both systems of recording, show only a slight difference (0 to 15 degrees); however, in four cases, the divergence of these indices reached 20 to 30 degrees. In comparing these with the indices of direction of the electrical axis of the ECG determined by standard and by unipolar limb leads (frontal plane of the Einthoven triangle), it turned out that sometimes the indices of the system of precordial leads were closer, and sometimes the indices of the vectorcardiogram taken by the cube system were closer. Despite the fact that the deviation of the electrical axis of the ECG was quite variable, for the most part it indicated a direction of 10 to 25 degrees further to the left

than did the direction of the maximum vector of the QRS loop.

According to all of the above-mentioned methods of determining the projections of the electromotive forces in the frontal plane in left ventricular hypertrophy, the electrical axis is disposed horizontally, rarely in the intermediate region or inclined slightly to the left. The latter, however, is seen in cases of the more serious type, bordering on group III. As Grant points out, considerable deviation of the electrical axis to the left is seen only in cases of marked dilatation of the ventricles and is associated with the development of fibrosis of the myocardium and disturbances of myocardial conduction.

A constant and pronounced deviation posteriorly is seen in the direction of the QRS loop. Regardless of whether we summated the deviations of the maximum vectors or of the middle vectors, or the maximum axes of projections II and III or of IV and V, the total deviation in 29 cases of the 30 was posterior, being greater in 23 cases than the maximum posterior deviation observed in the vectorcardiograms of healthy persons. The maximum vector of the sagittal projection of the QRS loop by the cube method in 28 of 29 cases was directed posteriorly; in 20 patients, the angle alpha exceeded +110 degrees (greater than the posterior deviation in the normal). Hence, the deviation of the QRS loop posteriorly must be accepted as characteristic of the vectorcardiogram of patients with left ventricular hypertrophy. The agreement in the absolute majority of these cases in the orientation of the QRS loop posteriorly upon analysis of vectorcardiograms taken by both above-mentioned methods confirms the correctness of the method recommended by us for the determination of the antero-posterior orientation of the QRS loop by means of summating the deviations of the maximum vectors of two projections.

The next vectorcardiographic sign of left ventricular hypertrophy is the presence of a large arc (a) at the upper segment of the ascending curve of the QRS loop. This arc is oriented frequently to the left and is almost invariably considerably posterior (in 27 of 30 patients). In vectorcardiograms taken by the cube method, this arc is less obvious and is less frequently encountered (in 19 of 29 cases). The appearance of arc (a) of the QRS loop is probably connected with hypertrophy of the postero-basilar portion of the left ventricle.

To characterize the dimensions of arc (a) and its direction, we determined the angle (γ) between the maximum vector and the maximum axis. As was predicted, the maximum axis of the QRS loop was situated to the left and posteriorly from the maximum vector in all patients of group II in which an arc was present. The angle γ of the maximum projection varied from eight to 25 degrees and more.

In all 30 cases the QRS loop had a slight initial deviation anteriorly and to the right (the area of it was not more than one-fifth the area of the QRS loop). The rate of evolution of the initial part of the QRS loop was slow, which is apparent in the thickening of the trace and the reduction in magnitude of the marking intervals and of the segments of the curve. The terminal deviation begins without any clear-cut delimitation immediately after arc (a). In the majority of cases the ascending curve of the QRS loop is more prolonged than the descending.

The movement of the trace of the beam which defines the QRS loop, in the presence of left ventricular hypertrophy, is counter-clockwise in projection I in 24 of 30 cases. According to the findings of M. I. Kechker and Sh. I. Shurgaya, in the normal the situation is reversed. The cases in which the evolution is clockwise include those with more protracted QRS loops with a tendency to vertical position. Rotation of the frontal projection of the QRS loop in a counter-clockwise direction is associated, it seems, with horizontal position of the loop. However, there were instances of an intermediate position in left ventricular hypertrophy with rotation of the beam counter-clockwise. Projections II, III, IV, and V of the QRS loop exhibit the following rotations of the beam: II - counter-clockwise; the other three - clockwise in the great majority of cases.

The basic characteristic of any site of myocardial hypertrophy is an increase in vectors, reflecting an increase in the electrical potential of the hypertrophied fibers. The more extensive the hypertrophied portion of the heart, the longer must the corresponding part of the QRS loop continue at the greater distance from the isoelectric point, i.e., the greater must be the area of the QRS loop. Planimetric measurements were made of the areas of QRS loops in 30 patients of group II. With precordial vectorcardiograms, in 24 patients there was an increase in the area of the greatest projection (usually projection III) of the QRS loop as compared with the normal maximum.

Of the remaining six, in five it was greater, and in only one was it slightly less, than the average normal value for the area. The area of the greatest projection of the QRS loop in patients of group II who had hypertension and chronic nephritis varied from 1.5 to 15 sq. cm. (normal from 0.7 to 3.1 sq. cm.). In patients with aortic valvular disease, the area of the QRS loop varied from 4.3 to 17.1 sq. cm. The greater area of the QRS loop in aortic valvular disease is the result of a prolonged compensatory process beginning early in life. In this, the myocardium probably possesses better opportunities for hypertrophy. In young patients with hypertension and chronic nephritis, the area of the QRS loop is greater than in older persons. As pointed out by A. L. Myasnikov, "In young patients with hypertension, myocardial hypertrophy develops more quickly and to a greater extent..., whereas in older patients the development is slower and less marked".

The area of the QRS loop in vectorcardiograms taken by the cube method in the same patients varied from 0.3 to four sq. cm. In 18 patients there was an increase in the area as compared with the normal; of the remaining 11 cases, in three the area was very small. From these cases it is apparent that, even in cases of advanced hypertrophy of the left ventricle the cube method demonstrates an increased QRS area less uniformly than does the precordial vectorcardiogram. In addition to the causes indicated above, the greater number of projections of the precordial vectorcardiogram improves the information derived. One of the five projections corresponds most closely in magnitude to the spatial area of the QRS loop. Recordings taken between electrodes I and III, near the anatomic axis, exhibit the greatest difference in potentials.

The maximum vector of the QRS loop in these same patients was not less than 1.8 mv (18 mm) and attained, in a number of cases, seven to eight mv (70-80 mm). In 18 cases its length equalled or exceeded 38 mm, i.e., was greater than normal. Probably, the area and the maximum vectors of the QRS loop depend primarily on the degree of myocardial hypertrophy. These indices (especially the area) increase with progression of development of hypertrophy. In all cases except four, the QRS loop of the precordial vectorcardiogram was not closed. The T loop was discordant from the QRS loop of the precordial vectorcardiograms in 25 of the 30 cases.

As illustration, let us consider the history of

disease, ECG, and vectorcardiogram over a period of time in patient M., 43 years old. Since the end of 1955 he had suffered with hypertension of the malignant type. He complained of headache, dull pain in the heart region, and slight dyspnea. The blood pressures ranged from 230/130 to 180/110 mm Hg. Percussion and X-ray studies showed a marked increase in the left ventricle.

ECG on December 10, 1957 (Figure 2a) showed horizontal position of the electrical axis of the heart (angle alpha = +one degree), left ventricular hypertrophy (Sv2 = 21 mm, Rv5 = 28 mm, S-T1, V5-6 slightly depressed), QRS = 0.1 second.

Precordial vectorcardiogram (Figure 2a) showed the QRS loop to be oriented horizontally (angle alpha₁ = +26 degrees), posteriorly (toward the electrode located at point five) and inferiorly. In projections II and III, arc (a) was high and shifted posteriorly. Area of projection III was 10.2 sq. cm., maximum vector equal to 54 mm. The QRS loop was unclosed only in projection III. Rotation of the beam defining projections I and II was counterclockwise, and in projections III, IV, and V was clockwise. Vectorcardiogram taken by the cube method (Figure 2a) showed area of the QRS loop of 1.2 sq. cm., length of maximum vector = 20 mm (upper limits of normal). Only the marked deviation of the QRS loop posteriorly (angle alpha₃ = +142 degrees in the sagittal projection) and rotation of the beam in the clockwise direction indicated the presence of left ventricular hypertrophy.

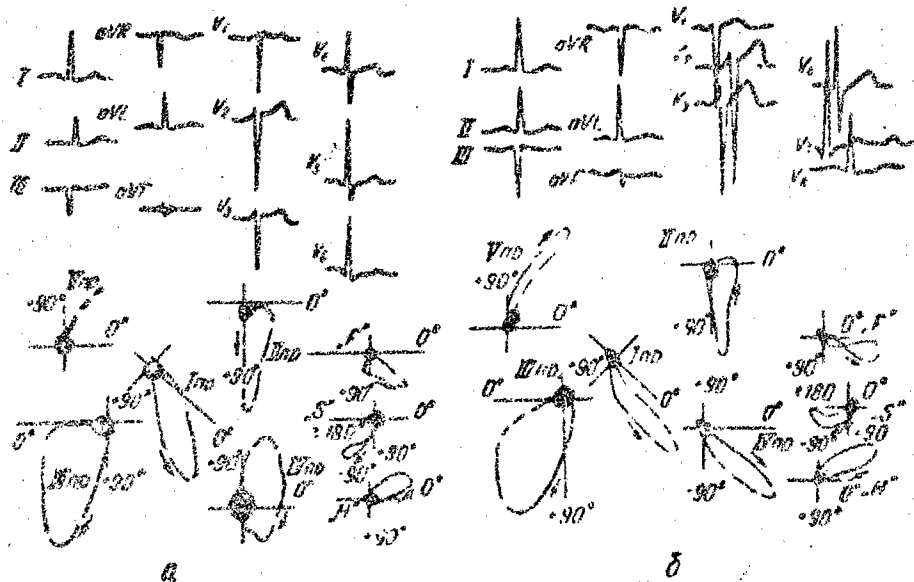
The patient entered the clinic again eight months later, in serious condition and with overt manifestations of renal insufficiency. Blood pressure ranged from 280/180 to 220/130 mm Hg.

ECG on August 23, 1958 (Figure 2b) showed deviation of the electrical axis of the heart somewhat to the left (angle alpha = -10 degrees); hypertrophy of the left ventricle, along with myocardial ischemia, had become more pronounced (Sv2 = 25 mm, Rv4 = 43 mm, Rv5 = 38 mm, S-TI, II, V4, 5, 6 slightly depressed).

Precordial vectorcardiogram (Figure 2b) showed the QRS loop to be oriented more horizontally (angle alpha₁ = +21 degrees) and more posteriorly (toward the fifth electrode, as seen in projection V). The arc (a) (projection III) became more sloping and started off lower

(which, as E. A. Kyandzhuntseva points out, is seen with progression of left ventricular hypertrophy). There was a marked increase in the area of the QRS loop (in projection III) to 15 sq. cm. This was larger than in the vectorcardiogram taken in 1957 (Figure 2a) and the slowing of the movement of the beam in the ascending loop was more marked. The QRS loop was open in all projections. The T loop in all projections was quite divergent from the QRS loop. Vectorcardiogram taken by the cube method (Figure 2b) showed increase in left ventricular hypertrophy. The area of the QRS loop (1.9 sq. cm.) and its maximum vector (25 mm) were much increased as compared with the preceding vectorcardiogram. The QRS loop was unclosed and was oriented away from the T loop.

The patient died November 23, 1958, with manifestations of increasing uremia and circulatory failure. Pathologic findings showed a heart weight of 650 gm, thickening of the wall of the left ventricle to 25 mm and of the right ventricle to five mm. There was dilatation of the chambers of the heart. Microscopic studies showed marked hypertrophy of the muscle fibers and of their nuclei.



NR = Projection

Figure 2

Hence, of the 30 patients in group II, 26 had vectorcardiograms which showed sufficient changes for

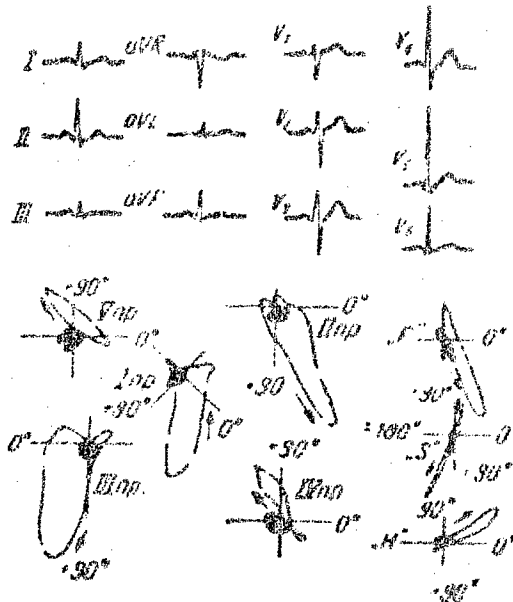
confirmation of the clinical opinion concerning the presence of left ventricular hypertrophy. In the other four cases, there was also evidence of left ventricular hypertrophy, but because of the absence of increase in the area of the QRS loop and in the maximum vector we considered the evidence not fully convincing. In the ECG and in the vectorcardiogram taken by the cube method, only 21 patients had adequate changes for diagnosis of left ventricular hypertrophy.

In analyzing the ECG and vectorcardiograms of the 13 patients in group I, we detected peculiarities inherent to them. The ECG of only three patients showed a moderate deviation of the electrical axis of the heart to the left, and only in four was there horizontal position of the electrical axis. Vectorcardiograms taken by both methods showed, in these cases, horizontal or intermediate position of the maximum vector of the QRS loop; only in one case was there a moderate deviation of the axis to the left. In the other six patients, we observed intermediate position both of the electrical axis of the ECG and of the maximum vector of the QRS loop. Deviation of the QRS loop posteriorly was observed in eight of 13 precordial vectorcardiograms, and in three vectorcardiograms there was moderate posterior deviation of the maximum vectors, as seen also in the normal. In vectorcardiograms taken by the cube method, the posterior deviation of the QRS loop was seen in eight of 12 cases.

In nine patients of 12, arc (a) was large and shifted posteriorly. The area of the QRS loop on the precordial vectorcardiograms was increased in six of 13 patients; only in one case was it less than the normal average. Vectorcardiograms taken by the cube method showed an increase in the area of the QRS loop only in three patients.

In a number of cases the first sign of myocardial hypertrophy in the left ventricle was either deviation of all QRS loops posteriorly or the presence of arc (a) directed posteriorly. But in a number of patients, even in the early stages of development of hypertrophy there was an increase in the area of the QRS loop. In vectorcardiograms taken by the cube method, in the frontal plane in seven patients of 12, i.e., less often than in patients of group II but more often than normal, there was counter-clockwise rotation of the tracing beam. The QRS loop of the precordial vectorcardiogram was closed in 12 of 13

patients. The T loop diverged from the QRS loop in different projections in only three patients.



VR = Projection

Figure 3

Hence, of 13 patients of group I, in eight there was evidence in the precordial vectorcardiogram of left ventricular hypertrophy, whereas in the ECG there was such evidence in only two of 12 patients, and only in five of 12 on vectorcardiograms taken by the cube method.

Let us give an example.

Patient I., 20 years old. For a year the patient had been ill with chronic nephritis. The blood pressure fluctuated from 125/85 to 180/95 mm Hg. There was constriction of the retinal arteries. X-ray studies showed the heart not to be enlarged, but to have a rounded configuration.

ECG on June 5, 1958 (Figure 3) showed intermediate position of the electrical axis of the heart (angle $\alpha = +46$ degrees); there was no evidence of left ventricular hypertrophy. Vectorcardiogram (Figure 3) showed significant increase in the area of the QRS loop with decrease in the maximum vector.

Vectorcardiogram taken by the cube method showed the QRS loop to be increased (0.25 sq. cm.) and the sagittal projection to be deviated posteriorly (angle α = +111 degrees).

Upon analysis of the ECG and the vectorcardiograms of patients in group III, certain peculiarities were noted which were most likely associated with fibrosis of the myocardium. Most obvious was a marked shift of the majority of the vectors to the left. The maximum vector of projection I of the QRS loop was deviated to the left of zero in seven patients; in the other nine patients it was situated between zero and +12 degrees. Considerably further to the left was the electrical axis of the ECG, which in four patients was further left than -30 degrees and in five was between zero and -30 degrees. In 15 of 16 patients the QRS loop of the vectorcardiogram was deviated posteriorly, more so than in patients in groups I and II. Posteriorly shifted arcs (a) of the QRS loops were detected in ten patients, but were slanted and were situated more distally. In eight patients the QRS loops were narrow, and there was often crossing of the trace.

The area of the QRS loop of the vectorcardiogram in patients of group III was less than in patients of group II. The area of the largest QRS loop in group III was 5.2 sq. cm. Only in six of the 16 patients was the QRS loop larger than normal. Increase in the maximum vector of the QRS loop of the precordial vectorcardiogram was seen in nine patients. The QRS loop was unclosed in ten patients. The T loop was discordant from the QRS loop in eight patients.

Conclusions

(1) The basic vectorcardiographic signs characteristic of all stages of development of myocardial hypertrophy of the left ventricle are as follows: increase in the area of the QRS loop and in the length of its maximum vector, orientation of the QRS posteriorly and slightly to the left or horizontally, and the presence of arc (a), shifted posteriorly, on the ascending curve of the QRS loop. For all periods in the development of left ventricular hypertrophy, except for the very earliest, failure of closure of the QRS loop and discordance of the QRS and T loops are characteristic.

(2) The vectorcardiogram, more frequently than the

ECG, aids in diagnosing hypertrophy of the left ventricle, especially in the early stages of its development. The vectorcardiogram is capable of providing a characterization of the degree of development of hypertrophy and of the increase in dilatation of the heart chambers.

(3) The method of choice, in our opinion, is the method of precordial vectorcardiography, which is more sensitive to changes in the bulk of the myocardium than is the cube method.

Bibliography

Akulnichev, I. T., "Klin. Med." [Clinical Medicine], 1950, No. 10, 64

Akulnichev, I. T., "Voyen.-Med. Zhurn." [Military Medical Journal], 1956, No. 1, 79

Kechker, M. I., Shurgaya, Sh. I., "Klin. Med.", 1958, No. 8, 87

Kechker, M. I., "Ter. Arkh." [Therapeutic Archives], 1960, No. 2, 65

Myasnikov, A. L., "Hypertension", Moscow, 1954

Grant, R. P., Clinical Electrocardiography. The Spatial Vector Approach, New York, 1957

Klepzig H., Doll E., Reidel H., Ztschr. Kreislauforsch., 1955, Bd. 44, S. 36.

Mougin, M., Milovanovich J. B., Pouret P., 3e Congrès Mondial de Cardiologie. Resumés des Communications. Bruges, 1958, p.423.

Sodi-Pallares D., New Bases of Electrocardiography. London, 1956.

Wenger, R., Klinische Vektorkardiographie. Darmstadt, 1956.

Received 16 June 1959