

AD \_\_\_\_\_

Award Number: DAMD17-96-C-6111

TITLE: Real-Time Full-Field Direct Digital Telemammography

PRINCIPAL INVESTIGATOR: Edward A. Sickles, M.D.

CONTRACTING ORGANIZATION: University of California, San Francisco  
San Francisco, California 94143-0962

REPORT DATE: October 1999

TYPE OF REPORT: Annual

PREPARED FOR: U.S. Army Medical Research and Materiel Command  
Fort Detrick, Maryland 21702-5012

DISTRIBUTION STATEMENT: Approved for public release  
distribution unlimited

The views, opinions and/or findings contained in this report are those of the author(s) and should not be construed as an official Department of the Army position, policy or decision unless so designated by other documentation.

**DISC QUALITY INSPECTED 4**

# REPORT DOCUMENTATION PAGE

Form Approved  
OMB No. 074-0188

Public reporting burden for this collection of information is estimated to average 1 hour per response, including the time for reviewing instructions, searching existing data sources, gathering and maintaining the data needed, and completing and reviewing this collection of information. Send comments regarding this burden estimate or any other aspect of this collection of information, including suggestions for reducing this burden to Washington Headquarters Services, Directorate for Information Operations and Reports, 1215 Jefferson Davis Highway, Suite 1204, Arlington, VA 22202-4302, and to the Office of Management and Budget, Paperwork Reduction Project (0704-0188), Washington, DC 20503

1. AGENCY USE ONLY (Leave blank)	2. REPORT DATE October 1999	3. REPORT TYPE AND DATES COVERED Annual (16 Sep 98 - 15 Sep 99)
----------------------------------	--------------------------------	--

4. TITLE AND SUBTITLE Real-Time Full-Field Direct Digital Telemammography	5. FUNDING NUMBERS DAMD17-96-C-6111
--	--

6. AUTHOR(S) Edward A. Sickles, M.D.
---

7. PERFORMING ORGANIZATION NAME(S) AND ADDRESS(ES) University of California, San Francisco San Francisco, California 94143-0962  e-mail: edwards@email.his.ucsf.edu	8. PERFORMING ORGANIZATION REPORT NUMBER
--	---

9. SPONSORING / MONITORING AGENCY NAME(S) AND ADDRESS(ES) U.S. Army Medical Research and Materiel Command Fort Detrick, Maryland 21702-5012	10. SPONSORING / MONITORING AGENCY REPORT NUMBER
--	---

11. SUPPLEMENTARY NOTES

12a. DISTRIBUTION / AVAILABILITY STATEMENT Approved for public release distribution unlimited	12b. DISTRIBUTION CODE
---	------------------------

13. ABSTRACT (*Maximum 200 Words*)

This research investigates an important application of full-field direct digital mammography (FFDDM): telemammography, the electronic transfer of digital mammography images to remote viewing sites. This should permit radiologists with great interpretive expertise to manage and read in real time *all* mammography examinations in a multiple-site practice, an approach superior to either deferred interpretation by expert readers or real-time interpretation by general radiologists. We have completed the acquisition of a large data set of FFDDM cases and demonstrated that remote interpretation of these images by expert mammographers is as effective (slightly better, but difference not statistically significant) as conventional film interpretation by general diagnostic radiologists. By showing that telemammography technology can be developed for routine clinical operation, and that real-time off-site management and interpretation of a general-radiologist mammography practice by mammography specialists is feasible as standard operating procedure (data analysis still in progress), we expect to establish telemammography applications of digital radiography as both valid and useful. The application of these procedures to routine mammographic examinations should bring to bear the expertise of mammography specialists at the community-practice general-radiologist level. This should benefit all women undergoing mammography in the future.

14. SUBJECT TERMS Mammography, breast imaging, digital radiography, teleradiology, breast cancer	15. NUMBER OF PAGES 51
	16. PRICE CODE

17. SECURITY CLASSIFICATION OF REPORT Unclassified	18. SECURITY CLASSIFICATION OF THIS PAGE Unclassified	19. SECURITY CLASSIFICATION OF ABSTRACT Unclassified	20. LIMITATION OF ABSTRACT Unlimited
--	---	--	---

## FOREWORD

Opinions, interpretations, conclusions and recommendations are those of the author and are not necessarily endorsed by the U.S. Army.

\_\_\_\_\_ Where copyrighted material is quoted, permission has been obtained to use such material.

\_\_\_\_\_ Where material from documents designated for limited distribution is quoted, permission has been obtained to use the material.

\_\_\_\_\_ Citations of commercial organizations and trade names in this report do not constitute an official Department of Army endorsement or approval of the products or services of these organizations.

\_\_\_\_\_ In conducting research using animals, the investigator(s) adhered to the "Guide for the Care and Use of Laboratory Animals," prepared by the Committee on Care and use of Laboratory Animals of the Institute of Laboratory Resources, national Research Council (NIH Publication No. 86-23, Revised 1985).

*EAD* ✓ \_\_\_\_\_ For the protection of human subjects, the investigator(s) adhered to policies of applicable Federal Law 45 CFR 46.

\_\_\_\_\_ In conducting research utilizing recombinant DNA technology, the investigator(s) adhered to current guidelines promulgated by the National Institutes of Health.

\_\_\_\_\_ In the conduct of research utilizing recombinant DNA, the investigator(s) adhered to the NIH Guidelines for Research Involving Recombinant DNA Molecules.

\_\_\_\_\_ In the conduct of research involving hazardous organisms, the investigator(s) adhered to the CDC-NIH Guide for Biosafety in Microbiological and Biomedical Laboratories.

*Edward A. Pickles*

PI - Signature

*9/24/99*

Date

## TABLE OF CONTENTS

Front Cover.....	1
SF 298 Report Documentation Page.....	2
Foreword.....	3
Table of Contents.....	4
Introduction.....	5
Body.....	6
Key Research Accomplishments.....	9
Reportable Outcomes.....	9
Conclusions.....	10
References.....	10
Appendix.....	11

## INTRODUCTION

Current attempts at controlling breast cancer concentrate on early detection by means of mass screening, using periodic mammography and physical examination, because ample evidence is now available to indicate that such screening indeed can be effective in lowering the death rate.

Screen-film mammography has several technical limitations which reduce its effectiveness, most of which can be overcome by full-field direct digital mammography (FFDDM) [1,2]. The principal theoretical advantage of FFDDM comes from decoupling image display from the image receptor. This permits the digital image to be captured electronically, stored digitally, and then manipulated, analyzed, and displayed however, whenever, and wherever it is needed. Practical applications of FFDDM currently under development include: real-time image display, post-acquisition image enhancement, image archival and retrieval, dual-energy subtraction imaging, computer-aided diagnosis, and computer-aided instruction.

This research will investigate still another application of digital breast imaging: teleradiology mammography, or telemammography [1,2]. Electronic transfer of digital images to remote viewing sites can be accomplished almost as rapidly as between the standard display workstation and computer storage. Radiologists who work in several different offices or hospitals will be able to monitor and interpret examinations that are carried out in a nearby or even at distant location or locations. This will permit those radiologists with the greatest interpretive expertise to manage and read in real time *all* mammography examinations, an operational procedure far superior to the alternative of choosing between deferred interpretation by expert readers or real-time interpretation by general radiologists [3,4]. In addition, mammography screening in mobile units will be made more efficient, not only by overcoming the need to transport films from the site of examination to the site of interpretation, but also by permitting image interpretation while patients are still available for repeat or additional exposures. Telemammography can also be used to facilitate second-opinion interpretation, in effect making world-class mammography expertise immediately accessible to community-practice radiologists. Finally, digital image transmission can be the cornerstone upon which multi-site teaching conferences are built, from applications as simple as the simultaneous conduct of teaching rounds among the nearby hospitals that participate in a residency training program to intercontinental multi-institution conferences supported by satellite transmission of digital mammograms.

The majority of the clinical activities of the breast imaging service at our institution take place in the Breast Imaging Section of UCSF/Mt. Zion Medical Center, staffed by full-time breast imaging specialists. Additional mammography examinations are done at the UCSF/Parnassus Ambulatory Care Center (ACC), staffed by general diagnostic radiologists. During the conduct of this study, the UCSF/Mt. Zion Medical Center will serve as the site of great interpretive expertise, whereas the UCSF/Parnassus ACC will be a satellite site staffed by general radiologists.

By demonstrating that [a] telemammography technologies can be developed for routine clinical operation, and [b] that real-time off-site management and interpretation of a general-radiologist mammography practice by mammography specialists is feasible as standard operating procedure, we will help to establish telemammography applications of

digital radiography as both valid and useful. The application of these procedures to routine mammographic examinations should contribute to more efficient and higher quality breast imaging, by bringing to bear the expertise of mammography specialists at the community-practice general-radiologist level. This should benefit all women undergoing mammography in the future.

## **BODY**

Seven tasks were outlined in the Statement of Work within our grant proposal. All of the Year 1 tasks were accomplished as initially planned. These involved the development of telemammography infrastructure: (a) creation of a telemammography network, (b) installation of the first (of two) FFDDM units at UCSF/Mt. Zion Medical Center, (c) development of a digital mammography display workstation (DMDW), and (d) integration of the above-described systems.

When we initially developed our digital mammography display workstation (DMDW), we planned on using images having a matrix of 4,095 x 5,120 (40-Mbyte per image). However, Fischer Imaging Corp. supplied us with an improved-image-quality second-generation FFDDM unit, which utilized an image area (4,095 x 5,625; 46-Mbyte per image) somewhat larger than that of their first-generation FFDDM unit. This increase in image file size affected our DMDW system memory capacity such that we were unable to simultaneously display eight digital images on the DMDW. However, during Year 2, we increased the amount of system memory installed in the DMDW from 384 Mbytes to 512 Mbytes, so that now we have no difficulty displaying simultaneously eight digital images on the DMDW.

During Year 1 and the first half of Year 2, we not infrequently experienced the problem of drop-out of image pixels when digital mammogram data were transmitted from the FFDDM imager to the capture computer. When this problem occurred, the capture computer system hung up, resulting in lack of completion of the mammogram to be stored onto disk, and inability to use the FFDDM images for subsequent analysis. We solved this problem by the end of the first half of Year 2, in part by upgrading our ATM software device driver. As a result, during the second half of Year 2, we have been able to acquire acceptable FFDDM images on virtually all patients recruited for the project.

As initially planned for completion in Year 2, we acquired more than 400 FFDDM cases employing the unit already installed at UCSF/Mount Zion Medical Center, for use in our telediagnosis protocol. The other major activity scheduled for Year 2 involved installation of a second FFDDM unit at the UCSF/Parnassus ACC and completion of the final telemammography chain to incorporate this second FFDDM unit into the existing network. However, because the manufacturer of our FFDDM equipment was unable to deliver the second unit during Year 2, we were unable to proceed apart from planning for space renovation at the ACC.

Since we needed to free up extra time in Year 3 to install our second FFDDM unit at the UCSF/Parnassus ACC and to establish the telemammography chain in its final form, we

chose to perform the telediagnosis protocol in Year 2, instead of performing it in Year 3 as initially planned. This was made possible because we had already acquired all the FFDDM cases required for the telediagnosis protocol before the end of the second half of Year 2. Note that this change in sequence of work in no way compromised the experimental design of the overall project, because the case material for telediagnosis was to be derived from FFDDM examinations performed at UCSF/Mount Zion Medical Center, and because the telediagnosis protocol had to be completed successfully before proceeding to the teleconsultation and telemanagement protocols.

As stated previously, we acquired more than 400 FFDDM cases from the UCSF/Mount Zion Medical Center. From these cases, we selected appropriate numbers of normal and abnormal cases for image interpretation study, according to the plan described in our grant proposal. Indeed, the entire telediagnosis procedure was carried out exactly as described in the grant proposal. The aim of the telediagnosis protocol was to evaluate the accuracy of interpretation of transmitted FFDDM images by expert mammographers as compared to the interpretation of conventional film mammograms by general diagnostic radiologists. We imposed identical controls on viewing conditions for both conventional film mammograms and FFDDM images to eliminate environmental discrepancies in image interpretation. We also utilized our established image quality criteria for both conventional film and FFDDM images to eliminate the possibility that image quality discrepancies might bias interpretation. Results of the image interpretation study indicated that both sensitivity and specificity were somewhat higher (improved) for FFDDM interpretation than for conventional film interpretation. These differences were not statistically significant. We therefore can conclude that interpretation of transmitted FFDDM images by expert mammographers is no less accurate than that of conventional film mammograms by general diagnostic radiologists. This basic observation permitted us to proceed with our planned teleconsultation and telemanagement protocols, both of which were designed to establish the utility of telemammography applications in routine clinical practice.

Installation and networking of our second FFDDM unit at the UCSF/Parnassus ACC was completed by the end of the first quarter of Year 3 of the project. However, the primary activity performed during Year 3 was the acquisition of the remaining cases needed for study, and performance of our teleconsultation and telemanagement protocols. The teleconsultation protocol tests the clinical effectiveness of digital mammography consultation between general radiologists and expert breast-imaging radiologists, using selected difficult mammography cases. The aim here is to evaluate the ability of telemammography to facilitate real-time consultation between on-site general diagnostic radiologists and remotely-located expert breast-imaging radiologists. The telemanagement protocol tests the effectiveness of remote real-time interpretation and management of digital mammography examinations by expert breast-imaging radiologists (versus real-time on-site interpretation and management of conventional screen-film mammograms by general diagnostic radiologists). If telemanagement succeeds, this will permit the replacement of on-site general radiologists with remotely-located expert breast-imaging radiologists.

In the middle of Year 3, it became apparent that although we would be able to acquire all the case material needed for study, that we would not be able to complete all the data analysis. We therefore applied for, and were granted, a one-year no cost extension for our project (from Mr. Wayne Hoffman, Director, Contracts Office, USAMRMC). Hence, this report is submitted as an annual report rather than as a final report. The remainder of data analysis will be completed during Year 4, at no cost to the USAMRMC.

We now discuss the current status of each of the seven tasks within the Statement of Work in our grant proposal.

**Task 1. Set up the first FFDDM system at UCSF/Mount Zion Medical Center.** By the end of Year 1, we had completed all six components of this task, as reported in the annual report for Year 1, which was judged “acceptable as written”.

**Task 2. Telemammography chain – part 1.** By the end of Year 1, we had completed all five components of this task, as reported in the annual report for Year 1, which was judged “acceptable as written”.

**Task 3. Installation of the second FFDDM system at the UCSF/Parnassus ACC.** During Year 2, we completed planning for space renovation at the ACC [part of sub-task (a)]. The remainder of the installation of our second FFDDM system was completed by the end of the first quarter of Year 3.

**Task 4. Telemammography chain – part 2.** By the end of the first quarter of Year 3, we had completed all five components of this task.

**Task 5. Telediagnosis.** All five components of the telediagnosis protocol were completed in Year 2, rather than in Year 3 as initially planned. This was reported in the annual report for Year 2, which was judged “acceptable as written”.

**Task 6. Teleconsultation.** As indicated in our initial grant proposal, this activity had been planned for execution and completion during Year 3. By the end of Year 3, we had completed the selection of case material [sub-task (a)], “truth” determination [sub-task (b)], retrieval of ACC film mammograms for viewing at ACC [sub-task (c)], and establishment of satisfactory communication between FFDDM display workstations at ACC and Mount Zion [sub-task (d)]. However, because the acquisition of FFDDM case material was not completed until close to the end of Year 3, there has not been enough time to complete the data analysis for this protocol, which requires utilization of *all* of the case material (not just the earlier-acquired case material). The remainder of data analysis [sub-tasks (e), (f), and (g)] will be completed in Year 4.

**Task 7. Telemanagement.** As indicated in our initial grant proposal, this activity had been planned for execution and completion during Year 3. By the end of Year 3, we had completed the selection of case material [sub-task (a)] and set up of the telemanagement protocol [sub-task (b)]. However, because the acquisition of FFDDM case material was

not completed until close to the end of Year 3, there has not been enough time to complete the data analysis for this protocol, which requires utilization of *all* of the case material (not just the earlier-acquired case material). The remainder of data analysis [sub-tasks (c), (d), (e), (f), and (g)] will be completed in Year 4.

## KEY RESEARCH OUTCOMES

- Successful installation of two FFDDM imagers, at separate sites within the same mammography practice
- Successful establishment of a telemammography chain between the two FFDDM sites, so that images from one site are interpreted in real time by radiologists at the other site
- Demonstration that interpretation of transmitted FFDDM images by expert mammographers is no less accurate than that of conventional film mammograms by general diagnostic radiologists (results show somewhat improved sensitivity and specificity for FFDDM, but they are not statistically significant)

## REPORTABLE OUTCOMES

There already have been five scientific publications of the work produced by our project. These are listed below, with full reference citations.

1. Lou SL, Sickles E, Huang HK, Cao F, Hoogstrate D, Jahangiri M. Full-field direct digital telemammography - preliminary. *SPIE Proc Med Imaging* 1997; 3035:369-379.
2. Huang HK, Lou SL, Sickles EA, Hoogstrate D, Jahangiri M, Cao F, Wang J. Technical issues in full-field direct digital telemammography. *In* Lemke HU, Vannier MW, Inamura K, eds. *Computer assisted radiology and surgery*. Amsterdam, Elsevier Science, 1997:662-667.
3. Lou SL, Sickles EA, Huang HK, Hoogstrate D, Cao F, Wang J, Jahangiri M. Full-field direct digital telemammography: technical components, study protocols, and preliminary results. *IEEE Transact Inform Tech Biomed* 1997; 1:270-278.
4. Lou SL, Huang HK, Sickles EA, Hoogstrate D, Cao F, Wang J. Full-field direct digital telemammography: system implementation. *SPIE Proc Med Imaging* 1998; 3339:156-163.
5. Zhang H, Lou SL, Hoogstrate D, Sickles EA, Huang HK, Wong A. DICOM image transmission for real-time telemanagement of full field digital mammography (FFDM). *SPIE Proc Med Imaging* 1999; 3662:225-230.

## CONCLUSIONS

Work on this project is proceeding, reasonably on schedule. By the end of Year 1 of the project, we installed the first of two full-field direct digital mammography (FFDDM) imagers, developed a digital mammography display workstation, and developed the infrastructure and began the clinical use of a telemammography chain between the Breast Imaging Section at UCSF/Mount Zion Medical Center and the Laboratory for Radiological Informatics at UCSF/Parnassus Medical Center, two miles apart. By the end of Year 2 of the project, we acquired a large data set of FFDDM cases and demonstrated that remote interpretation of these images by expert mammographers is as effective (slightly more effective, but difference not statistically significant) as conventional film interpretation by general diagnostic radiologists. By the end of Year 3 of the project, we installed the second FFDDM imager at the UCSF/Parnassus ACC and assembled the final telemammography chain. We also completed acquisition of all FFDDM cases required for performance of our teleconsultation and telemanagement protocols. However, since we were unable to complete data analysis for these two protocols, we applied for and were granted a one-year no cost extension for the project. Data analysis will be completed during Year 4. By the end of the project, we expect to demonstrate that [a] telemammography technology can be developed for routine clinical operation, and [b] that real-time off-site management and interpretation of a general-radiologist mammography practice by mammography specialists is feasible as standard operating procedure, thus helping to establish telemammography applications of digital radiography as both valid and useful. The application of these procedures to routine mammographic examinations should contribute to more efficient and higher quality breast imaging, by bringing to bear the expertise of mammography specialists at the community-practice general-radiologist level. This should benefit all women undergoing mammography in the future.

## REFERENCES

- [1] Sickles EA. Current status of digital mammography. *In* Ioannidou-Mouzaka L, Agnantis NJ, Karydas I, eds. *Senology. Proceedings of the 7th International Congress on Senology*. Amsterdam, Excerpta Medica/Elsevier Science Publishers, 1992:23-28.
- [2] Huang HK. *Elements of digital radiology; a professional handbook and guide*. New Jersey, Prentice-Hall, 1987.
- [3] Sickles EA, Ominsky SH, Sollitto RA, Galvin HB, Monticciolo DL. Medical audit of a rapid throughput mammography screening practice: methodology and results of 27,114 examinations. *Radiology* 1990; 175:323-327.
- [4] Sickles EA. Quality assurance: how to audit your own mammography practice. *Radiol Clin North Am* 1992; 30:265-275.

## **APPENDIX**

There have been five scientific publications of the work produced by our project. These are appended to this annual report, as follows.

# Full-Field Direct Digital Telemammography -- Preliminary

S.L. Lou, Edward Sickles, H.K. Huang, Fei Cao, David Hoogstrate, Mohammad Jahangiri

Laboratory for Radiological Informatics  
Department of Radiology, University of California San Francisco,  
530 Parnassus Avenue, Rm. CL-158, San Francisco, CA 94143-0628

## ABSTRACT

Full-field direct digital mammography has many advantages over the conventional film/screen imaging detector. Among these are larger dynamic range, lower scattering noise, and the possibility of using it for telemammography applications to alleviate the shortage of expert mammographers. We are in the process of developing a full-field direct digital telemammography imaging chain to investigate its usefulness for telediagnosis, teleconsultation, and telemanagement.

This paper describes the first phase of a three-year research program to set up a full-field direct digital mammography (FFDDM) imaging chain at the Breast Imaging Section connecting the University of California, San Francisco Medical Center and the Mt. Zion Hospital in the San Francisco Bay area. The chain consists of two FFDDM system (Fischer Imaging, Denver, CO), and two 2,500 (2K) line two-monitor workstations (VICOM, Fremont, CA). An OC-3 155 Mbits/sec asynchronous transfer mode (ATM) communication network (Pacific Bell, San Francisco, and FORE, Warrendale, PA) is used to connect the FFDDM and the two workstations. The FFDDM is based on a slot scan CCD detector which can image a full breast with 3,100 x 3,870 pixels (12 bits), and produce a direct digital image with 50 micron pixel size.

Preliminary results of the FFDDM demonstrate that it has a greater dynamic range and lower detector noise than that of a film-screen detector, and that the scattered radiation is reduced without using a grid. However, the spatial resolution is less than that of the conventional screen/film system. The 2K workstation can display simultaneously any two or four full-view mammographic images by either scrolling or subsampling on the two monitors. Display of an image takes about 1.5 seconds from the RAID disks. The ATM can transmit a 32 Mbyte digital mammogram from the FFDDM to the workstation in 3-4 seconds.

This paper also describes the three research protocols in telediagnosis, teleconsultation, and telemanagement.

**Key Words:** Digital mammography, teleradiology, high resolution display, asynchronous transfer mode, breast imaging

## 1. BACKGROUND

Breast cancer is the fourth most common cause of death among women in the United States [1]. There is no known means of preventing the disease, and available therapy has been unsuccessful in reducing the national mortality rate over the past 60 years. Current attempts at controlling breast cancer concentrate on early detection by means of mass screening, using periodic mammography and physical examination, because ample evidence is now available to indicate that such screening indeed can be effective in lowering the death rate.

Film-screen mammography has certain technical limitations which reduce its effectiveness: the film gradient must be balanced against the need for wide latitude and detection of microcalcifications. In addition, portrayal of the clarity of the margins of breast masses are reduced due to the presence of film noise in the displayed image, film processing artifacts can degrade the mammographic image, and the day-to-day variability inherent in automated film processors can produce suboptimal image quality.

Early digital mammography applications acquired data by digitizing conventional mammography films. This approach severely limits the potential of digital mammography since the resultant images can contain no more radiographic information than do the standard films from which they are produced. Indeed, most current digital images are slightly inferior

in quality to their corresponding parent films, accounting in no small part for the general lack of clinical acceptance of digital mammography applications.

Direct digital mammography can overcome most of these problems, at the same time providing additional features not available with standard mammographic imaging [2]. During the past several years, due to the concentrated efforts from the National Cancer Institute and the United States Army Medical Research and Development Command, some prototype direct digital mammography systems are being developed by the jointed effort between academic institutions and the private industry. Some of these systems are ready for clinical evaluation [3]. Our full-field direct digital telemammography research program utilizes one of these prototype systems [4].

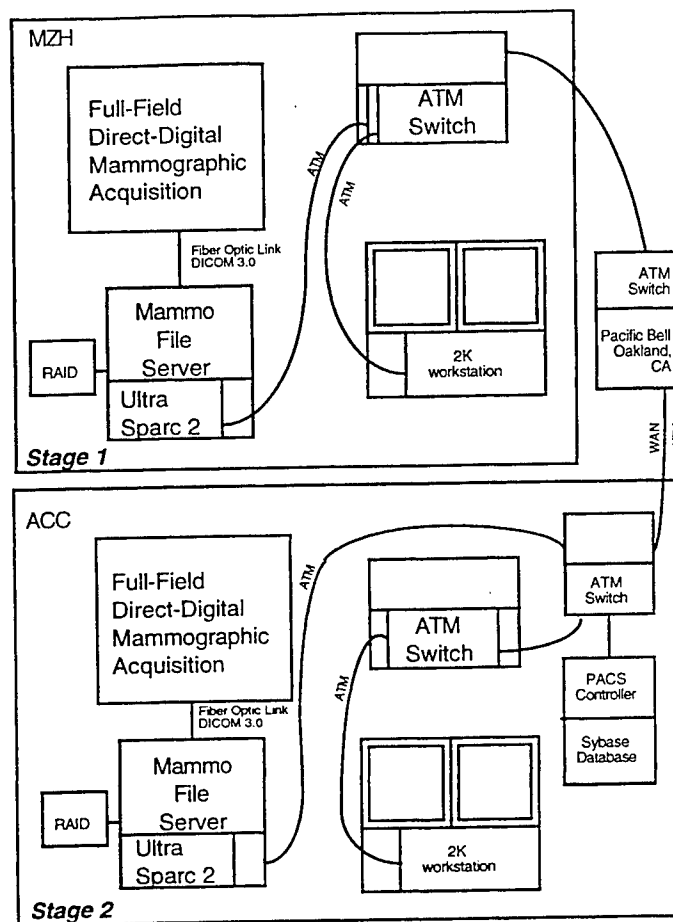
A major component in a digital mammography system is the image display. The basic requirement for general use is the ability to portray the entire breast with such fine detail that tiny structures, such as malignant microcalcifications, are readily visible. Furthermore, since routine mammographic interpretation involves four images of a current examination compared with four images from a prior examination, digital workstations either must include at least eight monitors or utilize monitors providing sufficiently fine detail that two or more whole-breast mammograms are displayed per monitor [5]. The principal theoretical advantage of direct digital mammography comes from decoupling image display from the image receptor. This permits the digital image to be captured electronically, stored digitally, and then manipulated, analyzed, and displayed however, whenever, and wherever it is needed.

Our research aims to explore teleradiology mammography, or telemammography applications. Electronic transfer of digital images to remote viewing sites can be accomplished almost as rapidly as between the standard display workstation and computer storage [6]. Numerous activities utilizing teleradiology have been devised, many of which are clearly applicable to mammography practice [7]. Radiologists who work in several different offices or hospitals will be able to monitor and interpret examinations that are carried out in a nearby or even at distant location or locations. This will permit those radiologists with the greatest interpretive expertise to manage and read in real time all mammography examinations, an operational procedure far superior to the alternative of choosing between deferred interpretation by expert readers or real-time interpretation by general radiologists [8,9]. Real time is defined in this context as a very rapid turnaround time between examination and interpretation. In addition, mammography screening in mobile units will be made more efficient, not only by overcoming the need to transport films from the site of examination to the site of interpretation, but also by permitting image interpretation while patients are still available for repeat or additional exposures. Furthermore, telemammography can be used to facilitate second-opinion interpretation, in effect making world-class mammography expertise immediately accessible to community-practice radiologists.

This paper describes the first phase of a three-year research program to set up a full-field direct digital telemammography chain (FFDDM).

## 2. THE TELEMAMMOGRAPHY CHAIN

The first phase goal is to set up a telemammography chain at the University of California, San Francisco (UCSF) Medical Center, between the comprehensive breast imaging service at UCSF-Mt Zion Hospital (MZH) and the outpatient mammography service at the UCSF-Ambulatory Care Center (ACC), with the former as the diagnostic center and the latter as the satellite site. Figure 1 shows the FFDDM telemammography. The instrumentation of setting up a real-time telemammography chain are in two stages: stage 1 is to set up a real-time local area network (LAN) with asynchronous transfer mode (ATM) technology within MZH [10], using the first full-field direct digital mammography (FFDDM) unit; stage 2 is to set up a real-time wide area network (WAN) ATM between MZH and ACC with a second FFDDM unit via the existing picture archive and communication system (PACS) infrastructure [10]. The distance between these two sites is approximately two miles.



**Figure 1** Systematic diagram of the real-time FFDDM tele mammography chain

### Full-Field Direct Digital Mammography (FFDDM)

We formed a collaborative research partnership with Fischer Imaging Corporation (Denver, CO). Fischer provides the FFDDM units and engineering support and we concentrate our effort in the tele mammography chain including the system software, softcopy display, and patient research protocols. Table 1 shows the current specifications of the FFDDM.

#### Image Data Base

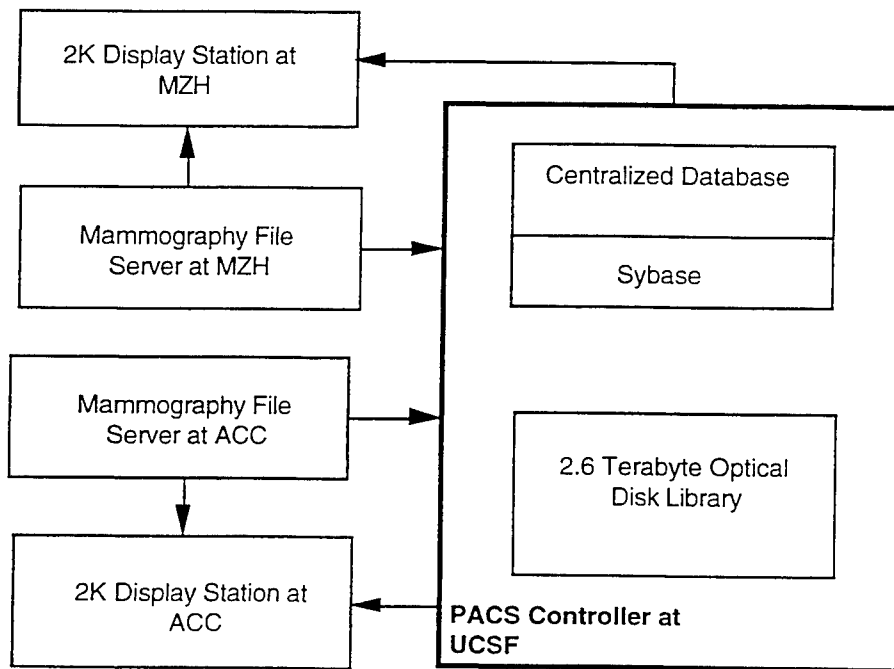
FFDDM images in DICOM 3.0 format is managed by the mammography file server (MFS). The two MF servers are in turn connected to an existing PACS centralized data base management system consisting of [10]:

- 1) An image archive system composed of an archive server (SUN SPARCserver 690MP, SUN Microsystems, Mountain View, CA), with a 2.6 terabyte optical library (Cranel, Ohio).
- 2) A mirrored relational data base server Sybase (Emeryville, CA), with a structured query language (SQL) running on two SUN SPARCserver 10.

All FFDDM images acquired is managed by this centralized data base. Figure 2 shows the connection of the two MF servers and the centralized data base.

**Table 1 Specification of the Fischer FFDDM System**

Image Area	193 x 240 mm
Detector	Charge-coupled devices (CCD)
Image Scan Time	slot scan, 4.5 secs (nominal)
kV Range	25-50 kVP
Tube Current	200 mA at 45 kVP
Focal Spot Size	0.30 mm (nominal)
Pixel Size	Nominal Mode: 62 x 62 microns (High res.): 31 x 31 microns
Image Matrix	3,100 x 3,870 pixels (nominal), 12 bits/pixel
Image Size	24 Mbytes
Spatial Resolution	8 lp/mm (nominal), 16 lp/mm (High Res.)
Detective Quantum Eff.	less than or equal to 50% at f(0)
Scatter-to-Primary	less than or equal to 0.15



**Figure 2 Dataflow between the two mammography file servers and the centralized database.**

**Image Communication between MZH and ACC**

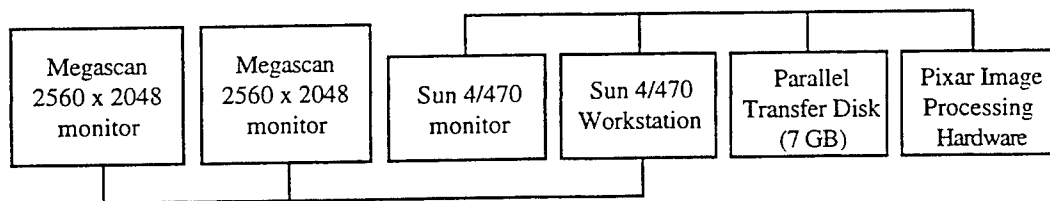
We use the asynchronous transfer mode (ATM) OC-3 for both WAN and LAN with the T-1 and Ethernet as the back-up networks. Table 2 shows the time required to send a 10MB (2K X 2.5K X 2 bytes) and 40MB (4K X 5K X 2 bytes) FFDDM image from MZH to ACC using T1 and ATM. With this ATM communication speed, the utility of real-time telemammography can be realized.

**Table 2 Time Required to send an 10 MB, 40 MB FFDDM Image from MZH to ACC using T1 and ATM (OC3) (No Compression)**

	2K x 2.5K x 2 bytes (10 MB)		4K x 5K x 2 bytes (40 MB)	
	One image	One exam 4 images	One image	One exam 4 images
T1 (1.5 mbits/s) realization 100 KB/s	100 sec (1.6 min)	400 sec (6.7 min.)	400 sec (6.7 min.)	1,600 sec (26.7 min.)
ATM (155 mbits/s) realization 60-70 mbits/s (7.5 MB/s)	1.3 sec	5.3 sec	5.3 sec	21.3 sec

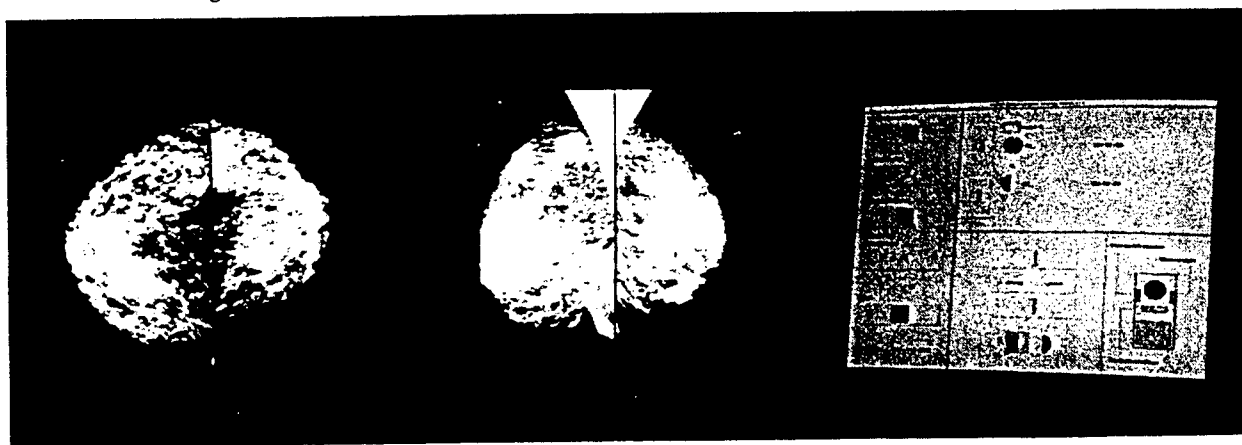
**Image Display**

The soft copy display is based on a two monitor 2K station by VICOM (Fremont, CA). This display station was specially designed for mammographic soft copy display. We began to use this system for digital mammography teaching file display in September 1994 [11,12]. The hardware architecture is shown in Figure 3. A digital mammogram can either be displayed as a subsampled 2K X 2.5K image or as a quadrant of the full-resolution 4K X 5K image on each of the two monitors. Figure 4 shows the 2K system with four subsampled images.

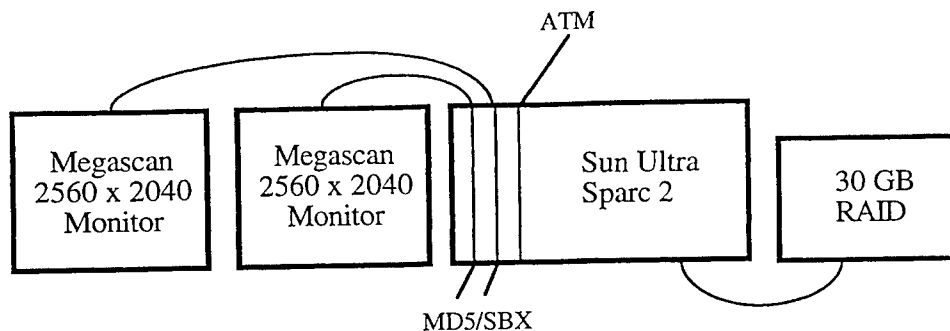


**Figure 3 Architecture of the existing 2K display workstation used for this study [11].**

Since this system uses five-year old technology, we are porting the software to the Ultra Sparc 2 platform with two DOME MD5/SBX boards. Figure 5 shows the block diagram of this new display system.



**Figure 4 The 2K Station Showing four Subsampled Mammograms**

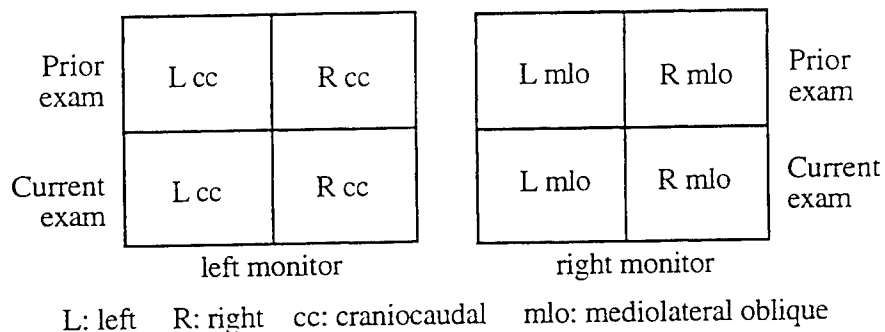


**Figure 5 Schematic of the new 2K mammography display workstation**

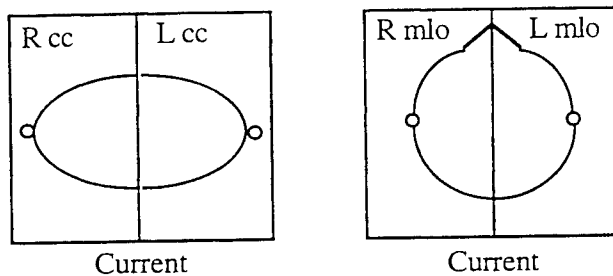
**Display Modes**

A standard mammographic examination consists of a craniocaudal and mediolateral oblique view of each breast, a total of four images per examination. For comparison purposes, four images from a prior examination of similar views are also used. Therefore, an optimal display mode shows eight images in proper orientation with one key stroke. Since two 2K image monitors is used for this study, we are developing display software to partition the two monitors into the following two configurations shown in Figure 6.

**Configuration 1: Four Images per Monitor**



**Configuration 2: Two Images per Monitor with a Rapid Paging Toggle Switch**



**Figure 6 Display Mode (1) Four Images Per Monitor; (2) Two Images Per Monitor**

A disadvantage of the first configuration is that each image will be limited to 1K x 1K pixels. To remedy this drawback we also developed a toggle switch in the display station allows the cursor-selected display of a 2K x 2K image on the other monitor that does not show the selected image in 1K x 1K format. A display program also allows the use of a 2K monitor to display a portion of a 4K image by using a scroll function.

The second configuration takes advantage of the fact that most breast images can be fitted into a narrow rectangle. Thus, we can split the 2K x 2K monitor in two 2K x 1K display areas. Four subsampled size images with proper cropping can be displayed at one time. With the hardware configuration, we can develop rapid paging software to switch current to prior examination images of the right or the left breast within 1.5 second. Again, an option can also be used to scroll a 4K image.

#### **Optimization of Visual Image Quality**

Image pre-processing is necessary to optimize the presentation of both the spatial and gray level data display on the display station. We developed three functions for special display of digital mammograms. The first algorithm optimizes the default brightness and contrast of FFDDM images presented on the display station. A preprocessing algorithm determines the histogram of each image. The 5% and 95% cumulative histogram values is used to generate the initial mean and window for the display of these images.

The second algorithm blackens all pixels beyond the x-ray collimators and outside the boundaries of the radiation field. An edge detection algorithm automatically delineates the boundaries of the radiation field. These boundaries are tested to determine if any portion of the radiation field has been excluded based on gray value deviation -- background is characterized by low deviations and the radiation field is characterized by higher deviations. The third algorithm automatically corrects the orientation of the mammogram based on left versus right side as well as specific mammographic projection.

### **3. RESEARCH PROTOCOLS**

Our research in telemammography investigates three protocols in telediagnosis, teleconsultation and telemanagement. To complete these protocols will take three years. In this section, we summarize these protocols with emphasis in case selection and the "truth" determination.

#### **Telediagnosis**

This protocol tests the clinical effectiveness of telemammography from image transmission of full-field direct digital mammograms versus on-site interpretation of conventional film-screen mammograms.

Normal and abnormal cases are acquired from mammographic examinations done at MZH involving both film-screen and full-field direct digital images. For abnormal cases, a study is considered to be the craniocaudal and mediolateral oblique views of the abnormal breast (both the film-screen and full-field direct digital mammograms) taken in a single procedure. For normal cases, a study is considered to be the craniocaudal and mediolateral oblique views of one of the normal breasts (both the film-screen and full-field direct digital mammograms) taken in a single procedure. Case selection is made by a highly skilled mammographer based on the interpretation of bilateral film-screen mammograms by that mammographer. Putatively normal cases is selected from a pool of current bilateral film-screen mammography examinations for which we also have normal mammograms in our files from at least 2 years previously. An effort is made to select abnormal cases which in the opinion of the mammographer are considered subtle. The "truth" of the abnormal and normal cases is determined by subsequent pathologic diagnosis if biopsy is performed, or (for normal cases) by subsequent demonstration of mammographic stability over the next 2 years.

A total of four hundred (400) cases will be collected, so that a range of 40% - 60% of normal-versus-abnormal cases are included in the study. Comparison is made between interpretation of film-screen images and interpretation of transmitted FFDDM images using either the monitor display or 4K x 5K laser-printed hard copy. The procedure is as follows:

1. Film-screen mammograms is interpreted by general diagnostic radiologists at ACC.
2. At the diagnostic center (MZH), radiologists with expertise in mammography makes diagnoses of transmitted full-field direct digital images using soft copy display and laser-printed hard copy. Neither group of radiologist-interpreters has access to knowledge of the proportion of normal to abnormal cases in the test set.
3. Diagnostic results from both MZH and ACC is tabulated with respect to the known abnormal and normal cases shown in Table 3.

**Table 3 Comparison Between MZH Radiologists and ACC Mammographers' Performance**

ACC (1)	MZH (2)	TRUTH			
		Abnormal		Normal	
		Frequency	Probability	Frequency	Probability
Abnormal	Abnormal	N <sub>11</sub>	P <sub>11</sub>	N <sub>01</sub>	P <sub>01</sub>
Abnormal	Normal	N <sub>12</sub>	P <sub>12</sub>	N <sub>02</sub>	P <sub>02</sub>
Normal	Abnormal	N <sub>13</sub>	P <sub>13</sub>	N <sub>03</sub>	P <sub>03</sub>
Normal	Normal	N <sub>14</sub>	P <sub>14</sub>	N <sub>04</sub>	P <sub>04</sub>
<b>Total</b>			$\pi$		$1 - \pi$

Where P<sub>11</sub> is the probability of both ACC radiologists and MZH mammographers diagnosed the "true abnormal" cases as abnormal; P<sub>12</sub> is the probability of the ACC radiologists diagnosed the "true abnormal" cases as abnormal, whereas the MZH mammographers diagnosed them as normals; etc.;

P<sub>04</sub> is the probability of both ACC radiologists and MZH mammographers diagnosed the "true normal" cases as normal; etc.

Once this table is set up, the sensitivity and specificity at ACC and MZH can be defined as

$$\text{Sensitivity (ACC)} = (P_{11} + P_{12}) / \pi$$

$$\text{Specificity (ACC)} = (P_{03} + P_{04}) / (1 - \pi), \text{ and}$$

$$\text{Sensitivity (MZH)} = (P_{11} + P_{13}) / \pi$$

$$\text{Specificity (MZH)} = (P_{02} + P_{04}) / (1 - \pi)$$

The null hypotheses to be tested are:

H<sub>0</sub>: Sensitivity (ACC) = sensitivity (MZH) is equivalent to

H<sub>0</sub>: P<sub>12</sub> = P<sub>13</sub>, and

H<sub>0</sub>: Specificity (ACC) = specificity (MZH) is equivalent to

H<sub>0</sub>: P<sub>03</sub> = P<sub>02</sub>

The chi-square test with 1 degree of freedom (d.f.) as described by Bennett [13]:

$\chi^2 = (N_{12} - N_{13})^2 / (N_{12} + N_{13})$  with 1 d.f. is to be used to test the null hypothesis that the two sensitivities are equal versus the alternative that they differ. Estimates of sensitivity can then be calculated for MZH and ACC. Similarly, the null hypothesis that the two specificities are equal can be tested with a chi-square test:  $\chi^2 = (N_{02} - N_{03})^2 / (N_{02} + N_{03})$  with 1 d.f.

This protocol tests the hypothesis that image interpretation by expert mammographers using telemammography procedure is as effective, if not better, than conventional film-screen interpretation by general diagnostic radiologists.

### Teleconsultation

This protocol tests the efficacy of the previously validated image transmission and display procedure discussed in telediagnosis, used for remote consultation on **problem cases**. The aim here is to evaluate the ability of telemammography to facilitate real-time consultation between on-site general diagnostic radiologists and remotely-located expert mammographers. Currently, such consultations are tedious, time-consuming, and logistically complex, to the point where they usually are reserved for only the most confusing cases. If successful, teleconsultation should enhance the consultative process such that it becomes much more widely utilized, thereby bringing mammographic interpretive expertise to bear at the community practice level. Selected mammography examinations from ACC are chosen by the general radiologist doing mammography interpretations there, for second opinion by mammography specialists at MZH. The criterion for case selection is unresolved problem(s) in interpretation or management that require additional consultation. Past experience at MZH with non-teleradiology consultations from general radiologists at both ACC and community-practice settings, indicates that at least 20% of cases are interpreted as normal or benign after MZH consultation. Review at MZH involves transmitted full-field direct digital images from the affected breast, employing both monitor display and hard copy display.

We assume that an expert mammographer will always be in attendance at the diagnostic center (MZH), but that only general radiologists will be at the satellite station. Figure 7 shows the teleconsultation chain, which is also used for telemanagement. The steps are as follows:

1. Mammography cases for teleconsultation is selected by radiologists at ACC, once initial film-screen image interpretation has been recorded. After completion of the film-screen mammography, informed consent will be obtained from patients for two additional real-time full-field direct digital mammograms of the affected breast (in the same craniocaudal and mediolateral oblique projections just used for film-screen mammography). These images will be archived in the overall mammography data base. The data base is transparent to users in the sense that it will provide the necessary images upon request regardless of the requested site.

2. An expert mammographer at MZH diagnoses the study, and results is to be appended automatically to the film-screen study in the data base.

3. When a teleconsultation is requested, both sites will call up the same set of digital images simultaneously and discuss the case using soft-copy display. During the consultation, both parties can move a two-way cursor independently to highlight any suspicious sites. If necessary, a digital hard copy can be printed to further aid the consultation at MZH.

4. Updated diagnoses will be appended in the data base and old diagnoses will be revised. A tag will be added to the revised diagnosis for future reference.

5. The "truth" determination for cases selected for the teleconsultation study is in two stages for the abnormal and normal. Radiologic-pathologic correlation will be done for all cases for which tissue diagnosis is obtained. The "truth" for this set is therefore determined. The remaining cases, all interpreted as benign or probably benign after teleconsultation, will be confirmed in two ways. First, all cases will undergo periodic mammographic surveillance for 2 years, after which time mammographic stability will establish benignity or interval change will have prompted tissue diagnosis, and therefore pathologic proof. Second, we will track these cases retrospectively to determine if they are follow-up studies from existing over-2-year-ago examinations which had been interpreted as benign. Thus, the "truth" of benignity of a case will be determined based on either historical comparison or waiting for a period of 2 years starting from the date of examination.

Similar evaluation methodology described in Telediagnosis with the comparison between ACC radiologists and MZH mammographers (Table 3) will be used.

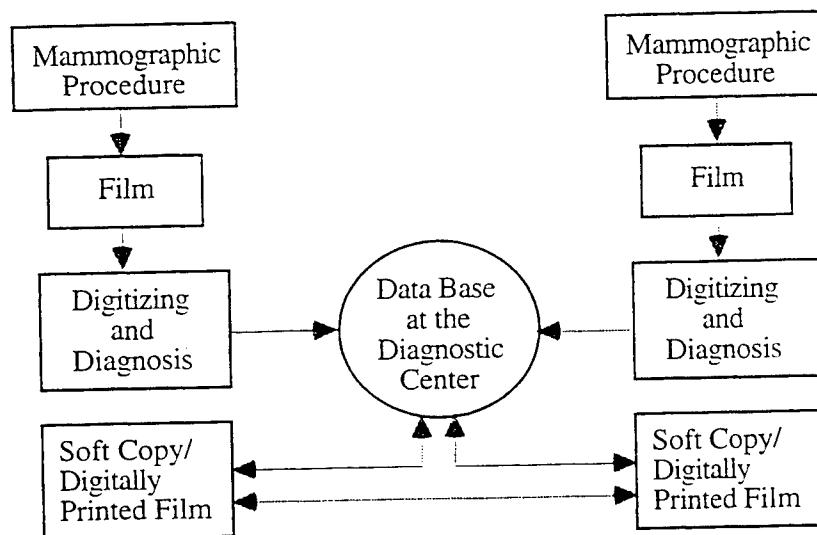


Figure 7 Teleconsultation Procedure

## Telemanagement

This protocol tests the efficacy of the previously validated image transmission and display procedure discussed in Telediagnosis, but now used for **remote real-time management and interpretation** of mammography examinations. The goal of telemanagement is even more ambitious than that of teleconsultation, to completely replace the on-site general radiologist with remotely-located expert mammographers. To evaluate the ability of telemammography to permit remotely guided interpretation and work-up, the accuracy of mammographic interpretations made on site at ACC by general radiologists is compared with those made remotely but interactively in real-time by expert mammographers at MZH. Unselected ACC mammography examinations (both screening and problem-solving cases), acquired using conventional screen-film techniques, are read by the general radiologist doing mammography interpretations there, according to normal operating procedure, including the taking of any additional images that are thought to be necessary. Interpretations will be completed prior to telemanagement. Informed consent then is obtained from patients for two additional real-time full-field direct digital mammograms of one breast (in the same craniocaudal and mediolateral oblique projections just used for film-screen mammography). The affected breast is studied if the film-screen interpretation was abnormal, one breast is selected randomly if the film-screen interpretation was normal. Before each patient is sent home, the digital images are transmitted to a mammography specialist at MZH, who decides either to interpret the examination as submitted, or to request additional views to complete the mammographic work-up and then interpret the examination. The MZH-based mammographer is blind as to the interpretation rendered by the ACC radiologist and as to whether any additional images were requested by the ACC radiologist. The general radiologist's on-site interpretation of film-screen images are compared with the mammography specialist's interpretation of digitized transmitted, "tele-managed" images.

"Truth" determination for the cases for the telemanagement protocol is similar to that in teleconsultation. Malignancy will be determined by radiologic-pathologic correlation after tissue diagnosis. Benignity is determined either by radiologic-pathologic correlation after tissue diagnosis (if available) or by 2-year-old historical comparisons and by subsequent periodic mammographic surveillance for 2 years. In both latter situations, mammographic stability is used to establish the benignity of a lesion.

With the "truth" determined, similar evaluation methodology to that described in Telemammography will be used, involving sensitivity and specificity tables comparing the performance of ACC radiologists and MZH mammographers (Table 3).

## 4. SUMMARY

Current attempts at controlling breast cancer concentrate on early detection by means of mass screening, using periodic mammography and physical examination, because ample evidence is now available to indicate that such screening indeed can be effective in lowering the death rate. However, state-of-the-art mammography utilizes film-screen recording systems, which have several technical limitations that reduce its effectiveness: the film gradient must be balanced against the need for wide latitude and detection of microcalcifications. In addition, portrayal of the clarity of the margins of breast masses are reduced due to the presence of film noise in the displayed image, film processing artifacts can degrade the mammographic image, and the day-to-day variability inherent in automated film processors can produce suboptimal image quality. Full-field direct digital mammography promises to overcome most of these problems, at the same time providing additional features not available with standard mammographic imaging [14]. Real-time Telemammography adds to these advantages the utilization of expert mammographers (rather than general radiologists) as interpreters of the mammography examinations.

The specific aim of FFDDM telemammography is to integrate the process of acquiring, storing, communicating, visualizing, and managing digital mammography examinations within the operational environment of an expert-mammographer diagnostic imaging center and a general-radiologist mammography practice. We have described the first phase in setting up the telemammography chain as well as the three research protocols in telediagnosis, teleconsultation, and telemanagement.

## ACKNOWLEDGMENTS

This research is partially supported by the California Breast Cancer Research Program: "Real-Time Telemammography" IRB-0148), the US Army Medical Research Material Command: "Full-field Direct Digital Telemammography (DAMD-96-C-6111) and "A Digital Breast Imaging Teaching File (USAMRMC DAMD17-94-J-4196), and the National HPCC Program, National Library of Medicine: A High-Performance Testbed Network for Collaborative

Health Care (N01-LM-4-3508). The authors would like to thank M. Tesic and M. Piccaro of Fischer Imaging Corporation for their contributions, and James Sayre of UCLA for the experimental design.

## REFERENCES

- [ 1 ] Boring CC, Squires TS, Tong T. 1992. *Cancer Statistics*. CA; 42:19-38.
- [ 2 ] Sickles EA. 1993. Current Status of Digital Mammography. *In* Proceedings of the 7th International Congress on Senology (Excerpta Medica International Congress Series). Amsterdam, Elsevier.
- [ 3 ] Nelson MT. 1995. A Clinician's View of Digital Mammography. Proc. 4th Intern. Conf. Imag. Management and Comm. (IMAC 95).
- [ 4 ] Toker E. and M. Piccaro. 1993. Design and Development of a Fiber Optic TDI CCD-Based Slot-Scan Digital Mammography System. *SPIE Proceedings*, Medical Imaging, 2009.
- [ 5 ] Lou SL, Huang HK, Breant CM. 1992. A 2K Radiological Image Display Station. *Radiology* 185(P), 146.
- [ 6 ] Huang H.K. 1996. Teleradiology Technologies and Some Service Models. *Comp. Med. Imaging & Graphics* 20:59-68.
- [ 7 ] Fajardo LL, Yoshino MT, Seeley GW, et al. 1990. Detection of Breast Abnormalities on Teleradiology Transmitted Mammograms. *Invest Radiol.* 25: 1111-1115.
- [ 8 ] Sickles EA, Ominsky SH, Sollitto RA, Galvin HB, Monticciolo DL. 1990. Medical Audit of a Rapid-throughput Mammography Screening Practice: Methodology and Results of 27,114 Examinations. *Radiology*. 175-323-327.
- [ 9 ] Sickles EA. 1992. Quality Assurance: How to Audit your Own Mammography Practice. *Radiol Clin North Am.* 30:265-275.
- [ 10 ] Huang HK. 1996. Clinical Experience with a Second-Generation Hospital-Integrated Picture Archiving and Communication system. *Journal of Digital Imaging* 9:151-166.
- [ 11 ] M Moskowitz, J Wang, HK Huang, E Sickles, J Allen, A Giles. 1995. High Resolution Display System for Mammograms. *Proc. SPIE Medical Imaging* 2431-44.
- [ 12 ] SL Lou, E Sickles, J Wang, HK Huang. 1994. A High Resolution Display System for Mammograms. *Radiology*, 193(P), 474.
- [ 13 ] Bennett BM. 1985. On Tests for Equality of Predictive Values for t Diagnostic Procedures. *Stats. in Med.* 4:535-539.
- [ 14 ] Tesic M. and Piccaro M.F. 1996. Digital Mammography Scanner: Performance Characteristics and Preliminary Clinical Results. The Institute of Electrical Engineers. *IEEE*, Savoy Place, London WC2R OBL. UK. pp. 3/1-3/7.

## Technical Issues in Full-Field Direct Digital Telemammography

H.K. Huang<sup>1</sup>, S.L. Lou<sup>1</sup>, Edward Sickles<sup>2</sup>, David Hoogstrate<sup>1</sup>,  
Mohammad Jahangiri<sup>1</sup>, Fei Cao<sup>1</sup>, Jun Wang<sup>3</sup>

1. Laboratory for Radiological Informatics, 2. Breast Imaging Section,  
3. Now with Philips Research Lab, Palo Alto, CA

Department of Radiology, University of California San Francisco,  
530 Parnassus Avenue, Rm. CL-158, San Francisco, CA 94143-0628, USA

### 1. Introduction

Current attempts at controlling breast cancer concentrate on early detection by means of mass screening, periodic mammography and physical examinations. Ample evidence is now available to indicate that such screening indeed can be effective in lowering the death rate [1]. However, state-of-the-art mammography utilizes film-screen recording systems, which have several technical limitations that reduce its effectiveness: the film gradient must be balanced against the need for wide latitude and detection of microcalcifications. In addition, portrayal of the clarity of the margins of breast masses are reduced due to the presence of film noise in the displayed image, film processing artifacts can degrade the mammographic image, and the day-to-day variability inherent in automated film processors can produce suboptimal image quality. Full-field direct digital mammography promises to overcome most of these problems, at the same time providing additional features not available with standard mammographic imaging [2-5]. Real-time Telemammography adds to these advantages by utilizing expert mammographers (rather than general radiologists) as interpreters of the mammography examinations.

We are in the process of setting up a telemammography system between two campuses at UCSF: the Breast Imaging Section at Mt. Zion Hospital (MZH), the Laboratory for Radiological Informatics (LRI), and the Ambulatory Care Center, Parnassus campus, two miles apart. This paper discusses some technical issues in developing telemammography including full-field direct digital mammography (FFDDM), image compression, high resolution workstations, communication networks, and telemammography protocols.

### 2. Direct Digital Mammography

#### 2.1. Digital Mammography systems

Currently, there are four manufacturers designing digital mammography systems: Bennett, Lorad, General Electric, and Fischer. Table 1 summarizes the current pros and cons of these four systems.

**Table 1. Pros and Cons of the four prototype direct digital mammography systems**

(1) Bennett (TREX Medical Group, Danbury, CT)

Pros

- Field upgradable to existing film/screen mammo units
- Short exposure times

Cons

- Expensive (for CCDs & Fiber Optic Tapers)
- Dead spaces between modules
- Requires grid for scattered radiation which increases dose to patient
- Bulky package because of CCDs, fiber optics, and electronics

(2) Lorad (TREX Medical Group, Danbury, CT)

Pros

- Inexpensive
- Decreased development time because design of camera is fundamentally the same as their biopsy camera

Cons

- Bulky package because of lens-based design
- Patient motion and discomfort due to long image acquisition time required to step and translate the detector over the entire field of view
- Requires precise mechanical translation of detector and collimator for subsequent image stitching and processing
- Image processing and stitching is a difficult task due to parallax issues

(3) General Electric (Milwaukee, WI)

Pros

- Field upgradable to existing mammo units
- Potentially small package when 50 micron pixel size is achieved (elimination of mechanical translation)

Cons

- Requires precise mechanical translation of detector to achieve an accurate effective 50 micron pixel size and for subsequent image processing
- Expensive technology at this time
- Requires grid for scattered radiation, which increases dose to patient.

(4) Fischer Imaging (Denver, CO)

Pros

- Detector technology is less expensive than Bennett and GE approaches
- Scatter rejection of slot scanner provides improved image quality per unit dose
- Decreased dose for 5cm and greater due to spectral optimization of system

Cons

- Requires precise alignment and mechanical scanning
- Package is bulky, due to CCDs, fiber, and electronics
- Mechanical/aesthetic design of camera cover is difficult due to pendulum scanning approach and necessity for small package
- Dead zone at edges of field of view due to camera width and camera ramp-up time/distance
- X-ray tube heat loading may shorten life of tube
- Increased development time due to ground-up engineering of entire system
- 4.5 s scan time may cause discomfort (motion will not be an issue because slot time is only 200 ms).

## 2.2 Full-Field Direct Digital Mammography

After carefully evaluating the pros and the cons of these four approaches, we selected the Fischer full-field direct digital mammography system (FFDDM) for our telemammography system for the following reasons[6,7]: the probability and the timing of implementation of a direct digital system in the clinical setting, the track record of the manufacturers in conducting a mammography research and development program, and our past working relationship with the

manufacturer. Table 2 summarizes the specifications of the Fischer FFDDM system. Figure 1 shows the prototype unit with the Fischer engineers. As of March, 1997, the first system has been installed in our Breast Imaging Section at MZH connecting to the LRI for clinical evaluation.

<b>Table 2</b>	<b>Specifications of the Fischer FFDDM System</b>
Image Area	221 mm x 270 mm
Detector	Charge-coupled devices (CCD)
Image Scan Time	slot scan, 6.0 secs (nominal)
kV Range	25-45 kVP
Tube Current	200 mA at 45 kVP
Target	Tungsten
Focal Spot Size	0.30 mm (nominal), 0.15 mm (High Res.)
Pixel Size	54 x 54 microns (nominal), 27 x 27 microns (High res.)
Image Matrix	4K x 5K pixels (nominal), 12 bits/pixel
Spatial Resolution	9 lp/mm (nominal), 18 lp/mm (High Res.)
Detective Quantum Eff.	greater than or equal to 50% at f(0)
Scatter-to-Primary	less than or equal to 0.15




Figure 1. A prototype full-field direct digital mammography unit with Fischer's engineers (left to right: G. Jeffery, M. Piccaro, S. Maydew)

### 2.3. Image Compression

FFDDM generates a  $4K \times 5K \times 2 = 40$  Mbyte image. Obviously, some data compression is needed to reduce its size to facilitate storage and communication. We have developed an on-line structure lossless and a wavelet lossy compression algorithm for this purpose. The on-line lossless method is based on segmentation of the breast from the background and then applying the prediction coding on the breast. The algorithm can be used while data is being acquired from the FFDDM with an average compression ratio of 3 to 4:1[8]. The wavelet lossy method can achieve very high compression ratios without losing diagnostic quality. Figure 2 shows an example with the original image, the 20:1 decompressed image using the wavelet transform and a simple uniform quantization, and an image showing the difference between the two.

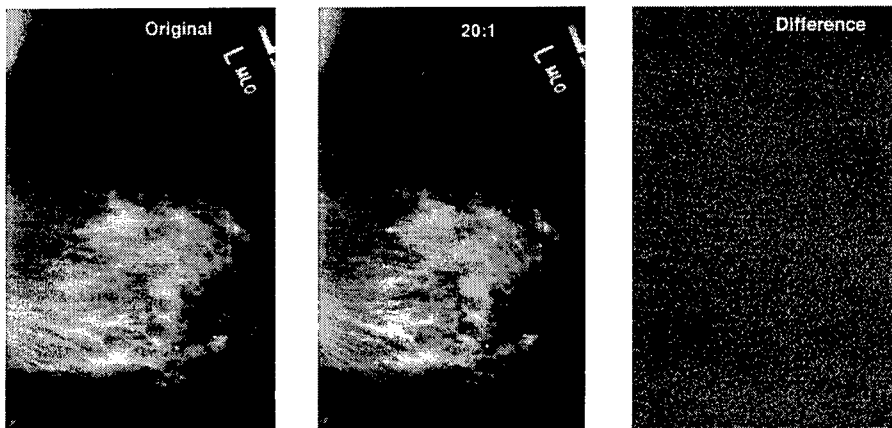


Figure 2. A Mammogram compressed with 20:1 using the wavelet transform. L: original, M: reconstructed, and R: difference image.

#### 2.4. Display Workstation

##### Workstation Architecture

We are developing a new 2K workstation for the FFDDM based on our experience with an existing 2K system for a mammography interactive teaching file [9,10]. The new system is based on an Ultra Sparc 2 platform (Sun Microsystems, Mountain View, CA) with two DOME MD5/SBX boards (Waltham, Mass). Figure 3 shows the block diagram of this new display system.

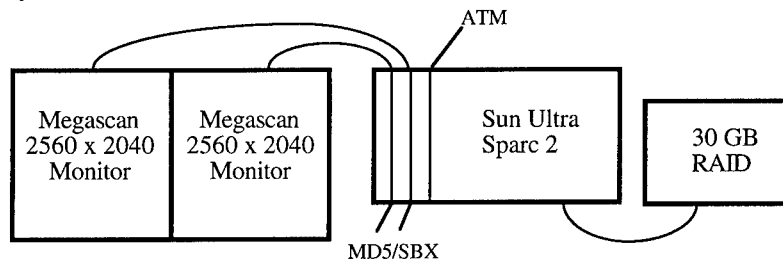


Figure 3. Schematic of the 2K mammography display workstation.

##### Display format

A standard mammographic examination consists of a craniocaudal and mediolateral oblique view of each breast, a total of four images per examination. For comparison purposes, four images from a prior examination of similar views are also used. Therefore, an optimal display mode should show eight images in proper orientation with one key stroke [11]. We have developed three display formats: one-on-one, two-on-one, and four-on-one monitor, all with scroll and zoom, shown in Figure 4.

### 3. Telemammography

#### 3.1. Image Communication between MZH and ACC

We use the asynchronous transfer mode (ATM) OC-3 (155 Mbits/sec) technology for both WAN and LAN [12]. Currently we can transmit a 40 Mbyte mammogram in 5.3 seconds (memory-to-memory) with the ATM. With this ATM communication speed, real-time telemammography can be utilized.

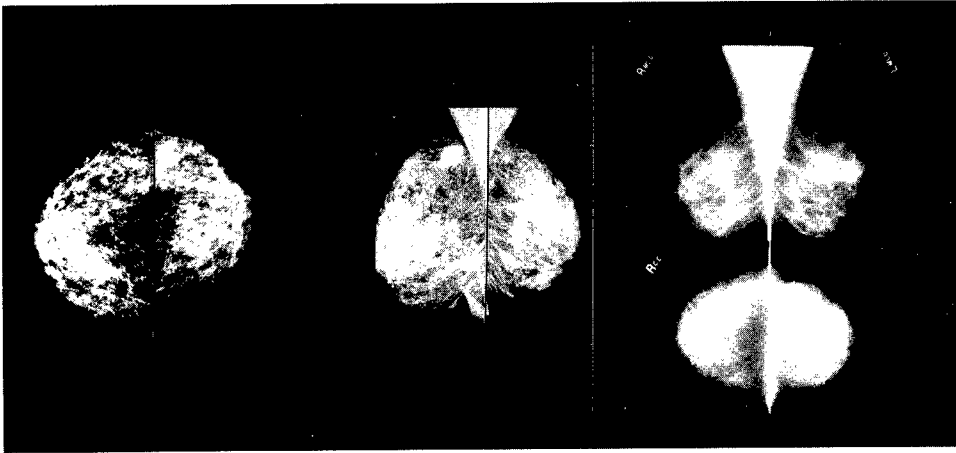


Figure 4. Three types of display format: one-on-one (see Fig. 2 left), two-on-one (left and middle), and four-on-one (left and middle) monitor.

### 3.2 Concept of an Expert Center

Telemammography is built on the concept of an expert center. Radiologists who work in several different offices or hospitals will be able to monitor and interpret examinations that are carried out in a nearby or even at a distant location or locations. This will permit those radiologists with the greatest interpretive expertise to manage and read in real time all mammography examinations, an operational procedure far superior to the alternative of choosing between deferred interpretation by expert readers or real-time interpretation by general radiologists [13,14]. Real time is defined in this context as a very rapid turnaround time between examination and interpretation. In addition, mammography screening in mobile units will be made more efficient, not only by overcoming the need to transport films from the site of examination to the site of interpretation, but also by permitting image interpretation while patients are still available for repeat or additional exposures. Furthermore, telemammography can be used to facilitate second-opinion interpretation, in effect making world-class mammography expertise immediately accessible to community-practice radiologists.

### 3.3 Telemammography Protocols

We are setting up three protocols: telediagnosis, teleconsultation and telemanagement for evaluating the effectiveness of telemammography.

#### Telediagnosis

This protocol tests the clinical effectiveness of telemammography from image transmission of full-field direct digital mammograms versus on-site interpretation of conventional film-screen mammograms.

#### Teleconsultation

This protocol tests the efficacy of remote consultation on **problem cases**. The aim here is to evaluate the ability of telemammography to facilitate real-time consultation between on-site general diagnostic radiologists and remotely-located expert mammographers. Currently, such consultations are tedious, time-consuming, and logistically complex, to the point where they usually are reserved for only the most confusing cases. If successful, teleconsultation should enhance the consultative process such that it becomes much more widely utilized, thereby bringing mammographic interpretive expertise to bear at the community practice level.

### Telemanagement

This protocol tests the efficacy of **remote real-time management and interpretation** of mammography examinations. The goal of telemanagement to completely replace the on-site general radiologist with remotely-located expert mammographers is more ambitious than that of teleconsultation.

### 4. Future Directions

We are in the first phase of a three year comprehensive program in developing the application of telemammography. The current phase is to resolve the technical issues of a telemammography system at MZH discussed in this paper. The second phase is to set up a second FFDDM in the Ambulatory Care Center at UCSF in order to compare the difference in operating environments between the two sites. The last phase is to collect patient data to evaluate the efficacy of the three clinical protocols.

### ACKNOWLEDGMENTS

This research is partially supported by the California Breast Cancer Research Program: "Real-Time Telemammography" (IRB-0148), the US Army Medical Research Materiel Command: "Full-field Direct Digital Telemammography" (DAMD-96-C-6111) and "A Digital Breast Imaging Teaching File" (USAMRMC DAMD17-94-J-4196), and the HPCC Program, National Library of Medicine: "A High-Performance Testbed Network for Collaborative Health Care" (N01-LM-4-3508). The authors would like to thank M. Tesic, M. Piccaro, S. Maydew, G. Jeffery and P. Campbell of Fischer Imaging Corporation for their contributions, and James Sayre of UCLA for the experimental design.

### REFERENCES

- [ 1 ] Boring CC, Squires TS, Tong T. 1992. *Cancer Statistics*. CA; 42:19-38.
- [ 2 ] Sickles EA. 1993. Current Status of Digital Mammography. *In* Proceedings of the 7th International Congress on Senology. Amsterdam, Elsevier.
- [ 3 ] Nelson MT. 1995. A Clinician's View of Digital Mammography. Proc. 4th Intern. Conf. Imag. Management and Comm. (IMAC 95).
- [ 4 ] Huang H.K. 1996. Teleradiology Technologies and Some Service Models. *Comp. Med. Imaging & Graphics* 20:59-68.
- [ 5 ] Fajardo LL, Yoshino MT, Seeley GW, et al. 1990. Detection of Breast Abnormalities on Teleradiology Transmitted Mammograms. *Invest Radiol*. 25: 1111-1115.
- [ 6 ] Toker E. and M. Piccaro. 1993. Design and Development of a Fiber Optic TDI CCD-Based Slot-Scan Digital Mammography System. *SPIE Proc., Med. Imag.*, 2009.
- [ 7 ] Tesic M. and Piccaro M.F. 1996. Digital Mammography Scanner: Performance Characteristics and Preliminary Clinical Results. The Institute of Electrical Engineers, *IEEE*, Savoy Place, London WC2R OBL, UK, pp. 3/1-3/7.
- [ 8 ] Wang J. 1996. "Three-Dimensional Medical Image Compression Using Wavelet Transform and Parallel Computing", Ph.D. Dissertation. UCLA.
- [ 9 ] Lou S.L., Huang HK, Breant CM. 1992. A 2K Radiological Image Display Station. *Radiology* 185(P), 146.
- [ 10 ] Moskowitz M, Wang J., Huang H.K., Sickles E., et al.. 1995. High Resolution Display System for Mammograms. *Proc. SPIE Medical Imaging* 2431-44.
- [ 11 ] Lou S.L., Sickles E., Wang J., Huang H.K. 1994. A High Resolution Display System for Mammograms. *Radiology*, 193(P), 474.
- [ 12 ] Huang H.K., Wong W.K., Lou S.L. et al. 1996. Clinical Experience with a Second-Generation Hospital-Integrated PACS. *JDI* 9:151-166.
- [ 13 ] Sickles E.A., Ominsky S.H., Sollitto R.A., Galvin H.B., Monticciolo D.L. 1990. Medical Audit of a Rapid-throughput Mammography Screening Practice: Methodology and Results of 27,114 Examinations. *Radiology*. 175-323-327.
- [ 14 ] Sickles E.A. 1992. Quality Assurance: How to Audit your Own Mammography Practice. *Radiol Clin North Am.* 30:265-275.

# Full-Field Direct Digital Telemammography: Technical Components, Study Protocols, and Preliminary Results

S. L. Lou, *Member, IEEE*, Edward A. Sickles, H. K. Huang, *Senior Member, IEEE*,  
David Hoogstrate, Fei Cao, Jun Wang, and Mohammad Jahangiri

**Abstract**—The early detection of breast cancer increases the survival rate in women. Today, film-screen mammography is the most common and effective technique for the detection of breast cancer. However, the film-screen image recording system of current mammography has several technical limitations that can reduce the breast cancer diagnostic accuracy. A state-of-the-art technology, full-field direct digital mammography (FFDDM) has the potential to increase the sensitivity of clinical and screening examinations and emerge as a film-screen mammography replacement. It is believed that efficiently delivering the superior image quality of FFDDM to expert mammographers will significantly increase the breast cancer diagnostic accuracy. This concept motivates the studies of FFDDM telemammography.

In this paper, we will report the FFDDM telemammography project that is being conducted in our facility. The fundamental technology of the FFDDM system and the characteristics of FFDDM images are described. Our research approach is through three protocols: tediagnosis, teleconsultation, and telemanagement. Each of these study protocols is defined. To conduct this FFDDM telemammography project, an asynchronous transfer-mode-network-based telemammography system is developed across two remote campuses in our facility. The architecture of this system is detailed. Unlike other medical imaging modalities, the matrix of an FFDDM image is huge. How to present the image information to mammographers via currently available display media is a challenging task. Our display approaches for the FFDDM images are described. Some preliminary study results from the current phase of this study are reported.

**Index Terms**—Digital mammography, high-resolution display, high-speed networking, telemedicine, teleradiology.

Manuscript received October 15, 1997; revised December 23, 1997. This work is supported in part by the California Breast Cancer Research Program: "Real-Time Telemammography" (IRB-0148), the U.S. Army Medical Research Material Command: "Full-field Direct Digital Telemammography" (DAMD-96-C-6111) and "A Digital Breast Imaging Teaching File" (USAMRMC DAMD17-94-J-4196), the National HPCC Program, National Library of Medicine: "A High-Performance Testbed Network for Collaborative Health Care" (N01-LM-4-3508), and the Department of Health and Human Services: "Optimization of Soft Copy Display Parameters for Digital Mammograms" (282-97-0057).

S. L. Lou, H. K. Huang, D. Hoogstrate, and F. Cao are with the Department of Radiology, Laboratory for Radiological Informatics, University of California, San Francisco, CA 94143-0628 USA (e-mail: andrew.lou@radiology.ucsf.edu).

E. A. Sickles is with the Breast Imaging Section, Department of Radiology, University of California, San Francisco, CA 94143-0628 USA.

J. Wang was with the Department of Radiology, Laboratory for Radiological Informatics, University of California, San Francisco, CA 94143-0628 USA. She is now with Philips Medical System, Palo Alto, CA 94304-1336 USA.

M. Jahangiri was with the Department of Radiology, Laboratory for Radiological Informatics, University of California, San Francisco, CA 94143-0628 USA. He is now with the Department of Radiology, University of Virginia, Charlottesville, VA 22903 USA.

Publisher Item Identifier S 1089-7771(97)09414-4.

## I. INTRODUCTION

**B**REAST cancer is the fourth most common cause of death among women in the United States [1]. There is no known means of preventing the disease, and available therapy has been unsuccessful in reducing the national mortality rate over the past 60 years. Current attempts at controlling breast cancer concentrate on early detection by means of mass screening, using periodic mammography and physical examinations, because ample evidence indicates that such screening indeed can be effective in lowering the death rate [2]–[5].

Conventional film-screen mammography has certain technical limitations that reduce its effectiveness: the film gradient must be balanced against the need for wide latitude and detection of microcalcifications. In addition, portrayal of the clarity of the margins of breast masses are reduced due to the presence of film noise in the image, film processing artifacts can degrade the mammographic image, and the day-to-day variability inherent in automated film processors can produce suboptimal image quality. Digital mammography is a method to alleviate some of these limitations.

Early digital mammography applications acquired data by digitizing conventional mammography films. This approach severely limits the potential of digital mammography, since the resultant images can contain no more radiographic information than the standard films from which they are produced. Indeed, most digitized images are currently slightly inferior in quality to their corresponding parent films, accounting in no small part for the general lack of clinical acceptance of digital mammography applications.

Direct digital mammography can overcome most of these problems, at the same time providing additional features not available with standard mammographic imaging, such as contrast enhancement, digital archive, and computer-aided diagnosis [6]–[14]. In addition, applications of real-time telemammography add to these advantages the utilization of expert mammographers (rather than general radiologists) to interpret mammography examinations. During the past several years, due to the concentrated efforts from the National Cancer Institute and the United States Army Medical Research and Development Command, some prototype direct-digital mammography systems have been developed by a joint effort between academic institutions and the private industry. Some of these systems are ready for clinical evaluation [12].

At the University of California, San Francisco (UCSF), we are embarking on a large-scale project of developing a tele-mammography system between two campuses: UCSF medical center (or main campus) and Mount Zion Hospital (MZH). These two campuses are two miles apart. The discussions in this paper focus on the first phase of the project, including the full-field direct digital mammography (FFDDM) technology transfer for clinical evaluations, the establishment of the tele-mammography clinical protocols, the image compression of digital mammograms, the development of a high-resolution workstation for digital mammogram display, and the setup of the asynchronous transfer mode (ATM) networks for the tele-mammography chain. Some clinical preliminary results will also be given.

## II. FULL-FIELD DIRECT DIGITAL MAMMOGRAPHY

Currently, there are four major manufacturers in the United States developing FFDDM systems: Bennett (Copiague, NY), LoRad Corporation (Danbury, CT), General Electric Medical Systems (Milwaukee, WI), and Fischer Imaging Company (Denver, CO). The system, Senoscan, developed by Fischer Imaging Company was selected for our tele-mammography project for the following reasons [15], [16]: the availability of the prototype system for clinical evaluations, the track record of the manufacturer in conducting mammography research and development programs, and our past working relationship with the manufacturer.

### A. Slot-Scanning FFDDM Technology

The imaging principle of the Senoscan FFDDM system is similar to the conventional mammography systems. They all utilize X-rays to expose a patient's breast, employ a bucky to support the breast, and incorporate a detector system into the bucky to record the mammogram. However, they differ mainly in two aspects: the scanning mechanism and the detector system. In a conventional system, a patient's entire breast is exposed by X-rays concurrently and the latent image is detected by a film-screen cassette, which is contained in the bucky. Unlike conventional mammography systems, the Senoscan uses a slot-scanning technology, in which a breast is scanned by an X-ray fan beam and the image is recorded by a charged-couple device (CCD) camera encompassed in the bucky. Fig. 1 shows a schematic diagram of the Senoscan FFDDM system. The X-ray photons emitted from the X-ray tube are shaped by a collimator to become a fan beam. The width of the fan beam covers one dimension of the image area ( $x$ -axis), and the fan beam swings in another dimension ( $y$ -axis). The movement of the detector system is synchronous with the scan of the fan beam. The detector system of the FFDDM is composed of a thin phosphor screen coupled with four CCD detector arrays via a tapered fiber-optic bundle. Each CCD array is composed of  $1100 \times 300$  CCD cells. The gap between any two adjacent CCD arrays is only 1-pixel wide, which simplifies the task of butting the gap. The phosphor screen converts the penetrated X-ray photons (i.e., the latent image) to light photons. The light photons pass through the fiberoptic bundle, reach the CCD cells, and are

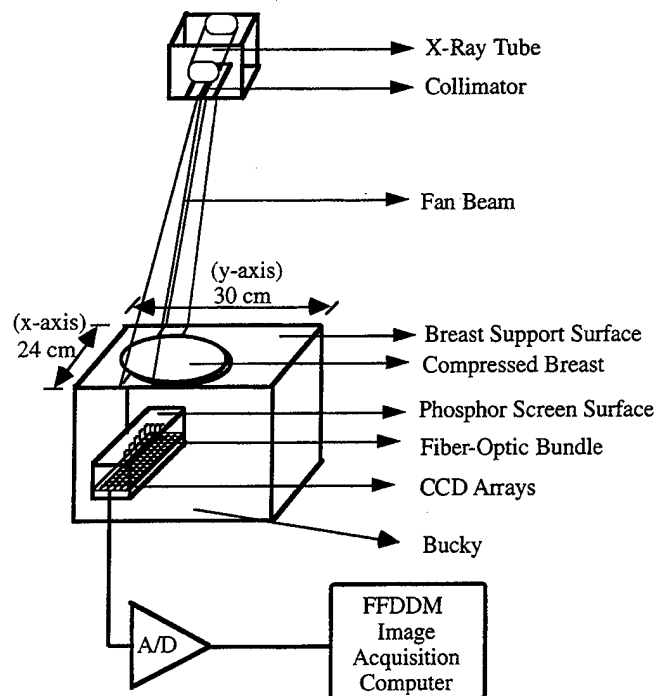


Fig. 1. Schematic of the prototype full-field direct digital mammography system (FFDDM).

then transformed to electrical signals. The more light photons received by each CCD cell, the larger the signal is transformed. The electrical signals are quantized by an analog-to-digital converter to create a digital image. Finally, the image pixels travel through a data channel into the system memory of the FFDDM acquisition computer.

### B. FFDDM Imaging Characteristics

The size of the bucky in the conventional mammography system can be either  $18 \times 24$  or  $24 \times 30$  cm<sup>2</sup>. Depending on the patient's breast size, the proper bucky size is selected to obtain the mammogram. However, the bucky size of the Senoscan FFDDM system is fixed with an image area of  $24 \times 30$  cm<sup>2</sup> to accommodate large breast sizes. For a pixel size of  $54 \times 54$   $\mu$ m<sup>2</sup> at the phosphor screen, the FFDDM system generates an image matrix of  $4096 \times 5625$  pixels. This spatial resolution is equivalent to approximately 9 lp/mm. For each pixel, the gray level ranges from zero to 4095 (i.e., 12-bit), where gray level zero is black and 4095 is white. Table I summarizes the imaging specifications of the Senoscan FFDDM system.

## III. TELEMAMMOGRAPHY APPLICATIONS

### A. Concept of an Expert Center

Tele-mammography is built on the concept of an expert center. Radiologists who work in several different offices or hospitals will be able to monitor and interpret examinations that are carried out in a nearby or even distant location [17]. This will permit those radiologists with the greatest interpretive expertise to manage and read in real time *all*

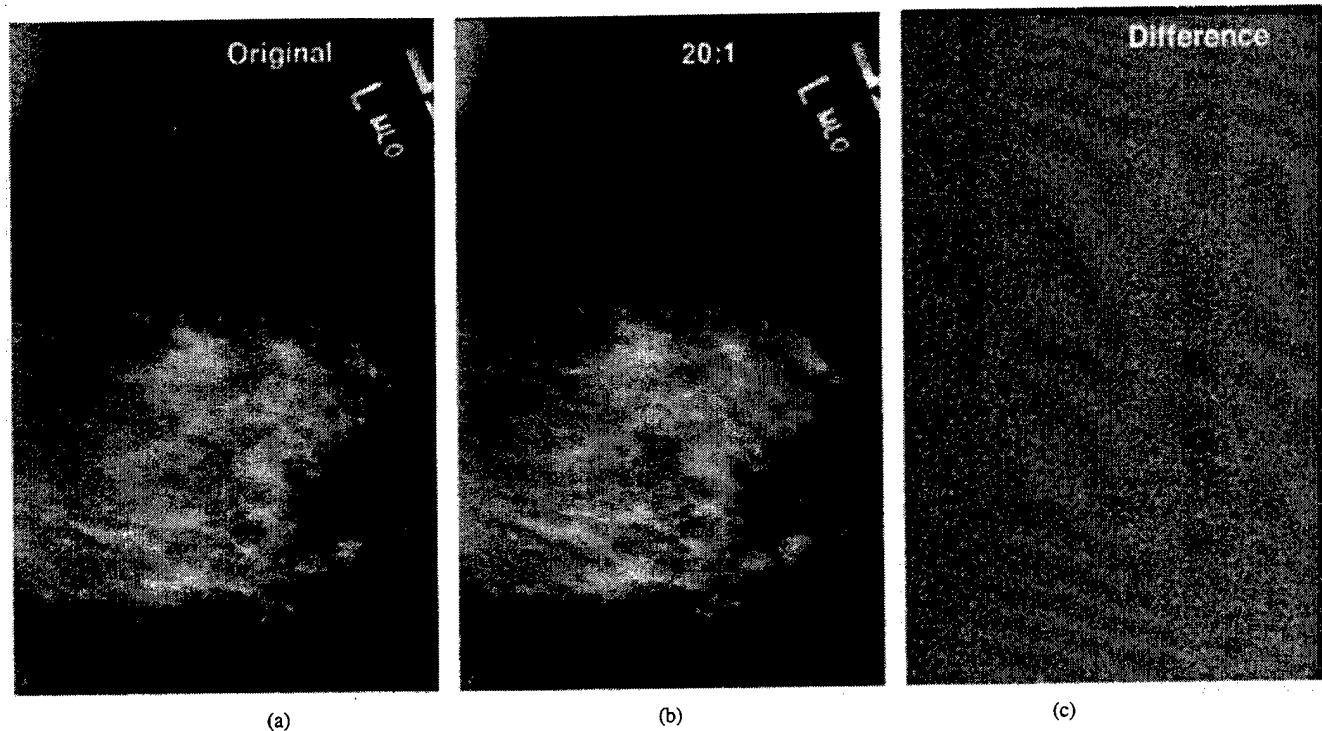


Fig. 2. A mammogram compressed with 20:1 using the wavelet compression technique: (a) original, (b) reconstructed, and (c) difference image.

TABLE I  
SPECIFICATIONS OF THE FISCHER FFDDM SYSTEM

Image Area	240 × 300 mm
Detector	Charge-coupled devices (CCD)
Image Scan Time	Slot scan, 4.5 s (nominal)
kV Range	25–50 kVP
Tube Current	200 mA at 45 kVP
Focal Spot Size	0.30 mm (nominal)
Pixel Size	Nominal Mode: 54 × 54 μm <sup>2</sup> , (High Res.): 27 × 27 μm <sup>2</sup>
Image Matrix	4096 × 5625 pixels (nominal), 12 bits/pixel
Spatial Resolution	9 lp/mm (nominal), 18 lp/mm (High Res.)
Detective Quantum Eff.	Less than or equal to 50% at f(0)
Scatter-to-Primary	Less Than or equal to 0.15

mammography examinations, an operational procedure far superior to the alternative of choosing between deferred interpretation by expert readers or real-time interpretation by general radiologists [18], [19]. Real time is defined in this context as a very rapid turnaround time between examination and interpretation. In addition, mammography screening in mobile units will be made more efficient, not only by overcoming the need to transport films from the site of examination to the site of interpretation, but also by permitting image interpretation while patients are still available for repeat or additional exposures. Furthermore, telemammography can be used to facilitate second-opinion interpretation, in effect making world-class mammography expertise immediately accessible to community-practice radiologists.

#### B. Telemammography Clinical Protocols

We set up three protocols: telediagnosis, teleconsultation, and telemanagement as a means to evaluate the effectiveness of the FFDDM telemammography system.

Telediagnosis protocol tests the clinical effectiveness of telemammography from image transmission of FFDDM's versus on-site interpretation of conventional film-screen mammograms.

Teleconsultation protocol tests the efficacy of remote consultation on *problem cases*. The aim here is to evaluate the ability of telemammography to facilitate real-time consultation between on-site general diagnostic radiologists and remotely located expert mammographers. Currently, such consultations are tedious, time-consuming, and logistically complex, to the point where they usually are reserved for only the most confusing cases. If successful, teleconsultation should enhance the consultative process such that it becomes much more widely utilized, thereby bringing mammographic interpretive expertise to bear at the community practice level.

Telemanagement protocol tests the efficacy of *remote real-time management and interpretation* of mammography examinations. The goal of telemanagement is more ambitious than that of teleconsultation: to completely replace the on-site general radiologist with remotely located expert mammographers.

## IV. TELEMAMMOGRAPHY TECHNICAL ISSUES

### A. Image Compression

As described in Section II-B, each digital mammogram generated from the FFDDM system is approximately 46 megabytes (4 K × 5.6 K × 2 bytes) in size. A breast screening examination usually contains two craniocaudal (CC) views and two mediolateral oblique (MLO) views. Thus, an examination will produce four images (or 184 megabytes). Therefore, data compression techniques are needed to reduce digital mammogram file size to facilitate storage and communication.

On-line structure lossless and wavelet lossy compression algorithms have been developed for this purpose. The on-line lossless method is based on segmentation of the breast region from the background and then applying prediction coding on the breast. Data can be compressed immediately after the first few lines of the image are acquired. Pipeline processing can be activated for both data acquisition and compression while the remaining data are acquired from the FFDDM. The average compression ratio of this algorithm is about 3-4:1 [20]. The wavelet lossy method can achieve much higher compression ratios and still retain diagnostic quality. Fig. 2 is an example of the wavelet compression with a simple uniform quantization showing the original image, the 20:1 decompressed image, and the difference between the original and the compressed images.

### B. Telemammography Chain

Currently, the major components in our telemammography system include one Senoscan FFDDM system, one data management system, two high-resolution ( $2 \times 2.5$  K) digital mammogram display workstations, and one laser film imager (model Li-21) from Konica Medical Corporation (Wayne, NJ). The Senoscan FFDDM system serves as the image acquisition component; the data management system functions as the database server for image archival and retrieval; the two display workstations provide soft copy display; and the laser film imager prints hard copy (films), which are used to compare image quality between soft copy display and hard copy film. All of these components are located at either the Breast Imaging Section, MZH, or the Laboratory for Radiological Informatics (LRI), UCSF medical center. To integrate these components into a functional telemammography system, wide and local area digital communication networks are essential.

1) *Digital Communication Networks*: There are a number of wide area network (WAN) technologies currently available on the market, such as Integrated Standard Digital Network (ISDN), Digital Service Private Line Mode-0 (DS-0), DS-1 (or T-1 line), DS-3 (or T-3 line), and ATM. In general, the service charges of the ISDN, DS-0, and T-1 are affordable; however, their communication bandwidth (between 56 KBits/s and 1.544 MBits/s) is not suitable for telemammography applications due to the large image file size. On the other hand, the service charges for T-3 and ATM are high, but their bandwidth is more suitable for telemammography applications. Table II shows a study of the data transfer rate of T-1 versus ATM OC-3 (155 MBits/sec) technologies. Currently, we can transmit a 40-megabyte mammogram in 5.3 s with the ATM. This ATM communication speed compared with 400 s for the T-1 allows the utility of real-time telemammography to be realized. In our telemammography project, the ATM technology was used for three reasons: 1) to utilize the existing campus-wide UCSF OC-12 Sonet Ring, 2) to accommodate the high-bandwidth requirement of the telemammography practices, and 3) to take advantage of the WAN and local area network (LAN) capability offered by ATM.

2) *Interhospital ATM Network Architecture*: Fig. 3 illustrates the major computer systems of the telemammography project interconnected with an ATM network. The main

TABLE II  
TIME REQUIRED TO SEND 10-MEGABYTES, 40-MEGABYTES FFDDM IMAGES FROM MZH TO ACC USING T1 AND ATM (OC3) (NO COMPRESSION)

	2K x 2.5K x 2 bytes (10 Mbytes)		4K x 5K x 2 bytes (40 Mbytes)	
	One image	One exam 4 images	One image	One exam 4 images
	T1 (1.5 Mbits/s) realization 100 Kbits/s	100 sec (1.6 min)	400 sec (6.7 min.)	400 sec (6.7 min.)
ATM (155 Mbits/s) realization 60-70 Mbits/s (7.5 Mbytes/s)	1.3 sec	5.3 sec	5.3 sec	21.3 sec

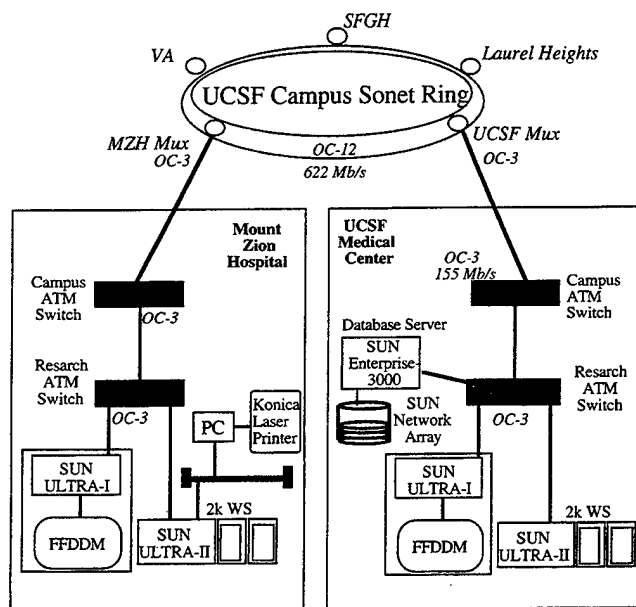


Fig. 3. Telemammography infrastructure at UCSF.

networking components are two FORE ASX-200BX ATM switches (Mountain View, CA). One located in the UCSF medical center and the other located at the MZH. The ATM switches communicate across the newly established UCSF OC-12C Sonet Ring linking the two sites.

Each of the switches can be configured with four network modules. Depending upon applications, each of the network modules can be configured as one 622-MBits/s port (OC-12) or four 155-MBits/s ports (OC-3C). Currently, our telemammography application uses the OC-3C modules. One of the ports in each of the ATM switches is reserved for the WAN connection to the UCSF campus Sonet Ring, as shown in Fig. 3. Locally, the computer systems are linked with the ATM switches via ATM host adaptor cards. The FORE SBA-200E host adaptor card was used for this requirement.

With this ATM network, we deployed one display workstation and one image acquisition computer associated with

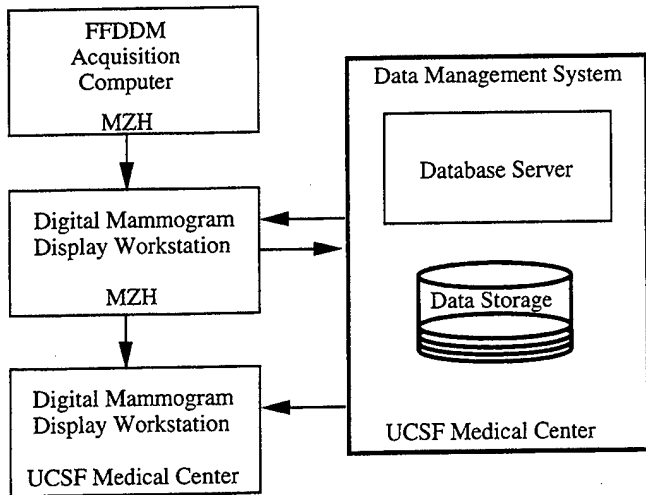


Fig. 4. Data flow of a digital mammogram.

the Senoscan FFDDM system at the MZH; the other display workstation and the data management system were installed at the UCSF medical center. The Konica laser film imager was installed at MZH and was attached to a PC, which functions as a print server. The display workstation at MZH transfers digital mammograms to the print server for photographing via a local area Ethernet connection.

3) *Image Communication Protocol*: The telemammography chain used in this study is fully compliant with the Digital Imaging and Communications in Medicine (DICOM) standard. The FFDDM images generated from the Senoscan system contain the file format and information following DICOM information object definitions. Images transferred between the acquisition computer, the display workstations, and the data management system use the DICOM storage service class. The data management system supports the DICOM query and retrieve service class for image retrieval. To photograph digital mammograms onto films, the PC print server supports the DICOM print service class.

4) *Digital Mammogram Data Flow*: Digital mammograms generated by the FFDDM system are first subsampled to  $600 \times 800$  pixels in the acquisition computer memory and displayed on the console monitor for quality assurance. The technician may adjust the contrast and brightness of the image to assess its quality. If the image quality is poor, it may be rejected and another scan performed. If the image quality is good, the mammogram is automatically transmitted to the display workstation at MZH through the ATM network using the DICOM storage class service. Once the image is received at the workstation, it is queued and transmitted to the second display workstation and the data management system located at the UCSF campus through the Sonet Ring. The copy of the images transferred to the data management system is for archival purposes. To test the teleconsultation and telemanagement protocols, the FFDDM images must be transferred to the second display workstation in a timely fashion. For this reason, all images queued to be transferred for archival have lower priority than those to be transferred to the display workstation at the UCSF medical center. Fig. 4 is a diagram illustrating the data flow.

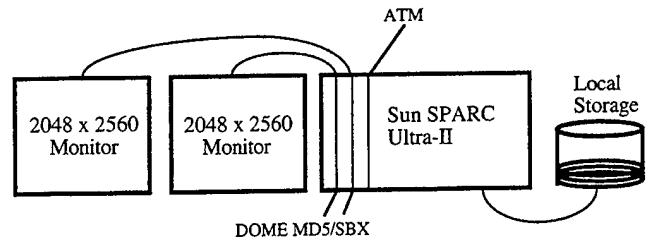


Fig. 5. Schematic of the digital mammogram display workstation.

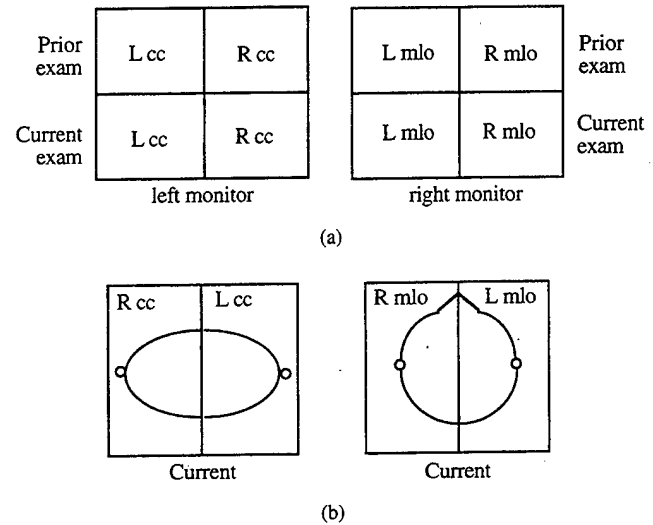


Fig. 6. Display modes: (a) two images on one monitor and (b) four images on one monitor.

### C. FFDDM Image Display

Monitors displaying  $4 \times 5.6$ -K pixels and 4096 gray levels are not commercially available. If they were, they would be costly. Monitors presenting  $2 \times 2.5$ -K pixels and 256 gray levels are available at affordable prices. To display the FFDDM images on this type of monitor and retain the image quality is a challenging task for three main reasons: 1) the spatial resolution of the FFDDM images may be reduced; 2) the grayscale resolution can be sacrificed; and 3) the number of images that can be displayed at one time is limited. An alternate method is to photograph the FFDDM images onto films as a hard copy and then view the mammograms via standard light boxes. However, the film approach will increase the cost of examination and not take full advantage of the FFDDM technology. Our intention is to develop a digital mammogram display workstation using the available monitor technologies for soft copy display and to use the soft copy for diagnostic purposes. The hard copy is particularly useful in the beginning of this project because it provides a means to compare the digital mammogram quality with the soft copy display. In addition, a hard copy is also used if a referring physician requests a copy for their file or for a presentation view graph.

1) *Hard Copy*: Digital mammograms may be printed in hard copy using the Konica laser film imager ( $50 \mu\text{m}/\text{pixel}$ ). The imager can record an FFDDM image with 12-bit information onto an  $8 \times 10$  " film. The laser film imager is attached

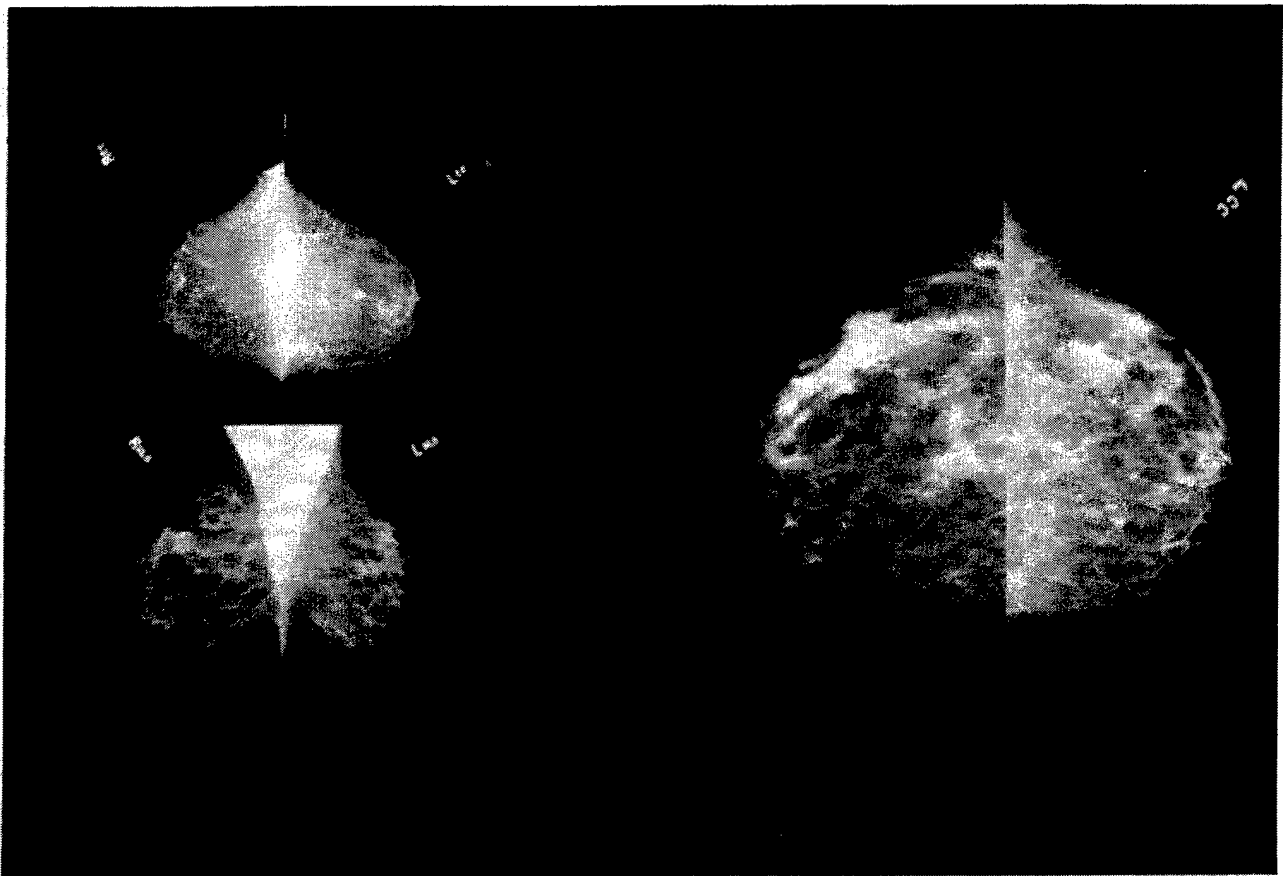

Fig. 7. FFDDM images displayed on  $2 \times 2.5$ -K monitors with 4-on-1 mode and 2-on-1 mode.

through a SCSI port to the print server (i.e., the PC), which acts as a DICOM converter. A GUI program in the mammogram display workstation controls the printing process. In the display workstation, the DICOM print client software issues a print service command to the PC, where it is converted to a native format for printing.

There are two methods that can be used in conjunction to match the appearance of the hard copy images with the soft copy format: 1) selecting one of seven preprogrammed lookup tables from the printer that best matches the characteristics of the monitor and 2) manipulating the contrast and brightness values that are stored in the DICOM header. The print client software interprets the DICOM header and communicates the contrast and brightness values to the print server.

2) *Soft Copy*: Digital mammograms can be viewed in soft copy format by using the digital mammography display workstation designed and implemented in-house. The display workstation utilizes the SUN SPARC Ultra-II platform (Mountain View, CA) with one 200-MHz CPU and 512 megabytes of memory, two DOME MD5-SBX boards (Waltham, MA), and two  $2 \times 2.5$ -K high-resolution Data Ray monitors (Westminster, CO). Fig. 5 shows the block diagram of the digital mammogram display workstation. The display workstation has the following features.

- 1) A DICOM image server process, which continually runs in the background to receive DICOM format images from any systems connected to the ATM network.

- 2) A three-layer hierarchy local database, which keeps track of information about patients, examinations, and images. The database allows the presentation of a patient list in the image display software, as described below. In addition, it provides a means to remove old images from the local storage to maintain enough space for new images. Attributes, such as patient name, hospital identification number, and birth date, are recorded for locating a particular patient. It is possible for patients to have multiple mammography examinations. The patient key is designed to use a combination of the examination date, time, and patient hospital identification number to guarantee that each examination is unique. Each examination may contain several images. A description of the patient positioning, such as breast laterality and view, is saved in the database.
- 3) A window-based image display and manipulation software, which provides users with a GUI environment for accessing patient information including text and images. A patient list allows users to browse through patients and their associated examinations and images. Images may be displayed in 1:1 (one image per monitor), 2:1, or 4:1 format using the two 2-K display monitors (see next section for details). Since the image matrix is  $4096 \times 5625$ , none of the above display modes can present a full-resolution FFDDM image on a single monitor. It is possible that the portion of the image displayed on the

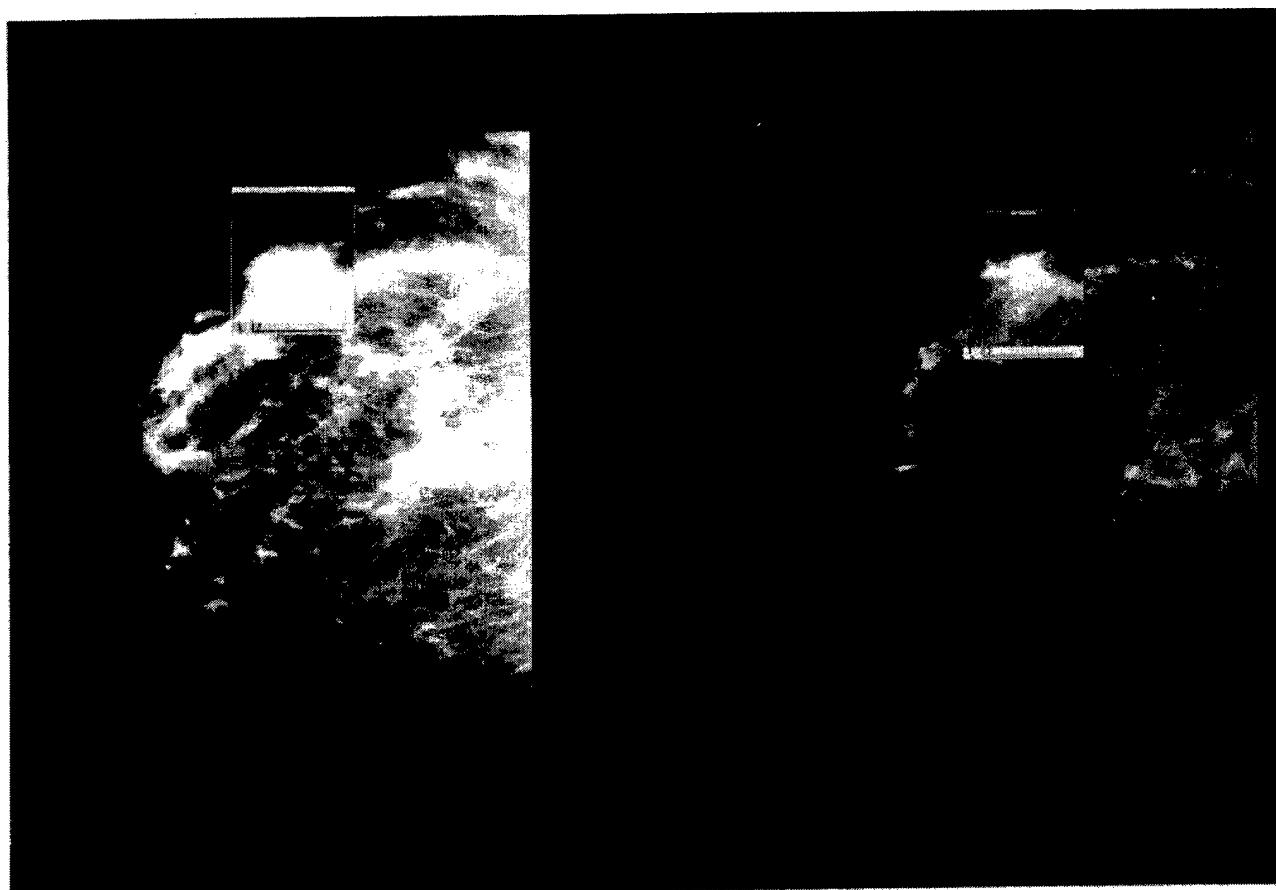


Fig. 8. A case illustrating the advantage of presenting FFDDM images with soft copy display.

monitors is background air. To insure that the relevant image information is displayed, the breast laterality is used to set the output rectangle of the image. The images in any of the display modes can be instantly expanded to full resolution ( $4 \times 5.6$  K) in 1:1 format and vice versa. With these two image display features, unnecessary operations of the display workstation are minimized. In addition, functions such as pan-and-scroll, window-and-level, scalable magnifying glass, rotation, and on-screen image exchange are provided to facilitate users' viewing practice.

3) *Display format*: As described in Section IV-A, a standard mammographic examination consists of a CC and an MLO view of each breast, a total of four images per examination. For comparison purposes, four images from a prior examination of similar views are also used. Therefore, an optimal display mode should show eight mammograms in proper orientation [21]. Figs. 6 and 7 illustrate two of the display modes that were implemented in the digital mammogram display workstation: two images on one monitor and four images on one monitor.

## V. PRELIMINARY PATIENT STUDY

### A. Patient Selection

Patient examination involves normal and abnormal cases. Normal patients can be recruited from regular screening ex-

aminations. The abnormal case selection was conducted by the Chief of the Breast Imaging Section during conventional mammography readings. From these readings, those patients suspected to have masses or calcifications were called in for further examinations.

### B. Patient Consent

The call-in patients were considered as candidates for this project. We discussed with these patients their options for further examinations, including the FFDDM examination. Those patients who accepted the FFDDM examination signed a consent form based on the approved protocol H1110-12421-02. We followed the study protocol in which only two views (CC and MLO) would be taken. So far, 60 patient examinations have been conducted.

### C. Preliminary Image Quality Study

All images were viewed using the digital mammography display workstation. Preliminary results indicate that the FFDDM images displayed on the display workstation are of good quality. All the lesions shown on conventional mammograms can be clearly identified on the workstation with add-on values of enhancement and manipulation features. Fig. 8 shows an example case in which soft copy display is particularly useful for viewing dense breast tissues, within which mammographers often have difficulty in detecting lesions. Both monitors show the same FFDDM image with

different window and level settings. In the left monitor, the window and level values present generally good contrast and brightness for the entire image. However, the region of dense breast tissues enlarged by the magnifying glass is completely whited out. The image can be manipulated by applying a different set of window and level parameters, as shown in the right monitor. Here, more detailed structure information can be perceived in the region of dense tissues, although the image as a whole seems to be dim. We have also printed two patient cases with the Konica laser imager for comparison of image quality. The printed image quality is comparable to that of the conventional mammogram.

## VI. FUTURE DIRECTIONS


We have completed the first phase of a three-year comprehensive program in developing the application of telemammography. This phase is to resolve the technical issues of the telemammography system, as discussed in this paper. The second phase is to set up a second FFDDM system in the UCSF Ambulatory Care Center, where the mission of healthcare delivery is toward outpatient. The goal is to compare the mammography service between the two sites with different operating environments, one being the expert site while the other is an outpatient clinic. The last phase is to collect sufficient patient data to evaluate the effectiveness and efficacy of telemammography with the three clinical protocols.

## ACKNOWLEDGMENT

The authors would like to thank M. Tesic and M. Piccaro of Fischer Imaging Corporation for their contributions as well as J. Sayre of UCLA for the experimental design.

## REFERENCES

- [1] C. Boring, T. Squires, and T. Tong, *Cancer Stat.*, vol. 42, pp. 19–38, 1992.
- [2] S. Feig, "Decreased breast cancer mortality through mammographic screening: Results of clinical trials," *Radiology*, vol. 167, pp. 659–665, 1988.
- [3] S. Shaprio, W. Venet, P. Strax *et al.*, "Selection, follow-up, and analysis of the health insurance plan study: A randomized trial with breast cancer screening," *J. Nat. Cancer Inst. Mono.*, vol. 67, pp. 65–74, 1985.
- [4] L. Tabar, G. Faberberg, G. W. Duffy, N. Day, A. Gad, and O. Grontoft, "Update of the Swedish two-county program of mammographic screening for breast cancer," *Radiol. Clin. North Amer.*, vol. 30, pp. 187–210, 1992.
- [5] O. Noriaki and Y. Koichi, "Improved detection rate of early breast cancer in mass screening combined with mammography," *Hap. J. Cancer Res.*, vol. 84, no. 7, pp. 807–812, 1993.
- [6] R. Smathers *et al.*, "Mammographic microcalcifications: Detection with Xerography, screen-film and digitized film display," *Radiology*, vol. 159, pp. 673–677, 1986.
- [7] D. Getty, R. Pickett, C. D'Oris, and J. Swets, "Enhanced interpretation of diagnostic images," *Invest. Radiol.*, vol. 23, pp. 240–252, 1987.
- [8] H. Chan *et al.*, "Improvement in radiologists' detection of clustered microcalcifications on mammograms," *Invest. Radiol.*, vol. 25, pp. 1102–1110, 1990.
- [9] D. Davies and D. Dance, "Automatic computer detection of clustered calcifications in digital mammograms," *Phys. Med. Bio.*, vol. 35, pp. 1111–1118, 1990.
- [10] N. Karssemeijer, "A stochastic model for automated detection of calcifications in digital mammograms," *Image Vision Comput.*, vol. 10, pp. 369–375, 1992.
- [11] E. Sickles, "Current Status of Digital Mammography," in *Proc. 7th Int. Congr. Senol. (Excerpta Medica Int. Congr. Series)*. Amsterdam, The Netherlands: Elsevier, 1993.
- [12] M. Nelson, "A clinician's view of digital mammography," in *Proc. 4th Int. Conf. Imaging Manage. Commun.*, 1995, pp. 235–237.
- [13] H. K. Huang, "Teleradiology technologies and some service models," *Comput. Med. Imaging Graph.*, vol. 20, pp. 59–68, 1996.
- [14] L. Fajardo *et al.*, "Detection of breast abnormalities on teleradiology transmitted mammograms," *Invest. Radiol.*, vol. 25, pp. 1111–1115, 1990.
- [15] E. Toker and M. Piccaro, "Design and development of a fiber optic TDI CCD-based slot-scan digital mammography system," *Proc. SPIE*, 1993, p. 2009.
- [16] M. Tesic and M. Piccaro, "Digital mammography scanner: Performance characteristics and preliminary clinical results," *IEEE Colloquium Digital Mammography*, London, U.K., 1996, pp. 3/1–3/7.
- [17] H. K. Huang, "Clinical experience with a second-generation hospital-integrated picture archiving and communication system," *J. Digital Imaging*, vol. 9, pp. 151–166, 1996.
- [18] E. Sickles, S. Ominsky, R. Sollitto, H. Galvin, and D. Monticciolo, "Medical audit of a rapid-throughput mammography screening practice: Methodology and results of 27,114 examinations," *Radiology*, vol. 175, pp. 323–327, 1990.
- [19] E. Sickles, "Quality Assurance: How to audit your own mammography practice," *Radiol. Clin. North Amer.*, vol. 30, pp. 265–275, 1992.
- [20] J. Wang, "Three-Dimensional Wavelet Compression," Ph.D. dissertation, Univ. of California, Los Angeles, 1996.
- [21] S. L. Lou, E. Sickles, J. Wang, and H. K. Huang, "A high resolution display system for mammograms," *Radiology*, vol. 193(P), p. 474, 1994.



**S. L. Lou** (S'81–M'82–M'93) received the B.S. degree in biomedical engineering from Chung-Yuan Christian University, Taiwan, R.O.C., in 1982 and the Ph.D. degree in biomedical physics from the University of California, Los Angeles (UCLA), in 1991.

He was a Visiting Assistant Professor in the Division of Medical Imaging, Department of Radiological Sciences, UCLA, from 1991 to 1992. He is currently an Assistant Professor in the Laboratory for Radiological Informatics, Department of Radiology, University of California, San Francisco (UCSF). He also holds a joint faculty appointment in the UCSF/University of California, Berkeley, Bioengineering Graduate Program. His major research activities over the past ten years have been in design and implementation of picture archiving and communication systems (PACS), telemedicine, and image processing.

**Edward A. Sickles** received the A.B. degree in zoology and chemistry from Columbia University, New York, NY, in 1965 and the M.D. degree in medicine from Cornell University Medical College, Ithaca, NY, in 1969.

He is Professor and Chief of the Breast Imaging Section, Department of Radiology, University of California, San Francisco. His major research activities include digital mammography and mammography outcomes research.

Dr. Sickles was the President for the American Society of Breast Disease from 1986 to 1989 and the Society of Breast Imaging from 1989 to 1990.

**H. K. Huang** (SM'88) is a Professor, Vice-Chairman, and Director of Radiological Informatics Laboratory, Department of Radiology, University of California, San Francisco (UCSF), with a joint appointment in the UCSF/University of California, Berkeley, Bioengineering Graduate Program. He has been working on PACS research and development since 1982. He implemented a PACS at University of California, Los Angeles (UCLA), in 1991 and a second-generation PACS at UCSF in 1994. His current research interests are in medical multimedia, high-speed medical image transmission, telemammography, and medical imaging informatics infrastructure design. He has published over 180 research papers and co-authored six books and trained over 50 Ph.D. students and postdoctoral fellows in medical-imaging-related research during the past 20 years.

**David Hoogstrate** received the B.A. degree in mathematics and geography from the University of Colorado, Boulder, in 1994.

He was a Research Assistant at the Cooperative Institute for Research in Environmental Science, University of Colorado, from 1994 to 1995. He is the System Manager of the LRI, Department of Radiology, University of California, San Francisco (UCSF). For the past three years, his research activity has focused on cryospheric research, PACS image acquisition, multimedia interface, digital mammography imaging, and asynchronous transfer mode network.

**Fei Cao** received the B.Sc. degree in space physics from Peking University, Peking, China, in 1982, the M.Sc. degree from the Chinese Academy of Sciences, Peking, in 1985, and the Ph.D. degree in space physics from the University of Alaska, Fairbanks, in 1991.

He was a Postdoctoral Fellow from 1992 to 1994 in the Max-Planck Institute, Germany. He is a Research Fellow in the Laboratory for Radiological Informatics, University of California, San Francisco. His research interests include medical imaging, computer-aided instruction models, network architecture, and Web applications.

**Jun Wang** received the B.S. degree in physics from Peking University, Peking, China, in 1984, the M.Sc. degree in medical physics from Chinese Academy of Sciences, Peking, in 1987, and the Ph.D. degree in biomedical physics from University of California, Los Angeles, in 1996.

She is currently with Philips Medical System, Palo Alto, CA.

**Mohammad Jahangiri** received the M.D. degree from the Army Medical College, Pakistan, in 1983 and the M.S. degree in public health from the University of California, Berkeley, in 1991.

He received his postdoctoral training in radiological informatics from the University of California, San Francisco, in 1997. He is now completing his residency in Diagnostic Medicine at the University of Virginia, Charlottesville. His research focuses on medical imaging informatics.

# Full-Field Direct Digital Telemammography: System Implementation

S.L. Lou<sup>1</sup>, H.K. Huang<sup>1</sup>, Edward Sickles<sup>2</sup>, David Hoogstrate<sup>1</sup>,  
Fei Cao<sup>1</sup>, and Jun Wang<sup>3</sup>

1. Laboratory for Radiological Informatics,  
2. Breast Imaging Section,  
Department of Radiology, University of California San Francisco,  
530 Parnassus Avenue, Rm. CL-158, San Francisco, CA 94143-0628, USA

3. Now with Philips Research Lab, Palo Alto, CA

## ABSTRACT

We are in the process of conducting a research of full-field direct digital telemammography using three protocols: telediagnosis, teleconsultation, and telemanagement. To conduct this research project, an asynchronous transfer mode network based telemammography system was developed across two remote campuses in our facility. The hardware and software components of this system are detailed. The system was embedded in a clinical environment for a four-month test. Some preliminary study results from the current phase of this study are reported.

Key words: digital mammography, high speed networking, high resolution display, teleradiology

## I. Introduction

The early detection of breast cancer increases the survival rate in women [1]. Today, film-screen mammography is the most common and effective technique for the detection of breast cancer [2-4]. However, the film-screen image recording system of current mammography has several technical limitations that can reduce the breast cancer diagnostic accuracy. A state-of-the-art technology, full-field direct digital mammography (FFDDM), has the potential to increase the sensitivity of clinical and screening examinations and emerge as a film screen mammography replacement [5]. It is believed that efficiently delivering the superior image quality of FFDDM to expert mammographers will significantly increase the breast cancer diagnostic accuracy. This concept motivates the studies of full-field direct digital (FFDD) telemammography.

In our previous work, we reported on three protocols, telediagnosis, teleconsultation, and telemanagement, to evaluate the FFDD telemammography concept [6,7]. We also presented a plan on how to develop such a test-bed for this evaluation study. Since then we have implemented the FFDD telemammography system between two campuses: UCSF medical center (or main campus) and Mount Zion Hospital (MZH) where our mammography expert center is. These two

campuses are two miles apart. In this paper, we first present our newly established asynchronous transfer mode (ATM) network-based tele mammography system. Then, a four-month clinical test is described. The test results regarding the time measurements of the system processing and preliminary image quality studies are reported. Based on these measured results, we estimated the elapsed time required for users to view the FFDDM images either at MZH or at the UCSF main campus. Finally, we discuss the possible approaches to optimize the image delivery performance.

## II. Tele mammography Test-Bed

We present the tele mammography test-bed in two aspects: hardware configuration and software implementation. In the hardware configuration aspect, the major computer and network systems and their associated functions are described. Based upon the hardware setup, software programs that we have developed to integrate all the components into a functional tele mammography system are given.

### II.1 Hardware configuration

Currently, the major components in our tele mammography system include one FFDDM system (the second system will be installed in September 1998), one data management system, two high resolution (2K x 2.5K) digital mammogram display workstations, and one Laser film imager. Figure 1 illustrates the configuration of this tele mammography system.

#### II.1.1 FFDDM system

The FFDDM system serves as the image acquisition component in the tele mammography system. It uses a slot-scanning based technology with a novel Charge-Coupled Device (CCD) detector from Fischer Imaging Corporation. (Denver, CO) [8,9]. The system contains an imaging unit and an acquisition computer which is a Sun Ultra-I computer system (Mountain View, CA). The imaging unit and the acquisition computer are linked by an electronic board developed by Fischer.

The image area of the FFDDM system is a rectangular of  $240 \times 300 \text{ mm}^2$ . The spatial resolution of a generated image is  $54 \times 54 \mu\text{m}^2$  per pixel in nominal and  $27 \times 27 \mu\text{m}^2$  in high resolution which is approximately to 9 line-pairs (lp) per mm and 18 lp/mm, respectively. The matrix size of the image is  $4,096 \times 5,625$  (4K x 5.5K) pixels, with 12 bits/pixel which is stored within 2 bytes. As a result, each image is about 46 Mbytes.

#### II.1.2 Data management system

The data management system functions as the database server for image archival and retrieval. The system is composed of a Sun Enterprise-3000 computer, a 42-Gbyte Sun Network Array Disk, and five fast-wide small computer standard interface (SCSI) disks (4 x 4.2 Gbytes and 1 x 2.1 Gbytes). In this management system, we store the digital mammogram data either in the Array Disk or in the SCSI disks while patient demographic information is managed by an Oracle database software.

### **II.1.3 Digital mammogram display workstations**

The two display workstations provide soft copy display for this telemammography system. Each of the display workstations consist of the following components:

- (1) one Sun Ultra-II that contains one 200-MHz CPU, 512-MByte CPU memory, and a 4.2-Gbyte fast-wide SCSI disk,
- (2) two DOME MD5-SBX display boards; each is assembled by 5 mega-pixel video RAM, one 10-bit digital to analog converter, and one 16-bit to 8-bit look-up-table, and
- (3) two Data Ray monitors (Westminster, CO); each provides 2,048 x 2,560 pixel matrix, 64 Hz frame rate, and 120 foot-lamber (maximum light output).

The image display and manipulation program is developed in-house and based on X-Motif and DOME image processing software libraries.

### **II.1.4 Laser film imager**

The laser film imager prints hard copy (films) which are used to compare image quality between soft copy display and hard copy film. Specifically speaking, the film imager includes two components: a PC computer and the laser imager. The PC computer serves as an interface between other computer systems and the laser imager via an Ethernet. The laser imager is able to photograph 4,096 x 5,120 pixels onto a film with 4096 gray levels.

### **II.1.5 ATM network**

All the components stated above (except for the laser film imager) are linked with an ATM network. In this ATM network configuration, two switches (one at each of the two campus) communicate through a UCSF Sonet ring sharing an OC-3C bandwidth (155 Mbits/second). Locally, the switches serves as a root to exchange information among the computer systems.

## **II.2 Software implementation**

In the present stage of the system development, our aim is to assure the images smoothly flow from the FFDDM system to the display workstations. The fundamental software includes DICOM communication programs, a workstation database program, and an image display and manipulation program.

### **II.2.1 DICOM communication software**

We use the Digital Imaging and Communications in Medicine (DICOM) communication protocols to transfer images such as storage, query, retrieve, and print service classes. The images generated by the FFDDM system contain the file format and information following DICOM information definitions. Digital mammograms transferred between computer systems are based on the DICOM storage service class. Currently, the data management computer system and the two display workstations can provide roles of service class provider (SCP) and service class user (SCU). The FFDDM acquisition computer only acts as an image client. The DICOM query/retrieve service class is established between the data management

computer only acts as an image client. The DICOM query/retrieve service class is established between the data management system and the two display workstations. The PC computer associated with the laser film imager provides the DICOM print class service. In the current stage, we only configure this service class between the PC and the digital mammogram display workstation in MZH.

### **II.2.2 Workstation database software**

Before a digital mammogram is ready for users to display in the image display workstation, it is processed by a workstation database software. The process includes (1) dividing the DICOM format file into a DICOM header file and an image pixel file, and (2) extracting information from the header file to form a local database. The database is a three-layer hierarchy which keeps track of information about patients, examinations, and images. The database allows us to present a patient list GUI in the image display software as described in Section II.2.3. In addition, it provides a means to remove old images from the local storage to maintain enough space for new images. Attributes such as patient name, hospital identification number, and birth date are recorded for locating a particular patient. It is possible for patients to have multiple mammography examinations. The patient key is designed to use a combination of the examination date, time, and patient hospital identification number to guarantee that each examination is unique. Each examination may contain several images. A description of the patient positioning, such as breast laterality and view, is saved in the database.

### **II.2.3 Image display and manipulation software**

A window-based image display and manipulation software is developed for providing users with a GUI environment for accessing patient information including text and images. A patient list allows users to browse through patients and their associated examinations and images. Images may be displayed in 1:1 (one image per monitor), 2:1, or 4:1 format using the two 2K display monitors. Since the image matrix is 4,096 x 5,625, none of the above display modes can present a full resolution FFDDM image on a single monitor. It is possible the portion of the image displayed on the monitors is background air. To insure the relevant image information is displayed, the breast laterality is used to set the output rectangle of the image. The images in any of the display modes can be instantly expanded to full resolution (4K x 5.6K) in 1:1 format, and vice versa. With these two image display features unnecessary operations of the display workstation are minimized. In addition, functions such as pan-and-scroll, window-and-level, scalable magnifying glass, rotation, and on-screen image exchange are provided to facilitate users' viewing practice.

## **III. Clinical Test and Preliminary Results**

### **III.1 Patient collection**

The telemammography system has been released for clinical testing since September 1997. Based on our clinical protocol, patients who have completed a film-screen mammography may have two additional FFDD mammograms of one breast with informed consent. This is conducted as follows:

- (1) Patient examination involves normal and abnormal cases.
- (2) Normal patients can be recruited from regular screening examinations.
- (3) The abnormal case selection is conducted by the chief of the Breast Imaging Section during conventional mammography readings. From the reading, those patients suspected to have masses or calcifications were called in for FFDDM examinations.
- (4) Only one cranio-caudal (CC) view and one medio-lateral oblique (MLO) view would be taken.

In four months, we have examined thirty-one patients with the FFDDM system.

### III.2 Telemammography operations

Digital mammograms acquired by the FFDDM system are first sub-sampled to 600 x 800 pixels in the acquisition computer memory and displayed on the console monitor for quality assurance. The technician may adjust the contrast and brightness of the image to assess its quality. If the image quality is poor, it may be rejected and another scan performed. If the image quality is good, the mammogram is automatically transmitted to the display workstation at MZH through the ATM network using the DICOM storage class service. Once the image is received at the workstation, it is first processed by the workstation database program; then it is queued and transmitted to the data management system located at the UCSF campus through the Sonet Ring. The data management system then relays the image to the second image display workstation at the main campus.

We embedded logging software to show the elapsed time spent in the image delivery and display programs. Our preliminary results indicate the image transfer performance of the local area ATM is better than that of wide area ATM. It takes 5-6 seconds to transfer one 46-MByte mammogram from one computer system to another (disk to disk) in ATM network. The image display workstation database program takes about 25 seconds to process one image. For image display, we measured that it requires about 8-9 seconds to display one digital mammogram from the local fast-wide SCSI onto the image display monitor.

### III.3 Preliminary image quality study

All images were viewed using the digital mammography display workstation. Preliminary results indicate that the FFDDM images displayed on the display workstation are of good quality. All the lesions shown on conventional mammograms can be clearly identified on the workstation with add-on values of enhancement and manipulation features. Figure 2 shows an example case that soft copy display is particularly useful for viewing dense breast tissues within which mammographers often have difficulty in detecting lesions. Both monitors show the same FFDDM image with different window and level settings. In the left monitor, the window and level values present generally good contrast and brightness for the entire image. However, the region of dense breast tissues enlarged by the magnifying glass is completely washed out. The image can be manipulated by applying a different set of window and level parameters as shown in the right monitor. Here, more detailed structure information can be perceived in the region of dense tissues although the image as a whole seems to be dim. We have also printed two patient cases with the Konica laser imager for comparison of image quality. The printed image quality is comparable to that of the conventional mammogram.

#### IV. Discussions

The elapsed time from the moment when a digital mammogram is accepted by a technologist in the FFDDM system to the time when the image is displayed on the MZH display workstation includes (1) the transmission time from the FFDDM acquisition computer to the workstation, (2) the queue time and the workstation database processing time, and (3) the image display time. If the image is also required to be displayed on the UCSF campus workstation, the elapsed time also includes: (1) the queue time and the transmission time from the MZH workstation to the data management system, (2) the queue time and transmission time from the data management system to the UCSF campus workstation, (3) the queue time and the workstation database processing time, and (4) the image display time. The queue time for each of the processes is set to 10 seconds. Based on the image transfer and display performances described in Section III.2, it is estimated that the elapsed time for an image to be displayed in the MZH and UCSF campus display workstations is about 50 seconds and 120 seconds, respectively.

The telemammography operations described in Section III.2 were for testing the entire image flow of the system. It is possible to independently transfer images from the FFDDM acquisition computer to the image display workstations in both at MZH and at the main campus. In this way, the time duration spent in the data management system and associated process queue time can be eliminated. As a result, it will be faster for users to view the image at the UCSF campus workstation. On the other hand, the workload of the FFDDM system will be increased which may slow down the following imaging procedures for the technologist.

#### V. Future Work

We have completed the first phase of a three year comprehensive program in developing the application of telemammography. This phase is to resolve the technical issues of the telemammography system as discussed in this paper. The second phase is to set up a second FFDDM system in the UCSF Ambulatory Care Center where the mission of health care delivery is toward out patient. The goal is to compare the mammography service between the two sites with different operating environment, one being the expert site while the other is an outpatient clinic. The last phase is to collect sufficient patient data to evaluate the effectiveness and efficacy of telemammography with the three clinical protocols.

#### Acknowledgments

This research is partially supported by the California Breast Cancer Research Program: "Real-Time Telemammography" (IRB-0148), the US Army Medical Research Materiel Command: "Full-field Direct Digital Telemammography" (DAMD-96-C-6111), the National HPCC Program, National Library of Medicine: "A High-Performance Testbed Network for Collaborative Health Care" (N01-LM-4-3508), and the Department of Health and Human Services: "Optimization of Soft Copy Display Parameters for Digital Mammograms" (282-97-0079).

## References

- [1] O. Noriaki, Y. Koichi, "Improved Detection Rate of Early Breast Cancer in mass screening combined with mammography," *Hap. J. Cancer Res.* vol. 84, no. 7, pp. 807-812, 1993.
- [2] S. Feig, "Decreased breast cancer mortality through mammographic screening: Results of clinical trials," *Radiology*, vol. 167, pp. 659-665, 1988.
- [3] S. Shaprio, W. Venet, P. Strax, et. al., "Selection, follow-up, and analysis of the health insurance plan study: a randomized trial with breast cancer screening," *J. Natl Cancer Inst Monogr.* vol. 67, pp. 65-74, 1985.
- [4] L. Tabar, G. Faberberg G, W. Duffy, N. Day, A. Gad, and O. Grontoft, "Update of the Swedish tw\_-county program of mammographic screening for breast cancer," *Radiol Clin North Am.* vol. 30, pp. 187-210, 1992.
- [5] National Cancer Institute (NCI) / National Aeronautics and Space Administration. (NASA) Workshop "Digital Mammograph", May 19-20, Washington, D.C.
- [6] S.L. Lou, E.A. Sickles, H.K. Huang, et. al. Full-Field Direct Digital Telemamimography - Preliminary *SPIE Proceedings*, Medical Imaging, PACS Design and Evaluation, vol 3035, pp. 369-379, 1997.
- [7] H. Huang, "Teleradiology Technologies and Some Service Models." *Comp. Med. Imaging & Graphics* vol. 20, pp. 59-68, 1996
- [8] E. Toker and M. Piccaro, 1993. Design and Development of a Fiber Optic TDI CCD-Based Slot-Scan Digital Mammography System. *SPIE Proceedings*, Medical Imaging, 2009.
- [9] M. Tesic and M. Piccaro, "Digital Mammography Scanner: Performance Characteristics and Preliminary Clinical Results," *IEEE*, Savoy Place, London WC2R OBL, UK, pp. 3/1-3/7, 1996.

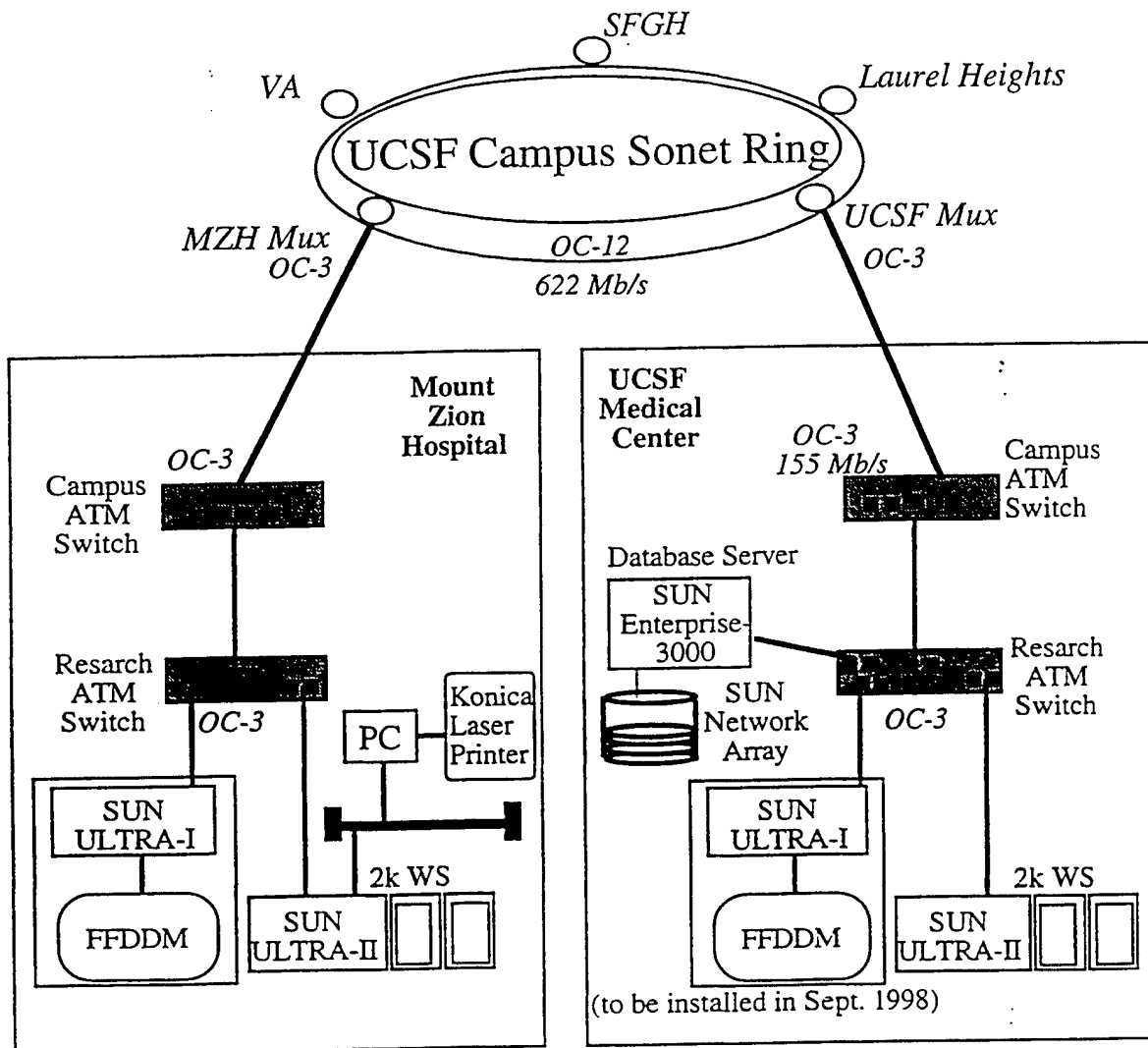


Figure 1

# DICOM Image Transmission for Real-time Telemanagement of Full Field Digital Mammography (FFDM)

Hong Zhang, S.L. Lou, David Hoogstrate,  
Edward A. Sickles\*, H.K. Huang, Albert Wong

*Lab for Radiological Informatics,  
University of California, San Francisco*

*\*Breast Imaging Section, Mt. Zion Hospital,  
University of California, San Francisco*

## ABSTRACT

The purpose of this project is to investigate the feasibility to remotely manage mammography examinations in real time, which is defined as mammography telemanagement. In such a scenario, the remotely located expert mammographer needs to view newly generated images and communicate with on-site technologist before a patient leaves the exam room. Therefore, almost real-time transmission of large volume digital mammograms between these two parties must be available. A digital telemammography test-bed has been setup between two clinical facilities in University of California, San Francisco. Both the hardware and software components of the system are discussed. Digital mammogram transmission between two campuses, however, is not yet optimal. Several methods are presented to improve the image availability. By implementing these schemes, the total time for transferring one digital mammogram from the FFDM to the remote expert workstation is reduced from 42 sec to 6 sec. It is concluded that, with improved system design and extended software capabilities, it is feasible to explore real-time telemanagement protocol in telemammography.

**Keywords:** Telemedicine, mammography, telemanagement, telemammography, DICOM

## 1. INTRODUCTION

The early detection of breast cancer increases the survival rate in women [1]. Today, film-screen mammography is the most common and effective technique for the detection of breast cancer [2-4]. However, the film-screen image recording system of current mammography has several technical limitations that can reduce the breast cancer diagnostic accuracy. A state-of-the-art technology, Full-Field Digital Mammography (FFDM), has the potential to increase the sensitivity of clinical and screening examinations and emerge as a film screen mammography replacement [5]. It is believed that efficiently delivering the superior image quality of FFDM to expert mammographer will significantly increase the breast cancer diagnostic accuracy. This concept motivates the studies of full-field digital telemammography.

In our previous work, we reported on three protocols, teleradiology, teleconsultation, and telemanagement, to evaluate the FFDM telemammography concept [6,7]. The definitions of each of the protocols are listed in Table 1. The telemammography scenario is illustrated in Figure 1. We have since then implemented the FFDM telemammography system between two UC San Francisco campuses: the Medical Center (the main campus) and the Mount Zion Hospital (MZH), where our mammography expert center is [8]. These two campuses are two miles apart.

Telediagnosis	Remote diagnosis of digital mammograms by mammography specialists at the expert center.
Teleconsultation	General radiologist interpreting mammograms at the satellite site requests second opinion from mammographer at the expert center.
Telemanagement	Real-time remote interpretation and management of mammography exams performed at the satellite site by mammographer at the expert center.

Table 1. Three Telemammography Protocols

In this paper, we first present the configuration of our asynchronous transfer mode (ATM) network-based telemammography system. Then, we discussed the elapsed time required for users to view the FFDM images either at MZH or at the UCSF main campus. Our recent approaches to optimize the image delivery performance are discussed in Section 3, followed by the digital mammogram transmission speed test results.

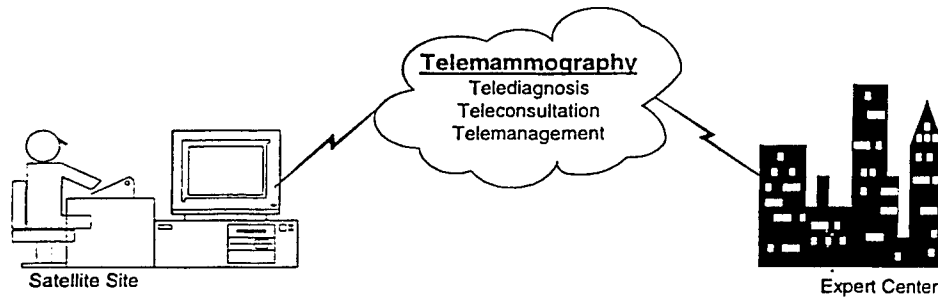


Figure 1. Telemammography Scenario

## 2. TELEMAMMOGRAPHY SYSTEM

The telemammography test-bed at the University of California, San Francisco consists of two parts: hardware components and software packages. In the hardware aspect, the major computer and network systems and their associated functions are described below, as well as the in-house developed software packages.

### 2.1 Hardware Components

Currently, the major components in our tele-mammography system include one FFDM system, one data archiving system, two high resolution (2K x 2.5K) digital mammogram display workstations, and one Laser film imager. Figure 2 illustrates the configuration of this telemammography system.

Serving as the image acquisition component in the telemammography system, the FFDM system has an imaging unit. The digital mammogram generated has a matrix size 4,096 x 5,625 (4K x 5.5K) pixels, with 12 bits/pixel. Each image is as large as 46 Mbytes. In addition, an image acquisition workstation (Sun Ultra-I workstation) is attached to the FFDM system to temporarily stores the digital mammogram before it routes images out.

The data archiving system functions as the database server for image archival and retrieval. The system is composed of:

- One Sun Enterprise 3000 Server,
- Five Fast/Wide SCSI disks,
- One Sun StorEdge Disk Array (45GBytes), and
- Oracle Relational Database

In the archiving system, we store the digital mammogram data either in the Disk Array or in the SCSI disks, while patient demographic information is managed by an Oracle database server.

The two display workstations provide soft copy display for this telemammography system. Each of the display workstations consist of the following components:

- One Sun Ultra2 Workstation (200MHz CPU, 512MB memory, and a 4.2GB disk)
- Two DOME Md5-SBX display boards
- Two Data-Ray monitors (2k x 2.5k pixel/monitor)

All the components stated above are linked through ATM networks. The uplink to the UCSF SONET ring (OC-3, 155 Mbps) has one ATM switch at the main campus and the Mt. Zion Hospital respectively.

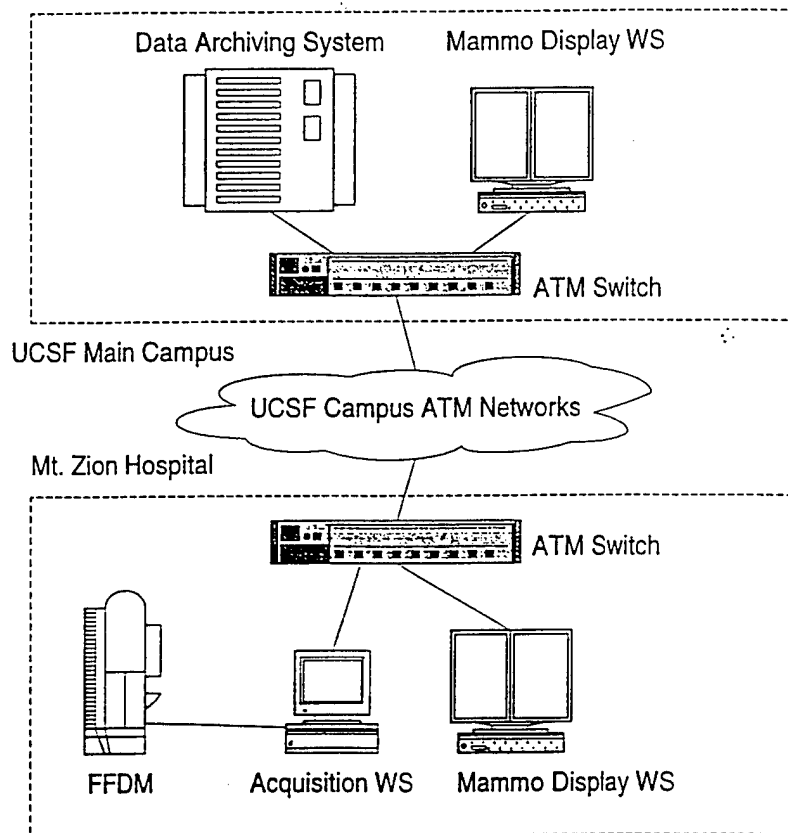


Figure 2. Telemammography Test-bed at UC San Francisco

## 2.2 Software Packages

The software packages implemented include DICOM communication programs and display workstation program.

(1) DICOM communication facilities. We use the DICOM communication protocols to carry out storage, query and retrieval service classes. The images generated by the FFDM system contains the information and format complied to the DICOM information object definitions. Digital mammograms transferred between computer systems are based on the DICOM storage service class. The data archiving system and the two display workstations can provide roles of service class provider (SCP) and service class user (SCU). The FFDM acquisition computer only acts as an image client. The DICOM Query/Retrieve service classes are established between the data management system and the two display workstations for historical patient data retrieval.

(2) Display workstation software packages. Before a digital mammogram is ready for users to display in the image display workstation, it is processed by workstation database utilities. X-Window based image display and manipulation software is developed, providing users with a GUI environment for accessing patient information including text and images. A patient list allows users to browse through patients and their associated examinations and images. Images may be displayed in 1:1 (one image per monitor), 2:1, or 4:1 format using the two 2K display monitors. To insure the relevant image information is displayed, the breast laterality is used to set the output rectangle of the image. The images in any of the display modes can be instantly expanded to full resolution (4K x 5.6K) in 1:1 format, and vice versa. With these two image display features, unnecessary operations of the display workstation are minimized. In addition, image manipulation functions such as pan-and-scroll, window-and-level, scalable magnifying glass, rotation, and on-screen image exchange are provided to facilitate users' viewing practice.

### 3. SYSTEM IMPROVEMENT

In the current test-bed, it takes about 120 seconds to transmit one mammogram (46MB) from the FFDM acquisition workstation to the remote expert workstation including the time for image transmission, job queues, information extraction, database transactions, and image archival [9]. Image transmission delay of over 2 minutes is not appropriate in such a telemanagement scenario, where almost real-time feedback from remote expert is desired. The reasons of the problem can be clarified as: (1) disk I/O and local queue within each host add up to the total elapsed time, and (2) the mammogram is being routed between several hosts before it finally reaches the expert workstation for review.

By investigating the current test-bed setup and implementation, two approaches are developed to improve image availability: First, existing DICOM storage service class software is enhanced so that images can be kept and sent out while they are still in memory. Second, data flow within the system is redesigned and optimized.

#### 3.1 Direct Memory Access (DMA)

The DICOM communication software being used in the current telemammography system is developed over the Mallinckrodt CTN 93 DICOM implementation. Complied with DICOM standard, image transfer between two hosts is carried out by a C-Store Service Class Provider (SCP) and a Service Class User (SCU). The current implementation of the C-Store SCP saves incoming images to hard disk, blocking other routines' access to the image while it is in memory. The implementation of the SCU has to read DICOM objects from hard disk.

As a result, in the current system, all incoming images have to be saved to disk first, then read from disk again, instead of from high-speed memory, before it can be further processed. This mechanism works fine for most image communication applications, but is not perfect for telemanagement protocol because image needs to be routed immediately to another host. Figure 3 (Left) illustrates the data flow within a host.

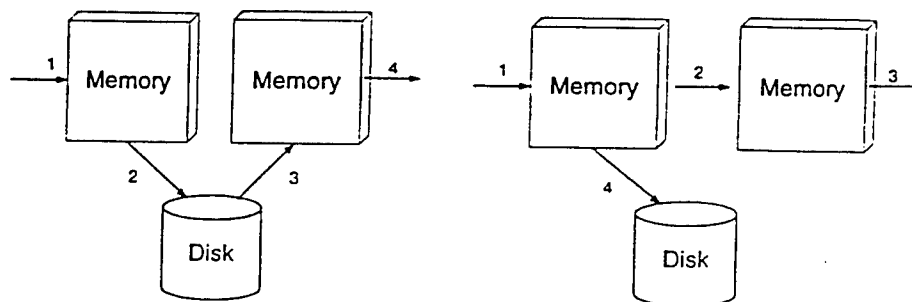


Figure 3. Data Flow within a Host (Left: traditional approach; Right: new approach with DMA)

To take full advantage of the fast speed memory, the existing functionality is enhanced by adding Direct Memory Access feature, while maintaining the compliance to DICOM standards. In the Direct Memory Access (DMA) mode, an incoming image is received at the memory, and is routed to another host before being saved to the hard disk. The new mechanism is also exhibited in Figure 3 (Right).

With the availability of the DMA technique, the image can be shared and accessed by multiple threads and/or processes for various image processing purposes, as shown in Figure 4.

#### 3.2 Image Flow Optimization

In the current system, when a digital mammogram is generated, it is automatically transmitted to the MZH display workstation through ATM network using DICOM storage class service. Once the image is received at the MZH display workstation, it is queued and then routed to the data archiving system. The data archiving system forwards the image to the second expert workstation at UCSF and stores the image in the central storage for long-term archival purpose. Figure 5 is the diagram illustrating the image flow in our current test-bed.

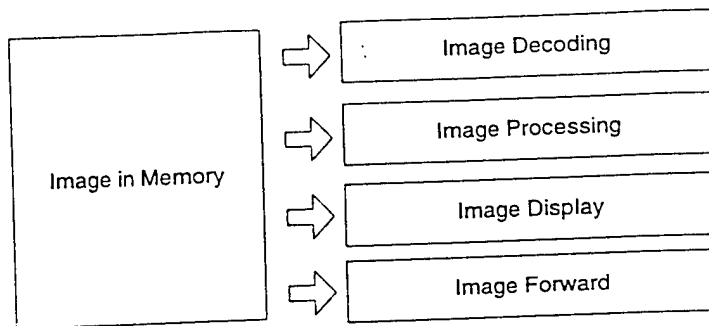


Figure 4. Online Image Sharing

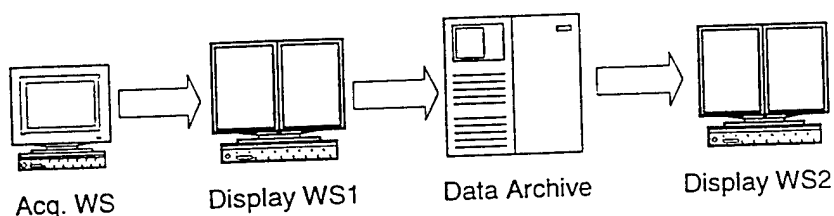


Figure 5. Data Flow within Existing System

The total elapsed time from the moment when a digital mammogram is generated in the FFDM system to the time when the image arrives on the MZH display workstation includes: (1) the transmission time from the FFDM acquisition computer to the workstation; (2) the queue time at the MZH workstation.

For telemanagement protocol, the image also needs to be sent to the UCSF campus workstation. Then, The elapsed time also includes: (1) the transmission time from the MZH workstation to the data management system, (2) the queue time and transmission time from the data management system to the UCSF campus workstation, (3) the queue time at the UCSF campus workstation.

The queue time for each of the processes is set to 10 seconds. The existing of queue delay ascribes mainly to the lack of direct memory access capability. With the above-mentioned DMA technique, it is possible to handle DICOM image object while it is received in memory and reduces the queue time.

The optimal image flow, as illustrated in Figure 6, will expedite mammogram availability by establishing another channel between the FFDM acquisition computer and the second expert display workstation. When a new digital mammogram is transmitted to the MZH display workstation, the same copy is simultaneously transferred to the UCSF display workstation, both via OC-3 ATM networks and DICOM storage service class.

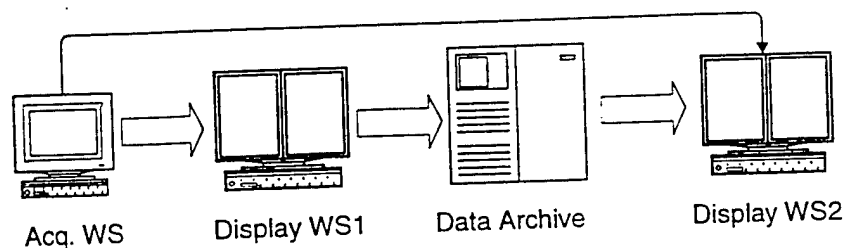


Figure 6. Improved Data Flow

#### 4. RESULT AND DISCUSSION

For the time being, we are in the testing stage of the new telemammography test-bed configuration. We use our existing hardware, to simulate and measure the elapsed time from the moment when the FFDM acquisition computer is ready to transmit a 46 Mbytes digital mammogram to the moment when the image is received at the UCSF campus workstation. Except for the image transmission, all the intermediate tasks, such as job queues, information extraction, database transactions, and image archival, are excluded. The average time is 42 and 6 seconds for the existing and the improved system, respectively.

Telemangement of digital mammography expects real-time feedback from remote expert. Fast transmission of large volume digital mammogram thus becomes a challenging task. A telemammography test-bed has been setup between two UC San Francisco clinical facilities. In the current system configuration, the overhead of network and disk I/O delays the image availability at the remote expert workstation. By implementing the Direct Memory Access technique for DICOM storage service class and optimizing the mammogram data flow within the system, it is feasible to explore fast telemangement protocol in digital mammography environments.

#### 5. ACKNOWLEDGEMENT

This work is support in part by from California Breast Cancer Research Program (IRB-0148), the US Army Medical Research Material Command (USAMRMC DAMD17-94-J-4196, DAMD-96-C6111), and the NLM (N01-LM-4-3508).

#### References

- [1] O. Noriaki, Y. Koichi, "Improved Detection Rate of Early Breast Cancer in mass screening combined with mammography," *Hap. J. Cancer Res.* Vol. 84, no. 7, pp. 807-812, 1993.
- [2] S. Feig, "Decreased breast cancer mortality through mammographic screening: Results of clinical trials," *Radiology*, Vol. 167, pp. 659-665, 1988.
- [3] S. Shaprio, W. Venet, P. Strax, et. al., "Selection, follow-up, and analysis of the health insurance plan study: a randomized trial with breast cancer screening," *J. Natl. Cancer Inst. Monogr.*, Vol. 67, pp. 65-74, 1985.
- [4] L. Tabar, G. Faberberg G, W. Duffy, N. Day, A. Gad, and O. Grontoft. "Update of the Swedish two-county program of mammographic screening for breast cancer," *Radiol. Clin. North Am.*, Vol. 30, pp. 187-210, 1992.
- [5] National Cancer Institute (NCI) / National Aeronautics and Space Administration. (NASA) Workshop "Digital Mammography", May 19-20, Washington, D.C.
- [6] S.L. Lou, E.A. Sickles, H.K. Huang, et. al. "Full-Field Direct Digital Telemammography - Preliminary," *SPIE Proceedings, Medical Imaging, PACS Design and Evaluation*, Vol. 3035, pp. 369-379, 1997.
- [7] H.K. Huang, "Teleradiology Technologies and Some Service Models," *Comp. Med. Imaging & Graphics*. Vol. 20, pp. 59-68, 1996.
- [8] S.L. Lou, E.A. Sickles, H.K. Huang, David Hoogstrate, Fei Cao, J. Wang and Mohammad Jahangiri, "Full-Field Direct Digital Telemammography - Technical Components, Study Protocols, and Preliminary Results," *IEEE Trans. on Information Technology in Biomed.*, Vol. 1, No. 4, pp. 270-278, 1997.
- [9] S.L. Lou, H.K. Huang, E.A. Sickles, D. Hoogstrate, F. Cao, and J. Wang, "Full-field direct digital telemammography: system implementation," *SPIE Proceedings, Medical Imaging 1998: PACS Design and Evaluation*, Vol. 3039, pp.156-164, 1998.