

AD _____

Award Number: DAMD17-98-1-8631

TITLE: Neuroprotective Treatment of Laser-Induced Retinal Injuries

PRINCIPAL INVESTIGATOR: Mordechai Rosner, M.D., M.Med.Sc.
Yoram Solberg, M.D., Ph.D.
Michael Belkin, M.D., M.A.

CONTRACTING ORGANIZATION: Tel-Aviv University
Tel-Hashomer 52621 Israel

REPORT DATE: October 2000

TYPE OF REPORT: Annual

PREPARED FOR: U.S. Army Medical Research and Materiel Command
Fort Detrick, Maryland 21702-5012

DISTRIBUTION STATEMENT: Approved for public release;
Distribution Unlimited

The views, opinions and/or findings contained in this report are those of the author(s) and should not be construed as an official Department of the Army position, policy or decision unless so designated by other documentation.

DIC QUALITY INSPECTED 4

20001130 016

REPORT DOCUMENTATION PAGE

Form Approved
OMB No. 074-0188

Public reporting burden for this collection of information is estimated to average four per response, including the time for reviewing instructions, searching existing data sources, gathering and maintaining the data needed, and completing and reviewing this collection of information. Send comments regarding this burden estimate or any other aspect of this collection of information, including suggestions for reducing this burden to Washington Headquarters Services, Directorate for Information Operations and Reports, 1215 Jefferson Davis Highway, Suite 1204, Arlington, VA 22202-4302, and to the Office of Management and Budget, Paperwork Reduction Project (0704-0188) Washington, DC 20503

| | | | | |
|--|--|---|--|--|
| 1. AGENCY USE ONLY (Leave blank) | | 2. REPORT DATE October 2000 | 3. REPORT TYPE AND DATES COVERED Annual (1 Sep 99 - 1 Sep 00) | |
| 4. TITLE AND SUBTITLE Neuroprotective Treatment of Laser-Induced Retinal Injuries | | | 5. FUNDING NUMBERS DAMD17-98-1-8631 | |
| 6. AUTHOR(S) Mordechai Rosner, M.D., M.Med.Sc. Yoram Solberg M.D., Ph.D. Michael Belkin M.D., M.A. | | | | |
| 7. PERFORMING ORGANIZATION NAME(S) AND ADDRESS(ES) Tel-Aviv University Tel-Hashomer 52621 Israel E-MAIL: mrosner@post.tau.ac.il belkin@mail.netvision.net.il | | | 8. PERFORMING ORGANIZATION REPORT NUMBER | |
| 9. SPONSORING / MONITORING AGENCY NAME(S) AND ADDRESS(ES) U.S. Army Medical Research and Materiel Command Fort Detrick, Maryland 21702-5012 | | | 10. SPONSORING / MONITORING AGENCY REPORT NUMBER | |
| 11. SUPPLEMENTARY NOTES Report contains color graphics. | | | | |
| 12a. DISTRIBUTION / AVAILABILITY STATEMENT Approved for public release; distribution unlimited | | | 12b. DISTRIBUTION CODE | |
| 13. ABSTRACT (Maximum 200 Words) Purpose: Laser induced retinal injuries are operational and medical problem in the battlefield as a result of lasers used in military equipment and the introduction of visually incapacitating laser weapons. It is not possible to prevent all these injuries and there is no treatment. This study was designed to evaluate the neuroprotective effect of memantine in our rat model of laser-induced retinal-lesions. Methods: Argon laser retinal lesions were inflicted in the eyes of 36 pigmented rats. The treated group received memantine 10 mg/kg dissolved in saline, immediately after exposure to laser and then every 8 hours for 3 days. The control group received the solvent at the same volume and schedule. The rats were sacrificed 3, 20 or 60 days later and the retinal lesions were evaluated by light microscopy and morphometric measurements. Results: No difference was demonstrated between the treated and the control groups, in the histopathologic appearance of the lesions, their size and the magnitude of photoreceptor nuclei loss within the lesions. Conclusions: Memantine treatment, when given systemically at the dose and schedule evaluated, is not effective in ameliorating the retinal injury induced by argon laser in rats. | | | | |
| 14. SUBJECT TERMS Neuroprotection, laser, retina, memantine, rat | | | 15. NUMBER OF PAGES: 15 | |
| | | | 16. PRICE CODE | |
| 17. SECURITY CLASSIFICATION OF REPORT Unclassified | 18. SECURITY CLASSIFICATION OF THIS PAGE Unclassified | 19. SECURITY CLASSIFICATION OF ABSTRACT Unclassified | 20. LIMITATION OF ABSTRACT Unlimited | |

FOREWORD

Opinions, interpretations, conclusions and recommendations are those of the author and are not necessarily endorsed by the U.S. Army.

___ Where copyrighted material is quoted, permission has been obtained to use such material.

___ Where material from documents designated for limited distribution is quoted, permission has been obtained to use the material.

___ Citations of commercial organizations and trade names in this report do not constitute an official Department of Army endorsement or approval of the products or services of these organizations.

X In conducting research using animals, the investigator(s) adhered to the "Guide for the Care and Use of Laboratory Animals," prepared by the Committee on Care and use of Laboratory Animals of the Institute of Laboratory Resources, national Research Council (NIH Publication No. 86-23, Revised 1985).

N/A For the protection of human subjects, the investigator(s) adhered to policies of applicable Federal Law 45 CFR 46.

N/A In conducting research utilizing recombinant DNA technology, the investigator(s) adhered to current guidelines promulgated by the National Institutes of Health.

N/A In the conduct of research utilizing recombinant DNA, the investigator(s) adhered to the NIH Guidelines for Research Involving Recombinant DNA Molecules.

N/A In the conduct of research involving hazardous organisms, the investigator(s) adhered to the CDC-NIH Guide for Biosafety in Microbiological and Biomedical Laboratories.

M. Roxy 15.9.2000
PI - Signature Date

TABLE OF CONTENTS:

| | <u>PAGE</u> |
|------------------------------|--------------------|
| FRONT COVER | 1 |
| SF 298 | 2 |
| FOREWORD | 3 |
| TABLE OF CONTENTS | 4 |
| INTRODUCTION | 5 |
| BODY | 6 |
| KEY RESEARCH ACCOMPLISHMENTS | 9 |
| REPORTABLE OUTCOMES | 9 |
| CONCLUSIONS | 9 |
| REFERENCES | 10 |
| APPENDICES (FIGURES) | 12 |

INTRODUCTION:

Extensive research has focused on protective devices and safety measures to prevent laser-induced retinal injuries, as well as on their treatment. Unfortunately, there is yet no accepted therapy for reducing retinal neuronal death and the associated scarring and disruption of the retinal architecture resulting from exposure to laser radiation. Neuronal lesions tend to spread after an injurious event such as trauma or ischemia, and neuroprotective compounds can minimize this spread and thus limit further damage^{1,2}. We have shown that this is the case in laser-induced retinal lesions as well. Consistent experimental evidence points to the efficacy of non-competitive N-methyl-D-aspartate (NMDA) antagonists in animal models of CNS global or focal ischemia⁴⁻⁷. Many of these pharmacological compounds are currently undergoing clinical trials for treatment of stroke and traumatic brain injury. One of the promising is memantine (1-amino 3,5-dimethyl-adamantane hydrochloride). Memantine is a moderate-affinity, voltage-dependent, uncompetitive antagonist of NMDA receptors. In contrast to competitive NMDA antagonists, memantine is well tolerated in humans and was shown to improve parkinsonian symptoms independently of dopaminergic drugs and for the treatment of dementia. It was found to lead to functional improvement and reduces care dependence in severely demented patients⁸⁻¹⁰. It has been shown also to be effective in preventing neuronal damage after permanent focal cerebral ischemia¹¹. It was also proved effective in phase III clinical trials for Alzheimer disease and phase II clinical trials for diabetic retinopathy, showing its effectiveness as a neuroprotective drug (data not yet published).

In the current research we evaluated the neuroprotective effectiveness of memantine, that has been proved to be safe for usage in human, in our well-established rat model for retinal lesion following argon laser lesions^{3,13-16}. Retinal lesions were induced by argon laser irradiation in retinas of pigmented rats. Thirty-six rats were used for the evaluation of the drug. Eighteen were treated by memantine and eighteen (the control group) receives the vehicle-saline. The rats were sacrificed at 3, 20 and 60 days after exposure to laser. The efficacy of memantine treatment in limiting the extent of the injury was evaluated histologically at the acute, intermediate and late phases after injury. The evaluation included light microscopic examination of serial sections, morphometric measurements of the lesion diameter and assessment of the extent of photoreceptor cell loss in the retinal outer nuclear layer.

BODY:

Methods

Animals

Pigmented DA rats (Strain DA/OLa/Hsd, Harlan OLAC Ltd., Blackthorn Bicester Oxon., England; raised in Tel-Aviv University animal house), 90 days old, were used for the experiments. The posterior segment of the eye of this strain has a uniform pigmentation, making it particularly useful for retinal laser injury production. The animals were fed ad libitum with a normal diet and maintained on a 12-h light/dark cycle. They were anesthetized by intraperitoneal injections of ketamine (40 mg/kg) and xylazine (8 mg/kg). Laser retinal lesions were produced in each eye, and the rats were sacrificed after 3, 20 or 60 days by lethal doses of pentobarbital sodium injected intraperitoneally. The eyes were enucleated for histopathologic and morphometric evaluations.

All procedures involving animals were performed according to the guidelines of the Association for Research in Vision and Ophthalmology Resolution on the Use of Animals in Research.

Laser injury

Following dilatation of the pupil with topical topicamide 0.5% sterile drops (Mydramid, Fischer), a contact lens, specially constructed in our laboratory to fit a rat eye, were coupled to the cornea with 2.5% hydroxypropyl methylcellulose. Six argon laser (Novus 2000, Coherent, Palo Alto Ca) lesions (514 nm, 200 μ m, 0.1 W, 0.05 sec) were produced in each eye, one to three disc diameters from the optic disc. These laser settings were found in our previous studies to result in lesions of uniform size and configuration, involving mainly the outer retinal layers.

Administration of drugs

The treated group received memantine hydrochloride 10 mg/kg dissolved in saline, immediately after exposure to laser and then every 8 hours for 3 days. The control group received the solvent at the same volume and schedule.

Experimental design

A total of 36 rats were used in this study. Six laser lesions were produced in each eye of each animal. Half of them (18 rats) served as the test (treated) group, which received intraperitoneal injections of memantine dissolved in saline and the other half served as the control group and received intraperitoneal injections of the vehicle-saline at the same regimen. The effect of the treatment was evaluated at three time points: 3, 20 and 60 days after the injury was inflicted. The retinal lesions were evaluated for histopathologic and morphometric differences in a masked fashion.

Histopathologic and morphometric studies

The rats were sacrificed 3, 20 or 60 days after irradiation. The eyes were enucleated and fixed in 2% glutaraldehyde. Using a surgical microscope, the posterior segment of the fixed eyes was dissected into tissue samples, each incorporating one retinal laser lesion.

A total of 48 laser lesions from the treated group and 48 laser lesions from the control group (4 laser lesions from each animal) were subjected to both histological and morphometric examination. The tissue samples were embedded in plastic (epon) blocks, sectioned serially (2 μ m) with an ultramicrotome and stained with toluidine-blue.

Stained sections from the central part of the lesion, exhibiting the greatest amount of laser-induced retinal destruction, were examined by light microscopy for histopathological changes of the retinal lesions.

To further evaluate the neuroprotective effects of memantine, a quantitative morphometric assessment of the retinal lesions were carried out using a computer-assisted image analysis system (Scan Array 2, Galai, Migdal Haemek). Two morphometric measurements were performed on each lesion in order to evaluate the severity of the argon laser injury.

The first measured the largest diameter of the lesion. This was done by determining the edges of the lesion area, according to the changes in the retinal pigmented epithelium and in the cytoarchitecture of the outer retinal layers (Figure 1). These changes included loss of pigment granules in the retinal pigment epithelium, loss of its monolayer structure and loss of retinal pigment epithelial cells, disruption of the outer and inner segments, changes in the outer nuclear layer, and thickness and infolding of the inner retinal layers (the inner nuclear layer, inner plexiform layer, ganglion cell layer and nerve fiber layer). The transition from normal retina to the lesion area is well defined, making the criteria for morphometric measurements clear and reproducible.

The second evaluated the extent (percentage) of photoreceptor cell loss. This was done by calculating the differences between the numbers of ONL nuclei in the outer nuclear layer at the area of the lesion, with that of the normal outer nuclear layer along 100 μm of the retina on both sides of the lesion.

All histopathologic and morphometric evaluations were performed in a masked fashion.

Statistical analysis

A sample size of twelve animals enables to detect any differences between the treated test groups and the vehicle-injected control groups, that is twice the standard deviation within the groups.

All morphometric measurements were performed in two sections at the center of each retinal lesion and averaged. A two-way analysis of variance was used to calculate the significance of the treatment and time effects.

Results

In both treated and control eyes, histopathological examination of the retinal lesions 3 days after laser irradiation revealed damage to the retinal pigment epithelium, the inner and outer segments of the photoreceptors, the outer nuclear layer, the outer plexiform layer and the inner nuclear layer (Figure 1, upper photographs). The retinal pigment epithelium showed local proliferation with formation of a multilayered membrane containing phagocytic cells. The outer and inner segments of the photoreceptors were disrupted and deformed. The outer nuclear layer showed loss of nuclei, as well as the presence of pyknotic nuclei at the periphery, tapering off towards the center of the lesion, where they were completely absent. The center of the lesion was filled with cellular debris, dispersed pigment granules and pigment-laden macrophages. The outer plexiform layer was disrupted and the inner nuclear layer was mildly edematous. The inner plexiform layer, the ganglion cell layer and the nerve fiber layer were folded internally, creating internal bulging at the inner retinal surface over the area of the lesion.

At 20 and 60 days after laser irradiation (Figure 1, middle and lower photographs), the multilayered proliferative membranes in the lesion became more thinned. The retinal pigment epithelium layer had reformed. The outer and inner segments of the photoreceptors had reformed at the periphery of the lesion, showing disruption only in the central area. The outer nuclear layer showed fewer pyknotic nuclei, and the central area, in which there was total loss of the outer nuclear layer, had decreased in size. The inner plexiform layer was less edematous. The rest of the histopathological findings did not differ significantly from the findings at 3 days. Bulging of the inner retinal surface was still evident. This bulging was assumed to be a result of the edema of the inner retinal layers at the earlier period, with subsequent traction of the normal retinal layers at the edge of the lesion towards its center once the edema had resolved.

The histological findings of the laser-induced retinal lesions were similar to those described in the literature¹⁷. The histopathological findings in the lesions of the treated group did not differ from those of the control group (Figure 1). Furthermore, there were no significant morphometric differences between the two groups with respect to the diameter of the lesions (Fig. 2) or the loss of photoreceptor nuclei at the injury site (Fig. 3) when examined at 3 days, 20 days or 60 days after laser irradiation.

Discussion

Lasers assume increasing use in communication, industry and the military fields, accounting for increasing numbers of accidental eye injuries¹⁸⁻²⁵. Concern has been growing that lasers might be used as a weapon in the future battlefield, making the eyes a major target²⁶⁻²⁷. Injury to retinal neurons, whether by traumatic, ischemic or other mechanisms, has generally been considered an irreversible phenomenon that cannot be halted or slowed down. There is no accepted therapy available for these devastating injuries. The retina is part of the central nervous system (CNS), and when injured might exhibit similar pathogenic mechanism to those involved in neuronal death following CNS injury²⁸⁻³¹. New insights into these mechanisms have provided a theoretical basis for evaluating various pharmacological strategies to induce neuroprotection. Most of the available information on neuroprotection comes from studies of the CNS following traumatic or ischemic injury. It is now well documented that much of the post-injury tissue damage results from delayed inflammation and an autodestructive cascade of events³¹⁻³². Glutamate receptor antagonists are among the most intensively studied pharmacological agents for reducing neurotoxicity arising out of CNS damage³³⁻³⁶. Glutamate plays a dominant role in CNS¹ as well as retinal neurotransmission^{37,38}. However, exposure of neurons to high concentrations of extracellular glutamate can lead to their death^{1,30}. It is now well established that after CNS injury the damaged neurons release massive amounts of glutamate, which interacts with adjacent cells and eventually destroys them. Thus a biochemical cascade develops, in which injured neurons amplify the initial traumatic effect and cause the damage to spread to neighboring tissue, causing exacerbation of the original insult^{1,30}. The neurocytotoxic action of glutamate appears to be modulated mostly by its NMDA receptor³¹⁻³⁹. Similar neurocytotoxic effects of glutamate, mediated through the activation of NMDA receptors, have been demonstrated in retinal neurons both *in vitro* and *in vivo*⁴⁰⁻⁴², and administration of NMDA-receptor blocker to retinal neurons in culture improved their survival following their exposure to glutamate^{41,43}. Glutamate-receptor blockers also protect retinal neurons from hypoxic damage⁴⁴⁻⁴⁶. It therefore seems likely that the retina might respond to agents shown to have neuroprotective properties in the CNS.

We demonstrated⁶⁷ the neuroprotective effect of MK-801, the "gold-standard" and the most potent known NMDA-receptor antagonist, in argon laser-induced retinal injury. The lesions, which are located in the external retinal layers and the choroid, are reproducible and can be accurately quantified, making it possible to evaluate the potential damage-spread limiting effects of neuroprotective drugs. We followed the histopathological changes in the argon laser-induced retinal lesions for 60 days in MK-801 treated animals (3mg/kg, intraperitoneally) and compared them to those observed in laser lesions inflicted in retinas of control rats injected with saline. We also evaluated the severity of the argon laser injuries in treated and control lesions by morphometric measurement of the diameters of the lesions and the extent of photoreceptor cell losses in the retinal outer nuclear layer. At 20 days and at 60 days, the MK-801-treated lesions were found to be significantly smaller than their control counterparts. Differences in ONL thickness loss between MK-801-treated and control lesions were also highly significant and indicated that significant numbers of ONL neurons were rescued by MK-801 from the spread of the damage. On the basis of these results, we suggest that glutamate plays a key role in the spread of laser-induced retinal injury, by mediating the continuous destruction of the photoreceptors. Antagonism by MK-801 of these glutamate-induced effects significantly improves the outcome. However, the known toxicity of MK-801 precludes its further experimental use in human laser injuries involving the neural retinal elements.

In this study, we examined the effect of memantine on retinal injury induced by argon laser irradiation in pigmented rats. Memantine - a moderate-affinity, voltage-dependent, uncompetitive antagonist of NMDA receptors, is well tolerated in humans and was shown to be an effective drug to treat Parkinson disease and dementia⁸⁻¹⁰. It was also effective in preventing neuronal damage after permanent focal cerebral ischemia¹¹. It was also proved effective in phase III clinical trials for Alzheimer disease and phase II clinical trials for diabetic retinopathy, showing its effectiveness as a neuroprotective drug (data not yet published).

The regime used for rats was intraperitoneal injections of memantine hydrochloride 10 mg/kg dissolved in saline, immediately after exposure to laser and then every 8 hours for 3 days. However, the results of the current study show that memantine treatment, given systemically, at this dose and regimen, was not effective in ameliorating the retinal injury induced by argon laser in rats.

We recommend to continue with the original plan.

KEY RESEARCH ACCOMPLISHMENTS:

- Memantine treatment, given systemically, at this dose and regimen, was not effective in ameliorating the retinal injury induced by argon laser in rats.

REPORTABLE OUTCOMES:

- | | |
|--|---|
| - manuscripts, abstracts, presentations; | none |
| - patents and licenses applied for and/or issued; | none |
| - degrees obtained that are supported by this award; | Basic research by ophthalmologic resident |
| - development of cell lines, tissue or serum repositories; | none |
| - informatics such as databases and animal models, etc; | none |
| - funding applied for based on work supported by this award; | none |
| - employment or research opportunities applied for and/or received on experiences/training supported by this award. | none |

CONCLUSIONS:

Memantine treatment is not effective in ameliorating the retinal injury induced by argon laser in rats, when given systemically at the dose and schedule evaluated.

We recommend continuing with the original plan to evaluate the effect of the approved drug brimonidine.

REFERENCES:

1. Choi DA: The role of glutamate neurotoxicity in hypoxic-ischemic neuronal death. *Annu Rev Neurosci.* 1990;13:171-182.
2. Choi DA: Glutamate neurotoxicity and diseases of the nervous system. *Neuron.* 1988;1:623-634.
3. Y. Solberg, M. Rosner, J. Tureyz, M. Belkin MK-801 has neuroprotective and anti-inflammatory effects on retinal laser injury. *Investigative Ophthalmology & Visual Science* Vol. 38, pp. 1380-1389, 1997.
4. Prince DA, Feeser HR: Dextromethorphan protects against cerebral infarction in a rat model of hypoxia-ischemia. *Neurosci. Lett.* 1988;85:291-296.
5. Park CK, Nehls DG, Graham DI, Teasdale GM, McCulloch J: The glutamate antagonist MK-801 reduces focal ischemic brain damage in the rat. *Ann Neurol.* 1988;24:543-551.
6. Minematsu K, Fisher M, Li L, Davis MA, Knapp AG, Cotter RE, McBurney RM, Sotak CH: Effects of a novel NMDA antagonist on experimental stroke rapidly and quantitatively assessed by diffusion-weighted MRI. *Neurology.* 1993;43:397-403.
7. Steinberg GK, Kunis D, DeLaPaz R, Poljak A: Neuroprotection following focal cerebral ischemia with the NMDA antagonist dextromethorphan, has a favorable dose response profile. *Neurol. Res.* 1993;15:174-180.
8. Nouzeilles MI, Cammarota A, Leiguarda R: Effect of memantine (NMDA antagonist) on Parkinson's disease: a double-blind crossover randomized study. *Merello M, Clin Neuropharmacol,* 1999; 22:273-6.
9. Winblad B, Poritis N: Memantine in severe dementia: results of the 9M-Best Study (Benefit and efficacy in severely demented patients during treatment with memantine). *Int. J. Geriatr. Psychiatry* 1999; 14:135-46.
10. Ruther E, Glaser A, Bleich S, Degner D, Wiltfang J: A prospective PMS study to validate the sensitivity for change of the D-scale in advanced stages of dementia using the NMDA-antagonist memantine. *Pharmacopsychiatry* 2000; 33:103-8.
11. Dogan A, Eras MA, Rao VL, Dempsey RJ: Protective effects of memantine against ischemia-reperfusion injury in spontaneously hypertensive rats. *Acta Neurochir (Wien),* 1999;141:1107-13.
12. Rosner M, Tchirkov M, Dubinski G: Animal model of military relevant laser induced eye injuries. The 1994 U.S.A.-Israel Bilateral Medical Research and Development Symposium Abstracts. 1994;16.
13. Rosner M, Tchirkov M, Dubinsky G, et al: Methylprednisolone ameliorates laser induced retinal injury in rats. ARVO annual meeting, Fort Lauderdale, 1996, p. 694.
14. Solberg Y, Rosner M, Belkin M: Pharmacological treatments of laser eye injuries by neuroprotection. SPIE, San Jose, 1996, p. 47.
15. M. Rosner, Y. Solberg, J. Tureyz, E. Karin, M. Tchirkov, G. Dubinsky, M. Belkin Neuroprotective therapy for argon-laser induced retinal injury. *Experimental Eye Research,* Vol. 65, pp. 485-495, 1997.
16. Powell JO, Bresnick GH, Yanoff M et al. Ocular effects of argon laser radiation. II. Histopathology of chorioretinal lesions. *Am J Ophthalmol* 1971; 71:1267-1276.
17. Gabel VP, Birngruber R, Lorenz B et al: Clinical observations of six cases of laser injury to the eye. *Health Physics.* 1989;56:705-710.
18. Haifeng L, Guanghuang G, Dechang W, et al: Ocular injuries from accidental laser exposure. *Health Physics.* 1989;56:711-716.
19. Liu H, Gao G, Wu D, et al: Injuries from accidental laser exposure. *Health Physics.* 1989;56:716-718.
20. Kearney JJ, Cohen HB, Stuck B, et al: Laser injury to multiple retinal foci. *Lasers Surg Med.* 1987;7:499-502.
21. Jiemin X, Guiado X, Zhongli C, et al: Experimental studies of the injurious effects of Q-switched Nd:YAG lasers and their outdoor applications. *Health Physics.* 1989;56:647-652.
22. Boldrey EE, Little HL, Flocks M, et al: Retinal injury due to industrial laser burns. *Ophthalmology* 1981;88:101-107.

23. Friedmann AI: A natural clinical history of a severe accidental retinal laser burn at the posterior pole of the eye. *Doc Ophthalmol.* 1988;68:395-400.
24. Wolfe JA: Laser retinal injury. *Military Medicine.* 1985;150:177-185.
25. Mellerio J, Marshall J, Tengroth B, et al: Battlefield laser weapons: an assessment of systems, hazards, injuries and ophthalmic resources required for treatment. *Laser Light Ophthalmol.* 1991;4:41-67.
26. Tengroth B, Anderberg B: Blinding laser weapons. *Laser Light Ophthalmol.* 1991;4:35-39.
27. Faden AI: Pharmacotherapy in spinal cord injury: A critical review of recent development. *Clin Neuropharmacol.* 1987;10:193-204.
28. Siesjo BK: Mechanisms of ischemic brain damage. *Crit Care Med.* 1988;16:954-963.
29. Choi DW: The role of glutamate neurotoxicity in hypoxic-ischemic neuronal death. *Annu Rev Neurosci.* 1990;13:171-182.
30. Faden AI, Salzman S: Pharmacological strategies in CNS trauma. *Trends in Pharmacol Sci.* 1992;13:29-35.
31. Lipton SA: Molecular mechanisms of trauma-induced neuronal degeneration. *Curr. Opin. Neurol. Neurosurg.* 1993;6:588-596.
32. Peruche B, Kriegelstein J: Mechanisms of drug actions against neuronal damage caused by ischemia: An overview. *Prog. Neuropsychopharmacol. Biol. Psych.* 1993;17:21-70.
33. Scatton B: Excitatory amino acid receptor antagonists: a novel treatment for ischemic cerebrovascular diseases. *Life Sci.* 1994;55:2115-2124.
34. Cottrell JE: Possible mechanisms of pharmacological neuronal protection. *J. Neurosurg. Anaesthesiol.* 1995;7:31-37.
35. Danysz W, Parsons CG, Bresink I, Quack G: Glutamate in CNS disorders. *Drug News and Perspectives.* 1995;8:261-277.
36. Brandon C, Man-Kit Lam D: L-Glutamic acid: A neurotransmitter candidate for cone photoreceptors in human and rat retinas. *Proc Natl Acad Sci USA.* 1983;80:5117-5121.
37. Barstable CJ: Glutamate and GABA in retinal circuitry. *Curr Opin Neurobiol.* 1993;3:520-525.
38. Muir KW, Lees, KR: Clinical experience with excitatory amino acid antagonist drugs. *Stroke.* 1995;26:503-513.
39. Hahn JS, Aizenman E, Lipton SA: Central mammalian neurons normally resistant to glutamate toxicity are made sensitive by elevated extracellular Ca²⁺: Toxicity is blocked by the N-methyl-D-Aspartate antagonist MK-801. *Proc Natl Acad Sci USA.* 1988;85:6556-6560.
40. el-Asrar AM, Morse PH, Maimone D, Torczynski E, Reder AT: MK-801 protects retinal neurons from hypoxia and the toxicity of glutamate and aspartate. *Invest Ophthalmol Vis Sci.* 1992;33:3463-3468.
41. Siliprandi R, Canella R, Carmignoto G, Schiavo N, Zanellato A, Zanoni R, Vantini G: N-methyl-D-Aspartate-induced neurotoxicity in the adult rat retina. *Vis. Neurosci.* 1992;8:567-573.
42. Levy DI, Lipton SA: Comparison of delayed administration of competitive and uncompetitive antagonists in preventing NMDA receptor-mediated neuronal death. *Neurology.* 1990;40:852-855.
43. Sugawara T, Mori T, Kamei S, Tazawa Y: Protective effect of dextromethorphan on the ischemic retinal damage in rabbit. *Nippon Ganka Gakkai Zasshi.* 1992;96:90-95.
44. Gupta LY, Marmor MF: Mannitol, dextromethorphan and catalase minimize ischemic damage to retinal pigment epithelium and retina. *Arch. Ophthalmol.* 1993;111:384-388.
45. Cao W, Zaharia M, Drumheller A, Casanova C, Lafond G, Brunette JR, Jolicoeur FB: Effects of dextromethorphan on ischemia induced electroretinogram changes in rabbit. *Curr. Eye Res.* 1994;13:97-102.
46. Lombardi G, Moroni F, Moroni F: Glutamate receptor antagonists protects against ischemia-induced retinal damage. *Eur. J. Pharmacol.* 1994;271:489-495.

FIGURES

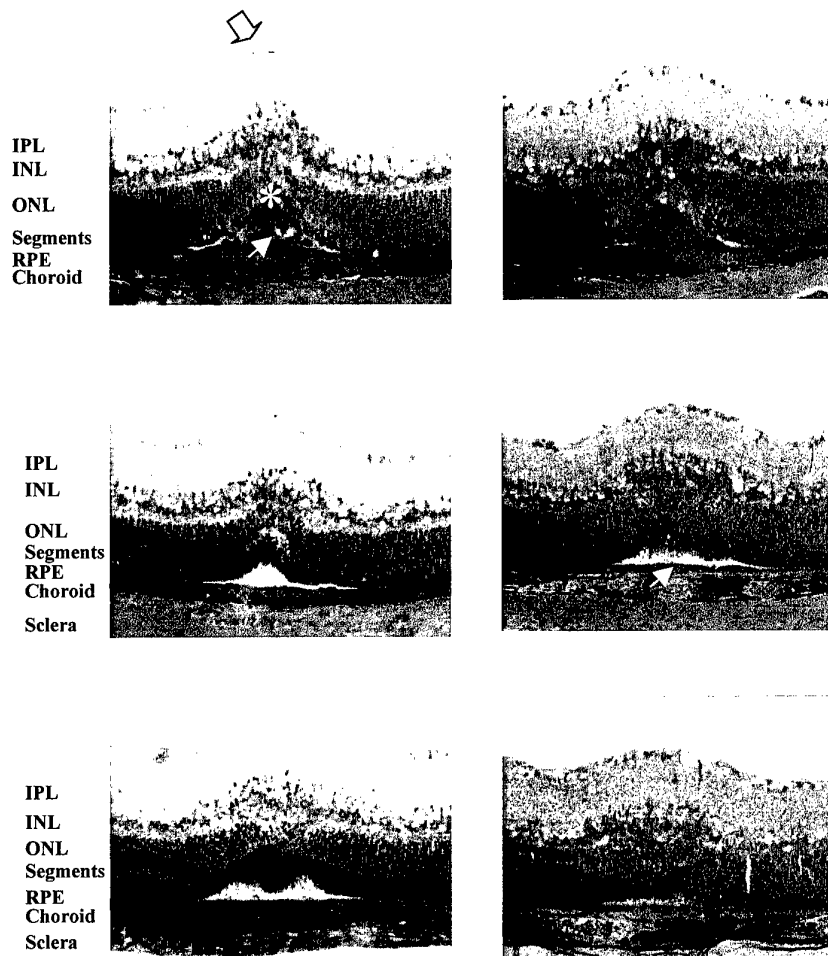


Fig. 1. Retinal lesions of control (left) and memantine treated (right) at 3 days (upper), 20 days (middle) and 60 days (lower) after laser exposure. (Toluidine blue, Original magnification $\times 100$, IPL-inner plexiform layer; INL-inner nuclear layer; ONL-outer nuclear layer; RPE-retinal pigment epithelium)

Three days after exposure, the control lesion (upper left) showed disruption of the outer nuclear layer with extensive loss of nuclei at the central area of the lesion (asterisk). There was loss of inner and outer segments and development of fusiform proliferative plaque at the level of the retinal pigment epithelium (thin arrowhead). An internal retinal bulging was formed at the area of the lesion (thick arrow). In the memantine treated rats, 3 days after exposure (upper right) similar findings are seen. Twenty and 60 days after exposure (middle and lower), thinner plaques (thin arrowhead) were seen. The inner and outer segments were reformed. The findings were similar in the memantine treated and the saline treated control rats.

Fig. 2. Effect of memantine on the mean retinal lesion diameter.

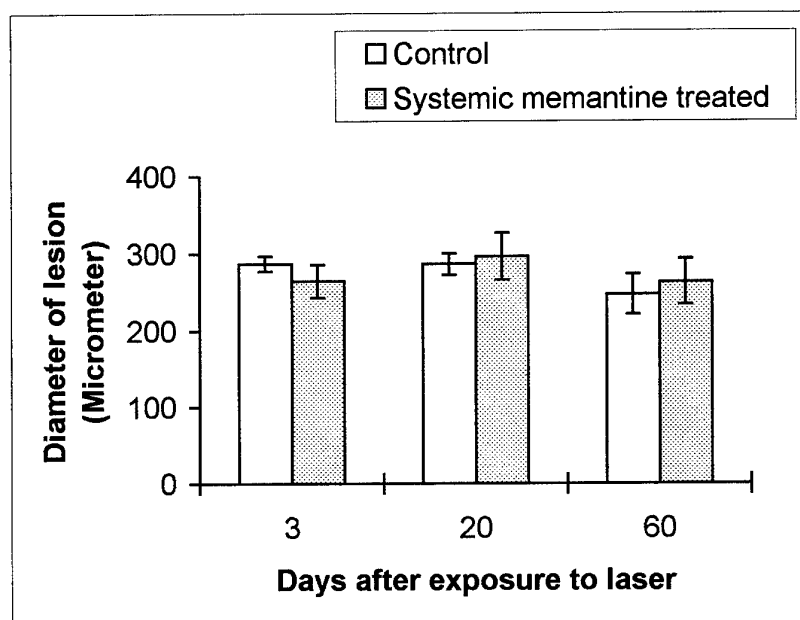


Table 1. Effect of systemic Memantine treatment on diameter of lesion

| | <u>Control</u> | <u>Test</u> | <u>t-test</u> |
|----|----------------|-------------|---------------|
| 3 | 286.7± 9.8 | 264.3±21.3 | 0.06 |
| 20 | 286.4±13.6 | 296.1±30.3 | 0.53 |
| 60 | 247.5±26.0 | 263.1±29.5 | 0.35 |

Fig. 3. Effect of memantine on the mean percentage of photoreceptor cell nuclei loss.

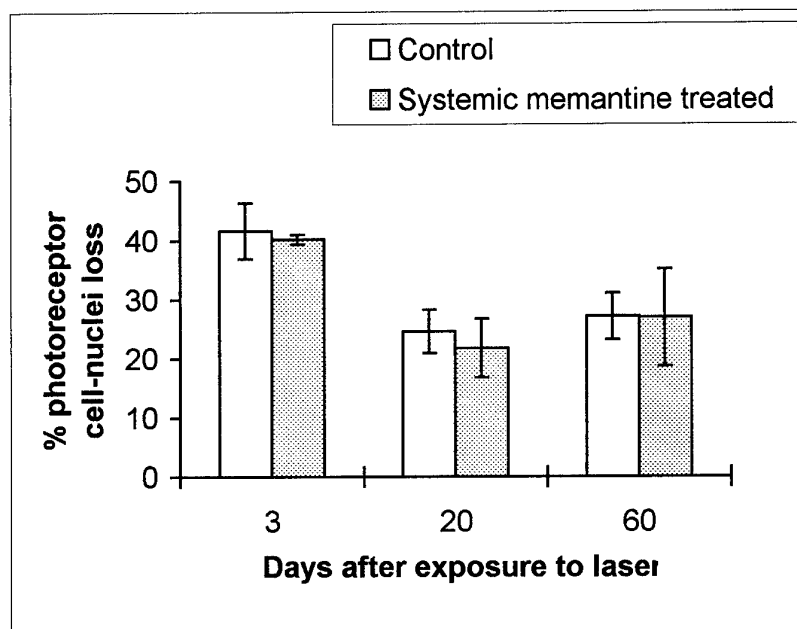


Table 2. Effect of systemic Memantine treatment on % photoreceptor cell loss

| | <u>Control</u> | <u>Test</u> | <u>t-test</u> |
|----|----------------|-------------|---------------|
| 3 | 41.6±4.7 | 40.2±0.8 | 0.53 |
| 20 | 24.6±3.7 | 21.7±5.0 | 0.36 |
| 60 | 27.1±3.9 | 26.9±8.2 | 0.95 |