

AD \_\_\_\_\_

Award Number: DAMD17-96-C-6079

TITLE: Stereoscopic Digital Mammography: Improving Cancer  
Diagnosis

PRINCIPAL INVESTIGATOR: David Getty, Ph.D.

CONTRACTING ORGANIZATION: BNN Systems and Technologies  
Cambridge, Massachusetts 02138

REPORT DATE: July 2000

TYPE OF REPORT: Final

PREPARED FOR: U.S. Army Medical Research and Materiel Command  
Fort Detrick, Maryland 21702-5012

DISTRIBUTION STATEMENT: Approved for Public Release;  
Distribution Unlimited

The views, opinions and/or findings contained in this report are those of the author(s) and should not be construed as an official Department of the Army position, policy or decision unless so designated by other documentation.

20010122 110

**REPORT DOCUMENTATION PAGE**Form Approved  
OMB No. 074-0188

Public reporting burden for this collection of information is estimated to average 1 hour per response, including the time for reviewing instructions, searching existing data sources, gathering and maintaining the data needed, and completing and reviewing this collection of information. Send comments regarding this burden estimate or any other aspect of this collection of information, including suggestions for reducing this burden to Washington Headquarters Services, Directorate for Information Operations and Reports, 1215 Jefferson Davis Highway, Suite 1204, Arlington, VA 22202-4302, and to the Office of Management and Budget, Paperwork Reduction Project (0704-0188), Washington, DC 20503

<b>1. AGENCY USE ONLY (Leave blank)</b>		<b>2. REPORT DATE</b> July 2000	<b>3. REPORT TYPE AND DATES COVERED</b> Final (17 Jun 96 - 16 Jun 00)	
<b>4. TITLE AND SUBTITLE</b> Stereoscopic Digital Mammography: Improving Cancer Diagnosis			<b>5. FUNDING NUMBERS</b> DAMD17-96-C-6079	
<b>6. AUTHOR(S)</b> David Getty, Ph.D.				
<b>7. PERFORMING ORGANIZATION NAME(S) AND ADDRESS(ES)</b> BNN Systems and Technologies Cambridge, Massachusetts 02138 E-MAIL: getty@bbn.com			<b>8. PERFORMING ORGANIZATION REPORT NUMBER</b>	
<b>9. SPONSORING / MONITORING AGENCY NAME(S) AND ADDRESS(ES)</b> U.S. Army Medical Research and Materiel Command Fort Detrick, Maryland 21702-5012			<b>10. SPONSORING / MONITORING AGENCY REPORT NUMBER</b>	
<b>11. SUPPLEMENTARY NOTES</b>				
<b>12a. DISTRIBUTION / AVAILABILITY STATEMENT</b> Approved for public release; distribution unlimited				<b>12b. DISTRIBUTION CODE</b>
<b>13. ABSTRACT (Maximum 200 Words)</b>  The subject of study in this project was the potential benefit of using stereoscopic digital mammography as an adjunct to standard film mammography to improve the detection and diagnosis of breast cancer. We sought to determine whether stereo mammography might bring significant gains – either in earlier detection of worrisome lesions, or in more accurate discrimination of lesions as benign or malignant. Several main activities were required to accomplish this evaluation. We further developed and refined a system for capturing and viewing stereo mammograms, using state-of-the-art digital methods. Over the duration of the project, stereo mammograms and film studies were acquired on a large number of path-proven cases. Three experienced mammographers served as consultants, and an extensive effort was devoted to developing with them a comprehensive list of visual features to consider in reading the stereo mammograms. In a final reading study with 137 cases, we measured diagnostic accuracy obtained with standard film mammograms alone compared to that obtained with film combined with the stereo mammogram. We found that the stereo mammogram significantly improved diagnostic accuracy. A second, exciting finding was that new, additional lesions, mostly masses, were detected in the stereo mammogram but were not visible in the film study, in 30% of the cases.				
<b>14. SUBJECT TERMS</b> Mammography, stereoscopic, digital, detection, diagnosis				<b>15. NUMBER OF PAGES</b> 62
				<b>16. PRICE CODE</b>
<b>17. SECURITY CLASSIFICATION OF REPORT</b> Unclassified	<b>18. SECURITY CLASSIFICATION OF THIS PAGE</b> Unclassified	<b>19. SECURITY CLASSIFICATION OF ABSTRACT</b> Unclassified	<b>20. LIMITATION OF ABSTRACT</b> Unlimited	

NSN 7540-01-280-5500

Standard Form 298 (Rev. 2-89)  
Prescribed by ANSI Std. Z39-18  
298-102

FOREWORD

Opinions, interpretations, conclusions and recommendations are those of the author and are not necessarily endorsed by the U.S. Army.

\_\_\_ Where copyrighted material is quoted, permission has been obtained to use such material.

\_\_\_ Where material from documents designated for limited distribution is quoted, permission has been obtained to use the material.

0/ Citations of commercial organizations and trade names in this report do not constitute an official Department of Army endorsement or approval of the products or services of these organizations.

N/A In conducting research using animals, the investigator(s) adhered to the "Guide for the Care and Use of Laboratory Animals," prepared by the Committee on Care and use of Laboratory Animals of the Institute of Laboratory Resources, national Research Council (NIH Publication No. 86-23, Revised 1985).

0/ X For the protection of human subjects, the investigator(s) adhered to policies of applicable Federal Law 45 CFR 46.

N/A In conducting research utilizing recombinant DNA technology, the investigator(s) adhered to current guidelines promulgated by the National Institutes of Health.

N/A In the conduct of research utilizing recombinant DNA, the investigator(s) adhered to the NIH Guidelines for Research Involving Recombinant DNA Molecules.

N/A In the conduct of research involving hazardous organisms, the investigator(s) adhered to the CDC-NIH Guide for Biosafety in Microbiological and Biomedical Laboratories.

  
PI - Signature

7/11/2000  
Date

## Table of Contents

Cover.....	1
SF 298 .....	2
Foreword.....	3
Table of Contents.....	4
Introduction .....	5
Body.....	6
Key Research Accomplishments.....	33
Reportable Outcomes.....	34
Conclusions .....	35
References.....	37
Appendices.....	39
Appendix A: Full Checklist/Questionnaire.....	39
Appendix B: Reduced Checklist/Questionnaire .....	50
Appendix C: Reader Debriefing Form .....	54
Presentations, Abstracts, and Personnel.....	56


## INTRODUCTION

The subject of study in this project was the potential benefit of using stereoscopic digital mammography as an adjunct to standard film mammography in the detection and diagnosis of breast cancer. We sought to determine whether stereo mammography might bring significant gains – either in earlier detection of worrisome lesions, or in more accurate discrimination of lesions as benign or malignant. Several main activities were required to accomplish this evaluation. We needed first to refine a system previously developed for capturing and viewing stereo mammograms, using state-of-the-art digital methods. Over the duration of the project, stereo mammograms were acquired on a large number of path-proven cases. Three experienced mammographers served as consultants, and an extensive effort was devoted to developing with them a comprehensive list of visual features to consider in reading the stereo mammograms. Finally, we conducted two reading studies to measure diagnostic accuracy obtained with standard film mammograms alone compared to that obtained with film combined with the stereo mammogram. The second, final reading study also explored the possibility that the stereo mammogram may significantly increase detection sensitivity for very subtle lesions not visible in the film mammogram.

## BODY OF REPORT

### 1. Stereoscopic Display Workstation (Tasks 1, 2, 3, 8)

During the project, we completed a substantial amount of development work on the stereo display workstation, shown in Figure 1 below. This work has included: (1) reorganization of the system's graphical user interface, (2) addition of functionality to give the user control over many aspects of the displayed stereo image, (3) development of a database structure for storing the stereo images and parametric display information, (4) testing of alternative methods of controlling aspects of the display, and (5) development and incorporation of a new high-resolution, monochrome monitor. We discuss each of these efforts below.



**Figure 1. Stereoscopic display workstation.**

#### 1.1 Design of a graphical user interface for the mammographer

Early in the project, we moved from a graphical interface designed with the needs of the developer as a primary concern to one in which the convenience and needs of the mammographer as user took center stage. In particular, we moved the essential controls required by the mammographer to the primary window for immediate accessibility, and moved secondary controls, needed infrequently, to hidden windows accessed from items on the menu bar. While the graphical interface remains as a convenient and logical means for the mammographer to access a full range of controls, we found that much of the commonly-used functionality is better implemented using control provided by a three-button mouse, thereby avoiding the need for the mammographer to look over at the system control monitor. This issue is discussed at greater length in Section 1.4 below.

## 1.2 Addition of control functionality to the stereo display

During the project, we added zoom, pan, and scroll capabilities to the stereo display. When looking at tissue containing very fine detail, such as a dense cluster of very small microcalcifications, we found that it is very helpful to be able to zoom in on the finding at either 2X or 4X magnification. Although, there is no gain in absolute information in a zoomed image, since pixels are merely replicated, visual perception is often significantly improved. Also, when a stereo image is magnified by zooming, perceived depth is magnified by the same scale factor. Since only a portion of the original image is visible when the mammogram is zoomed (1/2 of each dimension at 2X and 1/4 at 4X), the ability to pan and scroll within the larger available image becomes important. We implemented routines that allow the user to carry out continuous panning and scrolling of the visible display window within the larger stored image.

## 1.3 Development of a database structure for storing stereo images and parameters

As we began to acquire a large set of stereo mammograms, it became important for us to develop a database and software to manage this database. We developed capabilities of storing stereo images as linked pairs that define a case. In addition, the database stores particular information about each case that allows the stereo image to be displayed initially with optimized grayscale windowing, optimal image registration, and, optionally, with a description of the case.

## 1.4 Implementation and comparative testing of several alternative means for control of the stereo display

### 1.4.1 Speech-enabled control of the stereo display system

During the first two years of the project, we investigated the use of speech recognition technology for controlling aspects of the stereo display system. A possible advantage of using speech to control the display is that the user is not distracted from his/her viewing of the mammographic images. Without speech control, the user must look over at the control monitor screen and use a mouse or the keyboard to manipulate controls displayed on the monitor. With speech control, the user can simply speak commands to cause changes to the stereo display and immediately see the resulting effects on the stereo mammogram.

The speech subsystem included a hardware card and driver software developed by Speech Systems Inc. We wrote software routines and speech syntaxes that implement a range of control functions by speech. The user wears a lightweight headset that includes a boom microphone, and holds a small control incorporating a push-to-talk button. Although the system can be run with voice-activated input, we have found that use of the push-to-talk device is preferable since it allows the user to carry on other conversations intermixed with control commands.

The implemented speech commands fell into four categories: (1) case selection, (2) windowing of the display grayscale, (3) inversions of depth and grayscale, and (4) 3-D cursor control. Case selection commands allow the user to choose a particular case to be displayed.

Windowing commands permit the user to slowly (or rapidly) increase or decrease image brightness or contrast and to halt the change when an appropriate setting is reached. The system also allows the user to specify particular brightness or contrast settings, and to save current settings as defaults for the case. Inversion commands allow the user to invert depth in the displayed mammogram and to invert grayscale.

Our experience with speech control of the display system during the second year led to several conclusions. A primary drawback to the use of speech to control the display is the need to tether the mammographer to the workstation with a headset or dictation-style microphone. And a push-to-talk button is needed to exclude incidental conversation from being presented to the recognition system. A primary conclusion we reached is that speech control is appropriate and convenient only for categorical commands (for example, "invert brightness", "invert depth", "zoom in", "zoom out", "cursor on", "cursor off"). Speech control is not optimal for controlling continuous parameters such as adjusting brightness and contrast in the displayed image. A command to "increase brightness" can be used to initiate an increase in brightness at a particular rate that can then be halted with a "stop" command. But, in order to give the user fine enough control, the rate of change of brightness has to be made quite slow, which can be irritating if the desired change is large—and overshooting occurs frequently because of time lag in the speech recognition process. Continuous process adjustments are much better made with a continuous controller such as a mouse or joystick.

#### 1.4.2 Comparison of mouse and joystick control of the stereo display

Our explorations indicate that control over continuous adjustments of the stereo display is far better implemented by giving the user fine motor control using a physical device such as a mouse or trackball, although not a joystick. We have conducted experiments using both a mouse and a joystick. The mouse was implemented as a direct controller of brightness (movements along the X-axis) and contrast (movements along the Y-axis). By direct control, we mean that position of the mouse maps directly to values of brightness and contrast. In contrast, the joystick was necessarily implemented as a rate controller of brightness (X-axis) and contrast (Y-axis), where movement of the joystick away from its spring-loaded neutral central position determines rate and direction of change of brightness and/or contrast. The results of our study indicate that the mouse, using direct control, is a much more intuitive control of brightness and contrast. The user quickly develops the appropriate cognitive model of a square in which low brightness is at the left edge, high brightness at the right edge, low contrast at the bottom edge and high contrast at the top edge. It is easy for the user to make large rapid changes in brightness or contrast by making rapid movements of the mouse towards the appropriate region of the square, and then to make small, fine movements for precise adjustment. By contrast, the control of rate of change of brightness and/or contrast provided by the joystick is much less intuitive to the user. It takes longer, and is more difficult, to achieve a desired brightness and contrast level.

#### 1.4.3 Exploration of control of stereo display modes

In reading sessions with the expert mammographers, we tried out several different methods for assigning control of display attributes to a three-button mouse. We determined from their feedback that one configuration seemed to be very intuitive and easy to use. In this

configuration, the left mouse button toggles grayscale reversal, from black on white to white on black. The middle mouse button toggles between two states: one in which movement of the mouse moves a cursor around on the display surface, and one in which movement of the mouse controls brightness (X-axis movement, with brightness increasing to the right) and contrast (Y-axis movement, with contrast increasing with upward movement). The right mouse button toggles inversion of displayed depth, in which foreground becomes background and background becomes foreground.

Working with the experts, we also determined that users found it very helpful to get visual feedback about current brightness and contrast settings. This feedback was implemented in graphical form by providing a two-dimensional plot of brightness and contrast on the system monitor, with brightness plotted along the X-axis, and contrast along the Y-axis. The current settings are indicated by placement of a cursor at an appropriate position in the space. Furthermore, "optimal" default settings are shown on the plot by the position of a small square. If the user loses his/her bearings, these default settings can be regained by using the mouse to move the cursor towards the square.

### 1.5 Development and incorporation of a high-resolution, monochrome monitor

A limitation of the original stereo display workstation was its utilization of a color monitor for the stereo display. This is non-optimal in that each displayed pixel is represented on the screen by a triad of red, green, and blue dots. However, the color capability is unnecessary in that the mammographic image is purely grayscale. Consequently, some spatial resolution is lost relative to that achievable with a purely monochrome monitor. Originally, the choice of the color monitor was dictated by the requirement that the monitor be capable of syncing to a vertical refresh rate of 120 Hz; only a few color monitors had that capability.


Following the completion of our pilot reading study, we explored with the MegaScan Corporation the possibility of adapting one of their high-resolution, monochrome monitors for use with our stereo display system. MegaScan was extremely helpful in custom building a monochrome monitor with a fast-decay phosphor (needed to prevent ghosting in the stereo image), matched to the vertical and horizontal frequencies of the Matrox display controller card in the system. Vertical image size was adjusted to achieve pixels with a 1:1 aspect ratio in stereo display mode. This much-improved monitor was used in the final reading study; the mammographers commented that the displayed images were much improved on the new monitor.

## 2. Case Set Acquisition (Task 4)

### 2.1 Installation and testing of a prototype GE digital mammography unit

The mammographic detector for stereoscopic imaging that was originally intended for use in this project was a small-field-of-view CCD-based digital imager covering an area of approximately 6 x 6 cm, developed at the University of Massachusetts Medical Center (UMMC). This sensor would provide relatively high contrast and spatial resolution in a confined area that would have been adequate for the proposed stereoscopic studies of already detected lesions.

However, during the first year of the project, General Electric installed at UMMC a prototype clinical full-field-of-view digital mammography detector that is integrated with a GE DMR x-ray machine. It became clear to us that there would be significant advantages to this project in using this device to capture our stereoscopic mammograms. A most important advantage was the much larger field of view, enabling stereo imaging of the entire breast.



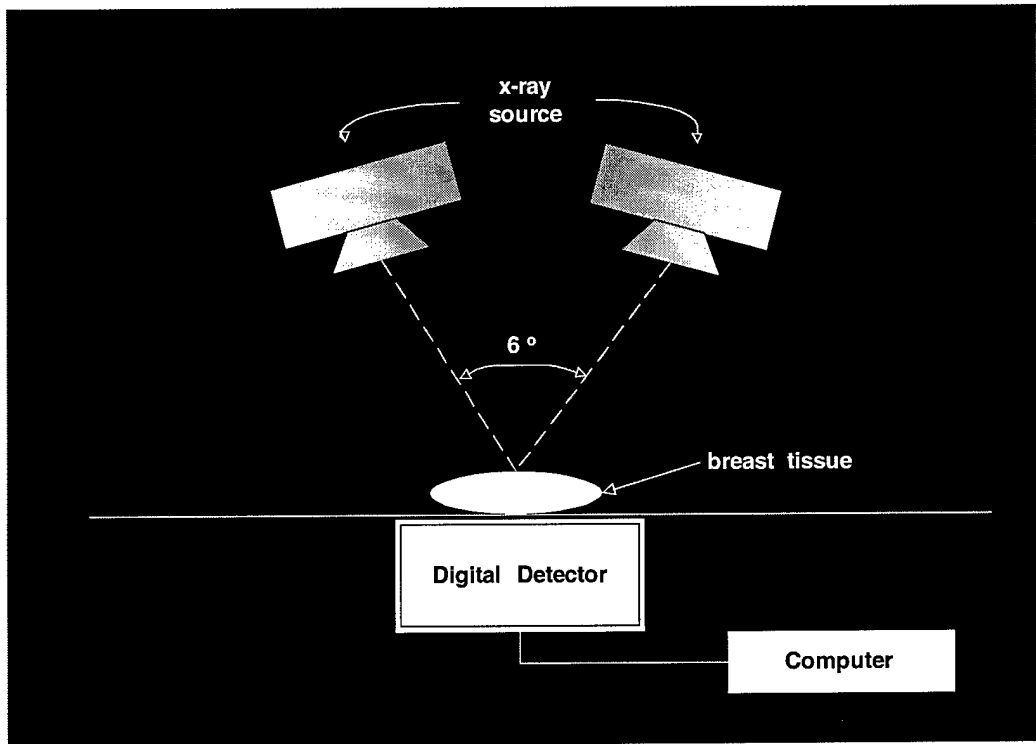
**Figure 2. GE digital mammography unit.**

Secondly, initial testing of the physical characteristics of the new full-field imager revealed that the radiation dose with this device was even lower than with typical small-field CCDs, with outstanding contrast resolution. This is due to the direct contact of the scintillator with the photosensitive material without any intermediate fiberoptic plate or taper. Measurements of the modulation transfer function with this imager have revealed a significantly higher modulation at low to mid frequencies which is exactly what radiologists need to enhance the contrast resolution. This objective evaluation was followed by imaging of the standard ACR phantom. It appears that the overall detectability of the phantom features appears to be significantly better than that obtained with film screen systems. Thus, we turned to this device for capturing the stereo mammograms for this project. In order to precisely control the movement of the x-ray tube by 6 degrees between a stereo pair of image acquisitions, GE provided a high precision electronic goniometer, which provides a digital readout of the tube angle in better than 0.5 degree increments.

## 2.2 Capture and processing of stereo digital mammograms

The acquisition of a stereo mammogram requires the capture of two x-ray mammograms, with the x-ray tube being shifted by 6 degrees between the two image captures, as illustrated in Figure 3 below. The breast to be imaged is compressed on the mammography unit's table in a

cranio-caudal position. The x-ray tube is first set at  $-3$  degrees relative to straight down and the first digital x-ray is acquired. The tube is then shifted by 6 degrees to  $+3$  degrees without any movement of the breast, and the second x-ray exposure is made. The digital images are stored on a hard disk in the imaging system.



**Figure 3. Acquisition of a stereo mammogram.**

During Years 2 and 3 of the project, we developed and refined a software application to semi-automate the processing of the raw digital stereo images into viewable stereo pairs. Each digital mammographic image captured on the GE unit at UMMC is 2304 pixels wide by 1800 pixels high, with a grayscale resolution of 16 bits stored in a 16-bit word. Captured digital images are stored as 16-bit TIFF-format files and burned onto a CD-ROM which is then sent to BBN. Because of limitations of the stereo display card in our workstation, we need to process the raw digital images to reduce the size of each image to 1024 by 1024 pixels and to reduce the grayscale from 16 bits to 8 bits.

A number of steps are involved in this processing. First, the left-eye image of a pair is opened and visually examined to judge the adequacy of the image. Then, an image-processing algorithm is applied to the image to segment the breast tissue from the surround. The user can iteratively modify the threshold used in this process until a satisfactory segmentation is achieved. The program then calculates a cumulative histogram of grayscale values for the pixels representing breast tissue and determines the minimum, median, and maximum grayscale values. This process is then repeated for the right-eye image. The program then determines the offset between the median grayscale value of breast tissue in the two images and applies it as an additive correction to all of the pixels in the appropriate one of the two images, in order to equalize their median values. Without this correction, the grayscale appearance of the two

images may be sufficiently different that it is difficult to visually fuse the two images into a stereo view. We believe that the difference in grayscale between the two images is due to software within the GE mammographic unit that apparently attempts to optimize mapping of x-ray density to grayscale usage independently for each newly acquired mammogram. Consequently, we frequently find differences in the grayscale histograms between the two images of a stereo pair, even though the two images are of the same breast, with no breast re-compression between images. The only difference in the two images is the small 6-degree movement of the x-ray source between images. We have also encountered systematic changes in the use of the 16-bit grayscale range over the past months of image acquisition. We believe that these changes are due to updates of the image-capture software in the prototype GE mammographic unit that have been made by the GE engineers as they have learned more about the performance of the unit.

In the next step, our program reduces the grayscale of both images from 16 bits to 8 bits. A linear re-mapping of the grayscale is used, extending from the minimum 16-bit grayscale value to the maximum 16-bit value. The transformed versions of both images are saved as 8-bit TIFF files. The program next saves a stereo-viewable 1024 x 900 pixel overview of each of the two images by sampling every other pixel and every other line. This pair of images is useful to the mammographer to obtain a stereo view of the entire breast, albeit at reduced spatial resolution.

The program then places a 1024 by 1024 region-of-interest outline into the full left-eye image and permits the user to move this outline around within the larger image until the user is satisfied that the verified lesion and surrounding tissue are appropriately enclosed within the window. The coordinates of the user-selected location of the outline are recorded, and the region-of-interest is then extracted and saved as a 1024 x 1024 8-bit TIFF file. This process is repeated for the right-eye image, except that the coordinates used for positioning the 1024 x 1024 window in the image are the same ones determined from the left-eye image. This pair of images is of primary importance to the mammographer since it permits a stereo view of the lesion at full spatial resolution.

### 2.3 Patients enrolled in the project

Over the course of the project, 188 patients were enrolled. The period of enrollment began later than we wished, at the start of Year 2, because of delays in the installation and acceptance testing of the new GE digital mammography unit in the mammography clinic at UMMC. And the period of enrollment was forced to end sooner than we wished, midway through Year 4. At that time the FDA ordered that the GE digital mammography unit not be used with any angular offset of the x-ray tube until additional shielding was designed by GE and added to the edges of the compression table. The purpose of the shielding would be to prevent any portion of the x-ray beam from escaping the confines of the table when the tube was angled away from straight on. The necessary modifications to the equipment did not happen within the remaining 6 months of the project, so no further patients could be enrolled.

Of the 188 patients who consented to participate, one, or in a few cases two, stereo mammograms were obtained on 183 of them. Of the 183 stereo-imaged patients, 177 received a

stereo mammogram of a single breast, namely, the one containing the lesion that was to be biopsied. The other 6 patients had lesions in both breasts, both of which were biopsied. For these patients, we obtained a stereo mammogram of each breast. Finally, 8 patients who received a stereo mammogram had two lesions in the same breast, both of which were biopsied. As a result, we ended up with stereo mammograms for a total of 197 biopsy-proven lesions.

### **3. Perceptual Feature and Checklist Development (Tasks 5, 6, 7)**

The feature-based approach to visual image analysis followed in these studies has been shown in several other image-based medical diagnostic contexts to be very helpful in determining a new modality's merits and potential. The basic requirement is to conduct an extensive effort to identify, refine and objectify the image features that will go into the analysis. Three activities must be undertaken. An initial extensive exploration of the domain of potentially relevant features must be undertaken and then repeatedly revisited as the readers become more familiar with the new modality (Task 5). Our experience has shown that these explorations are best accomplished by independent interviews of at least several readers expert in the current modalities that the new modality would presumably supplement or replace. When the information from each of the individual readers has been independently collected and then pooled, the next main activity is to give each reader an opportunity to consider what the other readers have suggested. They should then interact to reach consensus on the final set of features and on the exact wording of each to be utilized in describing the features (Task 6). The third activity is for the researchers to turn that consensus list into the checklist/questionnaire that the readers will follow and fill out on each case in the reading studies (Task 7).

#### **3.1 Explorations of new stereo-based visual features (Task 5)**

In the first year, while awaiting accumulation of stereo images of the intact breasts, we carefully examined each of our existing set of stereo images of biopsy specimens. Working with the checklist/questionnaire that we had developed in several prior studies of conventional 2-D mammography as a starting point, we sought first to consider how each of the 2-D features might be better or differently visible in the stereo display. We then carefully explored conceptually and visually for features that would be uniquely accessible in stereo. We did this with just one of our expert readers as a way to get started and to develop a comprehensive framework for the ultimate explorations with all three of our experts on the intact breast images when a sufficiently large set of them was eventually accrued. That framework provided for a systematic consideration of the potential impact on diagnosis of the information provided by the images at all conceivable levels of visual analysis of a lesion. At the lowest level are characteristics of the elements of the lesion. At the next level are characteristics of the lesion's overall pattern or configuration. At the top are characteristics of how the lesion relates to other lesions or structures in its neighborhood, including the parenchymal structure in which it is situated.

Our guided explorations with each of the experts on the intact breast images did not begin until the second half of Year 2, and then it continued into the middle of Year 4. The explorations were mainly in the context of having the readers talk aloud about what they looked for and saw as they read selected images. Each expert read a large number of cases selected to encompass each type of lesion presentation. The experts were also asked to comment on cases in the

Preliminary Reading Study, and many of those comments suggested potentially new features or new interpretations of features.

The following is a summary of the results of those various explorations.

### 3.1.1. Stereo-based information in lesions that present as clusters of calcifications.

*Information in the locus, shape and orientation of individual elements of calcification.* The stereo display provides a powerful new basis for perceiving the locus, shape and orientation in depth of individual calcifications. The characteristic size and shape of elements comprising the cluster are now recognized as critically important in diagnostic analysis, so this is a sharpening of information now known to be of critical importance.

*Information in the locus, shape and orientation of sub-clusters.* The improved localization of individual elements in depth also permits much more accurate perceptions of the position, shape and orientation in depth of sub-clusters. Linear arrangements of elements are of particular diagnostic significance because they can suggest conformance of the lesion to a ductal structure. Stereo viewing seems to aid detection of linearity immensely, regardless of the 3D orientation of the line of elements. Also, the added information that stereo provides for improved sensing of the shapes and orientations of the individual elements comprising the sub-cluster may permit even sharper diagnostic distinctions, helping, for example, to distinguish between less virulent (cribriform) and more aggressive (comedo) types of malignant tumors.

*Information in the configuration of the cluster as a whole.* Importantly, stereo viewing can tell the mammographer whether a collection of elements truly occupy a small volume in depth—and thus qualify as a related cluster—or are actually dispersed in depth and only appear to be clustered from the imaged point-of-view. Being able to see better the positions in depth of individual elements as well as the position, shape and orientation of its sub-clusters, will enable improved perception of the overall configuration in depth of the cluster as a whole. This can be additionally important in determining the type of lesion spawning those calcifications. If, for example, it were comprised of two or more linear sub-clusters, telling whether or not they pointed to a common nexus would be an important further consideration of its ductal conformance.

*Information in the locus and orientation of the cluster relative to other visible structures in the breast.* Perception in depth of the locus and configuration of the cluster in relation to the configurations and locations in depth of other breast structures opens many new possible bases for diagnosis. Of first interest in this regard are relationships between the cluster in different configurations or orientations and how it relates to the surrounding parenchymal structure. The potential for critical new diagnostic information is probably greater in this regard with respect to lesions that present as masses, but well worth exploring here as well. The refined information that the stereo display can provide about the overall configuration of the cluster will potentially provide bench marks for characterizing its orientation, and how it, in turn, relates to the surrounding parenchymal structure. One might expect, for example, that a branching configuration would be oriented appropriately relative to the ductal system whether visually evident or not. Also intriguing, for those lesions that present both as a cluster of calcifications

and a mass, are the possibilities of relating configuration of the cluster to configuration of the mass. Experience with the few cases we have of this combination has suggested that how the calcifications are situated may help in distinguishing a malignant mass from a fibroadenoma.

### 3.1.2. Stereo-based information in lesions that present as masses.

*Information in the locus, size, shape and orientation of individual lobulations.* A critical consideration in the diagnosis of masses is the nature of the surface of the mass. Telling whether and how it is lobulated is an important consideration, and that can only be crudely determined in conventional mammography from inspection of the border seen only in profile. There is no way to tell where any individual lobe originates on the surface of the mass, the angle at which it protrudes from the surface, or its true length or shape. Stereo can potentially provide all of that information. Indeed, in one case we have examined, a large lobe that does not protrude out from the mass profile at all can be seen in its full extent in depth against the frontal surface of the mass. In conventional mammography, that lobe would be seen, if at all, just as a meaningless variation in density in the interior of the mass.

*Information in the distribution and arrangement of lobulations.* With the ability to distinguish the wholes of individual lobulations comes the potential for assessing characteristics of them in combination—how they are arranged, how nested, etc. Such distributional characteristics may be informative of the glandular structure in which the tumor is growing, e.g., in some type of lobular structure.

*Information in the origin, length, configuration and path of individual spicules.* Determining whether the mass shows any evidence of spiculation is also critical to diagnosis, and, for the same reasons that apply in checking for lobulation, the conventional display provides very limited information, while the stereo display is potentially very informative. Our experience is that where an individual spicule emerges from the mass can often be clearly pinpointed, and its path, from beginning to end, even if twisting, clearly traced in depth. This provides remarkably complete views of individual spicules probably never previously seen, not even in the most intensive pathology examinations, limited as they are to slice-by-slice viewing of specimens.

*Information in the locus and orientation of the mass relative to other visible structures in the breast.* Again, the stereo display promises to supply much more information about the overall configuration of the lesion, here the shape of the mass and the arrangement of variations in its surface, possibly to provide bench marks for determining its orientation relative to the surrounding parenchymal structure. If the mass appears to be lobular, where and how the lobulation varies over its surface may be discernible enough to suggest how it ought to be oriented and how it ought to fit into the parenchymal structure. When the mass exhibits clear spicules, that provides sufficient evidence to confidently call it malignant. But seeing how those spicules extend into the parenchyma and interact with other structures may be important for guiding treatment and prognosis. It might also contribute to understanding the disease process. We have one example where two spicules extending from a large mass end up connected to two smaller masses. That poses an intriguing question about whether and how the three masses are related.

### 3.1.3. Stereo-based information in lesions that present as architectural distortion.

*Information in the locus of the origin of the defining spicules and in their radiating paths.*  
The stereo display will provide the same richness of information here as with the spicules emanating from visible masses, ensuring much more accurate identification of architectural distortion. Being able to pinpoint precisely where the origin lies relative to the parenchyma may contribute to improved understanding of the disease process. We have one case in which the visible mass appears to be but a dense collection of spicules all emanating from the center of the mass. This poses a very interesting question about whether some masses might be but dense collections of processes that when seen individually as just a few spokes emanating from a point are called architectural distortion. The stereo display will also provide a powerful source of information for distinguishing between normal striations in the parenchyma that in a particular two-dimensional view just happen to line up in depth into a purely illusory spoke pattern. We have one clear case so far where in conventional mammography there appeared to be architectural distortion, but where the stereo display showed that not to be the case.

### 3.2. Reaching consensus on the features to be included on the checklist/questionnaire (Task 6)

The plan originally was to have the experts meet together with us in one extended session to review each other's feature lists and reach consensus on a final list. That original plan proved to be impractical for two reasons. First, we found it inappropriate to attempt to reach consensus in just one meeting. Gaining familiarity with the full spectrum of features visible in the stereo display proved to be more drawn out and iterative than we had expected. It became clear that multiple opportunities for discussion would be required. Indeed, the readers were still learning how to interpret the stereo display even well into the preliminary reading study as evidenced in their recorded comments on individual cases. Also, it proved to be very difficult to schedule our busy experts to meet all together even on one occasion, let alone repeatedly. We decided, therefore, to meet with them where possible two at a time and singly where necessary to review with them what the other expert or experts had to say. And that process continued even into and after the preliminary reading study. It was in that recurring back and forth fashion that we arrived at consensus on a final list of features and on a common agreement as to the wording of the individual features.

### 3.3. Construction of the checklist/questionnaire (Task 7)

The checklist/questionnaire was to be designed originally to support the readers just at the task of diagnosing the biopsy-verified lesion(s) on each case. With the change to full-field-of-view imaging came the opportunity to expand the reader's task to include searching for additional significant lesions in the stereo images of each case. While the preliminary reading study was aimed just at diagnosing the verified lesion on each case, we found that the readers were frequently reporting in their comments on lesions that they could see in the stereo display that were not visible on the films. So, for the final reading study, we added the detection task and expanded the checklist/questionnaire to cover reporting on lesions newly revealed in the stereo display.

The full checklist/questionnaire designed to cover both tasks is presented in Appendix A.

### 3.3.1. Structure and function of the full checklist/questionnaire

The cover sheet first informs the reader about the verified lesion(s) that are to be feature analyzed and diagnosed. Each of the verified lesions is already marked on the films. What we indicate on the cover sheet is the form of presentation that each takes, indicating to the reader the one or more specialized checklist/questionnaires tailored to that presentation that the reader will be required to fill out. Also on the cover sheet are sections devoted to the *detection task* where the reader will ultimately return to report on the results of the search in the stereo display for additional possible lesions of concern not visible on the films. Sections are provided for reporting on how many such lesions there are, up to five, and for reporting on the locus and form of presentation of each, up to three.

The remaining 11 pages, divided into three sections, are devoted to the *diagnostic task*. Each section is a checklist/questionnaire tailored to a different one of the three main forms of presentation that a lesion can take, individually or in combination: a mass, a cluster of calcifications, or architectural distortion. Each provides for the reader to do the feature assessments and rate the probability of malignancy first based on the films alone and then based on the films plus stereo. Each is also designed to stand alone, in the sense that it provides for the reader to rate all of the features relevant to that form of presentation as well as providing at the end for rating the probability of malignancy and commenting on the case. Where a lesion presents in more than one form, the appropriate questionnaires are combined, and just one page is provided at the end for the reader to rate malignancy and make comments.

The general procedure was for the reader to conduct the feature assessments and rate the probability of malignancy of each verified lesion. They were to do that first based on the films alone, then again based on films plus stereo. They were then to search the stereo display and report on any additional lesions, or additional presentations of the verified lesion, visible on stereo but not on the films.

### 3.3.2. Construction of a reduced checklist/questionnaire

In pretests of the final reading study, we found that the full checklist/questionnaire was far too long. What with all the required looking back and forth between the films and the stereo display, often on a feature-by-feature basis, it was taking as much as 20 minutes or longer to read a case, following and filling out the full questionnaire. The only recourse was to drastically reduce the number of features to be assessed. To get the length of the reading session in reasonable bounds, we found that we could retain only a few features. We selected features to be retained that seemed most promising to yield new information from the stereo display. The reduced checklist/questionnaire is presented in Appendix B. The original 12 pages are reduced to 4. The cover page now gives just the information on the form of presentation of the verified lesions. Page 2 provides for rating two features of masses, one feature of calcification clusters, and two features of architectural distortion. Page 3 provides for rating the probability of malignancy of the verified lesion, for rating the extent to which the stereo helped in reaching the

diagnosis, and for commenting on the cases. Page 4 is for the reader to report on the search for additional worrisome lesions or additional presentations of the verified lesion(s) visible on the stereo display but not on the films. This drastically reduced form helped us to get the reading time per case down to about 5 minutes.

#### 4. Preliminary Reading Study (Tasks 9, 10, 11, 12)

We decided to conduct a preliminary reading study during Year 3, using the cases acquired up to that point. The reasons for carrying out this study were to help develop and debug the procedures to be used in the final reading study, to gain some preliminary insight from the readers about the potential value of the stereo mammogram, to identify any problems with the stereo display or the stereo mammograms, and to obtain some preliminary measure of the improvement in diagnostic accuracy afforded by the stereo mammogram.

##### 4.1 Method

###### 4.1.1 Development of software to control the reading session

We developed a program that was used to control the reading session, providing the reader with appropriate information on the system monitor, case-by-case, and giving the reader control over aspects of the displayed images. The program first informed the reader of the next case study number to be read and the age of the patient. When the reader had examined the films alone, the program accepted an estimated probability of malignancy typed in by the reader. A non-stereo display of the digital images was then enabled. The reader could view one or the other of the two images, toggling between them, manipulating brightness, contrast, and grayscale inversion with movements of the mouse and use of its three buttons. After typing in a second estimated probability of malignancy, the reader was then shown the digital images in stereo. The same controls of the display were available, including now inversion of depth. The reader then entered a new estimate of the probability of malignancy. This ended reading of the current case, and information about the next case was then presented.

###### 4.1.2 Case set

The case set for the preliminary study consisted of 76 cases with pathology-proven lesions. For each of these cases, we had acquired the set of diagnostic films that had led to the biopsy of the lesion. The distribution of lesions by type and by pathology truth is shown below in Table 1.

**Table 1. Distribution of lesions by type and pathology.**

Lesion Type	Truth		Total
	Benign	Malignant	
Mass	22	12	34
Calcifications	29	4	33
Architectural Distortion	2	7	9
Total	53	23	76

#### 4.1.3 Readers

Four highly experienced mammographers participated in this study. Two of these mammographers were two of the three expert consultants to the project, namely, Dr. Jack Meyer and Dr. Norman Sadowsky. The other two mammographers were Dr. Larry Moss from the University of Massachusetts Medical Center and Dr. Elsie Levin from Faulkner Hospital.

#### 4.1.4 Study Design

Each reader participated in two reading sessions (each approximately a half day in length) reading half of the cases in the first session and the other half of the cases in the second. The cases were read without knowledge of pathology truth, and none were ones that the two experts had previously seen, with pathology truth, in the guided interview. Each set was arranged in a single random order. At the start of the first reading session, we provided a brief training session in which the reader was familiarized with the operation of the stereo display workstation and given an opportunity to practice with its keyboard controls.

Each case was read in three phases, in immediate succession. In the first phase the reader was shown the set of available film images from the diagnostic study, mounted on an automated film viewer, and told the patient's age. The reader was then required to estimate the probability, on a 100-point scale, that the lesion was malignant and to enter that value via the keyboard for recording by the system.

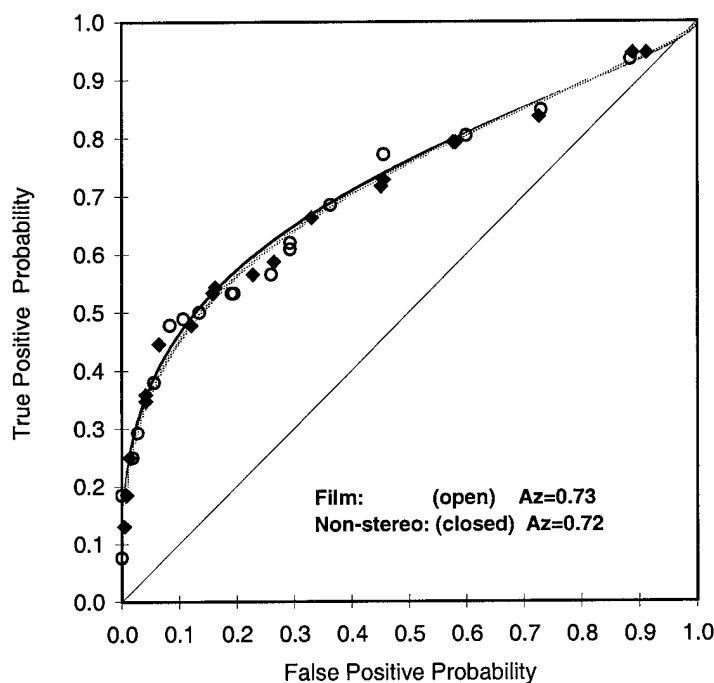
In the second phase of reading a case, the reader could view one or the other of the two available digital images for the case in non-stereo mode on the display monitor. In this phase, only non-stereo viewing of the images was allowed; both eyes always saw the same image. The reader was allowed to switch back and forth between the two images, but was only able to see one at a time. The films for the case were still available to the reader for reference. The reader was able to control aspects of the display, including brightness, contrast, and grayscale inversion. After viewing the non-stereo presentations of the digital images, the reader was required to make a new assessment of the probability that the lesion was malignant, taking into account the information available both on the films and on the non-stereo display, and type that assessment into the system.

In the third phase, the display was enabled to show the reader the two digital images as a single stereoscopic pair. The reader put on the stereo-viewing eyeglasses (StereoGraphics CrystalEyes LCD glasses) to view the images in this stereoscopic mode. The case's films remained available to the reader for reference. As above, the reader was able to control aspects of the stereo display, including brightness, contrast, grayscale inversion, plus, in this condition, depth inversion. After viewing the stereo image, the reader again was required to assess the probability that the lesion was malignant, this time taking into account the information provided by both by the films and by seeing the lesion in stereo.

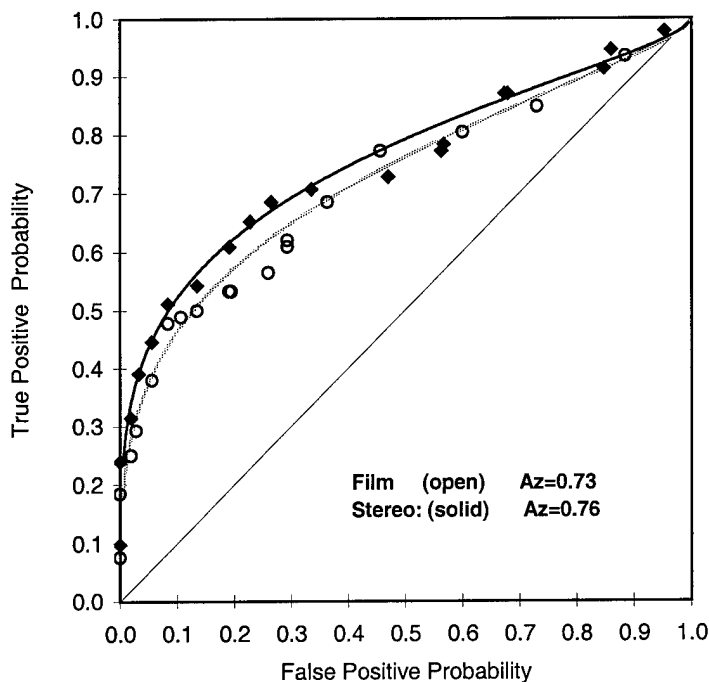
## 4.2 Results

### 4.2.1 Accuracy analyses

We conducted ROC analyses on the pooled data of our 4 readers. We show the fitted ROC curves and the empirical data points for judgments based on film alone versus film plus non-stereo viewing of the digital mammogram in Figure 4 below, and for film alone versus film plus the stereo mammogram in Figure 5. We used as our measure of diagnostic accuracy,  $A_z$ , the area under the fitted ROC curve. The estimated values of  $A_z$  for film alone, film + non-stereo digital, and film + stereo digital were 0.73, 0.72 and 0.76. The film-alone accuracy of 0.73 is relatively low for standard mammography, indicating that this case set was relatively difficult to diagnose. Statistical analysis of the results showed that film + non-stereo digital was not significantly more accurate than film alone ( $p > .83$ ). On the other hand, film + stereo digital was significantly more accurate than film alone ( $p < .04$ ). Thus, the stereo mammogram added a significant amount of adjunctive diagnostic information to that obtained from the films alone.



**Figure 4. ROCs for film alone and film plus the non-stereo digital mammogram.**



**Figure 5. ROCs for film alone and film plus the stereo digital mammogram.**

We would have liked also to examine the accuracy results broken down by type of lesion. However, we were unable to carry out this analysis because the number of cases in each of the resulting subsets is too small to obtain reliable results. We note that we were able to conduct this type of analysis on the results of the final reading study, reported below, where we had available a much larger case set.

#### 4.3 Discussion

We read carefully through the log of comments written by each reader as he/she read cases. From their comments, we were able to draw several general conclusions, as well as observations about particular cases. The most important general conclusion, commented on by all four readers, is that the spatial resolution of the digital images displayed on our workstation (whether stereo or non-stereo) is poorer than that of the films. This is manifest largely in cases presenting with very small, fine micro-calcifications. Our readers frequently commented that some of the calcifications visible in the films were simply not visible in the digital images. (However, we should note also that occasionally readers remarked that calcifications, when they were large enough to be visible in the digital image, were more clear or more visible in the digital images than on the film). We believe that there may be two reasons for the apparently poorer spatial resolution in the digital images. The first is a possible limitation of the 100-micron spot size of the GE digital mammography unit. There is some reason to think that 100 microns is too large a spot size to adequately capture very small calcification elements that may be only 50 microns in diameter. A second reason is a degradation of available spatial resolution by the shadow mask in the color display monitor used in the stereo display workstation. The fact that each grayscale pixel on our color monitor necessarily is composed of triads of equally

illuminated color dots, guarantees some loss of spatial resolution available in the image. We considered this problem to be sufficiently serious that we resolved to replace the color monitor with a high-resolution grayscale (monochrome) monitor before conducting the final reading study.

A second general observation was that vertical elongation present in the display—an uncorrectable distortion characteristic of this monitor—sometimes created a problem in interpreting a displayed lesion. The distortion arises because in order to present a correct aspect ratio in stereo display mode, the vertical size of the displayed image needs to be half of the screen height rather than full height. The autosync circuits in this (and, in fact, in most) monitors attempt to automatically cause the image to fill the screen vertically. Unfortunately, the manual vertical size control on our Hitachi monitor will only permit reduction of the vertical image size to about two-thirds of the full screen height, causing a displayed circular area to appear as an ellipse, elongated vertically. While our readers could take this known distortion into account fairly well, it did make it difficult to decide, sometimes, whether an apparently linear calcification element was truly linear or only optically stretched. Similarly, a mass that was truly spherical would take on the appearance of an ovoid. We regarded this, too, as a serious problem, one that we were able to resolve in acquiring a monochrome monitor for the final reading study.

But the most potentially important and exciting finding from our review of the case-by-case comments was that, in 6 of the 76 cases read, one or more readers reported detecting a new, additional lesion in the stereo display that was *not visible in the standard films*. In 3 of the cases, a mass was visualized where only calcifications were seen on the film. In the other 3, architectural distortion was seen on the stereo but not on the film. This finding suggests that a significant role for stereo mammography may lie in increasing the detectability of early, subtle lesions that are not visible in a standard mammographic film study.

## **5. Final Reading Study (Tasks 10, 11,12, 13)**

The final reading study was conducted in the second half of Year 4, using all cases for which we had an acceptable stereo mammogram and an acceptable diagnostic film study. We simplified the reading procedure to include only two stages of reading: (1) film alone, followed by (2) film plus stereo digital mammogram. We omitted the prior second stage used in the preliminary reading study—film plus non-stereo viewing of the digital mammogram. This had been included in the preliminary reading study as a control condition to assess the amount of help provided by the digital mammogram, when viewed as an additional 2D non-stereo view. The result in the preliminary study was that the non-stereo digital mammogram provided no significant improvement in diagnostic accuracy when supplied as an adjunct to the film study. Consequently, we chose to omit that condition in the final reading study in order to save reading time. This was important because the protocol in the final reading study included several new, additional tasks for the reader. For each case, these included (1) making quantitative ratings of several perceptual features on a checklist/questionnaire, (2) making a subjective, quantitative rating of how much the stereo mammogram helped, (3) writing down comments about the case, and (4) examining the stereo mammogram for any new, additional lesions not visible in the film study, and documenting any such lesions found.

## 5.1 Method

### 5.1.1 Case set

Of the 197 stereo-imaged, biopsy-proven lesions that potentially could have been included in this study, we had to exclude 60, leaving a total of 137 lesions. The primary reason for exclusion was that the diagnostic film study (the one leading to the decision for biopsy) was not available to us, or was missing critical films. Other reasons were poor quality of the films (e.g., motion artifact or copy films that were blurred) or poor quality of the stereo mammogram (typically because of movement of the imaged breast between capture of the two images, resulting in a stereo pair that could not be well fused visually).

The distribution of the included 137 lesions, by type and by pathology truth, is shown in Table 2 below.

**Table 2. Distribution of lesions by type and pathology.**

Lesion Type	Truth		Total
	Benign	Malignant	
Mass	34	15	49
Calcifications	69	10	79
Architectural Distortion	2	7	9
Total	105	32	137

### 5.1.2 Readers

Five highly experienced mammographers from three different Boston area hospitals participated in the final reading study. Two of the mammographers, Dr. Jack Meyer and Dr. Phyllis Kornguth, are associated with Brigham and Woman's Hospital. Two other readers, Dr. Larry Moss and Dr. Luis Diaz, are located at the University of Massachusetts Medical Center. The fifth reader, Dr. Elsie Levin, is associated with Faulkner Hospital.

### 5.1.3 Study design

Each reader participated in from three to five reading sessions (each approximately a half day in length) reading from 25 to 50 cases per session. The cases were read without knowledge of pathology truth. The case set was read in a single random order in order to minimize reloading of the films on the automated film viewer. At the start of the first reading session, we provided a brief training session in which the reader was familiarized with the operation of the stereo display workstation and given an opportunity to practice with its keyboard controls.

Each case was read in two phases, in immediate succession. In the first phase the reader was shown the set of available film images from the diagnostic study, mounted on a panel of an automated film viewer, and informed of the patient's age. The reader was provided with a paper form for each case that was to be filled out. The first page of the form provided the reader with information about the lesion type that had been biopsied. The location of the lesion was also

marked on one or more of the films. The reader's first task was to make quantitative ratings from the films of the one or two perceptual features that applied to the presenting lesion type. The reader then estimated the probability, on a 100-point scale, that the lesion was malignant.

In the second phase of reading a case, the stereo mammogram of the case was enabled to show the reader the two digital images as a single stereoscopic pair. The reader put on the stereoviewing eyeglasses (StereoGraphics CrystalEyes LCD glasses) to view the images in this stereoscopic mode. The case's films remained available to the reader for reference. The reader was able to control aspects of the stereo display through positioning of the mouse and use of its three buttons, including brightness, contrast, grayscale inversion, and depth inversion. After viewing the stereo image, the reader went back to the paper form and again made quantitative assessments of the relevant perceptual features, now using information both from the stereo mammogram and the films. This was followed by a second assessment of the probability that the lesion was malignant, this time taking into account the information provided by both by the films and the stereo mammogram. Then the reader made a quantitative rating of the amount of additional information provided by the stereo mammogram for this case, and wrote down any comments about the case.

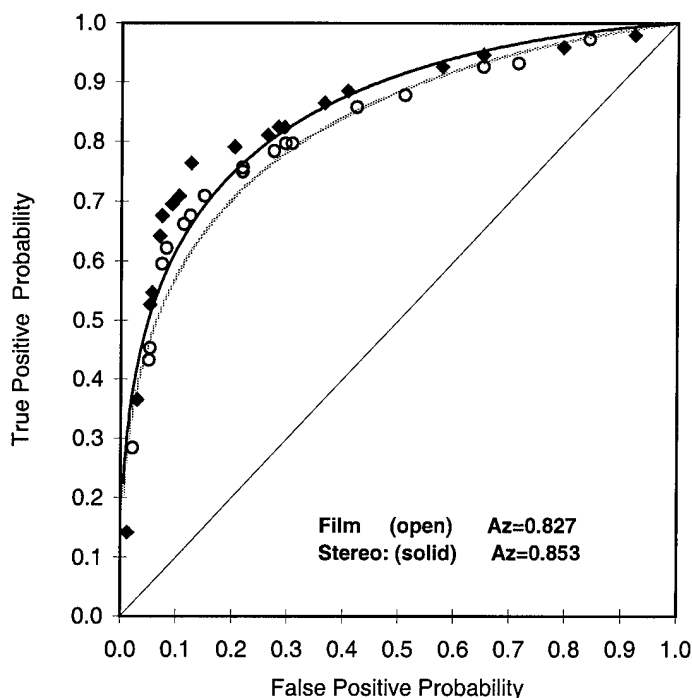
Finally, the reader was asked to examine both the full-resolution partial-breast view, centered on the biopsied lesion, and the half-resolution complete-breast overview for any new, additional lesions, or additional presentations of the verified lesion, that were detectable in the stereo mammogram, but *were not visible in any of the films*. If the reader detected any such lesion, he/she was asked to check off the lesion type, write down a description of the lesion, and indicate its location on a diagram.

At the end of the final session, each reader was asked to spend a few minutes filling out a debriefing form (see Appendix C). The form presented the reader with a series of questions aimed (1) at helping us better understand the findings and limitations of the study, and (2) at helping us reflect on how stereo mammography might best be employed in a clinical setting.

## 5.2 Results

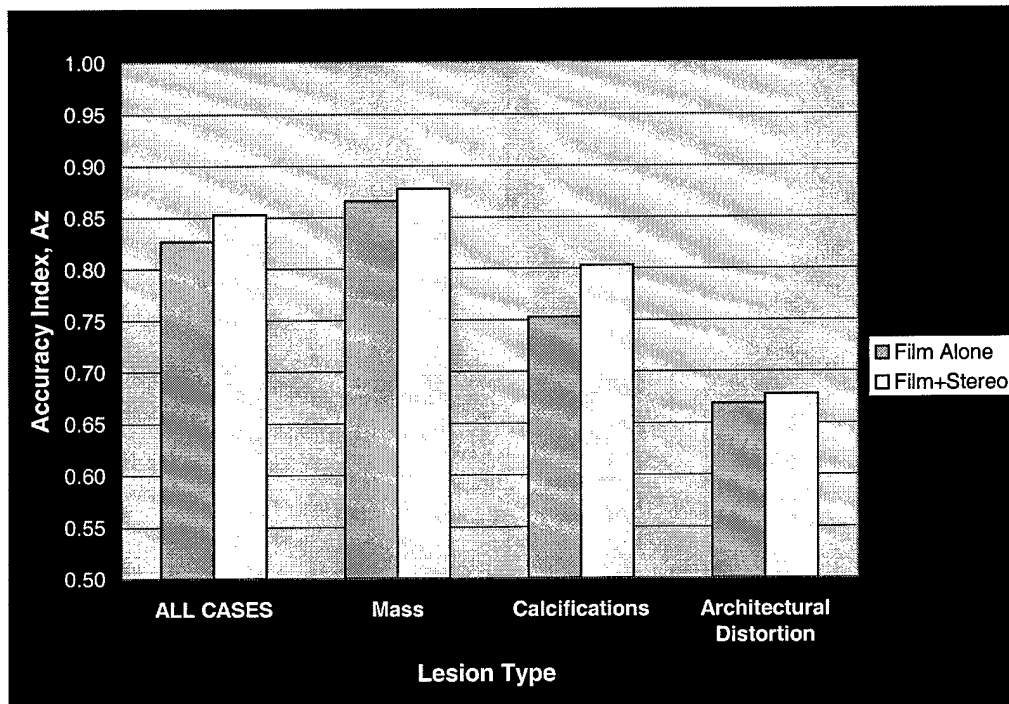
### 5.2.1 Accuracy analyses

*For all cases.* We performed ROC analyses on the readers' judgments of the likelihood of malignancy, pooled over the 5 readers and all cases. As in the preliminary study, we used the area under the fitted ROC curve,  $A_z$ , as our measure of diagnostic accuracy. The fitted curves and the empirical data points are shown below in Figure 6 for film alone versus film plus the stereo mammogram. The estimated value of  $A_z$  for film alone was .827, and for film plus stereo was .853. The improvement in accuracy when the stereo mammogram was included, an increase of .026 in  $A_z$ , is statistically significant ( $p = .003$ ). We note that these accuracy measures are higher than those observed in the preliminary reading study, probably because the smaller case set used in the preliminary study was more difficult to interpret.



**Figure 6. ROCs for film alone and film plus the stereo mammogram, for all cases.**

*By lesion type.* We also performed ROC analyses separately for each of the three lesion types: masses, clustered calcifications, and architectural distortion. The estimated values of Az are shown in Figure 7 below, comparing film alone with film plus the stereo mammogram for each of the three lesion types. For masses, addition of the stereo mammogram increased accuracy from an Az of .861 for film alone to an Az of .873 when the stereo mammogram was added. This improvement is not statistically significant ( $p > .15$ ). For clustered calcifications, accuracy increased from .753 for film alone to .803 when the stereo mammogram was included, a significant improvement ( $p < .05$ ). For architectural distortion, accuracy increased marginally from .678 to .680, an improvement that is not statistically significant ( $p > .40$ ). Because there were very few cases of architectural distortion in our sample, these last accuracy estimates should not be regarded as very reliable.



**Figure 7. Diagnostic accuracy by type of lesion**

*By reader.* Finally, we performed ROC analyses separately for each reader, using all cases. The estimated values of Az are shown in Table 3 below for each of the 5 readers, comparing film alone with film plus the stereo mammogram. The accuracy measures for film alone are fairly similar across readers. And with the exception of one reader (Reader #3), all of the readers show similar improvements in accuracy from the addition of the stereo mammogram. We do not know why Reader #3 failed to show improvement with the addition of the stereo mammogram, although this reader was the least experienced of the five.

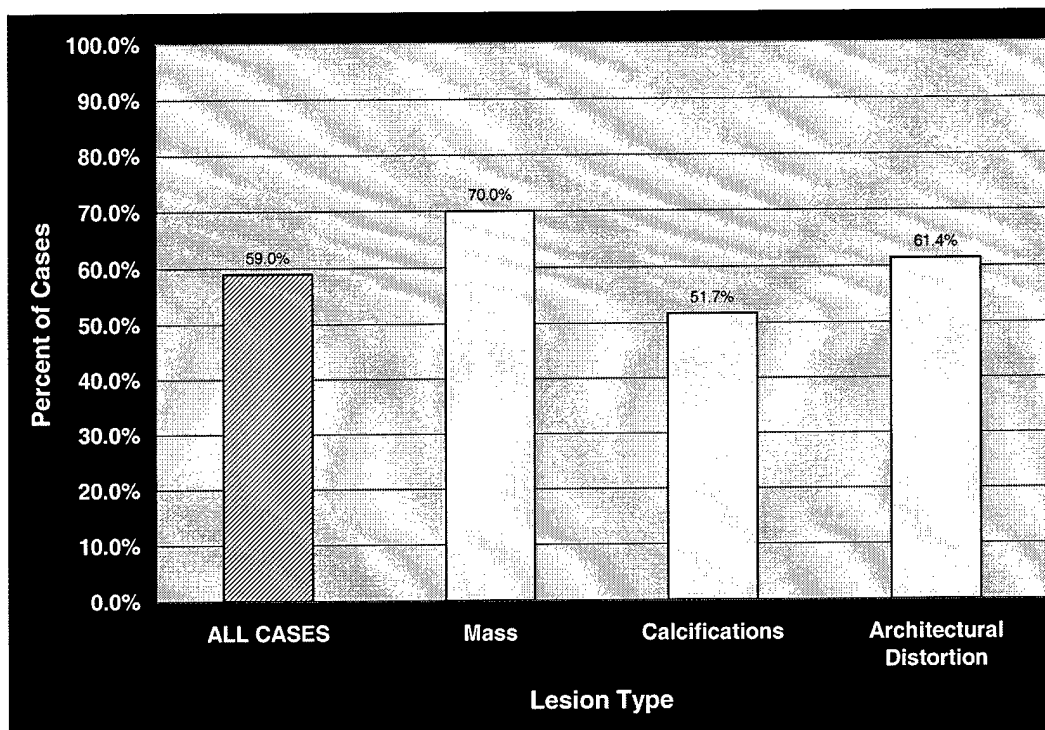
**Table 3. Estimated accuracy, Az, for individual readers**

<i>Reader</i>	<i>Film alone</i>	<i>Film + Stereo</i>	<i>Increase in Az</i>
1	.875	.898	+ .023
2	.876	.912	+ .036
3	.832	.820	- .012
4	.794	.851	+ .057
5	.839	.865	+ .026
Average	.843	.869	+ .026

### 5.2.2 Rating of the amount of additional information provided by the stereo mammogram

One item on the checklist/questionnaire filled out for each case, by each reader, asked the reader to rate the amount of additional information provided by the stereo mammogram, on a ten-point scale (see Appendix B). The endpoints of the scale were labeled "None" and "Much." We tabulated the cases where the reader felt that the stereo mammogram provided at least some new information, and present this data, pooled over readers, as percentages in Figure 8 below.

Over all lesion types, the stereo mammogram was judged to be helpful on about 60% of the cases. It was judged to be most helpful for mass lesions (70% of masses), slightly less helpful for architectural distortion (61%), and helpful about half the time for clustered calcifications (52%). This last percentage is relatively low because very small elements of calcium, visible in the films, were frequently not visible in the digital mammogram. We discuss this further in Section 5.2.4 below.



**Figure 8. Percent of cases for which the stereo mammogram provided additional information.**

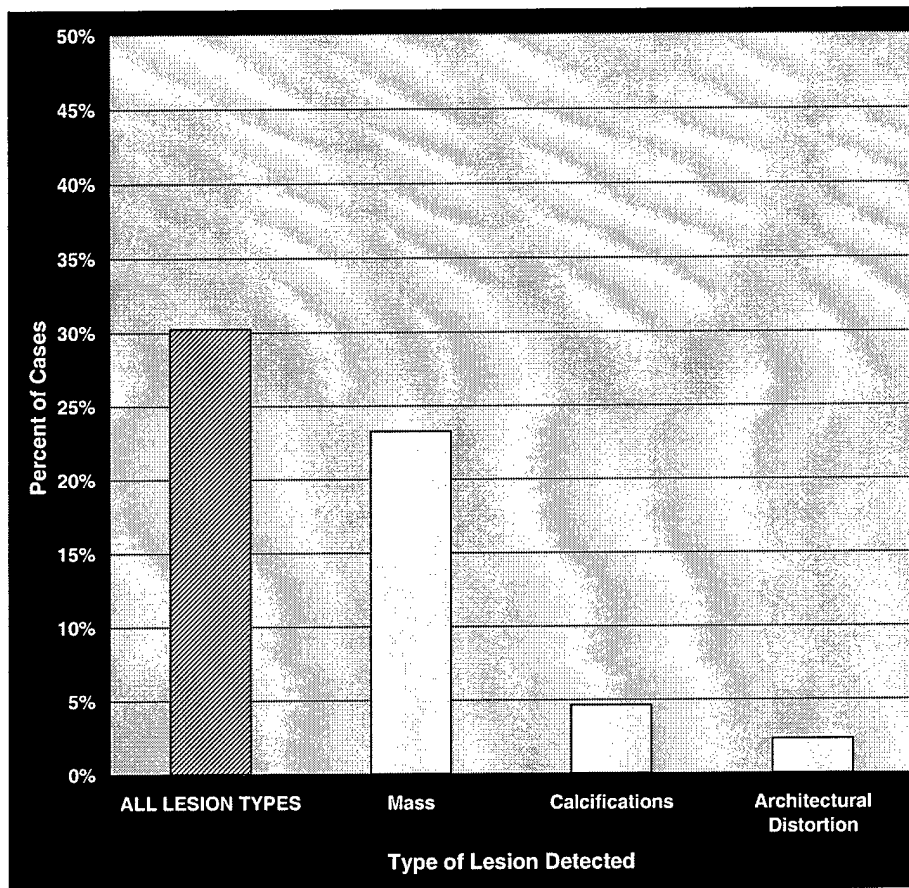
### 5.2.3 New lesions detected only in the stereo mammogram

As mentioned above, an additional task for the readers was to scan the stereo mammogram of each case for any new, additional lesions, that were detectable in the stereo mammogram but *not visible in the film study*. Readers were somewhat impeded in this task because the full-resolution stereo view encompassed only a partial view of the breast—a 1024 by 1024 pixel window centered on the lesion that had been biopsied. They could, and were encouraged to, also call up the stereo overview of the entire breast. The overview, however, was only at half-resolution (every other line and pixel discarded). Consequently, our results from this analysis are almost certainly conservative, underestimating the actual number of new lesions that might have been seen in a full-resolution stereo view of the entire breast.

Nevertheless, even with this limitation, the results of this analysis are very striking and exciting. *Within the 129 different cases included in the final study (8 cases included two proven lesions in the same breast), 52 new lesions were detected in the stereo mammogram by one or more of the readers. These lesions were not visible in any of the films.* Since the completion of

the reading study, we carefully reviewed this set of newly detected lesions with the help of our consulting expert mammographer, Dr. Carl D'Orsi. In this review, we examined the films, the stereo image and all of the documentation on the case (the mammography and pathology reports). *Using rather strict criteria for declaring a newly detected lesion as probably real, we ended up with a set of 39 new lesions detected in the stereo mammogram and not visible in the film study.*

Effectively, then, a new lesion was detected in 30% of the cases, as shown below in Figure 9. The breakdown of the set of newly detected lesions by lesion type is shown in the three bars to the right: 30 masses, 6 clusters of calcifications, and 3 areas of architectural distortion.



**Figure 9. Percent of cases in which a new lesion was detected in the stereo mammogram.**

In 15 of the cases of a new stereo-detected mass, the cted mass was seen not as an additional lesion but as an additional presentation of the verified lesion (e.g., as a mass surrounding calcifications that had been detected in the film study). In the other 15 cases of a newly detected mass, the mass was a new lesion unrelated to the biopsied lesion seen in the film study. For newly detected clustered calcifications, 2 cases involved calcifications associated with a film-detected mass; the other 4 cases were newly detected calcifications unrelated to the biopsied, film-detected lesion. For newly detected architectural distortion, 1 case involved

architectural distortion detected in the stereo in association with calcifications seen in the film; for the other two cases, the architectural distortion was unrelated to the biopsied, film-detected lesion.

#### 5.2.4 Tabulation of comments made by the readers

We categorized and tabulated the comments made by the readers on individual cases. We also examined the more general comments made by the readers on the debriefing forms. We summarize these comments below, grouped by lesion type.

*Mass.* Readers very frequently commented that they could see the characteristics of a mass border better in stereo than in the films (39/52 lesions = 75%). Since the border appearance is important in judging the likelihood that a mass is malignant, this would probably help with the recommendation between biopsy and accelerated follow-up. The stereo image often helped them delineate more of the border of a partially obscured mass, by separating overlying tissue in depth. Spiculations were sometimes more conspicuous in stereo leading to more confidence about their presence.

*Clustered calcifications.* For a significant percentage of cases with clustered calcifications, readers reported that the elements were poorly seen in the digital image, or fewer elements were seen compared to the film study (35/88 clusters = 40%). On the other hand, when the calcium particles were large enough to be seen well in the stereo image, readers frequently commented that they could visualize the shape of the elements better in the stereo image (44/88 clusters = 50%). There were also frequent comments that the geometric distribution of the elements (e.g., following a ductal pattern) could be better seen in the stereo image since it was directly visualized (26/88 lesions = 30%).

*Architectural distortion.* Readers commented that the stereo image was very helpful for detecting architectural distortion (6/11 lesions = 55%). They reported that the conspicuity of these lesions was considerably enhanced in stereo. They also found it helpful in determining whether a perceived architectural distortion was real or just due to a superposition of tissue.

*General.* Although our stereo imaging protocol in use for this project specified that the stereo mammogram would always be a CC view, readers noted that for some cases, a different stereo view (e.g., MLO or Lateral) would have provided much more information. Of course, in clinical use, any view could be obtained in stereo. As readers gained experience with the stereo display, they frequently commented that the ability to easily switch back and forth among different viewing modes—inverting the grayscale and inverting depth—was very helpful, as was the ability to easily control brightness and contrast to optimize viewing. This is clearly a major advantage of a digital display over film.

### 5.3 Development of Statistical Prediction Rules

#### 5.3.1 Statistical analysis of individual features

We conducted a statistical analysis of the ability of each of the individual features (shown in the checklist/questionnaire in Appendix B) to discriminate benign from malignant lesions. The results of two-tailed *t*-tests are shown below in Table 4. Both mass features, whether rated from the film alone or adjunctively with the stereo mammogram, are highly significant. The single calcification feature is significant when rated from film alone, but not when rated with the stereo image. After talking with the readers, it seems likely that there was a considerable amount of confusion about the definition of this feature, with different readers interpreting it in different ways. We think this explains the failure to find a significant effect for the stereo image. Finally, neither feature of architectural distortion was statistically significant. However, since the number of cases of architectural distortion was very small, the sample size is really too small to confidently draw any conclusion about the possible value of those features.

**Table 4. Two-tailed *t*-tests of individual features**

Feature	<i>t</i>	<i>df</i>	Sig.
Mass: % margin clearly circumscribed-film	8.341	249	<.0005
Mass: % margin clearly circumscribed-stereo	7.549	244	<.0005
Mass: Confidence re spiculation-film	5.439	249	<.0005
Mass: Confidence re spiculation-stereo	5.540	243	<.0005
Calc.: Degree distribution is uniform-film	3.532	423	<.0005
Calc.: Degree distribution is uniform-stereo	0.115	401	.909
AD: Number of lines converging-film	0.811	58	.421
AD: Number of lines converging-stereo	0.579	54	.565
AD: Confidence of convergence-film	0.590	54	.558
AD: Confidence of convergence-stereo	0.398	50	.692

#### 5.3.2 Development of statistical prediction rules (SPRs)

The development of meaningful statistical prediction rules for predicting the likelihood of malignancy requires training data for an adequately comprehensive set of perceptual features. This would have been possible had we been able to collect feature data on our case set using the original large checklist we developed. However, this is possible in only a very much more limited way given the drastically reduced feature set of the revised checklist we had to use. There are too few observations of architectural distortion to enable training of an SPR for that lesion type. But, there are some interesting results to report from training a linear discriminant prediction rule for masses and another for clustered calcifications.

*Mass SPR.* We performed a stepwise linear discriminant analysis on the 4 mass features rated by the readers, 2 rated on film alone and 2 rated on film plus stereo. The trained SPR includes two of the four features: (1) percent of the margin clearly circumscribed—from film alone, and (2) confidence re the presence of spiculation—from the stereo image. It is of interest that the judgment of the presence of spiculation is more discriminating based on information in

the stereo image than in the films. We conducted an ROC analysis of the probabilities of malignancy predicted by the SPR, for each case/reader. The diagnostic accuracy of this SPR, based on only those two features, was 0.826, measured by the area under the ROC. Recall that the accuracy for the readers for masses was 0.861 for film alone and 0.873 for film plus stereo. This surprisingly high accuracy for the SPR suggests that much of the diagnostic information extracted by readers for masses is contained in the border-related information of these two features.

*Clustered calcification SPR.* We next performed a stepwise linear discriminant analysis on the 2 calcification features rated by the readers, one each on film alone and film plus stereo. The trained SPR includes only a single feature: the degree to which the elements are uniformly distributed—from film alone. The diagnostic accuracy of that SPR, based on an ROC analysis of its predicted probabilities of malignancy for the cases, was 0.631. For the readers, accuracy was 0.753 for film alone and .803 for film plus stereo. This difference between the SPR and reader accuracy is not surprising since there are many other calcification features besides the one included in the SPR that are known to have diagnostic significance.

#### 5.4 Discussion

The analyses of the final reading study show that the stereo mammogram enabled readers to improve their diagnostic accuracy modestly, but significantly, from an Az of .827 to .853. Interestingly, looking at the gains by lesion type, the largest increase was seen for clustered calcifications, a gain of .05 from .753 to .803. This increase occurred in spite of the fact that readers commented that they could see calcifications less well, or see fewer of them, in the digital image than in the films. It suggests that the volumetric structure of the cluster that is immediately apparent in stereo, and that rarely can be appreciated in the 2D film, may be contributing significantly to diagnostic accuracy. It is also possible that larger gains might be achieved, not only for clustered calcifications but for other lesion types as well, as readers gain more experience with the appearance of lesions in 3D, especially when that experience is correlated with lesion truth. We do not fully understand, at this point, what the full range of differences may be in appearance between lesions associated with benign and malignant disease processes.

By far the most exciting finding of the final reading study, one that already had been suggested by the results of the preliminary reading study, was the detection of new lesions in the stereo images of our cases that were not visible on the films, in 30% of the cases. Some of these were new lesions, unrelated to the biopsied lesion seen in the films. For these new, unrelated lesions, we do not presently have any independent confirmation of their existence, other than our own strict review of each case with Dr. D'Orsi's help. However, we will conduct an intensive follow-up of these cases, both out of our obvious concern for the medical welfare of the patients for whom these new lesions may be very significant, and secondly to learn whether the lesions are real and the nature of their true pathology.

For the other newly detected lesions that were an additional presentation of a lesion seen in the films (e.g., detecting a mass in the stereo image surrounding a cluster of film-detected calcifications), we already know the pathology truth since these lesions were biopsied. Of

considerable interest is the finding that of 12 cases where a mass was seen in the stereo image surrounding calcifications that had been detected in the film (and that prompted the biopsy), pathology reported a mass in at least 8 of them (1 malignant mass, 5 fibroadenomas, 1 papilloma, and 1 cyst). Thus, the stereo mammogram seems to be very sensitive in revealing very subtle masses that are not visible in the film mammogram.

## KEY RESEARCH ACCOMPLISHMENTS

- Enrolled 188 female patients in the project, acquiring stereo mammograms of 197 biopsy-proven lesions.
- Explored alternative means of giving the user control over aspects of the stereo display, resulting in a software interface that is powerful but easy for a mammographer to use.
- Developed semi-automated software to carry out the processing steps needed to prepare the raw digital stereo mammograms for display on the workstation.
- Developed a checklist/questionnaire of stereo-based, quantitatively-assessed, visual features, based on perceptual explorations of stereo mammograms and guided interviews with three expert mammographers.
- Conducted a final reading study (5 mammographers, 137 cases) comparing the diagnostic accuracy of reading the film study alone with reading the film study together with the stereo mammogram.
- Determined that stereo mammography significantly improved diagnostic accuracy over film alone.
- Importantly, discovered that readers frequently detected additional, new lesions in the stereo mammogram that were not visible in the film study (39 lesions in 129 cases).

## REPORTABLE OUTCOMES

### MEETING PRESENTATIONS

Getty, D. J. Stereoscopic Digital Mammography: Improving Detection and Diagnosis of Breast Cancer. Invited presentation at the *Federal Technology Transfer Workshop on Breast Cancer Detection, Diagnosis and Treatment*, Washington, DC, May 1-2, 1997.

Getty, D. J. Stereoscopic Digital Mammography: Improving Diagnostic Accuracy. Invited platform speaker at the *Era of Hope*, Department of Defense Breast Cancer Research Meeting, Washington, DC, October 31 – November 4, 1997.

Getty, D. J. Invited participant in the *Working Group on Digital Mammography*, Bethesda, MD, March 9-10, 1998.

Getty, D. J. Stereoscopic Digital Mammography: What Can You See in a Stereo View of the Breast That You Can't See in Two Standard Orthogonal 2D Films? *Eighth Far West Medical Image Perception Conference*, Alberta, Canada, May 28-30, 1999.

Getty, D.J. Stereoscopic Digital Mammography: Improving Detection and Diagnosis of Breast Cancer. Invited platform speaker at the *Era of Hope*, Department of Defense Breast Cancer Research Meeting, Atlanta, GA, June 8-11, 2000.

### PATENTS

#### Stereo Radiography

Inventors: David J. Getty, A.W.F. Huggins

Patent Number 6,031,565, issued February 29, 2000.

## CONCLUSIONS

The main result of this research is our demonstration that stereo displays can improve mammography with respect both to the detection and diagnosis of breast lesions. An important secondary result is that we have, in the process, developed a system for displaying the stereo mammograms that mammographers find effective and easy to use. We first expand briefly on the nature of these two results and then consider various implications of them for the role that stereo mammography might play in the clinic and for the direction of future research. Finally, we evaluate these achievements as medical and scientific products.

The primary aim of this project was to determine whether and to what extent the stereo display could improve the accuracy of lesion diagnosis. We did find a statistically significant gain in accuracy ( $Az = .843$  for film alone versus  $Az = .869$  for film plus stereo). But, considering the large and growing reliance on needle biopsies for diagnosing lesions, that gain is probably of more academic than clinical significance. We need to acknowledge, of course, that the version of stereo we tested was disadvantaged by the digital display having only 100 micron resolution, and that larger gains would be expected with resolution as fine as 50 microns likely to be available in the not too distant future. The costs of needle biopsies are not entirely insignificant, and it may that stereo with higher resolution would be clinically competitive. For the present, however, our finding with respect to improved detection appears to be far the more clinically significant.

In our original proposal, we anticipated having to work with stereo images acquired with a narrow-field-of-view camera. That restriction ruled out the possibility of studying detection performance. However, early in the course of the research, full-field-of-view stereo images became available, and this provided an opportunity for us to add to the research an evaluation of the effect of stereo on detection. It was a limited opportunity, because the program had not been designed and could not be changed at that point to encompass the kind of case collection and follow up required for a fully adequate evaluation of detection. But the opportunity was there to take at least a partial look, and since it involved essentially no added cost, we took that opportunity. The basic approach was to add to the reader's task the requirement to search the stereo images for additional lesions not visible on the films. What we found was that, for 39 of the 129 cases, one or more of the readers, were sure they could see an additional lesion in the stereo that was not visible on the films. We are presently doing an intensive follow up on these cases— first and foremost in the medical interests of the patients for whom these detections may be very significant, and second to get a definitive measure of how much stereo really helps in detection. In the meantime, we have to rely heavily on the conviction of our highly experienced mammographers, that for many of these cases, the stereo display is picking up potentially significant lesions not seen in conventional film mammography. This suggests that stereo may have a very important future role to play in breast cancer screening—at least for patients at high risk, where the added cost in dollars and radiation exposure might be well justified by the earlier detections that stereo could provide. Further research on this question is surely justified, beginning with our current intensive search for truth data on these particular cases.

Development of the system for displaying the stereo images is our other main accomplishment. A particularly big challenge in the present research, and one that will continue in future studies, has been to get the readers to go beyond just looking in the stereo display for features familiar to them from their training and experience with films. The present project has shown that the domain of features of potential diagnostic value newly addressable in the stereo display is quite large. Making it easy for the readers to explore that large, new world then becomes very important, and the design of the stereo display system, in turn, becomes very important. The primary need is for the system to deliver the experience of depth in as perceptually compelling a way as possible, to give the readers strong impressions of the features of a lesion's structure in depth. One would like those new aspects of structure to be so visually compelling that they can, in a sense, "speak for themselves", rather than require that the reader *deliberately* seek them out. We believe that the system we developed is highly successful in that critical regard. The system should also make it easy for the reader, when some subtle feature has been sensed, to manipulate the display to bring it out as clearly as possible. The present system provides for a wide range of manipulations of the display – zoom, pan and scroll capabilities, windowing of the display grayscale, and inversion of depth and grayscale – and the user interface has been carefully crafted for the reader to take full and flexible advantage of those options. We explored various options for user control, including voice control and various combinations of joystick, mouse and keyboard controls. We settled on a combination of mouse and keyboard controls, which the readers have found to be quite acceptable – easy to learn, comfortable and efficient to use. This system has served us well in this project, and we see it as a good model of a system for future research in stereo mammography.

With respect to the merits of these results from a medical or clinical perspective, we point first to our finding that stereo could make a significant contribution toward earlier detection of breast cancer. Further study is needed to confirm that finding, but if true, it could be of great potential value, particularly to high-risk patients. We note, secondly, the great value that our display system could have in implementing stereo in the clinic. For any such implementation to be successful, the display system and its user interface would have to be very well designed so that mammographers would accept it and use it in a facile and effective way. Since the system we developed well approximates that need, it too can be considered a valuable product from the medical perspective.

## REFERENCES AND BACKGROUND LITERATURE

- D'Orsi, C. J., Getty, D. J., Swets, J. A., Pickett, R. M., Seltzer, S. E., and McNeil, B. J. (1992) Reading and decision aids for improved accuracy and standardization of mammographic diagnosis. *Radiology*, 184, 619-622.
- D'Orsi, C. J. and Kopans, D. B. (1993) Mammographic feature analysis. *Seminars in Roentgenology*, 28, 204-230.
- D'Orsi, C. J. and Karellas, A. (1995) Digital mammography: Are we ready? *The Lancet*, in press.
- DuMond, J. W. (1932) The technique of stereofluoroscopy. *Radiology*, 19, 366-387.
- Getty, DJ. (1996) Assisting the radiologist to greater accuracy. In *SPIE Medical Imaging 1996: Physics of Medical Imaging*, RL Van Metter and J. Beutel (Eds.), 2708, 2-15.
- Getty, D.J., and Huggins, A.W.F. (1986) Volumetric 3-D displays and spatial perception. In E.J. Wegman and D.J. DePriest (Eds.), *Statistical Image Processing and Graphics*, NY: Marcel Dekker.
- Getty, D. J., Pickett, R. M., D'Orsi, C. J., and Swets, J. A. (1988) Enhanced interpretation of diagnostic images. *Investigative Radiology*, 23(4), 240-252.
- Getty, D.J., Pickett, R.M., Chylack, L.T., Jr., McCarthy, D.F., and Huggins, A.W.F. (1989) An enriched set of features of nuclear cataract identified by multidimensional scaling. *Current Eye Research*, 8, 1-8.
- Getty DJ, Seltzer SE, Tempany CMC, Pickett RM, Swets JA, McNeil BJ. (1997) Prostate cancer: relative effects of demographic, clinical, histologic, and MR imaging variables on the accuracy of staging. *Radiology*, 204, 471-479.
- Huggins, A.W.F., and Getty, D.J. (1982) Display-control compatibility in 3-D displays. In D. Getty (Ed.), *3-D Displays: Perceptual Research and Applications to Military Systems*, Psychological Document 2570, American Psychological Association, 1200 17th St., NW, Washington, D.C. 20036
- Jarre, H. A. and Teschendorf, O. E. (1933) Roentgenstereoscopy: A review of its present status. *Radiology*, 21, 139-155.
- Karellas, A., Harris, L.J., and Davis, M.A. (1989) Design and evaluation of a prototype CCD-based imaging system for electronic radiography. *Medical Physics*, 16, 681.
- Karellas, A., Harris, L.J., and D'Orsi, C.J. (1990) Small field digital mammography with a 2048 x 2048 pixel charge-coupled device. *Radiology*, 177, 288.
- Karellas, A. and D'Orsi, C. J. (1992) Near real-time mammographic imaging with a CCD. *SPIE, International Working Group Newsletter*, 2(3).
- Karellas, A., Harris, L.J., Liu, H., Davis, M.A., and D'Orsi, C.J. (1992a) Charge-coupled device detector: Performance considerations and potential for small-field mammographic imaging applications. *Medical Physics*, 19(4), 1015-1023.
- Karellas, A., Liu, H., Harris, L. J., and D'Orsi, C.J. (1992b) Operational characteristics and potential of scientific-grade charge-coupled devices in x-ray imaging applications. *SPIE, Electron Tubes and Image Intensifiers*, 1655, 85-91.

- Karellas, A., Liu, H., Harris, L.J., and D'Orsi, C.J. (1994) Digital mammo delivers quick, reliable images. *Diagnostic Imaging*, Feb., 1994, 77-80.
- Liu, H., Karellas, A., Harris, L.J., and D'Orsi, C.J. (1993) Optical properties of fiber tapers and their impact on the performance of a fiber-optically coupled CCD x-ray imaging system. *Proc. SPIE*, 1994, 136-147.
- Liu, H. Karellas, A., Moore, S. C., Harris, L. J. and D'Orsi, C. J. (1994) Lesions detectability considerations for an optically-coupled CCD x-ray imaging system. *IEEE Trans. Nucl. Sci.*, 41, 1506-1509.
- Seltzer, S. E., McNeil, B. J., D'Orsi, C. J., Getty, D. J., Pickett, R. M., and Swets, J. A. (1992) Combining evidence from multiple imaging modalities: A feature-analysis method. *Computerized Medical Imaging and Graphics*, 16(6), 373-380.
- Seltzer SE, Getty DJ, Tempany CMC, Pickett RM, Schnall MD, McNeil BJ, Swets JA. (1997) Staging prostate cancer with MR imaging: a combined radiologist-computer system. *Radiology*, 202: 219-226.
- Swets, J. A. (1979) ROC analysis applied to the evaluation of medical imaging techniques. *Investigative Radiology*, 14(2), 109-121.
- Swets, J. A. (1986a) Indices of discrimination or diagnostic accuracy: Their ROCs and implied models. *Psychological Bulletin*, 99(1), 100-117.
- Swets, J. A. (1986b) Form of empirical ROCs in discrimination and diagnostic tasks: Implications for theory and measurement of performance. *Psychological Bulletin*, 99(2), 181-198.
- Swets, J. A. (1988) Measuring the accuracy of diagnostic systems. *Science*, 240, 1285-1293.
- Swets, J. A. (1992) The science of choosing the right decision threshold in high-stakes diagnostics. *American Psychologist*, 47(4), 522-532.
- Swets, J. A., Pickett, R. M., Whitehead, S. F., Getty, D. J., Schnur, J. A., Swets, J. B., Freeman, B. A. (1979) Assessment of diagnostic technologies. *Science*, 205, 753-759.
- Swets, J. A. and Pickett, R. M. (1982) *Evaluation of diagnostic systems: Methods from signal detection theory*, NY: Academic Press.
- Swets, J. A., Getty, D. J., Pickett, R. M., D'Orsi, C. J., Seltzer, S. E., and McNeil, B. J. (1991) Enhancing and evaluating diagnostic accuracy. *Medical Decision Making*, 11, 9-18.
- Warren, S.L. (1930) A roentgenologic study of the breast. *Amer. J. Roentgeneology Radium Therapy*, 1930, 24, 113-124.
- Wolfe, J.N. (1976) Risk for breast cancer development determined by mammographic parenchymal pattern. *Cancer*, 1976, 37, 2486-2492.

## Response Form--X-Ray Mammography (Stereo Study)

Reader: \_\_\_\_\_

Case No. \_\_\_\_\_

● **Appearance on films of tissue - verified findings**

Verified finding 1

VF1

- Mass
- Calcifications
- Architectural Distortion

Verified finding 2

VF2

- Mass
- Calcifications
- Architectural Distortion

Reader: \_\_\_\_\_

Case No. \_\_\_\_\_

Verified Finding No. \_\_\_\_\_

## Mass (MM)

● Density of mass relative to surrounding glandular tissue

<b>Film</b>	0	1	2	3	4	5	6	7	8	9	10	MM01-F	
	mass density much lower				isodense				mass density much higher				
<b>Stereo</b>	0	1	2	3	4	5	6	7	8	9	10	MM01-S	

● Confidence about the presence of fat within the mass

<b>Film</b>	0	1	2	3	4	5	6	7	8	9	10	MM02-F
	definitely NONE present					definitely some present						
<b>Stereo</b>	0	1	2	3	4	5	6	7	8	9	10	MM02-S

● Size of mass

<b>Film</b>	Largest diameter ( in either CC or oblique view)	_____ mm	MM03-F
<b>Film</b>	Smallest diameter ( in either CC or oblique view)	_____ mm	MM03-F

● Shape of mass

<b>Film</b>	0	1	2	3	4	5	6	7	8	9	10	MM04-F
	round/oval			lobular				irregular				
<b>Stereo</b>	0	1	2	3	4	5	6	7	8	9	10	MM04-S

<b>Film</b>	0	1	2	3	4	5	6	7	8	9	10	MM05-F
	planar, disk-like					ovoid, spherical						
<b>Stereo</b>	0	1	2	3	4	5	6	7	8	9	10	MM05-S



**Mass (MM) - cont.**

**If there are associated calcifications:**

- Confidence that at least some are internal to the mass

<b>Film</b>	0	1	2	3	4	5	6	7	8	9	10	MM11-F
	Definitely NONE internal					definitely some internal						
<b>Stereo</b>	0	1	2	3	4	5	6	7	8	9	10	MM11-S

- Number of calcification elements inside the mass

<b>Film</b>	<input type="radio"/>	<input type="radio"/>	<input type="radio"/>	<input type="radio"/>	<input type="radio"/>	MM12-F
	0	1 to 3	4 to 6	7 to 10	more than 10	
<b>Stereo</b>	<input type="radio"/>	<input type="radio"/>	<input type="radio"/>	<input type="radio"/>	<input type="radio"/>	MM12-S

- Confidence that at least some are external to the mass

<b>Film</b>	0	1	2	3	4	5	6	7	8	9	10	MM13-F
	definitely NONE external					definitely some external						
<b>Stereo</b>	0	1	2	3	4	5	6	7	8	9	10	MM13-S

Reader: \_\_\_\_\_

Case No. \_\_\_\_\_

Verified Finding No. \_\_\_\_\_

## Calcification Cluster (CC)

- Confidence regarding the presence of worrisome calcifications

<b>Film</b>	0	1	2	3	4	5	6	7	8	9	10	
	definitely NOT present										definitely present	CC01-F
<b>Stereo</b>	0	1	2	3	4	5	6	7	8	9	10	CC01-S

### Element Characteristics

- Size of largest individual element (best visual estimate)

<b>Film</b>	○	○	○	
	less than 0.5 mm	0.5 mm to 1.0 mm	more than 1.0 mm	CC02-F

- Variability of size of elements

<b>Film</b>	0	1	2	3	4	5	6	7	8	9	10	
	low variability of size										high variability of size	CC03-F
<b>Stereo</b>	0	1	2	3	4	5	6	7	8	9	10	CC03-S

**Calcification Cluster (CC) - cont.**

- Degree to which the elements can be characterized as fine linear

<b>Film</b>	0	1	2	3	4	5	6	7	8	9	10	CC04-F	
	definitely NONE of the elements are fine linear								at least one or two elements definitely are, or several probably are, fine linear				
<b>Stereo</b>	0	1	2	3	4	5	6	7	8	9	10	CC04-S	

- Degree to which the elements can be characterized as branching

<b>Film</b>	0	1	2	3	4	5	6	7	8	9	10	CC05-F	
	definitely NONE of the elements are branching								at least one or two elements definitely are, or several probably are, branching				
<b>Stereo</b>	0	1	2	3	4	5	6	7	8	9	10	CC05-S	

- Degree to which the elements can be characterized as pleomorphic (heterogeneous)

<b>Film</b>	0	1	2	3	4	5	6	7	8	9	10	CC06-F	
	definitely NONE of the elements are pleomorphic (heterogeneous)								at least one or two elements definitely are, or several probably are, pleomorphic (heterogeneous)				
<b>Stereo</b>	0	1	2	3	4	5	6	7	8	9	10	CC06-S	

- Degree to which the elements can be characterized as punctate

<b>Film</b>	0	1	2	3	4	5	6	7	8	9	10	CC07-F	
	definitely NONE of the elements are punctate								at least one or two elements definitely are, or several probably are, punctate				
<b>Stereo</b>	0	1	2	3	4	5	6	7	8	9	10	CC07-S	

**Calcification Cluster (CC) - cont.****Distribution Characteristics**

## ● Number of elements

<b>Film</b>	<input type="radio"/>	<input type="radio"/>	<input type="radio"/>	<input type="radio"/>	CC08-F
	1 to 3	4 to 6	7 to 10	more than 10	
<b>Stereo</b>	<input type="radio"/>	<input type="radio"/>	<input type="radio"/>	<input type="radio"/>	CC08-S

## ● Size of the focal distribution

**Film:** Largest dimension in CC view \_\_\_\_\_ mm CC09-F

## ● Degree to which the elements are distributed uniformly in the volume

<b>Film</b>	0	1	2	3	4	5	6	7	8	9	10	CC10-F
	very irregular distribution									very uniform distribution		
<b>Stereo</b>	0	1	2	3	4	5	6	7	8	9	10	CC10-S

## ● Degree to which the distribution can be characterized as segmental

<b>Film</b>	0	1	2	3	4	5	6	7	8	9	10	CC11-F
	definitely NOT segmental									definitely segmental		
<b>Stereo</b>	0	1	2	3	4	5	6	7	8	9	10	CC11-S

**Calcification Cluster (CC) - cont.****Relationship to Other Aspects of This Study**

- Confidence regarding presence of related architectural distortion

<b>Film</b>	0	1	2	3	4	5	6	7	8	9	10	CC12-F
	definitely NOT present										definitely present	
<b>Stereo</b>	0	1	2	3	4	5	6	7	8	9	10	CC12-S

- Confidence regarding presence of related mass

<b>Film</b>	0	1	2	3	4	5	6	7	8	9	10	CC13-F
	definitely NOT present										definitely present	
<b>Stereo</b>	0	1	2	3	4	5	6	7	8	9	10	CC13-S

## Architectural Distortion (AD)

- Confidence that the architectural distortion is related to prior surgery

<b>Film</b>	0	1	2	3	4	5	6	7	8	9	10	AD01-F
	definitely NOT related to prior surgery											
						definitely related to prior surgery						
<b>Stereo</b>	0	1	2	3	4	5	6	7	8	9	10	AD01-S

- Number of lines that appear to converge to a common point

<b>Film</b>	○		○		○		○		○		AD02-F
	0		2		3		4		5 or more		
<b>Stereo</b>	○		○		○		○		○		AD02-S

- Confidence that the lines do converge to a common point

<b>Film</b>	0	1	2	3	4	5	6	7	8	9	10	AD03-F
	definitely do NOT converge											
						definitely do converge						
<b>Stereo</b>	0	1	2	3	4	5	6	7	8	9	10	AD03-S

- Confidence regarding the presence of related worrisome calcifications

<b>Film</b>	0	1	2	3	4	5	6	7	8	9	10	AD04-F
	definitely NOT present											
						definitely present						
<b>Stereo</b>	0	1	2	3	4	5	6	7	8	9	10	AD04-S

- Confidence regarding the presence of a related mass

<b>Film</b>	0	1	2	3	4	5	6	7	8	9	10	AD05-F
	definitely NOT present											
						definitely present						
<b>Stereo</b>	0	1	2	3	4	5	6	7	8	9	10	AD05-S



**Stereo-detected Findings (use overview as well as magnified view)**

- **Number of additional findings detected on stereo (not visible on films)**

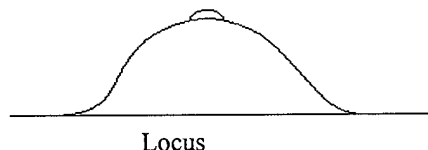
0            1            2            3            4            5            NF1

- **Appearance on stereo of additional findings detected on stereo (not visible on films)**

Stereo-detected finding 1

SD1

- Mass
- Calcifications
- Architectural Distortion



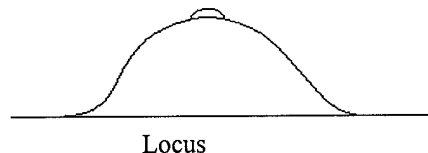
Description: \_\_\_\_\_  
 \_\_\_\_\_

SD2

Stereo-detected finding 2

SD3

- Mass
- Calcifications
- Architectural Distortion



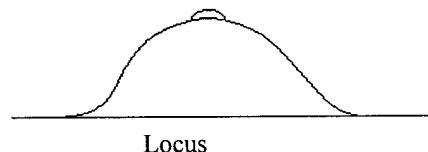
Description: \_\_\_\_\_  
 \_\_\_\_\_

SD4

Stereo-detected finding 2

SD5

- Mass
- Calcifications
- Architectural Distortion



Description: \_\_\_\_\_  
 \_\_\_\_\_

SD6

## Response Form--X-Ray Mammography (Stereo Study)

Reader: \_\_\_\_\_

Case No. \_\_\_\_\_

● **Appearance on films of tissue - verified findings**

Verified finding 1

VF1

- Mass
- Calcifications
- Architectural Distortion

Verified finding 2

VF2

- Mass
- Calcifications
- Architectural Distortion





**Stereo-detected Additional Presentation of Verified Finding**

Verified finding 1

SD01

- Mass
- Calcifications
- Architectural Distortion

Verified finding 2

SD02

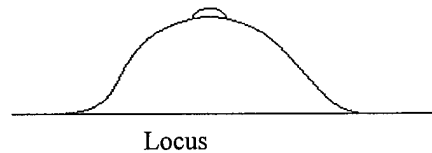
- Mass
- Calcifications
- Architectural Distortion

**Stereo-detected Additional Findings (use overview as well as magnified view)**

Stereo-detected finding 1

SD03

- Mass
- Calcifications
- Architectural Distortion



Description: \_\_\_\_\_

SD04

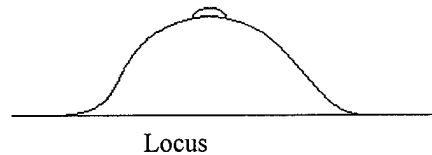
\_\_\_\_\_

SD05

Stereo-detected finding 2

SD06

- Mass
- Calcifications
- Architectural Distortion



Description: \_\_\_\_\_

SD07

\_\_\_\_\_

SD08

FORM FOR READER COMMENTS FOLLOWING THE STEREO MAMMOGRAPHY  
STUDY APRIL-MAY, 2000

Aims of this debriefing: 1) to help us better understand the findings and limitations of the present study; and 2) to help us think better about how stereo mammography might best be employed in a clinical setting.

- 1) In what ways do you think stereo mammography could be helpful in determining whether a detected lesion is benign or malignant? Address its possible contributions with respect to each of the three main forms of presentation, and with respect to the key discriminating aspects of each form.

Masses:

Clusters of calcifications:

Architectural distortion:

- 2) When a lesion presents in more than one form, e.g., as a mass and calcifications, how might stereo mammography help in classification with respect to revealing how the different presentations relate to each other?
- 3) Are there ways in which stereo mammography might contribute to error in classifying a lesion as benign or malignant in any one the above presentations?

- 4) In what ways do you think stereo mammography could be helpful in lesion detection? Address its possible contributions with respect to each of the three main forms of presentation.

Masses:

Clusters of calcifications:

Architectural distortion:

- 5) Are there ways in which stereo mammography might contribute to error in detection of a lesion in any one of the above presentations?
- 6) Do you have any other comments about how stereo mammography might aid or hinder mammographic detection or diagnosis of breast lesions?
- 7) Assuming that sufficiently high-resolution digital displays are available, what suggestions do you have about how stereo mammography might be best employed in clinical practice?

## **PRESENTATIONS, ABSTRACTS, AND PERSONNEL**

**Project Title:** Stereoscopic Digital Mammography: Improving Cancer Diagnosis

**Principal Investigator:** David J. Getty, Ph.D.

**Contract No.** DAMD17-96-C-6079

**Contractor:** BBN Systems and Technologies  
Now:  
BBN Technologies  
A Division of GTE Technology Organization  
10 Moulton Street  
Cambridge, MA 02138

**Subcontractor:** University of Massachusetts Medical Center  
Department of Radiology  
55 Lake Avenue, North  
Worcester, MA 01655

**Principal Investigator:** Carl J. D'Orsi, M.D.

**Term of Contract:** 17 June 1996 - 17 November 2000 (Research completed 16 June 2000)

**Date:** 14 July 2000

## MEETING PRESENTATIONS

Getty, D. J. Stereoscopic Digital Mammography: Improving Detection and Diagnosis of Breast Cancer. Invited presentation at the *Federal Technology Transfer Workshop on Breast Cancer Detection, Diagnosis and Treatment*, Washington, DC, May 1-2, 1997.

Getty, D. J. Stereoscopic Digital Mammography: Improving Diagnostic Accuracy. Invited platform speaker at the *Era of Hope*, Department of Defense Breast Cancer Research Meeting, Washington, DC, October 31 – November 4, 1997.

Getty, D. J. Invited participant in the *Working Group on Digital Mammography*, Bethesda, MD, March 9-10, 1998.

Getty, D. J. Stereoscopic Digital Mammography: What Can You See in a Stereo View of the Breast That You Can't See in Two Standard Orthogonal 2D Films? *Eighth Far West Medical Image Perception Conference*, Alberta, Canada, May 28-30, 1999.

Getty, D.J. Stereoscopic Digital Mammography: Improving Detection and Diagnosis of Breast Cancer. Invited platform speaker at the *Era of Hope*, Department of Defense Breast Cancer Research Meeting, Atlanta, GA, June 8-11, 2000.

## PATENTS

### Stereo Radiography

Inventors: David J. Getty, A.W.F. Huggins

Patent Number 6,031,565, issued February 29, 2000.

## MEETING ABSTRACTS

Following are the extended abstracts presented with a poster at:

*Era of Hope*, Department of Defense Breast Cancer Research Meeting, Washington, DC, October 31 – November 4, 1997.

*Era of Hope*, Department of Defense Breast Cancer Research Meeting, Atlanta, GA, June 8-11, 2000.

October, 1997

**STEREOSCOPIC DIGITAL MAMMOGRAPHY:  
IMPROVING DIAGNOSTIC ACCURACY**

**Dr. David J. Getty, Dr. Ronald M. Pickett, Dr. John A. Swets,  
Dr. Carl J. D'Orsi\*, and Dr. Andrew Karellas\***

BBN Corporation, Cambridge, MA 02138

\*University of Massachusetts Medical Center, Worcester, MA 01655

We hypothesize that stereoscopic viewing of the internal structure of the breast in depth can lead to substantial improvements in the ability to detect subtle breast lesions and, once detected, to substantial improvements in the ability to correctly distinguish malignant from benign lesions. Moreover, we believe that stereo viewing may lead to new insights about the three-dimensional structure of breast lesions and how they develop. The primary aims of this project are to further develop a prototype system using state-of-the-art methods for capturing and displaying stereo mammograms, and then to evaluate the improvement in the diagnosis of breast cancer resulting from stereoscopic viewing compared to standard, non-stereoscopic viewing.

Many of the problems and limitations with standard mammography arise from the fact that the radiologist must construct a mental image of the three-dimensional internal structure within the breast from a pair of two-dimensional x-ray images, usually taken at right angles to one another. The difficult problem for the radiologist is to integrate the information across the two views and, from that, to imagine the implied three-dimensional structure. With stereo mammography, the radiologist can directly see the internal three-dimensional structure of the breast, without having to construct it in his/her mind from a pair of two-dimensional views. Tissue lying at different depth planes that is confusingly superimposed in a two-dimensional view becomes clearly separated in depth in a stereoscopic view, and true lesions appears as compact objects in the breast volume, making them easier to detect and easier to interpret.

**Keywords: Stereoscopic Mammography, Digital Mammography, Increased Diagnostic Accuracy, Stereoscopic Display, CCD Digital Camera**

This work was supported by the U.S. Army Medical Research and Materiel Command under DAMD 17-96-C-6079.

Together with colleagues at the University of Massachusetts Medical Center, we have developed a prototype stereo mammography system which consists of two parts—the first which acquires stereo digital images, the second which displays them. A stereo mammogram consists of two x-ray images of the breast taken from slightly different points of view. A state-of-the-art CCD camera captures each x-ray of the breast as a direct-digital image which is stored as a data file on a computer. To view the stereo image, a radiologist, equipped with special LCD glasses, views the two images on a computer workstation display that rapidly and alternately presents each x-ray image to only one eye. What the radiologist sees is a single in-depth image of the breast.

Over the next three years, we will acquire stereo mammograms of the intact breast from about 300 women patients scheduled for biopsy of a focal breast lesion. Using these path-proven stereo mammograms, we will seek to develop an understanding of new stereo-based visual features of focal benign and malignant lesions, and of normal breast tissue. We will carry out reading studies to compare the diagnostic accuracy achievable with: (1) standard films, (2) non-stereo viewing of the digital images plus standard films, and (3) stereo viewing of the digital images plus standard films.

In the early months of the project, we have worked on developing software for the stereo display workstation. This software permits the radiologist to control many aspects of the displayed stereo image, including brightness and contrast, black/white reversal, depth inversion, and control over the position of a three-dimensional cursor. We have determined that many of these controls are essential to achieve an optimal stereo image. We are presently incorporating speech-recognition technology into the system to give the radiologist no-hands control over many aspects of the display using spoken commands, without having to look away from the stereo image.

We have also conducted a preliminary reading study comparing stereo and non-stereo viewing of radiographs of 27 breast biopsy specimens for which we have complete stereo and non-stereo image sets as well as pathologic proof. A single expert mammography reader rated the probability of malignancy after reading the images for each case, under three different conditions. Diagnostic accuracy, measured by the ROC area index,  $A_z$ , had a value of .73 when the reader viewed the two standard, non-stereo localization films. Adding a non-stereo radiograph of the excised specimen did not improve accuracy. But, adding a stereo view of the excised specimen raised diagnostic accuracy to .94. Because this result is based on a small sample of cases, read by only a single expert mammographer, it should be regarded only as suggestive of the promise of this technique.

We are excited by the possibility that stereo mammography may improve substantially our ability to detect and diagnose subtle breast cancer. This project, using state-of-the-art methods to capture and display stereo mammograms, will enable us to evaluate this potential.

June, 2000

## USE OF STEREOSCOPIC DIGITAL MAMMOGRAPHY TO IMPROVE EARLY DETECTION AND DIAGNOSIS OF BREAST LESIONS

**Dr. David J. Getty, Dr. Ronald M. Pickett, Dr. John A. Swets,  
Dr. Carl J. D'Orsi\*, and Dr. Andrew Karellas\***

BBN Technologies, Cambridge, MA 02138

\*University of Massachusetts Medical Center, Worcester, MA 01655

david.getty@bbn.com

The goal of this project is to assess the benefits of stereoscopic mammography over the current standard two-dimensional approach to detection and diagnosis of breast cancer. In the standard approach, the radiologist views separately two orthogonal images, and has to construct what can only be a rather crude mental image of the breast's three-dimensional internal structure. With stereo mammography, the radiologist views two digital x-ray images of the breast taken from slightly different points of view and, wearing special stereo-viewing glasses, sees directly a fused, in-depth image of the internal structure of the breast in rich veridical detail. Tissue lying at different depth planes, confusingly superimposed in the standard mammogram, becomes clearly separated in depth in the stereoscopic view, and true lesions appear as 3-D objects in the breast volume, making them easier both to detect and to diagnose.

Our approach in this project is to refine a system we've developed for capturing and viewing stereo mammograms, using state-of-the-art methods, and then to evaluate the improvement in the diagnosis of breast cancer resulting from stereo viewing compared to standard, non-stereo viewing. Stereo mammograms are acquired using the new GE full-field-of-view digital mammography unit, with the two views offset by 6 degrees. The stereo images are viewed on a workstation equipped with a high-resolution monitor and special image manipulation software.

Results from a preliminary study using 76 path-proven cases indicate that stereo mammograms (in addition to the standard films) lead to significantly *more accurate diagnosis* of detected breast lesions compared to films alone. Of perhaps greater significance, is the suggestion of *improved detection*. Additional, worrisome lesions (architectural distortions or masses) were detected in the stereo mammograms of 5 cases that were not seen on the standard films. A much larger reading study will be completed prior to the end of this project. This research is important in that stereo mammography holds the promise of leading to substantial improvements over standard mammography in the early detection and diagnosis of breast cancer.

The U.S. Army Medical Research and Materiel Command under DAMD 17-96-C-6079 supported this work.

Together with colleagues at the University of Massachusetts Medical Center, we have developed a prototype stereo mammography system which consists of two parts—the first which acquires stereo digital images, the second which displays them. A stereo mammogram consists of two x-ray images of the breast taken from slightly different points of view. A state-of-the-art CCD camera captures each x-ray of the breast as a direct-digital image which is stored as a data file on a computer. To view the stereo image, a radiologist, equipped with special LCD glasses, views the two images on a computer workstation display that rapidly and alternately presents each x-ray image to only one eye. What the radiologist sees is a single in-depth image of the breast.

Over the next three years, we will acquire stereo mammograms of the intact breast from about 300 women patients scheduled for biopsy of a focal breast lesion. Using these path-proven stereo mammograms, we will seek to develop an understanding of new stereo-based visual features of focal benign and malignant lesions, and of normal breast tissue. We will carry out reading studies to compare the diagnostic accuracy achievable with: (1) standard films, (2) non-stereo viewing of the digital images plus standard films, and (3) stereo viewing of the digital images plus standard films.

In the early months of the project, we have worked on developing software for the stereo display workstation. This software permits the radiologist to control many aspects of the displayed stereo image, including brightness and contrast, black/white reversal, depth inversion, and control over the position of a three-dimensional cursor. We have determined that many of these controls are essential to achieve an optimal stereo image. We are presently incorporating speech-recognition technology into the system to give the radiologist no-hands control over many aspects of the display using spoken commands, without having to look away from the stereo image.

We have also conducted a preliminary reading study comparing stereo and non-stereo viewing of radiographs of 27 breast biopsy specimens for which we have complete stereo and non-stereo image sets as well as pathologic proof. A single expert mammography reader rated the probability of malignancy after reading the images for each case, under three different conditions. Diagnostic accuracy, measured by the ROC area index,  $A_z$ , had a value of .73 when the reader viewed the two standard, non-stereo localization films. Adding a non-stereo radiograph of the excised specimen did not improve accuracy. But, adding a stereo view of the excised specimen raised diagnostic accuracy to .94. Because this result is based on a small sample of cases, read by only a single expert mammographer, it should be regarded only as suggestive of the promise of this technique.

We are excited by the possibility that stereo mammography may improve substantially our ability to detect and diagnose subtle breast cancer. This project, using state-of-the-art methods to capture and display stereo mammograms, will enable us to evaluate this potential.

PROJECT STAFF

David J. Getty (P.I.), Ph.D.  
Ronald M. Pickett, Ph.D.  
John A. Swets, Ph.D.  
Barbara Freeman, BA  
Carl J. D'Orsi, M.D.  
Andrew Karellas, Ph.D.

BBN Technologies  
BBN Technologies  
BBN Technologies  
BBN Technologies  
University of Massachusetts Medical Center  
University of Massachusetts Medical Center

MAMMOGRAPHY CONSULTANTS

Jack Meyer, M.D.  
Norman Sadowsky, M.D.

Brigham and Women's Hospital  
Faulkner Hospital

MAMMOGRAPHY READERS

Jack Meyer, M.D.  
Phyllis Kornguth, M.D., Ph.D.  
Norman Sadowsky, M.D.  
Elsie Levin, M.D.  
Larry Moss, M.D.  
Luis Diaz, M.D.

Brigham and Women's Hospital  
Brigham and Women's Hospital  
Faulkner Hospital  
Faulkner Hospital  
University of Massachusetts Medical Center  
University of Massachusetts Medical Center