

AD _____

AWARD NUMBER: DAMD17-97-1-7144**TITLE:** Tomosynthesis Breast Imaging:
Early Detection and Characterization of Breast Cancer**PRINCIPAL INVESTIGATOR:** Leena M. Hamberg, PhD**CONTRACTING ORGANIZATION:** Massachusetts General Hospital
Boston, Massachusetts 02114**REPORT DATE:** July 2000**TYPE OF REPORT:** Final**PREPARED FOR:** U.S. Army Medical Research and Materiel Command
Fort Detrick, Maryland 21702-5012**DISTRIBUTION STATEMENT:** Approved for public release; distribution unlimited

The views, opinions and/or findings contained in this report are those of the authors and should not be construed as an official Department of the Army position, policy or decision unless so designated by other documentation.

20010327 044

REPORT DOCUMENTATION PAGEForm Approved
OMB No. 074-0188

Public reporting burden for this collection of information is estimated to average 1 hour per response, including the time for reviewing instructions, searching existing data sources, gathering and maintaining the data needed, and completing and reviewing this collection of information. Send comments regarding this burden estimate or any other aspect of this collection of information, including suggestions for reducing this burden to Washington Headquarters Services, Directorate for Information Operations and Reports, 1215 Jefferson Davis Highway, Suite 1204, Arlington, VA 22202-4302, and to the Office of Management and Budget, Paperwork Reduction Project (0704-0188), Washington, DC 20503

1. AGENCY USE ONLY (Leave blank)**2. REPORT DATE**

July 2000

3. REPORT TYPE AND DATES COVERED

Final (1 Jul 97 - 30 Jun 00)

4. TITLE AND SUBTITLE

Tomosynthesis Breast Imaging: Early Detection and Characterization of Breast Cancer

5. FUNDING NUMBERS

DAMD17-97-1-7144

6. AUTHOR(S)

Leena Hamberg, Ph.D.

7. PERFORMING ORGANIZATION NAME(S) AND ADDRESS(ES)Massachusetts General Hospital
Boston, Massachusetts 02114**8. PERFORMING ORGANIZATION
REPORT NUMBER****E-MAIL:**

LHAMBERG@PARTNERS.ORG

9. SPONSORING / MONITORING AGENCY NAME(S) AND ADDRESS(ES)U.S. Army Medical Research and Materiel Command
Fort Detrick, Maryland 21702-5012**10. SPONSORING / MONITORING
AGENCY REPORT NUMBER****11. SUPPLEMENTARY NOTES****12a. DISTRIBUTION / AVAILABILITY STATEMENT**

Approved for public release; distribution unlimited

12b. DISTRIBUTION CODE**13. ABSTRACT (Maximum 200 Words)**

A digital tomosynthesis mammography method was developed with which to obtain tomographic images of the breast by acquiring a series of low radiation dose images as the x-ray tube moves in an arc above the breast. Reconstruction algorithms were developed and implemented for rapid reconstruction of breast tomograms. A tomosynthesis study producing tomograms through the whole breast can be performed with a total dose that is equivalent to one conventional mammogram. The optimum number of views is seven to nine and optimum tomographic angle 30 to 40 degrees. MTF or spatial resolution for tomosynthesis was similar to that of 2 dimensional images and SNR is approximately equal to conventional mammograms even with equivalent total radiation dose. A reader study using the developed complex background phantom indicate improved lesion detection with tomosynthesis, for both round and spiculated masses, a mastectomy specimen reader study showed that the lesion margins can be better assessed with tomosynthesis as compared to film-screen mammography.

14. SUBJECT TERMS

Breast Cancer

15. NUMBER OF PAGES

20

16. PRICE CODE**17. SECURITY CLASSIFICATION
OF REPORT**

Unclassified

**18. SECURITY CLASSIFICATION
OF THIS PAGE**

Unclassified

**19. SECURITY CLASSIFICATION
OF ABSTRACT**

Unclassified

20. LIMITATION OF ABSTRACT

Unlimited

NSN 7540-01-280-5500

Standard Form 298 (Rev. 2-89)
Prescribed by ANSI Std. Z39-18
298-102

TABLE OF CONTENTS

A. INTRODUCTION

BODY

B. METHODS AND RESULTS

TASK 1.

B.1. IMAGE RECONSTRUCTION ALGORITHM

B.1.1 Shift and Add Algorithm

B.1.2. Backprojection Algorithm

TASK 2.

B.2. RADIATION DOSE

B.3. TOMOGRAPHIC ANGLE, NUMBER OF VIEWS AND SLICE THICKNESS

B.4. TOMOSYNTHESIS IMAGE QUALITY

B.4.1. Spatial Resolution of a Tomosynthetic Mammographic Image

B.4.2. Signal-to-Noise Ratio (SNR) in a Tomosynthetic Mammographic Image

TASK 3.

B.5. PHANTOM DEVELOPMENT

B.5.1. Wire Phantom

B.5.2. Complex background phantom

TASK 4 AND 5.

B.6. LESION DETECTION WITH DIGITAL TOMOSYNTHESIS

TASK 6 AND 7.

B.7. MASTECTOMY SPECIMEN STUDY

C. KEY RESEARCH ACCOMPLISHMENTS

D. REPORTABLE OUTCOMES

E. CONCLUSIONS

F. REFERENCES

G. LIST OF PERSONNEL

FINAL REPORT

TOMOSYNTHESIS BREAST IMAGING: EARLY DETECTION AND CHARACTERIZATION OF BREAST CANCER (DAMD-97-1-7144)

The goal of this work was to implement a digital tomosynthesis imaging method for detection of breast cancer. Our objectives were to optimize tomosynthesis data acquisition and image reconstruction and to develop a complex phantom for a reader detection study and to perform an image quality study by using mastectomy specimens. In summary our results demonstrate that digital tomosynthesis provides a series of tomograms at selected intervals through a breast imaged. This is achieved by reconstructing focal planes at various depths from 9 low dose views, each acquired with 1/9 of the dose of a single mammogram, along an arc corresponding to a 40 degree total angle. Our phantom studies demonstrated that MTF or spatial resolution of tomosynthetic images is similar to that of 2-dimensional mammography and that the SNR is the highest around the focal tomosynthesis plane and it is higher in a tomosynthesis image than in a 2-dimensional image. In a reader study performed with a specially developed complex background phantom it was demonstrated that the detection of round and spiculated mass targets improves substantially by performing a digital tomosynthesis study. In a mastectomy specimen study it was demonstrated that the image quality was improved as compared to film/screen and two dimensional images and some new probable masses were seen. This implies that tomosynthesis has potential to increase the sensitivity of breast cancer detection especially in dense breasts.

A. INTRODUCTION

Mammography is currently the best method of detecting early stage breast cancer. However some cancers are missed on mammography screening mainly due to the complex background of normal, radiographically dense fibroglandular breast structures which may mask the presence of a breast cancer [1-11]. In our study we have implemented a new mammographic imaging method, digital tomosynthesis, in order to "see through" the dense breast tissues and thus to improve the detectability of a breast lesion. Digital tomosynthesis of a breast is a digital imaging technique used to calculate tomosynthetic images from a set of digital images (views) that are acquired at different positions around an object as the X-ray source is moved in an arc while the object and the detector are stationary. Any plane of the imaged object can be brought into sharp focus while structures outside the selected focal plane are blurred [12].

We implemented a tomosynthesis technique on a full-field digital mammography unit, which has high detective quantum efficiency (higher than film screen systems), low noise and large detector area with rapid readout times (300 msec). The system components are presented in Figure 1.

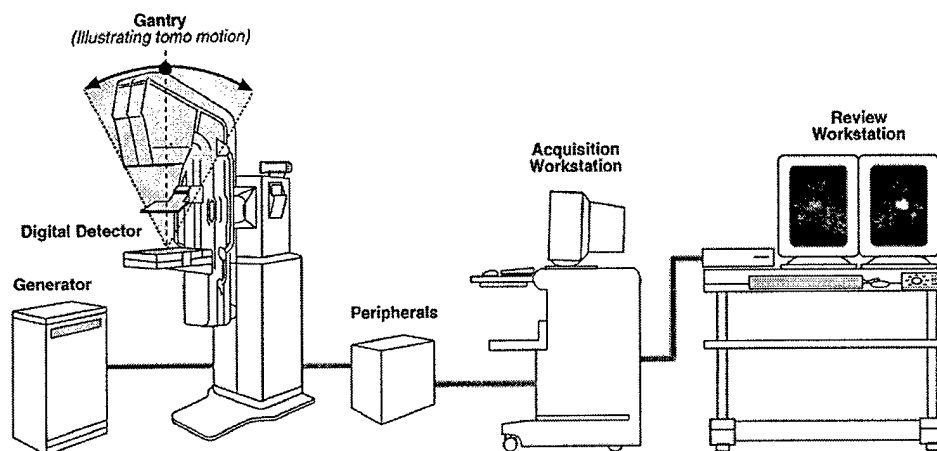


Figure 1. A graphical presentation of the digital tomosynthesis system used in the study. The x-ray source can move in an arc above the full size digital detector plate. During each exposure the x-ray tube is stationary moving to the next position between exposures. 9 views are usually acquired at 9 exposure positions within a 40° arc. Any plane parallel to the detector can be reconstructed from these data.

(Courtesy of Jeff Eberhard, GE Medical Systems)

The digital detector plate is composed of a Cesium Iodide (CsI) phosphor in direct contact with an amorphous silicon photodiode/transistor array (see Figure 2). The columnar structure of CsI phosphor directs the light produced in each x-ray interaction with the scintillator toward the silicon detector with very little lateral diffusion yielding high spatial resolution. The spatial resolution measured by the modulation transfer function (MTF) out to the Nyquist frequency (5 lp/mm for 100 μ m pixel pitch) is similar to that of the highest resolution presently achievable with mammography films. Advantages of using digital detector technology in general include high detective quantum efficiency (DQE) and no need for processors and dark rooms and fast image acquisition speed. When digital detector technology is combined with a tomo-drive fast data acquisition at various locations corresponding to different angles above the object, or a breast, can be achieved. The acquired images are then further reconstructed to a set of

tomosynthesis images (thin planes parallel to the detector) through the whole object making it possible to see structures more clearly at different depths within the object as compared to a conventional 2-dimensional shadowgram.

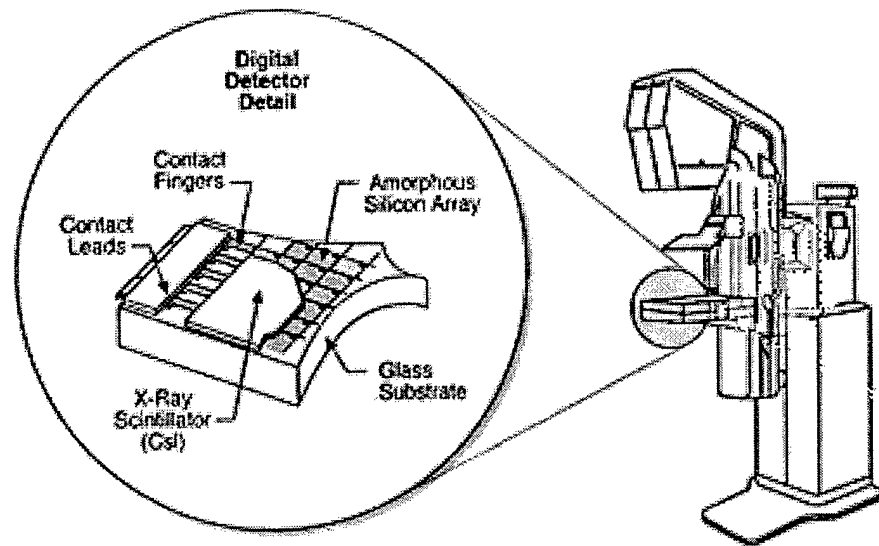


Figure 2. A digital detector is composed of a Cesium Iodide (CsI) phosphor in direct contact with an amorphous silicon photodiode/transistor array. The columnar structure of CsI phosphor directs the light produced in each x-ray interaction with the scintillator toward the silicon detector with very little lateral diffusion yielding a high spatial resolution. The spatial resolution measured by the modulation transfer function (MTF) out to the Nyquist frequency (5 lp/mm for 100um pixel pitch) is similar to that of the highest resolution presently achievable with mammography films. (Courtesy of Jeff Eberhard, GE Medical Systems)

The tomosynthesis images are digitally reconstructed from a number of 2-dimensional projection images acquired by moving an X-ray tube in an arc above the object. Thus a final tomosynthesis image is a calculated image, which is reconstructed from many projection images, presenting structures within a thin slice in focus while the structures above and below the focal plane are blurred.

The goals of this grant were 1) to optimize image reconstruction algorithms, 2) to optimize imaging parameters, including tomographic angle and required number of images, 3) to develop a complex background phantom, 4) to obtain phantom images and 5) to perform a phantom reader study as well as 6) to obtain breast specimen images and 7) to investigate specimen image quality through a specimen reader study.

BODY

B. METHODS AND RESULTS

The system we used utilized a full-field digital flat-panel mammography system that has low noise and a 300msec image readout time. Images were obtained by manually moving the tube in an arc above the object and a precision inclinometer was used to determine the position. The system has now been updated and a motor installed providing automated x-ray tube movement making the process of data acquisition faster and more accurate for the clinical studies. In this study our experimental approach was to use phantoms and mastectomy specimens to optimize the data acquisition methods and to investigate the tomosynthesis image quality and lesion detection capabilities of digital tomosynthesis.

TASK 1.

B.1. IMAGE RECONSTRUCTION ALGORITHM

B.1.1 Shift and Add Algorithm

The early approach to tomosynthesis was analogue. Miller et. al. reported laminagraphy in 1971 whereby various levels of the imaged object were 'reconstructed' by serially photographing into a single image the shifted or moved radiographs that were acquired at various angles around the object [13]. This kind of approach is called shift and add approach. This was the first approach we took in our studies to reconstruct the tomograms from the digital images by computer. The amount of shift determines what level of the object is in focus in a reconstructed image. This early approach used a MATLAB algorithm and could be used only on a system that had MATLAB running on that system. Using the MATLAB based reconstruction algorithm the reconstruction of one tomosynthetic image took about one minute.

B.1.2. Backprojection Algorithm

In the second phase of the study we implemented a backprojection algorithm for tomosynthesis image reconstruction using the C⁺⁺-programming language. This renders the implemented tomosynthesis image reconstruction algorithm easily applicable to various computer systems. Currently, reconstruction of one tomosynthetic image with a matrix size of 2304*1800 takes about 20 seconds. In order to speed up the reconstruction

process we implemented our algorithm so as to allow the user to reconstruct varying size regions of interest within the field of view or within the detector area by selecting the location of the region of interest. Moreover the gridsize, i.e. the output image matrix size, is implemented as an input parameter making reconstructions with varying matrices possible. The range of tomosynthesis image levels can be determined as well. The next stage will be an implementation of a filtered backprojection approach by investigating the impact of various filters on the image quality and features.

TASK 2.

B.2. RADIATION DOSE

Tomosynthesis involves acquiring a number of low dose images. For example if a data acquisition of 9 views is performed, each of these 9 images are acquired by using a 1/9 of the dose of one normal mammogram. Within each of these low dose images electronic noise is a substantial fraction of the total noise within the image and thus the system noise or electronic noise in the detector and read-out electronics is critical. Our results of phantom and mastectomy studies indicate that high quality tomosynthesis images can be obtained by using a total dose that is equivalent to the dose used for a normal mammogram. The determination of the technique factors (kV and mAs) in our specimen study was indeed done by first taking an auto-timed mammogram with a normal film-screen system using a Mo-Mo target-filter combination and then converting these technique factors to equivalent factors for the Rh-Rh target-filter combination and these were used for the tomosynthesis data acquisition.

B.3. TOMOGRAPHIC ANGLE, NUMBER OF VIEWS AND SLICE THICKNESS

The total tomographic angle or the total arc which is used for the x-ray tube motion in tomosynthesis data acquisition will affect image quality. The thickness of the "in-focus" or tomosynthesis plane in the direction perpendicular to the detector is inversely related to the total angle used. We measured the in-focus, tomographic, slice thickness using the "wire" phantom we developed. The phantom contains two fine wires (20 micron thick), one at a 7 and the other at a 60 degree angle relative to the phantom base. The total angle used to acquire the tomographic views ranged from 8° to 40° and the corresponding slice thicknesses ranged from 2.8mm to 0.9mm. In other words, as the tomographic angle increased the slice thickness decreased. In our complex phantom reader study and

mastectomy specimen study we used a 40° total angle providing a 0.9mm tomosynthesis slice thickness and the tomosynthetic slices reconstructed were at 1mm intervals covering the whole object.

B.4. TOMOSYNTHESIS IMAGE QUALITY

To characterize the tomosynthesis image quality we designed and manufactured a "wire" phantom. This phantom includes two angled wires (7° and 60°) for the determination of the modulation transfer function (MTF) for the system. From the MTF the spatial resolution in a tomosynthetic image can be obtained. In addition, the wire phantom can be used for estimating the tomosynthetic slice thickness, which changes as a function of the extent of the arc the projection images are acquired. An alternate, visual manner for the spatial resolution determination is provided by a line pair pattern embedded at a 25mm depth in the 230mm*180mm*50mm (Length*Width*Height) block of BR12 material.

B.4.1. Spatial Resolution of a Tomosynthetic Mammographic Image

We studied the spatial resolution in a tomosynthetic image as a function of the number of views, rotation angle used and as a function of dose. We imaged the wire phantom using various combinations of projections and rotation angles and mAs values per projection. From the reconstructed images we determined the line spread functions (LSF) and took a Fourier Transformation of a LSF yielding the modulation transfer function (MTF) for a tomosynthetic image. The cut-off frequency did not change significantly as a function of the rotation angle or the number of views and it was about the same as measured in 2-dimensional, projection, and digital mammograms.

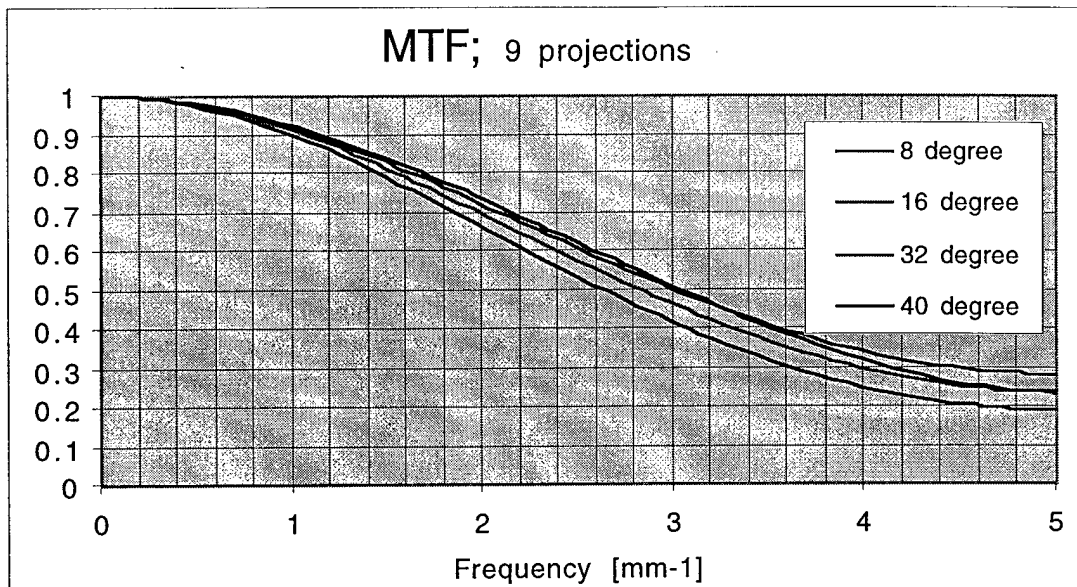


Figure 3. The graphs represent the modulation transfer functions obtained using 9 views but varying the arc of the tube rotation; i.e. the total angle. The cut-off frequency does not change significantly as a function of the angle and is about the same as measured in 2-dimensional, projection, and digital mammograms.

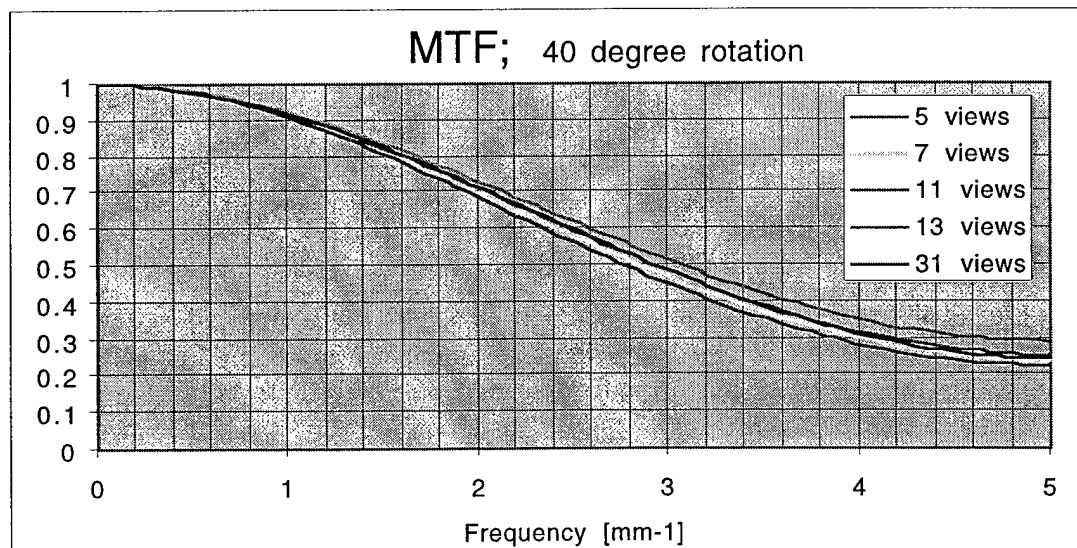


Figure 4. The graphs represent the modulation transfer functions (MTF) obtained using a 40 degree rotation angle and varying number of views. The cut-off frequency does not change significantly as the number of the projections changes.

B.4.2. Signal-to-Noise Ratio (SNR) in a Tomosynthesis Image

We characterized the SNR ratio in tomosynthesis images at an equivalent radiation dose to one normal mammogram as well as at higher doses, 1.3, 1.5 and 2 times the dose of a normal mammogram. The number of projection views and the angle of the rotation were kept constant for these measurements. The SNR was measured as a function of the slice location and the entrance dose. These measurements demonstrated that SNR was the highest around the focal plane (515mm in this case) and decreased as the slice location moved away from the focal plane. In addition, the SNR increased with increasing dose. However, even the lowest dose SNR in a tomosynthesis image is equal to a conventional mammogram obtained using an equivalent dose, which indicates that electronic noise is low. The experiment was done by using a uniform phantom. Tomosynthesis will improve the SNR as compared to conventional imaging when a complex phantom is used. This improvement is demonstrated in Section B.6.

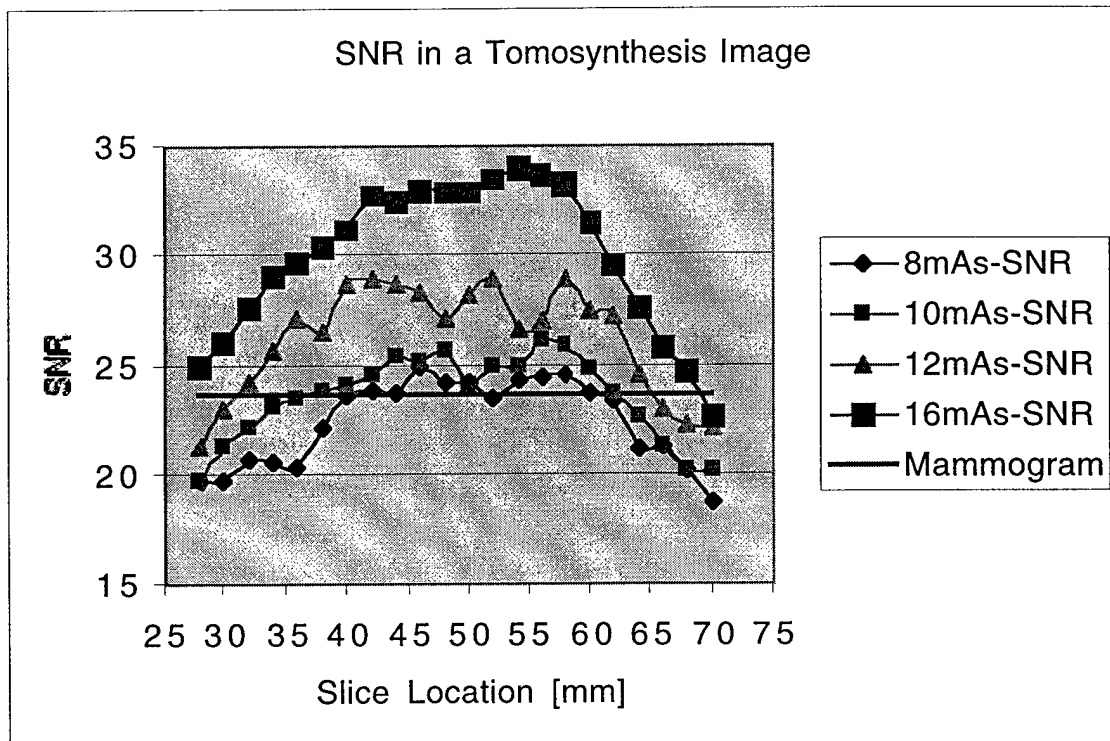


Figure 5. A presentation of the signal to noise ratio (SNR) for a 300 micron thick calcification. The SNR was measured as a function of the slice location and as a function of the entrance dose. It can be seen that SNR is highest around the focal plane (51.5mm) and decreases as the slice location moves away from the focal plane. In addition, the SNR increases with increasing dose.

TASK 3.

B.5. PHANTOM DEVELOPMENT

B.5.1. Wire Phantom

The "wire phantom" was designed for studies measuring spatial resolution in tomosynthesis images. In addition to structures used for evaluation of tomosynthesis image blur it includes two wires, one deep and one shallow that travel 7° and 60° to the vertical direction. The wires can be used for the determination of the modulation transfer function (MTF) and spatial resolution for the tomosynthesis system. In addition the tomosynthetic slice thickness, which changes as a function of the extent of the arc that was used to acquire the projection images, can be measured with this phantom as well. An alternate, visual manner for the spatial resolution determination is provided by a line pair (2-20 lp/mm) pattern embedded at a 25mm depth in the 230mm*180mm*50mm (Length*Width*Height) block of BR12 material. In addition the phantom includes three star patterns that are embedded at known depths and can be used to determine/verify the depth of a reconstructed slice. These star patterns are composed of 4 10mm long gold wires positioned at 45 degrees with respect to each other.

B.5.2. Complex background phantom

We have designed and manufactured a complex background phantom with which to perform reader studies using a full-field digital mammography system. Two main different configurations of this phantom were constructed in collaboration with Computerized Image Reference Systems (CIRS, Norfolk, VA). The first version used signal plates that were the size of the complex background plates and within which many different targets were embedded. However, reader studies designed to compare the lesion detectability with two different imaging methods demand a large number of various type of targets, round masses, spiculated masses and calcifications. The use of a target plate with a fixed target configuration may introduce a bias to the study as the readers may learn / remember the configuration of the targets. To remove any bias we designed a new complex phantom that makes it possible to have an unpredictable, random arrangement of targets in each data acquisition.

The complex phantom is built using epoxy resin, which is breast tissue equivalent material simulating 70% glandular lobules in a 100% fat background. The formulation of each composition was optimized at energies between 15 keV and 40 keV. The ratio of glandular tissue to fat is 50%. A set of four background plates was manufactured. A

design of a signal plate includes a signal plate holder (12*10cm) with a 10*8cm empty square in the middle within which 16 small target plates (2*2.5cm) can be arranged in a random fashion. Altogether 64 signal or target plates were manufactured; 16 with varying size calcification clusters, 16 round masses with varying diameters and thicknesses, 16 spiculated masses with different diameters and thicknesses and 16 blank targets made of 50/50 material. This phantom was used for a reader detection study in order to compare the lesion detection capabilities of 2-dimensional imaging and tomosynthesis.

TASKS 4. AND 5.

B.6. LESION DETECTION WITH DIGITAL TOMOSYNTHESIS

Comparison of Film-Screen and FFDM

We compared the low contrast lesion detection in full-field digital mammography images and conventional film-screen images by using a contrast-detail phantom containing gold disks of thicknesses from 0.05 to 1.6 microns and 0.1 to 3.2 mm in diameter. Both images, digital and film-screen, were obtained using equivalent technique factors. On the digital system we assessed image lesion detection capability as a function of dose and target/filter type and acquired the images at both 50 μ m and 100 μ m pixel size. The digital images had a significantly lower ($p < 0.05$) object contrast threshold (allowed detection of thinner objects) than screen-film images for all studied techniques and target/filter combinations. Moreover, the lesion-detection using the digital system was superior to conventional screen-film system even using half of the radiation dose of that was used to acquire a conventional screen-film image.

Comparison of 2-dimensional FFDM Imaging and Tomosynthesis

By using the complex phantom (see B 3.2.2.) we performed a reader detection study and compared 2-dimensional mammograms to the tomosynthesis images. Studies of a total of 320 targets were acquired by using a 2-dimensional imaging method and a digital tomosynthesis method. The targets were calcification clusters, blank targets, round and spiculated masses with varying diameters and thicknesses. The diameters of the round and spiculated masses ranged from 0.45 cm to 1.0 cm while the thickness changed between 1.45 mm and 4 mm. Spiculations were 1.5 mm nylon fibers for the thinner (1.45 mm and 2.05 mm) and 2 mm fibers for the thicker (3.2 mm and 4.5 mm) masses. Each calcification group included 5-8 calcifications. 40 imaging studies were performed; 20 2-dimensional studies and 20 tomosynthesis studies. Each phantom set up was arranged by

randomly selecting small targets and sequentially putting them in a target holder capable of holding 16 targets. Within each set up blank target plates were included as well in a random fashion. Total thickness of the imaged phantom was 4.5cm representing an average breast thickness encountered clinically. This was accomplished by using 4 1cm thick complex background plates, 2 above and 2 underneath the 0.5cm thick signal plate.

2-dimensional images were acquired with a full, mammographic dose (30kV, 63mAs, RhRh), and tomosynthesis data was acquired by using 9 views and 1/9 of a full dose (30kV, 5.6mAs per view, 62mAs total, RhRh). Tomosynthesis images were reconstructed at 1mm intervals through the whole target plate. Images were read by one radiologist and one medical physicist. Each reader was asked to distribute a total of 12 "votes" between different target types (round mass, spiculated mass, calcification, blank) for each particular target. 12 votes were given for a particular target type if the reader was sure or totally confident about the type of target. The vote decreased when the reader's confidence decreased. For instance, if the reader was sure that a mass was located within a target location but could not distinguish whether it was round or spiculated he/she gave a vote of 6 for a round mass, 6 for a spiculated mass, 0 for calcification cluster and 0 for a blank plate.

When a score of 10 is considered as a correct reading all the calcifications were read correctly by one of the readers, and 96% by the other in the tomosynthesis images and all the calcifications were read correctly in the 2-dimensional images. In tomosynthesis images out of the 97 round masses 64% and 55% were read correctly by the two readers as only 4% were read correctly in 2-dimensional images by both of the readers. Out of 95 spiculated masses 86% and 82% were read correctly in tomosynthesis but only 1% and 0% in 2-dimensional images. ROC curves clearly demonstrate the superiority of the digital tomosynthesis over the 2-dimensional imaging in detecting round and spiculated masses while calcifications can be seen by both techniques. Figure 5 is an example of ROC curves for a detection of round and spiculated masses.

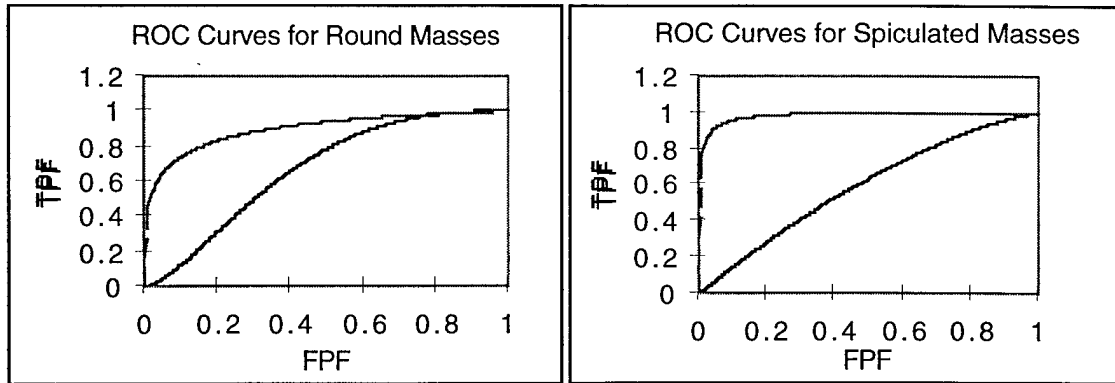


Figure 7. ROC curves for one of the readers for round and spiculated masses. The higher curve represent the reading of digital tomosynthesis images in both cases and the lower curve the reading of 2-dimensional images. It can be seen that digital tomosynthesis method substantially improved the lesion detection in this phantom study where the randomly located targets were sandwiched between complex background plates. The total thickness of the phantom was 4.5cm representing an average breast thickness encountered clinically. The visibility of the calcifications was good in both techniques.

TASKS 6. AND 7.

B.7. MASTECTOMY SPECIMEN STUDY

A mastectomy breast specimen study of 25 specimens was performed in order to compare the film-screen mammography and digital tomosynthesis in lesion and calcification detection. 23 specimens were included in the reader study. The data acquisition was performed by first obtaining a conventional film-screen image using autotiming. The technique factors used for film-screen (Mo-Mo target filter combination) were then converted to equivalent Rh-Rh technique factors as the digital tomosynthesis data were acquired using a Rh-Rh target-filter combination. The total mAs value thus obtained was evenly divided by the number of views used to acquire the tomosynthesis data leading to the total dose that was equivalent to that of normal mammogram. 9 views were acquired through a 40 degree acquisition angle. Tomosynthesis images were reconstructed at 1mm intervals using a 100 micron output matrix size and a backprojection algorithm. Images were read by mammography radiologists. In half of the studies, film-screen images were read first and tomosynthesis images were compared to film-screen images and in another half the tomosynthesis images were read first and the film-screen images were compared to the tomosynthesis images. The reader was asked to score the ability to assess the calcification edge sharpness, calcification group

visibility and group distribution as well as calcification morphology. In addition scores were given to the ability to assess lesion edge sharpness, lesion contrast and lesion morphology. The reader also answered whether more relevant information was seen with the second method and whether the second method changed the reader's understanding or diagnosis.

The results of the mastectomy specimen study clearly demonstrated that lesion detection in digital tomosynthesis images was better than in conventional mammograms. Five of the masses were better seen on tomosynthesis images than on conventional mammograms. 3 lesions were only seen on tomosynthesis images. The ability to assess the margins of a lesion or the morphology of a lesion was better for tomosynthesis images than for conventional mammograms in 11 cases. In one case the lesion was seen as well on both images and in another case film-screen demonstrated suspicious tissue that was not interpreted as suspicious on tomosynthesis images. Overall the calcifications were more easily seen in film-screen images because of the limitations of the current display system that made it necessary for the reader to zoom and pan the images in order to see small calcifications. However, in one tomosynthesis study the distribution of a calcification group was better seen on tomosynthesis images than on film-screen images.

The results of the specimen study are similar to our complex phantom reader study where an improvement in detection of round and spiculated masses was achieved by tomosynthesis. The calcifications were as well seen on both 2-dimensional images and tomosynthesis images. It became clear in the specimen reader study that optimized display software is needed for rapid presentation of tomosynthesis image series with capabilities of rapid zooming or full display for the 2k images as well as optimized window and level functions.

C. KEY RESEARCH ACCOMPLISHMENTS

- SNR for tomosynthesis is approximately equal to conventional mammograms even with equivalent radiation dose to that of the conventional mammogram.
- MTF or spatial resolution for tomosynthesis is similar or slightly inferior to that of 2 dimensional mammography.
- As the tomographic angle increased from eight degrees to 40 degrees the effective slice thickness decreased from 2.8 to 0.9mm.

- A new reconstruction algorithm based on ray tracing or backprojection decreases the reconstruction time for tomosynthesis images and makes it possible to reconstruct slices through the whole sample or breast in a relatively short time. In addition any region of interest can be reconstructed into an output matrix, the size of which is defined by the user.
- Complex phantom experiments indicate improved lesion detection for both round and spiculated masses.
- Mastectomy specimen study indicate that the ability to assess lesion margins and morphology is better in digital tomosynthesis as compared to film-screen mammography.

D. REPORTABLE OUTCOMES

Experimental and theoretical spectral optimization for digital mammography

Venkatakrishnan V, Yavuz M, Niklason LT, Opsahl-Ong B, Han S, Landberg C, Nevin R, Hamberg LM, Kopans DB

Proceedings of the SPIE International Conference on Medical Imaging 1999 Vol 3659, San Diego, CA, February 1999. Editors John M Boone and James T Dobbins

Digital Breast Imaging: Tomosynthesis and Digital Subtraction Mammography

Niklason LT, Kopans DB, Hamberg LM

Breast Disease 10(3,4) (1998) 1-14

Digital Tomosynthesis in Breast Imaging

Niklason LT, Christian BT, Niklason LT, Kopans DB, Castleberry, DE, Opsahl-Ong B, Landberg CE, Slanetz PJ, Giardino AA et al.,

Radiology 1997;205:399-406

Experimental and theoretical spectral optimization for digital mammography

Venkatakrishnan V, Yavuz M, Niklason LT, Opsahl-Ong B, Han S, Landberg C, Nevin R, Hamberg LM, Kopans DB

SPIE International Conference on Medical Imaging 1999, February 1999, San Diego, CA, Session: Physics of Medical Imaging

Antiscatter Grids: Are grids required for Digital Mammography? Niklason LT, Venkatakrishnan V, Opsahl-Ong B, Landberg C, Hamberg LM

84th Scientific Assembly and Annual meeting of the Radiological Society of North America, November 1998, Chicago, IL, Session: Physics: Mammography. Abstract, Radiology 1998, 209(P): 158.

Contrast-Detail Comparison of a Full-Field Digital Mammography System and a Screen-Film System. Rosol MS, Niklason LT, Venkatakrishnan V, Silvennoinen H, Kopans D, Hamberg LM Accepted for Presentation in 85th Scientific Assembly and Annual meeting of the Radiological Society of North America, November 1999, Chicago, IL

Antiscatter Grids: Are grids required for Digital Mammography? Niklason LT, Venkatakrishnan V, Opsahl-Ong B, Landberg C, Hamberg LM
Abstract, Radiology 1998, 209(P): 158.

E. CONCLUSIONS

In summary our results demonstrate that 1) SNR for tomosynthesis is approximately equal to conventional mammograms even with equivalent radiation dose to that of one conventional mammogram, 2) MTF or spatial resolution for tomosynthesis is similar or slightly inferior to that of 2 dimensional mammography, 3) as the tomographic angle increased from eight degrees to 40 degrees the effective slice thickness decreased from 2.8 to 0.9mm, 4) a ray tracing algorithm for tomosynthesis image reconstruction makes it possible to reconstruct slices through the whole sample or breast in a relatively short time, 5) tomosynthesis provides improved lesion detection for both round and spiculated masses and 6) the ability to assess lesion margins and morphology is better in digital tomosynthesis as compared to film-screen mammography.

These results suggest that digital tomosynthesis potentially may increase sensitivity and improve ability to detect cancers in dense breast tissue and may increase specificity and ability to characterize a lesion through discrimination of superimposed structures from breast cancer. There is a need for investigating various reconstruction approaches aimed at emphasizing different breast structures as well as developing specialized display software and hardware to be able to display full 2k images and to perform adaptive windowing of the large tomosynthesis data sets.

F. REFERENCES

- [1] Hilman BJ, Fajardo LL, Hunter TB, et. al. Mammogram interpretation by Physician Assistants, *AJR*, 1987, 149:907.
- [2] Basset LW, Bunnell DH, Jahnashahi R, Gold RH, Arndt RD, Linsman J, Breast cancer detection: One versus two views, *Radiology*, 1987, 165:95.
- [3] Baines CJ, Miller AB, Wall C, et. al. Sensitivity and specificity of first screen mammography in the Canadian Breast Screening Study: A preliminary report from five centers, *Radiology*, 1986, 295.
- [4] Haug PJ, Tocino IM, Clayton PD, Bair TL, Automated management of screening and diagnostic mammography, *Radiology*, 1987, 164:747.
- [5] Holland R, Mravunac M, Hendricks JHCL, Bekker BV, So-called interval cancers of the breast, *Cancer* 1982, 49:2527-2533.
- [6] Martin J, Moskowitz M, Milbrath JR, Breast cancers missed by mammography, *Am J Roentgenol* 1979, 132: 737-739.
- [7] Holland R, Hendriks JHCL, Mravunac M, Mammographically occult breast cancer: A pathologic and radiologic study, *Cancer* 1983, 52:1810-1819.
- [8] Feig S, Shaber G, Patchefsky A, Schwartz GF, Edeiken J, Libshitz H, Nerlingen R, Curley RF, Wallave JD, Analysis of clinically occult and mammographically occult breast tumors, *Am J Roentgen* 128: 403-408.
- [9] Ma L, Fishell E, Wright B, Hanna W, Allan S, Boyd NF, Case control study of factors associated with failure to detect breast cancer by mammography, *J Natl Cancer Inst* 1992, 84:81-785.
- [10] Jackson VP, Hendrick RE, Feig SA, Kopans DB, Imaging of the radiographically dense breast, *Radiology* 1993, 188:297-301.
- [11] Bird R, Wallace T, Yankaskas B, Analysis of cancers missed at screening mammography, *Radiology*, 1992, 184:613-617.
- [12] Niklason LT, Christian BT, Niklason LE, Kopans DB, Castelberry DE, Opsahl-Ong BH, Landberg CE, Slanetz PJ, Giardino AA, Moore R, Albagi D et.al. Digital tomosynthesis in breast imaging, *Radiology* 1997, 205:399-406.
- [13] Miller E.R, Edward M, McCurry BSEE, Hruska B An Infinite Number of Laminagrams from a Finite Number of Radiographs, *Radiology* 1971, 98:249-255.

G. LIST OF PERSONNEL

List of personnel part of this research effort:

1. Dr. Elkan Halpern, Staff Statistician, MGH
1. Dr. Leena M. Hamberg, Staff Physicist, MGH Department of Radiology
2. Dr. Daniel Kopans, Staff Radiologist, MGH Department of Radiology
3. Dr. Loren Niklason, Physicist, Consultant
4. Michael Rosol, Graduate Student
5. Dr. Vaidehi Venkatakrisnan, Post-Doctoral Fellow, MGH Department of Radiology

MGH=Massachusetts General Hospital