

AD _____

Award Number: DAMD17-98-1-8484

TITLE: Phase I NKX3.1 in Prostate

PRINCIPAL INVESTIGATOR: Edward P. Gelmann, M.D.

CONTRACTING ORGANIZATION: Georgetown University
Washington, DC 20007-2197

REPORT DATE: January 2001

TYPE OF REPORT: Final, Phase I

PREPARED FOR: U.S. Army Medical Research and Materiel Command
Fort Detrick, Maryland 21702-5012

DISTRIBUTION STATEMENT: Approved for Public Release;
Distribution Unlimited

The views, opinions and/or findings contained in this report are those of the author(s) and should not be construed as an official Department of the Army position, policy or decision unless so designated by other documentation.

20010521 073

REPORT DOCUMENTATION PAGE

Form Approved
OMB No. 074-0188

Public reporting burden for this collection of information is estimated to average 1 hour per response, including the time for reviewing instructions, searching existing data sources, gathering and maintaining the data needed, and completing and reviewing this collection of information. Send comments regarding this burden estimate or any other aspect of this collection of information, including suggestions for reducing this burden to Washington Headquarters Services, Directorate for Information Operations and Reports, 1215 Jefferson Davis Highway, Suite 1204, Arlington, VA 22202-4302, and to the Office of Management and Budget, Paperwork Reduction Project (0704-0188), Washington, DC 20503

1. AGENCY USE ONLY (Leave blank)	2. REPORT DATE January 2001	3. REPORT TYPE AND DATES COVERED Final, Phase I (1 Jul 98 - 31 Dec 00)
----------------------------------	--------------------------------	---

4. TITLE AND SUBTITLE Phase I NKX3.1 in Prostate Cancer	5. FUNDING NUMBERS DAMD17-98-1-8484
--	--

6. AUTHOR(S)
Edward P. Gelmann, M.D.

7. PERFORMING ORGANIZATION NAME(S) AND ADDRESS(ES)
Georgetown University
Washington, DC 20007-2197

E-Mail: gelmanne@goergetown.edu

8. PERFORMING ORGANIZATION REPORT NUMBER

9. SPONSORING / MONITORING AGENCY NAME(S) AND ADDRESS(ES)
U.S. Army Medical Research and Materiel Command
Fort Detrick, Maryland 21702-5012

10. SPONSORING / MONITORING AGENCY REPORT NUMBER

11. SUPPLEMENTARY NOTES
This report contains colored photos

12a. DISTRIBUTION / AVAILABILITY STATEMENT
Approved for Public Release; Distribution Unlimited

12b. DISTRIBUTION CODE

13. ABSTRACT (*Maximum 200 Words*)

We have isolated a prostate-specific gene, *NKX3.1*, that maps to chromosome 8p21, a common region for loss of heterozygosity in human prostate cancer. *NKX3.1* is a homeobox gene that is expressed at high levels in adult human prostate. Deletion of *NKX3.1* in the mouse has suggested that *NKX3.1* has a suppressor effect on prostatic epithelial cell growth, and that haploinsufficiency is sufficient to produce epithelial hyperplasia. Inconsistent with the interpretation that *NKX3.1* is a classical tumor suppressor gene, the coding region of *NKX3.1* is not mutated in human prostate cancer. We have generated an antibody highly specific for *NKX3.1*. Using this reagent we have shown that loss of *NKX3.1* expression is increasingly likely with prostate tumor progression. This loss of expression ranges from 16% of radical prostatectomy specimens to 80% in metastases. We have shown that a genetic polymorphism (*NKX3.1* R52C) that changes DNA-binding properties of the *NKX3.1* protein is present in approximately 10% of the human population. We have not found a difference in the frequency of *NKX3.1* R52C between Caucasians and African Americans. The polymorphism is a risk factor for aggressive prostate cancer (high grade or high stage) (RR=1.8, 95%CI = 1.01-3.22).

14. SUBJECT TERMS
Prostate Cancer

15. NUMBER OF PAGES
13

16. PRICE CODE

17. SECURITY CLASSIFICATION OF REPORT
Unclassified

18. SECURITY CLASSIFICATION OF THIS PAGE
Unclassified

19. SECURITY CLASSIFICATION OF ABSTRACT
Unclassified

20. LIMITATION OF ABSTRACT
Unlimited

Table of Contents

Cover.....	
SF 298.....	
Introduction.....	3
Body.....	3
Key Research Accomplishments.....	6
Reportable Outcomes.....	6
Conclusions.....	7
References.....	7
Appendices.....	7

Introduction

We have isolated a prostate-specific gene, *NKX3.1*, that maps to chromosome 8p21, a common region for loss of heterozygosity in human prostate cancer. *NKX3.1* is a homeobox gene. The mRNA is expressed at high levels in adult human prostate, at very low levels in testis and in no other tissues (1,2). Expression of *NKX3.1* is androgen-regulated (1). Moreover, mice either heterozygous or homozygous for deletion of *NKX3.1* had prostatic hyperplasia and an elevated growth fraction of prostatic epithelial cells (2). This implied that *NKX3.1* has a suppressor effect on prostatic epithelial cell growth, and that haploinsufficiency was sufficient to produce epithelial hyperplasia. Inconsistent with the interpretation that *NKX3.1* is a classical tumor suppressor gene, the coding region of *NKX3.1* is not mutated in human prostate cancer (3). However, disruption of a single allele or diminished expression of *NKX3.1* may occur in human prostate cancer and contribute to prostate neoplasia. We previously had reported that the human population had a polymorphism in *NKX3.1* that changed amino acid 52 from arginine to cysteine (R52C) to generate a variant protein (3). The polymorphism disrupts a consensus phosphorylation sequence and abrogates dependence of DNA binding on phosphorylation in vitro. This provided a basis for asking about the role of R52C in prostate cancer risk.

Body

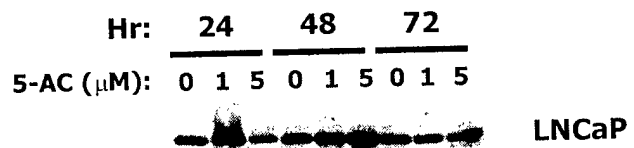
The approved Statement of Work had five aims. This Statement of Work anticipated a budget of \$125,000. The project was funded at 75% of the requested support level. This progress report is organized under headings of each of the aims of the original Statement of Work.

Aim 1: Mutational analysis of the *NKX3.1* promoter region

The original human genomic clone of *NKX3.1* contained 1.3 kb of 5' untranslated region. We found this region to have little or no transcriptional activity when placed upstream from a luciferase reporter construct. We spent much of the last year cloning a putative 5' UTR from a phage λ human genomic DNA library. However, nucleotide sequencing of nearly 16 kb revealed that there was no overlap with the 1.3 kb of known 5' untranslated *NKX3.1* sequence. Since this information is relatively recent, we have no further progress to report on this part of Aim 1.

In addition to promoter mutation, a second potential mechanism for regulation of *NKX3.1* expression in human tissues and tumors is promoter methylation. To begin to assess the role that gene methylation may play in *NKX3.1* expression, we studied the effect of 5-azacytidine (5-AC), a methylase inhibitor, on the expression of *NKX3.1* in prostate cancer cells. 5-AC has a complex effect on the expression of *NKX3.1* in LNCaP cells (Figure 1). At 24 hours 1 μ M markedly increased expression. At 48 hours of treatment both 1 and 5 μ M increased expression. However after 72 hours of treatment expression of *NKX3.1* in LNCaP cells returned to baseline. We are continuing to study the regulation of *NKX3.1* by methylation and are examining the effect of 5-AC in prostate cancer cell lines that do not express *NKX3.1*.

Figure 1
Effect of 5-Azacytidine on *NKX3.1* Expression



Aim 2: *NKX3.1* R52C polymorphism in racial groups and in prostate cancer patients and controls

Using the Taqman assay described in our proposal we determined *NKX3.1* genotype in a cohort of 558 men with prostate cancer from the Physicians Health Study and 695 age-matched controls. The results for the total study population shown in Table 1 show no statistically significant difference between the two groups.

When we analyzed only men who presented with aggressive prostate cancer defined as stage C or D or Gleason score ≥ 7 , we found a statistically significant increase in the frequency of NKX3.1 R52C among the cases, RR=1.8 (CI = 1.01-3.22). No differences between cases and controls were found for nonaggressive cancers or those men with unknown stage and grade.

Table 1

Relative risk of prostate cancer according to the CGC→TGC polymorphism of NKX3.1

NKX3.1 genotype	No. Cases (%)	No. Controls (%)	RR	95% CI
Overall Cancer				
CC	499 (89.4)	637 (91.7)	1.00	Reference
CT	57 (10.2)	55 (7.9)	1.32	0.90-1.95
TT	2 (0.4)	3 (0.4)	0.85	0.14-5.11
CT+TT			1.30	0.89-1.90
Nonaggressive Cancer ^a				
CC	234 (90.4)	285 (89.6)	1.00	Reference
CT	25 (9.7)	31 (9.8)	0.98	0.56-1.71
TT	0	2 (0.6)	0	
CT+TT			0.92	0.53-1.60
Aggressive Cancer ^a				
CC	229 (88.8)	313 (93.4)	1.00	Reference
CT	27 (10.5)	21 (6.3)	1.76	0.97-3.19
TT	2 (0.8)	1 (0.3)	2.73	0.25-30.33
CT+TT			1.80	1.01-3.22
Unknown Aggressiveness				
CC	36 (87.8)	39 (92.9)	1.00	Reference
CT	5 (12.2)	3 (7.1)	1.81	0.40-8.10
TT	0	0	0	
CT+TT			1.81	0.40-8.10

^aAggressive cancer were those cases identified at presentation as stages C or D or Gleason score ≥ 7 .

Since the Physicians Health Study cohort was composed mostly of Caucasians, we have used a smaller cohort from Richard Hayes, PhD, of the National Cancer Institute, to determine the racial distribution of the *NKX3.1* R52C polymorphism (4). The data shown in Table 2 demonstrate that there are no differences in the frequency of the *NKX3.1* R52C variant protein between African Americans and Caucasians.

Table 2

***NKX3.1* Genotype in White and Black American Men**

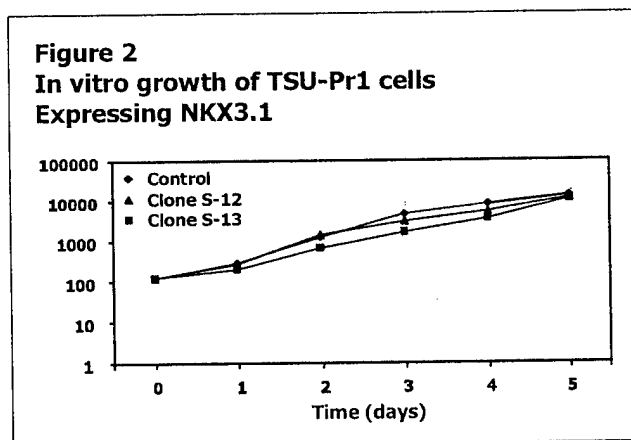
RACE	<i>NKX3.1</i> Genotype - Nucleotide 154			Total
	C/C	C/T	T/T	
White	116 (87.9%)	15	1	132
Black	103 (90.35%)	9	2	114
Total	219 (89.0%)	24	3	246

Aim 3: Immunohistochemical detection of *NKX3.1* protein in prostate cancer tissues.

We generated a rabbit antiserum to recombinant human *NKX3.1* protein. The antiserum was used to study expression of *NKX3.1* in normal human tissues and prostate cancer. This work has been published and is included as an appendix to this report (5). Among normal human tissues *NKX3.1* expression was seen in testis, in rare pulmonary mucous glands, and in isolated regions of transitional epithelium of the ureter. *NKX3.1* was uniformly expressed in nuclei of normal prostate epithelial cells in 61 histologic sections from radical prostatectomy specimens. We analyzed 507 samples of neoplastic prostate epithelium, most of which were contained on a tissue microarray that contained samples from different stages of prostatic neoplasia. We observed complete loss of *NKX3.1* expression in 5% of benign prostatic hyperplasia, 20% of high-grade prostatic intraepithelial neoplasia, 6% of T1_{a/b} samples, 22% of T3/4 samples, 34% of hormone-refractory prostate cancer, and 78% of metastases. Our data show that *NKX3.1* expression is highly, but not exclusively, specific for the prostate. Loss of *NKX3.1* expression is strongly associated with hormone-refractory disease and advanced tumor stage in prostate cancer ($p < 0.0001$).

Aim 4: Identify the effect of *NKX3.1* expression on prostate cancer phenotype in cultured cells

We have transfected *NKX3.1* expression vectors into TSU-Pr1 human prostate cancer cells. We saw no effect of *NKX3.1* expression on in vitro cell growth or morphology of TSU-Pr1 cells. A growth curve is shown in Figure 2. Interestingly, the cells are not indifferent to the expression of *NKX3.1* since in the absence of continuous antibiotic selective pressure, the *NKX3.1* expression plasmid is lost. In the future as part of phase II of this project we will examine the effect of *NKX3.1* on the growth of TSU-Pr1 cells in nude mice. Preliminary data from our phase II project suggest that *NKX3.1* affects in vivo growth probably by increasing apoptotic rate of cells expressing the gene (Figure 3). The data in Figure 3 were not generated as part of phase I. The animal experiments were not



performed with DOD funding. We have also found that in vitro NKX3.1 expression sensitizes cells to induction of cell death by physical and chemical agents. In both stably transfected and transiently transfected TSU-Pr1 cells we have found that NKX3.1 expression nearly doubles the cell death response to irradiation or okadaic acid treatment. Representative data from transient transfection experiments are shown in Figure 4. Full length NKX3.1 protein expression caused a 1.7-fold increased cell death three days after exposure to 20 Gy irradiation. Constructs that were truncated at amino acid 184 eliminated a C-terminal region that attenuated NKX3.1 transcriptional activation (6). The R52C mutation had a negative effect on activation of protein activity by deletion of the C-terminal sequence. A negative control was the gene inserted in reverse orientation in the expression vector.

Aim 5: Determine if RT-PCR for NKX3.1 can be applied to detect circulating prostate cancer cells

Expression of NKX3.1 is highly restricted in the mouse to prostatic lobes and bulbourethral gland (2). NKX3.1 expression is less tightly controlled in adult human tissues. There is a low level of expression in the testis and a faint signal on northern blots of peripheral blood mononuclear cell RNA. We tested whether NKX3.1 could be used in human blood samples to detect low levels of prostatic carcinoma cells. However, we found that with nested PCR reactions we could detect NKX3.1 sequences in the blood of normal men and women. We therefore have concluded that NKX3.1 will not be a useful marker for detection of circulating micrometastatic prostatic cells in patients with prostate cancer.

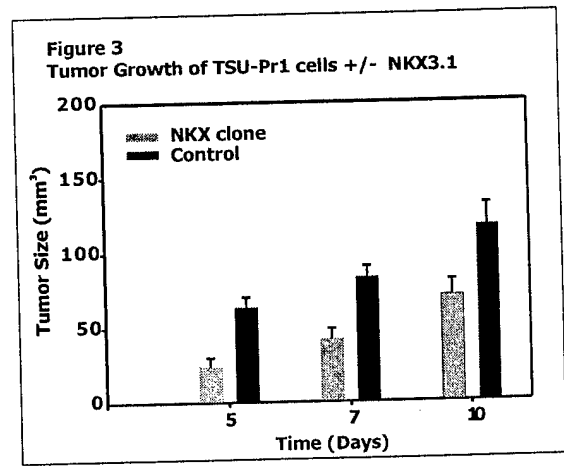
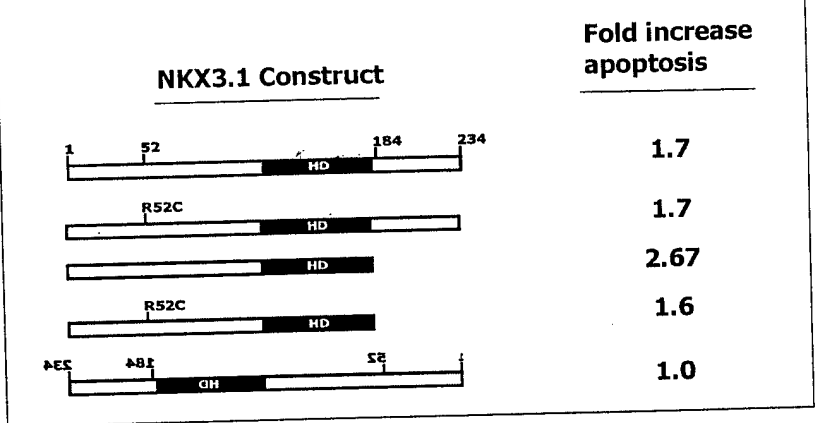


Figure 3
Effect of NKX3.1 on Apoptosis after Transient Transfection



Key Research Accomplishments

- Determined frequency of NKX3.1 R52C polymorphism in the population and in cancer patients
- Showed that there NKX3.1 R52C variant is present with equal frequency in blacks and whites
- Demonstrated that NKX3.1 R52C is a risk factor for aggressive prostate cancer
- Developed a rabbit antiserum to human NKX3.1
- Demonstrated loss of NKX3.1 expression in prostate cancer increases with tumor progression
- Identified normal tissues that express NKX3.1

Reportable Outcomes

1. Funding applied for and received:

Genetic polymorphisms in prostate cancer
NIEHS ES-09888
PI – Edward Gelmann

2. Employment or research opportunities

David Steadman, PhD

Postdoctoral fellow received funding in 1999 from the US Army prostate cancer research program for studies of the biochemistry of NKX3.1 binding to DNA.

Conclusions

This is the final report of phase I of our project NKX3.1 in Prostate Cancer. We have successfully accomplished four of the five original aims despite receiving only 75% of requested funding. We have demonstrated that NKX3.1 expression decreases during prostate cancer progression. This implies that loss of NKX3.1 expression may favor tumor progression and more aggressive cancer. A variant NKX3.1 protein NKX3.1 R52C, present in approximately 10% of the population, is a risk factor for aggressive prostate cancer. We have demonstrated a model system for the study of NKX3.1 effect on cell death in vitro. Future studies will examine the interaction between NKX3.1 and the cell death mechanism, will determine if loss of NKX3.1 expression in primary prostate cancer has prognostic significance and will readdress the control of NKX3.1 expression by promoter methylation.

References

1. He, W. W., Sciavolino, P. J., Wing, J., Augustus, M., Hudson, P., Meissner, P. S., Curtis, R. T., Shell, B. K., Bostwick, D. G., Tindall, D. J., Gelmann, E. P., Abate-Shen, C., and Carter, K. C. A novel human prostate-specific, androgen-regulated homeobox gene (NKX3.1) that maps to 8p21, a region frequently deleted in prostate cancer. *Genomics*, 43: 69-77, 1997.
2. Bhatia-Gaur, R., Donjacour, A. A., Sciavolino, P. J., Kim, M., Desai, N., Norton, C. R., Gridley, T., Cardiff, R. D., Cunha, G. R., Abate-Shen, C., and Shen, M. M. Roles for Nkx3.1 in prostate development and cancer. *Genes and Development*, 13: 966-977, 1999.
3. Voeller, H. J., Augustus, M., Madlike, V., Bova, G. S., Carter, K. C., and Gelmann, E. P. Coding region of NKX3.1, prostate-specific homeobox gene on 8p21, is not mutated in human prostate cancers. *Cancer Res.*, 57: 4455-4459, 1997.
4. Hayes, R. B., Pottern, L. M., Strickler, H., Rabkin, C., Pope, V., Swanson, G. M., Greenberg, R. S., Schoenberg, J. B., Liff, J., Schwartz, A. G., Hoover, R. N., and Fraumeni, J. F., Jr. Sexual behaviour, STDs and risks for prostate cancer. *Br.J.Cancer*, 82: 718-725, 2000.
5. Bowen, C., Bubendorf, L., Voeller, H. J., Slack, R., Willi, N., Sauter, G., Gasser, T. C., Koivisto, P., Lack, E. E., Kononen, J., Kallioniemi, O. P., and Gelmann, E. P. Loss of NKX3.1 expression in human prostate cancers correlates with tumor progression. *Cancer Res*, 60: 6111-6115, 2000.
6. Carson, J. A., Fillmore, R. A., Schwartz, R. J., and Zimmer, W. E. The Smooth Muscle gamma -Actin Gene Promoter Is a Molecular Target for the Mouse bagpipe Homologue, mNkx3-1, and Serum Response Factor. *J.Biol.Chem.*, 275: 39061-39072, 2000.

Appendix

Cai Bowen, Lukas Bubendorf, H. James Voeller, Rebecca Slack, Niels Willi, Guido Sauter, Thomas C. Gasser, Pasi Koivisto, Ernest E. Lack, Juha Kononen, Ollie Kallioniemi, and Edward P. Gelmann. Loss of NKX3.1 expression in human prostate cancers correlates with tumor progression. *Cancer Research*, 60:6111-5, 2000.

Loss of NKX3.1 Expression in Human Prostate Cancers Correlates with Tumor Progression^{1,2}

Cai Bowen, Lukas Bubendorf, H. James Voeller, Rebecca Slack, Niels Willi, Guido Sauter, Thomas C. Gasser, Pasi Koivisto, Ernest E. Lack, Juha Kononen, Olli-P. Kallioniemi, and Edward P. Gelmann³

Lombardi Cancer Center [C. B., H. J. V., R. S., G. S., E. P. G.] and Department of Pathology [E. E. L.], Georgetown University, Washington, DC 20007-2007; Cancer Genetics Branch, National Human Genome Research Institute, NIH, Bethesda, Maryland 20892-4470 [L. B., J. K., O-P. K.]; Institute for Pathology [L. B., N. W., G. S.] and Urologic Clinics [T. C. G.], University of Basel, Basel, Switzerland; Laboratory of Cancer Genetics, Tampere University Hospital, Tampere, Finland [P. K.]

ABSTRACT

NKX3.1 is a prostate-specific homeobox gene located on chromosome 8p21. In the mouse, *Nkx3.1* has growth-suppressive and differentiating effects on prostatic epithelium. Mutations of the coding region of *NKX3.1* were not found in human prostate cancer, failing to support the notion that *NKX3.1* was a tumor suppressor gene. To study the expression of *NKX3.1* protein in human tissues and prostate cancer, we derived a rabbit antiserum against purified recombinant *NKX3.1*. Among normal human tissues, *NKX3.1* expression was seen in testis, in rare pulmonary mucous glands, and in isolated regions of transitional epithelium of the ureter. *NKX3.1* was uniformly expressed in nuclei of normal prostate epithelial cells in 61 histological sections from radical prostatectomy specimens. We analyzed 507 samples of neoplastic prostate epithelium, most of which were contained on a tissue microarray that contained samples from different stages of prostatic neoplasia. We observed complete loss of *NKX3.1* expression in 5% of benign prostatic hyperplasias, 20% of high-grade prostatic intraepithelial neoplasias, 6% of T1_{a,b} samples, 22% of T3/4 samples, 34% of hormone-refractory prostate cancers, and 78% of metastases. Our data show that *NKX3.1* expression is highly, but not exclusively, specific for the prostate. Loss of *NKX3.1* expression is strongly associated with hormone-refractory disease and advanced tumor stage in prostate cancer ($P < 0.0001$).

INTRODUCTION

NKX3.1 is a homeobox gene with prostate-specific expression in the adult (1). *NKX3.1* maps to chromosome 8p21, a region that undergoes LOH⁴ in ~75% of prostate cancer specimens (2-6). For this reason, *NKX3.1* was a candidate target gene for disruption by the 8p21 LOH. However, mutational analysis failed to find any tumor-

specific mutations of *NKX3.1* in human prostate cancer tissues (2). *NKX3.1* has potent growth-suppressing and differentiating effects on prostatic epithelium. Mice heterozygous for targeted disruption of *Nkx3.1* have abnormal prostate morphology with overgrown and dysplastic epithelium (7). Disruption of prostate epithelial morphology and dysplasia is more severe in *Nkx3.1*-null mice (7). The suggestion that gene dosage, and therefore the amount of protein, may be important for the growth-suppressor effects of *NKX3.1* prompted us to study its expression in human prostate cancer specimens.

This report describes the derivation of an antiserum against purified recombinant *NKX3.1* protein and the immunohistochemical expression of *NKX3.1* in normal human tissues and in prostate cancer specimens. One report of *NKX3.1* mRNA expression in human prostate cancer tissues described increased expression in prostate cancers compared with adjacent normal tissue (8). Our data examining *NKX3.1* protein expression support the opposite conclusion. We demonstrate that loss of the expression of this growth suppressor correlates with prostate tumor progression.

MATERIALS AND METHODS

Expression and Purification of *NKX3.1* Recombinant Protein. A 3'-truncated cDNA of wild-type *NKX3.1*, including nucleotides 1-581 and excluding the region that coded for the COOH-terminal region of the protein downstream from the homeodomain, was inserted into pMAL-C2g vector (New England Biolabs, Waltham, MA) at the *SaI*I and *Eco*RI restriction sites. Fusion plasmid was transformed into BL-21-competent cells (Stratagene, La Jolla, CA). An overnight culture of bacteria containing the fusion plasmid was induced with 0.5 mM IPTG for 2 h. MBP⁹-*NKX* fusion protein was purified by affinity chromatography with amylose resin (New England Biolabs). Purified fusion protein was cleaved with 0.05 μg of genenase I (New England Biolabs) per 10 μg of fusion protein at room temperature for 24 h. Pure recombinant *NKX3.1* was purified again by DEAE ion exchange chromatography.

Production of *NKX3.1* Polyclonal Antibody. Twenty-five μg of purified *NKX3.1* recombinant protein in TiterMax adjuvant emulsion (CytRx Corporation, Norcross, GA) were inoculated into New Zealand White rabbits. The total volume of the initial inoculation was 400 μl, and a 200-μl boost was administered 3-4 weeks later. Rabbits were test bled 3-4 weeks after the initial inoculation and after the second boost. Rabbit anti-*NKX3.1* antibody was purified by affinity chromatography by successive passes through BL-21-MBP CNBr-activated Sepharose 4B (Amersham Pharmacia Biotech, Uppsala Sweden) followed *NKX3.1* CNBr-activated Sepharose 4B.

Immunohistochemical Staining. Deparaffinized tissue sections were preheated in 10 mM sodium citrate solution for 20 min in a Black and Decker vegetable steamer. *NKX3.1* antibody diluted 1:1000 in blocking buffer (1:70 dilution of goat serum in PBS) was incubated on slides for 1 h at room temperature. Sections were then incubated with 1:200 diluted biotinylated secondary antibody (Vector Labs, Burlingame, CA) for 30 min and ABC solution (Vector Labs) for another 30 min. VIP peroxidase substrate (Vector Labs) was used to stain tissues, which were then counterstained with methyl green.

Tissues. Sections of normal human tissues were obtained from the Lombardi Cancer Center Histopathology and Tissue Shared Resource. Prostate tissue specimens for normal tissue and the 30 prostate cancers in the validation set came from the Lombardi Cancer Center Histopathology and Tumor Core Facility. These specimens were collected at the time of RP and therefore represent specimens from clinical stage I and II prostate cancers. All histological diagnoses were confirmed

Received 3/17/00; accepted 9/1/00.

The costs of publication of this article were defrayed in part by the payment of page charges. This article must therefore be hereby marked *advertisement* in accordance with 18 U.S.C. Section 1734 solely to indicate this fact.

¹ This work was supported by grants from the NIH (CA78327) and the United States Army (DAMD17-98-1-8484) to E. P. G. and was assisted by Shared Resources of the Lombardi Cancer Center through a National Cancer Institute Cancer Center Support Grant. L. B. was supported by the Swiss National Science Foundation (81BS-052807) and the CaPCURE Foundation, and P. K. by the Academy of Finland and the Tampere University Hospital Foundation.

² The authors of this report made the following contributions: C. B. isolated and purified the recombinant protein, made the antibody, developed the immunohistochemical technique, and stained the histologic sections. L. B. helped develop the tissue microarray technology and constructed the prostate cancer tissue microarray. H. J. V. made the expression vectors for the recombinant fusion protein. R. S. performed the statistical analysis. E. E. L. did the Gleason scoring of histologic samples. N. W. supported tissue microarray construction and histologic review of specimens. G. S. contributed to the development of tissue microarray technology and coordinated the tissue collection and the microarray facility in Basel. T. C. G. helped to select the specimens for the array and provided important clinical information. P. K. collected specimens of hormone-refractory prostate cancer and supporting clinical information. J. K. and O-P. K. developed the tissue microarray technology for high-density arraying of the clinical prostate specimens. E. P. G. directed the research on *NKX3.1*, performed the review of *NKX3.1* staining and scoring, analyzed the data, and prepared the figures.

³ To whom requests for reprints should be addressed, at Lombardi Cancer Center, Georgetown University, 3800 Reservoir Road, N.W., Washington, DC 20007-2007. Phone: (202) 687-2207; Fax: (202) 784-1229; E-mail: Gelmanne@gunet.georgetown.edu.

⁴ The abbreviations used are: LOH, loss of heterozygosity; IPTG, isopropyl-1-thio-β-D-galactopyranoside; MBP, maltose-binding protein; RP, radical prostatectomy; BPH, benign prostatic hyperplasia; PIN, prostatic intraepithelial neoplasia; HR, hormone-refractory.

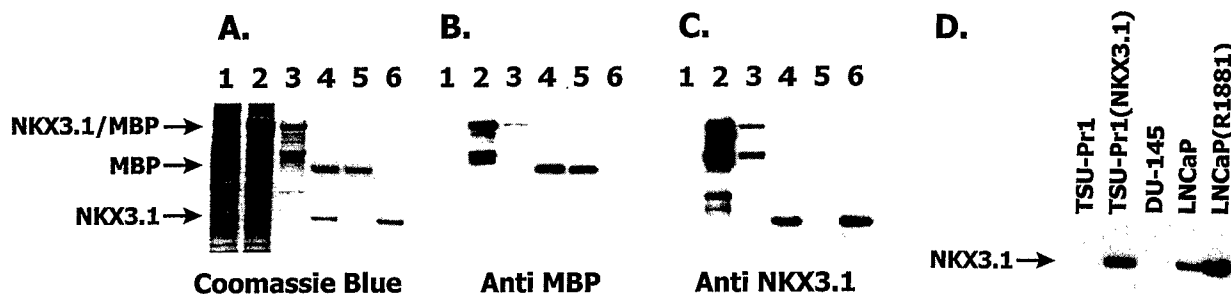


Fig. 1. Antibody to recombinant NKX3.1. A, Coomassie blue staining of samples from purification of recombinant protein. Lane 1, total *E. coli* protein extract prior to IPTG induction; Lane 2, total *E. coli* protein extract after IPTG induction, Lane 3, NKX3.1/MBP fusion protein from amylose column; Lane 4, DEAE-Sepharose-purified fusion protein cleaved with genenase I; Lane 5, DEAE-Sepharose-purified MBP after genenase I digestion of fusion protein; Lane 6, DEAE-Sepharose-purified NKX3.1 after genenase I digestion of fusion protein. B, Western blot of gel as in A, using anti-MBP. C, Western blot of gel as in A, using purified rabbit antibody to NKX3.1. D, Western blot with anti-NKX3.1. Contents of the lanes are labeled.

by staining parallel sections with H&E. Specimens were reviewed by one of us (E. L.) for purposes of assigning Gleason grades.

Tissue Microarrays. The prostate tissue microarray was constructed as described previously (9). Briefly, core tissue biopsies (diameter, 0.6 mm) were taken from paraffin-embedded prostate tumors (donor blocks) and precisely arrayed into a new recipient paraffin block (35 × 20 mm) with a custom-built precision instrument (Beecher Instruments, Silver spring, MD). After the array block was constructed, multiple 4- μ m sections were cut with a microtome using an adhesive-coated tape sectioning system (Instrumedics, Hackensack, NJ). Formalin-fixed and paraffin-embedded tumor and benign control specimens were obtained from the archives of the Institutes for Pathology, University of Basel (Basel, Switzerland), the Cantonal Institute for Pathology (Liestal, Switzerland), and the Tampere University Hospital (Tampere, Finland). The tissue microarray initially contained 632 specimens from all stages of tumor progression. The presence of tissue conforming to the histopathological category assigned in the original assembly was verified by review of an H&E-stained section within 50 μ m of the section stained for NKX3.1; this review identified 477 tissue core specimens that were included in the analysis. Tissue samples included BPH as control ($n = 43$); primary tumors with stage T_{1a/b} according to International Union Against Cancer criteria (10), incidentally discovered after transurethral resection for presumed BPH ($n = 109$); clinically localized tumors obtained from RP specimens (clinical stage T2; $n = 110$); primary, locally advanced tumors (clinical stage T3/4) treated by transurethral resection ($n = 27$); distant metastases collected from autopsies of patients who had died from end-stage metastatic prostate cancer ($n = 35$); and 108 local recurrences after hormonal therapy failure, including 65 transurethral resections from living patients and 43 specimens obtained from autopsies. Tumor grading on the original tissue sections was performed according to Gleason (11). The array also included 54 cores from high grade PIN lesions; however, because of the focal nature of PIN, we verified the H&E staining of each sample on the array and identified only 20 as clearly showing high-grade PIN in the tissue core specimens on the array.

Statistical Methods. Specimens were available from 30 radical prostatectomies. These specimens were assessed for Gleason score and NKX3.1 expression to determine whether NKX3.1 expression differed among specimens with at least one Gleason grade ≥ 4 compared with those with both grades < 4 . The prostate tissue samples available for tissue microarray analysis were ordered by increasing disease severity for the following classifications: BPH, PIN, T1 tumors, RP specimens, and T3/4 tumors. Specimens available from HR samples and metastatic disease represented more severe disease than the previously mentioned tissues, but their position in severity status relative to each other was unknown. Of primary interest was whether there is a decrease in NKX3.1 expression with increasing disease status. Two separate questions were addressed. The first was whether a trend in NKX3.1 expression is present with disease status BPH through T3/4 in the order listed above, with HR tumors as the most severe disease status. The second question was similar, except that metastatic disease rather than HR tumors was the most severe disease. Of additional interest was whether the combined group of T_{1a/b} and RP tissues differed from T3/4 and whether it differed from metastatic tumors. These questions were tested using a Jonkheere-Terpstra test as implemented in StatXact (Cytel). Unless specified below, all tests were considered significant

if $P < 0.05$. To control for the two tests using HR or metastatic tumors as the sixth tissue type, the decrease in NKX3.1 expression was considered significant if the two-sided P was < 0.025 . Specific pairwise comparisons with BPH through T3/4 were performed for HR or metastatic tumors provided the overall test was significant. Similarly, the two comparisons of T_{1a/b} with either T3/4 or metastatic tissue were considered significant for $P < 0.025$.

RESULTS

Recombinant NKX3.1 was made as an MBP fusion protein in *Escherichia coli*. Cleavage of the fusion protein with genenase yielded electrophoretically pure NKX3.1 (Fig. 1A). Antibody to MBP did not react with cleaved NKX3.1, indicating complete cleavage of NKX3.1 from the fusion protein (Fig. 1B). Rabbit antiserum derived against purified recombinant NKX3.1 reacted only with NKX3.1 on Western blot and not with either *E. coli* proteins or MBP (Fig. 1C). The antiserum recognized 32-kDa NKX3.1 in TSU-Pr1 cells transfected with an NKX3.1 expression plasmid, but detected no proteins in TSU-Pr1 cells because they express $< 1/100$ the level of *NKX3.1* mRNA found in LNCaP cells (Fig. 1D).⁵ The induction of *NKX3.1* mRNA by androgen treatment of LNCaP cells has been described and was reflected in the induction of NKX3.1 protein after R1881 treatment of LNCaP cells (Fig. 1D; Refs. 1, 12).

The expression of *NKX3.1* mRNA is restricted in the adult mouse and humans. In the mouse, expression is seen only in the prostatic lobes and the bulbourethral gland (7). Expression in humans was seen predominantly in the prostate, but low levels of mRNA were also detected in testis (1). There also appeared to be signals in peripheral blood lymphocytes (1). In fact, our attempts to use *NKX3.1* as a prostate-specific marker failed because reverse transcription-PCR detected transcripts in female peripheral blood.⁶ To clarify the expression of NKX3.1 in human tissues, we did immunohistochemical staining of 16 human tissues, including prostate, brain, heart, lung, kidney, testis, bladder, ureter, skin, liver, spleen, bone marrow, small and large intestine, breast, and endometrium, using our rabbit antiserum. On the basis of preliminary studies with LNCaP cells and *NKX3.1*-transfected TSU-Pr1 cells, we expected to find this homeobox protein localized to the nucleus.

We detected expression of NKX3.1 in testis, confirming the results for mRNA expression (Fig. 2, A and B). We also noted expression of NKX3.1 in rare mucous glands of the lung (Fig. 2, C and D). Lastly, we found expression of NKX3.1 in groups of ureteral epithelial cells periodically spaced along the lumen of the ureter (Fig. 2, E and F). Bladder transitional epithelium contained rare single cells with nu-

⁵ H. J. Voeller and E. P. Gelmann, unpublished data.

⁶ H. J. Voeller and E. P. Gelmann, unpublished data.

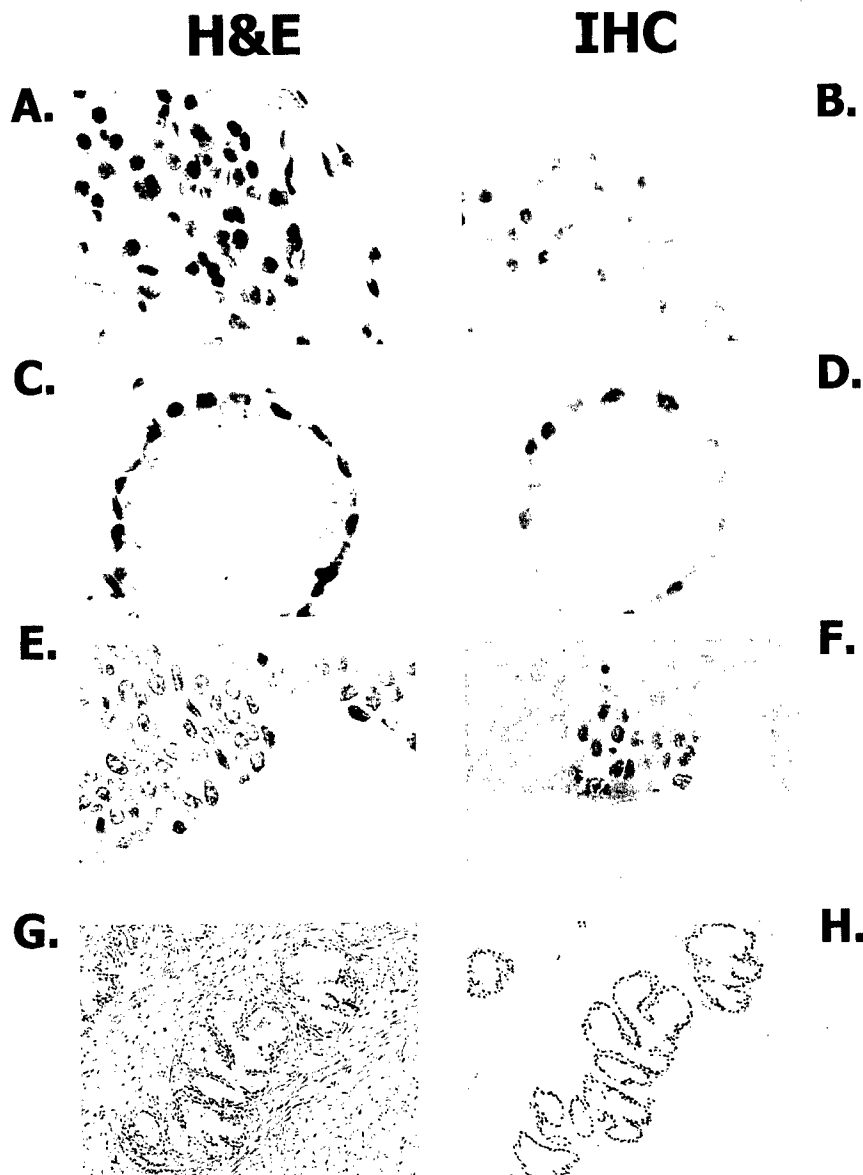


Fig. 2. Immunohistochemical staining of normal human tissues with anti-NKX3.1. Sections were cut in parallel and stained with either H&E (A, C, E, and G) or anti-NKX3.1 (B, D, F, and H). Images A–F were captured digitally using $\times 400$ microscopic magnification; G and H, were captured digitally using $\times 63$ magnification. A and B, normal testis seminiferous tubules. C and D, pulmonary mucous gland. E and F, ureteral transitional epithelium. G and H, prostate gland. IHC, immunohistochemistry.

clear staining (not shown). We found no expression in tissues that contained blood cells, including bone marrow and spleen. Nonmalignant prostatic epithelial cells had uniformly positive nuclear staining for NKX3.1. This was seen in 61 RP specimens (Fig. 2, G and H).

To determine the expression of NKX3.1 in neoplastic prostate epithelium, we analyzed a tissue microarray that contained a spectrum of tissue samples providing a cross-section of prostate tumor progression. To validate the data in the array from one category of tissue, we performed conventional immunohistochemical staining on a separate set of 61 embedded tissue blocks from prostatectomy specimens. Thirty of these blocks contained malignant foci that were scored for NKX3.1 expression and compared with the results of the RP samples in the tissue microarray.

Neoplastic prostate epithelium was found to display three different patterns of immunostaining for NKX3.1 expression. Many samples stained uniformly for NKX3.1. Some samples stained heterogeneously, with some malignant cells stained and adjacent cells not stained. Some samples displayed no staining for NKX3.1. In samples in which malignant cells did not express NKX3.1, adjacent normal epithelial cells were invariably positive, providing an internal control for the quality of the specimen. The patterns of staining are shown in Fig. 3. For the purposes

of analyzing the 477 microarray samples and the 30 sections, uniform staining was awarded a score of 2, heterogeneous staining a score of 1, and samples that did not stain were scored 0.

The results of staining for the tissue microarray are shown in Table 1. Whereas the majority of samples from early-stage cancers stained uniformly for NKX3.1 in epithelial cell nuclei, the number of samples with heterogeneous or negative staining increased among the locally advanced T3/4 and HR samples. There was a significant reduction of NKX3.1 expression in advanced prostate cancer as defined by either HR ($P < 0.0001$) or metastatic disease ($P < 0.0001$). HR demonstrated significantly lower NKX3.1 expression than BPH ($P < 0.0001$), T1_{a,b} ($P < 0.0001$), and RP ($P = 0.013$). Metastatic samples differed from all tissue samples BPH through T3/4 ($P < 0.0001$ for each). The combined group of T1_{a,b} tumors and RP samples had significantly higher NKX3.1 expression than metastases ($P < 0.0001$) but did not achieve a significant difference compared with T3/4 ($P = 0.061$; Refs. 13, 14).

Seventy-eight percent of metastatic samples had no staining for NKX3.1. The integrity of these autopsy samples was confirmed by staining for Ki-67, which was seen to decorate nearly all of the metastatic samples. Because Ki-67 may be more stable than NKX3.1 under conditions found at autopsy, we also compared the HR speci-

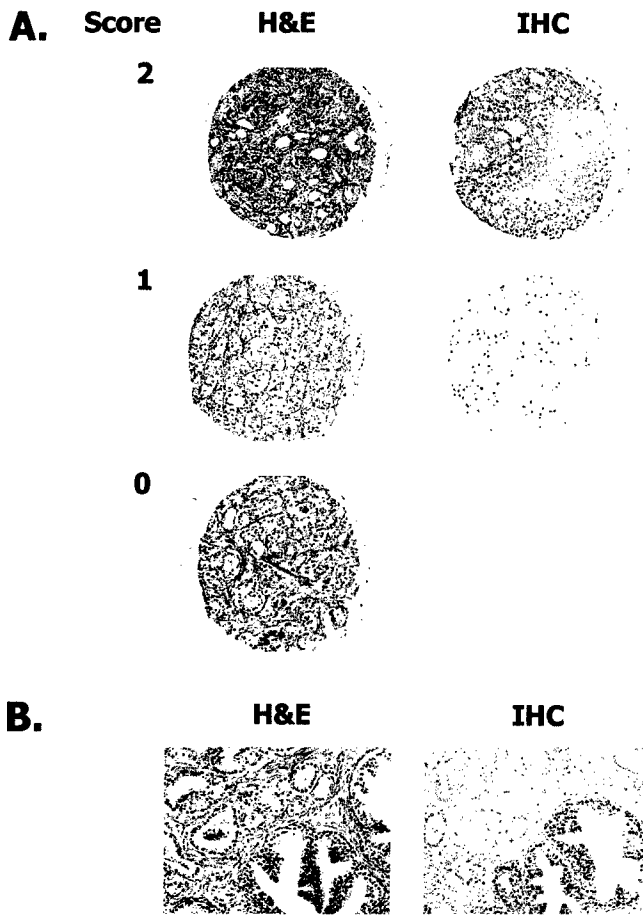


Fig. 3. Immunohistochemical staining of prostatic tissue and tissue microarrays with anti-NKX3.1. A, examples of prostate cancer specimens from tissue microarrays stained with H&E (left) and corresponding section stained with anti-NKX3.1 (right). Staining patterns observed were diffuse staining (2), heterogeneous staining (1), or no staining (0). All tissues were scored according to this scheme, and the data are summarized in Table 1. B, parallel sections from a Gleason score 3 + 3 prostate cancer specimen stained with either H&E (left) or anti-NKX3.1 (right). Images were captured at $\times 100$. NKX3.1 expression was absent in the adenocarcinoma (upper left of slide) and present in hyper-trophic glands (lower right of slide). IHC, immunohistochemistry.

mens that were obtained surgically with those obtained at autopsy. Among 128 HR specimens, 43 were autopsy specimens and 85 were surgical specimens. Of the HR autopsy specimens, 23 of 53 (43%) had staining scores of 0 compared with 24 of 85 (25%) surgical HR specimens. Therefore, it is probable that diminished staining of autopsy-derived material resulted, in part, from antigen degradation.

However, staining of HR autopsy specimens scored positive twice as often as staining of autopsy-derived metastases.

The series of 30 RP specimens analyzed as conventional sections cut from paraffin blocks gave nearly identical results to the distribution of staining patterns found among the RP specimens in the tissue microarray. The microarray RP samples gave a nearly identical distribution of staining scores compared to these 30 paraffin block samples; therefore, the staining of conventional samples validated the tissue microarray data and confirmed that a fraction of early-stage prostate cancers lose expression of NKX3.1.

The 30 samples from paraffin blocks were subjected to histological grading (11). In contrast to the relationship between loss of NKX3.1 staining and prostate tumor progression, we found no relationship between NKX3.1 staining scores and Gleason scores in the 30 RP blocks. The distribution of NKX3.1 staining results over the range of tumor grades as measured by Gleason score is shown in Table 2. Samples were compared across all scores and compared as groups with at least one grade ≥ 4 versus both grades < 4 . There was no evidence indicating that patients with lower NKX3.1 expression had higher Gleason scores ($P = 0.611$; Ref. 13).

DISCUSSION

Our data show that NKX3.1 expression is lost in a significant fraction of early-stage prostate cancer and that loss of expression correlates with tumor progression. Because NKX3.1 has differentiating and growth-suppressing effects in the mouse prostate, it is tempting to speculate that NKX3.1 plays a tumor-suppressor function in human prostate cancer. If, similar to the mouse, the human prostatic epithelium is sensitive to the level of NKX3.1 protein, then diminution in the level of NKX3.1 expression, even in tissues that demonstrate heterogeneous staining, may play a role in the pathogenesis or progression of human prostate cancer. NKX3.1 staining was found in three patterns in the tissue samples. Most samples, except for metastases, showed diffuse staining of both normal and neoplastic prostatic epithelial cells. In our experience, all normal prostate epithelial cells express NKX3.1. NKX3.1 expression decreases with disease severity. That fact combined with the lack of relationship between NKX3.1 expression and the Gleason score means that NKX3.1 expression has the potential to be a promising new prognostic marker if it is associated with patient survival. Further studies are warranted in this area. A previous report that *NKX3.1* mRNA expression was increased in prostate cancer tissues compared with adjacent normal tissues arrived at a different conclusion from our findings (8). If the results of Xu *et al.* (8) are confirmed, it would lead to the conclusion that control of NKX3.1 expression occurs at the posttranscriptional level.

In the survey of 61 tissue sections, we found no example of

Table 1 Frequencies of progression array staining for NKX3.1

NKX3.1 staining score	Tissue microarray samples, n (%)							RP sections, ^a n (%)
	BPH	PIN	T1 _{a/b}	RP ^a	T3/4	HR	Meta ^b	
2	36 (84)	9 (45)	83 (76)	68 (62)	14 (52)	64 (50)	4 (10)	19 (63)
1	5 (12)	7 (35)	19 (17)	24 (22)	7 (26)	20 (16)	5 (13)	7 (23)
0	2 (5)	4 (20)	7 (6)	18 (16)	6 (22)	44 (34)	31 (78)	4 (13)
Total (100%) tissue	43	20	109	110	27	128	40	30
	<i>P vs.</i>							
HR	<0.0001 ^c	0.789	<0.0001 ^c	0.013 ^c	0.529			
Meta	<0.0001 ^c	<0.0001 ^c	<0.0001 ^c	<0.0001 ^c	<0.0001 ^c			
T1 _{a/b} + RP					0.061		<0.0001 ^d	

^a RP samples from tissue microarray and paraffin sections presented similar NKX3.1 score profiles.

^b Meta, metastatic disease.

^c This test is significant at 0.05. No adjustment was made because these analyses were controlled by the overall test.

^d This test is significant at the specified $P < 0.025$.

Table 2 *NKX3.1* staining and Gleason scores

NKX3.1 staining score	Gleason score					
	2 + 2	2 + 3	3 + 3	3 + 4	4 + 4	4 + 5
2	1	3	7	6	2	0
1	1	3	2	0	1	0
0	1	0	1	0	1	1

nonmalignant prostatic glands failing to stain for NKX3.1. In the array, two BPH specimens displayed no staining. We cannot state at this time whether this represents a background of tissues that failed to stain for technical reasons or a subset of prostatic hyperplasia with true loss of NKX3.1 expression. Analysis of PIN samples revealed that more than half had reduced or absent NKX3.1 expression. Therefore, NKX3.1 may also play a role in the development of prostate cancer. A larger number of PIN lesions need to be analyzed to elucidate the role of NKX3.1 in prostate cancer development.

The finding that NKX3.1 expression was lost most often in metastases is consistent with the notion that metastatic disease is the most dedifferentiated state of prostate cancer. It may also be that NKX3.1 expression is under the control of prostate stromal cells. In murine tissue recombinants of neonatal epithelium and mesenchyme from the urogenital sinus, only tissues that underwent prostatic differentiation expressed *Nkx3.1* (7). On the other hand, the quality of the specimens, particularly from autopsies, could have resulted in sample degradation and diminished ability to detect NKX3.1. The mechanism of modulating NKX3.1 expression in human prostate cancer remains to be elucidated. It has not been determined whether *NKX3.1* undergoes LOH in those tissues that display LOH at 8p21. Therefore, it is possible that loss of a single *NKX3.1* allele as a result of LOH at 8p21 could down-regulate NKX3.1 expression. Because NKX3.1 is a differentiating protein, its expression may be regulated by gene methylation. We presently are characterizing the upstream sequences of *NKX3.1* to identify regions that may be targets for gene silencing by methylation. Methylation is an important mechanism for loss of differentiated functions in human cancers such as diminished estrogen-receptor expression in breast cancer (15, 16). It remains to be determined whether promoter methylation plays a role in the down-regulation of NKX3.1 expression in prostate cancer.

The survey of NKX3.1 expression in normal tissues underscores the high degree of prostate specificity in the expression pattern of this protein. The role of NKX3.1 in the function of extraprostatic cells where it was found, bronchial mucous glands, testis, and ureter, is unknown. *Nkx3.1* is not expressed in murine testis, and the *Nkx3.1* (-/-) mice were fertile. There was no obvious ureteral or pulmonary pathology attributed to loss of *Nkx3.1* in the gene-deleted mice (7). If the only apparent action of *NKX3.1* is as a prostate-specific repressor, the gene may have application in prostate-specific gene therapy. The potential for application of gene therapy to the treatment of prostate cancer is under active investigation. There may be advantages to the use of suppressor genes with limited tissue-specific effects to minimize toxicity of gene therapy to other organs. Whether ectopic expression of NKX3.1 in organs other than the prostate will have any functional ramifications remains to be shown. In addition, because of its tissue-specific expression in the adult, the *NKX3.1* promoter is a potentially useful determinant for prostate-specific expression of exogenous genes. The probasin promoter has been quite useful in generating a murine prostate cancer model by driving organ-specific expression of the SV40 T antigen (17-19). Whether the *Nkx3.1* promoter will have similar effects remains to be shown. Early in murine development, *Nkx3.1* expression occurs in many regions of the embryo and may play a noncritical role in the development of other organs (20, 21). Lastly, the *NKX3.1* promoter may have applications

in tissue-specific gene therapy of prostatic disease. The expression of NKX3.1 in other tissues shown in this report will help to identify potential organs for side effects of treatments targeted to the prostate by the *NKX3.1* promoter.

ACKNOWLEDGMENTS

The Lombardi Cancer Center Histopathology and Tissue Shared Resource provided normal human tissues. We are particularly grateful to Baljit Singh for assistance. Microscopy was done in the Lombardi Cancer Center Microscopy and Imaging Shared Resource.

REFERENCES

- He, W. W., Scivolino, P. J., Wing, J., Augustus, M., Hudson, P., Meissner, P. S., Curtis, R. T., Shell, B. K., Bostwick, D. G., Tindall, D. J., Gelmann, E. P., Abate-Shen, C., and Carter, K. C. A novel human prostate-specific, androgen-regulated homeobox gene (*NKX3.1*) that maps to 8p21, a region frequently deleted in prostate cancer. *Genomics*, 43: 69-77, 1997.
- Voeller, H. J., Augustus, M., Madlike, V., Bova, G. S., Carter, K. C., and Gelmann, E. P. Coding region of *NKX3.1*, prostate-specific homeobox gene on 8p21, is not mutated in human prostate cancers. *Cancer Res.*, 57: 4455-4459, 1997.
- Kagan, J., Stein, J., Babaian, R. J., Joe, Y. S., Pisters, L. L., Glassman, A. B., von Eschenbach, A. C., and Troncoso, P. Homozygous deletions at 8p22 and 8p21 in prostate cancer implicate these regions as the sites for candidate tumor suppressor genes. *Oncogene*, 11: 2121-2126, 1995.
- Vocke, C. D., Pozzatti, R. O., Bostwick, D. G., Florence, C. D., Jennings, S. B., Strup, S. E., Duray, P. H., Liotta, L. A., Emmert-Buck, M. R., and Linehan, W. M. Analysis of 99 microdissected prostate carcinomas reveals a high frequency of allelic loss on chromosome 8p21-22. *Cancer Res.*, 56: 2411-2416, 1996.
- MacGrogen, D., Levy, A., Bostwick, D., Wagner, M., Wells, D., and Bookstein, R. Loss of chromosome arm 8p loci in prostate cancer: mapping by quantitative allelic imbalance. *Genes Chromosomes Cancer*, 10: 151-159, 1994.
- Emmert-Buck, M. R., Vocke, C. D., Pozzatti, R. O., Duray, P. H., Jennings, S. B., Florence, C. D., Bostwick, D. G., Liotta, L. A., and Linehan, W. M. Allelic loss on chromosome 8p12-21 in microdissected prostate intraepithelial neoplasia. *Cancer Res.*, 55: 2959-2962, 1995.
- Bhatia-Gaur, R., Donjacour, A. A., Scivolino, P. J., Kim, M., Desai, N., Norton, C. R., Gridley, T., Cardiff, R. D., Cunha, G. R., Abate-Shen, C., and Shen, M. M. Roles for *Nkx3.1* in prostate development and cancer. *Genes Dev.*, 13: 966-977, 1999.
- Xu, L. L., Srikanth, V., Sesterhenn, I. A., Augustus, M., Dean, R., Moul, J. W., Carter, K. C., and Srivastava, S. Expression profile of an androgen regulated prostate specific homeobox gene *NKX3.1* in primary prostate cancer [In Process Citation]. *J. Urol.*, 163: 972-979, 2000.
- Kononen, J., Bubendorf, L., Kallioniemi, A., Barlund, M., Schraml, P., Leighton, S., Torhorst, J., Mihatsch, M. J., Sauter, G., and Kallioniemi, O. P. Tissue microarrays for high-throughput molecular profiling of tumor specimens. *Nat. Med.*, 4: 844-847, 1998.
- International Union Against Cancer (UICC). Classification of Malignant Tumours, 5th ed. Berlin: Wiley-Liss, 1997.
- Gleason, D. F., Mellinger, G. T., and VACURG. Prediction of prognosis for prostatic adenocarcinoma by combined histologic grading and clinical staging. *J. Urol.*, 111: 58-64, 1974.
- Prescott, J. L., Blok, L., and Tindall, D. J. Isolation and androgen regulation of the human homeobox cDNA, *NKX3.1*. *Prostate*, 35: 71-80, 1998.
- Hollander, M., and Wolfe, D. A. Nonparametric Statistical Methods. New York: Wiley, 1973.
- Mehta, C., and Patel, N. StatXact3 for Windows. Cambridge, MA: Cytel Software Corporation, 1995.
- Lapidus, R. G., Ferguson, A. T., Ottaviano, Y. L., Parl, F. F., Smith, H. S., Weitzman, S. A., Baylin, S. B., Issa, J. P. J., and Davidson, N. E. Methylation of estrogen and progesterone receptor gene 5' CpG islands correlates with lack of estrogen and progesterone receptor gene expression in breast tumors. *Clin. Cancer Res.*, 2: 805-810, 1996.
- Ferguson, A. T., Lapidus, R. G., Baylin, S. B., and Davidson, N. E. Demethylation of the estrogen receptor gene in estrogen receptor-negative breast cancer cells can reactivate estrogen receptor gene expression. *Cancer Res.*, 55: 2279-2283, 1995.
- Matuo, Y., Adams, P. S., Nishi, N., Yasumitsu, H., Crabb, J. W., and Matusik, R. J. The androgen-dependent rat prostate protein, Probasin, is a heparin binding protein that co-purifies with heparin-binding growth factor-1. *In Vitro Cell Dev. Biol.*, 25: 581-584, 1989.
- Yan, Y., Sheppard, P. C., Kasper, S., Lin, L., Hoare, S., Kapoor, A., Dodd, J. G., Duckworth, M. L., and Matusik, R. J. Large fragment of the probasin promoter targets high levels of transgene expression to the prostate of transgenic mice. *Prostate*, 32: 129-139, 1997.
- Greenberg, N. M., DeMayo, F., Finegold, M. J., Medina, D., Tilley, W. D., Aspinall, J. O., Cunha, G. R., Donjacour, A. A., Matusik, R. J., and Rosen, J. M. Prostate cancer in a transgenic mouse. *Proc. Natl. Acad. Sci. USA*, 92: 3439-3443, 1995.
- Bieberich, C. J., Fujita, K., He, W. W., and Jay, G. Prostate-specific and androgen-dependent expression of a novel homeobox gene. *J. Biol. Chem.*, 271: 31779-31782, 1996.
- Kos, L., Chiang, C., and Mahon, K. A. Mediolateral patterning of somites: multiple axial signals, including Sonic hedgehog, regulate *Nkx-3.1* expression. *Mech. Dev.*, 70: 25-34, 1998.