

AD \_\_\_\_\_

Award Number: DAMD17-98-1-8606

TITLE: Characterization of an ICII82, 780-Induced, Estrogen Receptor (ER)- $\beta$  Mediated Apoptotic Pathway in Prostate Cancer Cells and Establishment of (ER)- $\beta$ -Regulated Electrophile-Processing Phase II Enzyme Downregulation as a Promotional Factor in Human Prostatic Carcinogenesis

PRINCIPAL INVESTIGATOR: Shuk-Mei Ho, Ph.D.

CONTRACTING ORGANIZATION: University of Massachusetts  
Medical School  
Worcester, Massachusetts 01655

REPORT DATE: May 2001

TYPE OF REPORT: Annual

PREPARED FOR: U.S. Army Medical Research and Materiel Command  
Fort Detrick, Maryland 21702-5012

DISTRIBUTION STATEMENT: Approved for Public Release;  
Distribution Unlimited

The views, opinions and/or findings contained in this report are those of the author(s) and should not be construed as an official Department of the Army position, policy or decision unless so designated by other documentation.

20020123 078

# REPORT DOCUMENTATION PAGE

Form Approved  
OMB No. 074-0188

Public reporting burden for this collection of information is estimated to average 1 hour per response, including the time for reviewing instructions, searching existing data sources, gathering and maintaining the data needed, and completing and reviewing this collection of information. Send comments regarding this burden estimate or any other aspect of this collection of information, including suggestions for reducing this burden to Washington Headquarters Services, Directorate for Information Operations and Reports, 1215 Jefferson Davis Highway, Suite 1204, Arlington, VA 22202-4302, and to the Office of Management and Budget, Paperwork Reduction Project (0704-0188), Washington, DC 20503

1. AGENCY USE ONLY (Leave blank)	2. REPORT DATE May 2001	3. REPORT TYPE AND DATES COVERED Annual (1 Sep 99 - 30 Apr 01)
----------------------------------	----------------------------	---

4. **TITLE:**  
Characterization of an ICII82, 780-Induced, Estrogen Receptor (ER)- $\beta$  Mediated Apoptotic Pathway in Prostate Cancer Cells and Establishment of (ER)- $\beta$ -Regulated Electrophile-Processing Phase II Enzyme Downregulation as a Promotional Factor in Human Prostatic Carcinogenesis

5. **FUNDING NUMBERS**  
DAMD17-98-1-8606

6. **AUTHOR(S)**  
Shuk-Mei Ho, Ph.D.

7. **PERFORMING ORGANIZATION NAME(S) AND ADDRESS(ES)**  
University of Massachusetts Medical School  
Worcester, Massachusetts 01655  
Email - shuk-mei.Ho@umassmed.edu

8. **PERFORMING ORGANIZATION REPORT NUMBER**

9. **SPONSORING / MONITORING AGENCY NAME(S) AND ADDRESS(ES)**  
U.S. Army Medical Research and Materiel Command  
Fort Detrick, Maryland 21702-5012

10. **SPONSORING / MONITORING AGENCY REPORT NUMBER**

11. **SUPPLEMENTARY NOTES**

12a. **DISTRIBUTION / AVAILABILITY STATEMENT**  
Approved for Public Release; Distribution Unlimited

12b. **DISTRIBUTION CODE**

13. **Abstract (Maximum 200 Words) (abstract should contain no proprietary or confidential information)**  
To investigate the role of ER- $\beta$  in human prostate carcinogenesis, and in growth regulation of a prostate cancer cell line (DU145), we proposed: 1) to study effects of antiestrogens/estrogens on growth of DU145 cells, 2) to Immunostain tissue sections from discarded human radical prostatectomy specimens and to perform semiquantitative RT-PCR on microdissected tissues to determine the level of ER $\beta$  expression in normal and abnormal prostate tissues.  
Under **Specific Aim 1**, the proposed works have been completed and the results had been published in *Cancer Research* Journal and reported in the first progress report. In addition, we demonstrated the antiestrogen-induced cell growth inhibition in DU145 cells might be due to the induction of cell cycle arrest at G0-G1 phase. Under **Specific Aim 2**, Using GC17 we showed that in normal prostates, ER $\beta$  was strongly expressed in the nuclei of basal epithelial cells. ER $\beta$  expression was transiently elevated in early PIN lesions, but progressively diminished in higher grade PIN lesions. Similarly, ER $\beta$  immunostaining was markedly diminished in Gleason grade 3 and 4 adenocarcinomas and absent in higher-grade cancers. ER $\beta$  expression reappeared in metastatic prostatic carcinomas. The results were also compared to ER $\alpha$  and androgen receptor expressions in those samples.

14. **SUBJECT TERMS**  
Prostate Cancer

15. **NUMBER OF PAGES**  
33

16. **PRICE CODE**

17. **SECURITY CLASSIFICATION OF REPORT**  
Unclassified

18. **SECURITY CLASSIFICATION OF THIS PAGE**  
Unclassified

19. **SECURITY CLASSIFICATION OF ABSTRACT**  
Unclassified

20. **LIMITATION OF ABSTRACT**  
Unlimited

## Table of Contents

Cover.....	1
SF 298.....	2
Table of Contents.....	3
Introduction.....	4
Body.....	5-9
Key Research Accomplishments.....	8-9
Reportable Outcomes.....	9
Conclusions.....	9
References.....	9
Appendices.....	9-33

**Title and Abstract Page**

Proposal Title: *Role of estrogen receptor- $\beta$  in growth regulation of an androgen-independent prostate cancer cell line (DU145) and its expression in PIN lesions*

Award Category: *Idea Award*

Principal Investigator: *Shuk-mei Ho, Ph. D., 508-856-1909 (tel), 508-856-8699 (fax), E-mail address: shuk-mei.ho@umassmed.edu*

Organization: *University of Massachusetts Medical School, 55 Lake Avenue North, Worcester, MA 01655, USA.*

**Abstract**

The **goal** of our **Phase I proposal** was to investigate the role played by a recently discovered, estrogen receptor (ER) subtype, ER- $\beta$ , in human prostate carcinogenesis, and in growth regulation of a prostate cancer cell line (DU145). The **rationale** for our proposed studies was a) we and others found expression of ER- $\beta$ , but not ER- $\alpha$  transcript, the prostatic epithelium of the **rat**; b) localization of ER $\beta$  in basal cell of the **human prostate** and its augmented expression in prostatic intraepithelial neoplasia (PIN) lesions, c) expression of ER $\beta$ , but not ER- $\alpha$ , in an androgen independent prostatic cell line DU145, and d) cell growth inhibition of DU145 cells by antiestrogens [4-hydroxytamoxifen (4OH-TAM) or ICI182,780 (ICI)] and not by estrogens [estradiol-17 $\beta$  (E2) or diethylstilbestrol (DES)]. These findings led us to **hypothesize that 1) selected antiestrogens, via ER $\beta$  signaling, exerted inhibitory action on prostatic cancer cell growth, and 2) altered expression of ER $\beta$  is involved in the genesis of human PIN lesions and its progression to higher grades.** To test these **novel ideas** we proposed: **Specific Aim 1**-DU145 cells are to be treated with estrogens/antiestrogens to determine if, and which of, these compounds inhibit cell growth, regulate expression of two estrogen-regulated genes (PR and pS2), and/or induce apoptosis/cell growth inhibition. An ER $\beta$  antisense oligodeoxynucleotide (ODN) is used to determine receptor subtype-specificity. **Specific Aim 2**-Immunostaining of sections from discarded human radical prostatectomy specimens to determine if expression of ER $\beta$  is upregulated in PIN lesions, and semiquantitative RT-PCR is conducted on RNA extracted from microdissected tissues to determine if levels of ER $\beta$  mRNA concomitantly increase.

Significant progress has been made during the 18 months. Under **Specific Aim 1**, the proposed works have been completed and the results had been published in *Cancer Research* Journal (see attached reprint of the article) and reported in the first progress report. Briefly, semi-quantitative RT-PCR analyses revealed that normal prostatic epithelial cells (PrECs) in primary cultures expressed only transcripts of ER- $\beta$ , but not those of ER- $\alpha$ , along with messages of PR and pS2, two estrogen-regulated genes. However, expression patterns of ER subtypes and their regulatory genes in malignant PrECs (DU145, PC-3) were highly variable. Moreover, estrogens/antiestrogens exerted growth inhibitory actions on prostatic cancer cells in a ER subtype-specific manner. In PC-3 cells, which expressed both ER subtypes, estrogens as well as antiestrogens effectively inhibited cell growth. In contrast, in DU145 cells, which expressed only ER- $\beta$ , antiestrogens, but not estrogens, were growth inhibitors. ICI consistently elicited a more potent response than 4OH-TAM. With ER- $\beta$  antisense ODN, the results supported that this inhibitory effects of antiestrogens on DU145 cells is mediated via ER- $\beta$  associated pathway. In addition, we demonstrated the antiestrogen-induced cell growth inhibition in DU145 cells may be due to the induction of cell cycle arrest at G0-G1 phase. It leads to our ongoing study of antiestrogens/ ER $\beta$  regulated genes in DU145 cells and it potentially can discover previous-unidentified cell cycle control genes which are regulated by ER $\beta$ . Under **Specific Aim 2**, Using GC17 we showed that in normal prostates, ER $\beta$ , but not ER $\alpha$ , was strongly expressed in the nuclei of basal epithelial cells. ER $\beta$  expression was **transiently elevated** in early PIN lesions, but **progressively diminished** in higher grade PIN lesions. Similarly, ER $\beta$  immunostaining was **markedly diminished** in Gleason grade 3 and 4 adenocarcinomas and **absent** in higher-grade cancers. Interestingly, ER $\beta$  expression reappeared in metastatic prostatic carcinomas in bone and lymph nodes. The results were compared to ER $\alpha$  and androgen receptor expressions in those samples. Taken together, our findings, and reports that ER $\beta$  regulates expression of **electrophile-processing phase II enzymes**, strongly implicate ER- $\beta$  as an antitumorigenic molecule in normal PrEC and therefore **loss of ER $\beta$ -regulated expression of antioxidant enzymes may favor neoplastic development and progression.** This **paradigm-shifting hypothesis will be tested in our Phase II research in order to expand the horizon for developing new strategies for prostate cancer prevention.** The **reappearance of ER $\beta$  expression in metastatic foci may allow to treat patients with late stage disease with antiestrogens which we have shown to inhibit prostatic cancer cell growth *in vitro*.**

**Report Body****1. Progress**

**Task 1**-Use DU145, an androgen-independent prostatic cancer cell line, in culture systems to determine a) if estrogens/antiestrogens exert a growth inhibitory action on cell growth, and/or regulate ER $\beta$ , and PR mRNA expression, b) if the estrogen/antiestrogen-induced inhibition of cell growth is mediated by induction of apoptosis, c) if exposure of DU145 cells to an antisense oligonucleotide of ER $\beta$  will abrogate the estrogen/antiestrogen-induced growth inhibitory effects. (Negotiated time line for completion of Task 1 is 18 months, to be completed during Year 1 and Year 2)

**Summary of work accomplished under Task 1:**

We have essentially completed all the proposed work mandated under Task 1, except the study of induction of apoptosis in antiestrogen-induced inhibition of DU145 cell growth. The results of the completed studies under Task 1 had been published in June 15, 2000 issue of Cancer Research (see attached reprint of the article) and had been reported in the first annual 18 months report. To determine whether induction of apoptosis and/or cell cycle arrest are/is related to the antiestrogen-induced DU145 cell growth inhibition, we conducted flow cytometry analysis of DNA content in antiestrogen-treated DU145 cells. Results showed cell cycle arrest at G<sub>0</sub>-G<sub>1</sub> phase in the DU145 cells treated with ICI-182,780 for 24 hours but no evidence of induction of apoptosis (Figure 1).

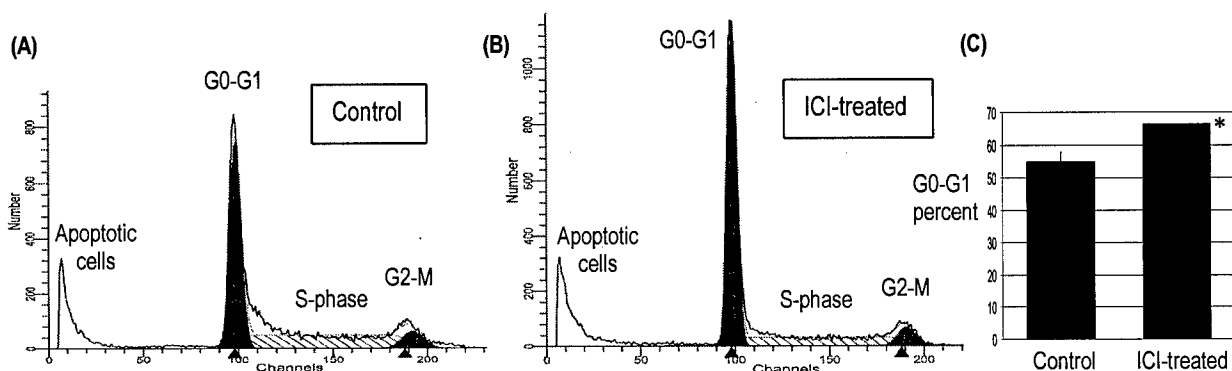


Figure 1. Data of flow cytometry analysis of DNA content in control and ICI-treated DU145 cells. DU145 cells were treated with 10<sup>-5</sup>M ICI for 24 h and fixed with ice-cold 70% ethanol for at least 24 h. The fixed cells were stained with propidium iodide for 30 min at 4°C and loaded onto flow cytometer. The vehicle (100% ethanol) treated cells were used as control. (A) & (B) DNA content histograms of control and ICI-182,780-treated cells (C) Percent of cells at G<sub>0</sub>-G<sub>1</sub> phase of control and ICI-treated cells. n = 3; column = mean; bar = standard deviation; \* = p < 0.01 compared to control cells.

**Task 2**-Using discarded human radical prostatectomy specimens we will determine a) Whether the expression of ER $\beta$  is upregulated in human prostatic intraepithelial neoplasia (PIN), and b) if levels of ER $\beta$  mRNA, determined by semiquantitative RT-PCR on laser microdissected tissues increase in accordance with the grade of the lesion. (conducted during year 2 and year 3)

**Summary of work accomplished under Task 2:**

A comprehensive manuscript documenting our findings accomplished during years 2 and 3 has been accepted for publication in July 2001 issue of the **The American journal of pathology** (see attached preprint of the article). A summary of our findings is outlined below. Our studies were conducted on 50 radical prostatectomy specimens (formalin-fixed, paraffin embedded), 7 specimens of metastases to bone, 5 lymph node specimens, containing metastatic foci and 18 samples of prostate tissue that was quick frozen in liquid nitrogen for subsequent laser microdissection.

As discussed in our previous progress report our first task was to find and characterize a highly specific antibody reagent for ER $\beta$  that would be used for immunohistochemical localization of the receptor in tissue sections. This reagent would allow us to compare the expression of the receptor at both the transcriptional and translational levels. Although there are numerous reagents for the receptor that are commercially or privately available close scrutiny of several of these antibodies, by us and others, have found them to be nonspecific and/or cross reactive with ER $\alpha$ . During the current grant period, in collaboration with investigators at BIOGENEX labs., we have developed and characterized an antibody reagent called GC-17 that meets all of the criteria of specificity. GC-17 is a polyclonal antibody directed against amino acid

sequences **449-465 in the F-domain of ER $\beta$  that has no homology with its  $\alpha$  isoform**. To prove its specificity we carried out comprehensive studies on human tissues which included: competitive inhibition ELISA assays, Western blot analysis on human prostate and testis homogenates, and competitive immunohistochemistry (see attached manuscript for details). Results from Western blot studies were compared subsequent RT-PCR. Summarizing we find: a) GC-17 specifically identified ER $\beta$  in Western blots as well as in tissue sections by immunohistochemistry. Whereas GC-17 identified both short and long forms of ER $\beta$  **only the long form (63kD) was detected in human prostate cells, prostate cancer cells and human testes (Figure 2)**. In marked contrast, using a well-characterized antibody for the ER $\alpha$  receptor, we find that the level of ER $\alpha$  protein was undetectable in these same tissues. **To our knowledge this is the first report which fully characterizes an antibody specific for ER $\beta$  in human tissues, reports that the long form of the receptor is solely expressed the human prostate and testes and that the  $\alpha$  isoform is expressed at very low to undetectable levels in these tissues**. We next studied and compared the immunolocalization and transcript expression of ER $\beta$ , the  $\alpha$  isoform and the androgen receptor (AR) in normal prostate, hyperplastic, low/moderate PIN lesions, grades 3–4/5 primary cancers and in metastases.

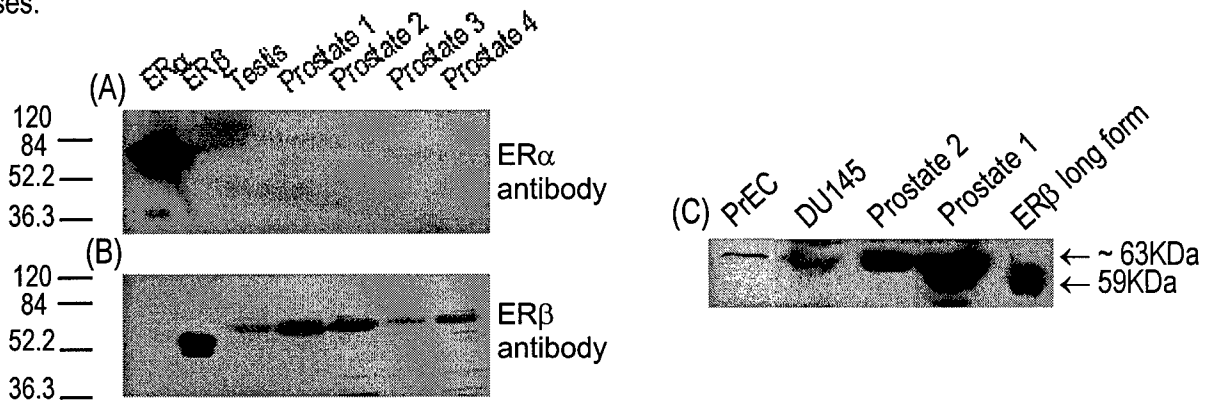


Figure 2: Western Blot Analysis: These autoradiographs illustrate the binding ability and specificity of GC-17 to ER- $\beta$  protein and its lack of cross reactivity with ER- $\alpha$  protein. (Panels A and B) Left to right: ER- $\alpha$  recombinant protein, short form of ER- $\beta$  recombinant protein, and tissue lysates from human testis and normal prostate (1-4). (Panel C) Left to right: Cell lysates of PrEC and DU145 cells, tissue lysates from human normal prostate (1-2), and long form of ER- $\beta$  recombinant protein. The recombinant proteins and cell or tissue lysates were separated with SDS-PAGE gel and the separated proteins were transferred onto PolyScreen<sup>®</sup> PVDF transfer membrane. The blot was incubated with the ER- $\alpha$  monoclonal antibody (Panel A) or GC17 ER- $\beta$  polyclonal antibody (Panels B and C) and the complexes were visualized by chemiluminescence ECL detection system followed by autoradiography. Note that the antibody detects only the ER $\alpha$  protein using ER- $\alpha$  monoclonal antibody and GC17 ER- $\beta$  polyclonal antibody does not detect the ER $\alpha$  protein but clearly identifies single bands for both forms of ER- $\beta$  recombinant proteins and for the cell or tissue lysates. These bands correspond to the reported size of the short and long forms of the receptor.

Using the GC-17 reagent we show that the ER $\beta$  receptor is predominately immunolocalized in the **nuclei of basal cells of normal ducts and acini of the human prostate** with a lesser presence in stromal cells (Figure 3). **Low/moderate grade PIN lesions were characterized by the presence of ER $\beta$  -positively stained nuclei of basal and dysplastic cells**. With progression to high grade PIN the expression of ER $\beta$  was markedly diminished (Figure 3). **Primary grade 3 carcinomas of the peripheral zone were in contrast strongly positive for the  $\beta$  receptor whereas its expression in grade 4/5 cancers was negligible to absent (Figure 4)**. In contrast, ER $\beta$  staining was almost totally absent in nuclei of grade 3 clear cell carcinomas of the transition zone (data not shown), indicating that this phenotype differs from its peripheral zone counterpart. **Significantly, strong positive immunostaining for the receptor was a constant feature in metastases to lymph nodes and bone (Figure 5)**. The results were summarized in Table 1.

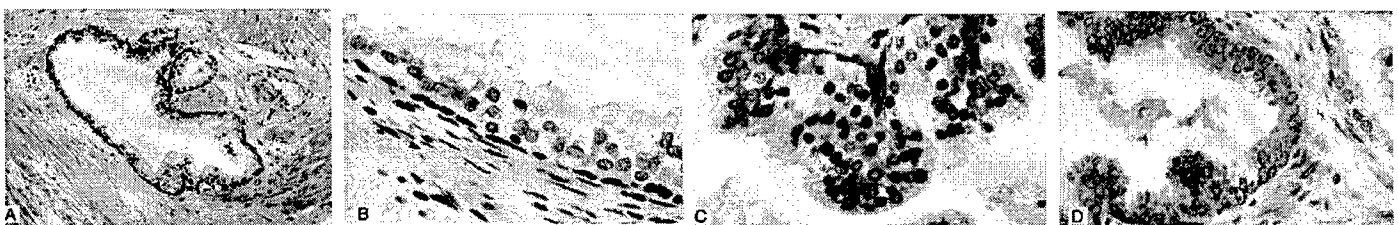


Figure 3: Panels A & B: Immunolocalization of ER- $\beta$  in the normal human prostate using the GC-17 antibody. Note the strong staining of cells in the basal layer and its virtual absence in the nuclei and cytoplasm of secretory cells (best seen in panel B). Some nuclear membrane staining was

however evident in a few secretory cells (Panels A & B). Nuclear staining is also evident in stromal cells. (X100) panel A and (X400) panel B. Panel C: ER- $\beta$  immunostaining in low/moderate grade dysplasia. Moderate to strong expression of the receptor is evident in dysplastic secretory cells. Note also the strongly stained cells in the basal layer. X 400. Panel D: ER- $\beta$  immunostained section of high-grade dysplasia. Nuclear staining is almost totally absent in this lesion. In some dysplastic cells light staining of nuclear membranes is evident. This area of the lesion is almost totally devoid of receptor stained basal cells. A few residual stained basal cells are however evident in the lower left corner of the lesion. Note the presence of two positively stained basal cells in a portion of a normal gland on the right (X250).




Figure 4: Panel A: ER- $\beta$  staining in grade 3 carcinoma: Strong nuclear immunostaining is evident in this grade 3 carcinoma. Light cytoplasmic staining of neoplastic cells is also present. Although positive immunostaining for the receptor was found in the majority of grade 3 cancers there was variation in the percent of stained cells in any given lesion. This was especially the case in areas of transition from grade to grade 4/5 carcinoma (see panel C) (X400). Panel C: ER- $\beta$  staining in an area of transition from grade 3-4/5 carcinoma. The majority of nuclei in this cancer are unstained. A few positively stained nuclei are however seen in two grade 4/5 gland (lower left corner) and in a single cell in a grade 3 gland (lower right). Light cytoplasmic staining is evident in most cells. Nuclear membrane staining is also present in many of these cells. Cytoplasmic staining was common in all grade of dysplasia and carcinoma. Nuclear membrane immunostaining was however only a feature of high grade dysplasias and grade 4/5 carcinoma (X400).




Figure 5: Panel A: ER- $\beta$  immunostaining in a prostatic carcinoma metastatic to bone. Note the strong nuclear immunostaining for the  $\beta$  receptor in this metastatic lesion. The neoplastic cells are localized between spicules of bone. Strong to moderate staining was present in the majority of metastases to bone (X400). Panel B: ER- $\beta$  immunostaining in a prostatic carcinoma metastatic to an internal iliac lymph node. Strong nuclear immunostaining is evident in this metastatic lesion. Strong PSA immunostaining of these cells were found (not illustrated). Note that the nuclei of several stromal cells in this lymph node are also positively stained for the receptor (X 400).

**Table 1: Immunohistochemical findings in dysplasias and carcinomas**

Lesion	ER- $\alpha$	ER- $\beta$	AR
<u>Dysplasia / Peripheral zone</u>			
Moderate grade*	-	+	+
High grade	-	-	+
<u>Dysplasia /Central zone*</u>	+	+	+
<u>Carcinoma/ Peripheral zone</u>			
Grade 3	-/+	+	+
Grade 4/5	-/+	-/+	+
<u>Carcinoma/ Transition zone</u>	-	-	+
<u>Metastatic carcinoma</u>			
Bone	-	+	+
Lymph nodes	-/++	+	+

\* Data reflects positive staining in dysplastic and basal cells. Staining restricted to residual basal cells in high-grade dysplasias. + = Positive staining in >50% of cases; -/++ = Positive staining in 40% of cases; -/+ = Positive staining in < 20% of cases. See text for estimates of the % of positively stained cells in each lesion.

In contrast to ER $\beta$  expression of the  $\alpha$  isoform was limited to the stromal cells of the normal human prostate. Interestingly ER $\alpha$  expression was found in dysplasias of the central zone, a region of the gland where prostate cancer is exceptionally rare (i.e. <3%). Moreover expression of the alpha-receptor was absent in all metastatic bone lesions and rare in lymph node metastases.

Expression of AR was consistently present in all dysplastic and neoplastic lesions irrespective of grade. In addition the receptor was strongly expressed in all metastatic lesions.

**RT-PCR** studies of laser microdissected grade 3 and 4/5 cancers paralleled our findings at the immunohistochemical level. Thus, we find that in **grade 4/5 carcinomas no transcripts of ER $\beta$  were evident** whereas they were strongly present in microdissected normal acini and grade 3 carcinomas (Figure 6).

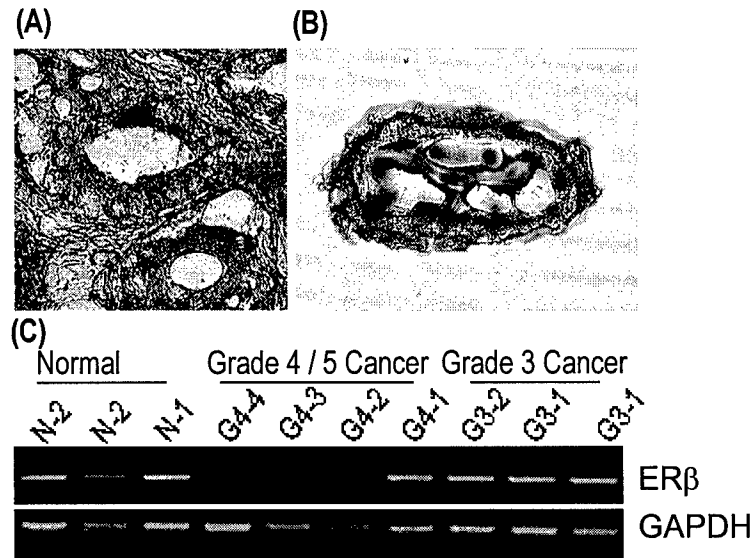


Fig. 7: Panels A & B, LCM dissection of a grade 3 carcinoma. Panel A: The grade 3 neoplastic gland that was microdissected is seen in the center of this microscopic field (X325). Panel B: The microdissected lesion is seen on the transfer cap (X325). Both sections were lightly stained with 10 % Harris hematoxylin. Panel C: Results of RT-PCR analysis of ER- $\beta$  mRNA on microdissected human normal prostate acini (N-1 and N-2) and grade 3 (G3-1 and G3-2) and 4/5 (G4-1 - G4-4) carcinomas. Total RNAs were extracted from the microdissected tissues on transfer cap and reverse-transcribed. The resultant cDNAs were subjected to PCR analyses. The amplified products were run into 2% agarose gel with ethidium bromide. Representative fluorographs for ER- $\beta$  and GAPDH RT-PCR analyses were shown.

Results from our study indicate that **prostatic carcinogenesis is characterized by a progressive loss of ER $\beta$  expression**. Taken together, with our past published report and those of others (Lau et al 2000, Kregge et al 1998) which indicate that ER $\beta$  probably acts to inhibit prostatic cell growth, the current findings are consistent with the concept that **loss of the receptor expression is permissive of progressive growth of transformed cells**. In this regard the continued expression of AR throughout the carcinogenic process would suggest that androgen action, unopposed by the inhibitory effects of ER $\beta$ , could enhance tumor progression. The reappearance of ER $\beta$  expression in metastatic foci may reflect undefined influences of the new microenvironment. If the receptor proves to be functionally intact in these foci it may be feasible to **treat patients with late stage disease with antiestrogens which we have shown to inhibit prostatic cancer cell growth *in vitro***. In this regard based on the findings from this study we will soon initiate these studies in collaboration with Astra/Zeneca pharmaceuticals Inc..

## 2. Key Research Accomplishments

- Induction of cell cycle arrest at G0-G1 phase was shown in antiestrogen-treated cells, suggesting that this alteration in cell cycle might be related to the antiestrogen-induced cell growth inhibition in prostate cancer cells.
- ER $\beta$ , but not ER $\alpha$ , expression was found in the nuclei of basal epithelial cells but not luminal cells in normal human prostate.
- ER $\beta$  expression was transiently elevated in early PIN lesions, but progressively diminished in higher grade PIN lesions.

- ER $\beta$  immunostaining was markedly diminished in Gleason grade 3 and 4 adenocarcinomas and absent in higher-grade cancers and reappeared in bone and lymph node metastases.

### 3. Reportable outcomes

**Presentations:** 1) Dr. Shuk-Mei Ho (PI). Title: *Estrogen regulation of prostate cancer growth and progression*. In: The Endocrine Society's 83<sup>rd</sup> annual meeting at Denver, CO. June 20-23, 2001. 2) Dr. Shuk-Mei Ho (PI). Title: *Novel estrogenic and antiestrogenic actions on ovarian and prostate cancer cells*. In: Hormones and Cancer 2000 meeting, Port Douglas, Australia. Nov 4-8, 2000.

**Publications and Manuscripts in preparation:** 1) Lau KM., LaSpina M., Long J and Ho, S-M Expression of estrogen receptor (ER)- $\alpha$  and ER- $\beta$  in normal and malignant prostatic epithelial cells: Regulation by methylation and involvement in growth regulation. *Cancer Research* 2000, 60:3175-3182. 2) Leav I, Lau KM, Adams J, McNeal J, Taplin ME, Wang J, Singh H and Ho, S-M. Comparative studies of the estrogen receptors  $\beta$  and  $\alpha$  and the androgen receptor in normal human prostate glands, dysplasia, and in primary and metastatic carcinoma. *American Journal of Pathology*, (in press and in July issue). 3) Lau KM and Ho S-M. Induction of G0-G1 cell cycle arrest by antiestrogens in prostate cancer cells (in preparation).

**Clinical Trials:** Dr. Mary Ellen Taplin, co-investigator, will submit a protocol for a Clinical II study to use ICI to treat advanced prostate cancer patients at our Medical Center.

### 4. Conclusion

**Our 18-month progress was on target and had generated findings/outcomes of high relevancy to the treatment and prevention of prostate cancer.** A) We demonstrated that induction of cell cycle arrest at G0-G1 phase is related to the growth inhibitory effects of antiestrogens (ICI-182,780) on DU145 which expressed a sole estrogen receptor (ER $\beta$ ). This finding raised the possibility that antiestrogens could regulate cell cycle control genes via ER $\beta$  and leads to our ongoing study of antiestrogen/ ER $\beta$  regulated genes using cDNA microarray to identify previous-unidentified cell cycle control genes which are involved in this antiestrogen-induced cell growth inhibition in DU145 cells. B) Our immunocytochemistry studies unequivocally indicated **exclusive ER $\beta$  expression in basal epithelial cells (BCs)** of the normal prostate. Its transient upregulation in low grade PIN and loss of expression in high grade PIN and carcinomas suggest that **ER $\beta$ -regulated functions may offer protection against neoplastic transformation of BCs in the normal prostate. The reappearance of ER $\beta$  expression in metastatic foci may allow to treat patients with late stage disease with antiestrogens which we have shown to inhibit prostatic cancer cell growth *in vitro*. It leads to a new clinical trial on using ICI-182,780 in advanced prostate cancer patients in our institute (see reportable outcome).**

### 5. Reference

K.M. Lau, M. LaSpina, J. Long, S.-M. Ho, *Cancer Res.* 60, 3175 (2000).  
J.H. Krege, *et al.*, *Proc. Natl. Acad. Sci. U.S.A.* 95, 15677 (1998).

### 6. Appendices

- 1). Abstract Title: *Estrogen regulation of prostate cancer growth and progression*. In: The Endocrine Society's 83<sup>rd</sup> annual meeting at Denver, CO. June 20-23, 2001.
- 2). Reprint: Lau KM., LaSpina M., Long J and Ho, S-M Expression of estrogen receptor (ER)- $\alpha$  and ER- $\beta$  in normal and malignant prostatic epithelial cells: Regulation by methylation and involvement in growth regulation. *Cancer Research* 2000, 60:3175-3182.
- 3). Reprint: Leav I, Lau KM, Adams J, McNeal J, Taplin ME, Wang J, Singh H and Ho, S-M. Comparative studies of the estrogen receptors  $\beta$  and  $\alpha$  and the androgen receptor in normal human prostate glands, dysplasia, and in primary and metastatic carcinoma. *American Journal of Pathology*, (in press and in July issue).

SHAPING THE FUTURE OF ENDOCRINOLOGY: TODAY'S RESEARCH... TOMORROW'S CARE

# PROGRAM & ABSTRACTS

THE ENDOCRINE SOCIETY'S 83RD ANNUAL MEETING

J U N E 2 0 - 2 3 , 2 0 0 1



10 **ENDO 2001**  
DENVER

 THE  
ENDOCRINE  
SOCIETY

## BASIC/CLINICAL—Nuclear Receptors in Prostate Cancer

### S64-1

#### ESTROGEN REGULATION OF PROSTATE CANCER GROWTH AND PROGRESSION

SM Ho,<sup>1</sup> KM Lau,<sup>1</sup> I Leav,<sup>2</sup> Y Chung.<sup>1</sup> <sup>1</sup>*Department of Surgery, Division of Urology, University of Massachusetts Medical School, Worcester, Massachusetts;* <sup>2</sup>*Department of Pathology, Tufts University Medical School, Boston, Massachusetts*

Normal and malignant prostatic functions are now known to be regulated by estrogens. We recently demonstrated that several prostatic cancer cell lines (DU145 and PC-3M) expressed only the estrogen receptor (ER)-beta subtype. These cell lines also expressed two estrogen-responsive genes, progesterone receptor and pS2. Their growth was curbed by antiestrogens such as tamoxifene and ICI-182,780 but not by estrogens. Treatment of these cell lines with ER-beta antisense oligonucleotide effectively reversed the growth inhibitory action of antiestrogens, thus suggesting that ER-beta mediates the action of antiestrogens. In addition, we recently developed a ER-beta-specific antibody directed against the F domain of the receptor. Using this reagent, we found that within the morphologically normal prostatic acini, ER-beta was expressed only in the basal cell compartment and not in the luminal cell compartment. It was rarely detected in stromal cells. In contrast, ER-alpha was seldom detected in basal epithelial cells but often expressed in stromal cells. Expression of ER-beta was progressively diminished in high-grade PINs as compared to low-moderate PINs. Similarly, a distinct loss of ER-beta expression was noted in high-grade 4/5 carcinoma when compared to grade 3 carcinoma. Interestingly, the majority of metastases to bone and lymph nodes exhibited strong ER-beta immunopositivity. In contrast, ER-alpha expression was absent in all PINs and uncommonly expressed in carcinomas in primary or metastatic sites. In summary, we observe downregulation of ER-beta expression occurs during prostate cancer development in the primary site but reappearance of the receptor in metastatic carcinomas. These changes in ER-beta expression may contribute to a loss in growth control regulation in normal and malignant prostatic epithelial cells. The presence of ER-beta as the predominant ER subtype in most metastases, together with our findings that antiestrogens, via ER-beta activation, inhibit cancer cell growth may be useful in devising receptor ligand-specific treatments for late stage disease. Supported in part by DAMD17-98-1-860.

# Expression of Estrogen Receptor (ER)- $\alpha$ and ER- $\beta$ in Normal and Malignant Prostatic Epithelial Cells: Regulation by Methylation and Involvement in Growth Regulation<sup>1</sup>

Kin-Mang Lau, Mark LaSpina,<sup>2</sup> John Long, and Shuk-Mei Ho<sup>3</sup>

Division of Urology, Department of Surgery, University of Massachusetts Medical School, Worcester, Massachusetts 01655 [K.-M. L., S.-M. H.], Department of Biology, Tufts University, Medford, Massachusetts 02155 [K.-M. L., M. L.] and Urological Clinic, New England Medical Center, Boston, Massachusetts 02111 [J. L.]

## ABSTRACT

The aim of the current study is to demonstrate normal and malignant prostatic epithelial cells (PrECs) as targets for receptor-mediated estrogenic and antiestrogenic action. Using an improved protocol, we have successfully isolated and maintained highly enriched populations of normal PrECs from ultrasound-guided peripheral zone biopsies, individually determined to be morphologically normal. Semiquantitative reverse transcription-PCR analyses were used to determine whether transcripts of estrogen receptor (ER)- $\alpha$  and those of ER- $\beta$  were expressed in our normal PrEC primary cultures, in a commercially available PrEC preparation (PrEC; Clontech), in an immortalized PrEC line established from a benign prostatic hyperplasia specimen (BPH-1), and in three prostatic cancer cell lines (LNCaP, PC-3, and DU145). Expression levels of ER- $\alpha$  and ER- $\beta$  transcripts were related to those of two estrogen-responsive genes [progesterone receptor (PR) and pS2], at the message levels, to gain insights into the functionality of the ER subtypes in PrECs. Interestingly, only transcripts of ER- $\beta$ , but not those of ER- $\alpha$ , were found in our primary cultures of normal PrECs, along with both PR and pS2 mRNA. These data strongly suggest that estrogen action was signaled exclusively via ER- $\beta$  in normal human PrECs. In contrast, PrEC (Clontech) and BPH-1 cells expressed both ER- $\alpha$  and ER- $\beta$  transcripts and no PR nor pS2 mRNA in PrEC and only a minimal level of PR mRNA in BPH-1. Among the three prostate cancer cell lines, LNCaP expressed ER- $\beta$  mRNA along with transcripts of PR and pS2, DU145 expressed messages of ER- $\beta$  and PR, and PC-3 cells exhibited ER- $\alpha$ , ER- $\beta$ , and pS2 mRNA. Thus, unlike normal PrECs, expression patterns of these genes in malignant PrECs are more variable.

Treatment of prostate cancer cells with demethylation agents effectively reactivated the expression of ER- $\alpha$  mRNA in LNCaP and DU145 and that of pS2 message in DU145. These findings provide experimental evidence that ER- $\alpha$  gene silencing in prostate cancer cells, and perhaps also in normal PrECs, are caused by DNA hypermethylation.

To evaluate the potential of using antiestrogens as prostate cancer therapies, we have assessed the growth-inhibitory action of estrogens (estradiol and diethylstilbestrol) and antiestrogens (4-hydroxy-tamoxifen and ICI-182,780) on PC-3 and DU-145 cells. In PC-3 cells, which express both ER subtypes, estrogens as well as antiestrogens are effective inhibitors. In contrast, in DU145 cells, which express only ER- $\beta$ , antiestrogens, but not estrogens, are growth inhibitors. By comparison, ICI 182,780 is the more effective cell growth inhibitor. Importantly, the ICI 182,780-induced antiproliferative effects were reversed by cotreatment of DU145 cells with an ER- $\beta$  antisense oligonucleotide, hence lending additional support to a central role played by ER- $\beta$  in mediating growth-inhibitory action of antiestrogens.

Received 11/24/99; accepted 4/13/00.

The costs of publication of this article were defrayed in part by the payment of page charges. This article must therefore be hereby marked *advertisement* in accordance with 18 U.S.C. Section 1734 solely to indicate this fact.

<sup>1</sup> Research was supported in part by United States Army Grant DAMD17-98-1-8606 and NIH Grants CA15776 (to S.-M. H.).

<sup>2</sup> Present address: New England College of Osteopathy, Biddeford, ME 04005.

<sup>3</sup> To whom requests for reprints should be addressed, at Division of Urology, Department of Surgery, Rm S4-746, University of Massachusetts Medical School, 55 Lake Avenue North, Worcester, MA 01655. E-mail: shuk-mei.ho@umassmed.edu.

## INTRODUCTION

Charles Huggins pioneered the use of the synthetic estrogen, DES,<sup>4</sup> in the treatment of advanced PCa in the early 1940s (1). The action of DES was thought to be mediated via a blockade of the pituitary-testicular axis, which effectively lowered circulating levels of androgen and caused tumor regression (2). However, recent investigations have demonstrated that DES exerts direct growth-inhibitory effects on prostatic cancer cells via induction of mitotic arrest or apoptosis (3-6). Unfortunately, because of serious adverse effects induced by the estrogenicity of DES (feminization, exacerbation of heart failure, vascular complications, gynecomastia, and impotence), the xenoestrogen has lost its attractiveness as a mainstay treatment for advanced PCa (7). Clinical use of TAM, a nonsteroidal estrogen mixed agonist/antagonist, was introduced in the 1980s as an alternative to DES in the treatment of PCa. It was better tolerated than DES but only produced low response rates (8-12). It was therefore concluded that further investigation of TAM in advanced PCa treatment was not warranted. Of late, two recent developments have rekindled interests in using antiestrogens as therapeutics for PC: (a) pure estrogen antagonists (e.g., ICI-164,384 and ICI-182,780; Ref. 13) and selective estrogen receptor modulators, such as raloxifene (14), have become available for clinical trials. Experimental evidence suggests that their mechanisms of action may differ significantly from those of estrogens (15-18) and therefore may yield more favorable outcomes; and (b) a newly discovered ER subtype (ER- $\beta$ ) was found to be expressed at high levels in the epithelial compartments of the rat prostate (19-23). Although ER- $\beta$  shares high homology with the classical ER (ER- $\alpha$ ), the two ER subtypes may regulate different sets of cellular functions (18, 24). Recent findings from an ER- $\beta$  knockout mouse suggest that ER- $\beta$  may suppress proliferation and prevent hyperplasia in the rodent prostate (25). Taken together, these new findings raise an intriguing possibility that ER- $\beta$  is expressed in normal and/or malignant human PrECs and plays a role in mediating estrogen action in these cell types.

Knowledge of the distribution of ER- $\beta$  in normal and malignant human PrECs is limited at this time. A recent study reported a lack of ER- $\beta$  expression in human prostate tissues (26), whereas several preliminary reports noted expression of this receptor subtype in basal epithelial cells of the human (27-29). In this study, we reported the development of an effective method to obtain and culture "pure" or highly enriched populations of normal PrECs from needle biopsies of the peripheral zone of the human prostate. Expression levels of ER- $\alpha$  and ER- $\beta$  transcripts in our primary cultures of normal PrECs were compared with those found in a PrEC preparation obtained from a commercial source (PrEC; Clontech), in an immortalized PrEC cell line established from a BPH specimen (BPH-1; Ref. 30), and in three prostatic cancer cell lines (DU145, PC-3, and LNCaP). Expression

<sup>4</sup> The abbreviations used are: DES, diethylstilbestrol; PCa, prostatic adenocarcinoma; TAM, tamoxifen; ER, estrogen receptor; E<sub>2</sub>, 17 $\beta$ -estradiol; PrEC, prostatic epithelial cell; BPH, benign prostatic hyperplasia; PR, progesterone receptor; 4OH-TAM, 4-hydroxy-TAM; ICI, ICI-182,780; ODN, oligodeoxynucleotide; FBS, fetal bovine serum; P/S, penicillin/streptomycin; RT-PCR, reverse transcription-PCR; GAPDH, glyceraldehyde-3-phosphate dehydrogenase; AR, androgen receptor.

levels of ER- $\alpha$  and ER- $\beta$  in normal and malignant PrECs were then related to the transcript expression levels of two estrogen-responsive genes (PR and pS2) to gain insights into the functionality of the ER subtypes. Additionally, we have compared the efficacy of two estrogens (DES and E<sub>2</sub>) to those of two antiestrogens (4OH-TAM and ICI) in inhibiting cell growth in PC-3 and DU145 cells. An ER- $\beta$  antisense ODN was then used to demonstrate that the antiestrogen-induced growth-inhibitory effects on prostate cancer cells were mediated via an ER- $\beta$  signaling mechanism. Finally, we provided the first experimental evidence in support of DNA methylation-mediated transcriptional inactivation of gene expression as the mechanism of ER- $\alpha$  silencing in PrECs.

## MATERIALS AND METHODS

**Establishment of Normal PrECs in Primary Cultures.** Tissue specimens used for generating primary cultures of normal PrECs were obtained from patients undergoing transrectal ultrasound-guided biopsies of the prostate for standard clinical indications. All patients contributing biopsy material were invited to participate in a prospective tissue acquisition study approved by the local Institutional Review Board (approval was granted to J. L. at the New England Medical Center). Written informed consent was obtained prior to biopsy from participating patients. From each participant, one biopsy core was obtained from the peripheral zone of the prostate, placed on a sponge pad soaked in sterile saline; a 1–2-mm section was excised from the midportion of the core and suspended in 5 ml of culture medium (described below). The two remaining ends of the core were inked at the ends opposite the sectioned midportion piece, placed in 10% formalin, and processed for histology. Histological examination of the end pieces of a biopsy core allowed us to determine the histological nature and the homogeneity of the core. Only specimens judged to be histologically normal, with no hyperplastic or neoplastic tissue contamination, were used to establish primary cultures of normal PrECs.

Each harvested tissue specimen was then washed three times with HBSS and cut into five to seven smaller pieces. The pieces were suspended in 2 ml of freshly prepared growth medium (see below) and transferred to a 60-mm Falcon culture dish (Becton Dickinson, Lincoln Park, NJ) coated with type I rat tail collagen (Collaborative Biomedical Products, Bedford, MA). An epithelial cell selection medium (the growth medium), reported previously (31), consisted of keratinocyte serum-free medium with 25  $\mu$ g/ml bovine pituitary extract, 5 ng/ml epidermal growth factor, 2 mM L-glutamine, 10 mM HEPES buffer, P/S (100 units/ml penicillin and 100  $\mu$ g/ml streptomycin), 5.5  $\mu$ l/ml fungizone, 20 ng/ml cholera toxin, and 1% heat-inactivated FBS was used to obtain enriched populations of PrECs. All culture reagents were obtained from Life Technologies, Inc. (Grand Island, NY) except for FBS, which was purchased from Sigma Chemical Co. (St. Louis, MO). The culture was incubated at 37°C in a 5% CO<sub>2</sub> atmosphere without disturbance for 7 days to allow epithelial cells to grow out of the tissue pieces. Culture medium was then routinely replaced every 4 days until cell culture reached ~80% confluence. The cells were split once before they were used for RNA extraction.

In addition to primary cultures obtained from biopsy explants, a batch of normal human PrECs were purchased from Clonetics Co. (San Diego, CA). The PrEC cells were cultured in the PrEGM medium (Clontech) supplemented with SingleQuots (Clonetics Co.) according to the manufacturer's recommended protocol.

**Maintenance of Established Prostatic Cell Lines.** All culture reagents were obtained from Life Technologies and FCS (St. Louis, MO), except otherwise specified. BPH-I (30), a nontumorigenic, SV40-immortalized, highly differentiated human prostate epithelial cell line, was provided as a gift by Dr. Simon Hayward at the University of California (San Francisco, CA). This cell line was maintained in RPMI 1640 with 10 mM HEPES, 1 mM sodium pyruvate, 2 mM L-glutamine, 4.5 g glucose/l, and 1.5 g of sodium bicarbonate/L (American Type Culture Collection, Rockville, MD) plus 5% heat-inactivated FBS, ITS (insulin-transferrin-selenium mixture; Collaborative Biomedical Research, Bedford, MA), and P/S. Three human prostate cancer cell lines (DU145, PC-3, and LNCaP) were purchased from American Type Culture Collection. For routine maintenance, DU145 and PC-3 cells were

grown in DMEM/F-12 supplemented with heat-inactivated FBS, 2 mM L-glutamine, 1 mM sodium pyruvate, 0.1 M nonessential amino acids, P/S, 0.05 mM  $\beta$ -mercaptoethanol (Sigma), and 1% ITS+. LNCaP cells were maintained in the same medium used for BPH-1 except that ITS+ was left out from the medium. All cell cultures were incubated at 37°C under a 5% CO<sub>2</sub> atmosphere.

**RNA Isolation and RT-PCR.** Total cellular RNA was isolated using RNA Stat-60 reagent (Tel-Test, Inc., Friendswood, TX) according to protocols provided by the manufacturer. The quality of each total RNA sample was checked and controlled by the following steps: (a) measurement of absorbance; (b) running of a denaturing RNA gel capable of detecting possible RNA degradation, as judged by the integrity and intensity of the 18S and the 28S rRNA signals; and (c) conducting a semiquantitative RT-PCR for the 18S rRNA at low cycle numbers. One  $\mu$ g of total cellular RNA was reverse transcribed using the GeneAmp RNA PCR kit (Perkin-Elmer, Norwalk, CT), and 2  $\mu$ l of the resulting cDNA were used in each PCR.

Intron-spanning primers were either obtained from published literature or designed using the Primer3 Output program.<sup>5</sup> Primer sequences for GAPDH, ER- $\alpha$  (primer set #1, exon 1–3), ER- $\beta$ , PR, and AR are given in Table 1. All PCR conditions were optimized for quantification of relative message contents under nonsaturating conditions. Preliminary experiments were conducted to ensure linearity for all semiquantitative procedures. Hot-start PCR using AmpliTaq Gold DNA polymerase (Perkin-Elmer) was used in all amplification reactions. The enzyme was activated by preheating the reaction mixtures at 95°C for 6 min prior to PCR. This protocol was chosen to minimize nonspecific product amplification. The routine PCR program was 30 cycles of 1 min at 94°C, 1 min at 60°C (annealing temperature), and 1 min at 72°C with the following modifications: (a) amplification for ER- $\beta$  cDNA used an annealing temperature of 58°C; (b) amplifications of ER- $\alpha$  cDNA and AR cDNA were carried out at an annealing temperature of 55°C; (c) cycle number for ER- $\alpha$  cDNA amplification was set at 35; and (d) GAPDH cDNA was amplified at 26 cycles. GAPDH cDNA levels served as a loading control. Amplification of the correct sequence was verified by direct DNA sequencing of each PCR product from at least two different samples.

To further confirm that primary cultures of normal PrECs and certain prostate cancer cell lines did not express ER- $\alpha$  mRNA (see "Results"), we used two additional pairs of primers (primer sets #2 and #3, Table 1) to amplify regions downstream of the coding sequence of ER- $\alpha$  (668 bp of exon 3–6 and 710 bp of exon 5–8, respectively). Together, these three pairs of ER- $\alpha$  primers (Table 1) covered most of the length of the coding sequence. They had been used successfully in our recent study on the expression of ER- $\alpha$  mRNA in ovarian cancer (32). If PCR at high cycle number failed to yield products from all three pairs of primers, we considered the sample to be devoid of ER- $\alpha$  cDNA.

**Treatment of DU145, PC-3, and LNCaP Cells with Demethylating Agents.** The three prostatic cancer cell lines were seeded at a density of 10<sup>4</sup> cells/ml medium in 25-cm<sup>2</sup> culture flasks, allowed to attach during a 24-h period, and exposed to two demethylating agents separately. The demethylating agents were added daily in aqueous solution. 5'-Azacytidine was added at final concentrations of 2.5 and 5  $\mu$ M and 5'-aza-2'-deoxycytidine at 0.5 and 0.75  $\mu$ M, respectively. Culture medium was changed every 4 days, and cells were subjected to a total of 8 days of demethylating agent treatment. At the end of the treatment period, the medium was removed, and cellular RNA was extracted for RT-PCR.

**Treatment of DU145 and PC-3 Cells with Estrogens/Antiestrogens.** Cells were seeded at a density of 5  $\times$  10<sup>3</sup> per ml into 24-well plates (Falcon; Becton Dickinson Labware, Lincoln Park, NJ) in a final volume of 1 ml of culture medium with 5% charcoal-stripped FBS. Twenty-four h after seeding, triplicate wells of cells were treated in with 1, 10, and 100  $\mu$ M of E<sub>2</sub>, DES, 4OH-TAM, or ICI. E<sub>2</sub>, DES, and 4OH-TAM were purchased from Sigma, and ICI was a generous gift from Zeneca Pharmaceuticals (Macclesfield, United Kingdom). Estrogens and antiestrogens were dissolved in absolute ethanol (Sigma) and added to the media daily. Cell cultures that were not treated with estrogenic compounds received absolute ethanol as a vehicle control. Total additive ethanol concentrations never exceeded 0.2% throughout the culture period. The cells were refed with freshly prepared medium every other day. At the end of a 4-day treatment period, cells in each well were trypsinized, and

<sup>5</sup> Internet address: <http://www.genome.wi.mit.edu/cgi-bin/primer/primer3.cgi>.

Table 1 Primer sequences for the RT-PCR analysis

Target gene	Primer sequence	Location (nt) <sup>a</sup>	Expected size
ER- $\beta$	ER $\beta$ -1: 5'-TGA AAA GGA AGG TTA GTG GGA ACC-3'	230-253	528 bp
	ER $\beta$ -2: 5'-TGG TCA GGG ACA TCA TCA TGG-3'	737-757	
ER- $\alpha$	ER $\alpha$ -1: 5'-TAC TGC ATC AGA TCC AAG GG-3'	41-60	650 bp
	ER $\alpha$ -2: 5'-ATC AAT GGT GCA CTG GTT GG-3'	671-690	(exon 1-3)
	ER $\alpha$ -3: 5'-GTG GGA ATG ATG AAA GGT GG-3'	742-761	668 bp
	ER $\alpha$ -4: 5'-TCC AGA GAC TTC AGG GTG CT-3'	1390-1409	(exon 3-6)
	ER $\alpha$ -5: 5'-GTG CCT GGC TAG AGA TCC TG-3'	1142-1161	710 bp
	ER $\alpha$ -6: 5'-TGG TGC ATG ATG AGG GTA AA-3'	1832-1851	(exon 5-8)
PR	PR-1: 5'-GAT TCA GAA GCC AGC CAG AG-3'	1817-1836	533 bp
	PR-2: 5'-TGC CTC TCG CCT AGT TGA TT-3'	2330-2349	
pS2	pS2-1: 5'-GGA GAA CAA GGT GAT CTG CG-3'	52-71	236 bp
	pS2-2: 5'-CAC ACT CCT CTT TTG GAG GG-3'	268-287	
AR	AR-1: 5'-CTC TCT CAA GAG TTT GGA TGG CT-3'	2896-2918	342 bp
	AR-2: 5'-CAC TTG CAC AGA GAT GAT CTC TGC-3'	3214-3237	
GAPDH	GAPDH-F: 5'-CCA CCC ATG GCA AAT TCC ATG GCA-3'	152-175	598 bp
	GAPDH-R: 5'-TCT AGA CGG CAG GTC AGG TCC ACC-3'	726-749	

<sup>a</sup> nt, nucleotide.

cell count was determined by direct counting using the trypan blue exclusion method. All treatment experiments were repeated at least three times to generate statistically relevant data.

**Treatment of DU145 Cells with ICI and ER- $\beta$  Antisense ODN.** DU145 cells ( $5 \times 10^3$  cells/well) were plated in 24-well plates (Falcon; Becton Dickinson Labware). After allowing 24 h for cell attachment, cell cultures were treated in triplicate with  $1 \mu\text{M}$  of ICI in the presence of  $2.5 \mu\text{M}$  ER- $\beta$  antisense, sense, or mismatch ODNs for 4 days. The ER- $\beta$  antisense ODN, an 18-mer, was designed to recognize the first translation start site on the ER- $\beta$  mRNA and its immediate 5' flanking region (Table 2). The nucleotide sequence of sense ODN is complementary to those of ER- $\beta$  antisense ODN (Table 2). On the basis of the sequence of ER- $\beta$  antisense ODN, five nucleotides were scrambled to generate a mismatch ODN that retains the same GC ratio of the ER- $\beta$  antisense ODN (Table 2). Both the sense and the mismatch ODNs served as controls for the antisense ODN. In all three ODNs, the first and the last three nucleotides were phosphorothioate modified to increase their stability *in cellulo*. The number of viable cells in each well was determined by direct counting using the trypan blue exclusion method after a 4-day treatment period. At least three individual experiments were performed to obtain statistically relevant data.

**Statistics.** Statistical analysis was performed by using Student SYSTAT software (Course Technology, Inc., Cambridge, MA). Data were analyzed by one-way ANOVA, followed by the Tukey post-hoc test, and a 95% confidence limit was used for all comparisons among treatment groups.

## RESULTS

**Expression of AR, ER- $\beta$ , PR, and pS2 mRNA, but not ER- $\alpha$  Transcripts, in Normal PrECs in Primary Cultures.** Five primary cultures of normal PrECs (N4#6, N3#5, N3#4, N2#3, and N2#2) were established in our laboratory from ultrasound-guided peripheral zone biopsies over a period of 18 months. The biopsy cores were all judged upon histological examination to contain only normal prostatic tissue with no BPH or cancerous foci contamination. The primary cell cultures were all early passages (second or third), cobblestone in appearance, with no visible fibroblast contamination. Semiquantitative RT-PCR analyses (Fig. 1) demonstrated that our normal PrEC cultures retained high levels of AR mRNA expression, which usually disappeared in late-passage normal PrEC primary cultures or in established PrECs (33). Interestingly, all five cultures of normal PrECs expressed uniform levels of ER- $\beta$  RNA and transcripts of the estrogen-responsive genes, PR and pS2. In contrast, expression of ER- $\alpha$  mRNA was noticeably absent in all five cultures, even when high cycle number PCR (>42 cycles) was used to amplify the cDNA. Interestingly, PrEC (Clonetics Co.), a commercially prepared normal PrEC culture, and BPH-1, a SV40 immortalized prostatic epithelial cell line, expressed both ER- $\alpha$  and ER- $\beta$ , but no PR or pS2 transcripts in PrEC (Clontech), and only a minimal level of PR mRNA in BPH-1.

**Expression of ER- $\beta$ , ER- $\alpha$  PR, and pS2 mRNA in Prostatic Cancer Cell Lines.** All three prostatic cancer cell lines, DU145, PC-3, and LNCaP, express ER- $\beta$  mRNA (Fig. 1, a and c). In contrast, ER- $\alpha$  mRNA was expressed only in the PC-3 cells. Interestingly, PR transcripts were detected only in DU145 and LNCaP cells and not in PC-3 cells. Messages of pS2 were found in PC-3 and LNCaP cells but not in DU145 cells. In accordance with reports in the literature, AR mRNA expression was only noted in LNCaP cells.

**Expression of ER- $\alpha$  Variant in Prostate Cell Lines.** When RT-PCR analyses were conducted for ER- $\alpha$  mRNA semiquantification in PrEC (Clonetics Co.), BPH-1, or PC-3 cells, we noticed that, in addition to the expected PCR product, a smaller PCR product was coamplified (Fig. 1, a and b). Sequencing analysis (data not shown) revealed that this smaller PCR product was derived from an ER- $\alpha$  mRNA variant that had the entire exon 2 deleted. We reported recently the coexistence of this ER- $\alpha$  mRNA variant with wild-type transcripts in normal and malignant human ovarian surface epithelial cells (33).

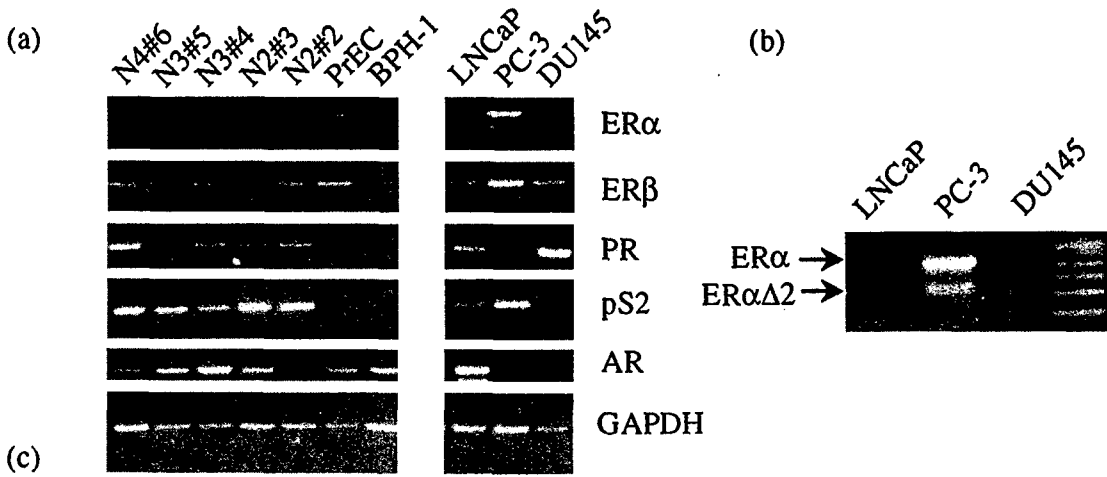
**Demethylation Reactivates ER- $\alpha$  and pS2 mRNA Expressions in DU145 Cells and ER- $\alpha$  Expression in LNCaP Cells.** Prior to exposure to demethylating agents, ER- $\alpha$  and pS2 transcripts were not detected in RNA samples prepared from DU145 cells (Fig. 1, a and c, and Fig. 2). After the 8-day treatment with 5'-aza-cytidine ( $2.5$  and  $5 \mu\text{M}$ ) or 5'-aza-2'-deoxycytidine ( $0.5$  and  $0.75 \mu\text{M}$ ), DU145 cells regained expression of both transcripts (Fig. 2). Interestingly, the absence of AR mRNA expression in DU145 cells was not reversed by treatment with demethylating agents. Exposure of LNCaP cells to demethylating agents also reactivated ER- $\alpha$  mRNA expression (data not shown).

**Effect of Antiestrogens and Estrogens on Cell Growth of DU145 and PC-3 Cells.** Cell growth analyses showed that the growth of DU145 cells, which only expressed ER- $\beta$  mRNA, was adversely effected by the antiestrogens ICI and 4OH-TAM (Fig. 3, A and B). A dose-dependent inhibition of cell numbers was observed in cultures exposed to ICI for 4 days when compared with control cultures treated with vehicle (absolute ethanol). A 40% reduction ( $P < 0.001$ ) in the cell numbers was achieved with an ICI dose of  $1 \mu\text{M}$ . A similar

Table 2 Oligonucleotide sequences for the antisense ODN experiments

Target gene	Sequences	Location <sup>a</sup>	Size
ER- $\beta$			
Antisense	5'-C <sup>b</sup> A <sup>b</sup> T <sup>b</sup> CAC AGC AGG GCT A <sup>b</sup> T <sup>b</sup> A <sup>b</sup> -3'	-15 to +3	18 bp
Sense	5'-T <sup>b</sup> A <sup>b</sup> T <sup>b</sup> AGC CCT GCT GTG A <sup>b</sup> T <sup>b</sup> G <sup>b</sup> -3'		
Mismatch	5'-G <sup>b</sup> A <sup>b</sup> T <sup>b</sup> CTC AGC AGG GCA A <sup>b</sup> A <sup>b</sup> T <sup>b</sup> -3'		

<sup>a</sup> The first base of translation-initiating site is +1.<sup>b</sup> This base was phosphorothioate modified.



N4#6	N3#5	N3#4	N2#3	N2#2	PrEC	BPH-1	LNCaP	PC-3	DU145	Sample
-	-	-	-	-	+	+	-	+	-	ER $\alpha$
+	+	+	+	+	+	+	+	+	+	ER $\beta$
+	+	+	+	+	-	-/+	+	-	+	PR
+	+	+	+	+	-	-	+	+	-	PS2
+	+	+	+	+	+	+	+	-/+	-	AR

Fig. 1. Results of RT-PCR analyses of ER- $\alpha$ , ER- $\beta$ , PR, pS2, and AR mRNAs among normal and malignant prostatic epithelial cells. Total RNAs were extracted and reverse transcribed. The resultant cDNAs were subjected to PCR analyses under optimized conditions. The amplified products were run into 2% agarose gel with ethidium bromide. Three individual experiments were performed. *a*, representative fluorographs for ER- $\alpha$ , ER- $\beta$ , PR, pS2, AR- and GAPDH RT-PCR analyses. *b*, an excerpt from the ER- $\alpha$  fluorograph, enlarged to illustrate the exon 2 deletion variant of ER- $\alpha$  (ER $\alpha$  $\Delta$ 2) in PC-3 cells. *c*, a summary of the data from RT-PCR analyses performed in three individual experiments. +, detectable level of expression; -, undetectable level of expression.

growth-inhibitory response was observed when DU145 cells were treated with 4OH-TAM. However, cell number reduction achieved with 1  $\mu$ M 4OH-TAM was only ~25% ( $P < 0.001$ ). In contrast, exposure of DU145 cells to 1  $\mu$ M estrogens ( $E_2$  and DES) did not

affect cell growth in 4-day exposure experiments (Fig. 3, C and D). However, in a separate series of experiments, DU145 cells were treated with 10  $\mu$ M DES, and we observed a significant reduction in cell number (data not shown). Furthermore, we had conducted competition experiments to determine whether  $E_2$  could reverse the growth-inhibitory effects induced by ICI and 4OH-TAM. DU145 cells were treated with 10<sup>-6</sup> M ICI or 4OH-TAM in the absence or presence of 10<sup>-8</sup>, 10<sup>-7</sup>, 10<sup>-6</sup> M  $E_2$ .  $E_2$  at all three concentrations was unable to reverse the ICI- or 4OH-TAM-induced cell growth inhibition (data not shown).

When PC-3 cells, which expressed transcripts of both ER subtypes, were exposed to antiestrogens (ICI and 4OH-TAM), a 25–30% reduction in cell growth was noted in cultures treated with 1 or 10  $\mu$ M of ICI or with 1  $\mu$ M 4OH-TAM ( $P < 0.001$ ; Fig. 4, A and B). Furthermore, exposure of PC-3 cells to  $E_2$  at 1 or 10  $\mu$ M concentrations also induced inhibition of cell growth ( $P < 0.05$  and  $P < 0.01$ , respectively; Fig. 4C). Interestingly, treatment with DES at the various concentrations up to 10<sup>-6</sup> M did not elicit statistically significant cell growth inhibition in PC-3 cells (Fig. 4D). However, in a separate experiment, PC-3 cells were treated with 10  $\mu$ M DES, and we observed a significant reduction in cell number (data not shown). Additionally, we had conducted competition experiments to determine whether DES could reverse the growth-inhibitory effects induced by ICI and 4OH-TAM. PC-3 cells were treated with 10<sup>-6</sup> M ICI or 4OH-TAM in the absence or presence of 10<sup>-8</sup>, 10<sup>-7</sup>, or 10<sup>-6</sup> M of DES. DES was able to reverse the ICI-induced, but not 4OH-TAM-induced, cell growth inhibition in a dose dependent manner (data not shown).

**Reduction of ICI-induced Cell Growth Inhibition by ER- $\beta$  Antisense ODN.** Treatment of DU145 cells were with ICI at 1  $\mu$ M induced a 40% reduction in cell number (Fig. 3). Cotreatment of DU145 cells with ICI and an ER- $\beta$  antisense ODN led to restoration of cell number ( $P < 0.001$ ; Fig. 5) whereas cotreatments with an ER- $\beta$  sense ODN or a mismatch ODN (Table 2) did not reverse the ICI-induced effects. These data support the notion that the ICI-

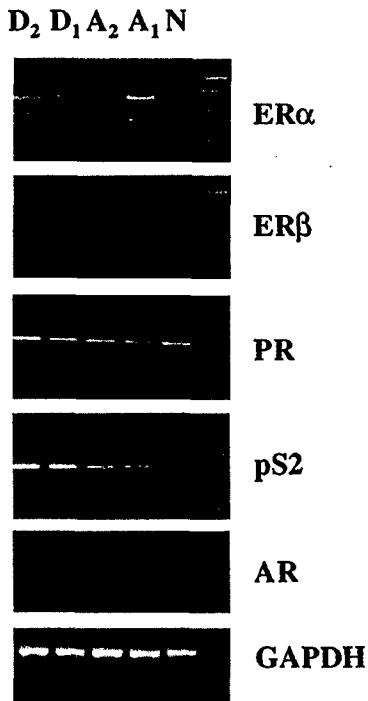


Fig. 2. Reactivation of ER- $\alpha$  and pS2 mRNA expression in DU145 cells by demethylating agents. Cells were treated with either 2.5  $\mu$ M ( $A_1$ ) or 5  $\mu$ M ( $A_2$ ) 5'-aza-cytidine or 0.5  $\mu$ M ( $D_1$ ) or 0.75  $\mu$ M ( $D_2$ ) 2'-deoxy-5'-aza-cytidine for 8 days. Cells without treatment were used as control (N). At the end of treatment, total RNAs were extracted and subjected to RT-PCR analyses as described in Fig. 1.

## Treatment of antiestrogens on DU145 cells

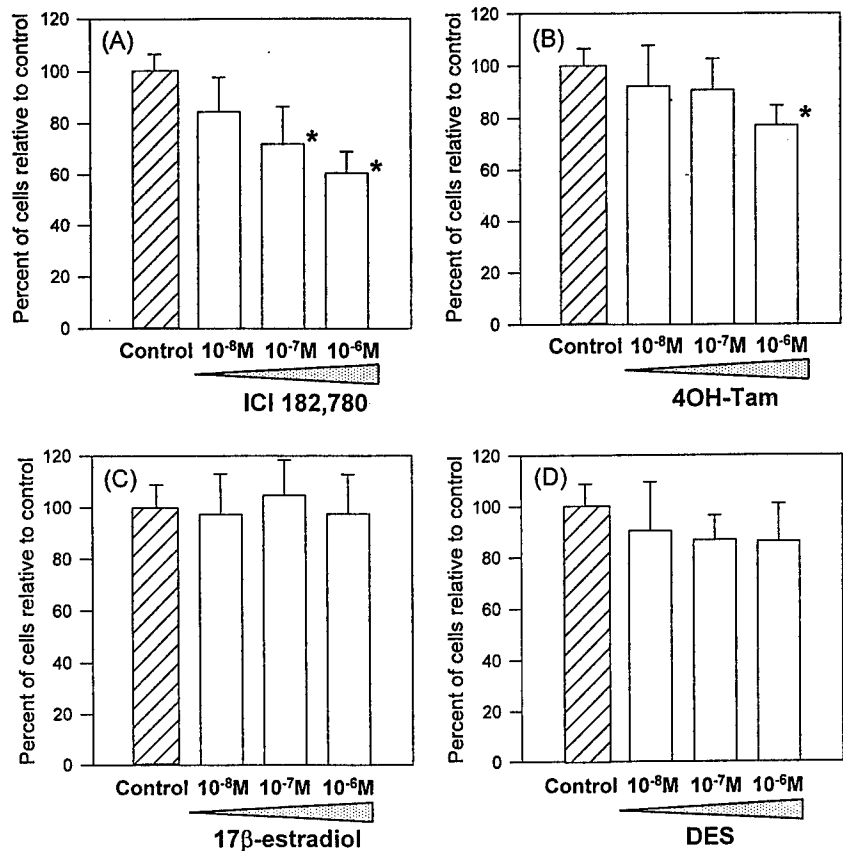


Fig. 3. Effects of antiestrogens and estrogens on cell growth of DU145 cells. Cells ( $5 \times 10^5$  cells/well) were plated in triplicate wells onto a 24-well plate. After 24 h for cell attachment, cells were treated for 4 days with antiestrogens (A, ICI and B, 4OH-TAM) or estrogens (C, E<sub>2</sub> and D, DES) at various concentrations as indicated. Cells treated with vehicle (absolute ethanol) were used as control. The number of viable cells at the end of 4 days of treatment was determined by the trypan blue exclusion method. Three individual experiments were performed. Columns, means; bars, SD;  $n = 9$ ; \*,  $P < 0.001$  compared with control (▨).

induced cell growth inhibition in DU145 cells is mediated via an ER- $\beta$  signaling mechanism.

## DISCUSSION

The roles played by estrogens in the neoplastic transformation of PrECs as well as in PCa progression and treatment remain controversial. Exposure of humans or rodents to estrogens induces a proliferative lesion, squamous metaplasia, in their prostates (34–37), whereas prolonged treatment of Noble rats with androgen plus estrogen causes a high incidence of PCa in the dorsolateral prostates of the treated animals (38–41). Paradoxically, DES, TAM, and other estrogens have been used as treatment regimens for advanced metastatic PCa (1, 7–12, 42, 43). In addition to acting as chemical castration agents, both estrogen and antiestrogen are believed to exert direct growth-inhibitory effects on prostatic cancer cells via induction of apoptosis or cell cycle arrest (3–6, 44). Precisely how estrogens/antiestrogens elicit these actions remains uncertain.

Traditionally, the actions of estrogens/antiestrogens are thought to be mediated via the classical ER, the  $\alpha$  subtype, which has been localized to the stromal compartment and basal epithelial cells of human and rodent prostates (22, 26, 45–48). Because ER- $\alpha$  is not expressed in the normal glandular epithelium of rat or human prostate (4, 21, 26, 46–49), it is widely believed that the action of estrogen/antiestrogen on normal PrECs is indirect, likely mediated via estrogen-induced stromal factors. However, after the discovery of ER- $\beta$  (19) and its localization to the epithelial compartment of rodent prostates (19, 21, 50), a distinct possibility has been raised that estrogen/antiestrogen could influence PrEC function via an ER- $\beta$  signaling pathway. However, at present, information on ER- $\beta$  in human PrECs is limited. Only one recent study (26) has evaluated the

expression pattern of ER- $\beta$  transcripts and proteins in human prostatic tissues and found nondetectable levels in both normal and diseased tissues. In contrast, the present study unequivocally demonstrated expression of ER- $\beta$  mRNA in highly enriched or pure human PrEC cultures established from peripheral zone biopsies. Furthermore, because ER- $\alpha$  message was undetectable but transcripts of two estrogen-dependent genes, *PR* and *pS2*, were expressed in these cultures, these data strongly suggest that ER- $\beta$  is the cellular mediator of estrogen action in normal human PrECs. Of interest to note is that both ER- $\alpha$  and ER- $\beta$  mRNA, but not *PR* or *pS2* transcripts, were expressed in a PrEC preparation purchased from a commercial source (PrEC; Clontech) and in the immortalized PrEC line, BPH-1, with only a minimal level of *PR* transcripts. The discrepancies between ER subtype, *PR*, and *pS2* expression in our primary PrEC cultures and those observed in PrEC (Clontech) and BPH-1 could be attributable to the tissue of origin of these cell cultures/lines. In this regard, PrEC cultures (Clontech) are routinely prepared from whole prostates, and BPH-1 was derived from a benign hyperplastic specimen (30), whereas our primary cultures were established from ultrasound-guided peripheral zone biopsies.

Issues relating to whether ER, and which subtype, is expressed in cancerous PrECs remain unsettled. Several investigators (51, 52) observed ER- $\alpha$  expression in human prostate cancer cell lines, including LNCaP, PC-3, and DU-145, whereas others (53) did not. Similarly, observations on ER- $\alpha$  expression in prostate cancer specimens were equally controversial. Bonkhoff *et al.* (26) reported recently that ER- $\alpha$  expression was infrequent in low-to-moderate grade adenocarcinoma but common in high-grade and metastatic cancers. Conversely, Konishi *et al.* (54) noted the presence of ER- $\alpha$  immunopositivity in well-differentiated adenocarcinomas but not in poorly

## Treatment of antiestrogens on PC-3 cells

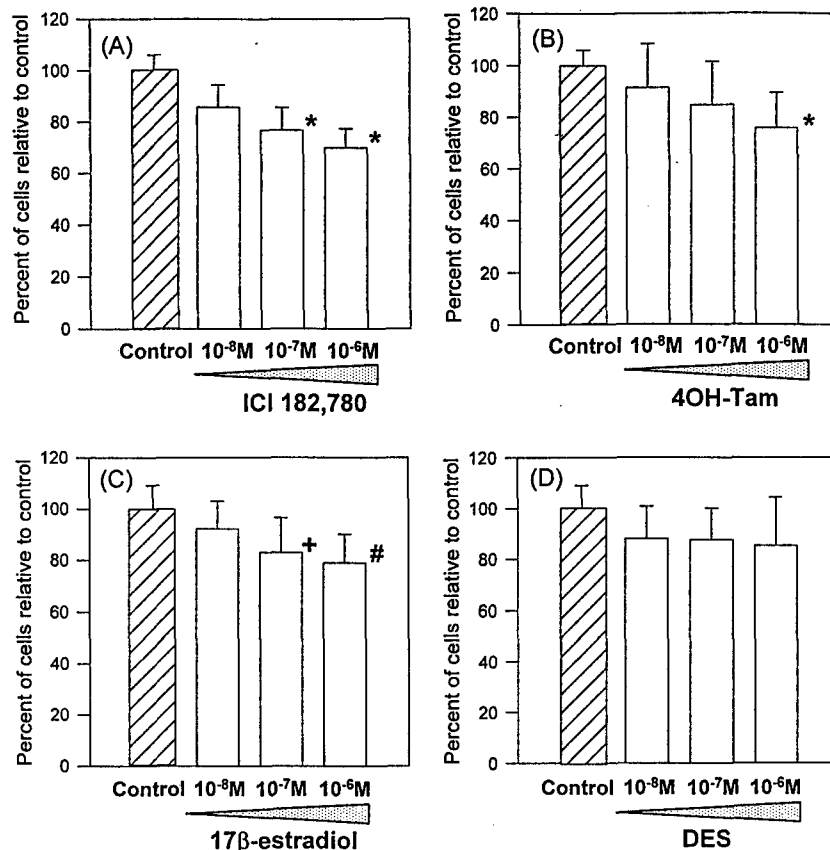


Fig. 4. Effects of antiestrogens and estrogens on cell growth of PC-3 cells. Cell growth assay was described in Fig. 3. A, ICI. B, 4OH-TAM. C, E<sub>2</sub>. D, DES. Columns, means; bars, SD;  $n = 9$ ; \*,  $P < 0.001$ ; #,  $P < 0.01$ ; +,  $P < 0.05$ ; compared with control (▨).

differentiated specimen. The latter observation was supported by two additional studies that reported no ER- $\alpha$  expression in lymph node and distant metastases (53, 55). These issues become more convoluted when the expression pattern of ER- $\beta$  is taken into consideration. A lack of ER- $\beta$  expression in human prostate tissues was reported by Bonkhoff *et al.* (26), whereas several preliminary reports noted expression of this receptor subtype in dysplastic and cancerous tissues

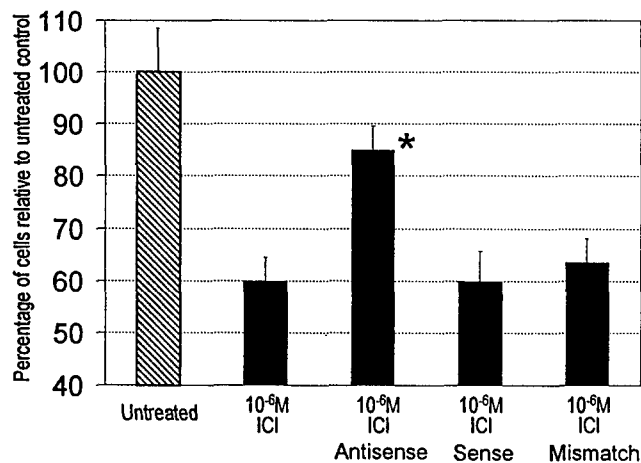


Fig. 5. Reversal of ICI-induced DU145 cell growth inhibition by ER- $\beta$  antisense ODN. Cells were treated with ICI at 10<sup>-6</sup> M in the absence or presence of 2.5  $\mu$ M of the antisense, sense, or mismatch ODNs for 4 days. Cell numbers in "untreated" cultures received no ICI treatment and were arbitrarily assigned a value of 100% (first column on the left). Cell numbers in cultures treated with ICI and ICI plus ODNs were expressed as percentages of cell numbers in the "untreated" cultures. Columns, means; bars, SD;  $n = 16$ . \*, significant difference between ICI-treated cultures and those that received ICI plus the antisense ODN at  $P < 0.001$ .

(27–29). Findings in the present study revealed that ER- $\beta$  mRNA was expressed in all three cancer cell lines (PC-3, DU145, and LNCaP), although in accordance with the literature, the ER- $\alpha$  message was only detected in PC-3 cells (51). Unlike primary PrEC cultures, which uniformly expressed both PR and pS2 transcripts, PR mRNA expression was only detected in DU145 and LNCaP cells whereas pS2 transcripts were found in PC-3 and LNCaP cells. Hence, despite uniform expression of ER- $\beta$ , the expression patterns of ER- $\alpha$ , PR, and pS2 among these prostatic cancer cell lines was variable. Because transcription of PR and pS2 is well recognized to be regulated by estrogen (56–58), the loss of expression of these two genes in some prostatic cancer cell lines suggests a deregulation of estrogen signaling in these cells. A similar phenomenon has been observed in ovarian cancer cell lines that express both ER subtype but no PR (33).

Until now, it remains unknown as to why prostatic epithelium expresses only ER- $\beta$  and not ER- $\alpha$ . In the present study, we demonstrated that treatment of DU145 and LNCaP cells with demethylating agents reactivated ER- $\alpha$  expression in these cells. These data provide the first experimental evidence in support of DNA methylation-mediated gene silencing (59, 60) as a mechanism of ER- $\alpha$  inactivation in PrECs. In breast cancers, it had been shown that hypermethylation of the promoter region of ER- $\alpha$  was associated with loss of expression of this receptor subtype in hormone-refractory cancers (61–64). Because of the fragile nature of PrECs in primary culture, we had not subjected them to demethylating agent treatment; it is reasonable to assume that the same mechanism transcriptional inactivation operates in ER- $\alpha$  silencing in the normal prostatic epithelium. Interestingly, loss of pS2 expression in DU145 cells might also be linked to hypermethylation-mediated transcriptional inactivation because exposure of this cell line to demethylating agents revived pS2 expression.

The *pS2* gene encodes an 84-amino acid, cystein-rich, secretory protein, which is widely expressed in estrogen-sensitive tissues (57). Its expression in prostate cancer specimens has been shown to be associated with premalignant changes and neuroendocrine differentiation (65, 66).

Different variants of ER- $\alpha$  transcripts are often found to coexist with the wild-type transcript in normal and malignant tissues (67, 68). These variants, produced by alternative splicing, are whole exon deletion variants that may have "outlaw functions." In PC-3 cells, a previous study has demonstrated the expression of an exon 4 deletion variant (51). In the current study, we found an exon 2 deletion variant in PC-3, BPH-1, and PrEC (Clontech) cells. Whether ER transcript variants have functional or regulatory roles in prostatic cells is a topic of future investigation.

Therapies for metastatic prostate cancers are limited. In addition to androgen ablation therapies, estrogens/antiestrogens have been used, singularly or in combination with other modalities, for treatment of the disease. DES is an effective treatment therapy; however, its estrogenicity induces significant adverse effects in patients and have resulted in termination of its use (7). In contrast, TAM, a nonsteroidal antiestrogen, is better tolerated but produces little objective responses in multiple trials (8-12). With the discovery of ER- $\beta$  as a new estrogen signaling pathway and the availability of pure antiestrogen such as ICIs (13), it becomes appropriate to address the issue of whether pure antiestrogens could be considered in the treatment of prostate cancer. In this study, we have compared the efficacy of two estrogens ( $E_2$  and DES) and two antiestrogens (4OH-TAM and ICI) in inhibiting cell growth in two androgen-refractory prostate cancer cell lines, PC-3 cells that we found express both ER subtypes, and DU145 cells that express only ER- $\beta$ . Past studies have shown that DES, when given at high concentrations (10-30  $\mu$ M range), exerts colchicine-like action, inhibits tubulin assembly, and induces apoptosis in prostate cancer cells (69, 70). Because the focus of the current study is to elucidate receptor-mediated action of DES, we have chosen to use concentrations not higher than  $10^{-6}$  M. Our results demonstrated all four estrogenic/antiestrogenic compounds, at relatively low doses, exerted antiproliferative effects on PC-3 cells, with antiestrogens exhibiting greater potencies. Furthermore, competition experiments showed that DES could reverse the effect of ICI, thus suggesting that estrogens and antiestrogens may share similar cellular mediators in this cell line. In contrast, DU145 cells responded only to antiestrogens with regard to cell growth inhibition. In both cases, ICI was found to be more potent than 4OH-TAM as a growth inhibitor. Furthermore, competition experiments demonstrated that  $E_2$  did not reverse the ICI-induced or 4OH-TAM-induced growth inhibition. This finding suggests that estrogens have little impact on the antiestrogenic action in DU145 cells. Importantly, the antiestrogen-induced growth-inhibitory response in DU145 cells was reversible by cotreatment with an ER- $\beta$  antisense ODN. Taken together, these findings raise several significant implications: (a) it is apparent that the estrogen/antiestrogen-induced antiproliferative action on prostatic cancer cells is ER subtype dependent. It supports the prediction for the antiproliferative action of ER- $\beta$  as previously discussed (71); (b) because ICI consistently expresses a higher potency, it may be better suited to be used in prostate cancer treatment. In clinical trials for breast cancer treatment, this compound has demonstrated high efficacy and low toxicity (72); and (c) our data have provided the first demonstration that estrogen/antiestrogen action in prostatic cancer cells could signal via an ER- $\beta$  pathway. Because ER- $\beta$  selective ligands have been reported recently (73), this development raises the likelihood of using receptor subtype ligands as cancer therapeutics in the future.

In summary, this study has demonstrated that human normal PrECs express exclusively ER- $\beta$  and likely signal via this receptor subtype

for estrogen/antiestrogen action. On the contrary, prostatic cancer cells exhibit a more variable pattern of ER subtype expression, and their responses to individual estrogen or antiestrogen will depend on the ER subtype(s) expressed in the cells. Significantly, we provide the first experimental evidence that ER- $\alpha$  gene silencing in prostate cancer cells, and perhaps also in normal cells, may be caused by DNA hypermethylation. Overall, data from this study lend support to the notion that ER- $\beta$  plays a central role in estrogen/antiestrogen signaling in normal and malignant human PrECs.

## REFERENCES

- Huggins, C., and Hodges, C. V. Studies of prostatic cancer. I. The effect of castration, of estrogen and androgen injection on serum phosphatases in metastatic carcinoma of the prostate. *Cancer Res.*, *1*: 293-297, 1941.
- Paulson, D. F. Management of metastatic prostatic cancer. *Urology*, *25* (2 Suppl.): 49-52, 1985.
- Brehmer, B., Marquardt, H., and Madsen, P. O. Growth and hormonal response of cells derived from carcinoma and hyperplasia of the prostate in monolayer cell culture. A possible *in vitro* model for clinical chemotherapy. *J. Urol.*, *108*: 890-896, 1972.
- Hartley-Asp, B., Deinum, J., and Wallin, M. Diethylstilbestrol induces metaphase arrest and inhibits microtubule assembly. *Mutat. Res.*, *143*: 231-235, 1985.
- Schulze, H., and Claus, S. Histological localization of estrogen receptors in normal and diseased human prostates by immunocytochemistry. *Prostate*, *16*: 331-343, 1990.
- Robertson, C. N., Roberson, K. M., Padilla, G. M., O'Brien, E. T., Cook, J. M., Kim, C. S., and Fine, R. L. Induction of apoptosis by diethylstilbestrol in hormone-insensitive prostate cancer cells. *J. Natl. Cancer Inst.*, *88*: 908-917, 1996.
- Ahmed, M., Choksy, S., Chilton, C. P., Munson, K. W., and Williams, J. H. High dose intravenous oestrogen (fosfestrol) in the treatment of symptomatic, metastatic, hormone-refractory carcinoma of the prostate. *Int. Urol. Nephrol.*, *30*: 159-164, 1998.
- Glick, J. H., Wein, A., Padavic, K., Negendank, W., Harris, D., and Brodovsky, H. Phase II trial of tamoxifen in metastatic carcinoma of the prostate. *Cancer (Phila.)*, *49*: 1367-1372, 1982.
- Spremulli, E., DeSimone, P., and Durant, J. A phase II study of Nolvadex® tamoxifen citrate in the treatment of advanced prostatic adenocarcinoma. *Am. J. Clin. Oncol.*, *5*: 149-153, 1982.
- Horton, J., Rosenbaum, C., and Cummings, F. J. Tamoxifen in advanced prostate cancer: an ECOG pilot study. *Prostate*, *12*: 173-177, 1988.
- Bergan, R. C., Blagosklonny, M., and Dawson, N. A. Significant activity by high dose tamoxifen in hormone refractory prostate cancer. *Proc. Am. Soc. Clin. Oncol.*, *14*: A637, 1995.
- Bergan, R. C., Reed, E., Myers, C. E., Headlee, D., Brwley, O., Cho, H.-K., Figg, W. D., Tompkins, A., Linehan, W. M., Kohler, D., Steinber, S. M., and Blagosklonny, M. V. A Phase II study of high-dose tamoxifen in patients with hormone-refractory prostate cancer. *Clin. Cancer Res.*, *5*: 2366-2373, 1999.
- Wakeling, A. E., Dukes, M., and Bowler, J. A potent specific pure antiestrogen with clinical potential. *Cancer Res.*, *51*: 3867-3873, 1991.
- Jones, C. D., Jevnikar, M. G., Pike, A. J., Peters, M. K., Black, L. J., Thompson, A. R., Falcone, J. F., and Clemens, J. A. Antiestrogens. 2. Structure-activity studies in a series of 3-aryl-2-arylbenzo[b]thiophene derivatives leading to [6-hydroxy-2-(4-hydroxyphenyl) benzo[b]thien-3-yl][4-[2-(1-piperidinyl)ethoxy]-phenyl]methanone hydrochloride (LY156758), a remarkably effective estrogen antagonist with only minimal intrinsic estrogenicity. *J. Med. Chem.*, *27*: 1057-1066, 1984.
- Van Den Bernd, G. J., Kuiper, G. G., Pols, H. A., and Van Leeuwen, J. P. Distinct effects on the conformation of estrogen receptor  $\alpha$  and  $\beta$  by both the antiestrogens ICI 164,384 and ICI 182-780 leading to opposite effects on receptor stability. *Biochem. Biophys. Res. Commun.*, *261*: 1-5, 1999.
- Zou, A., Marschke, K. B., Arnold, K. E., Berger, E. M., Fitzgerald, P., Mais, D. E., and Allegretto, E. A. Estrogen receptor  $\beta$  activates the human retinoic acid receptor  $\alpha$ -1 promoter in response to tamoxifen and other estrogen receptor antagonists, but not in response to estrogen. *Mol. Endocrinol.*, *13*: 418-430, 1999.
- Barkhem, T., Carlsson, B., Nilsson, Y., Enmark, E., Gustafsson, J., and Nilsson, S. Differential response of estrogen receptor alpha and estrogen receptor beta to partial estrogen agonists/antagonists. *Mol. Pharmacol.*, *54*: 105-112, 1998.
- Paech, K., Webb, P., Kuiper, G. G., Nilsson, S., Gustafsson, J., Kushner, P. J., and Scanlan, T. S. Differential ligand activation of estrogen receptors ER $\alpha$  and ER $\beta$  at API sites. *Science (Washington DC)*, *277*: 1508-1510, 1997.
- Kuiper, G. G., Enmark, E., Peltö-Huikko, M., Nilsson, S., and Gustafsson, J. A. Cloning of a novel receptor expressed in rat prostate and ovary. *Proc. Natl. Acad. Sci. USA*, *93*: 5925-5930, 1997.
- Mosselman, S., Polman, J., and Dijkema, R. ER  $\beta$ : identification and characterization of a novel human estrogen receptor. *FEBS Lett.*, *392*: 49-53, 1996.
- Lau, K. M., Leav, I., and Ho, S. M. Rat estrogen receptor- $\alpha$  and - $\beta$ , and progesterone receptor mRNA expression in various prostatic lobes and microdissected normal and dysplastic epithelial tissues of the Noble rats. *Endocrinology*, *139*: 424-427, 1997.
- Prins, G. S., Marmer, M., Woodham, C., Chang, W., Kuiper, G., Gustafsson, J. A., and Birch, L. Estrogen receptor- $\beta$  messenger ribonucleic acid ontogeny in the prostate of normal and neonatally estrogenized rats. *Endocrinology*, *139*: 874-883, 1998.
- Chang, W. Y., and Prins, G. S. Estrogen receptor- $\beta$ : implications for the prostate gland. *Prostate*, *40*: 115-124, 1999.

24. Montano, M. M., Jaiswal, A. K., and Katzenellenbogen, B. S. Transcriptional regulation of the human quinone reductase gene by antiestrogen-liganded estrogen receptor- $\alpha$  and estrogen receptor- $\beta$ . *J. Biol. Chem.*, 273: 25443-25449, 1998.
25. Krege, J. H., Hodgin, J. B., Couse, J. F., Enmark, E., Warner, M., Mahler, J. F., Sar, M., Korach, K. S., Gustafsson, J. A., and Smithies, O. Generation and reproductive phenotypes of mice lacking estrogen receptor  $\beta$ . *Proc. Natl. Acad. Sci. USA*, 95: 15677-15682, 1998.
26. Bonkhoff, H., Fixemer, T., Hunsicker, I., and Remberger, K. Estrogen receptor inhibition in prostate cancer and malignant prostatic lesions. *Am. J. Pathol.*, 155: 641-647, 1999.
27. Lau, K. M., LaSpina, M., Long, J., and Ho, S.-M. Antiestrogens, via ER $\beta$  pathway, inhibit growth of prostate cancer cells. *Proc. Am. Assoc. Cancer Res.*, 40: 637-638, 1999.
28. Sinisi, A., Pasquali, D., Rossi, V., Abbondanza, C., Puca, G. A., and Bellastella, A. Different expression of estrogen receptor  $\alpha$  and  $\beta$  in primary cultures of normal and malignant human prostate epithelial cells. *Proc. Endocr. Soc. 81th Annual Meeting*, Vol. PAB99, p. 264, 1999.
29. Taylor, A. H., Davis, I., and Al-Azzawi, F. Immunolocalisation of estrogen receptor isoform ER $\beta$  in formalin-fixed paraffin-embedded normal human reproductive tissues. *Proc. Endocr. Soc. 81th Annual Meeting*, Vol. PAB99, p. 183, 1999.
30. Hayward, S. W., Dahiya, R., Cunha, G. R., Bartek, J., Deshpande, N., and Narayan, P. Establishment and characterization of an immortalized but non-transformed human prostate epithelial cell line: BPH-1. *In Vitro Cell Dev. Biol. Anim.*, 31: 14-24, 1995.
31. Bright, R. K., Vocke, C. D., Emmert-Buck, M. R., Duray, P. H., Solomon, D., Fetsch, P., Rhim, J. S., Linehan, W. M., and Topalian, S. L. Generation and genetic characterization of immortal human prostate epithelial cell lines derived from primary cancer specimens. *Cancer Res.*, 57: 995-1002, 1997.
32. Lau, K. M., Mok, S. C., and Ho, S. M. Expression of human estrogen receptor- $\alpha$  and - $\beta$ , progesterone receptor, and androgen receptor mRNA in normal and malignant ovarian epithelial cells. *Proc. Natl. Acad. Sci. USA*, 96: 5722-5727, 1999.
33. Grant, E. S., Batchelor, K. W., and Habib, F. K. Androgen independence of primary epithelial cultures of the prostate is associated with a down-regulation of androgen receptor gene expression. *Prostate*, 29: 339-349, 1996.
34. Sugimura, Y., Cunha, G. R., Yonemura, C. U., and Kawamura, J. Temporal and spatial factors in diethylstilbestrol-induced squamous metaplasia of the developing human prostate. *Hum. Pathol.*, 19: 133-139, 1988.
35. Yonemura, C. Y., Cunha, G. R., Sugimura, Y., and Mee, S. L. Temporal and spatial factors in diethylstilbestrol-induced squamous metaplasia in the developing human prostate. II. Persistent changes after removal of diethylstilbestrol. *Acta Anat.*, 153: 1-11, 1995.
36. Triche, T. J., and Harkin, J. C. An ultrastructural study of hormonally induced squamous metaplasia in the coagulating gland of the mouse prostate. *Lab. Investig.*, 25: 596-606, 1971.
37. Levine, A. C., Kirschenbaum, A., Droller, M., and Gabrilove, J. L. Effect of the addition of estrogen to medical castration on prostatic size, symptoms, histology and serum prostate specific antigen in 4 men with benign prostatic hypertrophy. *J. Urol.*, 146: 790-793, 1991.
38. Noble, R. L. Production of Nb rat carcinoma of the dorsal prostate and response of estrogen-dependent transplants to sex hormones and tamoxifen. *Cancer Res.*, 40: 3547-3550, 1980.
39. Drago, J. R. The induction of NB rat prostatic carcinomas. *Anticancer Res.*, 4: 255-256, 1984.
40. Leav, I., Merk, F. B., Kwan, P. W., and Ho, S. M. Androgen-supported estrogen-enhanced epithelial proliferation in the prostates of intact Noble rats. *Prostate*, 15: 23-40, 1995.
41. Bosland, M. C., Ford, H., and Horton, L. Induction at high incidence of ductal prostate adenocarcinomas in NBL/Cr and Sprague-Dawley Hsd:SD rats treated with a combination of testosterone and estradiol-17 $\beta$  or diethylstilbestrol. *Carcinogenesis (Lond.)*, 16: 1311-1317, 1995.
42. Klotz, L., McNeill, I., and Fleshner, N. A Phase I-2 trial of diethylstilbestrol plus low dose warfarin in advanced prostate carcinoma. *J. Urol.*, 161: 169-172, 1999.
43. Smith, D. C., Redman, B. G., Flaherty, L. E., Li, L., Strawderman, M., and Pienta, K. J. A Phase II trial of oral diethylstilbestrol as a second-line hormonal agent in advanced prostate cancer. *Urology*, 52: 257-260, 1998.
44. Landstrom, M., Eklov, S., Colosetti, P., Nilsson, S., Damber, J. E., Bergh, A., and Funari, K. Estrogen induces apoptosis in a rat prostatic adenocarcinoma: association with an increased expression of TGF- $\beta$ 1 and its type-I and type-II receptors. *Int. J. Cancer*, 67: 573-579, 1996.
45. Wernert, N., Gerdes, J., Loy, V., Seitz, G., Scherr, O., and Dhom, G. Investigations of the estrogen (ER-ICA-test) and the progesterone receptor in the prostate and prostatic carcinoma on immunohistochemical basis. *Virchows Arch. A Pathol. Anat. Histopathol.*, 412: 387-391, 1988.
46. Ehara, H., Koji, T., Deguchi, T., Yoshii, A., Nakano, M., Nakane, P. K., and Kawada, Y. Expression of estrogen receptor in diseased human prostate assessed by non-radioactive in situ hybridization and immunohistochemistry. *Prostate*, 27: 304-313, 1995.
47. Kirschenbaum, A., Ren, M., Erenburg, I., Schachter, B., and Levine, A. C. Estrogen receptor messenger RNA expression in human benign prostatic hyperplasia: detection, localization, and modulation with a long-acting gonadotropin-releasing hormone agonist. *J. Androl.*, 15: 528-533, 1994.
48. Hiramatsu, M., Maehara, I., Orikasa, S., and Sasano, H. Immunolocalization of oestrogen and progesterone receptors in prostatic hyperplasia and carcinoma. *Histopathology*, 28: 163-168, 1996.
49. Rohlf, C., Blagosklonny, M. V., Kyle, E., Kesari, A., Kim, I. Y., Zelner, D. J., Hakim, F., Trepel, J., and Bergan, R. C. Prostate cancer cell growth inhibition by tamoxifen is associated with inhibition of protein kinase C and induction of p21 (waf1/cip1). *Prostate*, 37: 51-59, 1998.
50. Couse, J. F., Lindzey, J., Grandien, K., Gustafsson, J. A., and Korach, K. S. Tissue distribution and quantitative analysis of estrogen receptor- $\alpha$  (ER $\alpha$ ) and estrogen receptor- $\beta$  (ER $\beta$ ) messenger ribonucleic acid in the wild-type and ER $\alpha$ -knockout mouse. *Endocrinology*, 138: 4613-4621, 1997.
51. Carruba, G., Pfeffer, U., Fecarotta, E., Coviello, D. A., D'Amato, E., Lo Castro, M., Vidali, G., and Castagnetta, L. Estradiol inhibits growth of hormone-nonresponsive PC3 human prostate cancer cells. *Cancer Res.*, 54: 1190-1193, 1994.
52. Castagnetta, L. A., Miceli, M. D., Sorci, C. M., Pfeffer, U., Farruggio, R., Oliveri, G., Calabro, M., and Carruba, G. Growth of LNCaP human prostate cancer cells is stimulated by estradiol via its own receptor. *Endocrinology*, 136: 2309-2319, 1995.
53. Hobisch, A., Hittmair, A., Daxenbichler, G., Wille, S., Radmayr, C., Hobisch-Hagen, P., Bartsch, G., Klocker, H., and Culig, Z. Metastatic lesions from prostate cancer do not express oestrogen and progesterone receptors. *J. Pathol.*, 182: 356-361, 1998.
54. Konishi, N., Nakaoka, S., Hiasa, Y., Kitahori, Y., Ohshima, M., Samma, S., and Okajima, E. Immunohistochemical evaluation of estrogen receptor status in benign prostatic hypertrophy and in prostate carcinoma and the relationship to efficacy of endocrine therapy. *Oncology*, 50: 259-263, 1993.
55. Castagnetta, L. A., and Carruba, G. Metastatic lesions from prostate cancer do not express oestrogen and progesterone receptors. *J. Pathol.*, 185: 435-437, 1998.
56. Brown, A. M., Jeltsch, J. M., Roberts, M., and Chambon, P. Activation of p52 gene transcription is a primary response to estrogen in the human breast cancer cell line MCF-7. *Proc. Natl. Acad. Sci. USA*, 81: 6344-6348, 1984.
57. Stack, G., Kumar, V., Green, S., Ponglikitmongkol, M., Berry, M., Rio, M. C., Nunez, A. M., Roberts, M., Koehl, C., Bellocq, P., et al. Structure and function of the p52 gene and estrogen receptor in human breast cancer cells. *Cancer Treat. Res.*, 40: 185-206, 1988.
58. Savouret, J. F., Bailly, A., Misrahi, M., Rauch, C., Redeuilh, G., Chanchereau, A., and Milgrom, E. Characterization of the hormone responsive element involved in the regulation of the progesterone receptor gene. *EMBO J.*, 10: 1875-1883, 1991.
59. Zingg, J. M., and Jones, P. A. Genetic and epigenetic aspects of DNA methylation on genome expression, evolution, mutation and carcinogenesis. *Carcinogenesis (Lond.)*, 18: 869-882, 1997.
60. Jones, P. A., and Gonzalzo, M. L. Altered DNA methylation and genome instability: a new pathway to cancer? *Proc. Natl. Acad. Sci. USA*, 94: 2103-2105, 1997.
61. Ottaviano, Y. L., Issa, J. P., Parl, F. F., Smith, H. S., Baylin, S. B., and Davidson, N. E. Methylation of the estrogen receptor gene CpG island marks loss of estrogen receptor expression in human breast cancer cells. *Cancer Res.*, 54: 2552-2555, 1994.
62. Ferguson, A. T., Lapidus, R. G., Baylin, S. B., and Davidson, N. E. Demethylation of the estrogen receptor gene in estrogen receptor-negative breast cancer cells can reactivate estrogen receptor gene expression. *Cancer Res.*, 55: 2279-2283, 1995.
63. Martin, V., Ribieras, S., Song-Wang, X., Rio, M. C., and Dante, R. Genomic sequencing indicates a correlation between DNA hypomethylation in the 5' region of the p52 gene and its expression in human breast cancer cell lines. *Gene (Amst.)*, 157: 261-264, 1995.
64. Lapidus, R. G., Nass, S. J., Butash, K. A., Parl, F. F., Weitzman, S. A., Graff, J. G., Herman, J. G., and Davidson, N. E. Mapping of ER gene CpG island methylation by methylation-specific polymerase chain reaction. *Cancer Res.*, 58: 2515-2519, 1998.
65. Bonkhoff, H., Stein, U., Welter, C., and Remberger, K. Differential expression of the p52 protein in the human prostate and prostate cancer: association with premalignant changes and neuroendocrine differentiation. *Hum. Pathol.*, 26: 824-828, 1995.
66. Colombel, M., Dantem, R., Bouvier, S., Pangaud, C., Marechal, M., and Lasne, Y. Differential RNA expression of the p52 gene in the human benign and malignant prostatic tissue. *J. Urol.*, 162 (3 Part 1): 927-930, 1999.
67. Hirata, S., Yamada-Mouri, N., Nara, M., Takizawa, M., Ito, H., and Kato, J. Presence of alternatively spliced-estrogen receptor mRNA variants in normal human uterine endometrium and endometrial cancer. *Endocr. J.*, 42: 289-293, 1995.
68. Leygue, E. R., Watson, P. H., and Murphy, L. C. Estrogen receptor variants in normal human mammary tissue. *J. Natl. Cancer Inst.*, 88: 284-290, 1996.
69. Chaudoreille, M. M., Peyrot, V., Braguer, D., and Crevat, A. Interaction of some estrogens with tubulin. Formation of twisted ribbon structures. *Mol. Pharmacol.*, 32: 731-736, 1987.
70. Robertson, C. N., Robertson, K. M., Padilla, G. M., O'Brien, E. T., Cook, J. M., Kim, C. S., Fine, R. L. Induction of apoptosis by diethylstilbestrol in hormone-insensitive prostate cancer cells. *J. Natl. Cancer Inst.*, 88: 908-917, 1996.
71. Reynolds, T. New estrogen receptor adds complexity, recasts drug strategies. *J. Natl. Cancer Inst.*, 91: 1445-1447, 1999.
72. England, G. M., and Jordan, V. C. Pure antiestrogens as a new therapy for breast cancer. *Oncol. Res.*, 9: 397-402, 1997.
73. Montano, M. M., Ekena, K., Delage-Mourroux, R., Chang, W., Martini, P., and Katzenellenbogen, B. S. An estrogen receptor-selective coregulator that potentiates the effectiveness of antiestrogens and represses the activity of estrogens. *Proc. Natl. Acad. Sci. USA*, 96: 6947-6952, 1999.

Ed: Should  $\beta$  &  $\alpha$  be spelled out, as on copy? - PTR

# Comparative Studies of the Estrogen Receptors $\beta$ and $\alpha$ and the Androgen Receptor in Normal Human Prostate Glands, Dysplasia, and in Primary and Metastatic Carcinoma

Irwin Leav,\* Kin-Mang Lau,<sup>†</sup> Jason Y. Adams,\*  
John. E. McNeal,<sup>‡</sup> Mary-Ellen Taplin,<sup>§</sup>  
Jianfu Wang,<sup>¶</sup> Hema Singh,<sup>¶</sup> and Shuk-Mei Ho<sup>†</sup>

From the Department of Pathology,\* Schools of Medicine and Veterinary Medicine, Tufts University, Boston, Massachusetts; the Department of Surgery,<sup>†</sup> Division of Urology, and the Department of Oncology,<sup>§</sup> University of Massachusetts Medical School, Worcester, Massachusetts; the Department of Urology,<sup>‡</sup> Stanford University Medical Center, Stanford, California; and Biogenex Laboratories,<sup>¶</sup> Mountain View, California

An antibody, GC-17, thoroughly characterized for its specificity for estrogen receptor- $\beta$  (ER- $\beta$ ), was used to immunolocalize the receptor in histologically normal prostate, prostatic intraepithelial neoplasia, primary carcinomas, and in metastases to lymph nodes and bone. Comparisons were made between ER- $\beta$ , estrogen receptor- $\alpha$  (ER- $\alpha$ ), and androgen receptor (AR) immunostaining in these tissues. Concurrently, transcript expression of the three steroid hormone receptors was studied by reverse transcriptase-polymerase chain reaction analysis on laser capture-microdissected samples of normal prostatic acini, dysplasias, and carcinomas. In Western blot analyses, GC-17 selectively identified a 63-kd protein expressed in normal and malignant prostatic epithelial cells as well as in normal testicular and prostatic tissues. This protein likely represents a posttranslationally modified form of the long-form ER- $\beta$ , which has a predicted size of 59 kd based on polypeptide length. In normal prostate, ER- $\beta$  immunostaining was predominately localized in the nuclei of basal cells and to a lesser extent stromal cells. ER- $\alpha$  staining was only present in stromal cell nuclei. AR immunostaining was variable in basal cells but strongly expressed in nuclei of

secretory and stromal cells. Overall, prostatic carcinogenesis was characterized by a loss of ER- $\beta$  expression at the protein and transcript levels in high-grade dysplasias, its reappearance in grade 3 cancers, and its diminution/absence in grade 4/5 neoplasms. In contrast, AR was strongly expressed in all grades of dysplasia and carcinoma. Because ER- $\beta$  is thought to function as an inhibitor of prostatic growth, androgen action, presumably mediated by functional AR and unopposed by the  $\beta$  receptor, may have provided a strong stimulus for aberrant cell growth. With the exception of a small subset of dysplasias in the central zone and a few carcinomas, ER- $\alpha$ -stained cells were not found in these lesions. The majority of bone and lymph node metastases contained cells that were immunostained for ER- $\beta$ . Expression of ER- $\beta$  in metastases may have been influenced by the local microenvironment in these tissues. In contrast, ER- $\alpha$ -stained cells were absent in bone metastases and rare in lymph nodes metastases. Irrespective of the site, AR-positive cells were found in all metastases. Based on our recent finding of anti-estrogen/ER- $\beta$ -mediated growth inhibition of prostate cancer cells *in vitro*, the presence of ER- $\beta$  in metastatic cells may have important implications for the treatment of late-stage disease. (*Am J Pathol* 2001, 159:000-000)

Cellular differentiation and proliferation of prostatic epithelium has long been considered to be primarily mediated by androgens. In this regard, the majority of prostate cancers are initially responsive to anti-androgenic therapies but eventually become refractory to this form of treatment.<sup>1,2</sup> The first medical anti-androgenic therapy used to treat men with prostate cancer used estrogens, primarily acting indirectly at the hypothalamic level to down-regulate circulating levels of androgens, with resultant degenerative effects on neoplastic cells.<sup>3</sup> Paradoxically, despite its use as an anti-androgen, pharmacological doses of estrogens can also induce a marked proliferative alteration of prostatic epithelium termed squamous metaplasia, in the glands of a variety of mammals including humans.<sup>4-8</sup> The metaplastic change is initiated by the proliferation of basal cells that subsequently differentiate into squamous cells.<sup>5,6,8</sup> Importantly, it has been shown that estrogens alone can directly in-

Supported by United States Department of Defense grant DAMD17-98-1-8606.

Accepted for publication March 16, 2001.

Address reprint requests to Dr. Shuk-Mei Ho, 55 Lake Avenue North, S4-746, Department of Surgery, Division of Urology, University of Massachusetts Medical School, Worcester, MA 01655. E-mail: shuk-mei.ho@umassmed.edu.

duce squamous metaplasia in the regressed prostates of castrated or hypophysectomized dogs.<sup>5,6</sup>

Despite the proliferative effects of estrogens on basal cells, which are the purported progenitor cells of prostatic glandular epithelia,<sup>9</sup> the role that the hormone may play in the abnormal growth of the gland remains undefined. Results from a number of epidemiological<sup>10,11</sup> and experimental studies<sup>10-15</sup> have suggested that estrogens may be involved in this process.

Effects of estrogens on target tissues are now known to be mediated by ligand-specific transcription factor receptor proteins termed estrogen receptor- $\alpha$  and - $\beta$  (ER- $\alpha$  and ER- $\beta$ ).<sup>16-19</sup> The two isoforms have highly homologous in DNA-binding domains but significant differences in acid amino sequences are found in the N-terminal, hinge region, ligand binding, and F domains.<sup>17</sup> Both receptors are present in many of the same tissues but differences in organ and tissue distribution as well as in levels of expression have been reported for the two isoforms.<sup>17,20,21</sup> In this regard, ER- $\beta$  mRNA was found to be predominant over the ER- $\alpha$  isoform in the rat prostate<sup>16</sup> and it was also present in human gland albeit in lesser amounts than in the testis.<sup>17</sup> ER- $\beta$  and ER- $\alpha$  were also shown to bind to the same ligands with different affinity.<sup>21</sup> In addition, after binding to estrogens and anti-estrogens, the two ER isoforms use different enhancer elements such as estrogen responsive element and AP1 sites in promoter regions of gene.<sup>22</sup> Taken together, these two studies suggest that ER- $\alpha$  and ER- $\beta$  may mediate diverse downstream effects.<sup>22-24</sup>

Although the precise biological function of the two ER isoforms in the prostate is currently undefined,<sup>25</sup> in one study, ER- $\beta$  knockout mice have been reported to develop age-related prostatic hyperplasia, which suggests that the receptor may act to inhibit abnormal growth of the gland.<sup>26</sup> In support of this concept, Poelzl and colleagues<sup>27</sup> have recently reported that ER- $\beta$ , but not the  $\alpha$  isoform, specifically interacts with MAD2 the cell-cycle spindle assembly checkpoint protein. Moreover, Lau and colleagues<sup>28</sup> demonstrated that anti-estrogens down-regulate cell proliferation in human prostate cancer cells that only express the ER- $\beta$  isoform. ER- $\beta$  has also been found to be involved in mediating estrogen/anti-estrogen induction of quinone reductase via its interaction with the electrophile/anti-oxidant response element in the promoter region of the gene.<sup>29</sup> It has therefore been proposed that the receptor may be involved in regulating the expression of anti-oxidant enzymes and thus play a role in protecting cells against oxidative injury.<sup>25,29</sup>

Before the discovery of ER- $\beta$ , ER- $\alpha$  antibodies or *in situ* hybridization were used to study ER localization in normal, hyperplastic, and carcinomatous human prostate tissues.<sup>30-32</sup> Most of these reports showed that ER- $\alpha$  was predominately localized in the stroma of normal and hyperplastic prostates with the occasional detection of the receptor in basal cells and glandular epithelia. With the exception of one recent study,<sup>33</sup> ER- $\alpha$  immunostaining was not detected in primary or metastatic prostate cancers. To date, there is only one published report of ER- $\beta$  localization in the normal human prostate.<sup>34</sup> Similarly, one study has reported ER- $\beta$  protein expression in human

breast tissues using an antibody developed by the investigators.<sup>35</sup>

In the current investigation, we developed a novel antibody directed against the F domain of ER- $\beta$ , a region that has no homology with the  $\alpha$  receptor.<sup>17</sup> We demonstrate that this antibody does not cross-react with ER- $\alpha$ . This reagent was used to immunolocalize the receptor in morphologically normal glands from the three anatomical zones of the prostate, dysplasia (also termed "prostatic intraepithelial neoplasia"—the purported precursor of carcinoma),<sup>36,37</sup> and in primary and metastatic carcinoma. Laser-capture microdissection/reverse transcriptase-polymerase chain reaction (LCM/RT-PCR) was also used to study transcript expression of the receptor in dysplastic lesions and in grades 3 and 4/5 carcinomas. Results from the studies of ER- $\beta$  were compared with the concomitant investigation of androgen receptor (AR) and ER- $\alpha$  expressions at both immunohistochemical and transcript levels. In this manner, changes in the expression of any of the three receptors could be evaluated as to how they may relate to the development and progression of prostatic carcinoma. Differences in receptor expression between grades 3 and 4/5 were emphasized in our study because it has recently reported that the percentage of grade 4/5 carcinoma in a prostatic neoplasm is highly predictive of disease progression.<sup>38</sup>

To our knowledge, our report is the first in which antibodies specific for ER- $\beta$ , ER- $\alpha$ , and AR were used together with LCM/RT-PCR to compare the expression of these receptors in normal human prostate, dysplastic lesions, and carcinoma.

We find that within the epithelial compartment of normal human prostate, ER- $\beta$  is predominately localized in basal cells and to a lesser extent stromal cell nuclei. In contrast, ER- $\alpha$  was rarely detected in basal cells but was strongly expressed in stromal cell nuclei.

Expression of the  $\beta$  receptor was diminished in high-grade dysplasia and grade 4/5 carcinoma of the peripheral zone. A similar trend was found at the transcript level in microdissected tissues. The majority of metastases to bone and lymph nodes however contained ER- $\beta$ -immunopositive carcinoma cells. In contrast to ER- $\beta$ , ER- $\alpha$  expression at both protein and transcript levels was absent in all dysplasias but present in a few carcinomas of the peripheral zone. The  $\alpha$  receptor was however expressed in metastases to two lymph nodes and in the majority of central zone dysplasias. AR expression remained consistently strong in all grades of dysplasias and primary carcinomas as well as in metastases.

In summary, we report that a down-regulation of ER- $\beta$  expression occurs during prostatic carcinogenesis. This change may contribute to a loss in growth control processes mediated by the  $\beta$  receptor that could amplify the effects of persisting proliferative stimuli such as those mediated by AR.

The presence of ER- $\beta$  as the predominant ER subtype in most metastases, together with our recent findings that anti-estrogens binding to the receptor inhibit proliferation of prostate cancer cells,<sup>28</sup> may be useful in devising new ligand-specific treatments for late-stage disease.

## Materials and Methods

### Generation of the GC-17 Polyclonal Antibody

The composition of the immunizing peptide used to generate the GC-17 rabbit anti-ER- $\beta$  antibody was selected with the aid of the computer programs Protean (Dnastar, Inc., Madison, WI) and Peptool (BioTools, Inc., Edmonton, Alberta, Canada). A peptide sequence in the F domain of the human ER- $\beta$  receptor (amino acids 449 to 465) was selected, because there is no homology with ER- $\alpha$  at this region.<sup>17,39</sup> The peptide was custom synthesized by Research Genetics (Huntsville, AL) with a format of 4-branch multiple antigenic peptide. Each rabbit (male New Zealand White, 5 to 6 lbs) was first inoculated with 0.5 mg of peptide antigen with complete Freund's adjuvant, and then boosted with 0.25 mg of peptide plus incomplete Freund's adjuvant at day 14, day 21, and every 2 weeks afterward until a satisfactory serum titer was obtained. A direct enzyme-linked immunosorbent assay (ELISA) was used to assess the immune responses to the peptide antigen.<sup>40</sup>

### Methods Used to Test the Specificity of the GC-17 Antibody

#### Competitive Inhibition ELISA Assay

The wells of an ELISA plate, Pro-Bind (Becton-Dickinson Labware, Franklin, NJ) were coated with a recombinant protein composed of the entire ER- $\beta$  sequence (PanVera, Madison, WI) at a concentration of 5  $\mu$ g/ml. The GC-17 antibody (1:6000) was then preincubated with the immunizing peptide at concentrations ranging from 4 mg to 4  $\mu$ g/ml at room temperature for 30 minutes. In addition, 4 mg of a control peptide encompassing sequences in the N-terminal region of ER- $\beta$  (Research Genetics) was preincubated with the GC-17 antibody (1:6000) at room temperature for 1 hour. The resulting antigen/antibody complexes were then incubated with the bound recombinant ER- $\beta$  protein on the ELISA plate at 37°C for 2 hours. Alkaline phosphatase-conjugated anti-rabbit IgG antibody (Jackson ImmunoResearch, West Grove, PA) was used to recognize the GC-17 antibody that bound to recombinant ER- $\beta$  protein on the plate. The whole complexes were visualized by incubation with *p*-nitrophenyl phosphate in 2-amino, 2-methyl, 1,3-propanediol buffer, pH 9.6. Results were quantified by optical density using the Microplate reader 550 (Bio-Rad, Richmond, CA). The entire assay was done four times.

#### Competitive Immunohistochemistry

Lau and colleagues<sup>28</sup> have recently demonstrated that DU145 and LNCaP cells, both derived from a metastatic prostate cancer, express abundant ER- $\beta$  mRNA but not ER- $\alpha$  message. These cells were used to compliment and confirm that the GC-17 antibody reagent specifically detected ER- $\beta$  but not ER- $\alpha$  by immunohistochemical stain-

ing. Using the GC-17 antibody and the anti-ER- $\alpha$  antibody (NCL-ER-6F11; Novocastra, Newcastle-upon-Tyne, UK) at the same dilutions as for tissue sections (see below), we performed immunohistochemical studies on 10% formalin-fixed cytopins of DU145 and LNCaP cells that had been routinely processed, embedded in paraffin, sectioned at 5  $\mu$ m, and mounted on SuperFrost Plus slides (VWF Scientific, West Chester PA).

We performed peptide competition studies at the immunohistochemical level that approximated the conditions used in the ELISA assays described above. GC-17 antibody, at a dilution of 1:6000, was incubated with the immunizing ER- $\beta$  peptide at concentrations of 400 and 40  $\mu$ g at room temperature for 1 hour. In addition, competitive studies were conducted using ER- $\alpha$  recombinant peptide (400 and 40  $\mu$ g; Affinity Bioreagents Inc., Golden, CO) on DU145 cells. Incubation conditions and time were identical to those used for the ER- $\beta$  peptide competition studies. Deparaffinized sections of DU145 and LNCaP cells and human prostate tissue were then incubated with these mixtures at room temperature for 1 hour. Competition studies, done on prostate tissues, were identical to those performed on DU145 cells, except the peptide and antibody mixtures were incubated overnight and then applied to sections for 24 hours at room temperature. All of the remaining immunohistochemical and other staining procedures were identical to those used for tissue sections (see Immunohistochemical Procedures).

#### Western Blot Analysis

Four human normal prostate tissues from radical prostatectomies and one normal human testis tissue were used in this analysis. In addition, we used normal putative human prostate basal cells (PrEC; Clonetics, Walkersville, MD) and DU145 cells (ATCC, Rockville, MD) for these studies. Recombinant proteins, ER- $\alpha$  (RP310) and short form of ER- $\beta$  (RP311) (Affinity Bioreagents Inc.) as well as long form of ER- $\beta$  (PanVera), were included as controls. Tissues or cells were homogenized in radioimmunoprecipitation (RIPA) buffer containing 50 mmol/L Tris-HCl, pH 7.4, 1% Nonidet P-40 (Amaresco, Solon, OH), 0.5% sodium deoxycholate, 0.1% sodium dodecyl sulfate (SDS), 1 mmol/L phenylmethylsulfonyl fluoride in isopropanol, 1 mmol/L activated sodium orthovanadate and 2 $\times$  complete proteinase inhibitor cocktail (Boehringer Mannheim, Mannheim, Germany). Twenty-five  $\mu$ g of tissue protein extracts, 0.5  $\mu$ g of recombinant ER- $\alpha$  protein, or 0.5  $\mu$ g of recombinant ER- $\beta$  protein were mixed with 2 $\times$  SDS loading buffer (125 mmol/L Tris buffer, pH 6.8, 20% glycerol, 2% SDS, 2%  $\beta$ -mercaptoethanol and 1  $\mu$ g/ml bromophenol blue) and electrophoresed onto a 10% SDS-polyacrylamide gel under reducing conditions. The separated proteins were transferred onto a PolyScreen polyvinylidene-difluoride transfer membrane (NEN, Boston, MA). The membrane was incubated for 1 hour in blocking buffer [phosphate-buffered saline (PBS) with 5% nonfat dry milk]. The primary antibodies were applied at 1:6000 for GC-17 ER- $\beta$  antibody or 1:5 for 1D5 ER- $\alpha$  antibody (Biogenex, Mountainview, California) in PBS-T (PBS with 0.05% Tween-20) buffer

AQ.C)  
AQ.D

with 0.1% bovine serum albumin for overnight at room temperature. After washing five times with PBS-T buffer, the membrane was incubated with horseradish peroxidase-linked donkey anti-rabbit IgG antibody (Amersham Pharmacia Biotech, Piscataway, NJ) for GC-17 or goat anti-mouse IgG antibody (NEN) for 1D5 at 1:2500 for 1 hour. The signals were visualized with the chemiluminescence ECL detection system (NEN) and autoradiography. All reagents were purchased from Sigma (St. Louis, MO) unless specified.

## Prostate Tissues

### Formalin-Fixed Radical Prostatectomy Specimens

Tissues studied were from 50 radical prostatectomy specimens collected by JEM at Stanford University Medical School, during the years 1995 to 1999. Patients ranged in age from 46 to 73 years of age and none had received any treatment before their undergoing prostatectomy. Prostates were fixed in 10% buffered formalin for 24 hours then sectioned transversely. Tissues were dissected fixed in 10% buffered formalin for 3 hours, routinely processed, and embedded in paraffin. A histopathological diagnosis was made by JEM on a hematoxylin and eosin (H&E)-stained section. The criteria used in the grading of the carcinomas were those described by Stamey and colleagues.<sup>38</sup> The slide, together with the corresponding paraffin block, was then sent to IL at Tufts University where immunohistochemical studies were performed. At least one section from each case was stained with H&E and reviewed by IL to assure that it matched the tissue components in the original slide. Paraffin sections were cut at 6  $\mu$ m and mounted on SuperFrost Plus slides. Sections were left unbaked until used for immunohistochemical studies.

Among the 50 cases selected for study, 26 contained areas of carcinoma. Five of these were clear cell carcinomas of the transition zone whereas all of the remaining cancers were found in the peripheral zone. All of the peripheral zone cancers were composed of mixtures of grades 3 and 4/5 carcinomas. In contrast, all of the clear cell carcinomas were predominately grade 3 neoplasms. Twenty of the peripheral cancer specimens also contained varying amounts of low/moderate- to high-grade dysplastic lesions. Dysplasia of the peripheral zone was found in the absence of carcinoma in 6 of the 50 total cases we studied. Additionally, 7 of the 50 cases, were low/moderate-grade dysplasias of the central zone that did not co-exist with cancer. Among the 50 cases, two specimens each of lesion-free normal peripheral, central, and the transition zone were included in our study. Among the cases studied, 15 examples of benign prostatic hyperplasia were either commingled with other lesions<sup>10</sup> or occurred separately.<sup>5</sup>

### Bone and Lymph Node Metastases

In addition to the prostatectomy cases, archived paraffin blocks containing bone metastases were obtained

from seven patients of MET that were treated at the University of Massachusetts Medical Center. The patients' ages ranged from 59 to 74 and they were all clinically stage D2 at the time of diagnosis. All received anti-androgen treatment as follows: 1) four patients were orchectomized. One of these patients was given the LH/RH agonist Lupron (TAP Pharmaceuticals Inc, Deerfield, IL) and the AR competitive inhibitor Eulixin (Flutamide; Schering Corp., Kenilworth, NJ) for 3 months, one treated with Eulixin for 24 months and the remaining two were not given any further anti-androgenic therapy. 2) Three patients were not orchectomized. Two were treated with Lupron for 8 months and the other with Lupron and Eulixin for 3 months. Following these anti-androgenic therapies for the periods noted above, it was determined that all seven patients were failing therapy. At those time points, biopsies of suspected bone metastases were obtained from the iliac crest of each patient. These samples were immediately fixed in 10% buffered, routinely processed, embedded in paraffin, and 6- $\mu$ m sections were placed on SuperFrost Plus slides and stained with H&E. Replicate sections of these lesions were used for immunohistochemical studies.

In addition, we also studied five archived examples of metastases to regional lymph nodes. Two cases were obtained from the Department of Pathology at the University of Massachusetts Medical School and the remaining three were from the University of Florida Medical School (a generous gift from Dr. William Murphy). The patients were 60 to 85 years of age. Regional lymph nodes (external iliac and pelvic) were obtained from all patients during radical prostatectomy. Only one patient had received any treatment before surgery (Lupron).

### Frozen Tissues for LCM/RT-PCR

Eighteen separate specimens, derived from radical prostatectomies, were placed in cassettes containing Tris-buffered saline (Triangle Biomedical Sciences, Durham, NC) and quick-frozen in liquid nitrogen by JEM and then shipped in dry ice to IL. Approximately 15 minutes elapsed from the surgical removal of the gland to the initiation of freezing. Formalin-fixed and paraffin-embedded tissue sections, immediately adjacent to the quick frozen specimens, were also taken for subsequent immunohistochemical studies (see below).

For diagnostic purposes and lesion selection, tissues were first cryostat sectioned and then fixed briefly in 70% ethanol and stained with H&E. The frozen tissue blocks were then stored at  $-70^{\circ}\text{C}$  until they were used for microdissection. Before LCM, sections from these cases were found to contain varying amounts of grades 3 and 4/5 carcinomas as well as dysplastic and normal glands.

## Procedures

### Immunohistochemical Procedures

The following are the primary antibodies and the dilutions used in our studies: anti-ER- $\beta$ , rabbit polyclonal

AQ: E

AQ: F

AQ: G

antibody GC-17, diluted at 1:6000; anti-ER- $\alpha$ , mouse monoclonal antibody NCL-ER-6F11, diluted at 1:50 (Novocastra); anti-AR, rabbit polyclonal antibody, diluted to 22.7  $\mu\text{g/ml}$  (Upstate Biotechnologies, Lake Placid, NY); anti-Mib5/Ki67, mouse monoclonal antibody, diluted at 1:50 (Immunotech, Westbrook, ME); and anti-high molecular weight cytokeratin, mouse monoclonal antibody 34 $\beta$ E12, diluted at 1:50 (Enzo Diagnostics, Farmingdale, NY). Immunostaining for prostatic-specific antigen (PSA) was done with a Nexus immunostainer (Ventana, Tucson, AZ) using prediluted reagents.

Five- $\mu\text{m}$  thick sections were cut and mounted on Super-Frost Plus slides. Sections were left unbaked until immediately before use at which point they were baked for 1 hour at 60°C. After baking, sections were deparaffinized through three changes of xylene and rehydrated through graded alcohols into water. Heat-induced epitope retrieval was performed by boiling sections in citrate buffer pH 6.0 (pH 6.2 for ER- $\beta$ ) for 15 minutes on a laboratory hotplate. After boiling, sections were removed from the hotplate, allowed to cool at room temperature for 20 minutes, and were then rinsed thoroughly with water (sections stained for PSA did not require heat-induced epitope retrieval). Sections were then placed in 3% hydrogen peroxide for 15 minutes at room temperature to block endogenous peroxidase, washed with water, and placed in PBS (Sigma). Sections were then incubated with Power Block (Biogenex) nonspecific blocking reagent for 10 minutes at room temperature to reduce nonspecific staining, washed with water, and placed in PBS. Sections were then incubated with normal goat serum at 1:50 (Vector, Burlingame, CA) for 15 minutes at room temperature. The goat serum was then shaken off and sections were incubated with primary antibodies overnight at 4°C. After overnight incubation, each section received 20 seconds of washing with PBS, 20 seconds of washing with Biogenex Optimax detergent wash solution, followed by 10 minutes of washing in PBS on a rotator. Solutions were changed for every eight slides. After washing, sections were incubated with either Biogenex Multilink secondary antibody at a dilution of 1:20 for 20 minutes at room temperature or DAKO (Carpinteria, CA) ready to use secondary antibody for 10 minutes at room temperature. Sections were again washed according to the protocol described above. Sections were then incubated with either Biogenex streptavidin-conjugated horseradish peroxidase at a dilution of 1:20 for 20 minutes at room temperature or DAKO ready to use streptavidin-conjugated alkaline phosphatase for 10 minutes at room temperature. Sections were again washed as previously described. Immunostaining was visualized using either Biogenex liquid 3,3-diaminobenzidine (Biogenex) or DAKO's New Fuchsin as the chromogen. After development, sections were rinsed in water, lightly counterstained with 10% Harris modified hematoxylin.

Positive controls for GC-17 included DU145 cells (see above and Results) and tissue sections of prostate that were previously shown to be consistently stained with the antibody. Positive tissue controls for ER- $\alpha$  were human breast cancers, shown to contain numerous immunostained cells. Morphologically normal human prostate sections served as positive controls for AR as well as for anti-high molecular weight cytokeratin and MIB5/Ki-67

stains. For all reagents, negative controls were performed by substituting the primary antibody with a class-matched isotype.

### *LCM and RT-PCR*

In all instances, immunohistochemical studies for ER- $\beta$  were performed on the paraffin tissue sections that were adjacent to the frozen sections used for microdissection and RT-PCR analysis. Frozen sections were cut on a cryostat at 5  $\mu\text{m}$  and placed on precleaned glass slides (Fisher Scientific, Pittsburgh, PA) and immediately fixed in 70% ethanol for 5 seconds. The sections were then briefly dipped in distilled water, stained with 10% Harris hematoxylin for 15 seconds, dipped in distilled water, then successively placed in 70% ethanol for 30 seconds, briefly immersed in 1% eosin then placed in 95% ethanol for 1 minute, two changes of 100% ethanol for 1 minute each, and two changes of xylene for 30 seconds each. After air-drying for ~30 minutes, tissues were microdissected using a Pixcell 2 LCM unit (Arcturus, Mountainview, CA). Eight to 10 normal acini were microdissected from each of three different cases. Similarly, 10 to 20 dysplastic glands were dissected from four separate cases of high-grade lesions, and approximately the same numbers of neoplastic glands were obtained from five cases of grade 3 and six different examples of grade 4/5 carcinomas. RNA was extracted from each sample and then separately subjected to RT-PCR analysis. Total cellular RNA was separately isolated using RNA Stat-60 reagent (Tel-Test Inc., Friendwood, TX) according to protocols provided by the manufacturer. The total isolated cellular RNA was reverse-transcribed using the Gene-Amp RNA PCR kit (Perkin Elmer, CT) in total 20- $\mu\text{l}$  reaction mixture and 2  $\mu\text{l}$  of the resulting cDNA was used in PCR on ER- $\alpha$ , AR, and GAPDH and 3  $\mu\text{l}$  for PCR on ER- $\beta$ . Hot start PCR using AmpliTaq Gold DNA polymerase (Perkin-Elmer) was used in all amplification reactions. The enzyme was activated by preheating the reaction mixtures at 95°C for 6 minutes before to PCR. The PCR programs were 45 cycles for GAPDH and 55 cycles for ER- $\alpha$ , AR, and ER- $\beta$  of 1 minute at 94°C, 1 minute at 60°C (annealing temperature), and 1 minute at 72°C. This protocol was chosen to minimize nonspecific product amplification. The primer sequences for ER- $\alpha$ , AR, and GAPDH were described in our previous study.<sup>28</sup> The primer set for ER- $\beta$  was newly designed and the forward primer is 5'-GATGAGGGGAAATGCGTAGA-3' and the reverse primer is 5'-CTTGTTACTCGCATGCCTGA-3'.

AQ: H

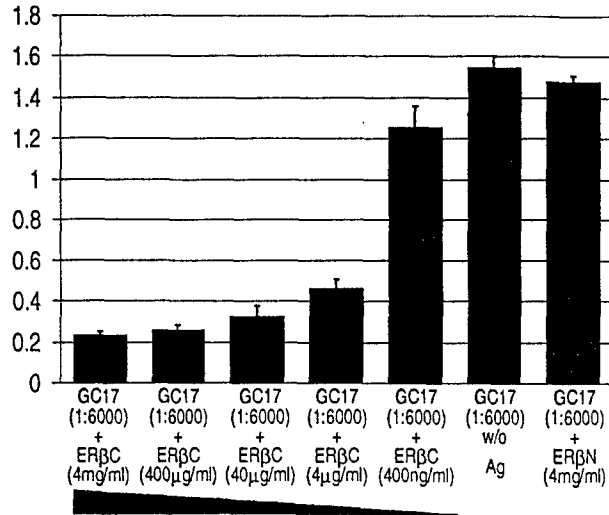
## *Results*

### *Specificity of the GC-17 Antibody*

#### *Competitive ELISA*

Preincubation of GC-17 with the immunizing peptide (C-terminus of ER- $\beta$ , ER $\beta$ C) successfully suppressed binding to the recombinant protein (Figure 1). The suppression occurred in a concentration-dependent manner

F1



**Figure 1.** Competitive ELISA. This graphic representation illustrates the concentration-dependent competition of the immunizing peptide (ERβC) with the GC-17 antibody. In addition, preincubation with 4 mg/ml of the control N-terminus peptide (ERβN) and GC-17 failed to compete out the binding to the recombinant ER-β peptide, demonstrating the specificity of the antibody. The GC-17 antibodies, bound to recombinant ER-β protein on ELISA plates, were recognized by alkaline phosphatase-conjugated anti-rabbit IgG antibodies. The whole complexes were visualized by incubation with *p*-nitrophenyl phosphate. The optical density at 405 nmol/L was measured. The entire assay was done four times. The column represents the mean value of optical density at 405 nmol/L of four measurements and the bar represents the SD. w/o, GC-17 preincubated without peptide antigen.

when compared to the control where the antibody was not preincubated with the immunizing peptide. In contrast, preincubation of GC-17 with the control N-terminus peptide of ER-β (ERβN) did not significantly suppress binding when compared with the control, indicating that the antibody was not cross-reactive with this region of the ER-β protein.

### Competitive Immunocytochemistry

Strong nuclear immunostaining was detected in sections of DU145 and LNCaP cells that served as positive controls for the peptide competition studies (Figure 2A). Preincubation of GC-17 with either 400 μg/ml or 40 μg/ml of the immunizing peptide ERβC totally abolished nuclear staining in sections of these cells, when compared with positive controls where the peptide was omitted (Figure 2B). Identical results were obtained with sections of human prostate (Figure 2, C and D). In contrast, preincubation of GC-17 with the recombinant ER-α protein failed to block ER-β immunostaining of DU145 cells by the antibody (data not shown). These studies confirmed that GC-17 does not cross-react with ER-α and supports data from our Western blot findings (see below). Thus, both the competitive ELISA and competitive immunocytochemistry showed GC-17 to be highly specific for binding to the ER-β protein.

In addition, DU145 and LNCaP cells, that only express ER-β,<sup>28</sup> were negative when immunostained with the ER-α (NCL-ER-6F11) antibody. Positive staining of prostate tissues with the ER-α antibody was restricted to stromal cells (see Immunohistochemistry of Normal Prostate below).

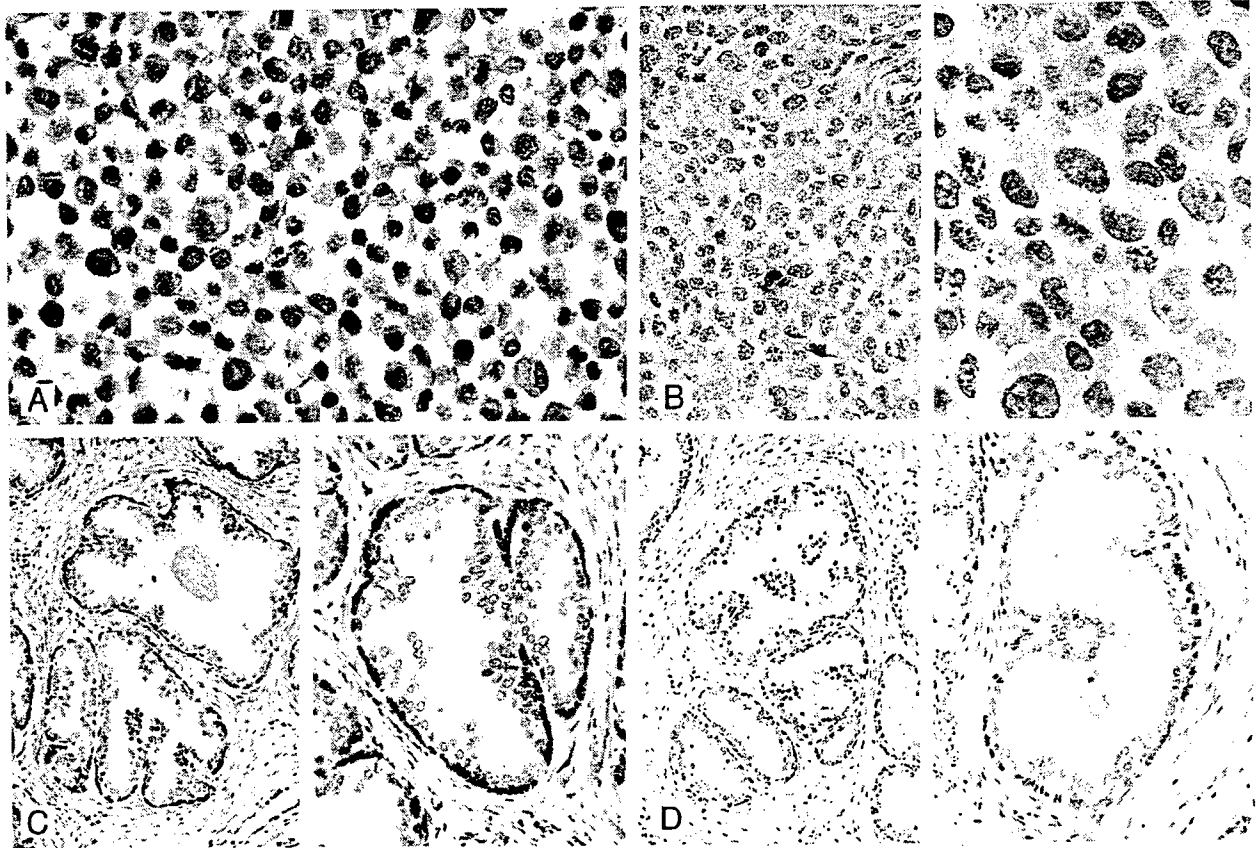
### Western Blot Analysis

Using Western blot analysis, GC-17 was demonstrated<sup>F3</sup> to specifically recognize two commercially available recombinant ER-β proteins and show no cross-reactivity to an ER-α recombinant protein (Figure 3; A, B, and C). The recombinant short-form ER-β protein (RP311) from Affinity Bioreagents Inc. has an estimated molecular size of 53 kd and represents a polypeptide (corresponding to amino acid residues 43 to 530) translated from the second initiation codon of the ER-β transcript.<sup>16-18</sup> The recombinant long-form ER-β protein (corresponding to amino acid residues 1 to 530) from PanVera represents the polypeptide translated from the first initiation codon of the transcript and has an estimated molecular size of 59 kd. Both short- and long-forms of recombinant receptor proteins were recognized by the GC-17 antibody as bands of their predicted sizes of 53 kd (Figure 3B) and of 59 kd (Figure 3C) in the Western blots. Interestingly, GC-17 recognized a protein of ~63 kd in lysates prepared from the human prostatic cancer cell line DU145 (Figure 3C), the putative human prostatic basal cell culture PrEC (Figure 3C), as well as from normal human testis and prostate tissues (Figure 3, B and C). In a previous study,<sup>19</sup> it was demonstrated that transfection of A549 cells with plasmids carrying a long-form ER-β nucleotide sequence or a short-form ER-β sequence the polypeptides expressed *in cellulo* had higher molecular sizes than those predicted from the numbers of their amino acid residues. In this regard, the *in cellulo*-translated polypeptide from the long-form coding sequence of ER-β had a molecular size of ~63 kd that is larger than the predicted size of 59 kd from amino acid length estimation. Similarly, the *in cellulo*-translated polypeptide from the short-form nucleotide sequence was ~56 kd instead of the predicted 53 kd. These data suggest post-translational modifications of the ER-β molecule occur in cells. Importantly, our Western blot analyses with GC-17 revealed expression of only a 63-kd polypeptide in DU145 and PrEC cells as well as in normal prostate and testes tissues. These findings support the notion that the long-form ER-β may be the receptor form expressed in cells and tissues. The level of ER-α protein in human normal testis and prostate tissues was undetectable with the 1D5, the anti-human ER-α antibody (Figure 3A) when ECL-Western blots were exposed to X-ray films for 30 seconds. However, very weak signals derived from the ER-α protein could be detected when the blots were exposed to X-ray films for more than 10 minutes.

### Immunohistochemistry of Prostate Tissues

#### Normal Prostate

In morphologically normal ducts and acini, nuclear ER-β<sup>F4</sup> expression was consistently densely localized in nuclei of basal cells as defined by anti-high molecular weight cytokeratin staining in replicate sections (Figure 4, A and B). Strong nuclei staining was absent in secretory cells but frequently observed in stromal cells. Occasionally nuclear membrane staining for the receptor was also evident in a



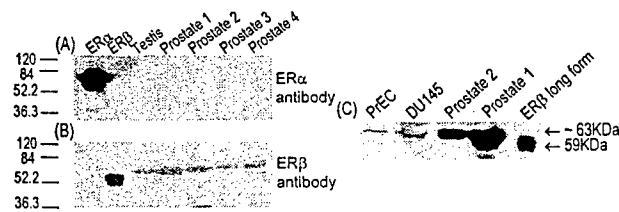
**Figure 2.** Competitive ER- $\beta$  immunostaining DU145 cells (A and B) and normal prostate (C and D). **A:** DU145 cells immunostained in the absence of competing peptide are shown. Note the strong nuclear staining in the majority of cells (original magnification,  $\times 265$ ). **B:** After incubation of GC-17 with  $40 \mu\text{g}$  of the immunizing peptide, there was almost a total absence of cells with positively stained nuclei (compare with A) [original magnifications:  $\times 115$  (left),  $\times 350$  (right)]. **C:** Tissue section of normal prostate. In the absence of competing peptide strong immunostaining of cells in the basal layer of glands is seen in this section of prostate (see also Figure 4, A and B) [original magnifications:  $\times 115$  (left),  $\times 230$  (right)]. **D:** A replicate section of the prostate illustrated in C after preincubation of GC-17 with  $40 \mu\text{g}$  of immunizing peptide. Note the absence of immunostaining in these sections [original magnifications:  $\times 90$  (left),  $\times 280$  (right)]. For details of the procedures used in these studies see Materials and Methods. All sections were counterstained with 10% Harris hematoxylin.

few luminal cells (Figure 4, A and B). ER- $\alpha$  immunostaining was not present in secretory cells of normal ducts and acini but individual scattered receptor-positive basal cells were observed in less than 10% of all sections studied. The  $\alpha$

receptor was however consistently found in stromal cell nuclei, especially in periglandular locations.

Pronounced nuclear staining for AR was a constant finding in secretory and stromal cell nuclei. In agreement with a past study,<sup>39</sup> variable immunostaining for AR was also observed in individual basal cells of normal glands. No difference was found in the cellular localization of the three steroid hormone receptors when the peripheral, transition, and central zones of the prostate were compared. Moreover, the same localization of the steroid hormone receptors, found in the three normal zones, was also seen in foci of benign prostatic hyperplasia.

The most consistent immunolocalization for the three receptors in basal cells was found within periurethral ducts.



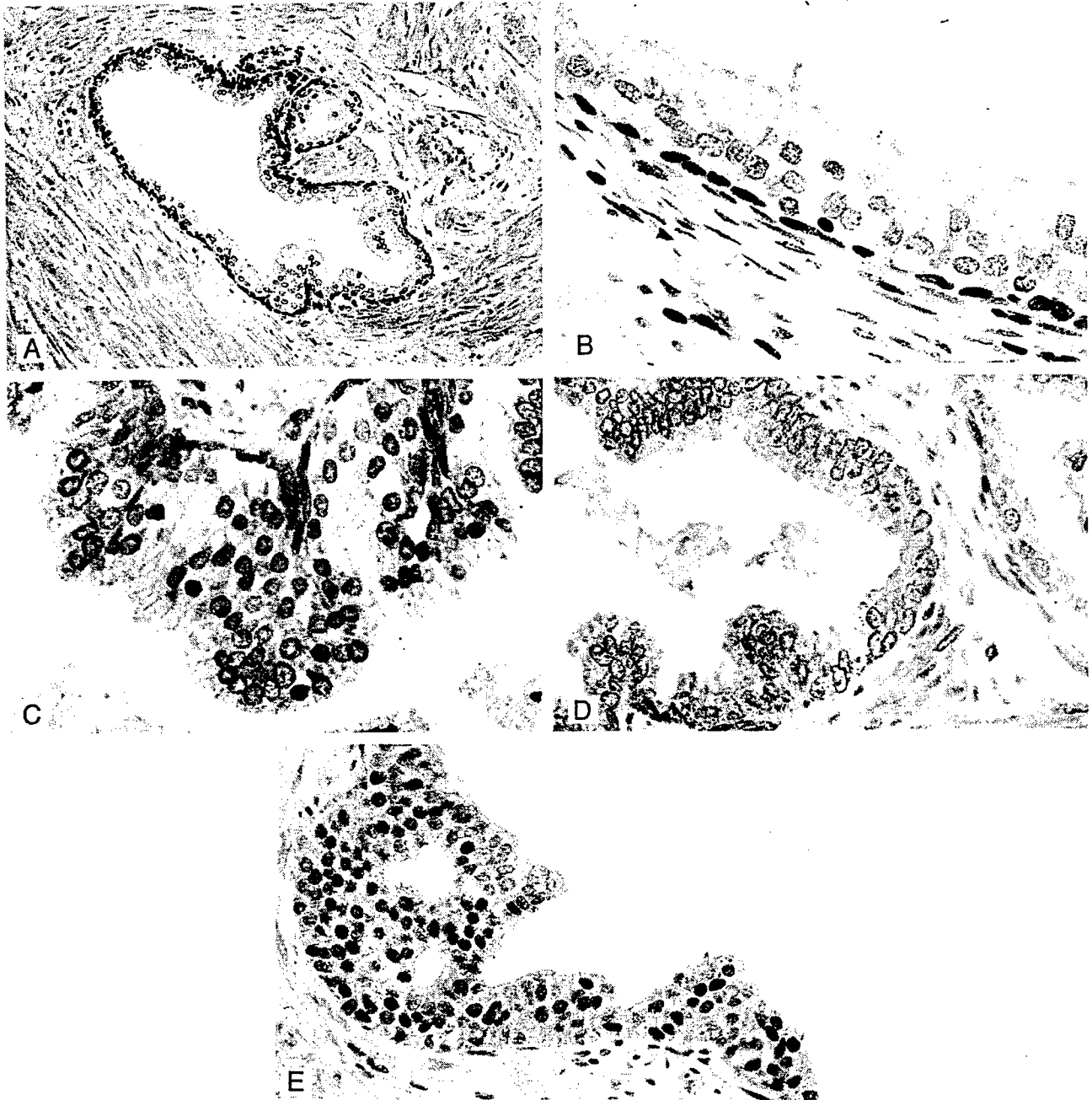
**Figure 3.** Western blot analysis. These autoradiographs illustrate the binding ability and specificity of GC-17 to ER- $\beta$  protein and its lack of cross-reactivity with ER- $\alpha$  protein. **A and B:** Shown from left to right are the ER- $\alpha$  recombinant protein, short form of ER- $\beta$  recombinant protein, and tissue lysates from human testis and normal prostate (1 to 4). **C:** From left to right are cell lysates of PrEC and DU145 cells, tissue lysates from human normal prostate (1 and 2), and long form of ER- $\beta$  recombinant protein. The recombinant proteins and cell or tissue lysates were separated with SDS-PAGE gel and the separated proteins were transferred onto PolyScreen polyvinylidene difluoride transfer membrane. The blot was incubated with the ER- $\alpha$  monoclonal antibody (A) or GC-17-ER- $\beta$  polyclonal antibody (B and C) and the complexes were visualized by the chemiluminescence ECL detection system followed by autoradiography. Note that the antibody detects only the ER- $\alpha$  protein using ER- $\alpha$  monoclonal antibody and GC-17-ER- $\beta$  polyclonal antibody does not detect the ER- $\alpha$  protein but clearly identifies single bands for both forms of ER- $\beta$  recombinant proteins and for the cell or tissue lysates. These bands correspond to the reported size of the short and long forms of the receptor (see Results).

### Dysplastic Lesions

Immunohistochemical findings in dysplastic and carcinomatous lesions are summarized in Table 1.

In the peripheral zone, a consistent pattern of ER- $\beta$  expression was found in dysplastic lesions. A secretory cell localization for nuclear ER- $\beta$  expression was commonly observed in low- to moderate-grade dysplastic lesions (Figure 4C). The majority of both basal and dysplastic secretory cells in these lesions, contained moder-

(4)



4/c

**Figure 4.** **A and B:** Immunolocalization of ER- $\beta$  in the normal human prostate using the GC-17 antibody. Note the strong staining of cells in the basal layer and its virtual absence in the nuclei and cytoplasm of secretory cells (best seen in **B**). Some nuclear membrane staining was however evident in a few secretory cells (**A and B**). Nuclear staining is also evident in stromal cells. Original magnifications:  $\times 100$  (**A**),  $\times 400$  (**B**). **C:** ER- $\beta$  immunostaining in low/moderate-grade dysplasia. Moderate to strong expression of the receptor is evident in dysplastic secretory cells. Note also the strongly stained cells in the basal layer (original magnification,  $\times 400$ ). **D:** ER- $\beta$ -immunostained section of high-grade dysplasia. Nuclear staining is almost totally absent in this lesion. In some dysplastic cells light staining of nuclear membranes is evident. This area of the lesion is almost totally devoid of receptor-stained basal cells. A few residual-stained basal cells are however evident in the **bottom left** corner of the lesion. Note the presence of two positively stained basal cells in a portion of a normal gland on the **right** (original magnification,  $\times 250$ ). **E:** ER- $\alpha$  immunostaining in dysplasia of the central zone. The majority of dysplastic cells are immunostained for the receptor in this lesion. There was however great variation in the percentage of positive cells found in these central zone lesions. Intraluminal pseudo-gland formation seen here was common in dysplasias of the central zone (Original magnification,  $\times 200$ ). All sections were counterstained with 10% Harris hematoxylin.

ate to strongly stained nuclei (Figure 4C). A marked diminution to total absence of ER- $\beta$  immunostained nuclei was a consistent feature in almost all dysplastic cells in the high-grade lesions we studied (Figure 4D). Staining was however present in residual basal cells within these high-grade lesions. Thus, a loss of ER- $\beta$  staining in high-grade dysplasias paralleled a decline in receptor-posi-

tive basal cells. In contrast to normal cells, the cytoplasm of dysplastic cells in lesions of all grades but especially in high-grade lesions were frequently stained by the GC-17 reagent, a feature not seen when the primary antibody was omitted from the incubation or with the use of any of the other anti-receptor reagents. Similarly nuclear membrane of cells in high-grade dysplastic cells also fre-

**Table 1.** Immunohistochemical Findings in Dysplasias and Carcinomas

Lesion	ER- $\alpha$	ER- $\beta$	AR
Dysplasia/peripheral zone			
Moderate grade*	-	+	+
High grade	-	-	+
Dysplasia/central zone*	+	+	+
Carcinoma/peripheral zone			
Grade 3	-/+	+	+
Grade 4/5	-/+	-/+	+
Carcinoma/transition zone	-	-	+
Metastatic carcinoma			
Bone	-	+	+
Lymph nodes	-/+++	+	+

\*Data reflects positive staining in dysplastic and basal cells. Staining restricted to residual basal cells in high-grade dysplasias. +, Positive staining in >50% of cases; -/+++, positive staining in 40% of cases; -/+, positive staining in <20% of cases. See text for estimates of the percent of positively stained cells in each lesion.

quently stained with the GC-17 antibody (Figure 4D). ER- $\alpha$ -positive dysplastic cells were not present within any of the peripheral zone lesions we studied.

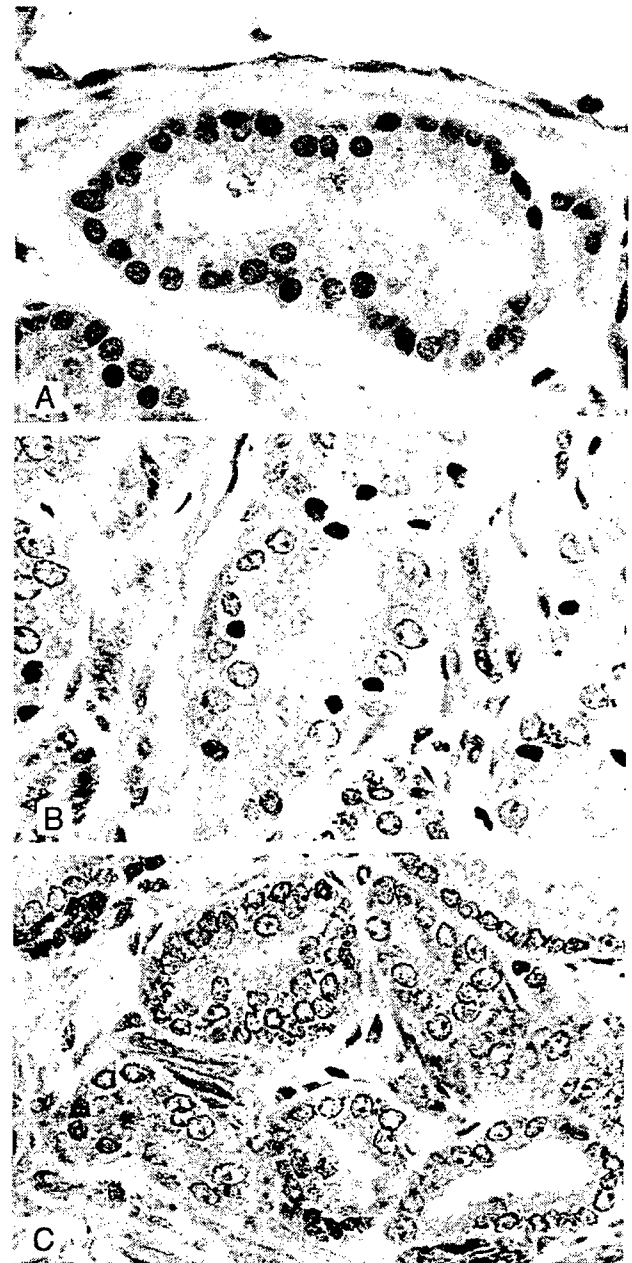
In marked contrast, ER- $\alpha$ -stained cells were detected in five of seven (71%) of dysplasias in the central zone (Figure 4E). There was however great variation in the numbers (10 to 90%) of immunopositive cells in any given central zone lesion. In replicate sections, six of these lesions contained dysplastic cells that were also positive for ER- $\beta$  staining.

As previously reported,<sup>41</sup> AR was strongly expressed in the majority (>95%) of dysplastic cells irrespective of the origin or grade of the lesion.

#### Grade 3 and 4/5 Carcinomas

A transition from ER- $\beta$ -positive to ER- $\beta$ -negative staining of cells was observed in all 21 cases where cancer was found in the peripheral zone that paralleled the progression of the grade 3 carcinomas to the less differentiated grade 4/5 neoplasms. ER- $\beta$ -positive cells were found in 13 of 15 (87%) grade 3 carcinomas of the peripheral zone. The spectrum of expression ranged from examples where all nuclei in an individual neoplastic gland were strongly stained (Figure 5A) to instances in which receptor immunostaining was weak and/or found in few cells within a given microscopic field. The latter examples were most often located in areas where a transition to higher grade carcinoma occurred (Figure 5B). Unlike their counterparts in the peripheral zone, the vast majority of cells comprising grade 3 clear cell carcinomas in the transition zone were devoid of ER- $\beta$  immunostaining. In two of five cases, scattered receptor-positive neoplastic cells were however found in a minority of glands (Figure 5C).

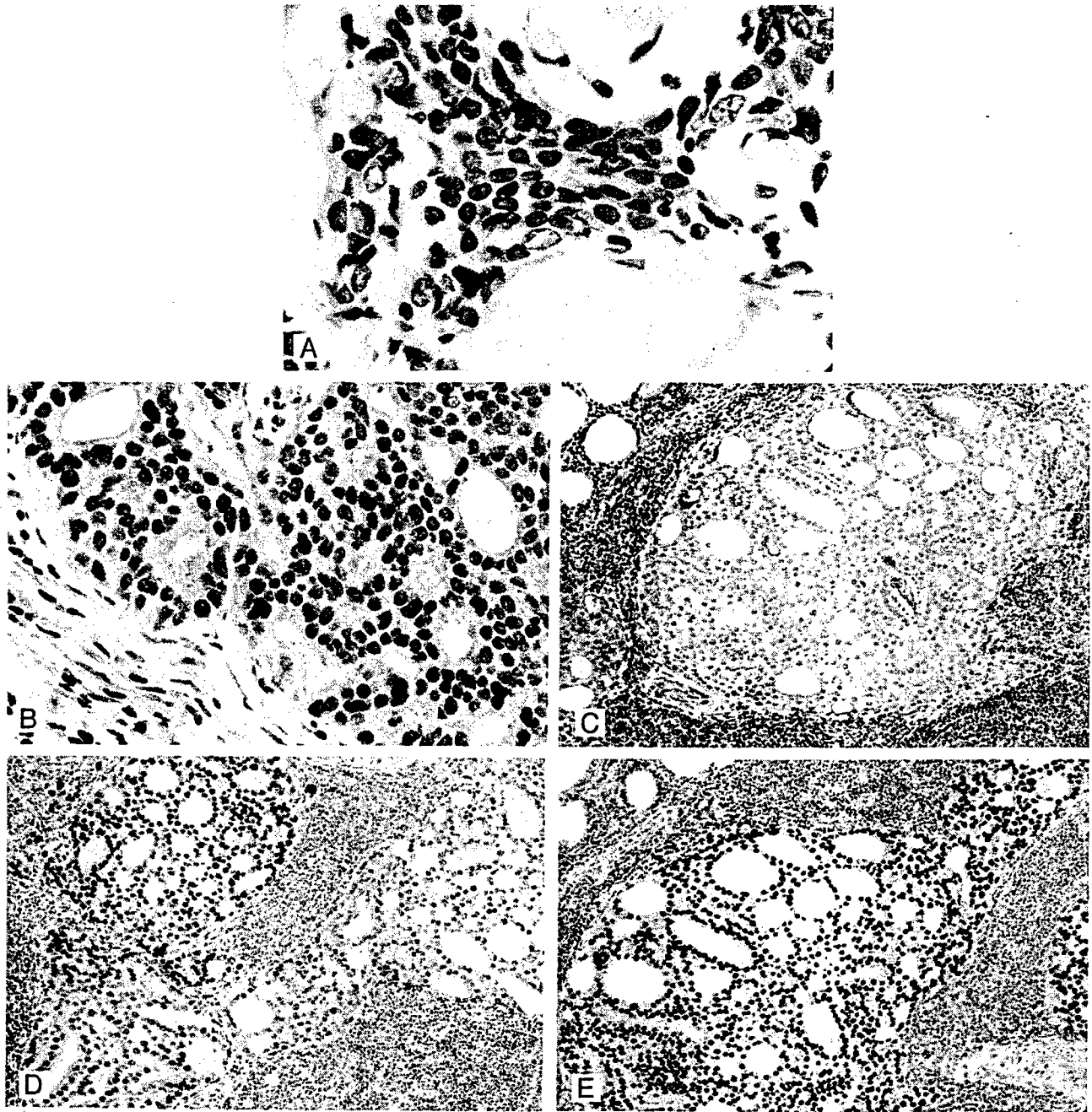
Almost complete absence of ER- $\beta$  nuclear staining was seen in all but 3 of 15 (20%) grade 4/5 carcinomas (Figure 5C). In the majority of cases however staining of the nuclear membrane was frequently apparent. In the three cases, positive cells represented only 10% or less of the total cancer cells in a given lesion and the staining intensity was usually diminished.



**Figure 5.** A: ER- $\beta$  staining in grade 3 carcinoma. Strong nuclear immunostaining is evident in this grade 3 carcinoma. Light cytoplasmic staining of neoplastic cells is also present. Although positive immunostaining for the receptor was found in the majority of grade 3 cancers there was variation in the percentage of stained cells in any given lesion. This was especially the case in areas of transition from grade 3 to grade 4/5 carcinoma (see C) (original magnification,  $\times 400$ ). B: ER- $\beta$  immunostaining of a clear cell carcinoma in the transition zone. Immunostaining for the receptor is absent in the majority of cells in this grade 3 clear-cell carcinoma. Scattered among the negatively stained cells are cells with small nuclei that are immunopositive for the receptor. The occurrence of these positive cells was uncommon in clear cell carcinomas. In most of these cancers all of the cells were unstained for the receptor. Interestingly, in replicate sections, these ER- $\beta$ -positive cells were negative for AR immunostaining whereas the reverse was true for the majority of cells that were negative for the  $\beta$  receptor (original magnification,  $\times 400$ ). All sections were counterstained with 10% Harris hematoxylin. C: ER- $\beta$  staining in an area of transition from grade 3 to grade 4/5 carcinoma. The majority of nuclei in this cancer are unstained. A few positively stained nuclei are however seen in two grade 4/5 glands (bottom left) and in a single cell in a grade 3 gland (bottom right). Light cytoplasmic staining is evident in most cells. Nuclear membrane staining is also present in many of these cells. Cytoplasmic staining was common in all grades of dysplasia and carcinoma. Nuclear membrane immunostaining was however only a feature of high-grade dysplasias and grade 4/5 carcinoma (original magnification,  $\times 400$ ).

bottom align

F5



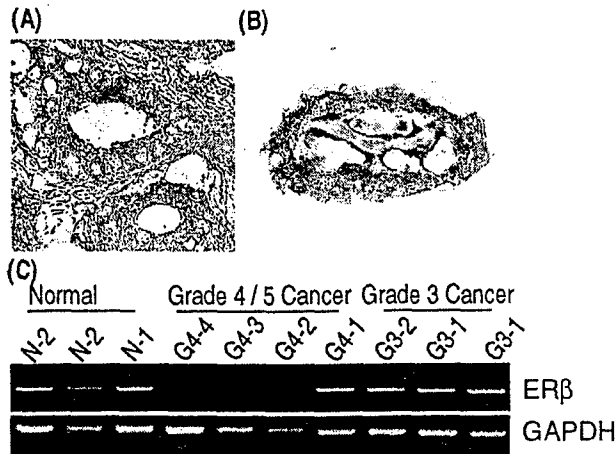
(4)

**Figure 6.** A: ER- $\beta$  immunostaining in a prostatic carcinoma metastatic to bone. Note the strong nuclear immunostaining for the  $\beta$  receptor in this metastatic lesion. The neoplastic cells are localized between spicules of bone. Strong to moderate staining was present in the majority of metastases to bone (original magnification,  $\times 400$ ). B: ER- $\beta$  immunostaining in a prostatic carcinoma metastatic to an internal iliac lymph node. Strong nuclear immunostaining is evident in this metastatic lesion. Strong PSA immunostaining of these cells were found (not illustrated). Note that the nuclei of several stromal cells in this lymph node are also positively stained for the receptor (original magnification,  $\times 400$ ). C: ER- $\beta$  immunostaining of a prostatic carcinoma metastatic to a lymph node. In this example the metastatic cells were unstained for the receptor. Cells in this same cancer were however immunostained for ER- $\alpha$  and AR (see D and E). As was the case for the metastasis illustrated in B these cells were strongly PSA-positive. Note that lymphocytes are strongly stained for the receptor, which was a consistent finding and provided an internal positive control for immunostaining with the  $\beta$  antibody (original magnification,  $\times 100$ ). D: ER- $\alpha$  immunostaining of the same lesion illustrated in C. Immunopositive cells are seen scattered throughout this metastatic lesion. In one other case of lymph node metastasis a very few positive cells ( $<10\%$ ) were present. ER- $\beta$  was however strongly expressed in that metastatic lesion. Note the absence of ER- $\alpha$  immunostaining of lymphocytes, a consistent finding that was in contrast to ER- $\beta$  staining in these cells (original magnification,  $\times 100$ ). E: Representative section of AR immunostaining in metastatic lymph node lesions. Strong nuclear staining was uniformly found in the majority of cells that comprised these metastatic lesions. Cytoplasmic staining occurred only in metastases from the patient who had received anti-androgenic therapy. Lymphocytes were lightly stained for AR (original magnification,  $\times 100$ ). All sections were counterstained with 10% Harris hematoxylin.

Immunostaining for ER- $\alpha$  was detected in only 2 (7.6%) of the total 26 cases of primary carcinoma we studied. In these two instances, a few ( $<10\%$ ) weakly positive cells were found in both grades 3 and 4/5 carcinomas. Stain-

ing for the receptor was consistently absent in all clear cell carcinomas of the transition zone.

Irrespective of grade, strong nuclear AR immunostaining was a constant feature in the vast majority cells



**Figure 7.** **A** and **B:** LCM dissection of a grade 3 carcinoma. **A:** The grade 3 neoplastic gland that was microdissected is seen in the center of this microscopic field (original magnification,  $\times 325$ ). **B:** The microdissected lesion is seen on the transfer cap (original magnification,  $\times 325$ ). Both sections were lightly stained with 10% Harris hematoxylin. **C:** Results of RT-PCR analysis of ER- $\beta$  mRNA on microdissected human normal prostate acini (N-1 and N-2) and grade 3 (G3-1 and G3-2) and 4/5 (G4-1 to G4-4) carcinomas. Total RNAs were extracted from the microdissected tissues on transfer cap and reverse-transcribed. The resultant cDNAs were subjected to PCR analyses. The amplified products were run into 2% agarose gel with ethidium bromide. Representative fluorographs for ER- $\beta$  and GAPDH RT-PCR analyses are shown.

(>95%) comprising cancers of the peripheral zone. Nuclear AR immunostaining was also present in almost all grade 3 clear-cell carcinomas but it was less intense than that found in peripheral zone carcinomas. Interestingly, the occasional few cells that were ER- $\beta$ -positive in these cancers were found to be negative for AR expression in replicate sections.

No change in the location or intensity of immunostaining for the three receptors in the stroma was evident in sections that contained carcinoma.

#### Metastatic Lesions

Nuclear ER- $\beta$  immunostaining was present in metastatic carcinoma cells in bone lesions from all but one of the seven cases (Figure 6A). The intensity of signal did however vary from strong to weak staining within cells comprising the lesions of individual case and/or among the cases. In three instances, carcinoma cells were surrounded by a prominent desmoplastic response in which ER- $\beta$  staining was frequently found in the nuclei of fibroblasts. Nucleated hematopoietic marrow cells were also positive for the receptor whereas mature red cells were negative, a finding that served as a positive and negative internal tissue control for ER- $\beta$  immunostaining in these lesions.

In contrast to the finding of ER- $\beta$  immunostaining in foci of all but one case of bone metastasis, no staining was observed for ER- $\alpha$  in these lesions. Despite the fact that all of the seven patients, including the one that lacked ER- $\beta$  expression had been given anti-androgenic therapy, nuclear AR staining was observed in most metastatic cells in the bone biopsies. However AR staining was also consistently present in the cytoplasm as well as in the nucleus of metastatic cells, a finding observed in

bone and lymph node lesions from all patients who received anti-androgenic therapy (see below).

PSA immunostaining was found in metastatic bone lesions in four cases but it tended to be scant especially when compared to lesions in lymph nodes from patients who did not receive anti-androgenic therapy (see following discussion).

Among the five cases of lymph node metastases, two contained a majority of neoplastic cells (>50%) that were uniformly strongly stained for ER- $\beta$  (Figure 6B): In one case immunostaining for the receptor was absent in the metastatic cells (Figure 6C) whereas in the remaining two cases a mix of negative and positively stained neoplastic cells were found. In one of the two cases, in which strong receptor expression was detected, the patient had been treated with the LH/RH agonist Lupron before surgery. Lymphocyte nuclei were consistently stained for the receptor and served as an internal positive tissue control in the two cases in which no receptor was detected in metastatic cells within the lymph nodes (Figure 6B).

ER- $\alpha$ -immunostained carcinoma cells were found in two of five cases of lymph node metastases. Both patients were untreated before surgery. In one of these cases, ER- $\beta$  staining was absent in metastatic cells (Figure 6C). In one case, numerous  $\alpha$  receptor-positive cells (>50%) were mixed with those in which receptor expression was absent (Figure 6D). Very weak staining for ER- $\alpha$  was identified in a few cells (<10%) in the other case.

In all five cases, AR immunostaining was present in the vast majority (>95%) of metastatic cells (Figure 6E). Nuclear AR expression was always strong in cancer cells and with the exception of the case where the patient received Lupron, cytoplasmic staining was not present in any of the metastatic cells. Strong PSA immunostaining was present in the cytoplasm of most metastatic cells in all cases including the one where the patient had received anti-androgenic therapy.

#### LCM/RT-PCR Analysis

An example of a LCM specimen used in our study is seen in Figure 7, A and B.

Our findings with RT-PCR analysis for ER- $\beta$  mRNA on LCM lesions approximated the results of immunohistochemical studies done on paraffin sections immediately adjacent to the frozen specimens used for RT-PCR as well as on other cases (Figure 7C). ER- $\beta$  transcripts were detected in two of the three samples of normal prostatic acini. In contrast, receptor message was found in only one of four microdissected samples of high-grade dysplasias. Sixty percent of grade 3 carcinomas contained ER- $\beta$  transcripts whereas receptor message was detected in two of six (30%) of the grade 4/5 cancers. In two cases where ER- $\beta$  message was present in grade 3 lesions, grade 4/5 carcinomas sampled within the same section lacked receptor mRNA expression. In close agreement with our immunohistochemical findings, AR mRNA was present in all normal glands, dysplasias, grade 3 cancers, and all but one of the grade 4/5 carcinomas. ER- $\alpha$  transcripts were not detected in any of the microdissected specimens we studied.

## Discussion

In this study we developed and comprehensively demonstrated the specificity of a novel antibody, prepared against the F domain of ER- $\beta$ . Using this reagent, together with antibodies for AR and ER- $\alpha$ , we immunolocalized the three receptors in normal human prostate, preneoplastic lesions, carcinoma, and in metastases. LCM/RT-PCR was used to assess the expression of the three receptors at the transcript level.

Using the GC-17 antibody reagent, we now show that ER- $\beta$  is predominately immunolocalized in basal cells and to a lesser extent in stromal cells of the morphologically normal human prostate. In addition nuclear membrane localization of ER- $\beta$  was occasionally observed in secretory cells. Our current studies have also confirmed past reports<sup>30,31</sup> that ER- $\alpha$  is detected in stromal cells and rarely in basal cells of the normal gland. As previously reported,<sup>41-43</sup> we found that AR was predominately localized in the nuclei of differentiated secretory cells and variably in basal cells of the normal acinar/duct unit as well as in stromal cells. The finding of all three receptors in stromal cells is compatible with the concept that they transduce steroid hormone signals to epithelial cells by a paracrine mechanism.<sup>43</sup> In this regard, Hall and colleagues<sup>44</sup> have reported that ER- $\beta$  functions as a transdominant inhibitor of ER- $\beta$  transcription and that it acts to decrease overall cellular sensitivity to estradiol. Therefore the  $\beta$  isoform, when co-localized with the  $\alpha$  receptor in stromal cells, may play a critical role in regulating paracrine signaling from these cells to epithelia. However the presence of ER- $\beta$  as virtually the sole ER subtype in basal cells, the purported precursor of secretory cells,<sup>9</sup> suggests that estrogens, acting through the receptor, may directly modulate the growth of these cells. In this context, it should also be noted that AR is variably expressed in basal cells.<sup>41,42</sup> Thus, proliferative signals mediated by AR in basal cells or by ER- $\alpha$  and AR in stromal cells may be opposed by the purported growth-inhibitory action of ER- $\beta$ <sup>25-28</sup> localized in basal cells.

Before the discovery of ER- $\beta$ <sup>5,6</sup> we reported that the separate administration of androgens and estrogens to hypophysectomized and castrated dogs induced marked proliferation of basal cells. Additionally, each hormone was found to direct distinct pathways of cell differentiation culminating in either squamous cells with estrogens or prototypic glandular cells with androgens.<sup>6</sup> Thus, although paracrine stimulatory signals emanating from stromal cells likely contributed to these effects, the direct action of the hormones mediated through their cognate receptors in basal cells may have also played a role. In either case results from these studies indicate that basal cells are major targets for the effects of steroid hormones in the prostate.

Mindful of these findings it was therefore of particular interest to trace the expression of ER- $\beta$ , normally localized in basal cells, and AR during prostatic cancer development and progression.

The transition from normal to low/moderate dysplastic glands in the peripheral zone was marked by the appearance of ER- $\beta$  homogeneously immunostained nuclei in

secretory as well as basal cells with no changes in the localization of the other receptors.

The expression of ER- $\beta$  was diminished in high-grade dysplasias when compared to normal glands and lower grade lesions. Because the receptor is predominately localized in basal cells in the normal gland, this finding is consistent with the reported depletion of these receptor-positive cells in the majority of high-grade dysplasias.<sup>37</sup> ER- $\beta$  staining was present in the majority of grade 3 carcinomas of the peripheral zone but was greatly diminished or absent in most grade 4/5 carcinomas. Interestingly nuclear membrane staining was evident in many cells in high-grade dysplasias and grade 4/5 carcinomas. The precise meaning of this finding is currently undefined but seems to represent the localization of ER- $\beta$  that occurs with neoplastic progression and could reflect alteration in receptor function. Recently, the promoter of human ER- $\beta$  gene has been cloned and showed regions of CpG islands.<sup>45</sup> The diminution of ER- $\beta$  expression in high-grade dysplasias and grade 4/5 cancers may be therefore related to the alteration of DNA methylation pattern in CpG islands of the promoter, resulting in down-regulation of the receptor at the transcriptional level.

While the underlying mechanism(s) for these findings in dysplasias awaits further investigation, based on the proposed anti-proliferative function of the receptor,<sup>25-28</sup> the presence of ER- $\beta$  in secretory cells of low/moderate-grade lesions may represent a transient abortive attempt to counter growth of these cells. In contrast, the attrition of receptor-positive basal cells in the high-grade dysplasias may signify a continuing loss of growth inhibitory function mediated by ER- $\beta$  in these precursor lesions. The reappearance of the  $\beta$  receptor in most grade 3 carcinomas and its possible effects on cancer growth is perplexing but may be related to the more favorable prognosis reported for these well-differentiated neoplasms.<sup>38</sup>

Interestingly, in contrast to grade 3 carcinomas of the peripheral zone, expression of the  $\beta$  receptor was present only in a few scattered cells that comprised clear cell cancers of the transition zone. The differences in  $\beta$  receptor expression between the two grade 3 cancers likely reflect a distinct biology inherent in neoplasms with the clear cell phenotype.

Although absent from peripheral zone lesions, ER- $\alpha$  staining was however found in dysplastic cells in most lesions of the central zone. This finding may reflect suspected biological differences<sup>46</sup> as well as distinct pathways of hormone responsiveness between the zones of the human prostate that could play a role in the pathogenesis of these lesions. Interestingly, the central zone is rarely the site of origin for prostate cancer.<sup>47</sup>

Our findings of RT-PCR analysis for ER- $\beta$  mRNA expression on microdissected specimens approximated results from our immunohistochemical studies, indicating that receptor expression was down-regulated at both the transcriptional and translational levels in high-grade dysplastic and 4/5 grade neoplastic lesions. Our findings in prostate therefore differ from those reported for human colon cancer in which Folley and colleagues<sup>48</sup> demonstrated that a selective loss of ER- $\beta$  protein but not receptor message expression occurs in these neoplasms.

These authors attributed the loss of ER- $\beta$  protein in colon cancers to be from posttranscriptional modifications of the receptor.

In our study ER- $\alpha$  expression was limited to only a small subset of dysplastic lesions in the central zone and to a very few primary carcinomas in the peripheral zone. Our findings therefore differed from those of Bonkhoff and colleagues<sup>33</sup> who found immunostaining for the receptor in high-grade dysplasias and grade 4/5 carcinomas. Using *in situ* hybridization these authors also reported that a high percentage of dysplasias and carcinomas in their study contained cells that expressed ER- $\alpha$  message. These results again differed from our findings as we did not detect ER- $\alpha$  message in any dysplasias or primary carcinomas we studied using the highly sensitive and specific LCM/RT-PCR analysis.

Unlike ER- $\beta$ , AR was consistently strongly expressed at both the transcript and immunohistochemical levels, irrespective of grade, across the spectrum of preneoplastic lesions and carcinomas we studied. These results are in agreement with our past studies of AR in dysplasias<sup>41</sup> and those of others in both primary and metastatic carcinomas.<sup>49</sup> Importantly, results from a past study<sup>50</sup> demonstrated the presence of structurally intact AR that functionally binds androgen in the majority of both hormone-dependent and -independent carcinomas. Our current findings, together with those cited above, suggest that AR is expressed and functional in the majority of high-grade dysplasias and primary prostate cancers. It is therefore possible that continued androgen-mediated stimulation of dysplastic and tumor cells, coupled with the apparent loss of ER- $\beta$  expression, may enhance carcinogenic progression as well as the growth of established prostatic carcinomas.

One of the most intriguing findings in our study was the high percentage of cases (83%) where the expression of ER- $\beta$  was present in prostatic carcinoma cells metastatic to bone and regional lymph nodes. In marked contrast, ER- $\alpha$  staining was absent in all but two cases where receptor-positive cells were found in lymph node metastases.

Although 58% of the patients with metastatic lesions in our study had been given anti-androgen therapy, positive staining for ER- $\beta$  was also present in cancer cells within the lymph nodes of three individuals that had not received this treatment. The presence of ER- $\beta$  in metastatic cells from patients who did or did not receive anti-androgenic treatment suggests that blocking of androgen action was not a primary cause for the expression of the receptor in these sites.

It is tempting to speculate that the new tissue microenvironment in which these metastatic cells are found may have provided local factors that influenced the expression of ER- $\beta$  and to a lesser extent ER- $\alpha$  in these sites. In this context, it has been reported that bone fibroblasts produced growth factors that induced human prostate cancer growth.<sup>51</sup> Alternatively, the metastatic process may, in some undefined manner, have favored the spread of cells with either ER isoform from the primary cancer.

In summary, we demonstrate that a consistent pattern of lost ER- $\beta$  expression at both the transcriptional and translational levels occurs during prostatic carcinogenesis and tumor progression. This may signify the loss of an important role the receptor would normally play in inhibiting growth of the prostate that could contribute to neoplastic development. The continued expression of presumably functional AR throughout these processes, as well as other undefined factors, may therefore exert persistent unopposed growth stimulus acting on these cells.

The cause of ER- $\beta$  expression and the effects that it may have on the growth of metastatic cells remains to be defined. The presence of the  $\beta$  isoform in these cancer cells may however have important ramifications for the treatment of patients with late-stage disease. In this regard, we recently reported that estrogens as well as anti-estrogens are potent growth inhibitors of human prostate cancer lines that express both ER isoforms.<sup>28</sup> In contrast, the growth of cells such as DU145, which only express ER- $\beta$ , was markedly inhibited by the anti-estrogen ICI 182,807. These findings together with results from our current studies may therefore be helpful in devising new ligand-specific strategies for treating patients with metastatic prostate cancer.

## References

1. Grayhack JT, Keeler TC, Kozlowski JM: Carcinoma of the prostate. Hormonal therapy. *Cancer* 1987, 60:589-601
2. Kozlowski JM, Ellis WJ, Grayhack JT: Advanced prostatic carcinoma. Early versus late endocrine therapy. *Urol Clin N Am* 1991, 18:15-24
3. Huggins C, Hodges CV: Studies on prostatic cancer. I. The effect of castration, of estrogen and androgen injection on serum phosphatases in metastatic carcinoma of the prostate. *CA Cancer J Clin* 1972, 22:232-240
4. Helpap B, Stiens R: The cell proliferation of epithelial metaplasia in the prostate gland. An autoradiographic *in vitro* study. *Virchows Arch B Cell Pathol* 1975, 19:69-76
5. Leav I, Merk FB, Ofner P, Goodrich G, Kwan PW, Stein BM, Sar M, Stumpf WE: Bipotentiality of response to sex hormones by the prostate of castrated or hypophysectomized dogs. Direct effects of estrogen. *Am J Pathol* 1978, 93:69-92
6. Merk FB, Warhol MJ, Kwan PW, Leav I, Alroy J, Ofner P, Pinkus GS: Multiple phenotypes of prostatic glandular cells in castrated dogs after individual or combined treatment with androgen and estrogen. Morphometric, ultrastructural, and cytochemical distinctions. *Lab Invest* 1986, 54:442-456
7. Mawhinney MG, Neubauer BL: Actions of estrogen in the male. *Invest Urol* 1979, 16:409-420
8. Levine AC, Kirschenbaum A, Droller M, Gabrilove JL: Effect of the addition of estrogen to medical castration on prostatic size, symptoms, histology and serum prostate specific antigen in 4 men with benign prostatic hypertrophy. *J Urol* 1991, 146:790-793
9. De Marzo AM, Nelson WG, Meeke AK, Coffey DS: Stem cell features of benign and malignant prostate epithelial cells. *J Urol* 1998, 160:2381-2392
10. Ho SM, Lee KF, Lane K: Neoplastic transformation of the prostate. *Prostate: Basic and Clinical Aspects*. Edited by RK Naz. Boca Raton, CRC Press 1997, pp 73-113
11. Bosland MC: The role of steroid hormones in prostate carcinogenesis. *J Natl Cancer Inst Monogr* 2000, 2000:39-66
12. Santti R, Newbold RR, Makela S, Pylkkanen L, McLachlan JA: Developmental estrogenization and prostatic neoplasia. *Prostate* 1994, 24:67-78
13. Pylkkanen L, Makela S, Santti R: Animal models for the preneoplastic lesions of the prostate. *Eur Urol* 1996, 30:243-248
14. Leav I, Ho SM, Ofner P, Merk FB, Kwan PW, Damassa D, Biochemical

- alterations in sex hormone-induced hyperplasia and dysplasia of the dorsolateral prostates of Noble rats. *J Natl Cancer Inst* 1988, 80:1045-1053
15. Bosland MC, Ford H, Horton L: Induction at high incidence of ductal prostate adenocarcinomas in NBL/Cr and Sprague-Dawley Hsd:SD rats treated with a combination of testosterone and estradiol-17 beta or diethylstilbestrol. *Carcinogenesis* 1995, 16:1311-1317
  16. Kuiper GG, Enmark E, Peltö-Huikko M, Nilsson S, Gustafsson JA: Cloning of a novel receptor expressed in rat prostate and ovary. *Proc Natl Acad Sci USA* 1996, 93:5925-5930
  17. Mosselman S, Polman J, Dijkema R: ER beta: identification and characterization of a novel human estrogen receptor. *FEBS Lett* 1996, 392:49-53
  18. Tremblay GB, Tremblay A, Copeland NG, Gilbert DJ, Jenkins NA, Labrie F, Giguere V: Cloning, chromosomal localization, and functional analysis of the murine estrogen receptor beta. *Mol Endocrinol* 1997, 11:353-365
  19. Bhat RA, Harnish DC, Stevis PE, Lyttle CR, Komm BS: A novel human estrogen receptor beta: identification and functional analysis of additional N-terminal amino acids. *J Steroid Biochem Mol Biol* 1998, 67:233-240
  20. Enmark E, Peltö-Huikko M, Grandien K, Lagercrantz S, Lagercrantz J, Fried G, Nordenskjöld M, Gustafsson JA: Human estrogen receptor beta-gene structure, chromosomal localization, and expression pattern. *J Clin Endocrinol Metab* 1997, 82:4258-4265
  21. Kuiper GG, Carlsson B, Grandien K, Enmark E, Haggblad J, Nilsson S, Gustafsson JA: Comparison of the ligand binding specificity and transcript tissue distribution of estrogen receptors alpha and beta. *Endocrinology* 1997, 138:863-870
  22. Paech K, Webb P, Kuiper GG, Nilsson S, Gustafsson J, Kushner PJ, Scanlan TS: Differential ligand activation of estrogen receptors ERalpha and ERbeta at AP1 sites. *Science* 1997, 277:1508-1510
  23. Enmark E, Gustafsson JA: Oestrogen recept—an overview. *J Intern Med* 1999, 246:133-138
  24. Gustafsson JA: Estrogen receptor beta—a new dimension in estrogen mechanism of action. *J Endocrinol* 1999, 163:379-383
  25. Chang WY, Prins GS: Estrogen receptor-beta: implications for the prostate gland. *Prostate* 1999, 40:115-124
  26. Krege JH, Hodgin JB, Couse JF, Enmark E, Warner M, Mahler JF, Sar M, Korach KS, Gustafsson JA, Smithies O: Generation and reproductive phenotypes of mice lacking estrogen receptor beta. *Proc Natl Acad Sci USA* 1998, 95:15677-15682
  27. Poelzl G, Kasai Y, Mochizuki N, Shaul PW, Brown M, Mendelsohn ME: Specific association of estrogen receptor beta with the cell cycle spindle assembly checkpoint protein, MAD2. *Proc Natl Acad Sci USA* 2000, 97:2836-2839
  28. Lau KM, LaSpina M, Long J, Ho SM: Expression of estrogen receptor (ER)-alpha and ER-beta in normal and malignant prostatic epithelial cells: regulation by methylation and involvement in growth regulation. *Cancer Res* 2000, 60:3175-3182
  29. Montano MM, Jaiswal AK, Katzenellenbogen BS: Transcriptional regulation of the human quinone reductase gene by antiestrogen-liganded estrogen receptor-alpha and estrogen receptor-beta. *J Biol Chem* 1998, 273:25443-25449
  30. Wernert N, Gerdes J, Loy V, Seitz G, Scherr O, Dhom G: Investigations of the estrogen (ER-ICA-test) and the progesterone receptor in the prostate and prostatic carcinoma on immunohistochemical basis. *Virchows Arch A Pathol Anat Histopathol* 1988, 412:387-391
  31. Schulze H, Claus S: Histological localization of estrogen receptors in normal and diseased human prostates by immunocytochemistry. *Prostate* 1990, 16:331-343
  32. Ehara H, Koji T, Deguchi T, Yoshii A, Nakano M, Nakane PK, Kawada Y: Expression of estrogen receptor in diseased human prostate assessed by non-radioactive in situ hybridization and immunohistochemistry. *Prostate* 1995, 27:304-313
  33. Bonkhoff H, Fixemer T, Hunsicker I, Remberger K: Estrogen receptor expression in prostate cancer and premalignant prostatic lesions. *Am J Pathol* 1999, 155:641-647
  34. Taylor AH, Al Azzawi F: Immunolocalisation of oestrogen receptor beta in human tissues. *J Mol Endocrinol* 2000, 24:145-155
  35. Fuqua SA, Schiff R, Parra I, Friedrichs WE, Su JL, McKee DD, Slentz-Kesler K, Moore LB, Willson TM, Moore JT: Expression of wild-type estrogen receptor beta and variant isoforms in human breast cancer. *Cancer Res* 1999, 59:5425-5428
  36. McNeal JE: Prostatic microcarcinomas in relation to cancer origin and the evolution to clinical cancer. *Cancer* 1993, 71:984-991
  37. Bostwick DG: High grade prostatic intraepithelial neoplasia: the most likely precursor of prostate cancer. *Cancer* 1995, 75:1823-1826
  38. Stamey JA, McNeal JE, Yemoto CM, Sigal BM, Johnstone IM: Biological determinants of cancer progression in men with prostate cancer. *JAMA* 1999, 281:1395-1400
  39. Gustafsson JA: An update on estrogen receptors. *Semin Perinatol* 2000, 24:66-69
  40. Harlow E, Lane D. *Antibodies: A Laboratory Manual*. New York, Cold Spring Harbor Laboratory, 1988, pp 139-242
  41. Leav I, McNeal JE, Kwan PW, Komminoth P, Merk FB: Androgen receptor expression in prostatic dysplasia (prostatic intraepithelial neoplasia) in the human prostate: an immunohistochemical and in situ hybridization study. *Prostate* 1996, 29:137-145
  42. Bonkhoff H, Remberger K: Widespread distribution of nuclear androgen receptors in the basal cell layer of the normal and hyperplastic human prostate. *Virchows Arch A Pathol Anat Histopathology* 1993, 422:35-38
  43. Gleave ME, Chung LW: Stromal-epithelial interaction affecting prostate tumor growth and hormonal responsiveness. *Endocrinol-Related Cancer* 1995, 2:243-265
  44. Hall JM, McDonnell DP: The estrogen receptor beta-isoform (ERbeta) of the human estrogen receptor modulates ERalpha transcriptional activity and is a key regulator of the cellular response to estrogens and antiestrogens. *Endocrinology* 1999, 140:5566-5578
  45. Li LC, Yeh CC, Nojima D, Dahiya R: Cloning and characterization of human estrogen receptor beta promoter. *Biochem Biophys Res Commun* 2000, 275:682-689
  46. McNeal JE, Leav I, Alroy J, Skutelsky E: Differential lectin staining of central and peripheral zones of the prostate and alterations in dysplasia. *Am J Clin Pathol* 1988, 89:41-48
  47. McNeal JE, Redwine EA, Freiha FS, Stamey TA: Zonal distribution of prostatic adenocarcinoma. Correlation with histologic pattern and direction of spread. *Am J Surg Pathol* 1988, 12:897-906
  48. Foley EF, Jazaeri AA, Shupnik MA, Jazaeri O, Rice LW: Selective loss of estrogen receptor beta in malignant human colon. *Cancer Res* 2000, 60:245-248
  49. Culig Z, Hobisch A, Bartsch G, Klocker H: Androgen receptor—an update of mechanisms of action in prostate cancer. *Urol Res* 2000, 28:211-219
  50. Ruizeveld de Winter JA, Janssen PJ, Sleddens HM, Verleun-Mooijman MC, Trapman J, Brinkmann AO, Santerse AB, Schroder FH, van der Kwast TH: Androgen receptor status in localized and locally progressive hormone refractory human prostate cancer. *Am J Pathol* 1994, 144:735-746
  51. Yomeda T: Cellular and molecular mechanisms of breast and prostate cancer metastasis to bone. *Eur J Cancer* 1998, 34:240-245