

AD\_\_\_\_\_

Award Number: DAMD17-99-1-9008

TITLE: Hand-Held Probe for MR Image-Guided Biopsy and Treatment  
of Prostate Cancer

PRINCIPAL INVESTIGATOR: Charles I. Dumoulin, Ph.D.

CONTRACTING ORGANIZATION: General Electric Corporation  
Research & Development  
Niskayuna, New York 12309

REPORT DATE: May 2001

TYPE OF REPORT: Final

PREPARED FOR: U.S. Army Medical Research and Materiel Command  
Fort Detrick, Maryland 21702-5012

DISTRIBUTION STATEMENT: Approved for Public Release;  
Distribution Unlimited

The views, opinions and/or findings contained in this report are those of the author(s) and should not be construed as an official Department of the Army position, policy or decision unless so designated by other documentation.

20020124 349

# REPORT DOCUMENTATION PAGE

Form Approved  
OMB No. 074-0188

Public reporting burden for this collection of information is estimated to average 1 hour per response, including the time for reviewing instructions, searching existing data sources, gathering and maintaining the data needed, and completing and reviewing this collection of information. Send comments regarding this burden estimate or any other aspect of this collection of information, including suggestions for reducing this burden to Washington Headquarters Services, Directorate for Information Operations and Reports, 1215 Jefferson Davis Highway, Suite 1204, Arlington, VA 22202-4302, and to the Office of Management and Budget, Paperwork Reduction Project (0704-0188), Washington, DC 20503

1. AGENCY USE ONLY (Leave blank)

2. REPORT DATE

May 2001

3. REPORT TYPE AND DATES COVERED

Final (1 Nov 98 - 30 Apr 01)

4. TITLE AND SUBTITLE

Hand-Held Probe for MR Image-Guided Biopsy and Treatment of Prostate Cancer

5. FUNDING NUMBERS

DAMD17-99-1-9008

6. AUTHOR(S)

Charles I. Dumoulin, Ph.D.

7. PERFORMING ORGANIZATION NAME(S) AND ADDRESS(ES)

General Electric Corporation  
Research & Development  
Niskayuna, New York 12309  
Email - dumoulin@crd.ge.com

8. PERFORMING ORGANIZATION  
REPORT NUMBER

9. SPONSORING / MONITORING AGENCY NAME(S) AND ADDRESS(ES)

U.S. Army Medical Research and Materiel Command  
Fort Detrick, Maryland 21702-5012

10. SPONSORING / MONITORING  
AGENCY REPORT NUMBER

11. SUPPLEMENTARY NOTES

Report contains color graphics

12a. DISTRIBUTION / AVAILABILITY STATEMENT

Approved for Public Release; Distribution Unlimited

12b. DISTRIBUTION CODE

13. ABSTRACT (Maximum 200 Words)

A hand-held probe for the biopsy and treatment of prostate cancer was developed in a 30 month program. The probe was designed to acquire Magnetic Resonance Images and incorporates MR tracking coils for real-time localization during biopsy. Seven tasks were proposed for the execution of this project, but Task 3 was eliminated in the final contract negotiations. All other tasks have been completed. In the first task, changes were made to the MR tracking software, making it more suitable for dynamic prostate imaging. In the second task, "mock-ups" of several probes were made and evaluated in a cadaver model. The most promising design was then used to create a working prototype probe that includes MR tracking coils, an MR imaging coil and a biopsy channel. The performance of this probe was compared to commercially available MR prostate imaging coils, and found to give a greater depth-of-penetration and twice the signal-to-noise ratio of the commercially available probe. This was validated in human volunteers in the fourth task. Final probes were built in the fifth task and biopsy functionality validated in dog models in the sixth task. Task seven of the original work statement is the writing of this report.

14. SUBJECT TERMS

Prostate Cancer, MR-Guided, Biopsy, Therapy

15. NUMBER OF PAGES

21

16. PRICE CODE

17. SECURITY CLASSIFICATION  
OF REPORT

Unclassified

18. SECURITY CLASSIFICATION  
OF THIS PAGE

Unclassified

19. SECURITY CLASSIFICATION  
OF ABSTRACT

Unclassified

20. LIMITATION OF ABSTRACT

Unlimited

## Table of Contents

	page
Front Cover	1
Standard Form 298	2
Table of Contents	3
Introduction	4
Body	5
Key Research Accomplishments	18
Reportable Outcomes	19
Conclusions	21
References	none
Appendices	none

## **Introduction**

A hand-held probe for the biopsy and treatment of prostate cancer was developed in a 30 month program. The probe was designed to acquire Magnetic Resonance (MR) images, and incorporates MR tracking coils for real-time localization during biopsy procedures. When properly placed, the probe can be used to insert a biopsy needle in the prostate to remove a tissue sample (or place therapeutic devices to destroy selected portions of the gland). Since the MR scanner employs a scan plane that is defined by the MR tracking coils within the probe, the images used for biopsy guidance are always registered to the path of the biopsy needle. Magnetic resonance imaging provides a much better view of the prostate gland (both normal and abnormal tissue) than is possible with any other imaging modality, including ultrasound. It is believed that this improved visualization of the prostate during biopsy will increase the specificity and reliability of the diagnosis and staging of prostate cancer. The scope of the research reported here includes the design, construction and evaluation of the MR biopsy probe. Evaluation of imaging aspects of the probe was performed in human volunteers. Evaluation of the biopsy capabilities of the probe was performed in canine models.

### Body

Seven tasks were initially proposed in a 30 month program to develop an MR biopsy probe for the prostate. These tasks are shown in Figure 1 of this report (reproduced from Figure 6 of the proposal) and in greater detail in table 1. During contract negotiations, task 3 was eliminated to reduce the size of the contract. Work on the remaining tasks proceeded on schedule and is described in detail below.

Task	Year 1	Year 2	Year 3
<b>Task 1</b> -- Develop needed enhancements to MR tracking system.	■		
<b>Task 2</b> -- Build first prototype probes.	■		
<b>Task 3</b> -- Install MR tracking system clinical scanner.	■		
<b>Task 4</b> -- Validate first prototype probe in humans.		■	
<b>Task 5</b> -- Build final prototype probe.		■	
<b>Task 6</b> -- Validate final prototype in phantoms and animals.			■
<b>Task 7</b> -- Write final report.			■
<i>Deliverable</i>			▼
Hand-held probe for MR image-guided biopsy and treatment of prostate cancer			

**Figure 1.** Schedule for the project as presented in the proposal.  
Note that Task 3 was eliminated in contract negotiations.

**Task 1. Develop needed enhancements to existing MR tracking system. Months 1-6.**

- Incorporate parametric description of probe for enhanced visualization on display screen.
- Make pulse sequence improvements to optimize image contrast.
- Integrate surface coil imaging and tracking functions into tracking software system.

**Task 2. Build first prototype probes (which include only imaging and tracking coils). Months 3-12**

- Evaluate commercially available prostate imaging probes.
- Integrate three or more tracking coils into a prostate imaging probe, rebuild probe if necessary.

**Task 3. Install MR tracking system on clinical scanner. Months 9-12**

- Identify clinical partner.
- Acquire and construct MR tracking hardware.
- Install and validate MR tracking at clinical site.

**Task 4. Validate first prototype probe in humans. Months 13-15**

- Perform safety review.
- Apply for and receive IRB approval.
- Make images in six human volunteers.

**Task 5. Build final prototype probes (which includes biopsy needle channels). Months 15-24**

- Identify suitable MR compatible biopsy needle.
- Review design concepts with practicing clinicians.
- Design and construct MR guided biopsy probe.

**Task 6. Validate final prototype in phantoms and animals. Months 24-30**

- Validate biopsy needle placement in phantoms.
- Demonstrate prostate biopsy in animal model.

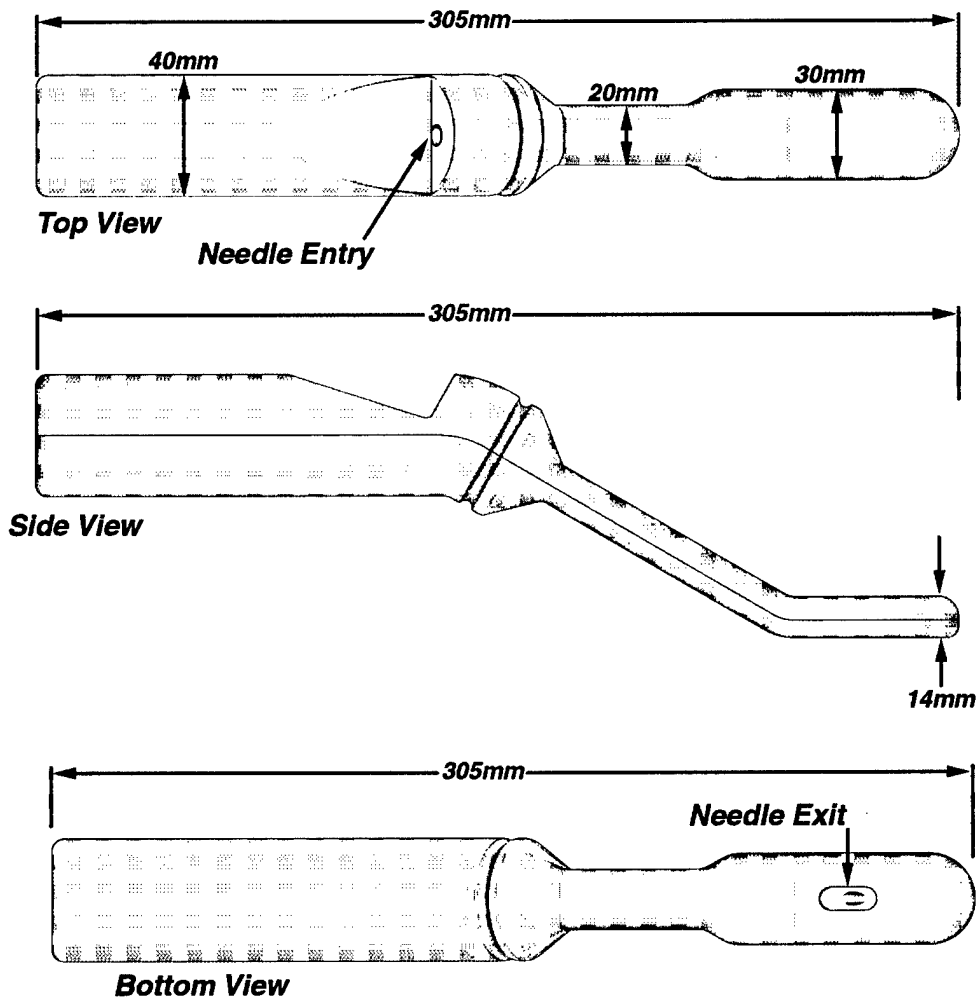
**Task 7. Write final report. Months 27-30**

- Write final report.
- Apply for phase 2 support.

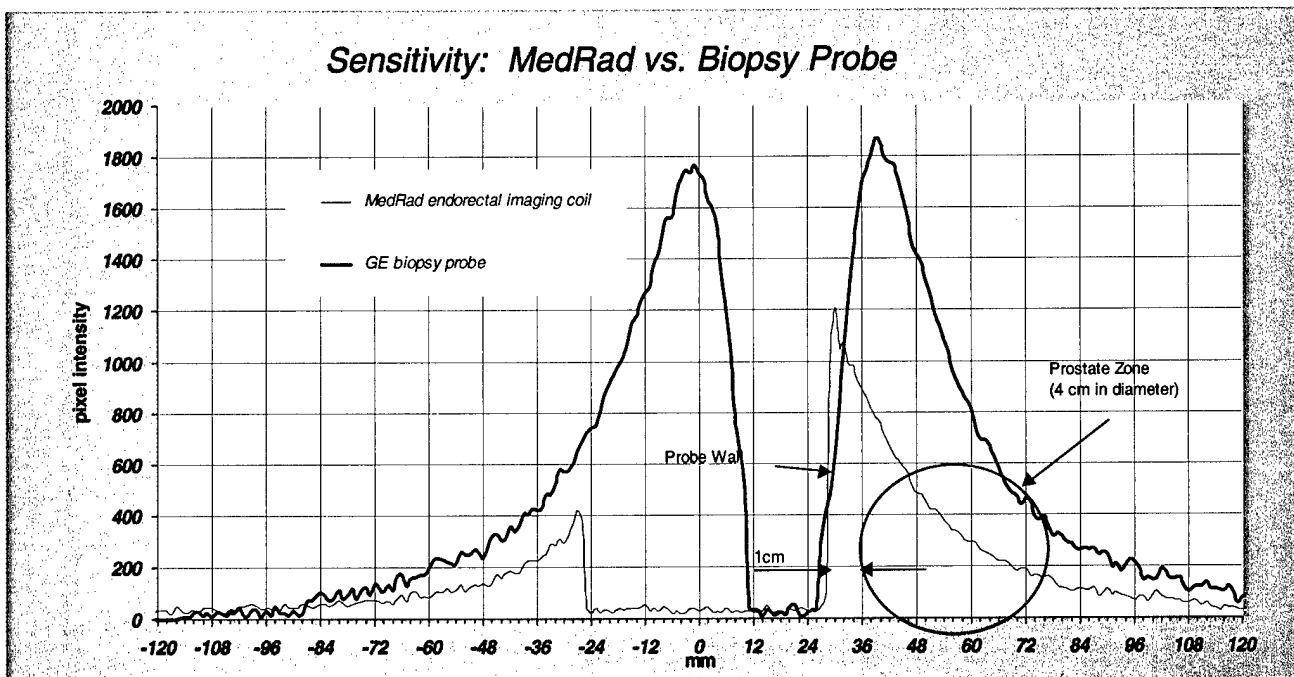
### First year's tasks

Tasks 1 and 2 were completed in the first year of the project. Details concerning the execution and accomplishments of these tasks were given in the first annual report on the project.

The primary goal of tasks 1 and 2 was to develop and test a trans-rectal probe for MRI imaging of the prostate. A line drawing of this probe is given in Figure 2 and a comparison of the probe with the standard commercially-available probe is given Figure 3. The probe was evaluated in phantoms and was shown to have at least twice the signal-to-noise ratio of commercially available prostate imaging probes.



**Figure 2.** Top, side and bottom views of the MR image-guided biopsy probe for the prostate



**Figure 3.** Intensity profiles showing sensitivity of the GE-built prostate coil and the commercially available Med-Rad coil.

## Second year's tasks

### Task 4 -- Validate first prototype probe in humans.

This task has three sub-tasks:

1. Perform safety review.
2. Apply for and receive IRB approval.
3. Make images in six human volunteers.

#### Sub-task 1

A safety review of the MR prostate imaging coil was held at GE's Research and Development Center on February 17, 2000. The committee performing this review consisted of the principal investigator and most of the co-investigators as well as GE staff members versed in safety aspects of MR probes, but not directly related to the project. The review covered the following aspects of the probe:

- 1) Heating measurements of dynamic disable circuitry
  - probe temperature must not exceed 4 degree C temperature rise during one hour long high-duty cycle MR examination
- 2) Physical "fit and finish" of the probe
  - Probe must be watertight and not have sharp edges
- 3) Cable pull test
  - Probe cable must withstand 10 pound pull test

4) Hi-pot isolation test

- Probe must maintain electrical isolation with 1500 Volts applied to probe while probe is immersed in saline water bath.

The probe was found to pass all safety tests and was deemed ready for human use.

Sub-task 2

Provisional approval of the research protocol, informed consent form and subject safety questionnaire was obtained from an Internal Review Board (IRB) prior to the award of the grant. This approval was renewed one year into the grant. Immediately before human use of the new prostate probe, a resubmission of the protocols and safety documentation was made to the IRB and full approval to use the probe was obtained.

The IRB was operated under the auspices of Independent Review Consultants, Inc., San Anselmo, California.

Sub-task3

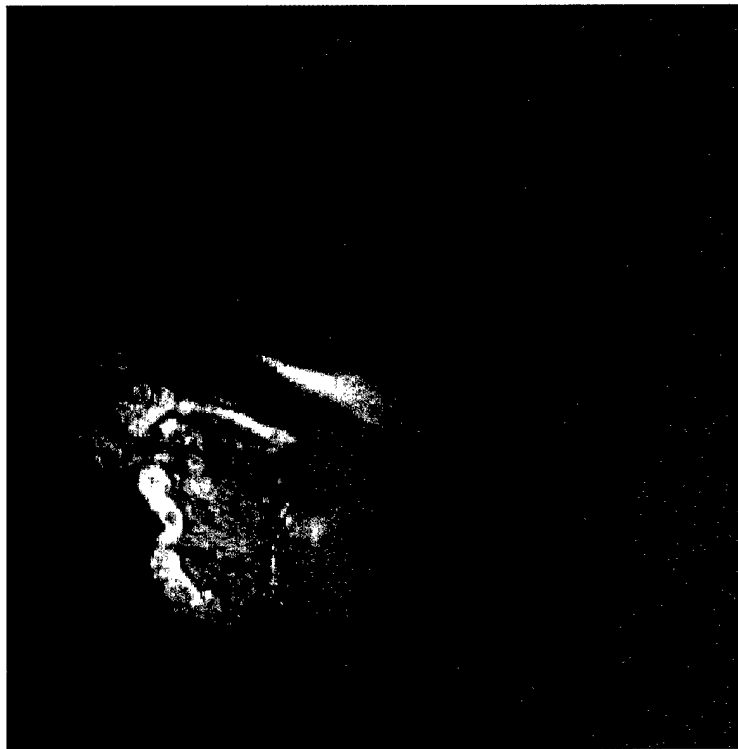Images of the prostate were obtained in six healthy human volunteers, between the ages of 28 and 70 years, on two different days. The informed consent and imaging protocols described in the grant application were followed. Each volunteer was given a digital rectal exam (DRE) by a urologist and then placed on his left side on the scanner bed. The imaging/biopsy probe was covered with a condom and inserted into the subject's rectum. The subject was then rolled into the magnet so that the probe was located in the approximate center of the imaging volume. Subject comfort was assessed every few minutes and recorded on a scale from one to ten (ten being the most uncomfortable). The imaging protocols included Fast Spin-Echo imaging (figures 4 and 5) and high-speed gradient-recalled imaging under MR tracking guidance (figures 6 and 7).

The probe was well tolerated in five of the six volunteers. One volunteer found the probe to be very uncomfortable, but nevertheless was able to complete a 20 minute exam protocol. One subject was able to tolerate the probe for a two hour exam.

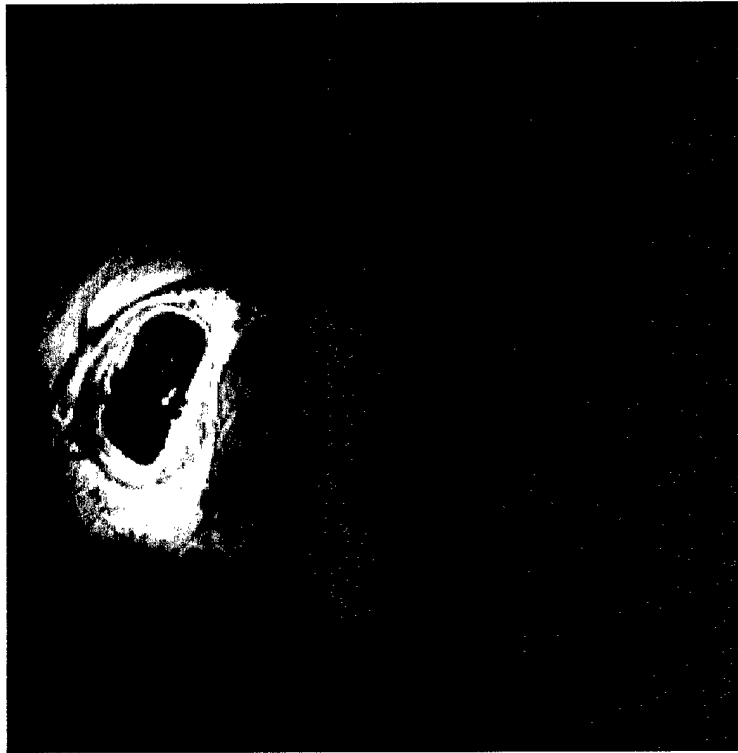During several of the volunteer procedures, extensive manipulation of the probe was performed to assess the probe's ability to provide biopsy access to all portions of the prostate gland. Real-time registration of the image plane with the probe was demonstrated during these manipulations. Alignment of the image plane with the biopsy needle channel was verified by placing a water-filled tube in the biopsy needle channel (figure 7).



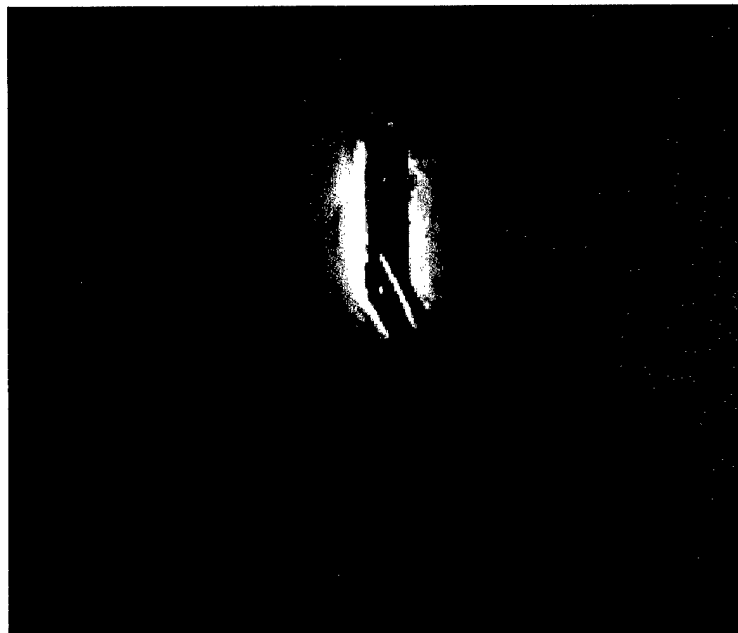
**Figure 4.** Fast Spin-Echo image of the prostate of a healthy volunteer. The prostate is viewed in a quasi-coronal orientation. The urethra is well visualized in the center of the gland.



**Figure 5.** Fast Spin-Echo image of the prostate of a healthy volunteer. Note the crescent-shaped bladder immediately above the prostate.



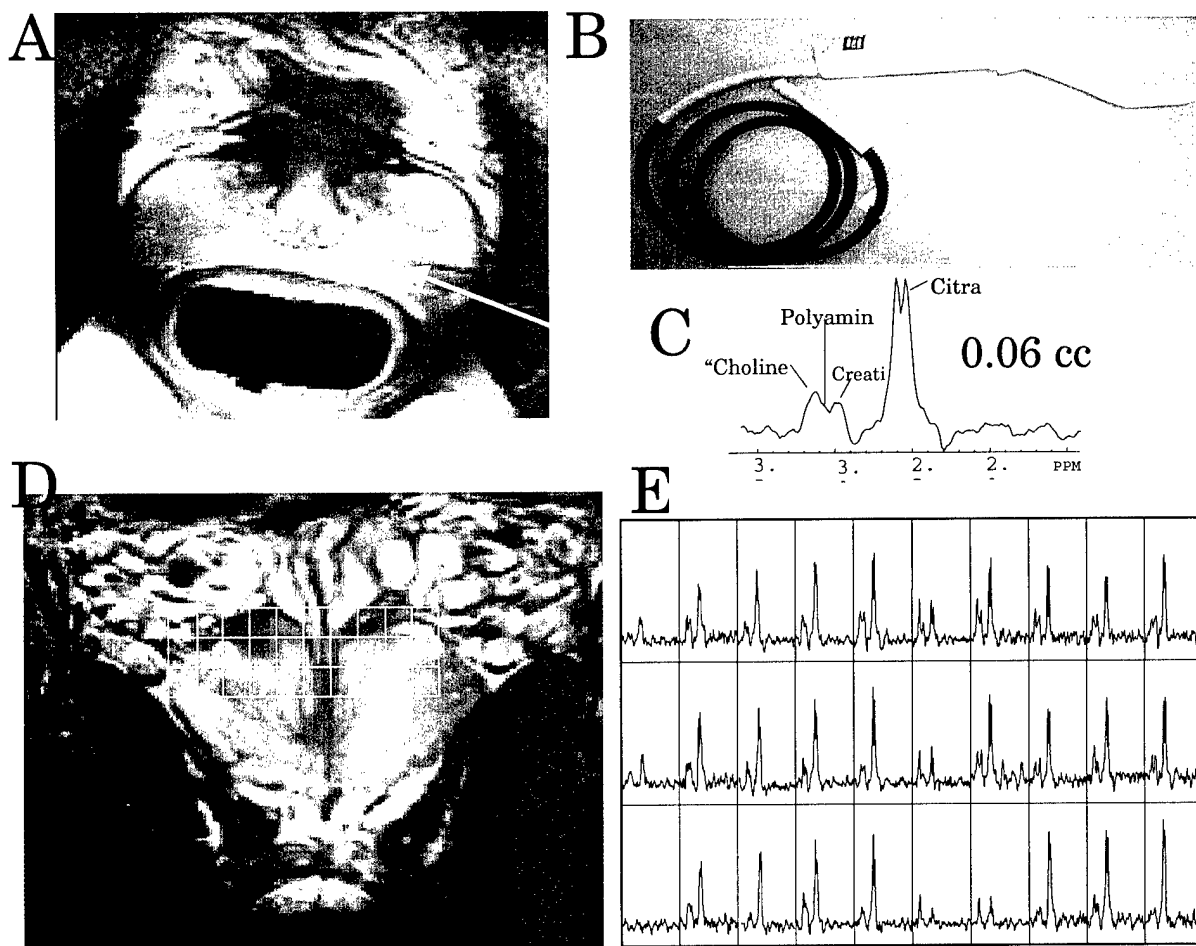
**Figure 6.** Gradient-recalled fast image of the prostate taken in a plane perpendicular to the imaging probe. The image plane was determined by the location of three tracking coils in the probe. In this image the prostate gland appears gray and is located to the right of the imaging probe, which appears as a dark rectangle. Total acquisition time was approximately one second.



**Figure 7.** Gradient-recalled fast image of the prostate taken in an oblique orientation containing the probe's biopsy needle channel. The dark outline of the probe in the rectum is clearly seen. A water-filled tube simulating the placement of a biopsy needle is also well depicted. The probe location was determined in about 50 msec and the image was acquired in approximately one second.

In addition to the six volunteers scanned at GE's Research and Development Center, six volunteers were scanned at the University of California, San Francisco. Scanning was performed by Dr. John Kurhanewicz under a UCSF IRB. In addition to acquiring excellent images, Dr. Kurhanewicz and his team were able to obtain diagnostic MR spectra of the prostate from voxel elements as small as 0.06cc. Observed spectral peaks included choline, creatine and citrate. The size of the spectroscopic voxel attainable with the prostate probe is significantly smaller than previous *in-vivo* efforts in humans.

Acquisition of *in-vivo* MR spectra of the prostate in voxels as small as 0.06cc is one of the most important results of this work. The concentrations of choline, creatine and citrate are known to be significantly different in healthy vs. malignant tissue, and this probe permits the non-invasive mapping of these metabolites over the prostate. We anticipate that the ability to acquire spectra with this spatial resolution will have a major impact on the diagnosis of prostate disease.



**Figure 8.** A) Image of the prostate obtained with the probe at UCSF, B) photo of the imaging probe (note the absence of tracking coils), C)  $^1\text{H}$  spectra from a single 0.06cc voxel, D) Grid of 3D spectroscopic voxels and E) Grid of  $^1\text{H}$  spectra acquired at the indicated locations given in D.

## **Third year's tasks**

### **Task 5 – Build final prototype probes.**

This task has three sub-tasks:

1. Identify suitable MR compatible biopsy needle.
2. Review design concepts with practicing clinicians.
3. Design and construct MR guided biopsy probe.

#### **Sub-task 1**

Discussions on the choice of biopsy needle were held with Dr. Bruce Daniel, Assistant Professor of Radiology, Stanford University. Dr. Daniel suggested that a 20 gauge aspiration needle manufactured by E-Z-EM be used for biopsy procedures. The needle is constructed of Inconel and creates minimal image artifacts.


#### **Sub-task 2**

The design of the probe was reviewed in discussions with Dr. Bruce Daniel (Stanford University), Dr. John Kurhanewicz (University of California, San Francisco) and Dr. Dan Vigneron (University of California, San Francisco) and Dr. Mike Moran (St. Peter's Hospital, Albany). Minor design changes in the tracking samples were found to be necessary. The magnetic susceptibility gradient between the air inside the probe and the tissue in the body was identified as a potential source of artifacts for some types of MR imaging.


#### **Sub-task 3**

Few changes in the initial design were found to be necessary. Several of the glass vials used in the original design for the tracking samples were found to leak over a period of several months. This problem was traced to incomplete sealing of the glass tube during heating, presumably due to over pressure of the heated aqueous sample. An alternate design in which plastic tubes are used instead of glass was developed and evaluated. The plastic tubes are sealed at much lower temperature and appear to provide a more robust tracking sample.

A total of eleven biopsy probes were constructed during the course of this project. Most were tuned for 1.5 Tesla imaging, but three were tuned to 0.5 Tesla and used on the 0.5 Tesla interventional MR scanner at Stanford University. All but two probes were constructed with MR tracking samples. Probes were evaluated at GE's Research and Development Center, University of California, San Francisco and Stanford University.



**Figure 9.** Plastic tracking samples in a prostate imaging probe. The samples are short segments of plastic tubing sealed with heat and containing  $\text{CuSO}_4$  solution. Samples are wrapped with 12 turns of wire to form the tracking coil. The tube and wire are then embedded in epoxy and glued to the body of the probe.



**Figure 10.** Photo of a 1.5 Tesla prostate imaging probe with three MR tracking coils (new design) and a biopsy needle channel.

## Task 6 – Validate final prototype in phantoms and animals.

This task has two sub-tasks:

1. Validate biopsy needle placement in phantoms.
2. Demonstrate prostate biopsy in animal model.

### Sub-task 1

Placement of the biopsy needle with the MR probe was performed in phantoms. The location of the biopsy needle was visualized as a signal void in the phantom. Signal voids from the biopsy needles were consistently found in the expected locations with an accuracy limited by the pixel resolution of the image.

### Sub-task 2

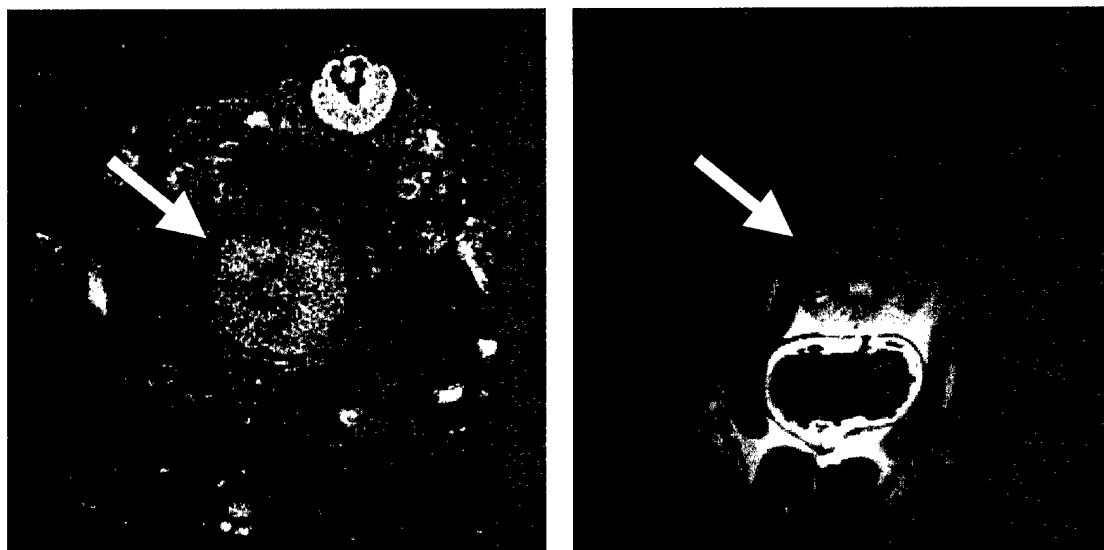
The biopsy and therapeutic capabilities of the prostate probe were evaluated on a 0.5 Tesla Open scanner (SIGNA SP) located at Stanford University. Imaging was performed on six mongrel male dogs, with prostates between 3 and 4 cm in diameter. Imaging was performed exclusively using the endorectal coil except in one case where imaging was performed with the head coil for comparison (Figure 11). The experimental protocol included percutaneous placement of two 3-mm diameter MR-compatible cryoprobes (Galil Medical USA) as well as a multiple channel Luxtron fiberoptic temperature sensor (Luxtron Inc, Santa Clara, CA). Imaging included T1-weighted spin-echo (SE) and T2-weighted fast spin-echo (FSE), before and after cooling, as well as ultra-short echo-time half-pulse/spiral imaging during freezing, and line-scan diffusion-weighted imaging after thawing to body temperature (Figure 12).

MRI-guided biopsy was also simulated in 2 cases using the working channel of the coil, and a 20-gauge, 20 cm E-Z-EM Inconel-equivalent aspiration needle. During the biopsy procedures, a fast multi-planar gradient-echo (FMPGR) pulse sequence was used (TR=150ms, BW=7.8 kHz). Placement of the biopsy needle into the prostate was accurate, but limited because of deflection of the needle by the condom covering the coil (condoms were used to keep the coil clean for multiple studies). In addition, the relatively shallow oblique angle of the foot of the coil, as well as the mid-foot location of the exit channel for the biopsy needle cause the straight needle to exit the coil at a very steep angle. Thus, the needle was directed primarily toward the tissues beyond the sensitive region of the imaging coil. In order to negotiate the needle into the deeper portions of the prostate gland, it was necessary to pull back the probe to the point where imaging of the gland was somewhat compromised.

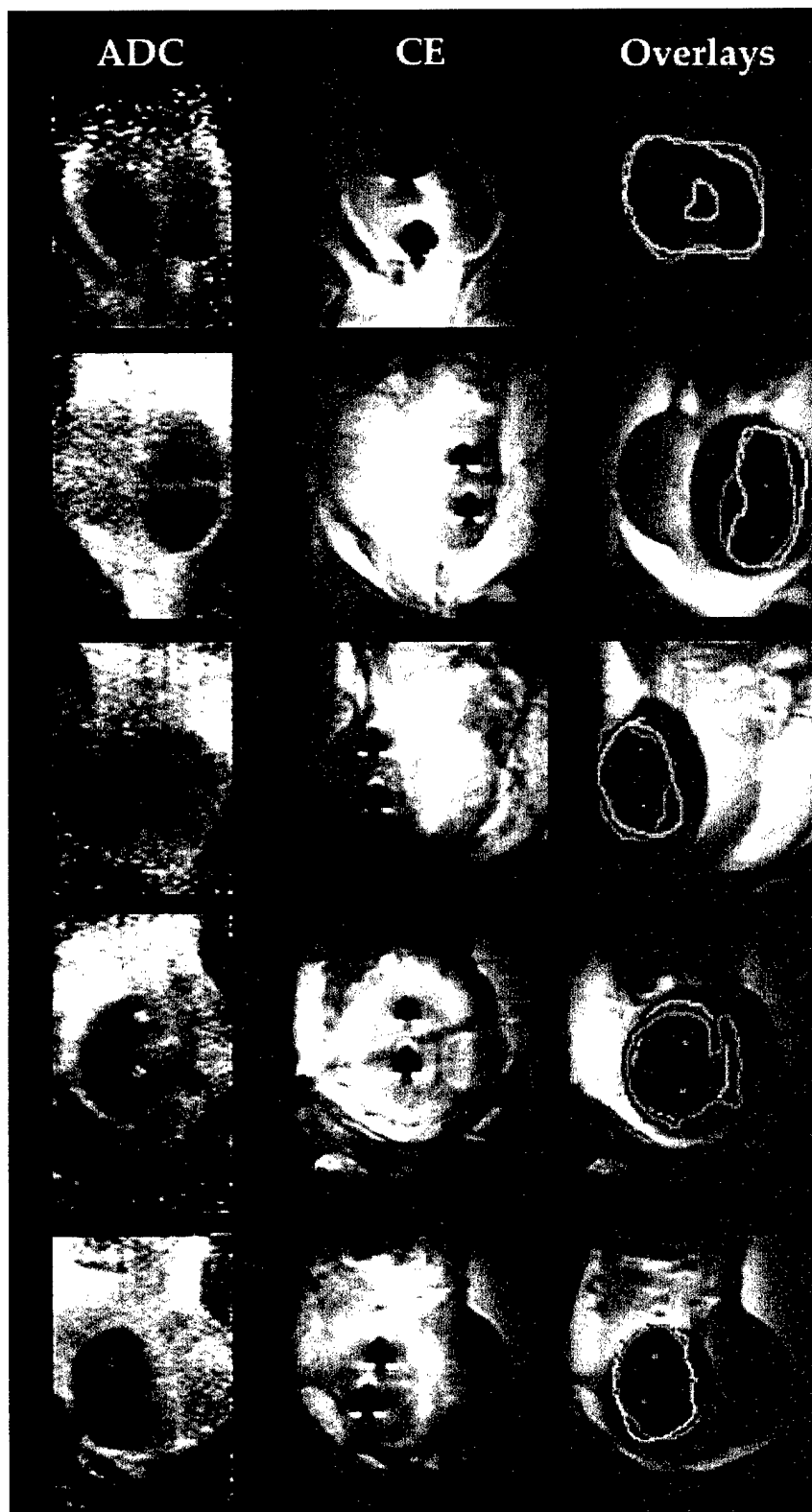
Overall the performance of the probe was found to be outstanding. SNR was dramatically improved over other options. This SNR gain enabled the acquisition of diffusion weighted images of cryolesions. This is an important

technique for characterizing the immediate effects of cryoablation and is a substantial step forward beyond standard MR imaging.

Future work at Stanford University will include both animal and experimental studies of prostate cryosurgery in humans and animals. The probe is also anticipated to be useful for imaging the female urethra. Artifacts caused by resonance offset conditions (such as those seen in half-pulse/spiral imaging) will be addressed by filling the coil with low-susceptibility material to reduce susceptibility artifacts from air in the coil.



**Figure 11.** 0.5 Tesla images of a dog prostate gland (white arrow) obtained with the standard head coil (left) and with the MR-guided biopsy probe developed in this project (right).



**Figure 12.** 0.5 Tesla images of a dog prostate gland obtained with the prostate probe. Diffusion-weighted images after thawing are shown in the first column. Spin echo images shown in the second column illustrate the placement of the cryoprobes, but do not highlight tissue damage very well. In the third column, images of the ice-ball formed by cryotherapy are overlaid with the boundaries of the diffusion-weighted changes illustrating utility of diffusion-weighting for measuring tissue damage caused by cryoablation.

## Key Research Accomplishments

### A. Enhancements made to the MR tracking system

- Parametric probe description and non-parametric probe descriptions
- Pulse sequence enhancements made to optimize image contrast
  - Spin Echo
  - Gradient Echo
  - Continuous imaging
- Surface coil imaging and tracking functions integrated
  - “pop-up” menu to define imaging parameters created
  - pulse sequence changes made to interact with the new “pop-up” menu

### B. First prototype probes built

- Commercially available probe evaluated
- Practicing clinical urologist consulted
- A new probe design conceived and tested in a cadaver model
- Prototype probe designed and built.
- Imaging and tracking functions of prototype probe tested in phantoms
- Prototype probe is smaller than commercially available probe, but has twice the Signal-to-Noise ratio at all depths of penetration.



### C. Probe design validated in humans

- Six volunteers imaged at GE's Research and Development Center
- Six volunteers imaged at UCSF
- Ultra-high spatial resolution (0.06cc) obtained for *in-vivo* MR spectroscopy of the human prostate.



### D. Therapeutic features of probe evaluated in dogs

- Probe used to monitor six cryoablation procedures in the dog prostate
- Probe used for diffusion-weighted imaging of dog prostates
- Biopsy procedures performed on two dogs in an open 0.5 Tesla scanner at Stanford University



## Reportable Outcomes

1. An oral presentation entitled: "Magnetic Resonance Tracking Image Guided Biopsy in Prostate", was presented at the Eighth annual meeting of the International Society of Magnetic Resonance in Medicine (ISMRM) (pg. 412 of the meeting proceedings). The authors were: R.D. Watkins, K.W. Rohling, E.E. Uzgiris, C.L. Dumoulin, R.D. Darrow and R.O. Giaquinto. Acknowledgment to the US Army was included.
2. A poster was presented by Dr. Michael Moran at the 17<sup>th</sup> World Congress on Endocrinology and SWL in Rhodes, Greece (September 2-5, 1999). The poster was entitled "Cadaveric Morphometrics for the use of a novel transrectal magnetic resonance (MR) image-guided focused ultrasonic ablation of the prostate". Authors of the poster were: AR Parekh, ME Moran, CJ Calvano, CL Dumoulin and EE Uzgiris. Acknowledgment to the US Army was included.
3. A disclosure letter entitled "A prostate Probe for MR image guided biopsy and MR guided delivery of therapy" was submitted to the General Electric Research and Development Center as the first step for filing a U.S. Patent. Inventors listed on the disclosure letter are: EE Uzgiris, KW Rohling, RD Watkins, RD Darrow and CL Dumoulin.
4. A proposal entitled "Hand-held probe for MR Image-Guided Focused Ultrasound treatment of Prostate Cancer" was submitted to the U.S. Army. This proposal received a score of 2.0 (excellent), but was not recommended for funding.
5. A joint proposal with the University of California at San Francisco (UCSF) entitled "Improved MRI/MRSI for biopsy guidance of prostate cancer" was submitted to the National Cancer Institute and has been funded (CA88214-01, priority score: 141).
6. A proposal entitled "MR-guided focused ultrasound ablation of prostate cancer" was submitted to the National Cancer Institute and has been funded (CA88102-01, priority score: 150).
7. Support from the US Army for phase 2 of this work was requested in a proposal entitled "Clinical Evaluation of a Hand-Held Probe for MR Image-Guided Biopsy and Treatment of Prostate Cancer". This grant request was not funded.
8. The first year annual report for this project was submitted to the US Army on November 30, 1999.
9. A poster presentation entitled: "Diffusion-weighted MRI after cryosurgery of the *in-vivo* canine prostate" was presented at the Ninth annual meeting

of the International Society of Magnetic Resonance in Medicine (ISMRM) (pg. 2210 of the meeting proceedings). The authors were: K. Butts, B.L. Daniel, J. Wansapura, L. Chen, S. Maier, C.L. Dumoulin and R.D. Watkins. Acknowledgment to the US Army is included.

10. Second Competitive renewal of NIH R01 (CA59897) entitled "Metabolic Imaging of the Prostate Using 3-D MRSI. Project period: 3/21/01-2/28/06 Total budget- \$1,960,585 , PI: Daniel Vigneron.

Manuscripts in preparation

1. Paper describing initial experience with probe (M. Moran, C.L. Dumoulin, R.D. Watkins et. al.)
2. Paper describing initial experience with probe for imaging and spectroscopy (J. Kurhanewicz, D. Vigneron, C.L. Dumoulin and R.D. Watkins)
- 3) Paper describing diffusion weighted imaging of the dog prostate during cryoablation ( B. Daniel, K. Butts, S. Maier, C.L. Dumoulin and R.D. Watkins)

Funded Personnel

Robert D. Darrow  
Charles L. Dumoulin  
Randy O. Giaquinto  
Joseph E. Piel  
Kenneth W. Rohling  
Charles J. Rossi  
Egidijus E. Uzgiris  
Ronald D. Watkins

## Conclusions

### Work summary

We have made enhancements to the MR tracking subsystem and we have constructed the first prototype probe for prostate imaging. The MR tracking enhancements permit greater flexibility in image acquisition and support new MR imaging schemes. Both parametric and non-parametric models of the prostate probe can be used with the MR tracking system.

The prototype probe that we constructed incorporates three MR tracking coils and a sensitive MR imaging coil. Evaluation of this probe in phantoms showed that the probe should be capable of making images of the entire prostate with twice the signal-to-noise ratio (SNR) of the most widely used commercially available prostate imaging probe. This gain in SNR has been realized in humans and the resulting improvement in image quality provided by the new MR probe is anticipated to be medically significant, even if the probe used only for diagnostic imaging.

One collateral benefit of the probe's high sensitivity is its ability to obtain MR spectra of the human prostate with excellent spatial resolution. The 0.06cc spectroscopic voxels obtained in human subjects is a substantial improvement over previous work. It permits the acquisition of chemically selective images in which maps of selected metabolites (e.g. choline, citrate etc.) are acquired over the prostate.

The prototype probe was also evaluated for several therapeutic procedures in dog prostate models. The probe proved very sensitive for imaging cryoablation of the prostate and for making high-resolution diffusion-weighted images. Biopsy needle placement using the probe was adequately performed in regions of the prostate near the probe. The angle of the needle exit was found to be less than optimal for deeper targets, however, since the region of optimal imaging overlaps the shallower portions of the needle track. It is believed that small changes to the geometry of the probe will be able to overcome this limitation.

### Significance

The MR imaging and biopsy probe developed in this project provides a major advance in the Signal-to-Noise ratio for MR measurements of the prostate. The probe has an SNR 2 to 3 times greater than that available with the standard commercially available probe for all portions of the prostate gland. The high SNR also enables the acquisition of *in-vivo* MR spectra from smaller voxels than previously possible. In clinical application, this gain in SNR will result in greater specificity and sensitivity for the staging of prostate cancer. The added benefit of a biopsy channel in the probe was demonstrated in phantoms and in canine models. We expect that in the near future probes of this (or related) design will become the standard for staging prostate disease and for image-guided biopsy of the prostate.