

AD_____

Award Number: DAMD17-00-1-0596

TITLE: Real-Time Palpation Imaging for Improved Detection and
Discrimination of Breast Abnormalities

PRINCIPAL INVESTIGATOR: Timothy J. Hall, Ph.D.

CONTRACTING ORGANIZATION: University of Kansas Medical Center
Kansas City, Kansas 66160-7700

REPORT DATE: October 2001

TYPE OF REPORT: Annual

PREPARED FOR: U.S. Army Medical Research and Materiel Command
Fort Detrick, Maryland 21702-5012

DISTRIBUTION STATEMENT: Approved for Public Release;
Distribution Unlimited

The views, opinions and/or findings contained in this report are those of the author(s) and should not be construed as an official Department of the Army position, policy or decision unless so designated by other documentation.

20020124 257

REPORT DOCUMENTATION PAGEForm Approved
OMB No. 074-0188

Public reporting burden for this collection of information is estimated to average 1 hour per response, including the time for reviewing instructions, searching existing data sources, gathering and maintaining the data needed, and completing and reviewing this collection of information. Send comments regarding this burden estimate or any other aspect of this collection of information, including suggestions for reducing this burden to Washington Headquarters Services, Directorate for Information Operations and Reports, 1215 Jefferson Davis Highway, Suite 1204, Arlington, VA 22202-4302, and to the Office of Management and Budget, Paperwork Reduction Project (0704-0188), Washington, DC 20503

1. AGENCY USE ONLY (Leave blank)		2. REPORT DATE October 2001	3. REPORT TYPE AND DATES COVERED Annual (15 Sep 00 - 14 Sep 01)	
4. TITLE AND SUBTITLE Real-Time Palpation Imaging for Improved Detection and Discrimination of Breast Abnormalities			5. FUNDING NUMBERS DAMD17-00-1-0596	
6. AUTHOR(S) Timothy J. Hall, Ph.D.				
7. PERFORMING ORGANIZATION NAME(S) AND ADDRESS(ES) University of Kansas Medical Center Kansas City, Kansas 66160-7700 E-Mail: thall@kumc.edu			8. PERFORMING ORGANIZATION REPORT NUMBER	
9. SPONSORING / MONITORING AGENCY NAME(S) AND ADDRESS(ES) U.S. Army Medical Research and Materiel Command Fort Detrick, Maryland 21702-5012			10. SPONSORING / MONITORING AGENCY REPORT NUMBER	
11. SUPPLEMENTARY NOTES Report contains CD-ROM				
12a. DISTRIBUTION / AVAILABILITY STATEMENT Approved for Public Release; Distribution Unlimited			12b. DISTRIBUTION CODE	
13. ABSTRACT (Maximum 200 Words) The purpose of our work is to develop and test a new kind of imaging system we call "palpation imaging". We expect that palpation imaging will be a useful tool for improving the discrimination between benign and malignant breast tumors. The scope of the effort in our first year of funding was to implement a newly-developed algorithm on a commercial ultrasound imaging system and to begin testing that new imaging system. The algorithm provides images of the mechanical strain induced in tissue by pressing the ultrasound transducer against the skin surface. These images are produced at substantially real-time frames rates with normal ultrasound B-mode and strain images displayed side-by-side at eight frames per second. The algorithm is fully integrated into the commercial system and requires no system modifications. Breast exams performed on volunteers have shown that no additional fixtures are required to perform these scans; in fact the palpation imaging study is almost identical to the standard clinical breast ultrasound exam. With the moderate number of patients examined to date, we find distinct strain images for cysts, fibroadenomas, and invasive ductal carcinomas. Comparing lesion area measured in B-mode versus strain images we find complete discrimination between benign and malignant lesions.				
14. SUBJECT TERMS Diagnostic, surgical, breast, imaging			15. NUMBER OF PAGES 31	
			16. PRICE CODE	
17. SECURITY CLASSIFICATION OF REPORT Unclassified	18. SECURITY CLASSIFICATION OF THIS PAGE Unclassified	19. SECURITY CLASSIFICATION OF ABSTRACT Unclassified	20. LIMITATION OF ABSTRACT Unlimited	

Table of Contents

Cover.....	1
SF 298.....	2
Table of Contents.....	3
Introduction.....	4
Body.....	4
Key Research Accomplishments.....	17
Reportable Outcomes.....	19
Conclusions.....	21
References.....	22
Appendices.....	22

Introduction

The purpose of our work is to develop and test a new kind of imaging method we call "palpation imaging". We expect that palpation imaging will be a useful tool for improving the discrimination between benign and malignant breast tumors. The scope of the effort in our first year of funding was to implement a newly-developed algorithm for motion tracking on a commercial ultrasound imaging system and to begin testing that new imaging system. The algorithm provides images of the mechanical strain induced in tissue by pressing the ultrasound transducer against the skin surface. These images are produced at substantially real-time frames rates with normal ultrasound B-mode and strain images displayed side-by-side at eight frames per second. The algorithm is fully integrated into the commercial system and requires no system modifications. Breast exams performed on volunteers have shown that no additional fixtures are required to perform these scans. In fact, the palpation imaging study is almost identical to the standard clinical breast ultrasound exam. With the moderate number of patients examined to date, we find distinct strain images for cysts, fibroadenomas, and invasive ductal carcinomas. Comparing lesion area measured in B-mode versus strain images we find complete discrimination between benign and malignant lesions with the data obtained so far. This work is summarized briefly in our contribution to the 2001 IEEE Ultrasonics Symposium Proceedings [1].

Body

Four Tasks (Tasks 1-3 and 6) were approved for implementation within the first year of support. The overall effort in year-1 was to program a commercial clinical ultrasound imaging system with our motion tracking algorithm and begin testing that system on phantoms and volunteer patients. We are extremely excited with our results to date and are very encouraged with the potential for this new kind of imaging system. Below is a description of the approved Tasks and the progress toward achieving each goal.

Task 1. *Implement real-time palpation imaging on a commercial sonography system (months 1-4): a) Program the imaging system digital signal processors to estimate strain from consecutive image frames. b) Develop a user interface for controlling the data acquisition and processing parameters. c) Test the system using existing phantoms and laboratory fixtures with mo-*

torized motion control to determine the penalty for using fixed-point versus floating point calculations.

One of the Co-Investigators in our effort (Dr. Yanning Zhu) spent three months at Siemens Medical Systems Ultrasound Group (SMSUG) (Issaquah, WA) learning to program their system and has modified our algorithms to efficiently execute on their SONOLINE Elegra Image Processor subsystem. We are grateful to SMSUG for their technical assistance in this effort. Although the software we have developed is fully functional, it is also still under development. Among the major accomplishments are that the system acquires ultrasound quadrature echo data, processes the normal ultrasound B-mode image and an image of mechanical strain, and displays these images side-by-side at about eight frames per second. We have found that frame rate is sufficiently fast to provide feedback to the hand-eye coordination system to allow manipulating the conditions of tissue compression to consistently obtain high-quality strain images. We have tested this system throughout its development and found no difference in the variance of time-delay (tissue displacement) estimates for either floating-point or integer computations (assuming the integer computations are implemented to maximize the available bit depth). The algorithm was implemented both on-line using the Siemens SONOLINE Elegra with two Texas Instruments TMS320C80 MVP (TI C80) processors (integer computation) and off-line using MATLAB and both integer (an implementation identical to that on the TI C80) and floating point computation. In both MATLAB implementations, the displacement estimates approach the Cramer-Rao lower bound on displacement estimates. This means that we are using the available information nearly as efficiently as physically possible. The manuscript that describes the implementation of this algorithm and initial testing for displacement variance is under development. A more extensive report of the experimental variance in displacement estimates (noise in strain images) as related to such experimental parameters as the transducer center frequency and bandwidth will follow.

Task 2. *Develop data acquisition techniques that provide high-quality palpation images without the use of fixtures (months 3-12): a) Implement techniques that mimic those used for phantom imaging including small hand-held fixtures to restrict motion perpendicular to the image plane. b) Test those techniques in phantoms and compare target contrast-to-noise ratio for laboratory (large motorized fixtures, controlled motion) versus clinical (small hand-held fixtures, restricted motion) systems. c) Test the clinical systems (real-time palpation imaging with small fixtures) using anthropomorphic breast*

phantoms. d) Test the clinical systems on volunteer patients with palpable breast abnormalities. e) Modify the data acquisition techniques to eliminate the need for fixtures to restrict motion while maintaining image quality. f) Measure conspicuity of breast lesions to assess the relative merit of different data acquisition techniques.

The greatest effort expended so far in this Task has been in the development of scanning techniques for obtaining high-quality strain images of the breast in vivo. As described in the proposal, we began with simple rectangular block phantoms and compared motorized versus freehand scanning. These tests used fixtures that allowed us to restrict out-of-plane (elevation) motion of the phantom material as the block was deformed in the axial direction (parallel to the acoustic beam). We found that the small fixture used for freehand scanning (hereafter called the "fixture") minimized elevation motion, just as the larger fixture used in the laboratory motorized compression system, but it was somewhat cumbersome to use. Freehand scanning of phantoms for strain imaging without fixtures was far easier than we had anticipated. We skipped the step of using fixtures on breast-shaped phantoms and went directly to freehand scanning of these objects and found this to also be trivially easy. The leap to scanning in vivo breasts was more difficult. In this case, the use of the freehand scanning fixture for minimizing elevation motion was little, if any, help. We found that breast tissue is so inhomogeneous, particularly with tissue boundaries sliding across each other, that the fixture did little to limit elevation motion and was more trouble than it was worth. The most significant improvement in ease of scanning came from further code optimization and modifying the user interface for controlling real-time palpation imaging so as to reduce the size of the region of interest (ROI) for which the strain images are computed. The result was a significantly higher frame rate. When the frame rate hit about four frames per second we had sufficiently frequent frame update to provide the hand-eye coordination system enough information to control the conditions of tissue compression and obtain high-quality strain images in vivo. Our frame rate is currently about eight frames per second with a somewhat reduced (ROI). Further development of the software is expected to provide a frame rate of 11 frames per second with full-field strain imaging. Iterating between what we learned with freehand scanning of phantoms, then in vivo breasts, and back to phantoms, we found that the key to obtaining sequences of high-quality strain images (high contrast-to-noise and high similarity from frame to frame) is high frame rate. The current frame rate is fast enough to allow us

to manipulate the compression conditions while scanning. This manipulation is essential for obtaining low noise strain image data. Figure 1 shows that the variance in our displacement estimates (the fundamental information in strain images) is comparable for freehand and motorized compression of a uniform block phantom. Displacement variance for in vivo breast scans are included for comparison and show that the variance for in vivo displacement estimates is somewhat higher than that for homogeneous phantom materials with simple geometry. (Note that our method for estimating this variance is valid for a homogeneous, isotropic phantom, but is only an approximation in heterogeneous tissue and provides an overestimate of the displacement variance for tissue.) This shows that the penalty in image quality due to freehand scanning is small, especially considering the huge benefit in flexibility in scanning procedure and future clinical acceptability.

Task 3. *Implement high-quality palpation imaging algorithm on a commercial sonography system and perform preliminary tests of image quality (months 7-17): a) Program the commercial sonography system to calculate a high-resolution, low-noise palpation images as quickly as possible over a large region of interest. b) Develop a user interface that allows manipulation of the image formation algorithm for the trade-off between spatial resolution and image noise. c) Test the high-quality algorithm on (geometrically) simple and anthropomorphic phantoms using the modified data acquisition techniques (Task 2.e). d) Use the real-time palpation imaging technique to locate the desired region of interest and obtain sonographic data with the appropriate pre- and post-compression for volunteer patients with palpable breast abnormalities.*

and **Task 6.** *Investigate the use of novel techniques, such as harmonic imaging and spatial quadrature, for improved information content in palpation images (months 18-36).*

This aspect of our work is proceeding extremely well. As shown in figure 1, we can estimate displacement, and therefore strain, in complex, inhomogeneous in vivo breast tissue nearly as well as we can in homogeneous gel phantoms with simple geometry. This is a much better result than we had anticipated. The key to this success is real-time imaging of strain that guides manipulation of the conditions of compression.

Currently we have implemented three displacement and strain algorithms on the Elegra. The simplest of these is the algorithm that runs in real-time for data acquisition. This uses an adaptive search strategy to predict the deformation based on previous displacement estimates. This adaptive search

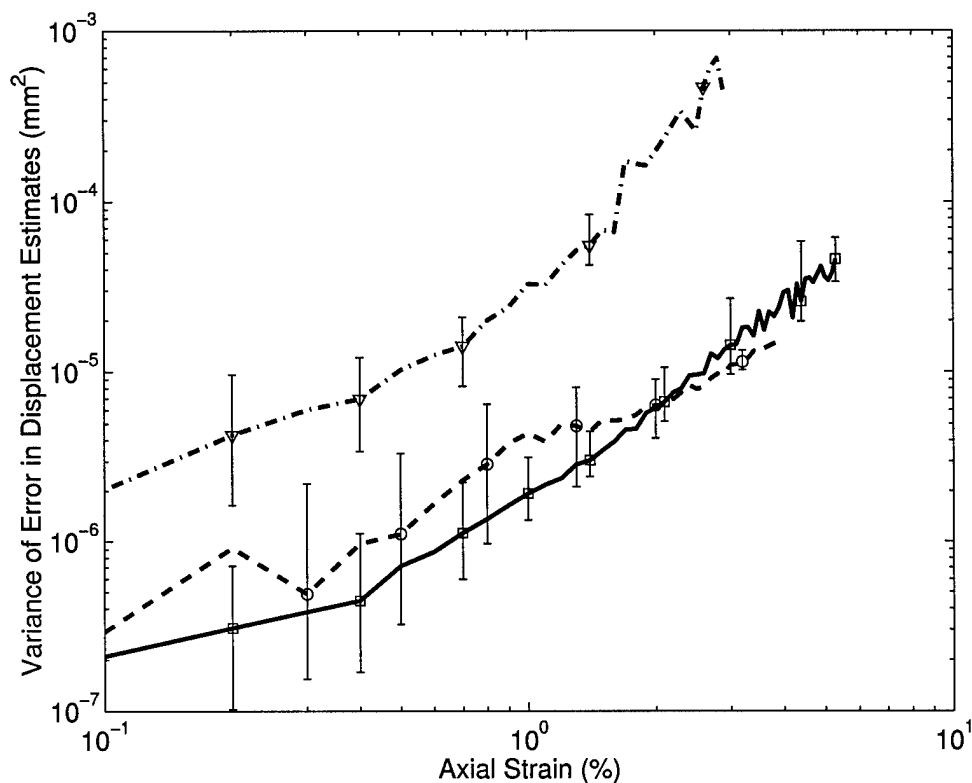


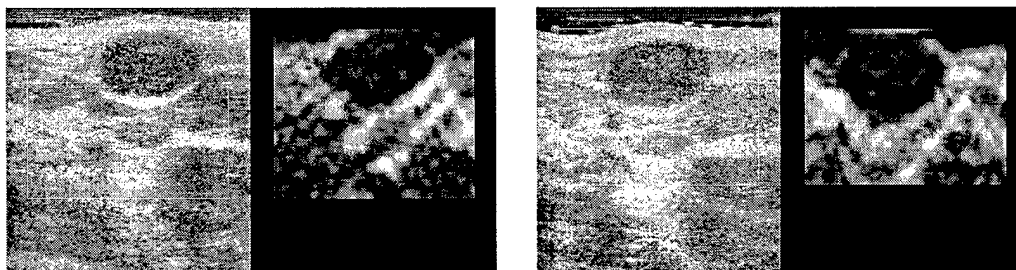
Figure 1: Plots comparing the variance of displacement estimate error for motorized and freehand scanning. The solid and dashed lines shows data obtained from a uniform gelatin block with motorized (solid) and freehand (dashed) compression. The dot-dash line is the average of three data sets obtained by freehand scanning of in vivo breast lesions. Our technique for estimating this variance will tend to overestimate the variance for heterogeneous materials such as breast tissue.

reduces the computational load for strain estimation by more than two orders of magnitude. The algorithm also decimates the data, thereby reducing the number of displacement estimates in a given region of interest. This algorithm is used primarily for data acquisition during freehand scanning and is a compromise between frame rate and image quality. To halt data acquisition the system 'freeze' button is pressed, just as in normal sonography, and the echo data are available for on-line post-processing. This same (real-time) strain imaging algorithm can be used to reprocess that data as

the user scrolls through image memory, or one of the other algorithms can be used. The second algorithm is identical to the first except that the data is not decimated. Estimating displacement with higher data density reduces the displacement variance in the adaptive search strategy resulting in a slight improvement in image quality. The third algorithm operates on the full data field (no decimation) and does not use the adaptive search strategy, instead using a full 2-D search. This approach is much more computationally intensive, requiring about one second per strain image frame, but produces images that lack the displacement error accumulation that can result from the adaptive search strategy. There are several options for further improving image quality which are discussed below. These will add to the computational load of strain imaging, and therefore are not likely candidates for improving real-time image quality, but they will significantly improve post-processed images. Several image examples from our current algorithms are displayed below. There is a significant penalty in the printed version of these images. A CD-ROM is included in this report that provides significantly higher quality images. In addition, this CD-ROM contains 'movie loops' of strain image sequences to illustrate what is seen on the monitor of the Elegra.

To date we have scanned 42 volunteers. Among these there were 25 cysts, 18 fibroadenomas, and 6 invasive ductal carcinomas. Some of these patients had multiple lesions, and some were scanned on repeat occasions. An example of the ability to repeat a strain image scan is shown in figure 2.

We have found that the high negative strain contrast for most fibroadenomas, with low pre-compression, decreases as the lesion is compressed. This implies that the tissue surrounding the lesion has a stress-strain relationship that is more nonlinear than that for the fibroadenoma. This behavior appears to be unique to fibroadenomas. It is seen in fibroadenomas found in both primarily glandular breasts and in fibro-cystic breasts. Figure 3 demonstrates the implications and reproducibility of this behavior. The average strain per frame suggests a slow compression rate in this case. The inter-frame skip was increased to pair every fourth frame in analyzing this sequence of data to achieve an average strain per frame of 1–1.5%. The cumulative strain in the sequence demonstrates that about a 20% compression range was achieved in this study. The cumulative strain plot begins at zero as an arbitrary starting point, since this is a relative plot of the total compression cycle. Frames with the same pre-compression (relative cumulative strain) and the same frame-average strain have equivalent strain images as shown in figures and , and



(a) Data acquired 17.Apr.2001 with the 7.5L40 array.

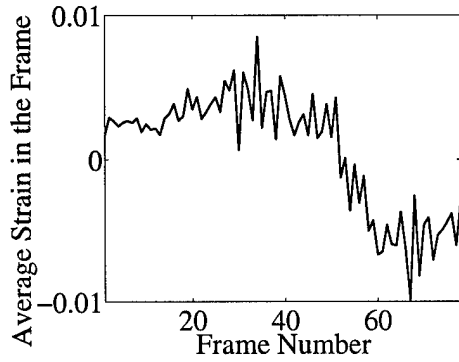
(b) Data acquired 30.Apr.2001 with the VFX13-5 array.

Figure 2: B-mode and strain images from the same patient acquired in two different scanning sessions two weeks apart. The no attempt was made to patient was positioned in same way in these studies. Instead the ‘best’ position for each study was selected independently. Experienced clinicians would recognize the difficulty in repeating a standard clinical sonogram in this manner. The ability to reproduce nearly the same strain image is very encouraging.

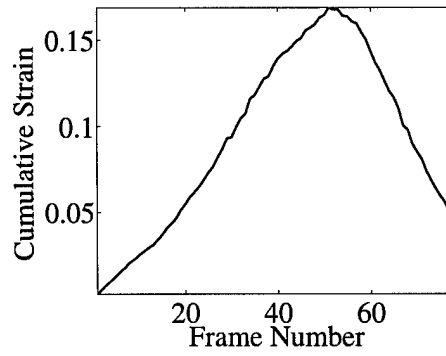
figures and . Note that the average strain in these pairs of frames are not equal, and there is likely small elevation motion in the relative comparison (as evidenced in the slightly different B-mode images), however, the comparison is very good.

It is difficult to describe the strain images of cysts, except to say that the frame-to-frame strain inside the typical cyst tends to decorrelate rapidly as if the contents are being ‘stirred’ while being compressed. Examples of movie loops of side-by-side B-mode and strain images sequences of cysts are included in the CD-ROM. This rapid decorrelation appears to be unique to cysts and is apparent in both simple and ‘complex’ cysts. An atypical image of a 3mm diameter cyst, shown in figure , demonstrates that very small objects can be resolved in strain images. The behavior of cysts is quite complicated, and we do not yet fully understand it. Of concern is why the decorrelation appears nearly equivalently in all cysts even when the viscosity of the contents is likely quite different. Also, since the capsule of cysts are sometimes locations of cancerous lesions, we want to further understand the role of the capsule in the resulting stain image.


The report by Garra, et al., [2] that demonstrated that the width of a lesion in a strain image compared to the same lesion measured in a B-mode



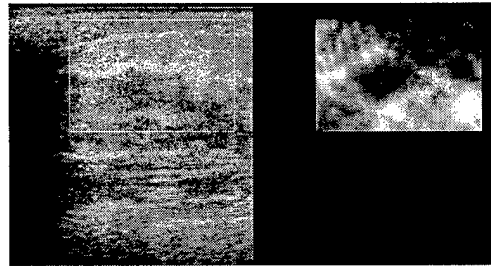
(a) Average strain.




(b) Cumulative strain.




(c) Image pairs for frame 44.



(d) Image pairs for frame 59.



(e) Image pairs for frame 17.



(f) Image pairs for frame 17.

Figure 3: Data obtained by freehand scanning of a fibroadenoma in vivo. When the pre-compression (cumulative strain) and average strain in the frame are equal, equivalent strain images are obtained.

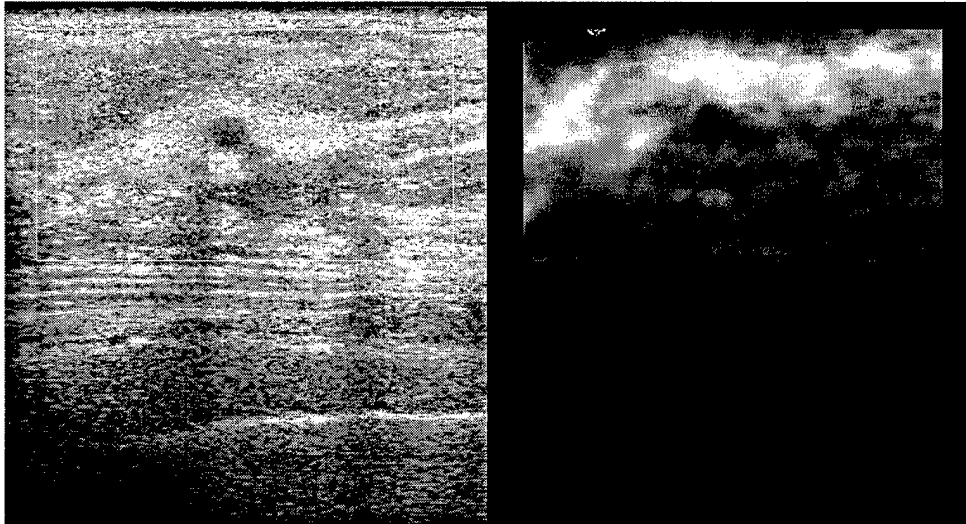
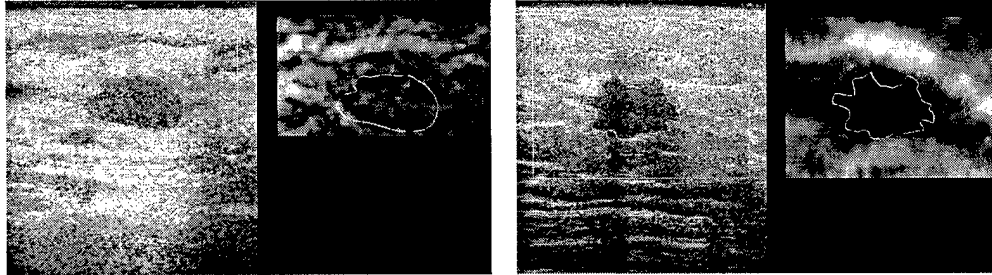


Figure 4: An image pair of a 3mm diameter cyst in a fibro-cystic breast. The cyst is easily demonstrated in the strain image confirming that small objects can be resolved in strain images.

image could be a useful criterion for discriminating malignant from benign lesions. In an effort to compare lesion size in the two imaging modalities with our data, we transferred the data to an off-line computer and reprocessed the strain images using the exact algorithm implemented on the Elegra. Movie loops of the side-by-side B-mode and strain image pairs (avi files) were created to view the motion of the lesion in the B-mode image and the resulting strain image. A representative frame was selected that showed the “typical” strain image for that lesion, and the B-mode image was displayed allowing the lesion boarder to be traced. The lesion width (and height) were estimated as the maximum dimension perpendicular (and parallel) to the acoustic beam. The tracing and measurement process was then repeated with the strain image from that same frame. Example images for a fibroadenoma and a carcinoma are shown in figure 5.

Garra, et al., suggested that the width of a carcinoma in a strain image is typically larger than that measured in a B-mode image. Our results support that observation, and apparently extend its diagnostic utility. Figure 6(a) shows plots of the width and height of these three lesion types as measured in B-mode and strain images. Figure 6(b) shows plots of a similar comparison of the total area of the lesion in the two imaging modes. Our results show



(a) B-mode and strain images of a fibroadenoma.

(b) B-mode and strain images of an invasive ductal carcinoma.

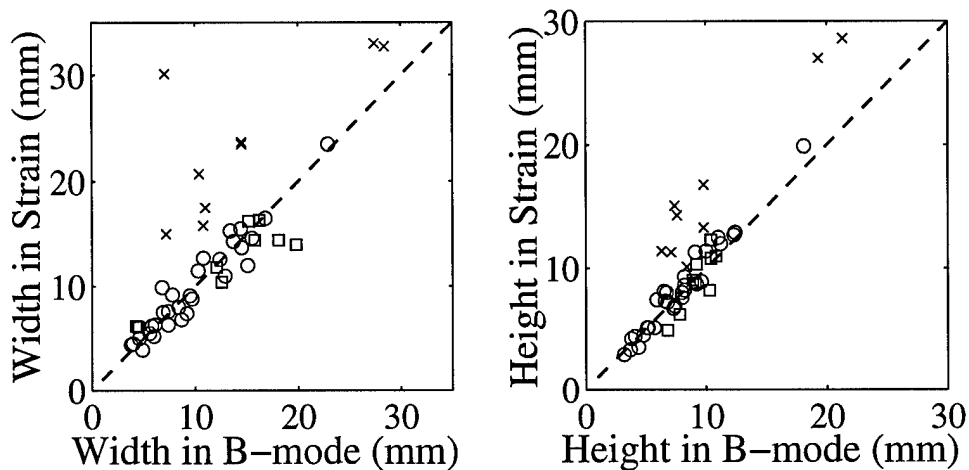
Figure 5: B-mode and strain images of lesions with their perimeter traced in the B-mode image, and that tracing also appearing in the strain image for comparison.

that the width and height of benign lesions tend to be about the same size in B-mode and strain images and carcinomas are larger in strain images than B-mode, but the separation between benign and carcinoma is much larger when we use the lesion area.

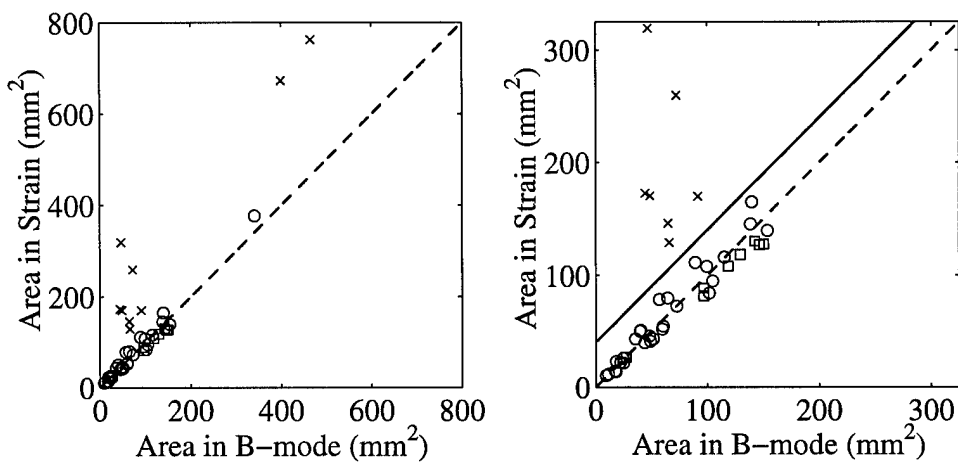
These results are very encouraging, and from this work we believe we are following a solid research plan. However, our enthusiasm must be tempered with the fact that we have relatively small numbers of samples of each lesion type so far, the data includes only one type of carcinoma (invasive ductal carcinoma), the carcinomas were ‘highly suspicious’ as a result of mammography and sonography. We will gain further confidence in these results as we scan less suspicious lesions and more of each type of ‘suspicious’ lesion. Our current plans are unchanged from those in the proposal and current protocol, except for the needs described below.

One of the reviewers of the initial application noted that sonography is highly operator dependent, that strain imaging would likely be at least as operator dependent, and that the difficulty in strain imaging might discourage its wide-spread use. We agree that in the hands of the untrained, sonography is not reproducible, and that trained, registered diagnostic medical sonographers are key in producing reliable diagnosis with ultrasound. We believe the same will be true for strain imaging. Our data provide evidence that a trained sonographer can sequentially scan a patient and produce comparable B-mode and strain images. The key to strain imaging, as in standard sonog-

raphy, is training. One of the challenges that we did not anticipate is the lack of knowledge of most sonographers in basic mechanics experiments and the associated difficulty in creating the intuition for sonographers in these studies. We propose to extend our research plan by including the future work described below. The additional costs for this work have not been estimated, but the merits of these efforts are clear.



(a) Plots of the lesion linear dimension.



(b) Plots of lesion area. All lesions are included in left plot. Only those smaller than about 1cm dia are shown in plot on the right.

Figure 6: Plots comparing the size of a lesion traced in the B-mode image versus the same lesion traced in a representative strain image for cysts (\circ), fibroadenomas (\square), and invasive ductal carcinomas (\times). The dashed line in each image represents equal size measurement in both images. The solid straight line (lower right plot) suggests that a simple linear discriminant would completely separate carcinomas from benign lesions based on lesion.

Future Work


1. *Improve the motion tracking algorithm.* The image sequences on the CD-ROM show that, although most of the images in the sequence include high-quality strain images, some of the strain images in a sequence have excessive noise, and that noise might significantly reduce the utility of that sequence for diagnosis. This is likely especially true in trying to evaluate the possible nonlinearity in strain contrast of fibroadenomas. Also, making the motion tracking more robust will increase the ease of scanning in real-time. In addition, it is very difficult to control the exact frame-to-frame strain rate during compression. As a result the average strain in each of a sequence of frames is not constant, and we must automatically scale each frame of the sequence to provide approximately the same mean gray level to avoid visual brightness flicker. The three items listed below will improve the overall quality of these image sequences:
 - Improve image quality through up-sampling (interpolating) the rf echo data from 36MHz (Elegra sampling frequency) to 72MHz or higher. An example of the benefit of this effort is demonstrated in figure 7.
 - Dynamically adjust the “skip” to maintain a constant frame-average strain of 1–1.5%. Many of the movie loops on the CD-ROM show the problem and illustrate the benefits. A dynamically-adjusted ‘skip’ will make the average brightness of these images more nearly equal and allow us to more accurately scale them.
 - Track the displacement vector field in time (frame to frame) and force that time-dependent field to be a smooth function thereby making motion tracking more robust. The benefit of this is a reduction in the large-scale displacement noise and an improved ability to judge the tissue nonlinearity (e.g., fibroadenoma).
2. *Develop training tools for teaching sonographers and clinicians basic mechanics in tissues and palpation imaging techniques.* Sonographers lack the experience of performing experiments in basic structural mechanics. Therefore, it is difficult to describe to them the need for manipulating ‘boundary conditions,’ even when it is explained in simple terms of direction of motion. We need a set of training tools to teach

sonographers what the appropriate tissue motion looks like in a B-mode image (their standard reference), what a high-quality strain image looks like when the motion is appropriate for tracking, and what the typical errors in motion are. For example, using simulation tools we have already developed we can demonstrate B-mode and strain image pairs of the desired uniaxial motion as well as situations where there is too much lateral motion, rotational motion, shear, and elevational motion. This will help to provide intuition in determining what is wrong when poor strain images are being obtained and how to correct it. Improved phantoms for practice scanning will reinforce this intuition.

- (a) Simulation software that demonstrates how a normal (B-mode) ultrasound image looks when data are acquired correctly and what can go wrong, and how to recognize what is wrong.
- (b) Phantoms as demonstration and training tools.
- (c) Phantoms to investigate the nature of strain imaging of cysts. A variety of cyst phantom designs will help us to determine the role of the capsule and the viscosity of the contents in the resulting strain image, as described above.

Key Research Accomplishments

- The motion tracking algorithm has been implemented on the Siemens SONOLINE Elegra and displays B-mode and strain images side-by-side at about eight frames per second.
- There is no significant difference between the displacement variance (strain image noise) for floating point or integer computation of displacement and strain.
- We found that the key to obtaining high-quality in vivo strain images of the breast is to form the images in “real-time,” that is, fast enough to provide the hand-eye coordination system sufficient feedback to control the conditions of tissue deformation. The minimum frame rate appears to be about four frames per second, but higher frame rates (currently about eight frames per second) make palpation imaging easier.



(a) Strain image generated with the sampling frequency of 36MHz.

(b) Strain image generated with the rf echo data interpolated to 72MHz.

(c) Strain image generated with the rf echo data interpolated to 144MHz.

Figure 7: Strain images of a phantom containing a spherical target in a uniform background with three different echo sample intervals. In all cases the displacement estimates are interpolated in the same manner to obtain sub-sample displacement accuracy, yet the benefit of interpolating the echo data is clear. Phantom data are used for this illustration to remove the ambiguity of whether the changes resulting from interpolation are real.

- We have developed scanning techniques for acquiring strain image data from in vivo breasts that provides reproducible results.
- There is no significant difference between the displacement variance (strain image noise) for freehand scanning versus motorized compression for strain imaging.
- We have found that the frame-to-frame strain patterns from various breast abnormalities appears to be unique to the abnormality. For example, the fluid within cysts appears to be ‘stirred’ when deformed in palpation imaging, and that ‘stirring’ causes the rf echo signal, and therefore the strain image, to decorrelate rapidly with time. We have also found that the strain contrast for fibroadenomas is not constant with compression; at very low pre-loading fibroadenomas are stiffer than their surroundings and provide high negative contrast. With increased compression that contrast is often significantly reduced; Invasive ductal carcinomas maintain a high negative contrast at all pre-load compressions.

- We have found that by comparing the area of a lesion measured on the standard ultrasound B-mode image with area measured on a strain image, benign lesions have nearly equal area on both modalities but invasive ductal carcinomas are significantly larger on the strain image than in B-mode.

Reportable Outcomes

Manuscripts

1. "In vivo results of real-time freehand elasticity imaging" Timothy J. Hall, Yanning Zhu, Candace S. Spalding, and Larry T. Cook, Submitted for inclusion in the 2001 IEEE Ultrasonics Symposium Proceedings.

Abstracts

1. "A New Technique for Real-Time Freehand Ultrasonic Elasticity Imaging" by Yanning Zhu, Timothy J. Hall, and Larry T. Cook, *J. Acoust. Soc. Am.* **109(5, Pt. 2)**, 2361-2, 2001
2. "Experimental Results of Real-Time freehand Elasticity Imaging" by Timothy J. Hall, Yanning Zhu, Candace S. Spalding, and Larry T. Cook, *J. Acoust. Soc. Am.* **109(5, Pt. 2)**, 2362, 2001
3. "A New System for Real-Time Freehand Ultrasonic Imaging of Tissue Elasticity" by Yanning Zhu, Timothy J. Hall, to be presented at the 2001 meeting of the Radiological Society of America, Chicago, IL, November, 2001 (poster)
4. "Ultrasound Palpation Imaging as a Tool for Improved Differentiation Among Breast Abnormalities" by Timothy J. Hall, Yanning Zhu, Candace S. Spalding, Larry T. Cook, Glendon G. Cox, and Marci Brecheisen, to be presented at the 2001 meeting of the Radiological Society of America, Chicago, IL, November, 2001 (poster)

Presentations

1. "Real-Time Palpation Imaging" by Timothy J. Hall, presented at The Conference for Ultrasonics in Biophysics and Bioengineering, Allerton

Park, Monticello, Illinois, May 2001 (Invited)

2. "A New Technique for Real-Time Freehand Ultrasonic Elasticity Imaging" by Yanning Zhu, Timothy J. Hall, and Larry T. Cook, presented at the Acoustical Society of America Meeting, Chicago, IL, June, 2001
3. "Experimental Results of Real-Time freehand Elasticity Imaging" by Timothy J. Hall, Yanning Zhu, Candace S. Spalding, and Larry T. Cook, presented at the Acoustical Society of America Meeting, Chicago, IL, June, 2001
4. "In Vivo Results of Real-Time Freehand Elasticity Imaging" by Timothy J. Hall, Yanning Zhu, Candace S. Spalding, and Larry T. Cook, presented at the 2001 IEEE Ultrasonics Symposium, Atlanta, GA, October, 2001
5. "A New System for Real-Time Freehand Ultrasonic Imaging of Tissue Elasticity" by Yanning Zhu, Timothy J. Hall, to be presented at the 2001 meeting of the Radiological Society of America, Chicago, IL, November, 2001 (poster)
6. "Ultrasound Palpation Imaging as a Tool for Improved Differentiation Among Breast Abnormalities" by Timothy J. Hall, Yanning Zhu, Candace S. Spalding, Larry T. Cook, Glendon G. Cox, and Marci Brecheisen, to be presented at the 2001 meeting of the Radiological Society of America, Chicago, IL, November, 2001 (poster)

Patents

1. Patent Application No. 60/253,031 "Ultrasonic Elasticity Imaging" by Timothy J. Hall and Yanning Zhu

Funding Applied For

1. 1R01CA94057-01 "3-D Palpation Imaging with Ultrasound," Yanning Zhu, PI (pending resubmission)

ASA 2001 (Hall and Zhu); UW 2001 (Hall, invited); IEEE 2001 (Hall and Zhu; manuscripts and presentations); RSNA 2001 (Hall and Zhu; posters and abstracts);

Patent application number 60/253,031 (work originally developed un NSF funding and extended within this project).

NIH grant application number 1R01CA94057-01 “3-D palpation imaging with ultrasound,” Yanning Zhu, Ph.D., PI.

manuscripts; abstracts; presentations; patents and licenses; degrees obtained; funding applied for; research opportunities based on this work

Conclusions

Our initial research plan included the development and initial testing of a method for real-time imaging of mechanical strain in tissue and is proceeding as planned. Our success in this effort far exceeds our anticipated results. The phantom studies proposed proved far too simple to evaluate the the merit of this technique, but the in vivo results demonstrate the reproducibility of strain imaging. Results to date show that each type of breast lesion studied has a characteristic pattern in a sequence of strain images and this might be useful in discriminating among breast lesion types. Further, measurements of lesion size in strain images compared to B-mode images appears to be a sensitive diagnostic criterion for discriminating malignant from benign lesions. One of our challenges is to teach a broader range of clinicians to perform this new scanning technique. Improvements in the motion tracking algorithm will make strain imaging more robust and increase the confidence of the sonographer. The development of training tools to help teach the basic mechanics behind this technique will improve the sonographers knowledge of the task at hand and guide in determining how to acquire the appropriate data. Our results to date indicate that real-time palpation imaging has the potential to significantly improve the diagnosis of breast abnormalities. This new tool runs as a software application on an existing clinical sonography system and is therefore easily distributed broadly when it is an appropriate product. Our software is computationally intensive, but it is expected that future sonography systems from all manufacturers will have sufficient computational capacity to support this application. Wide-spread use would likely follow, if our current results are representative. We look forward to continued success.

References

- [1] T. J. Hall, Y. Zhu, C. S. Spalding, and L. T. Cook, "In vivo results of real-time freehand elasticity imaging," in *IEEE Ultrason. Symp. Proc.*, 2001.
- [2] B. S. Garra, I. Céspedes, J. Ophir, S. R. Spratt, R. A. Zuurbier, C. M. Magnant, and M. F. Pennanen, "Elastography of the breast: Initial clinical results," *Radiology*, vol. 202, pp. 79–86, 1997.

Appendices

1. "In vivo results of real-time freehand elasticity imaging" Timothy J. Hall, Yanning Zhu, Candace S. Spalding, and Larry T. Cook, Submitted for inclusion in the 2001 IEEE Ultrasonics Symposium Proceedings.
2. "A New Technique for Real-Time Freehand Ultrasonic Elasticity Imaging" by Yanning Zhu, Timothy J. Hall, and Larry T. Cook, *J. Acoust. Soc. Am.* **109(5, Pt. 2)**, 2361-2, 2001
3. "Experimental Results of Real-Time freehand Elasticity Imaging" by Timothy J. Hall, Yanning Zhu, Candace S. Spalding, and Larry T. Cook, *J. Acoust. Soc. Am.* **109(5, Pt. 2)**, 2362, 2001
4. "A New System for Real-Time Freehand Ultrasonic Imaging of Tissue Elasticity" by Yanning Zhu, Timothy J. Hall, to be presented at the 2001 meeting of the Radiological Society of America, Chicago, IL, November, 2001 (poster)
5. "Ultrasound Palpation Imaging as a Tool for Improved Differentiation Among Breast Abnormalities" by Timothy J. Hall, Yanning Zhu, Candace S. Spalding, Larry T. Cook, Glendon G. Cox, and Marci Brecheisen, to be presented at the 2001 meeting of the Radiological Society of America, Chicago, IL, November, 2001 (poster)

IN VIVO RESULTS OF REAL-TIME FREEHAND ELASTICITY IMAGING

Timothy J. Hall, Yanning Zhu, Candace S. Spalding, and Larry T. Cook
Department of Radiology, University of Kansas Medical Center
3901 Rainbow Boulevard, Kansas City, KS 66160-7234

Abstract—We are developing a system for real-time estimation and display of tissue elastic properties using a clinical ultrasonic imaging system. Our hypothesis is that real-time feedback of elasticity images is essential in obtaining high-quality data. Extensive experience with laboratory fixtures and off-line processing of elasticity data showed that problems occurring in data acquisition often resulted in poor elasticity image quality. Our experience with real-time freehand elasticity imaging shows that images with high contrast-to-noise can be obtained. Results in volunteer patients have shown that high quality elasticity images are easily obtained in vivo in breast and thyroid pathologies. The key element to successful scanning is real-time visual feedback which guides the patient positioning and compression direction. Results show that individual images of axial strain in tissues can be quite misleading and that a ‘movie loop’ of strain images provides significantly more information adding to intuition.

I. INTRODUCTION

The potential for improving the qualitative nature of palpation by imaging quantitative measures of tissue viscoelasticity has generated a great deal of research and commercial interest world-wide. Our initial efforts focused on modelling displacement and strain, developing algorithms for displacement and strain estimation, and testing those techniques in phantoms and in vitro kidneys (see, for example, [1–5]). Significant effort was expended on developing high-order motion estimators for tracking fine-scale motion. However, little

We are grateful for the financial support of USAMRAA DAMD17-00-1-0596 and NSF BES-9708221 and technical support from Siemens Medical Systems Ultrasound Group. The U.S. Army Medical Research Acquisition Activity, 820 Chandler Street, Fort Detrick MD 21702-5014 is the awarding and administering acquisition office for DAMD17-00-1-0596. The information reported here does not necessarily reflect the position or policy of the U.S. Government, and no official endorsement should be inferred.

data were available to investigate the need or utility of the high-order motion estimation techniques for in vivo imaging of tissues. The most useful report [6] used relatively crude data acquisition hardware and simple motion tracking software, but this effort clearly demonstrated that strain imaging has merit in breast lesion discrimination.

Our efforts in this study focus on the development of algorithms with the potential for performing strain imaging at substantially real-time frame rates, and implementing and testing those algorithms on a state-of-the-art ultrasound imaging system. Our results demonstrate the value in real-time side-by-side display of B-mode and strain images for guiding data acquisition and data interpretation. Comparisons among different lesion types studied in vivo show a significant difference in strain images for cysts, fibroadenoma, and carcinoma.

The report by Garra, et al., [6] described a set of criteria applied to evaluate strain imaging compared to normal B-mode imaging. Among those criteria were lesion visibility, relative brightness, lesion margin regularity, lesion margin definition, lesion size (lateral and axial), B-mode image measurements relative to strain image and pathology measurements. Among their findings, they noted that all benign lesions have about the same width on B-mode and strain images, but the height measurement could not be trusted due to axial blurring in image formation. Fibroadenomas typically were non-uniform in stiffness; cancers were uniformly stiffer than their surroundings in all but one case.

Our results are generally consistent with those found by Garra, et al., but the differences in carcinoma size in B-mode and strain images is greater and all lesions found in sonography or mammography, whether palpable or not, were visible with our techniques. Some of our findings help to understand the shortcomings of

the results reported by Garra and provide even more evidence for the utility of this technique for the discrimination of carcinomas from benign conditions.

II. MATERIALS AND METHODS

Strain Image Formation

A 2-D block matching algorithm, based on the sum-squared difference (SSD) algorithm, is used for motion tracking in our implementation. With this method, motion is tracked by searching for a kernel of data from the pre-compression rf echo data in a search region of the post-compression rf echo field. The kernel size was selected to approximate the 2-D pulse-echo ultrasound point spread function for the system employed (Siemens SONOLINE Elegra with 7.5L40 and VFX13-5 linear arrays). Data were processed on the Image Processor subsystem of the Elegra. This subsystem hosts two Texas Instruments TMS320C80 processors. The SSD algorithm exceeds the computational capacity of the Image Processor subsystem. To reduce the computational load, an adaptive search strategy was developed which reduces the size of the required search region in performing the SSD block matching. The resulting algorithm displays streaming B-mode and strain images side-by-side at about eight frames per second and stores the full sequence of I-Q echo data at full bus speed for on-line post-processing.

Echo data obtained while scanning phantoms with motorized and freehand compression result in equivalent strain image contrast and resolution when the average strain in the image is the same for the two methods. Displacement variance is slightly higher for freehand compression, and the frame-to-frame strain is not constant, but this is a small penalty for the ease of freehand scanning. In fact, small (e.g., 2.4mm diameter) spherical targets are considerably easier to locate and scan with freehand compared to motorized compression.

Patient Scanning

All patients provided informed consent consistent with the protocol approved by the Human Subjects Committee (Institutional Review Board) at Kansas University Medical Center. Patient scans were performed in a manner consistent with a normal breast ultrasound exam; the breast was scanned with the patient (typically) in the supine position with her arm behind her head. When the breast lesion was located,

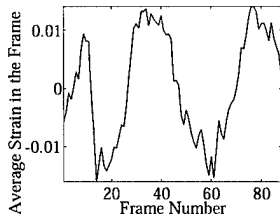
the transducer was pressed toward the chest wall at a steady rate in an effort to achieve about 1–1.5% compression frame-to-frame. In some cases, for example when scanning lateral lesions in large (D-cup) breasts, the patient was rolled slightly to her contralateral side so that gravity would flatten the breast tissue in the region to be scanned. Using this scanning technique, no patient has experienced any discomfort in our procedures.

The scanning procedure began, following lesion localization, by repeating the compress/release cycle for relatively large (>10%) compression while watching the B-mode image. The compression technique was adjusted, by changing the compression direction or patient position, until there was nearly uniaxial compression with minimal elevation motion. With this achieved, the strain imaging software was enabled to evaluate the quality of the sequence of strain images. If a large sequence (<30 frames) of strain images had good image quality (relatively high contrast-to-noise ratio) and high frame-to-frame similarity, the data acquisition was frozen, the image sequence stored, and select images recorded on-line. If the compression was too slow resulting in low frame-average strain, the inter-frame skip was adjusted to increase the strain between frame pairs used in displacement and strain estimation, as suggested by Lubinski, et al., [7]. A representative result for a 3mm cyst is shown in figure 1.

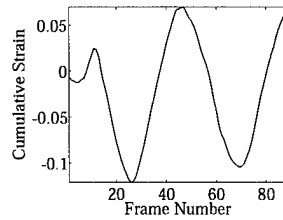
A similar scanning technique was used to acquire data from several thyroids. The scanning technique began by viewing the thyroid in a B-mode image during compress/release cycles to determine the preferred probe position and compression direction. The goal for the average strain between adjacent frames and the total cumulative strain are the same as before. We have much less experience with Palpation Imaging of the thyroid (compared with breast), however, figure 2 proves that high quality strain images can be obtained.

III. RESULTS


One of the most promising uses of this technology is differentiation among breast lesions. To date we have successfully scanned 42 breast patients. Among these patients we have acquired data from 25 cysts, 18 fibroadenomas, and six carcinomas. Each of these lesion types has a distinctive behavior in its strain image under cyclic compression. Cysts have well-defined



(a) Average strain.



(b) Cumulative strain.



(c) B-mode and strain images as displayed on the Elegra for frame 40 in the sequence.

Fig. 1. Data obtained by freehand scanning of a breast cyst *in vivo*. The average strain per frame (a) suggests nearly ideal compression rate in this case. The adjacent frames were used in analyzing this sequence of data. The cumulative strain in the sequence (b) demonstrates that about a 18% compression range was achieved in this study. A B-mode and strain image pair obtained from this sequence is shown in (c).




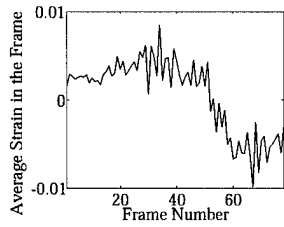
Fig. 2. A B-mode and strain image pair obtained by freehand scanning of a thyroid *in vivo*. A small benign lesion is seen in the lower corner of the thyroid.

boundaries at the top and sides, but sometimes show a very soft bottom layer. That layer might be due to a sediment inside the cystic fluid. The interior echoes within the cysts rapidly decorrelate with compression. Overall a cyst can be either relatively stiff,

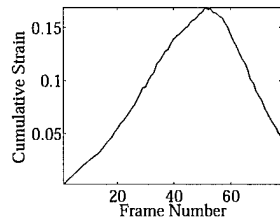
as if it were a distended balloon, or relatively soft. Fibroadenomas also (typically) have well-defined boundaries and often have relatively homogeneous interior stiffness. However, some fibroadenomas have heterogeneous strain patterns. All fibroadenomas are more comparable in stiffness to the surrounding tissues than carcinomas. Indeed, fibroadenomas appear to have a nonlinear stress-strain relationship relative to their surroundings as illustrated in figure 3. All carcinomas studied so far were invasive ductal carcinomas that were easily diagnosed from mammogram and sonogram results.

In an effort to compare lesion size in the two imaging modalities, we transferred the data to an off-line computer for further analysis. We reprocessed the strain images using the exact algorithm implemented on the Elegra. Movie loops of the side-by-side B-mode and strain image pairs (avi files) were created to view the motion of the lesion in the B-mode image and the resulting strain image. A representative frame was selected that showed the "typical" strain image for that lesion, and the B-mode image was displayed allowing the lesion border to be traced. The lesion width (and height) were estimated as the maximum dimension perpendicular (and parallel) to the acoustic beam. The tracing and measurement process was then repeated with the strain image from that same frame. Example images for a fibroadenoma and a carcinoma are shown in figure 4.


It is intriguing to examine the relative size of these lesions comparing their width, height, and area as measured in B-mode and strain images. Garra, et al., suggested that the width of a carcinoma in a strain image is typically larger than that measured in a B-mode image. Our results support that observation, and apparently extend its diagnostic utility. Figure 5(a) shows plots of the width and height of these three lesion types as measured in B-mode and strain images. Figure 5(b) shows plots of a similar comparison of the total area of the lesion in the two imaging modes. Our results show that the width and height of benign lesions tend to be about the same size in B-mode and strain images and carcinomas are larger in strain images than B-mode, but the separation between benign and carcinoma is much larger when we use the lesion area.



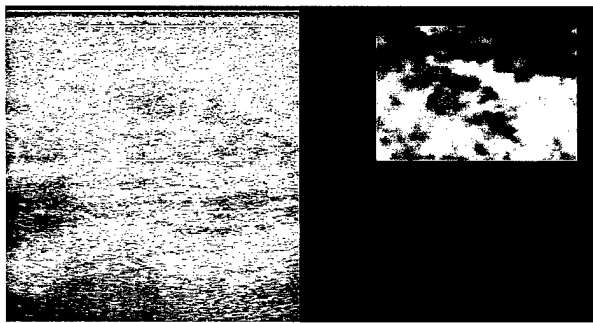
(a) Average strain.



(b) Cumulative strain.



(c) B-mode and strain images for frame 44. A similar image is found at frame 59.




(d) B-mode and strain images for frame 17. A similar image is found at frame 77.

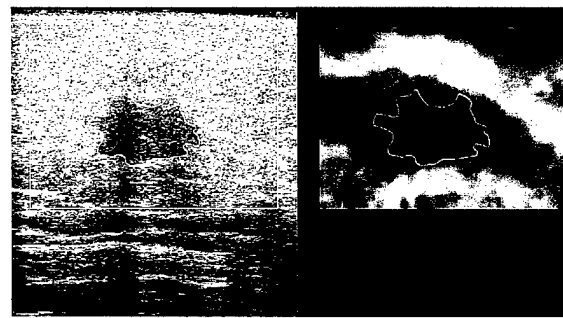
Fig. 3. Data obtained by freehand scanning of a fibroadenoma in vivo. The average strain per frame (a) suggests a slow compression rate in this case. The inter-frame skip was increased to pair every fourth frame in analyzing this sequence of data. The cumulative strain in the sequence (b) demonstrates that about a 20% compression range was achieved in this study.

IV. DISCUSSION

Real-time display of side-by-side B-mode and strain images is essential for guiding the manipulation of boundary conditions for the mechanics experiment that is strain imaging. The real-time feedback to the hand-



(a) B-mode and strain images of a fibroadenoma.

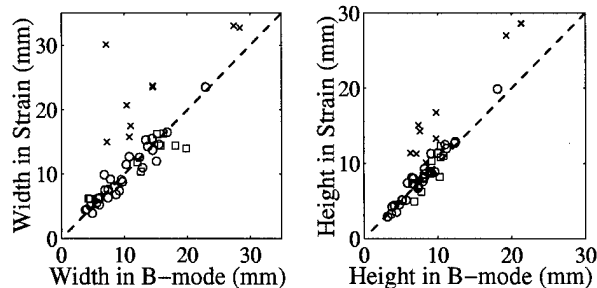


(b) B-mode and strain images of an invasive ductal carcinoma.

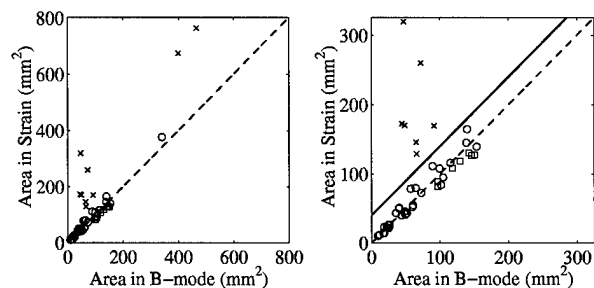
Fig. 4. B-mode and strain images of lesions with their perimeter traced in the B-mode image, and that tracing also appearing in the strain image for comparison.

eye coordination systems allows the sonographer to manipulate the compression direction, force, and rate to obtain high-quality sequences of strain images. The system involves no addition fixtures or remote data acquisition or signal processing hardware. It is fully integrated into the Elegra system.

Our results show significantly different strain image sequences for each lesion type studied. Although the range of lesion types does not include all those found in breasts, they do include the vast majority of types. It was found that to appreciate the differences among lesion types, and to determine the "typical" strain image for a given lesion, it was necessary to observe a sequence of B-mode and strain images displayed side-by-side. With that sequence, a very reproducible determination of the lesion boundary could be obtained. Measurements of lesion dimension were then made and the results for lesion width are consistent with



(a) Plots of the lesion linear dimension.



(b) Plots of lesion area. All lesions are included in left plot. Only those smaller than about 1cm dia are shown in plot on the right.

Fig. 5. Plots comparing the size of a lesion traced in the B-mode image versus the same lesion traced in a representative strain image for cysts (o), fibroadenomas (\square), and invasive ductal carcinomas (x). The dashed line in each image represents equal size measurement in both images. The solid straight line (lower right plot) suggests that a simple linear discriminant would completely separate carcinomas from benign lesions based on lesion.

those reported by Garra, et al. That report stated a lack of confidence in their measurements of lesion height. Our results with cylindrical and spherical targets in phantoms show that we can accurately measure lesion dimension in both height and width, and therefore we use lesion area as the criterion for comparing lesion size in B-mode and strain images.

The smoothly varying strain contrast appears to be unique to fibroadenomas so far in our experience. Smoothly varying contrast suggests that the stress-strain relationship for the fibroadenoma does not parallel that of the surrounding tissue. Fibroadenomas that vary in strain contrast appear dark (stiffer) at low precompression and lose contrast (become relatively softer) at higher precompression. This suggests that

the stress-strain relationship for the surrounding tissue is likely more nonlinear than that of the fibroadenoma.

The sequence of B-mode and strain image pairs allows the sonographer to select images representative of the “typical” strain image for a lesion. This ability, along with better determination of lesion boundary available by viewing a sequence of images, has likely improved the ability to measure true lesion size in strain imaging compared with the results reported by Garra, et al.

V. CONCLUSIONS

A new system for real-time imaging of tissue strain in vivo using freehand scanning is described and some of the results obtained with this system are reported. The new system provides real-time feedback allowing the user to manipulate the conditions of tissue compression resulting in the ability to successfully scan all patients for which the technique was attempted. The strain images for various lesion types are unique, and the relative size of the lesions appears to be a strong candidate for discriminating benign from cancerous lesions. However, further testing will be needed to support this observation.

REFERENCES

- [1] P. Chaturvedi, M. F. Insana, and T. J. Hall, “2-D companding for noise reduction in strain imaging,” *IEEE Trans Ultrason, Ferroelec, Freq Cont*, vol. 45, no. 1, pp. 179–191, 1998.
- [2] P. Chaturvedi, M. F. Insana, and T. J. Hall, “Testing the limitations of 2-D companding for strain imaging using phantoms,” *IEEE Trans Ultrason, Ferroelec, Freq Cont*, vol. 45, no. 4, pp. 1022–1031, 1998.
- [3] T. J. Hall, M. Bilgen, M. F. Insana, and T. A. Krouskop, “Phantom materials for elastography,” *IEEE Trans Ultrason, Ferroelec, Freq Cont*, vol. 44, no. 6, pp. 1355–1365, 1997.
- [4] M. F. Insana, P. Chaturvedi, T. J. Hall, and M. Bilgen, “3-D companding using linear arrays for improved strain imaging,” *Proc IEEE Ultrason Symp*, vol. 97CH36118, pp. 1435–1438, 1997.
- [5] Y. Zhu, P. Chaturvedi, and M. Insana, “Strain imaging with a deformable mesh,” *Ultrasonic Imaging*, vol. 21, pp. 127–146, 1998.
- [6] B. S. Garra, I. Céspedes, J. Ophir, S. R. Spratt, R. A. Zuurbier, C. M. Magnant, and M. F. Pennanen, “Elastography of the breast: Initial clinical results,” *Radiology*, vol. 202, pp. 79–86, 1997.
- [7] M. A. Lubinski, S. Y. Emelianov, and M. O’Donnell, “Adaptive strain estimation using retrospective processing,” *IEEE Trans Ultrason, Ferroelec, Freq Cont*, vol. 46, no. 1, pp. 97–107, 1999.

GOOD ABSTRACT

Note that until a new Resubmission number and PIN are issued by the system, your abstract has NOT been entered into the database.

Your abstract is free of errors and the abstract, as it will appear in the meeting program is shown below. You now have the option to submit the abstract or make changes by selecting the appropriate choice below. Scroll down to view the abstract.

This is the way your abstract will appear in the meeting program.

Experimental results of real-time freehand elasticity imaging Timothy Hall, Yanning Zhu, Candace Spalding, and Larry Cook (Radiology Dept., Univ. of Kansas Med Ctr., 3901 Rainbow BLVD, Kansas City, KS 66160 thall@kumc.edu)

A system for high-speed calculation of tissue elastic properties using a clinical ultrasonic imaging system will be presented. The hypothesis driving this development is that real-time feedback of elasticity images is essential in obtaining high-quality data (consecutive images with high spatial coherence). Extensive experience with laboratory fixtures and off-line processing of elasticity data showed that problems occurring in data acquisition often resulted in poor elasticity image quality. The delay in observing the resulting images, due to off-line processing, resulted in slow progress in developing experimental techniques and signal processing strategies. When high-quality data were obtained, high contrast-to-noise images were available. Initial experience with real-time freehand elasticity imaging shows that images with similar high contrast-to-noise can be obtained. Results in volunteer patients have shown that high quality elasticity images are easily obtained in vivo for a variety of breast pathologies, and the changes in breast tumor elasticity during the course of chemotherapy can be monitored. Video of real-time elasticity imaging will demonstrate the ease with which these results are obtained. We are grateful for the support by USAMRAA DAMD17-00-1-0596, Siemens Medical Systems, and NSF BES-9708221.

Number of words in abstract: 196

Suggested Special Session:

Technical Area: Biomedical Ultrasound/Bioresponse to Vibration

(PACS) Subject Classification number(s): 43.80, 43.60

Telephone number: (913) 588-7868

email address: thall@kumc.edu

Send notice to: Timothy Hall, Radiology Dept., Univ. of Kansas Med Center, 3901 Rainbow BLVD, Kansas City, KS 66160

Special Facility: computer projection

Method of Presentation: lecture

Guiding Principles: I have complied with ASA Guiding Principles

10428

1

17:54 2-2-2001

-
- Yes, I want to submit this and receive my PIN and Resubmission numbers.
 No, I want to change (i.e. edit) this abstract; get my abstract template back.

[Continue](#)

GOOD ABSTRACT

Note that until a new Resubmission number and PIN are issued by the system, your abstract has NOT been entered into the database.

Your abstract is free of errors and the abstract, as it will appear in the meeting program is shown below. You now have the option to submit the abstract or make changes by selecting the appropriate choice below. Scroll down to view the abstract.

This is the way your abstract will appear in the meeting program.

A new technique for real-time freehand ultrasonic elasticity imaging. Yanning Zhu, Timothy Hall, and Larry Cook (Dept. of Radiology, Univ. of Kansas Med. Ctr., 3901 Rainbow Boulevard, Kansas City, KS 66160 yzhu@kumc.edu)

An method for high speed, freehand ultrasonic elasticity imaging will be described. The method is based on a modified block matching technique. The modification serves two purposes. First, in order to achieve real-time performance a forward prediction mechanism is used to reduce the computational load that a conventional block matching technique requires. Second, in order to accommodate the waveform decorrelation associated with freehand scanning a statistical error detection and correction method was developed. This prevents the displacement estimation errors from propagating to affect a larger area. This new algorithm has been implemented on a Siemens Elegra (a high-end clinical ultrasound imaging system). The initial tests show that the new system can perform B-mode and strain display task at real-time frame rates. The strain images have low noise and excellent contrast. Some results obtained with this system will also be presented. The support by USAMRAA DAMD17-00-1-0596, NSF BES-9708221, and Siemens Medical Systems is gratefully acknowledged.

Number of words in abstract: 154

Suggested Special Session:

Technical Area: Biomedical Ultrasound/Bioresponse to Vibration

(PACS) Subject Classification number(s): 43.80, 43.60

Telephone number: (913) 588-7693 email address: yzhu@kumc.edu

Send notice to: Yanning Zhu, Dept. of Radiology, Univ. of Kansas Med. Center, 3901 Rainbow Boulevard, Kansas City, KS 66160

Special Facility:

Method of Presentation: poster

Guiding Principles: I have complied with ASA Guiding Principles

10440

1

18:4 2-2-2001

-
- Yes, I want to submit this and receive my PIN and Resubmission numbers.
 No, I want to change (i.e. edit) this abstract; get my abstract template back.

[Continue](#)

Abstract ID:

204754

Instructions

General

Information,

Tips, &

Frequently

Asked Questions

Submission

Guidelines

Abstract

Checklist

Submission

Type

Category

Type-specific

Questions

Authors and

Commercial

Disclosure

FDA Disclosure

Title

Body

Keywords

Other Options

Corresponding

Author Contact

Information

Logout

A NEW SYSTEM FOR REAL-TIME FREEHAND IMAGING OF TISSUE ELASTICITY

Yanning. Zhu and Timothy. J. Hall

PURPOSE: A new system for imaging the elastic properties of tissues in real-time with freehand scanning is described. **METHODS AND MATERIALS:** The system is based on the Siemens Sonoline Elegra ultrasonic imaging system and involves software modifications only (no additional hardware). The general problem of tracking 3-D motion with a 2-D imaging system, and the specific solution implemented in real-time on the Siemens Elegra will be described. The limitations in image quality due to freehand scanning (versus controlled motorized compression) will also be discussed. **RESULTS:** The variance in displacement estimates increases only slightly with freehand scanning versus motorized compression. Real-time imaging of tissue elasticity provides the visual feedback to know when high-quality data are acquired. **CONCLUSIONS:** Examples from phantoms and breast and thyroid abnormalities show that real-time feedback allows the sonographer to manipulate the scanning technique to reproducibly obtain high-quality images. High resolution, low noise images in phantoms and tissue show that this new system has great promise as a new diagnostic tool for soft tissues.

Submit Abstract

Displayed above is a copy of your Abstract submission. If you are satisfied with your abstract, select the "Continue" button and your abstract will be submitted. If you are not satisfied with your abstract, select the "Return to Checklist" button, and then choose the appropriate link from the Checklist page to edit your abstract. Please be sure that your abstract is complete before you select the "continue" button. **You will not be able to make changes once your abstract has been submitted**

[Continue](#)

[Return to Checklist](#)

[Logout](#)

If you have any questions or experience any problems, please contact Customer Support at rsna@dbpub.com or call (617) 621-1398 or (800) 375-2586.

RSNA Abstract Submitter

Abstract ID:
204840

Instructions

[General Information, Tips, & Frequently Asked Questions](#)
[Submission Guidelines](#)

Abstract Checklist

[Submission Type](#)

[Category](#)

[Type-specific Questions](#)

[Authors and Commercial Disclosure](#)

[FDA Disclosure](#)

[Title](#)

[Body](#)

[Keywords](#)

Other Options

[Corresponding Author Contact Information](#)

[Logout](#)

ULTRASOUND PALPATION IMAGING AS A TOOL FOR IMPROVED DIFFERENTIATION AMONG BREAST ABNORMALITIES

Timothy. J. Hall, Yanning. Zhu, Candace. Spalding, Patrick. Von Behren, Glendon. G. Cox and Marci. Brecheisen

PURPOSE: A new "palpation imaging" system for visualizing the elastic properties of tissues in real-time provides an opportunity to test the hypothesis that tissue elastic properties can be used to improve detection and discrimination in breast cancer imaging. A previous report by Garra, et al. (Radiology 202:79-86, 1997) provided criteria for strain image evaluation. **METHODS AND MATERIALS:** The system is integrated into the Siemens Sonoline Elegra ultrasonic imaging system and tracks motion in 2-D. The system provides sequences of strain images during freehand compression-release cycles. The sequence of high-quality strain images increases confidence in the interpretation of the strain image data. Normal breasts and those with cysts, benign solid tumors and malignant tumors were studied. **RESULTS:** Real-time image feedback has allowed us to form high-quality strain images of all palpable lesions. **CONCLUSIONS:** Images of tissue elasticity obtained with the new palpation imaging system show that most of Garra's criteria are consistent with current data, however some criteria can be improved.

Submit Abstract

Displayed above is a copy of your Abstract submission. If you are satisfied with your abstract, select the "Continue" button and your abstract will be submitted. If you are not satisfied with your abstract, select the "Return to Checklist" button, and then choose the appropriate link from the Checklist page to edit your abstract. Please be sure that your abstract is complete before you select the "continue" button. **You will not be able to make changes once your abstract has been submitted**

[Continue](#)

[Return to Checklist](#)

[Logout](#)

If you have any questions or experience any problems, please contact Customer Support at rsna@dbpub.com or call (617) 621-1398 or (800) 375-2586.