

AD \_\_\_\_\_

Award Number: DAMD17-96-C-6059

TITLE: MRI-Based Screen for Breast Cancer Patients Carrying a Breast Susceptibility Gene

PRINCIPAL INVESTIGATOR: Mitchell D. Schnall, M.D.

CONTRACTING ORGANIZATION: University of Pennsylvania  
Philadelphia, Pennsylvania 19104-3246

REPORT DATE: July 2001

TYPE OF REPORT: Final

PREPARED FOR: U.S. Army Medical Research and Materiel Command  
Fort Detrick, Maryland 21702-5012

DISTRIBUTION STATEMENT: Approved for Public Release;  
Distribution Unlimited

The views, opinions and/or findings contained in this report are those of the author(s) and should not be construed as an official Department of the Army position, policy or decision unless so designated by other documentation.

20020206 126

# REPORT DOCUMENTATION PAGE

Form Approved  
OMB No. 074-0188

Public reporting burden for this collection of information is estimated to average 1 hour per response, including the time for reviewing instructions, searching existing data sources, gathering and maintaining the data needed, and completing and reviewing this collection of information. Send comments regarding this burden estimate or any other aspect of this collection of information, including suggestions for reducing this burden to Washington Headquarters Services, Directorate for Information Operations and Reports, 1215 Jefferson Davis Highway, Suite 1204, Arlington, VA 22202-4302, and to the Office of Management and Budget, Paperwork Reduction Project (0704-0188), Washington, DC 20503

<b>1. AGENCY USE ONLY (Leave blank)</b>		<b>2. REPORT DATE</b> July 2001	<b>3. REPORT TYPE AND DATES COVERED</b> Final (15 Sep 96 - 31 Jul 01)	
<b>4. TITLE AND SUBTITLE</b> MRI-Based Screen for Breast Cancer Patients Carrying a Breast Susceptibility Gene			<b>5. FUNDING NUMBERS</b> DAMD17-96-C-6059	
<b>6. AUTHOR(S)</b> Mitchell D. Schnall, M.D.				
<b>7. PERFORMING ORGANIZATION NAME(S) AND ADDRESS(ES)</b> University of Pennsylvania Philadelphia, Pennsylvania 19104-3246  E-Mail: <a href="mailto:schnall@oasis.rad.upenn.edu">schnall@oasis.rad.upenn.edu</a>			<b>8. PERFORMING ORGANIZATION REPORT NUMBER</b>	
<b>9. SPONSORING / MONITORING AGENCY NAME(S) AND ADDRESS(ES)</b> U.S. Army Medical Research and Materiel Command Fort Detrick, Maryland 21702-5012			<b>10. SPONSORING / MONITORING AGENCY REPORT NUMBER</b>	
<b>11. SUPPLEMENTARY NOTES</b>				
<b>12a. DISTRIBUTION / AVAILABILITY STATEMENT</b> Approved for Public Release; Distribution Unlimited			<b>12b. DISTRIBUTION CODE</b>	
<b>13. Abstract (Maximum 200 Words) (abstract should contain no proprietary or confidential information)</b>  We have successfully performed an MR screening study on 181 patients at high risk for breast cancer that did not have an actionable mammogram or clinical finding prior to study entry. Abnormal MRI findings prompted a total of 31 biopsies, 6 of which yielded malignant findings. The cancer yield of the MRI screen was 3.3% of the women, and 1.8% of the exams (2.2% for the Initial screens and 1.1% of the follow up screens). The false negative rate of MRI with a variable follow up was 1/7 (14%). Although the data needs to be confirmed with larger studies, this data suggests that MRI may be a valuable tool for screening women at high risk for breast cancer.				
<b>14. Subject Terms (keywords previously assigned to proposal abstract or terms which apply to this award)</b> Screening, MRI, high-risk			<b>15. NUMBER OF PAGES</b> 19	
			<b>16. PRICE CODE</b>	
<b>17. SECURITY CLASSIFICATION OF REPORT</b> Unclassified	<b>18. SECURITY CLASSIFICATION OF THIS PAGE</b> Unclassified	<b>19. SECURITY CLASSIFICATION OF ABSTRACT</b> Unclassified	<b>20. LIMITATION OF ABSTRACT</b> Unlimited	

## Table of Contents

Cover.....	
SF 298.....	
Table of Contents.....	
Introduction.....	1-3
Body.....	3-12
Key Research Accomplishments.....	12-13
Reportable Outcomes.....	13
Conclusions.....	13
References.....	14-16
Appendices.....	

## Introduction

The incidence of breast cancer is increasing and it is estimated that approximately 1 in 8 (1) women in the United States will develop breast cancer in her lifetime. This translates to approximately 180,000 American women developing breast cancer each year and approximately 45,000 deaths due to breast cancer yearly (2). While it is well accepted that routine mammography screening coupled with clinical breast exam can reduce breast cancer mortality, the large prospective trials that demonstrated the impact of breast cancer screening strategies were performed without knowledge of the cancer risk of the individual subjects. Therefore, the effectiveness of these strategies must be assumed to apply to women at *average risk* for breast cancer. As a result of public awareness of the increasing incidence of breast cancer combined with the media coverage of recent advances in the genetics of breast cancer, women are increasingly concerned about their individual risk of developing breast cancer.

Multiple risk factors for the development of breast cancer have been reported but none have proven as significant as personal history and family history of the disease. Studies have shown that a woman's risk for breast cancer is strongly related to the number and types of relatives that have had breast cancer as well as other genetically related cancers such as ovarian carcinoma. Familial clustering of breast cancer was first described by physicians in ancient Rome (3) and first documented in the medical literature in 1866 by a French surgeon who reported ten cases of breast cancer in four generations of his wife's family (4). Although non-inherited factors certainly play a role in familial clustering of breast cancer, recent advances have provided unequivocal evidence for the presence of breast cancer susceptibility genes. These breast cancer genes are thought to be responsible for 5-10% of all newly diagnosed breast cancer and 25% of cases of women diagnosed with breast cancer before the age of 30 years (5).

Linkage analysis has been performed to determine the loci of breast cancer susceptibility genes. The genetic marker, now referred to as BRCA1, is felt to be responsible for the breast ovarian cancer syndrome. Carriers of mutations in BRCA1 are estimated to have an 85% lifetime risk of breast cancer and a 60% lifetime risk of ovarian cancer (6-8). Although BRCA1 is felt to be responsible for only 3-5% of all breast cancer (9,10), it is estimated that as many as 1 in 500-1000 women carry a BRCA1 mutation. In addition, cancer in these women tends to occur at a young age when the breasts are denser and cancers are more difficult to detect with conventional film-screen mammography. By the age of 50 years, more than 50% of the BRCA1 or BRCA2 mutation carriers have already developed the disease (7).

Recent studies comparing multiple pedigrees with a dominant inheritance pattern for breast cancer have shown that there is at least one gene or possibly multiple genes other than BRCA1 which predispose women to early onset breast cancer and which may also confer an increased risk of male breast cancer (11). These studies have now been confirmed with the finding of BRCA2 on chromosome 13 (11,12). It is likely that other genes that are linked to breast cancer will also be discovered.

In addition to family history, there are other important factors that place a woman at high risk for breast cancer. Although lobular carcinoma in situ (LCIS) is felt not to represent a malignant precursor, it is felt to be an important marker of a high risk for malignancy. A diagnosis of LCIS is felt to be associated with an 11 fold increase a women's risk of having breast cancer. Exogenous factors such as chest wall irradiation as a child also carry a very high risk of breast cancer (13).

In women already diagnosed with a unilateral breast cancer, there is also an increased risk for developing disease in the contralateral breast. Although the NSABP data from the B-14 trial would suggest a 2-3% incidence of cancer in the contralateral breast (14), further follow-up at 10 years reveals a close to 7% incidence of contralateral breast cancer detected by conventional techniques (15). This data is limited to patients with node negative disease and ER positive tumor. Recent studies have suggested that this incidence is much higher than the previously thought (16,17). In a recent study where MRI was used to screen the contra-lateral breast of 42 women known to have a unilateral cancer, Slanetz et al found 9 unsuspected cancers, a yield remarkably higher than expected (16). Dunfee (17) also reported on finding 9 unsuspected contra-lateral lesions in 92 patients. Although the true incidence of cancer in the contra-lateral breast is not really known, these small reports suggest that it might be higher than previously thought. Unfortunately, at present, there is no algorithm for imaging screening and surveillance for women considered at higher than average risk nor is the type of imaging characteristics of their breast factored into the recommendation for risk reduction or the possible recommendation for prophylactic surgery or use of chemoprevention regimens.

Breast cancer risk assessment provides an opportunity to devise appropriate clinical and imaging surveillance strategies for women in multiple different risk categories. We are fortunate at the University of Pennsylvania to have a comprehensive risk assessment clinic that counsels women at high risk for breast cancer and provides genetic testing when requested. Once a family with a mutation is identified, the testing of interested family members can be performed. Risk assessment may also be based on detailed personal and family histories rather than on genetic testing as discussed above. Multiple models are

used for assessing relative risk and cumulative risk of breast cancer. The Claus model (5) was derived specifically to predict risk for women with a family history of breast cancer. This analysis allows construction of tables that predict the cumulative risk of breast cancer at specific ages based on age at onset of various combinations of affected first-degree and second-degree relatives. The Gail model (18) calculates breast cancer risk using a formula that considers age at menarche, age at first live birth, number of first-degree relatives with breast cancer, number of previous breast biopsies, and age as pertinent factors. The appropriate choice of which model to use to derive a risk assessment for a patient is complex and is dependent on the lineage of the family (Claus model) and the adherence to screening guidelines of the affected family members (Gail model) (19).

While mammography has clearly become the gold standard in the detection of early, clinically occult breast cancer, it has limitations. For example, not all cancers are detected mammographically; some cancers present as interval palpable lesions that do not produce changes in the breast that are detected by conventional film-screen techniques. Variations in the composition of the breast led to the wide range of resultant mammographic appearances. The volume of glandular or radiographically "dense" tissue in the breast has a significant impact on the ability to detect small lesions mammographically. It is more difficult to diagnose a breast cancer in a radiographically dense woman. The dense breast is considered to be a major factor in the false-negative mammographic interpretation (20-22) We also know that mammography may be less sensitive in detecting small, early cancers in the dense or glandular breasts that are frequently seen in younger women (21).

Breast MRI has been shown to demonstrate mammogram and clinically occult cancer (23). The high sensitivity independent of breast density suggests that MRI may represent a powerful screening tool for breast cancer. Obviously, the cost of MRI screening for all women at this time is prohibitive. However, the possible gains in sensitivity combined with the added benefits of early detection of MRI may outweigh the cost in select populations of women. This study represents a pilot study of the use of MRI to screen women at high risk for breast cancer. It is aimed at determining initial estimates of the cancer yield of MRI screening relative to mammography screening.

## **Body**

### **Methods**

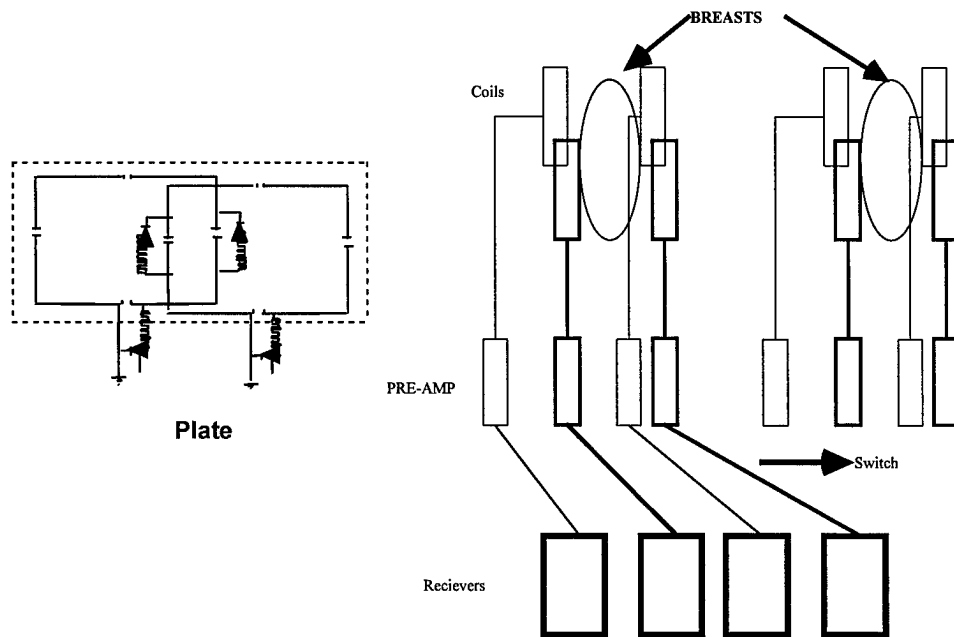
Women of all races and ethnic backgrounds older than 18 years of age that presented with a documented high risk for breast cancer were considered eligible for this study. The entrance criteria evolved during the conduct of the research.

Initially, the intent was to enroll women that were known to have a breast cancer susceptibility gene (mutation in BRCA1/BRCA2). Concerns regarding confidentiality of the patient's gene status and the need to undergo testing to enroll in the screening trial have resulting in a revision of the entrance criteria. Entrance criteria of a 30% lifetime risk of breast cancer were adopted. Specific risk criteria that were felt to meet this criteria include a 30% lifetime risk based on the Gail, Clause or other established risk model, greater than 40% probability of carrying a mutation based on the Cauch model, a previous biopsy that was positive for LCIS, and a history of chest wall radiation as a child. In addition, women with a known contralateral breast cancer were added as eligible for enrollment of the non cancer breast . Women were recruited from the Breast Cancer Risk Evaluation Center at the University of Pennsylvania or were referred from other clinicians with experience in Breast Cancer Risk Assessment.

All patients undergo a physical examination as part of their routine clinical care. In addition, as part of their normal clinical care, most patients have undergone routine mammography screening.

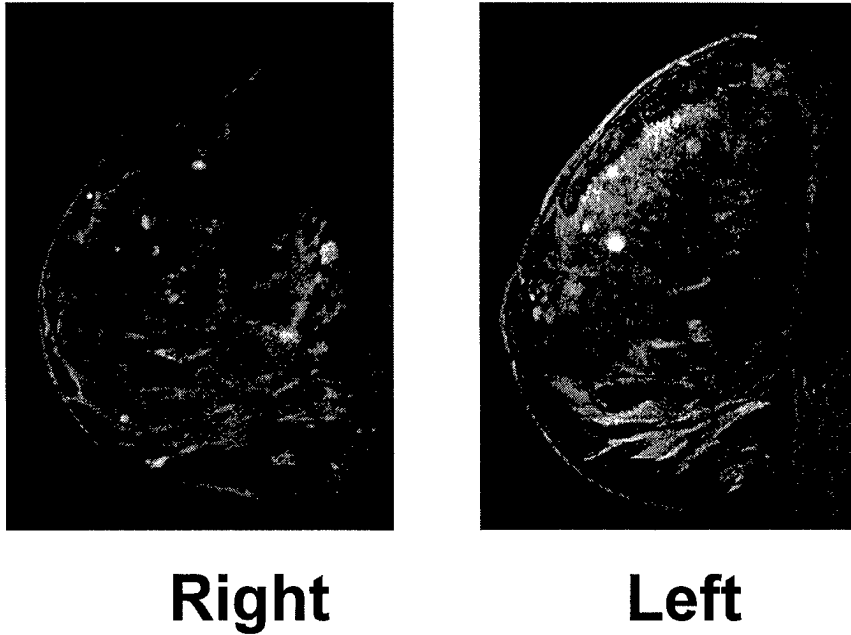
Under this protocol patients undergo MRI examinations performed on a 1.5 Tesla Signa Horizon Echo Speed (General Electric Medical Systems: Milwaukee, Wisc.). The MR examination consist of an axial localizing scan followed by a slab interleaved 3D gradient echo T1 weighted imaging sequence before and after the administration of 20 cc of intravenous gadolinium chelate. An eight-coil bilateral bi-planar array coil is utilized for this study (24,25). The coil design is illustrated below in figure 1:

Figure 1



Fat suppressed images are obtained over an 18 cm field of view using a 512 x 256 matrix and 2-3 mm slice thickness for each breast. The entire acquisition time for both breast is approximately three minutes. Two sequential acquisitions are obtained after the administration of contrast material. An example of a bilateral breast MRI examination is shown below in figure 2:

Figure 2



The high resolution MR images are interpreted as showing suspicious contrast enhancement, probably benign contrast enhancement, or no suspicious findings. Patients with probably benign contrast enhancement were followed to ensure stability. Suspicious enhancement is defined as: 1. ductal enhancement, 2. Segmental or clumped regional enhancement, or focal mass lesions greater than 5 mm without associated benign features (smooth margins, lobulated margins with internal septations).

Patients with suspicious contrast enhancement underwent short-term follow-up exam to ensure the lesion continues to enhance and continues to appear suspicious. During the time of that exam if the lesion continued to appear suspicious it was biopsied. Enhancement that was categorized as probably benign was followed to ensure stability.

## Results

**Technical Objective #1: Estimate the diagnostic yield and positive predictive value of breast MRI for the detection of cancer in a high risk population:**

One hundred and ninety four women high-risk women were screened. Of the 194 women screened, 13 were excluded from analysis. Subjects were

excluded from analysis due to technical failures (2), because of pre existing suspicious clinical or mammographic findings (9), lost to follow up after abnormal MRI (1), and due to inclusion based on a contra-lateral breast sarcoma (unusual lesion). These excluded cases were significant for demonstrating occult malignancy in several women. A case was excluded from analysis because the patient had suspicious cytology from a nipple aspirate prior to study entry. The MRI did demonstrate the cancer despite a normal mammogram. MRI detected breast cancer in a woman with breast swelling and negative mammogram. Another patient excluded from analysis was entered on the basis of a contra-lateral breast sarcoma. This is an unusual lesion and its inclusion would detract from the generalizability of the results. The MRI was significant in this patient in that it demonstrated an occult sarcoma in the contra-lateral breast. The remaining 181 women had no mammogram or clinical finding that was felt to be actionable at study entry. They constitute the cohort that will be analyzed.

The 181 women had a total of 342 exams. A table of the number of technically acceptable studies at each screening interval is included below in table 1

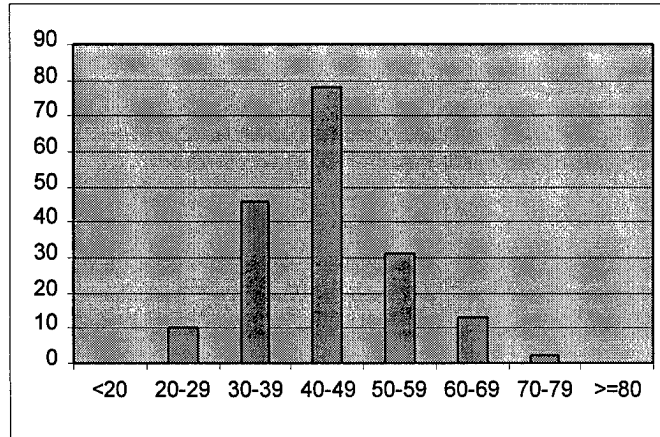
**Table 1**

	<i>Initial Study</i>	<i>1 year f/u</i>	<i>2year f/u</i>	<i>3 year f/u</i>	<i>4 year f/u</i>	<i>5 year f/u</i>
<i># of women</i>	180*	63	39	36	17	6

\* In 1 women the initial examination was technically inadequate and the subject elected not to repeat the study. She did have follow up scans in subsequent years.

The average age of the study population was 44+/-10 years. The age distribution of the population is shown in figure 3.

**Figure 3**



The risk criteria for entry are shown in table 2 below:

**Table 2**

<i>Risk Criteria for Entry</i>	<i>*Family/Personal History</i>	<i>Contralateral Breast CA</i>	<i>Mutation Carrier</i>	<i>LCIS</i>	<i>Chest Wall Irradiation</i>
<i># of Subjects</i>	107	26	21	25	2
<i>% of population</i>	59	15	11	14	1

\* This category includes women with unknown mutation status and women known to be negative for mutations in BRCA1 and BRCA2 but with significant family history.

There were a total of 52 abnormal MRI scans that lead to further evaluation by follow up or by biopsy. The initial scan was more likely to be interpreted as abnormal (36/180=20%) than the interval screens (16/162=10%). Approximately 40% (21/52) of the MRI abnormalities required no further action after follow up study. In many cases the abnormality resolved on follow up (16

cases). In others it was demonstrated to be stable (3). In 1 patient no follow up was performed due to patient preference and in another the follow up is still pending. The other 31/52 (60%) went on to biopsy. The likelihood of a scan leading to a biopsy was 21/180 (12%) for an initial screen and 10/162 (6%) on follow up screens.

The 5 types of procedures used to biopsy MRI findings are shown below:

**Table 3**

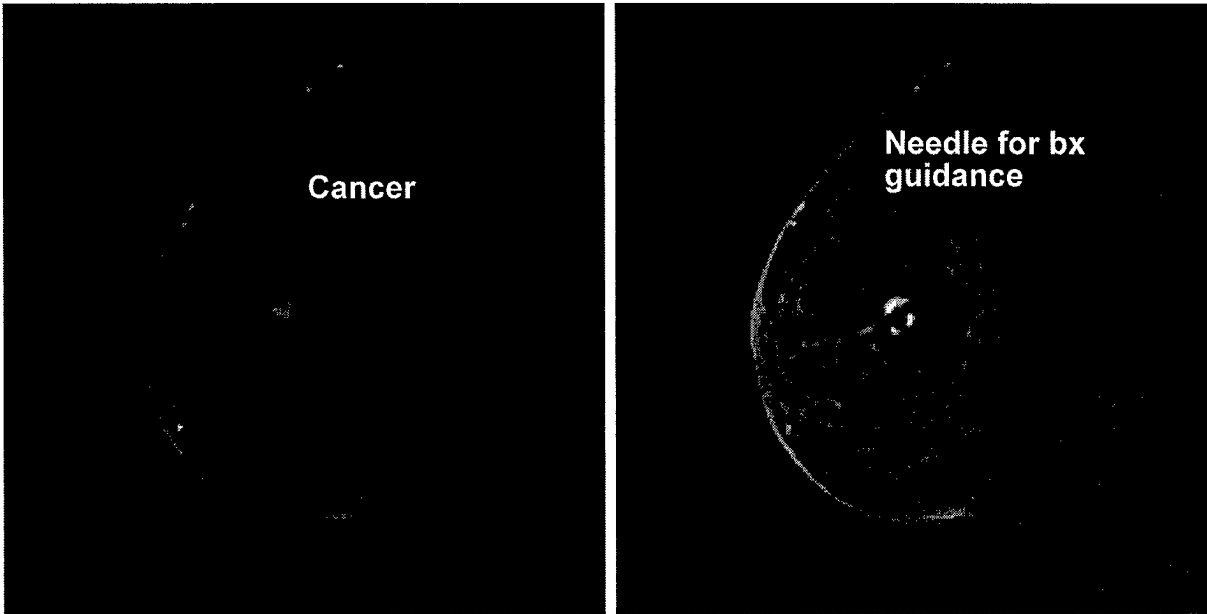
<i>Procedure</i>	<i>MRI core</i>	<i>MRI needle Localization</i>	<i>*Ultrasound Core</i>	<i>*Ultrasound Needle Localization</i>	<i>*Stereo Core</i>
<i># of procedures</i>	11	14	4	1	1

\*Ultrasound was used to guide biopsy if the MRI abnormality was visible on a directed ultrasound. In 1 case Stereo was used to the fact that calcification was seen in the area of MRI abnormality in retrospect.

In addition to MRI abnormalities, 6 patients developed mammogram abnormalities while on study. These included 3 probably benign findings that were followed (none progressed to bx) and 3 suspicious abnormalities that underwent biopsy. The 3 mammogram prompted biopsies yielded 1 cancer (DCIS) and 2 benign lesions. The patients with the mammogram prompted biopsy that resulted in a malignancy, had enhancement on the MRI that was identified but not considered suspicious enough to pursue.

Of the 31 biopsies prompted by MRI detected abnormalities, 6 demonstrated cancer, 2 resulted in LCIS and 3 in atypical ductal hyperplasia. The remaining biopsies resulted in other benign diagnoses including papiloma, fibroadenoma, and other benign findings. An example of an MRI demonstrating an occult cancer is shown in figure 4 below:

Figure 4



Over the entire screening interval there were 7 cancers detected. These include 5 detected only by MRI, 1 detected by MRI and mammography but felt to be probably benign on mammography and 1 detected by mammography and not felt to be suspicious by MRI. The total yield of the combined MRI/Mammogram screening intervention was 7/181 (3.8%). If mammography had been performed alone and we assume that the probably benign lesion would have progressed to a point that it would have been biopsied the yield for mammography alone would be 2/181 (1%). If MRI were performed alone the yield of the screening intervention would have been 6/181 (3.3%).

The MRI detected cancers were detected at a higher rate in the initial screen ( $4/180=2.2\%$ ) than in the follow up scans ( $2/162=1.2\%$ ). The MRI detected cancers were found in a single woman with a known mutation, in 4 women with positive family histories and in one woman with a history of LCIS. The mammogram detected cancer was seen in a woman with a known mutation. The yields in each of these populations is listed below in table 4:

**Table 4**

<i>Risk factor</i>	<i>Known Mutation</i>	<i>Family History</i>	<i>LCIS</i>	<i>Contra-lateral breast cancer</i>	<i>Chest wall irradiation</i>
<i>MRI yield</i>	4.7%	3.7%	4%	0	0
<i>Total Yield</i>	9.4%	3.7%	4%	0	0

**Technical Objective #2: Compare the diagnostic yield and positive predictive value of MRI to mammography and clinical examination:**

The patient population studied under this protocol is a heavily prescreened population and therefore patients with suspicious mammogram abnormalities were treated for those findings and not entered into this study. As indicated above 3 women were identified as developing suspicious mammogram findings while on study and underwent biopsy. The resultant biopsies were benign in 2 cases and in situ cancer in 1. Enhancement was observed at MRI on the single case of mammogram detected DCIS, however It was not felt to be suspicious. There were 6 cancers detected by MRI, 5 of which were occult to mammography. The yield of the MRI screening intervention for this population is 3.3% while that for mammography alone was 1%. Although a larger study is needed to generate statistical significance, it appears that MRI will have a larger cancer yield than mammography and clinical breast examination.

The results above are biased in favor of MRI, since the study designed excluded women with suspicious mammography or clinical findings at study entry. If we only consider both the mammography and MRI studies done as yearly follow-up studies (this creates a population prescreened by MRI and mammography), the mammogram yield would be  $1/162=0.6\%$  while the MRI yield would be  $2/162=1.2\%$  of the screens. Thus the MRI yield appears higher even when considering only follow up screens. This again needs to be confirmed on larger populations.

The positive predictive value of biopsy prompted by MRI findings (For malignancy) was  $6/31=19\%$ . This is consistent with the range of reported biopsy yields expected with traditional mammogram screening. The positive predictive value of biopsy prompted by mammogram abnormalities in this population was  $1/3=33\%$ .

**Technical Objective #3: Estimate the incidence of detecting interval breast cancers by MRI:**

The yield of detecting Interval breast cancer by MRI Is estimated to be  $2/162=1.2\%$ . This is approximately half of the yield of the initial screen ( $4/180=2.2\%$ )

**Technical Objective #4: Determine the interval change in lesions that do not meet the biopsy threshold.**

There were 52 examinations that were interpreted as requiring follow up or biopsy. There were 35 of the 52 cases that were immediately scheduled for biopsy. Four of the 35 abnormalities resolved at the time of the biopsy scan and biopsy was avoided. There were 17 cases In which longer term follow up was recommended for lesions felt to be likely benign. In 12 cases the finding resolved (no enhancement visible) on follow up intervals that varied from of 3-24 months. In 3 cases the lesion was stable on follow up intervals that varied 6-36 months. One patient was lost to follow up and 1 follow up is still pending.

**Key Research Accomplishments:**

**Presentations:**

- 1. M. Schnall. MRI based Screen for Patients at High Risk for Breast Cancer, Abstract presented at the Era of Hope meeting In Atlanta GA, June 9, 2000
- 2. L. Lo, M. Rosen, M. Schnall, S. Orel, E. Cruz, B. Weber. Pilot Study of Breast MR Screening of a High Risk Cohort, Accepted for presentation at the 2001 meeting of the Radiological Society of North America

**Publications:**

- The information included in this progress report form the basis for a manuscript that will be submitted for publication. It is anticipated that this will be submitted in 1-2 months.

**Stimulation of other research:**

- Established protocol for screening high risk patients with MRI. This protocol has been used as the template for other high risk screening trials including a multicenter pilot trial Funded by the National Cancer Institute (U01-CA74680: Protocol 6884), a trial funded by the National Research Counsel in the United Kingdom and a trial organized by the University of Toronto. These groups have collaborated closely under the umbrella of the International working group in breast MRI to organize an

international database to collect data from screening trials around the world in an effort to accelerate our the process of evaluating MRI as a high risk screening examination.

**Reportable Outcomes:**

1. Detected breast cancer that was occult to conventional screening in 5 women.
2. Database of 342 MRI screening examinations.
3. Multicenter High Risk screening pilot study funded by NCI (UO1-CA74680, protocol 6884)
4. Important component toward developing an international MRI screening database.

**Conclusion**

We have successfully performed an MR screening study on 181 patients at high risk for breast cancer that did not have an actionable mammogram or clinical finding prior to study entry. Abnormal MRI findings prompted a total of 31 biopsies, 6 of which yielded malignant findings. The cancer yield of the MRI screen was 3.3% of the women, and 1.8% of the exams (2.2% for the Initial screens and 1.1% of the follow up screens). The false negative rate of MRI with a variable follow up was 1/7 (14%), while the false negative rate of mammography for the same population was 5/7 (71%). Although the data needs to be confirmed with larger studies, this data suggests that MRI may be a valuable tool for screening women at high risk for breast cancer.

**Personnel funded from this project:**

Mitchell Schnall, M.D., Ph.D.: PI (Radiologist)  
Susan Orel, M.D.: CI (Radiologist)  
Barbara Weber, M.D.: CI (Oncologist)  
Timothy Rebbick, Ph.D.: CI (Biostatistics)  
Carol Reynolds, M.D.: CI (Pathologist)  
Theresa Ward/Colligan: Tech  
William D'Arcy: Buisness administrator  
John Tomaszewski, M.D.: CI (Pathologist)  
Jean McDermott, R.N.: Research coordinator

## References:

1. National Cancer Institute Surveillance, Epidemiology, and End Results Program, 1995-1997
2. National Institutes of Health Consensus Development Conference Statement: Treatment of Early Breast Cancer. (June 18-21, 1990) Bethesda, MD.
3. Lynch HT: Introduction to Breast Cancer Genetics. In Lynch, HT (ed): Genetics and Breast Cancer, pp1-13. New York, Van Nostrand Reinhold.
4. Broca P. Traite de tumeurs. Paris: Asselin; 1866.
5. Claus EB, Risch N, Thompson WD. Genetic analysis of breast cancer in the cancer and steroid hormone study. *Am J Hum Genet* 1991; 48:232-242.
6. Narod SA, Feuteun J, Lynch HT, et al. Familial breast-ovarian cancer locus on chromosome 17q12-23. *The Lancet* 1991; 338:82-83.
7. Easton DF, Bishop DT, Ford D, Crockford GP and the Breast Cancer Linkage Consortium. Genetic linkage analysis in familial breast and ovarian cancer - results from 214 families. *Am J Hum Genet* 1993; 52(4):678-701.
8. Easton DF, Ford D, Bishop DT and the Breast Cancer Linkage Consortium. Breast and ovarian cancer incidence in BRCA1 mutation carriers. *Lancet* 1994; 343(8899):692-695.
9. Sattin RW, Rubin GL, Webster LA, et al. Family history and the risk of Breast cancer. *JAMA* 253 1985; (13):1908-1913.
10. Colditz GA, Willett WC, Hunter DJ, et al. Family history, age and risk of breast cancer. *JAMA* 1993; 270:338-343.
11. Stratton MR, Ford D, Neuhausen S, et al. Familial male breast cancer is not linked to the BRCA1 locus on chromosome 17q. *Nature Genet* 1994; 7:103.
12. Wooster R, Neuhausen S, Mangion, et al. Localization of a breast cancer susceptibility gene, BRCA2, to chromosome 13q12-13. *Science* 265:2088-2090.
13. Ottesen GL, Graversen HP, Blichert-Toft M, Zedeler K, Andersen J. A Lobular carcinoma in situ of the female breast. Short-term results of a

prospective nationwide study. The Danish Breast Cancer Cooperative Group. *Am J Surg Pathol.* 1993 Jan;17(1):14-21.

14. Fisher B, Costantino J, Redmond C, et al A Randomized Clinical Trial Evaluating Tamoxifen in the Treatment of Patients with Node-Negative Breast Cancer who have Estrogen Receptor-Positive Tumors. *NEJM* 1989; 320:479-484.

15. Fisher B, Dignam J, Bryant J et al. Five Versus more than Five Years of Tamoxifen therapy for breast cancer patients with Node-Negative Breast Cancer who have Estrogen Receptor-Positive Tumors. *J Natl. Cancer Inst.* 1996; 88: 1529-1541.

16. Slanetz PJ, Edmister WB, Weisskoff RM, Giardino AA, Talele AC, Kopans DB. Occult contralateral breast cancer detected by breast MR. *Radiology (RSNA)* 1998; 467.

17. Dunfee WR, Glastad KA, Ford KL. Preoperative magnetic resonance imaging assessment of patients at high risk for breast carcinoma: Are bilateral examinations necessary? *suppl. AJR* 1999 vol. 172, (3):150.

18. Gail MH, Brinton LA, Byar DP, Corle DK, Green SB, Schairer C, Mulvihill J. Projecting individualized probabilities of developing breast cancer for white females who are examined annually. *J Natl Cancer Inst* 1989; 81:1879-1886.

19. Hoskins Kf, et al. Assessment and counseling for women with a family history of breast cancer: A guide for clinicians. *JAMA* 1995; 273:577-585.

20. Baker LH. Breast cancer detection demonstration project: Five-year summary report. *Cancer* 1982; 32:194-225.

21. Bird RE, Wallace TW, Yankaskas BC. Analysis of cancers missed at screening mammography. *Radiology* 1992; 184:613-617.

22. Dershaw DD. The false negative mammogram. *Applied Radiology*; 1994.

23. Harms SE, Flamig DP, Hesley KL, et al. MR imaging of the breast with rotating delivery of excitation off resonance: clinical experience with pathologic correlation. *Radiology* 1993;187:493-501.

24. Greenman RL, Lenkinski RE, Schnall MD. Bilateral imaging using separate interleaved 3D volumes and dynamically switched multiple receive coil arrays. *MRM* 1998;39:108-115.

25. Insko EK, Connick TJ, and Schnall MD, Orel SG. Multicoil array for high resolution imaging of the breast. *Magnetic Resonance in Medicine* 1997;37:778-784.