

AD _____

Award Number: MIPR OGC65E0095

TITLE: Tropical Medicine Imaging Project (TMIP) Phase II

PRINCIPAL INVESTIGATOR: James G. Smirniotopoulos, M.D.

CONTRACTING ORGANIZATION: Uniformed Services University of the
Health Sciences
Bethesda, Maryland 20814

REPORT DATE: September 2001

TYPE OF REPORT: Final

PREPARED FOR: U.S. Army Medical Research and Materiel Command
Fort Detrick, Maryland 21702-5012

DISTRIBUTION STATEMENT: Approved for Public Release;
Distribution Unlimited

The views, opinions and/or findings contained in this report are those of the author(s) and should not be construed as an official Department of the Army position, policy or decision unless so designated by other documentation.

20021105 035

REPORT DOCUMENTATION PAGE

Form Approved
OMB No. 074-0188

Public reporting burden for this collection of information is estimated to average 1 hour per response, including the time for reviewing instructions, searching existing data sources, gathering and maintaining the data needed, and completing and reviewing this collection of information. Send comments regarding this burden estimate or any other aspect of this collection of information, including suggestions for reducing this burden to Washington Headquarters Services, Directorate for Information Operations and Reports, 1215 Jefferson Davis Highway, Suite 1204, Arlington, VA 22202-4302, and to the Office of Management and Budget, Paperwork Reduction Project (0704-0188), Washington, DC 20503

1. AGENCY USE ONLY (Leave blank)		2. REPORT DATE September 2001	3. REPORT TYPE AND DATES COVERED Final (1 Apr 00 - 1 Aug 01)	
4. TITLE AND SUBTITLE Tropical Medicine Imaging Project (TMIP) Phase II			5. FUNDING NUMBERS MIPR OGC65E0095	
6. AUTHOR(S) James G. Smirniotopoulos, M.D.				
7. PERFORMING ORGANIZATION NAME(S) AND ADDRESS(ES) Uniformed Services University of the Health Sciences Bethesda, Maryland 20814 E-Mail: jsmirnio@rad.usuhs.mil			8. PERFORMING ORGANIZATION REPORT NUMBER	
9. SPONSORING / MONITORING AGENCY NAME(S) AND ADDRESS(ES) U.S. Army Medical Research and Materiel Command Fort Detrick, Maryland 21702-5012			10. SPONSORING / MONITORING AGENCY REPORT NUMBER	
11. SUPPLEMENTARY NOTES				
12a. DISTRIBUTION / AVAILABILITY STATEMENT Approved for Public Release; Distribution Unlimited			12b. DISTRIBUTION CODE	
13. ABSTRACT (Maximum 200 Words) The objective of this Tropical Medicine Central Resource (TMCR) is to create a global resource for health care providers on Tropical Medicine, with emphasis on the radiology of tropical diseases. This resource would be available on CD-ROM, but would be more universally available over the Internet. By having such a resource available, it will be much more likely that appropriate diagnoses will be made in a timely fashion with corresponding definitive treatment. This will result in decreased morbidity and mortality in both civilian and military populations, and a tremendous cost saving from deferred medical transports and decreased treatment time. Implementation of the project will happen in various phases: <ol style="list-style-type: none"> a. Gleaning optimal images and information for the various diseases (performed by subject matter experts) b. Digitizing approved images/photographs c. Inserting images and text into an electronic format d. Connecting images/text into a database-driven search/retrieve engine e. Displaying information over the internet and reproducing information on CD-ROM Deliverables listed on original SOW: <ol style="list-style-type: none"> 1. Produce a working demonstration "Tropical Medicine Website" from a subset of archived collection of images. 2. Produce a Tropical Medicine CD-ROM" from a subset of the archived collection of images. 				
14. SUBJECT TERMS Tropical, medicine, radiology, imaging, CT, MR, Computed Tomography, Magnetic Resonance, X-Rays, bacteria, virus, fungi, tuberculosis, parasite, worms			15. NUMBER OF PAGES 33	
			16. PRICE CODE	
17. SECURITY CLASSIFICATION OF REPORT Unclassified	18. SECURITY CLASSIFICATION OF THIS PAGE Unclassified	19. SECURITY CLASSIFICATION OF ABSTRACT Unclassified	20. LIMITATION OF ABSTRACT Unlimited	

Table of Contents

Cover.....	1
SF 298.....	2
Table of Contents.....	3
Metrics Used to Demonstrate Success/Efficacy.....	5
Final Results.....	6
Problems Encountered.....	7
Potential For AMEDD-Wide Adoption.....	8
Conclusions.....	9
Appendices.....	10-33

Tropical Medicine Central Resource


PI: James G. Smirniotopoulos, M.D./Maurice Reeder, M.D.

Location: USU

Funding:

Project Description:

Create distance learning materials for teaching the Imaging of Tropical Diseases using a website and a CDROM.




FY00 MEDCOM Telemedicine Program Final Presentation

Tropical Medicine Central Resource

Metrics Used to Demonstrate Success/Efficacy:

User Feedback regarding different modes of presentation of materials.
(Not yet implemented due to Copyright restrictions on content through
December 2001.



Tropical Medicine Central Resource

Final Results:

XXXXX images scanned

YYYYY webpages created

Demonstration CDROM created




FY00 MEDCOM Telemedicine Program Final Presentation

Tropical Medicine Central Resource

Problems Encountered:


Evolving DoD regulations for *.mil Websites
Requirement for Website Access under ADA
Requirement to satisfy Publisher's copyright ownership
Original radiographs not available for all illustrations
Insufficient resources for all three phases of project:

Physical Archive
Digitization of Text and Images
Creation of Linked Webpages



Tropical Medicine Central Resource

Potential for AMEDD-Wide Adoption:
Distance Learning programs of DoD benefit from TMCR content.
Potential for “Learning Theory” Experiments utilizing various methodologies to deliver similar content

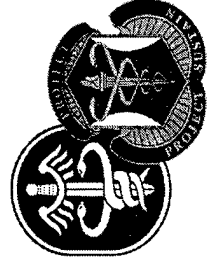


Tropical Medicine Central Resource

Conclusions:

Instantaneous access to imaging studies from an encyclopedic library of pathologically proven tropical disease offers the potential to:


- 1) Improve knowledge of Healthcare practitioners at all levels
- 2) TMCR can function as a comparative Atlas of Disease Imaging
- 3) Wide distributionn of content possible via Web and CDROM



Tropical Medicine Central Resource



James G. Siniotiopoulos, M.D.
Maurice Reeder, M.D.
Location: USUHS Bethesda, MD
Funding: MDA 90-F-39-C-0002

Project Description:
The project is a telemedicine program that provides
CDR(M)





FY00 MEDCOM Telemedicine Program Final Presentation

Tropical Medicine Central Resource





FY00 MEDCOM Telemedicine Program Final Presentation

Tropical Medicine Central Resource




FY00 MEDCOM Telemedicine Program Final Presentation

Tropical Medicine Central Resource




FY00 MEDCOM Telemedicine Program Final Presentation

Tropical Medicine Central Resource





FY00 MEDCOM Telemedicine Program Final Presentation



Tropical Medicine

International Registry of Tropical Imaging

The International Registry of Tropical Imaging serves as a worldwide archiving and retrieval source for imaging studies involved in the diagnosis of over 60 parasitic and infectious, neoplastic and miscellaneous diseases affecting over 2 billion people in the tropical and subtropical regions of the globe.



This is a project of the Radiology Department of
the Uniformed Services University.

Submit Cases

A PROJECT SPONSORED BY USAMRMC

HOME USAMRMC USUHS WEBMASTER USU RADIOLOGY

ABOUT TMCR

TMCR DISEASES

TMCR MISSION

TMCR STAFF

TMCR GUESTBOOK


TMCR FEEDBACK

USAMRMC

USU RADIOLOGY

4301 Jones Bridge Road
Bethesda, MD 20814

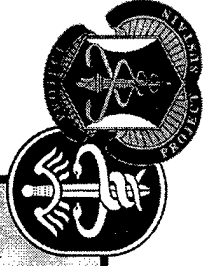

301-295-3145



Tropical Medicine Central Resource

Home | About TMCRC | Index of Diseases | TMCRC Mission | TMCRC Staff | TMCRC Guestbook

- Parasitic Diseases
 - Major Multi-System Diseases
 - Amebiasis
 - Chagas Disease**
 - Introduction
 - Geographical Distribution
 - Epidemiology and Pathology
 - Laboratory Diagnosis
 - Clinical Diagnosis
 - Imaging Diagnosis
 - Differential Diagnosis
 - References
 - Hydatid Disease
 - Schistosomiasis
 - Paragonimiasis
 - Taeniasis
- Gastrointestinal and Abdominal Diseases
 - Predominantly Small Bowel Diseases
 - Predominantly Colon Disease
 - Liver
 - Soft Tissue Diseases
 - Miscellaneous Diseases



Tropical Medicine Central Resource

Home | About TMR | Index of Diseases | TMR Mission | TMR Staff | TMR Guestbook

- Parasitic Diseases
- Major Multi-System Diseases
 - Amebiasis
 - Chagas Disease
- Introduction
- Geographical Distribution
- Epidemiology and Pathogenesis
- Laboratory Diagnosis
- Clinical Diagnosis
- Imaging Diagnosis
- Differential Diagnosis
- References
- Hydatid Disease
- Schistosomiasis
- Paragonimiasis
- Taeniasis
- Gastrointestinal and Abdominal Diseases
 - Predominantly Small Bowel
 - Predominantly Colon Disease
- Liver
- Soft Tissue Diseases
- Miscellaneous Diseases

Tropical Medicine Central Resource

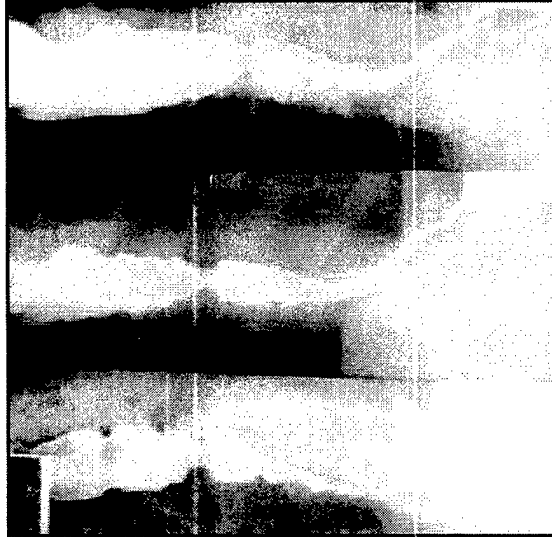

Home | About TMR | Index of Diseases | TMR Mission | TMR Staff | TMR Guestbook

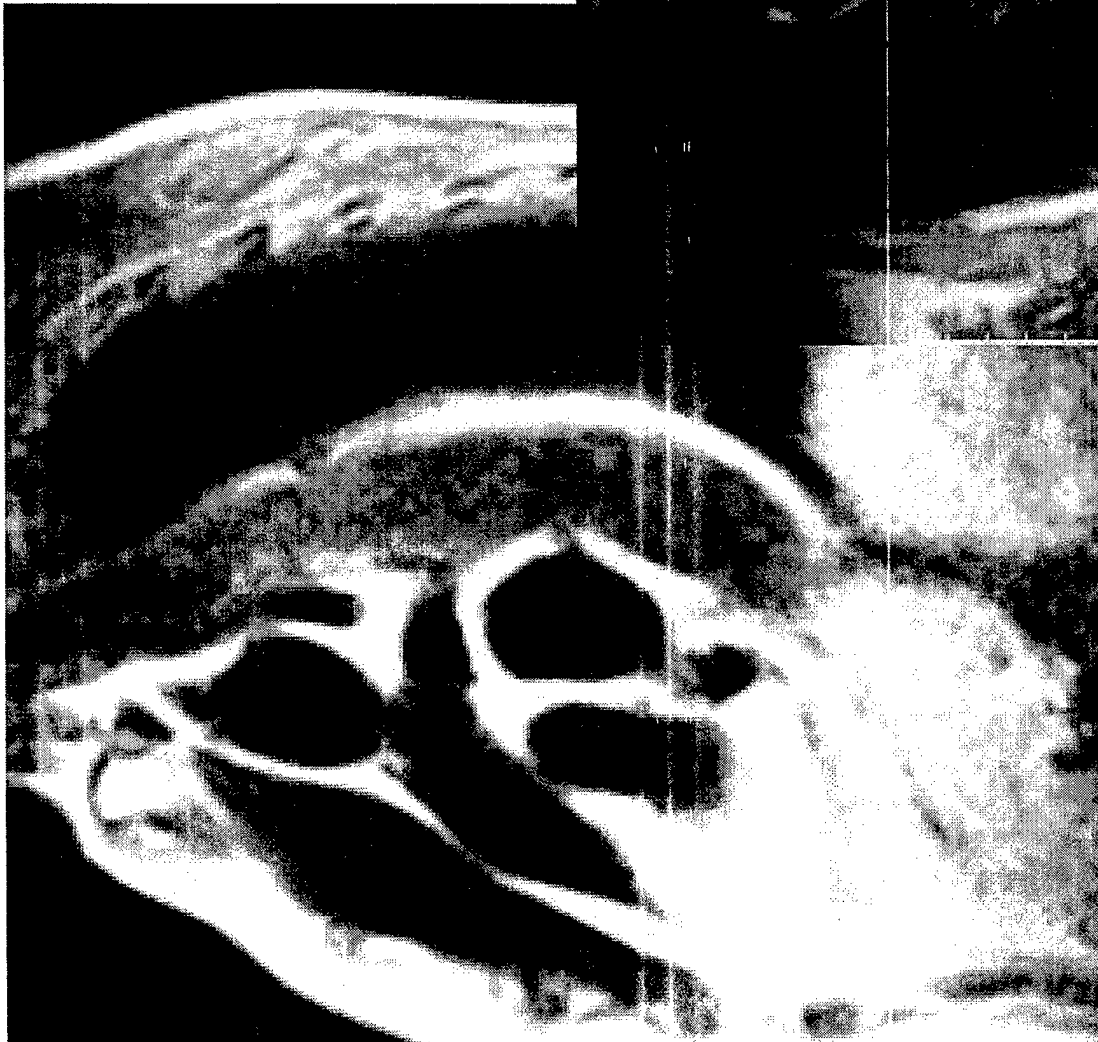
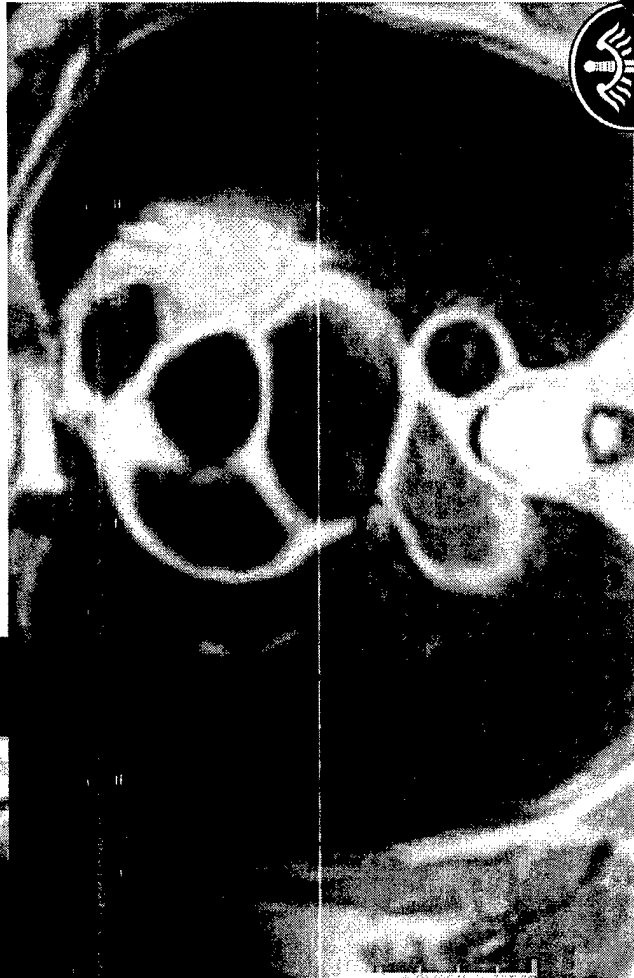
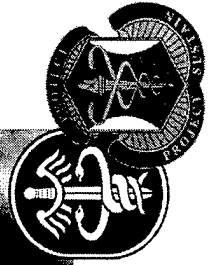


Esophagus



In the esophagus, early changes of motor dysfunction are hypercontractility and increased tone and hypertrophy of the circular muscle layer, often resulting in dysphagia. Later, as denervation progresses, there is decompensation, dilatation and stasis. Food may become lodged in the esophagus and cause local irritation, leading to inflammation, ulceration, bleeding, perforation and fistulas.

The earliest roentgen manifestations of Chagas' disease in the esophagus are of motor dysfunction. Initially, tone is maintained and there is little or no dilatation. Gradually increasing disturbances in tone, rhythm and motility over a number of years give the appearance of bizarre, dysrhythmic contractions on barium swallow (Fig. 4.8). In severe infections, however, there may be an extremely dilated and flaccid esophagus with a transverse diameter of 7 cm or more, exhibiting marked loss of tone with weak, uncoordinated contractions. The appearance of advanced megaesophagus both on plain radiographs of the chest and on barium swallow is remarkably similar to achalasia. In both entities the dilated esophagus appears as a vertical density along the entire right paramediastinal border on frontal films, usually distended with air and sometimes with an air-fluid level if the patient has recently ingested liquids (Figs. 4.9, 4.10, 4.11, 4.12). A tapered distal esophageal segment down to the cardiac sphincter is seen in Chagas' megaesophagus similar to that seen in achalasia. There may be some delay in passage of food through this area because of failure of relaxation and motor incoordination at the level of the sphincter as well as lack of propulsive peristalsis through the esophagus.





Tropical Medicine Central Resource




FY00 MEDCOM Telemedicine Program Final Presentation

Tropical Medicine Central Resource

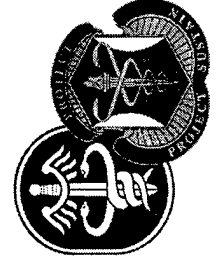

James G. Smirniotopoulos, M.D.
Maurice Reade, M.D.
Location: USLHS, Bethesda, MD
Funding: W71401-99-C-0002

CDROM
CDROM
CDROM



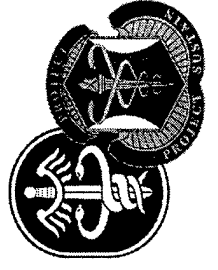

FY00 MEDCOM Telemedicine Program Final Presentation

Tropical Medicine Central Resource





FY00 MEDCOM Telemedicine Program Final Presentation

Tropical Medicine Central Resource




FY00 MEDCOM Telemedicine Program Final Presentation

Tropical Medicine Central Resource




FY00 MEDCOM Telemedicine Program Final Presentation

Tropical Medicine Central Resource




FY00 MEDCOM Telemedicine Program Final Presentation



Tropical Medicine

International Registry of Tropical Imaging

The International Registry of Tropical Imaging serves as a worldwide archiving and retrieval source for imaging studies involved in the diagnosis of over 60 parasitic and infectious, neoplastic and miscellaneous diseases affecting over 2 billion people in the tropical and subtropical regions of the globe.



This is a project of the Radiology Department of the Uniformed Services University.

Submit Cases

A PROJECT SPONSORED BY USAMRMC

HOME USAMRMC USUHS WEBMASTER USU RADIOLOGY

ABOUT TMCR

TMCR DISEASES

TMCR MISSION

TMCR STAFF

TMCR GUESTBOOK


TMCR FEEDBACK

USAMRMC

USU RADIOLOGY

4301 Jones Bridge Road
Bethesda, MD 20814

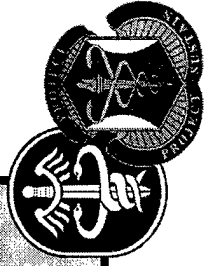
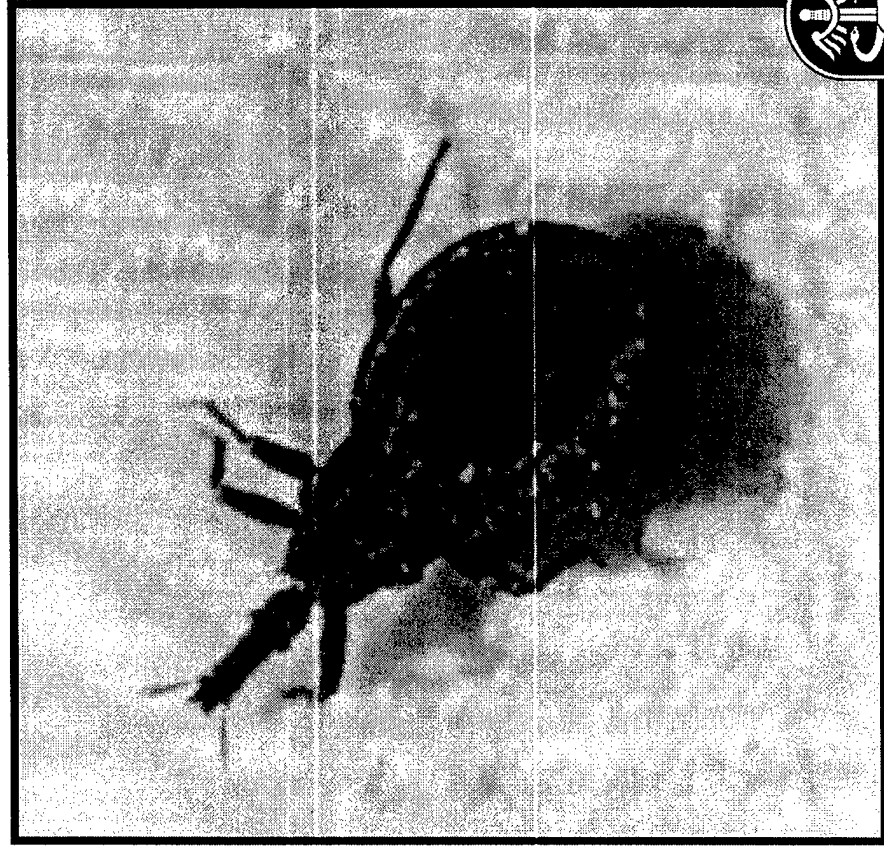
301-295-3145



Tropical Medicine Central Resource

Home | About TMCRC | Index of Diseases | TMCRC Mission | TMCRC Staff | TMCRC Guestbook

- Parasitic Diseases
 - Major Multi-System Diseases
 - Amebiasis
 - Chagas Disease**
 - Introduction
 - Geographical Distribution
 - Epidemiology and Pathology
 - Laboratory Diagnosis
 - Clinical Diagnosis
 - Imaging Diagnosis
 - Differential Diagnosis
 - References
 - Hydatid Disease
 - Schistosomiasis
 - Paragonimiasis
 - Taeniasis
 - Gastrointestinal and Abdominal Diseases
 - Predominantly Small Bowel Diseases
 - Predominantly Colon Disease
 - Liver
 - Soft Tissue Diseases
 - Miscellaneous Diseases



Tropical Medicine Central Resource

Home | About TCMR | Index of Diseases | TCMR Mission | TCMR Staff | TCMR Guestbook

- Parasitic Diseases
- Major Multi-System Diseases
 - Amebiasis
 - Chagas Disease**
 - Introduction
 - Geographical Distribution
 - Epidemiology and Pathogenesis
 - Laboratory Diagnosis
 - Clinical Diagnosis
 - Imaging Diagnosis
 - Differential Diagnosis
 - References
- Hydatid Disease
- Schistosomiasis
- Paragonimiasis
- Taeniasis
- Gastrointestinal and Abdominal Diseases
 - Predominantly Small Bowel
 - Predominantly Colon Disease
 - Liver
 - Soft Tissue Diseases
 - Miscellaneous Diseases

Tropical Medicine Central Resource

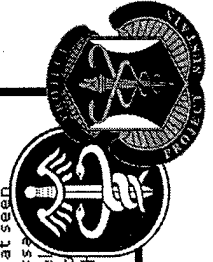

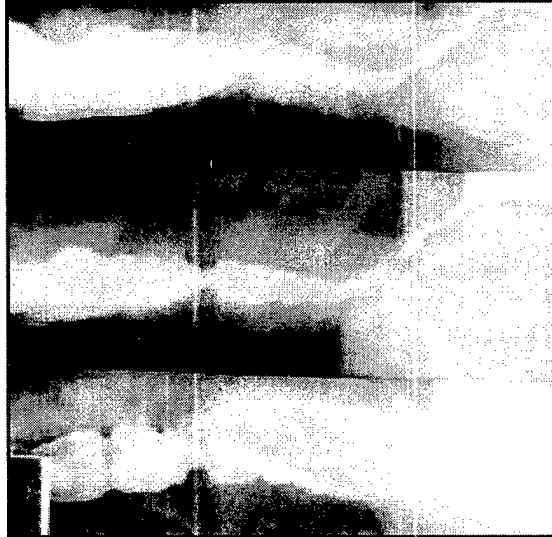
Home | About TCMR | Index of Diseases | TCMR Mission | TCMR Staff | TCMR Guestbook

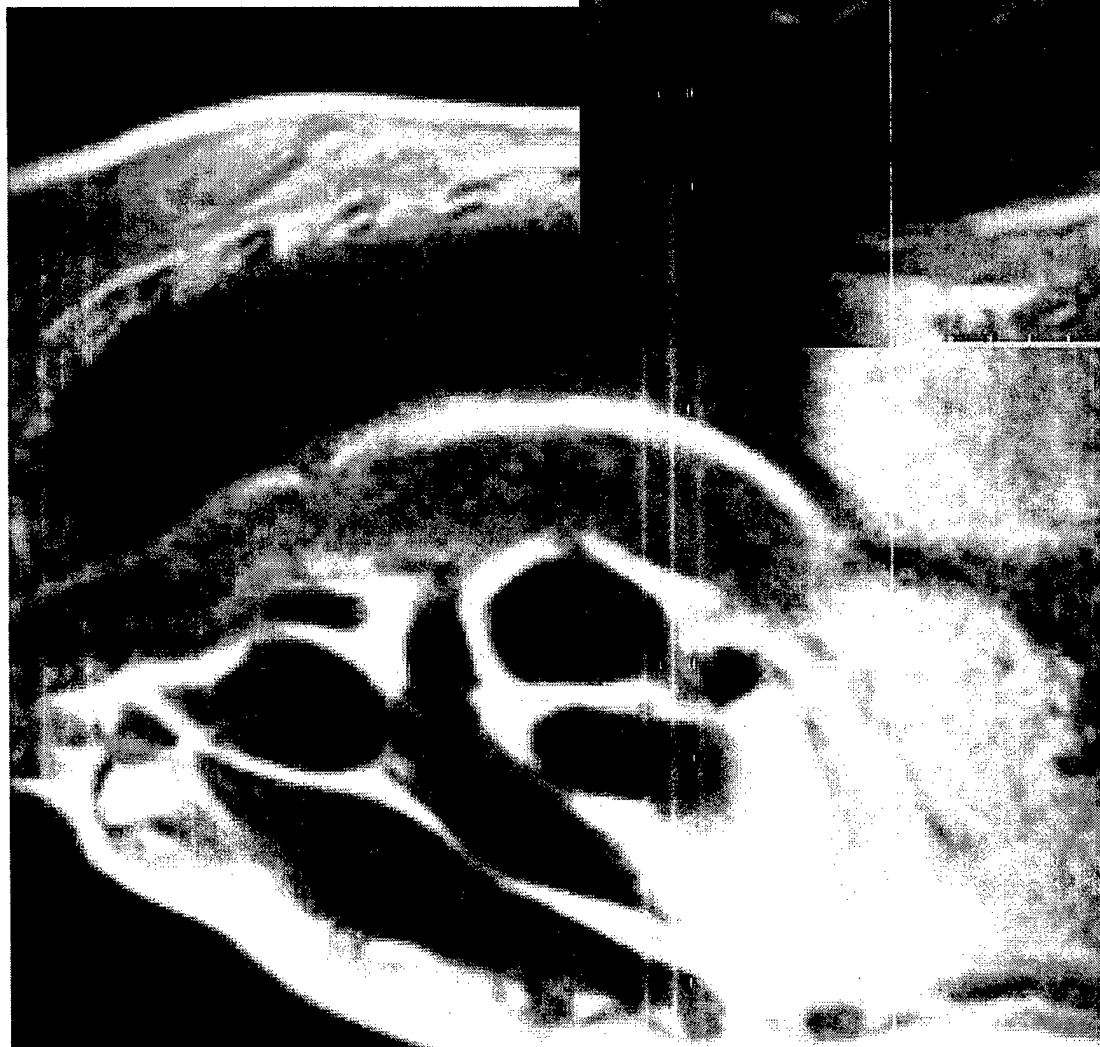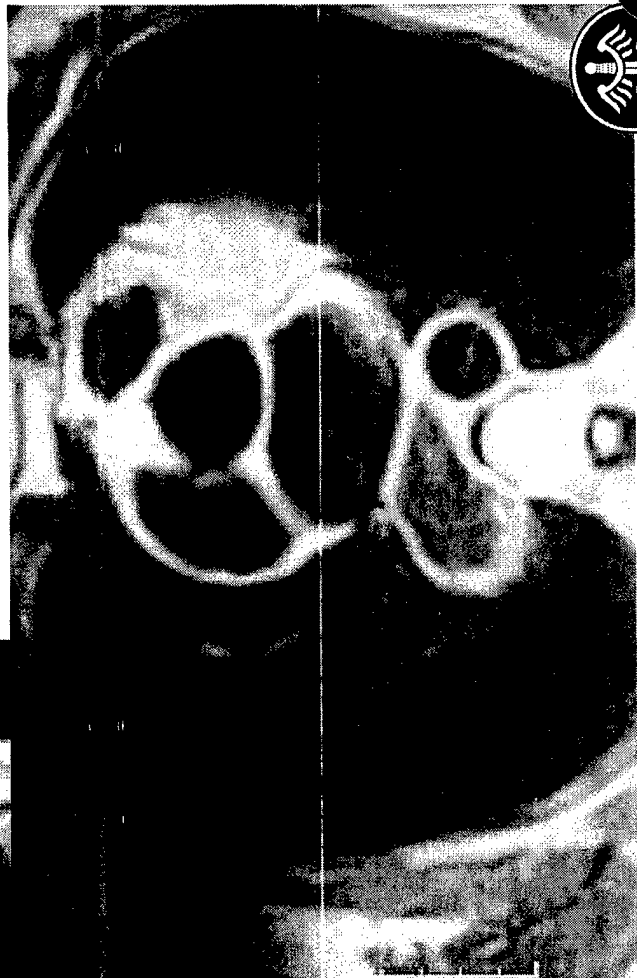



Esophagus



In the esophagus, early changes of motor dysfunction are hypercontractility and increased tone and hypertrophy of the circular muscle layer, often resulting in dysphagia. Later, as denervation progresses, there is decompensation, dilatation and stasis. Food may become lodged in the esophagus and cause local irritation, leading to inflammation, ulceration, bleeding, perforation and fistulas.

The earliest roentgen manifestations of Chagas' disease in the esophagus are of motor dysfunction. Initially, tone is maintained and there is little or no dilatation. Gradually increasing disturbances in tone, rhythm and motility over a number of years give the appearance of bizarre, dysrhythmic contractions on barium swallow (Fig. 4.8). In severe infections, however, there may be an extremely dilated and flaccid esophagus with a transverse diameter of 7 cm or more, exhibiting marked loss of tone with weak, uncoordinated contractions. The appearance of advanced megaesophagus both on plain radiographs of the chest and on barium swallow is remarkably similar to achalasia. In both entities the dilated esophagus appears as a vertical density along the entire right paramediastinal border on frontal films, usually distended with air and sometimes with an air-fluid level if the patient has recently ingested liquids (Figs. 4.9, 4.10, 4.11, 4.12). A tapered distal esophageal segment down to the cardiac sphincter is seen in Chagas' megaesophagus similar to that seen in achalasia. There may be some delay in passage of food through this area because of failure of relaxation and motor incoordination at the level of the sphincter as well as lack of propulsive peristalsis through esophagus.





Tropical Medicine Central Resource



FY00 MEDCOM Telemedicine Program Final Presentation

Chapters	Name of Chapters	Chapters Belong To:
Chapter 1	Amebiasis	Reeder
Chapter 2	Schistosomiasis	Palmer
Chapter 3	Hydatid Disease	Reeder
Chapter 4	Chagas Disease	Reeder
Chapter 5	Tuberculosis	Palmer
Chapter 6	The Mycosis	Palmer
Chapter 7	Taeniasis, Cysticercosis	Reeder
Chapter 8	AIDS	Reeder
Chapter 9	Giardiasis	Reeder
Chapter 10	Ascariasis	Reeder
Chapter 11	Anisakiasis	Reeder
Chapter 12	Ancylostomiasis	Reeder
Chapter 13	Strongyloidiasis	Reeder
Chapter 14	Capillariasis	Reeder
Chapter 15	Typhoid and Paratyphoid	Reeder
Chapter 16	Tropical Sprue	Reeder
Chapter 17	Trichuriasis	Reeder
Chapter 18	Helminthoma	Palmer
Chapter 19	Shigellosis	Palmer
Chapter 20	Lymphogranuloma	Reeder
Chapter 21	Clonorchiasis	Reeder
Chapter 22	Paragonimiasis	Reeder
Chapter 23	Melioidosis	Reeder
Chapter 24	Plague	Reeder
Chapter 25	Cardiac Disease	Palmer
Chapter 26	Filariasis	Palmer
Chapter 27	Dracunculiasis	Reeder
Chapter 28	Pentastomiasis	Palmer
Chapter 29	Tumoral Calcinosi	Palmer
Chapter 30	Tropical Pyomyositis	Palmer
Chapter 31	The Hemoglobinopathies	Reeder
Chapter 32	Brucellosis	Palmer
Chapter 33	Tetanus	Palmer
Chapter 34	Leprosy	Palmer

Chapter 35	Yaws	Palmer
Chapter 36	Tropical Ulcer	Palmer
Chapter 37	Ainhum	Reeder
Chapter 38	Scleroma	Reeder
Chapter 39	Noma	Reeder
Chapter 40	Small Pox	Palmer
Chapter 41	Burkitts Lymphoma	Palmer
Chapter 42	Kaposi Sarcoma	Reeder
Chapter 43	Malignant Neoplastic Diseases	Palmer
Chapter 44	NonMalignant Neoplastic Diseases	Palmer
Chapter 45	Toxoplasmosis	Palmer
Chapter 46	Fevers	Palmer

Chapters	Approximate Number of Images Scanned	Images Belong To:
Chapter 1	316	Reeder
Chapter 2	235	Palmers
Chapter 3	463	Reeder
Chapter 4	81	Reeder
Chapter 5	0	Palmers
Chapter 6	0	Palmers
Chapter 7	138	Reeder
Chapter 8	106	Reeder
Chapter 9	17	Reeder
Chapter 10	79	Reeder
Chapter 11	15	Reeder
Chapter 12	30	Reeder
Chapter 13	60	Reeder
Chapter 14	19	Reeder
Chapter 15	19	Reeder
Chapter 16	0	Reeder
Chapter 17	25	Reeder
Chapter 18	9	Reeder
Chapter 19	7	Palmers
Chapter 20	14	Reeder
Chapter 21	47	Reeder
Chapter 22	87	Reeder
Chapter 23	78	Reeder
Chapter 24	22	Reeder
Chapter 25	84	Palmers
Chapter 26	48	Palmers
Chapter 27	48	Reeder
Chapter 28	15	Palmers
Chapter 29	74	Palmers
Chapter 30	17	Palmers
Chapter 31	90	Reeder
Chapter 32	22	Palmers
Chapter 33	12	Palmers
Chapter 34	93	Palmers

Not Ready for Scanning
Not Ready for Scanning

Not back from Publisher

Chapter 35	60	Palmers	
Chapter 36	29	Palmers	
Chapter 37	24	Reeder	
Chapter 38	12	Reeder	
Chapter 39	9	Reeder	
Chapter 40	32	Palmers	
Chapter 41	54	Palmers	
Chapter 42	76	Reeder	
Chapter 43	72	Palmers	
Chapter 44	135	Palmers	
Chapter 45	26	Palmers	
Chapter 46	23	Palmers	
Total	2922		