

AD _____

Award Number: DAMD17-00-1-0176

TITLE: The Role of Myoepithelial Maspin in Breast Carcinoma
Progression, Diagnosis and Screening

PRINCIPAL INVESTIGATOR: Sanford H. Barsky, M.D.

CONTRACTING ORGANIZATION: University of California, Los Angeles
Los Angeles, California 90095-1406

REPORT DATE: August 2002

TYPE OF REPORT: Annual

PREPARED FOR: U.S. Army Medical Research and Materiel Command
Fort Detrick, Maryland 21702-5012

DISTRIBUTION STATEMENT: Approved for Public Release;
Distribution Unlimited

The views, opinions and/or findings contained in this report are those of the author(s) and should not be construed as an official Department of the Army position, policy or decision unless so designated by other documentation.

REPORT DOCUMENTATION PAGE

Form Approved
OMB No. 074-0188

Public reporting burden for this collection of information is estimated to average 1 hour per response, including the time for reviewing instructions, searching existing data sources, gathering and maintaining the data needed, and completing and reviewing this collection of information. Send comments regarding this burden estimate or any other aspect of this collection of information, including suggestions for reducing this burden to Washington Headquarters Services, Directorate for Information Operations and Reports, 1215 Jefferson Davis Highway, Suite 1204, Arlington, VA 22202-4302, and to the Office of Management and Budget, Paperwork Reduction Project (0704-0188), Washington, DC 20503

1. AGENCY USE ONLY (Leave blank)	2. REPORT DATE August 2002	3. REPORT TYPE AND DATES COVERED Annual (3 Jul 01 - 2 Jul 02)
----------------------------------	-------------------------------	--

4. TITLE AND SUBTITLE The Role of Myoepithelial Maspin in Breast Carcinoma Progression, Diagnosis and Screening	5. FUNDING NUMBERS DAMD17-00-1-0176
--	--

6. AUTHOR(S) Sanford H. Barsky, M.D.

7. PERFORMING ORGANIZATION NAME(S) AND ADDRESS(ES) University of California, Los Angeles Los Angeles, California 90095-1406 E-Mail: sbarsky@ucla.edu	8. PERFORMING ORGANIZATION REPORT NUMBER
---	--

9. SPONSORING / MONITORING AGENCY NAME(S) AND ADDRESS(ES) U.S. Army Medical Research and Materiel Command Fort Detrick, Maryland 21702-5012	10. SPONSORING / MONITORING AGENCY REPORT NUMBER
---	--

20021230 156

11. SUPPLEMENTARY NOTES report contains color
--

12a. DISTRIBUTION / AVAILABILITY STATEMENT Approved for Public Release; Distribution Unlimited	12b. DISTRIBUTION CODE
---	------------------------

13. ABSTRACT (Maximum 200 Words)

In glandular organs, a precancerous state precedes invasive carcinoma. In the breast this state is recognized as DCIS and consists of an epithelial cell proliferation confined by myoepithelial cells. Our laboratory has established cell lines/xenografts of myoepithelial cells. Our myoepithelial cell lines inhibit invasion and motility of breast carcinoma lines *in vitro* largely through maspin. The overall hypothesis of this proposal was how does myoepithelial maspin regulate breast (DCIS) carcinoma progression and can its detection in fine needle aspirates (FNA) and in ductal fluid abet diagnosis and screening? The first aim addressed the mechanism of maspin's inhibition of breast carcinoma invasion: We have shown that myoepithelial maspin does bind to plasma membranes of carcinoma cells and inhibit a pathway involved in cellular locomotion. Using differential display and microarray analysis we have further characterized the pathway(s) involved. The second aim utilized maspin antibodies on FNA to identify the myoepithelial component and we have further demonstrated with larger number of samples that this approach is successful. The third aim investigated the levels of maspin in nipple aspirates, in ductal lavage fluid and saliva. We have shown that maspin is both a tumor marker as well as a surrogate intermediate end point marker. Studies were conducted in year 02 that further extended our findings.

14. SUBJECT TERMS maspin, myoepithelial cells, DCIS, invasion, serpins fine needle aspiration, ductal fluid, breast cancer	15. NUMBER OF PAGES 50
	16. PRICE CODE

17. SECURITY CLASSIFICATION OF REPORT Unclassified	18. SECURITY CLASSIFICATION OF THIS PAGE Unclassified	19. SECURITY CLASSIFICATION OF ABSTRACT Unclassified	20. LIMITATION OF ABSTRACT Unlimited
---	--	---	---

Table of Contents

Cover.....	1
SF 298.....	2
Table of Contents.....	3
Introduction.....	4
Body.....	5
Key Research Accomplishments.....	6
Reportable Outcomes.....	7
Conclusions.....	8
References.....	11
Appendices.....	15

INTRODUCTION

In many glandular organs, a precancerous state is thought to exist which precedes the development of frankly invasive carcinoma. In the breast this state is recognized as DCIS and consists of a proliferation of epithelial luminal cells confined by myoepithelial cells within the ductal system (1-7). CGH and LOH studies have failed to demonstrate a difference between DCIS and invasive breast carcinoma. Our laboratory has recently demonstrated that paracrine regulation of this transition by myoepithelial cells may be the main determinant of this important step in human breast carcinoma progression. Because of their close proximity to precancerous lesions, myoepithelial cells would be expected to exert important paracrine influences on these processes. Myoepithelial cells of the breast differ from ductal cells in many ways: they lack ER- α , and its downstream genes; they synthesize the adjacent basement membrane; they rarely proliferate or fully transform and give rise rarely only to low grade benign neoplasms. Myoepithelial cells are present around normal ducts and precancerous proliferations but are absent in invasive carcinoma. Our laboratory has established immortalized myoepithelial cell lines and xenografts from benign human myoepitheliomas of the salivary gland (HMS-1, HMS-3) and breast (HMS-4,5) (8-23). These cell lines and xenografts express identical myoepithelial markers as their *in situ* counterparts. Our myoepithelial cell lines and xenografts and myoepithelial cells *in situ* constitutively express high amounts of proteinase and angiogenesis inhibitors which include TIMP-1, protease nexin-II, α -1 antitrypsin, an unidentified perhaps novel 31-33 kDa trypsin inhibitor (24), thrombospondin-1, soluble bFGF receptors, and maspin (25-34). The human myoepithelial cell lines, HMS-1, HMS-3, HMS-4, HMS-5 inhibit both ER-positive and ER-negative breast carcinoma invasion (down to 42% \pm 7% of control) ($p < .05$) and in CM assays (down to 30% \pm 8% of control) ($p < .01$).

The anti-invasive effects of HMS-1, HMS-3, HMS-4, HMS-5 and HMS-6 can be enhanced by phorbol 12-myristate 13-acetate (PMA) (down to 2% \pm 1% of control) and abolished by dexamethasone (up to 95% \pm 5% of control) ($p < .01$) Therefore with the appropriate pharmacological treatment, the myoepithelial cells do not only partially inhibit invasion --- they in fact near-totally eliminate it. PMA treatment causes an immediate and sustained release of maspin, a recently identified serpin. Immunoprecipitation of maspin from this CM nearly abolishes this anti-invasive effect. Adding purified native myoepithelial maspin to unconditioned media also results in a dramatic anti-invasive effect. Maspin exerts a similar inhibitory effect on breast carcinoma cell motility as noted by us using native maspin and others using both recombinant bacterial maspin and recombinant insect maspin(i) produced in Baculovirus-infected insect cells (35). Our findings suggest that myoepithelial-secreted maspin functions as a paracrine tumor suppressor, which may inhibit *in vivo* the progression of DCIS to invasive breast carcinoma.

The observation that myoepithelial cells express and secrete maspin has, in addition to these biological implications, important potential practical applications. Fine needle aspiration cytology of the breast is a safe noninvasive technique for diagnosing breast cancer that is being used with increasing frequency in older women and women with comorbid disease who would benefit from being spared a more invasive and anesthesia-requiring procedure such as lumpectomy. Presently however there is no way on FNA of distinguishing invasive breast cancer cells from DCIS cells. This is because both types of cells appear cytologically identical and on routine FNA there is no way to evaluate the cells in the anatomical context of the tissues. We feel

however that if myoepithelial cells could be selectively identified on FNA then their presence would suggest the DCIS state since they would be expected to be aspirated along with the DCIS epithelial cells. Their absence on the smear would suggest that the malignant cells which were present were derived from invasive carcinoma cells which are devoid of surrounding myoepithelial cells *in vivo*. Perhaps the absolute number or density of myoepithelial cells would also be discriminating factors. Our laboratory has shown that the immunocytochemical demonstration of maspin reliably distinguishes myoepithelial cells from all epithelial cells (normal, DCIS, and invasive carcinoma). Furthermore our laboratory has detected maspin in ductal fluid of the breast obtained by both nipple suction and selective breast ductal cannulation (36). This maspin in ductal fluid is produced by myoepithelial cells *in vivo* and reflects the integrity of the normal ductal lobular unit. Conceivably reduced levels of maspin in ductal fluid may reflect either structural or functional compromise of the myoepithelial layer and may be seen in high risk ν normal women and/or ducts with abnormal microcalcifications, precancerous or invasive histopathology (37-40).

BODY (STATEMENT OF WORK)

1. To investigate the mechanism of maspin's inhibition of breast carcinoma cell invasion and motility. - Months 1-36

A. Maspin binding to breast carcinoma cells/plasma membranes. - Months 1-6

B. Identification and characterization of a maspin binding protein.- Months 6-18

C. Maspin activation of a breast carcinoma cellular pathway.- Months 18-36

We have demonstrated during the second year of funding that purified myoepithelial maspin inactivates a cellular pathway involved in cellular locomotion. In addition we have demonstrated through differential display and microarray analysis that there is activation of several cellular pathways.

2. To utilize antibodies to maspin on fine needle aspirate (FNA) specimens to quantitate the myoepithelial component and determine if this determination discriminates between DCIS and invasive breast carcinoma. - Months 12-24

We have extended our previous observations by expanding them to a much larger number of cases and further demonstrated that antibodies to maspin (polyclonal and monoclonal) are the best discriminator between myoepithelial cells and epithelial cells and they can be used to quantitate the myoepithelial component in FNA.

3. To investigate the levels of maspin in ductal fluid obtained by the nipple suction approach (in high risk ν normal women) and in ductal fluid obtained by selective ductal cannulation and washings (ducts with and without microcalcifications from the same

patient) and determine whether maspin levels abet screening and correlate with histological findings/ - Months 24-36

We have demonstrated that nipple aspirate fluids and ductal lavage fluids obtained by ductoscopy is rich in maspin as a surrogate intermediate end point marker that reflects the integrity of the ductal lobular unit. The methods used in these studies are contained in our publications (41,42). Ductal fluid contains numerous proteins in addition to maspin such as bFGF which may also be a marker for early cancerous changes. These points are made in another of our publications (43). Access to the ductal system of the breast and specifically targeting the myoepithelial-epithelial connection through gene therapy intraductal approaches may prove efficacious in early breast cancer chemoprevention and treatment, strategies claimed in our patent application (44). We are anticipating concentrating on this aim in Year 03 of the study.

KEY RESEARCH ACCOMPLISHMENTS

- We have demonstrated during the second year of funding that purified myoepithelial maspin binds to plasma membranes of carcinoma cells via a membrane receptor and both inactivates a cellular pathway involved in cellular locomotion and activates several other pathways by differential display and microarray analysis. We are further characterizing these pathways presently.
- We have further demonstrated using larger numbers of samples that antibodies to maspin (polyclonal and monoclonal) are the best discriminator between myoepithelial cells and epithelial cells and they can be used to quantitate the myoepithelial component.
- We have demonstrated that nipple aspirate fluids and ductal lavage fluids obtained by ductoscopy is rich in maspin as a surrogate intermediate end point marker that reflects the integrity of the ductal lobular unit. Ductal fluid contains numerous proteins in addition to maspin such as bFGF which may also be a marker for early cancerous changes. Access to the ductal system of the breast and specifically targeting the myoepithelial-epithelial connection through gene therapy intraductal approaches may prove efficacious in early breast cancer chemoprevention and treatment, strategies claimed in our patent application. We have further demonstrated these points by studying more samples in year 02 and year 03 of the study.

REPORTABLE OUTCOMES

PUBLICATIONS

1. Shen KW, Wu J, Lu JS, Han QX, Shen ZZ, Nguyen M, **Barsky SH** and Shao ZM. Fiberoptic ductoscopy for breast cancer patients with nipple discharge. *Surgical Endoscopy* 15: 1340-1345, 2001.
2. **Barsky SH**, Kedeshian P and Alpaugh ML. Maspin and myoepithelial cells. Maspin edited by M.J.C. Hendrix. Landes Bioscience, Georgetown, Texas, 2002.
3. **Barsky SH** and Alpaugh ML. Myoepithelium: Methods of culture and study. Culture of Human Tumor Cells, edited R. Ian Freshney, John Wiley & Sons, Inc., New York, NY, 2002, in press

PATENTS AND LICENSES

1. Love SM and **Barsky SH**. Method and kit for obtaining fluids and cellular material from breast ducts. *U.S. Patent*, 6,221,622; June 2, 2001.
2. **Barsky SH**, Love SM and Alpaugh ML. Methods and kits for identifying ductal orifices in a nipple (U.S. Continuation-In-Part). *U.S. Patent Application*, 09/153,564, filed September 14, 1998, approved, May 15, 2002, issue date pending
3. Love SM and **Barsky SH**. Method and kit for obtaining fluids and cellular material from breast ducts (U.S. Continuation-In-Part). *U.S. Patent Application*, 09/740,561 filed December 19, 2000.
4. Love SM and **Barsky SH**. Method and kit including catheters for performing ductal lavage. *U.S. Patent Application (No. pending)*, filed March 15, 2002.
5. **Barsky SH** and Love SM. Methods for performing medical procedures within a breast duct. *U.S. Patent Application (No pending)*, filed March 30, 2002.

CONCLUSIONS

1. Mechanism of Maspin Action

Maspin activation / inactivation of a cellular pathway. The first question that we addressed is whether maspin exhibits specific, saturable, reversible, and displaceable binding to the surface of breast carcinoma cells in a manner of a ligand-receptor interaction and it does. The mechanism of maspin's effects on invasion and motility inhibition are still unknown. Our studies have shown that in myoepithelial cells it is *secreted* in large amounts. We have been able to purify native maspin to homogeneity. We have obtained *rmaspin* from Dr. Zhang (Baylor). Both *rmaspins* (bacterial and insect) and native maspin derived from myoepithelial cells have been iodinated and incubated with first intact MDA-231, MDA-468, MCF-7, T47D cells and then with their plasma membrane fractions. Excess unlabelled ligand was added and specific binding was determined with Scatchard analysis to calculate the K_d of binding and the # of binding sites/cell or /membrane protein. Specific, displaceable binding indicated a binding protein (receptor). The cell line with the highest maspin binding was used as source to isolate a maspin receptor. In year 02 we carried this approach further by identification and characterization of a maspin binding protein. Two approaches were used: Maspin was crosslinked to Sepharose 4B and an affinity column was made. The plasma membrane preparation from the breast carcinoma cell line exhibiting the highest maspin binding was extracted, iodinated by the lactoperoxidase method and added to the maspin affinity column. Controls included BSA cross-linked to Sepharose 4B or cross-linked Sepharose4B alone. The bound fraction was eluted with 0.2 M glycine HCl pH 3.5, immediately neutralized with 1.0M Tris/saline, lyophilized and run on a gel. Autoradiograms were used to identify a specific binding protein. Since maspin is a serpin, candidate receptor molecules included membrane associated proteinases such as the uPA/uPAR complex or MT-MMPs. Since maspin, in addition to inhibiting invasion also inhibits cell motility (which in itself could explain its inhibition of invasion), inhibition by binding to the handful of known motility-stimulating ligand-receptor complexes such as scatter factor/hepatocyte growth factor-c-met receptor, autocrine motility factor-receptor, autoxin-receptor, bFGF and its receptor, interleukin 6 and its receptor, integrins, and E cadherin was investigated by doing a simultaneous Western blot on the eluted material with antibodies to these different molecules. Since another possibility was that maspin was directly binding a negative regulator of cell motility rather than inhibiting a positive regulator, TGF β -receptor and retinoic acid-receptor complexes, known negative regulators of cell motility were investigated by Western blotting. Recently investigators have shown that maspin binds to single stranded tissue plasminogen activator (ss t-PA); this molecule which is secreted could be a target for maspin action. However in the vast majority of the carcinoma and melanoma lines we studied where maspin exerted a pronounced suppressive effect on both motility and invasion, no ss t-PA was detected in these lines; hence maspin must be acting on a different target. Since both invasion and motility involve complex intracellular pathways, we hypothesize that maspin triggered a signal transduction pathway leading to inhibition of invasion/motility. For that reason we investigated by differential display and microarray analysis various genes whose expression levels were altered (up or down) by the actions of maspin. Computational analysis of these genes identified several candidate pathways of action. We are further analyzing these in year 03

2. Maspin in FNA

We have utilized maspin antibodies on FNA specimens to quantitate the myoepithelial component and determine if this determination discriminates between DCIS and invasive breast carcinoma. Polyclonal (rabbit) and monoclonal (murine) antibodies to maspin have been used (Pharmingen, San Diego, CA) according to standard immunocytochemical cytological protocols. We had great success with this approach in year 01 and expanded this to a much larger number of cases in year 02. We chose cases known by subsequent biopsy to be either pure DCIS or predominantly invasive carcinoma (most invasive breast cancers have at least some DCIS component). Without knowing the surgical pathology we determined first whether there were any myoepithelial cells present on the FNA and we then determined their number by assessing them by maspin positive immunostaining. We determined both the absolute number of myoepithelial cells and the ratio of myoepithelial cells to epithelial cells (the immunopositive to immunonegative ratio) and grouped the cases where there were no myoepithelial cells and the cases where there were some myoepithelial cells and determined the mean number \pm standard deviation in this second group. We then subdivides these results into cases of known DCIS and cases of predominantly invasive cancer and did a t test on the results to see if DCIS and invasive breast cancer differed in their average number of myoepithelial cells present on FNA. Analyzing the results in this manner assumed and confirmed a Gaussian distribution for the number of myoepithelial cells in both groups. Based on the differences in the mean values and/or the slope of this curve we were able to perform power calculations to determine the number of cases needed to achieve statistical significance. Basically the steeper the slope of this curve the more discriminating the myoepithelial measurement was and the fewer the number of cases needed. Based also on the differences in the mean values (how many standard deviations apart) of myoepithelial cell numbers or myoepithelial/epithelial ratios between our two groups, DCIS and invasive carcinoma, we were able also to perform power calculations and determine the number of cases needed. Furthermore we have used antibodies to smooth muscle actin, S100 and CALLA, all of which are fairly myoepithelial specific to compare with our maspin results. All of the latter antibodies recognized structural myoepithelial components and as such quantitate myoepithelial cell number. Maspin, on the other hand, not only identified myoepithelial cell number but provided an index of myoepithelial cell function---after all maspin is a serpin and a paracrine tumor suppressor. Therefore the use of maspin in this setting was more informative.

3. Maspin in Ductal Fluid

Maspin in ductal fluid was measured by Western blot with total protein normalization. Human subjects approval for the collection of ductal fluid through select duct cannulation was obtained.. Small aliquots of this collected ductal fluid (50 patients) was used for the present studies. Nipple aspirates were collected by nipple suction (Sartorius/Petrakis). Analysis of nipple aspirates revealed the pooled contributions of all or most of the ducts where selective ductal cannulation allowed for a discrimination of one duct from another (eg, a duct with DCIS or microcalcifications v a normal duct. Our findings indicated that maspin was present reflecting the

integrity of the ductal-lobular unit. We also demonstrated maspin in saliva, a fluid which reflects the abundance of myoepithelial cells in the salivary glands (See publication in Appendix).

In year 02, ductal fluid was begun to be collected following cannulation and washing of selected ducts in patients with microcalcifications on screening mammography who are about to undergo either excisional or core biopsy. In year 03, we will expand this to a larger number of cases. Paired comparisons of maspin levels in ductal fluid obtained from ducts harboring microcalcifications or DCIS and normal ducts from the same patients have and will continue to be made. Maspin levels will be correlated with the histopathology surrounding the microcalcifications. We have shown that some of these patients exhibit normal ductal histopathology surrounding their microcalcifications, some exhibit proliferations like hyperplasia, adenosis, ADH, and DCIS and still others invasive carcinoma. The screening value of maspin levels in all of these patients is emerging. Our approach to the evaluation of maspin values and to their discriminatory ability among the different groups has been similar to that given above for the analysis of myoepithelial cell number. Measurements of *myoepithelial* maspin in ductal fluid will continue to be compared to levels of a breast *epithelial* cell marker such as carcinoembryonic antigen (CEA) or bFGF. We, in fact, have recently found that bFGF is elevated in ductal fluid of certain patients. Hence the maspin/CEA or maspin/bFGF ratio might be predictive of risk with increased maspin/CEA or increased maspin/bFGF correlating with normalcy and decreased maspin/CEA or decreased maspin/bFGF correlating with either high risk, microcalcifications and/or precancerous histopathology. We are continuing to investigate these questions in year 03.

REFERENCES

1. Cavenee, W.K. 1993. A siren song from tumor cells. *J. Clin. Invest.* 91:3.
2. Liotta, L.A., P.S. Steeg, and W.G. Stetler-Stevenson. 1991. Cancer metastasis and angiogenesis: an imbalance of positive and negative regulation. *Cell* 64:327-336.
3. Safarians, S., M.D. Sternlicht, C.J. Freiman, J.A. Huaman, and S.H. Barsky. 1996. The primary tumor is the primary source of metastasis in a human melanoma/SCID model: implications for the direct autocrine and paracrine epigenetic regulation of the metastatic process. *Int. J. Cancer.* 66:151-158.
4. Folkman, J. and M. Klagsbrun. 1987. Angiogenic factors. *Science* 235:442-447.
5. Cornil, I., D. Theodorescu, S. Man, M. Herlyn, J. Jambrosic, and R.S. Kerbel. 1991. Fibroblast cell interactions with human melanoma cells affect tumor cell growth as a function of tumor progression. *Proc. Natl. Acad. Sci. USA* 88:6028-6032.
6. Guelstein, V.I., T.A. Tchypsheva, V.D. Ermilova, and A.V. Ljubimov. 1993. Myoepithelial and basement membrane antigens in benign and malignant human breast tumors. *Int. J. Cancer* 53:269-277.
7. Cutler, L.S. 1990. The role of extracellular matrix in the morphogenesis and differentiation of salivary glands. *Adv. Dent. Res.* 4:27-33.
8. Sternlicht, M.D., Safarians, S., Calcaterra, T.C., and S.H. Barsky. 1996. Establishment and characterization of a novel human myoepithelial cell line and matrix-producing xenograft from a parotid basal cell adenocarcinoma. *In Vitro Cell. Dev. Biol.* 32:550-563.
9. Sternlicht, M.D., S. Safarians, S.P. Rivera, and S.H. Barsky. 1996. Characterizations of the extracellular matrix and proteinase inhibitor content of human myoepithelial tumors. *Lab. Invest.* 74:781-796.
10. Hackett, A.J., H.S. Smith, E.L. Springer, R.B. Owens, W.A. Nelson-Rees, J.L. Riggs, and M.B. Gardner. 1977. Two syngeneic cell lines from human breast tissue: the aneuploid mammary epithelial (Hs578T) and the diploid myoepithelial (Hs578Bst) cell lines. *J. Natl. Cancer Inst.* 58:1795-1806.
11. Langone, J.J. 1982. Protein A of *Staphylococcus aureus* and related immunoglobulin receptors produced by streptococci and pneumococci. *Adv. Immunol.* 32:157-252.
12. DeClerck, Y.A. 1988. Purification and characterization of a collagenase inhibitor produced by bovine vascular smooth muscle cells. *Arch. Biochem. Biophys.* 265:28-37.
13. Herron G.S., M.J. Banda, E.J. Clark, J. Gavrilovic, and Z. Werb. 1986. Secretion of metalloproteinases by stimulated capillary endothelial cells:

- expression of collagenase and stromelysin activities is regulated by endogenous inhibitors. *J. Biol. Chem.* 261:2814-2818.
14. Hanspal, J.S., G.R. Bushell, and P. Ghosh. 1983. Detection of protease inhibitors using substrate-containing sodium dodecyl sulfate-polyacrylamide gel electrophoresis. *Anal. Biochem.* 132:288-293.
 15. Heussen, C., and E.B. Dowdle. 1980. Electrophoretic analysis of plasminogen activators in polyacrylamide gels containing sodium dodecyl sulfate and copolymerized substrates. *Anal. Biochem.* 102:196-202.
 16. Erickson, L.A., D.A. Lawrence, and D.J. Loskutoff. 1984. Reverse fibrin autography: a method to detect and partially characterize protease inhibitors after sodium dodecyl sulfate-polyacrylamide gel electrophoresis. *Anal. Biochem.* 137:454-463.
 17. Andreasen, P.A., B. Georg, L.R. Lund, A. Riccio, and S.N. Stacey. 1990. Plasminogen activator inhibitors: hormonally regulated serpins. *Mol. Cell. Endocrinol.* 68:1-19.
 18. Albini, A., Y. Iwamoto, H.K. Kleinman, G.S. Martin, S.A. Aaronson, J.M. Kozlowski, and R.N. McEwan. 1987. A rapid *in vitro* assay for quantitating the invasive potential of tumor cells. *Cancer Res.* 47:3239-3245.
 19. O'Reilly, M.S., Holmgren, L., Shing, Y., Chen, C., Rosenthal, R.A., Moses, M., Lane, W.S., Cao, Y., Sage, E.H., and J. Folkman. 1994. Angiostatin: A novel angiogenesis inhibitor that mediates the suppression of metastases by a Lewis lung carcinoma. *Cell* 79:315-328.
 20. Kataoka, H., K. Seguchi, T. Iwamura, T. Moriyama, K. Nabeshima, and M. Koono. 1995. Reverse-zymographic analysis of protease nexin-II/amyloid b protein precursor of human carcinoma cell lines, with special reference to the grade of differentiation and metastatic phenotype. *Int. J. Cancer* 60:123-128.
 21. Narindrasorasak, S., D.E. Lowery, R.A. Altman, P.A. Gonzalez-DeWhitt, B.D. Greenberg, and R. Kisilevsky. 1992. Characterization of high affinity binding between laminin and Alzheimer's disease amyloid precursor proteins. *Lab. Invest.* 67:643-652.
 22. Kibby, M.C., M. Jucker, B.S. Weeks, R.L. Neve, W.E. Van Nostrand, and H.K. Kleinman. 1993. b-Amyloid precursor protein binds to the neurite-promoting IKVAV site of laminin. *Proc. Natl. Acad. Sci. USA* 90:10150-10153.
 23. Takahashi, H., S. Fujita, H. Okabe, N. Tsuda, and F. Tezuka. 1995. Immunohistochemical characterization of basal cell adenomas of the salivary gland. *Path. Res. Pract.* 187:145-156.
 24. Rao, C.N., Y.Y. Liu, C.L. Peavey, and D.T. Woodley. 1995. Novel extracellular matrix-associated serine proteinase inhibitors from human skin fibroblasts. *Arch. Biochem. Biophys.* 317:311-314.

25. Khokha, R., P. Waterhouse, S. Yagel, P.K. Lala, C.M. Overall, G. Norton, and D.T. Denhardt. 1989. Antisense RNA-induced reduction in murine TIMP levels confers oncogenicity on Swiss 3T3 cells. *Science* 243:947-950.
26. Zou, Z., A. Anisowicz, M.J.C. Hendrix, A. Thor, M. Neveu, S. Sheng, K. Rafidid, E. Seftor, and R. Sager. 1994. Maspin, a serpin with tumor-suppressing activity in human mammary epithelial cells. *Science* 263:526-529.
27. Hopkins, P.C.R., and J. Whisstock. 1994. Function of maspin. *Science* 265:1893-1894.
28. Pemberton, P.A., Wong, D.T., Gibson, H.L., Kiefer, M.C., Fitzpatrick, P.A., Sager, R., and P.J. Barr. 1995. The tumor suppressor maspin does not undergo the stressed to relaxed transition or inhibit trypsin-like serine proteases: evidence that maspin is not a protease inhibitory serpin. *J. Biol. Chem.* 270:15832-15837.
29. Sheng, S., Pemberton, P.A., and R. Sager. 1994. Production, purification, and characterization of recombinant maspin proteins. *J. Biol. Chem.* 269:30988-30993.
30. Folkman, J. 1995. Clinical applications of research on angiogenesis. *N. Engl. J. Med.* 333:1757-1763.
31. Roberts D.D. 1996. Regulation of tumor growth and metastasis by thrombospondin-1. *FASEB J.* 10:1183-1191.
32. Weinstat-Saslow, D.L., Zabrenetzky, V.S., VanHoutte, K., Frazier, W.A., Roberts, D.D., and Steeg, P.S. 1994. Transfection of thrombospondin 1 complementary DNA into a human breast carcinoma cell line reduces primary tumor growth, metastatic potential, and angiogenesis. *Cancer Res* 54:6504-6511.
33. Bao, L., Matsumura, Y., Baban, D., Sun, Y., and D. Tarin. 1994. Effects of inoculation site and Matrigel on growth and metastasis of human breast cancer cells. *Br. J. Cancer* 70:228-232.
34. Fridman, R., Kibbey, M.C., Royce, L.S., Zain, M., Sweeney, T.M., Jicha, D.L., Yannelli, J.R., Martin, G.R., and H.K. Kleinman. 1991. Enhanced tumor growth of both primary and established human and murine tumor cells in athymic mice after coinjection with Matrigel. *J. Natl. Cancer Inst.* 83:769-774.

35. Sheng S, Carey J, Seftor EA, Dias L, Hendrix MJC and Sager R. PNAS 93: 11669-11674, 1996.
36. Love SM and Barsky SH. Breast-duct endoscopy to study stages of cancerous breast disease. *The Lancet* 348: 997-999, 1996.
37. Shao ZM, Radziszewski WJ and Barsky SH. Tamoxifen enhances myoepithelial cell suppression of human breast carcinoma progression by two different effector mechanisms. *Cancer Lett*, 157: 133-144, 2000.
38. Nguyen M, Lee MC, Wang JL, Tomlinson JS, Shao ZM and Barsky SH. The human myoepithelial cell displays a multifaceted anti-angiogenic phenotype. *Oncogene* 19: 3449-3459, 2000.
39. Alpaugh ML, Lee MC, Nguyen M, Deato M, Dishakjian L and Barsky SH. Myoepithelial-specific CD44 shedding contributes to the anti-invasive and anti-angiogenic phenotype of myoepithelial cells. *Experiment Cell Res* 26: 150-158, 2000.
40. Lee MC, Alpaugh ML, Nguyen M, Deato M, Dishakjian L and Barsky SH. Myoepithelial specific CD44 shedding is mediated by a putative chymotrypsin-like sheddase. *Biochem Biophys Res Commun* 279: 116-123, 2000.
41. Shen KW, Wu J, Lu JS, Han QX, Shen ZZ, Nguyen M, Shao ZM, and Barsky SH. Fiberoptic ductoscopy for patients with nipple discharge. *Cancer* 89: 1512-1519, 2000.
42. Shen KW, Wu J, Lu JS, Han QX, Shen ZZ, Nguyen M, Barsky SH and Shao ZM. Fiberoptic ductoscopy for breast cancer patients with nipple discharge. *Surgical Endoscopy*, in press, 2001.
43. Liu YL, Wang JL, Chang H, Barsky SH, Nguyen M. Breast cancer diagnosis with nipple fluid bFGF. *Lancet* 356: 567, 2000.
44. Barsky SH and Alpaugh ML. Compositions and methods for intraductal gene therapy. *United States Patent Application*, 60/116,470, filed January 20, 2000.

APPENDIX

CHAPTER 4

Maspin and Myoepithelial Cells

Sanford H. Barsky
Paul Kedeshian
Mary L. Alpaugh
Department of Pathology
UCLA School of Medicine
Los Angeles, California, U.S.A.

From:

Maspin

edited by Mary J.C. Hendrix, Ph.D., D.Sc.

LANDES
BIOSCIENCE
GEORGETOWN, TX USA

EUREKAH.COM
AUSTIN, TX USA

Reprints of this and all Intelligence Unit book chapters are available at:
www.eurekah.com

Please also visit our Landes Bioscience website to view and order
Intelligence Unit books online:
www.landesbioscience.com

CHAPTER 4

Maspin and Myoepithelial Cells

Sanford H. Barsky, Paul Kedeshian and Mary L. Alpaugh

Introduction

Most cellular paracrine regulation of tumor progression is an important determinant of tumor growth, invasion and metastasis but one cell which has largely been ignored in this regulation is the myoepithelial cell. In any organ where there is significant branching morphogenesis such as the breast, myoepithelial cells ubiquitously accompany and surround epithelial cells and are thought to keep in check (negatively regulate) the process of branching. Myoepithelial cells surround both normal ducts and precancerous lesions, especially of the breast (so-called DCIS, ductal carcinoma-in-situ), and form a natural border separating proliferating epithelial cells from proliferating endothelial cells (angiogenesis). Myoepithelial cells, by forming this natural border, are thought to negatively regulate tumor invasion and metastasis. Whereas epithelial cells are susceptible targets for transforming events leading to cancer, myoepithelial cells are resistant. Indeed tumors of myoepithelial cells are uncommon and when they do occur, are almost always benign. Therefore it can be said that myoepithelial cells function as both autocrine as well as paracrine tumor suppressors. Our laboratory has found that myoepithelial cells secrete a number of suppressor molecules including high amounts of diverse proteinase inhibitors which include TIMP-1, protease nexin-II, and α -1 antitrypsin, but low amounts of proteinases and high amounts of diverse angiogenic inhibitors which include thrombospondin-1 and soluble bFGF receptors but low amounts of angiogenic factors compared to common malignant cell lines. However the most striking difference between the suppressive effector molecules secreted by myoepithelial cells and carcinoma cells is the levels of maspin secretion. Whereas carcinoma cells do not secrete maspin, myoepithelial cells secrete this serpin in large quantities. This observation holds in vitro, in mice, and in humans and suggests that maspin and myoepithelial cells exert pleiotropic suppressive effects on tumor progression. Since maspin is both a proteinase inhibitor, a locomotion inhibitor and an angiogenesis inhibitor, the diverse actions of maspin may largely explain the pronounced anti-invasive and anti-angiogenic effects of myoepithelial cells on carcinoma and pre-carcinoma cells. The same actions of maspin also may account for the low grade biology of myoepithelial tumors which are devoid of appreciable angiogenesis and invasive behavior. Finally since maspin is a secretory product of myoepithelial cells, the presence of maspin in body fluids such as in breast ductal fluid and in saliva reflects the structural and functional integrity of the

ductal-lobular units of the mammary and salivary glands respectively. Maspin, in ductal fluid, may serve as a surrogate (intermediate) end point marker (SEM) to estimate the risk of DCIS progression to invasive cancer in the breast and alternatively, in saliva, may serve as a tumor marker to detect the presence of incipient myoepithelial tumors occurring within the salivary glands of the head and neck.

Review of Current Research

Studies of Maspin and Myoepithelial Cells

It has become clear that cancer cells come under the influence of important paracrine regulation from the host microenvironment.¹ Such host regulation may be as great a determinant of tumor cell behavior in vivo as the specific oncogenic or tumor suppressor alterations occurring within the malignant cells themselves, and may be mediated by specific extracellular matrix molecules, matrix-associated growth factors, or host cells themselves.^{2,3} Both positive (fibroblast, myofibroblast and endothelial cell) and negative (tumor infiltrating lymphocyte and cytotoxic macrophage) cellular regulators exist which profoundly affect tumor cell behavior in vivo.^{4,5} One host cell however, the myoepithelial cell, has escaped the paracrine onlooker's attention. The myoepithelial cell, which lies on the epithelial side of the basement membrane, is thought to contribute largely to both the synthesis and remodeling of this structure. This cell lies in juxtaposition to normally proliferating and differentiating epithelial cells in health and to abnormally proliferating and differentiating epithelial cells in precancerous disease states such as ductal carcinoma in situ (DCIS) of the breast. This anatomical relationship suggests that myoepithelial cells may exert important paracrine effects on normal glandular epithelium and may regulate the progression of DCIS to invasive breast cancer. Circumstantial evidence suggests that the myoepithelial cell naturally exhibits a tumor suppressor phenotype. Myoepithelial cells rarely transform and when they do generally give rise to benign neoplasms that accumulate rather than degrade extracellular matrix.⁶ Myoepithelial cells directly or indirectly through their production of extracellular matrix and proteinase inhibitors including maspin are thought to regulate branching morphogenesis that occurs in the developing breast and salivary gland during embryological development.⁷ There have been a paucity of studies on myoepithelial cells because they have been relatively difficult to culture and because tumors that arise from these cells are rare.

In previous studies we have been extremely fortunate to have successfully established immortalized cell lines and transplantable xenografts from benign or low grade human myoepitheliomas of the salivary gland and breast.^{8,9} These cell lines and xenografts displayed an essentially normal diploid karyotype and expressed identical myoepithelial markers as their in situ counterparts including high constitutive expression of maspin. Unlike the vast majority of human tumor cell lines and xenografts which exhibited matrix-degrading properties, these myoepithelial lines/xenografts like their myoepithelial counterparts in situ retained the ability to secrete and accumulate an abundant extracellular matrix composed of both basement membrane and non-basement membrane components. When grown as a monolayer one prototype myoepithelial cell line, HMS-1, exerted profound and specific effects on normal epithelial and primary carcinoma morphogenesis.⁸ These studies support our position

that our established myoepithelial lines/xenografts recapitulate a normal differentiated myoepithelial phenotype and can therefore be used experimentally as a primary myoepithelial surrogate. Prompted by these studies and by the conspicuous absence of studies examining the role of the myoepithelial cell in tumor progression, we decided to examine the myoepithelial cell from this perspective. Experiments with these cell lines/xenografts together with relevant in situ observations form the cornerstone of our studies which observe that the human myoepithelial cell is a natural tumor suppressor.

Maspin and Myoepithelial Cells Inhibit Tumor Invasion

Breast ducts and acini are surrounded by a circumferential layer of myoepithelial cells exhibiting strong immunoreactivity for S100, smooth muscle actin, and diverse proteinase inhibitors including maspin, α 1-AT, PNII/APP, and TIMP-1 (Fig. 1A). In DCIS, the myoepithelial layer appeared either intact or focally disrupted, but the myoepithelial cells themselves exhibited the same pattern of immunoreactivity (Fig. 1B). In DCIS although proliferations of vWf immunoreactive blood vessel capillaries were observed focally within the supporting stroma, such blood vessels were not observed within the proliferating DCIS cells on the epithelial side of the myoepithelial layer (Fig. 1C). The human tumoral-nude mouse xenografts derived from the human myoepitheliomas of the salivary gland, HMS-X and HMS-3X, and breast, HMS-4X demonstrated an immunocytochemical profile identical to each other and to that exhibited by the myoepithelial cells surrounding normal ducts and DCIS with especially intense maspin immunoreactivity (Fig. 1D). Not only was strong proteinase inhibitor immunoreactivity present within the myoepithelial cells of these xenografts, but strong proteinase inhibitor immunoreactivity could be demonstrated within their extracellular matrix as well. Within this abundant extracellular matrix deposited by the different human myoepithelial xenografts, murine blood vessels were not observed (Fig. 1E, Fig. 1F; Fig. 1G). Using a mouse specific Cot-1 DNA probe (Fig. 1H), human myoepithelial xenografts HMS-X, HMS-3X, and HMS-4X, demonstrated an absent or near absent murine component indicative of absent to near absent angiogenesis. Human non-myoepithelial xenografts of breast cancer cell lines, MDA-MB-231 and MDA-MB-468, in contrast, showed a comparatively large murine component of presumed angiogenesis. The human myoepithelial xenografts, HMS-X, HMS-3X, and HMS-4X, instead exhibited a very dense accumulation of extracellular matrix accounting for a gross "pearl" appearance of these xenografts (Fig. 1I)

Detailed studies⁹ conducted with HMS-1 (Fig. 1J), a prototype myoepithelial cell line, revealed a constitutively high proteinase inhibitor to proteinase ratio in strong contrast to the high proteinase to proteinase inhibitor ratio observed in a number of malignant human cell lines (Fig. 2A). Marker studies with this cell line and corresponding xenograft (HMS-X) reflected the constitutive gene expression profile of myoepithelial cells in situ (Fig. 2B). This was especially true with respect to maspin. Direct gelatin zymography of CM revealed only low levels of the 92 and 72 kDa type IV collagenases (MMP-9 and MMP-2 respectively) in HMS-1; the 72 kDa collagenase was reduced 6-fold in HMS-1 compared to the levels in the majority of the malignant lines; direct fibrin zymography revealed visibly lower levels of the 54 kDa urokinase plasminogen activator (uPA) in HMS-1. This was also observed in casein/plasminogen gels. Tissue type plasminogen activator was not detected in any cell line, nor was plasmin detected in control gels lacking plasminogen. Stromelysin-1 (MMP-3) was

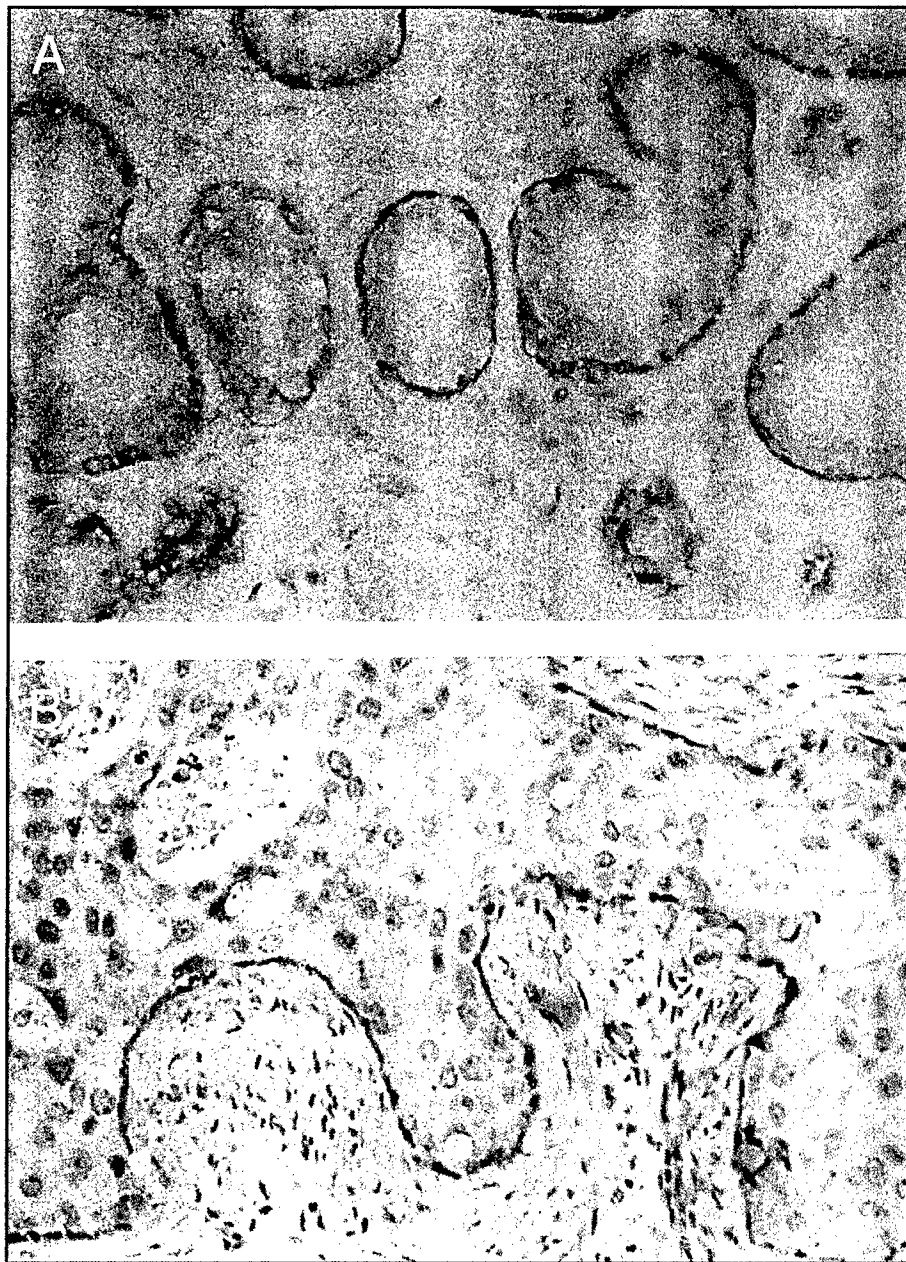


Fig. 1A & B. In situ immunocytochemistry profile of myoepithelial cells and their derived cell lines/xenografts. (A) Differential maspin immunoreactivity of myoepithelial cells surrounding breast ducts and acini; (B) Differential maspin immunoreactivity of myoepithelial cells in DCIS.




Fig. 1C & D. In situ immunocytochemistry profile of myoepithelial cells and their derived cell lines/xenografts. (C) Angiogenesis demonstrated by vWf immunoreactivity limited to stromal side of DCIS; (D) Cytoplasmic maspin immunoreactivity of myoepithelial xenograft, HMS-X.

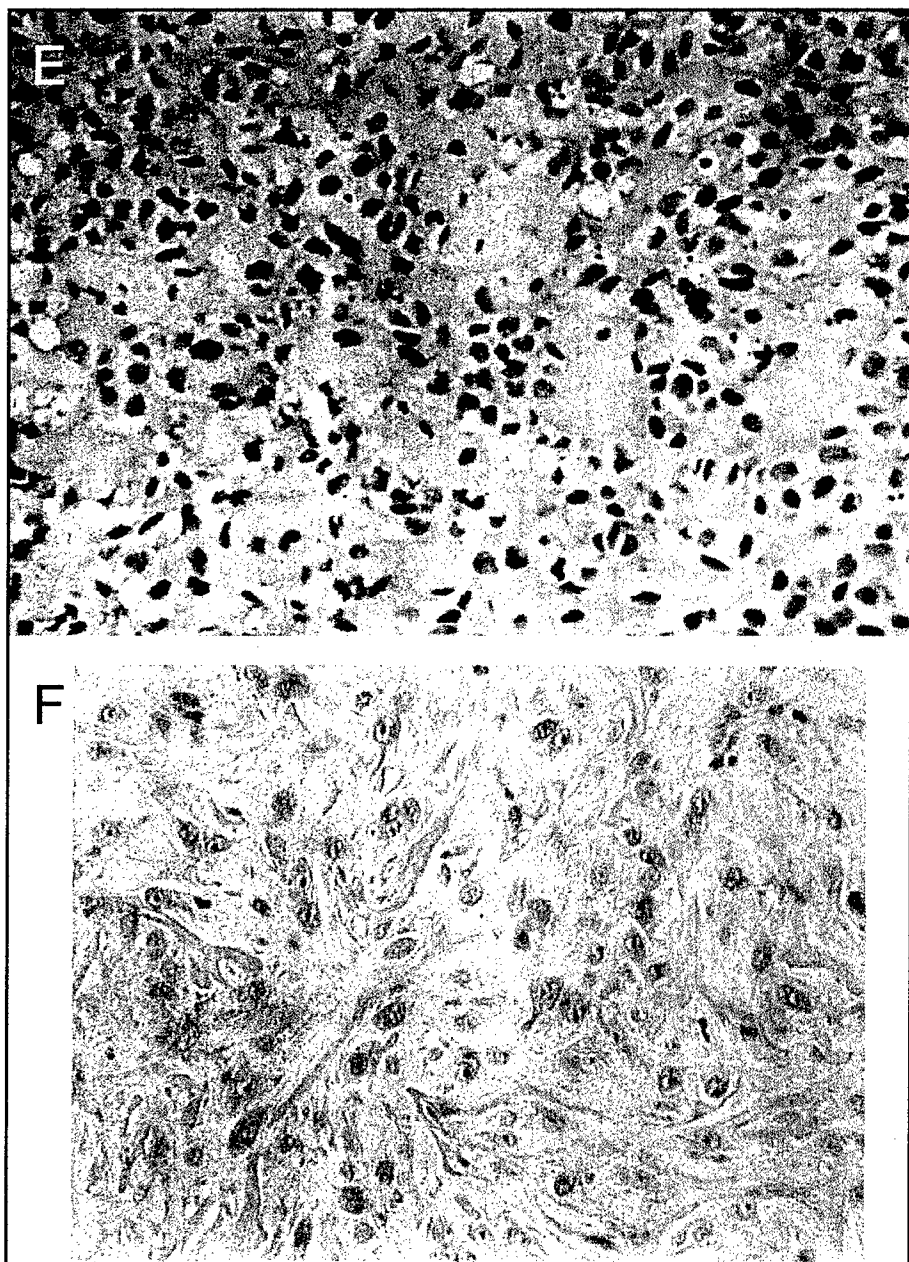


Fig. 1E & F. In situ immunocytochemistry profile of myoepithelial cells and their derived cell lines/xenografts. (E) HMS-X, (F) HMS-4X.




Fig. 1G. In situ immunocytochemistry profile of myoepithelial cells and their derived cell lines/xenografts. HMS-6X myoepithelial xenografts exhibit abundant matrix accumulation devoid of apparent angiogenesis.

also not detected in HMS-1. The proteinase inhibitor expression profile of HMS-1, in contrast, was characterized by high constitutive expression in CM of several proteinase inhibitors including TIMP-1; PAI-1; three trypsin inhibitors: α 1-AT, PNII/APP, and an unidentified 31 kDa inhibitor detected initially on reverse zymography; and the tumor suppressor maspin. With respect to the trypsin serine proteinase inhibitors, the conspicuous doublet at 116 kDa consistently greater in HMS-1 than in any of the other lines examined was confirmed on Western blot to be PNII/APP. These bands represented the 770 and 751 amino acid isoforms of PNII/APP which possessed a Kunitz-type serine proteinase inhibitor domain. Interestingly in 2M urea extracts of HMS-X, HMS-3X, and HMS-4X, a novel 95 kDa band of trypsin inhibition was detected by reverse zymography and confirmed by Western blot to represent an active breakdown product of PNII. This 95 kDa PNII breakdown product was completely absent from HMS-1 CM and urea extracts of HMS-1 cells suggesting that it was produced in situ within the myoepithelial extracellular matrix to which it bound. The retention of proteinase inhibitor activity by this breakdown product indicated that it retained the Kunitz-type serine proteinase inhibitor domain responsible for its ability to inhibit trypsin. In contrast to PNII/APP, protease nexin I was not detected. The second trypsin serine proteinase inhibitor was present at 54 kDa and was α 1-AT. This inhibitor appeared nearly equivalent in HMS-1 compared to the malignant lines examined on reverse zymography, but by Western blot its signal was markedly stronger and slightly more mobile in HMS-1 than in the malignant lines. This data was

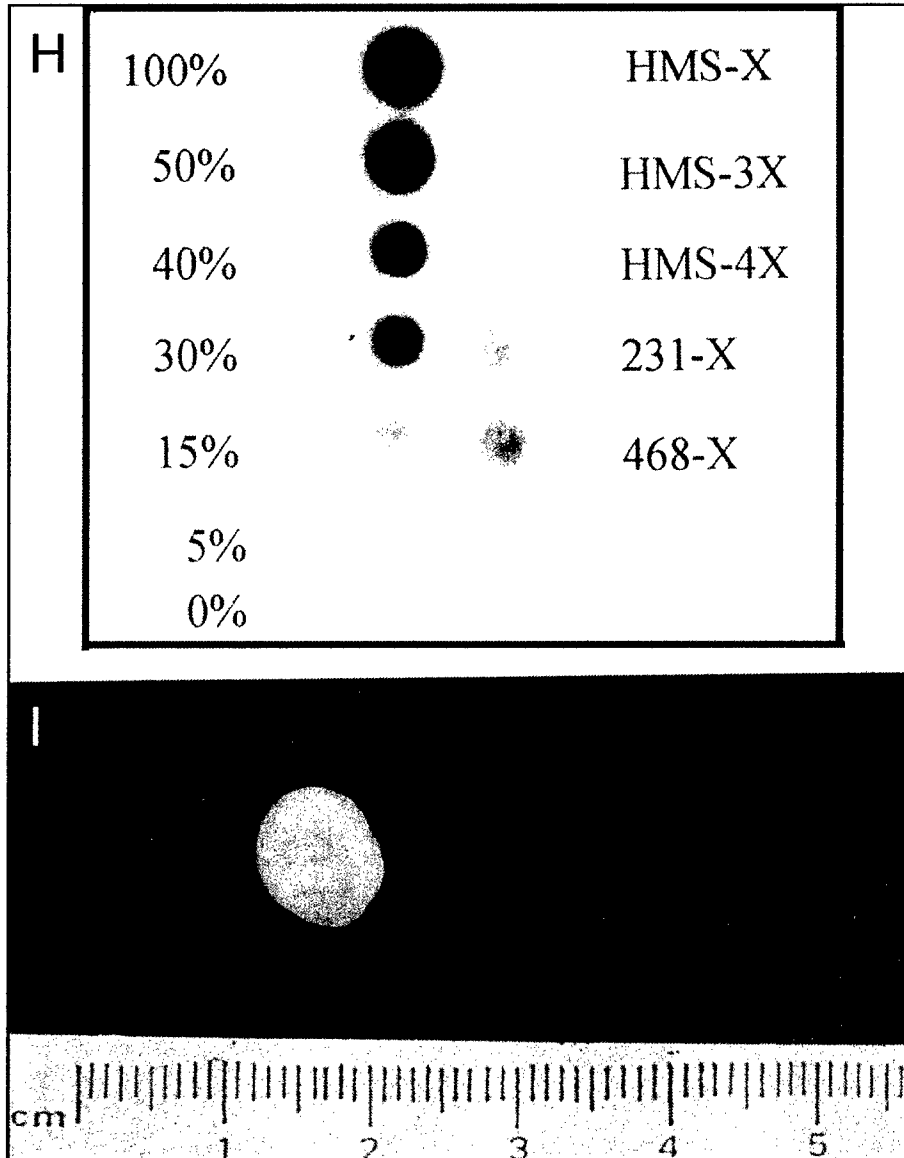


Fig. 1H & I. In situ immunocytochemistry profile of myoepithelial cells and their derived cell lines/xenografts. (H) Murine Cot-1 dot blot. Using a mouse specific Cot-1 DNA probe, human myoepithelial xenografts, HMS-X, HMS-3X and HMS-4X, are devoid of a murine DNA angiogenic component in contrast to the angiogenic-rich MDA-MB-231-X and MDA-MB-468-X breast carcinoma xenografts (right column); control dot blots of varying murine DNA percentages are also depicted (left column); (I) The typical myoepithelial xenograft looks and shells out like a white glistening "pearl".




Fig. 1J. In situ immunocytochemistry profile of myoepithelial cells and their derived cell lines/xenografts. Myoepithelial cells (HMS-1) grow as a monolayer in cell culture.

reconciled with the fact that α 1-AT was probably less glycosylated in HMS-1. This relative underglycosylation caused α 1-AT from HMS-1 to migrate slightly further into the gel and accounted for its poorer reactivation following SDS-denaturation on reverse zymography as compared to the more highly glycosylated isoforms present in the malignant lines. The third trypsin serine proteinase inhibitor detected at 31 kDa was clearly not a degradation product of either PNII or α 1-AT as demonstrated by negative Western blot. The 31 kDa inhibitor was strongly expressed in HMS-1 and was either absent or nearly absent in all of the malignant lines examined. Whether this unidentified inhibitor is a novel inhibitor is being determined. In contrast to the above inhibitors, PAI-1 was expressed only slightly greater in HMS-1 compared to the majority of the malignant lines by both reverse zymographic and Western blot analysis. Neither PAI-2, PAI-3 or α 2-antiplasmin were detected by Western blot analysis in any of the cell lines. Antiplasmin activity as determined by photometric assay was completely absent as well. The most striking difference, however, between the strong proteinase inhibitor profile of HMS-1 and the profile of the malignant cell lines examined was in the expression of maspin. Intense maspin transcripts (3.0 and 1.6 kb) and protein (42 kDa) were identified in HMS-1 and HMS-1 CM respectively but were completely absent in all of the malignant lines examined (Fig. 2A). With its proteinase inhibitor profile of increased maspin, TIMP-1, PNII, α 1-AT and the 31 kDa inhibitor, HMS-1 bore strong resemblance to normal human mammary epithelial cells (HMEC) (Fig. 2A) except that the expression of all of these proteinase inhibitors including maspin was even more enhanced in HMS-1. Being derived from normal ducts and acini of the human breast, HMEC cultures likely contain myoepithelial as well as epithelial cells. Thus the resemblance of HMS-1 to HMEC further supported our contention that HMS-1, though immortal, expressed a well-differentiated myo-

Enzymes/Inhibitors	HMS-1	C8161	MCF-7	T47D	BT-549	MDA-MB-157	MDA-MB-231	Hs578T	A253	A431	Hs578Bst	HMEC	Methods
PROTEINASES													
72-kDa Gelatinase A	●	●	●	●	●	●	●	●	●	●	●	●	Z
92-kDa Gelatinase B	○	○	○	○	○	○	○	○	○	○	○	○	Z
Stromelysin-1	○	○	○	○	○	○	○	○	○	○	○	○	Z
u-PA	●	●	●	●	○	●	●	●	●	○	○	○	Z
t-PA	○	○	○	○	○	○	○	○	○	○	○	○	Z
Plasminogen	○	○	○	○	○	○	○	○	○	○	○	○	Z
INHIBITORS													
Maspin	●	○	○	○	○	○	○	○	○	○	○	○	W,N
TIMP-1	●	○	○	○	○	○	○	○	○	○	○	○	Z,N
Protease Nexin II	●	○	○	○	○	○	○	○	○	○	○	○	Z,W
α1-Antitrypsin	●	○	○	○	○	○	○	○	○	○	○	○	Z,W
31-kDa Inhibitor	●	○	○	○	○	○	○	○	○	○	○	○	Z
PAI-1	●	●	○	○	○	○	○	○	○	○	○	○	Z,W
PAI-2	○	○	○	○	○	○	○	○	○	○	○	○	W
PAI-3	○	○	○	○	○	○	○	○	○	○	○	○	W
Protease Nexin I	○	○	○	○	○	○	○	○	○	○	○	○	W
α2-Antiplasmin	○	○	○	○	○	○	○	○	○	○	○	○	W,C

Fig. 2A. Relative constitutive expression of diverse proteinase inhibitors and proteinases in myoepithelial cells (HMS-1) compared to various malignant cell lines. Z, direct or reverse zymography; W, western blot; N, northern blot; C, chromogenic substrate assay.

epithelial phenotype. In addition, since HMS-1 was a clonal line expressing a pure myoepithelial phenotype, it would be predicted to express certain myoepithelial-associated proteins such as maspin, α1-AT, PNII/APP, and TIMP-1 to a greater degree than HMEC. Predictably, the myofibroblast line, Hs578Bst, was strongly expressive of TIMP-1 but did not express maspin, PNII or the 31 kDa inhibitor (Fig 2A). The strong proteinase inhibitor profile exhibited by HMS-1 was shared by all of the myoepithelial xenografts including HMS-X, HMS-3X, and HMS-4X.

In the modified Matrigel invasion chamber used in this study, HMS-1 cells and their conditioned media (CM) dramatically inhibited invasion of four invasive breast carcinoma cell lines (Fig. 2C). The HMS-1 line was itself non-invasive in this chamber. Predictably, the anti-invasive effects of HMS-1 could be abolished by CHX (40 µg/ml) 24 hr pretreatment. HMS-1 CM inhibited invasion in a dose response fashion up to 30%±8% of control (p<.01). Pretreatment of HMS-1 with dexamethasone (.25 µM) produced a complete invasion-permissive phenotype (100% of control) whereas

	HMS-X, 3X, 4X		Normal Breast		DCIS	
	Cells	Matrix	ME [*]	Epi [†]	ME	Epi
S-100	++++ [§]	-	++++	-	++++	-
Maspin	++++	-	++++	+	++++	±
α 1-AT	++	++	++	-	++	-
PNII	++	+++	++	-	++	±
TIMP-1	++	+	++	-	++	-
PAI-1	+	±	+	+	+	+

Fig. 2B. Myoepithelial-related immunoreactivity in situ.

* myoepithelial cells; [†] epithelial cells; [§] +++++, intensely positive; +++, strongly positive; ++, positive; +, weakly positive; ±, equivocally positive; -, negative.

pretreatment with PMA (5 μ M) produced an essentially nonpermissive phenotype (2% of control) ($p < .05$) (Fig. 2D). The effects of dexamethasone and PMA were quite dramatic. The effects of other agents including RA, dB-cAMP, Na-But, and 5-AzaC showed either permissive or non-permissive trends but were less dramatic. PMA's induction of the nonpermissive phenotype began after 20 minutes pretreatment, was almost complete after 2 hr and maximized after 24 hr ($p < .05$). The induction of this nonpermissive phenotype correlated with the induction of a dramatic 5-fold increase in maspin secretion measured in HMS-1 CM (Fig. 2E). As a result of PMA treatment, both an immediate release (within 2 minutes) of maspin from HMS-1 cells occurred (Fig. 2E) as well as a more sustained secretion for at least 24 hr following PMA pretreatment (Fig. 2E). The increased maspin secretion was not on the basis of an increase in steady state maspin transcripts (Fig. 2E). PMA also resulted in a less dramatic 2-fold increase in both MMP-9 and TIMP-1 secretion. Dexamethasone's induction of an invasion-permissive phenotype in HMS-1 was not associated with a change in either maspin transcription or secretion. Immunoprecipitation with anti-maspin antibody at 1/100 dilution successfully removed all detectable maspin from myoepithelial cell CM (Fig. 2F). This CM lost its ability to inhibit invasion (Fig. 2F). Similar results were observed with the CM from the other myoepithelial lines (HMS-3 and HMS-4) studied. None of the non-myoepithelial cell CM inhibited invasion.

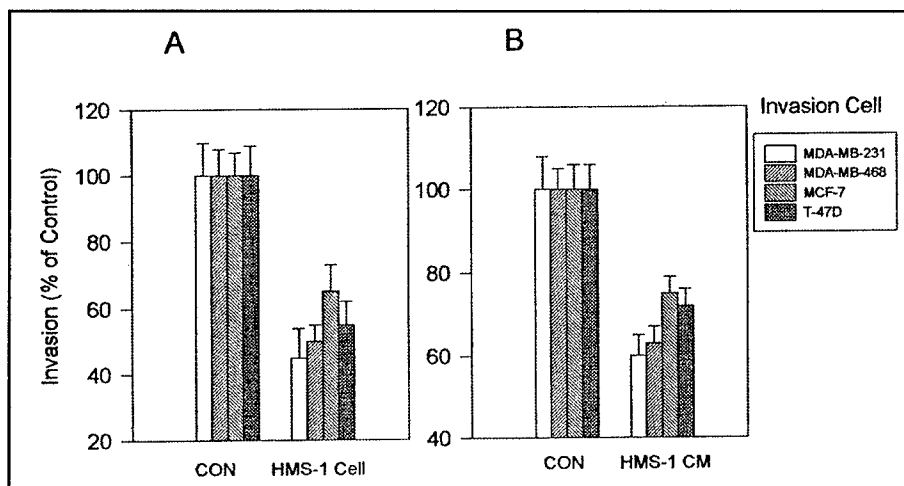


Fig. 2C. Effects of HMS-1 cells [A] and conditioned media (CM) [B] on MCF-7, T47D, MDA-MB-468 and MDA-MB-231 invasion. Both assays were performed in quadruplicate and show mean % invasion \pm standard deviation.

Maspin and Myoepithelial Cells Inhibit Tumor Angiogenesis

Human myoepithelial cells which surround ducts and acini of certain organs such as the breast form a natural border separating epithelial cells from stromal angiogenesis. Myoepithelial cell lines (HMS-1-6), derived from diverse benign myoepithelial tumors, all constitutively express high levels of active angiogenic inhibitors which include maspin, TIMP-1, thrombospondin-1 and soluble bFGF receptors but very low levels of angiogenic factors.¹⁰ Maspin recently has been shown conclusively to be an angiogenesis inhibitor.¹¹ As expected, our myoepithelial cell lines inhibit endothelial cell chemotaxis and proliferation. These myoepithelial cell lines sense hypoxia, respond to low O₂ tension by increased HIF-1 α but with only a minimal increase in VEGF and iNOS steady state mRNA levels. Their corresponding xenografts (HMS-X-6X) grow very slowly compared to their non-myoepithelial carcinomatous counterparts and accumulate an abundant extracellular matrix devoid of angiogenesis but containing bound angiogenic inhibitors. These myoepithelial xenografts exhibit only minimal hypoxia but extensive necrosis in comparison to their non-myoepithelial xenograft counterparts. These former xenografts inhibit local and systemic tumor-induced angiogenesis and metastasis presumably from their matrix-bound and released circulating angiogenic inhibitors. These observations collectively support the hypothesis that the human myoepithelial cell (even when transformed) is a natural suppressor of angiogenesis.

Myoepithelial cells in situ separate epithelial cells from stromal angiogenesis, and this seemingly banal observation serves to illustrate the fact that stromal angiogenesis never penetrates this myoepithelial barrier (Fig. 1C) raising the hypothesis that myoepithelial cells are natural suppressors of angiogenesis. This observation was reinforced by a microscopic, immunohistochemical and DNA analysis of our myoepithelial xenografts. Our diverse myoepithelial xenografts secrete and accumulate an abundant extracellular matrix which is devoid of blood vessels in routine hematoxylin

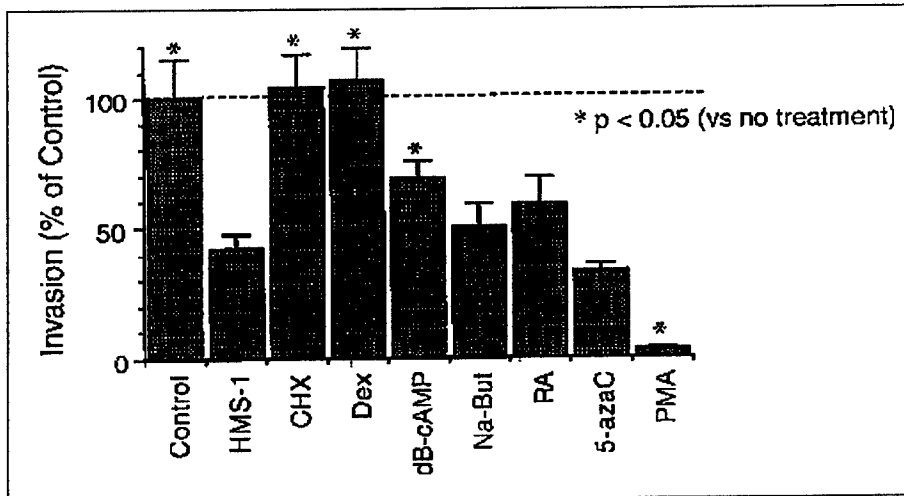


Fig. 2D. Effects of pharmacologic treatment of HMS-1 cells with various agents inducing permissive and non-permissive phenotypes: CHX, cyclohexamide; DEX, dexamethasone; dB-cAMP, N⁶,2'-O-dibutyryl adenosine 3':5'-cyclic monophosphate; Na-But, sodium butyrate; RA, all *trans* retinoic acid; 5-azaC, 5-azacytidine; PMA, phorbol 12-myristate 13-acetate.

and eosin staining (Fig. 1E; Fig. 1F; Fig. 1G) and vWf immunocytochemical staining in contrast to non-myoeptithelial xenografts which show bursts of blood vessels. Quantitation of vessel density in 10 HPFs reveals absent to low vessel density in the myoeptithelial xenografts compared to the non-myoeptithelial xenografts ($p < 0.01$). As mentioned previously, murine DNA Cot-1 analysis further reveals the absence of a murine component in the myoeptithelial xenografts. Since in the xenografts, angiogenesis would be murine in origin, the absence of a murine DNA component is another indication that angiogenesis is minimal. Interestingly the myoeptithelial xenografts grew slowly compared to the non-myoeptithelial xenografts, a feature which was not found in comparisons between the myoeptithelial *v* non-myoeptithelial cell lines.

To explain these *in vivo* observations, we analyzed the gene expression profiles of our myoeptithelial cell lines *v* non-myoeptithelial cell lines with respect to known angiogenic inhibitors and angiogenic factors. HMS-1, as a prototype myoeptithelial cell line, constitutively expressed none of the known angiogenic factors including bFGF, aFGF, angiogenin, TFG α , TGF β , TNF- α , VEGF, PD-ECGF, PIGF, IF α , HGF, and HB-EGF but rather expressed maspin, thrombospondin-1, TIMP-1 and soluble bFGF receptors at high levels; this was in contrast to a high angiogenic factor (which included bFGF, VEGF, TFG α , TGF β , HB-EGF, and PD-ECGF) to angiogenic inhibitor gene expression profile which was observed in non-myoeptithelial cell lines. Other myoeptithelial cell lines (HMS-2-6) exhibited an angiogenic inhibitor/angiogenic factor profile similar to that of HMS-1. Interestingly in 2M urea extracts of the myoeptithelial xenografts but not in any of the non-myoeptithelial xenografts, strong thrombospondin-1, TIMP-1 as well as plasminogen and prolactin fragments could be detected by Western blot. HMS-1 and HMS-1 CM (concentrated 10-100 fold) exerted a marked inhibition of endothelial migration and proliferation, both of which were abolished by pretreatment of the myoeptithelial cells with cyclohexamide or dexamethasone. HMS-1 cells themselves did not migrate in response to either K-SFM,

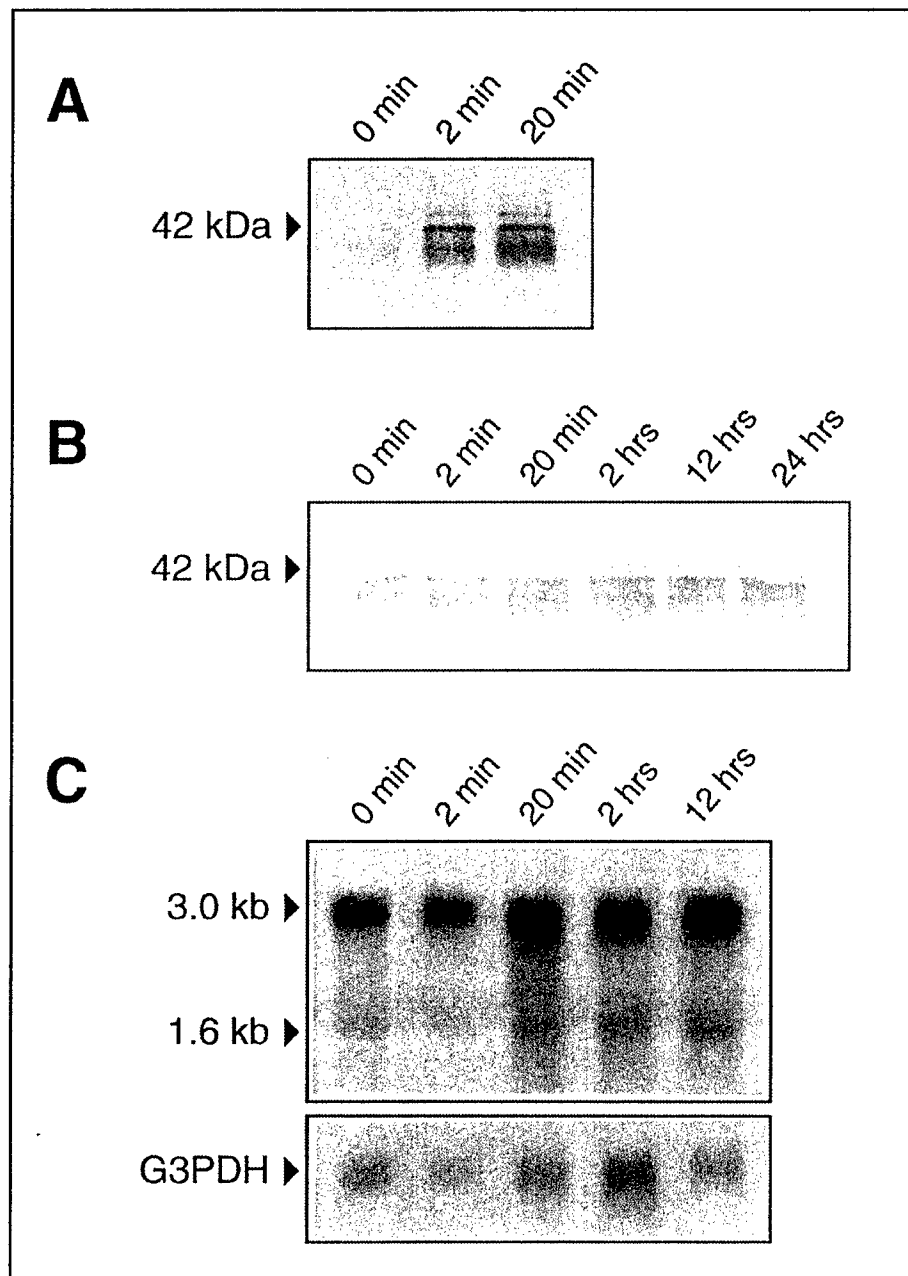


Fig. 2E. Immediate effects of PMA treatment on maspin secretion measured by Western blot of CM at designated times of PMA exposure [A]; delayed effects of PMA on maspin secretion measured by Western blot of CM 72 hours after PMA pretreatment for indicated time periods followed by removal of PMA [B]; Northern blot of maspin expression following exposure to PMA for indicated time periods [C].

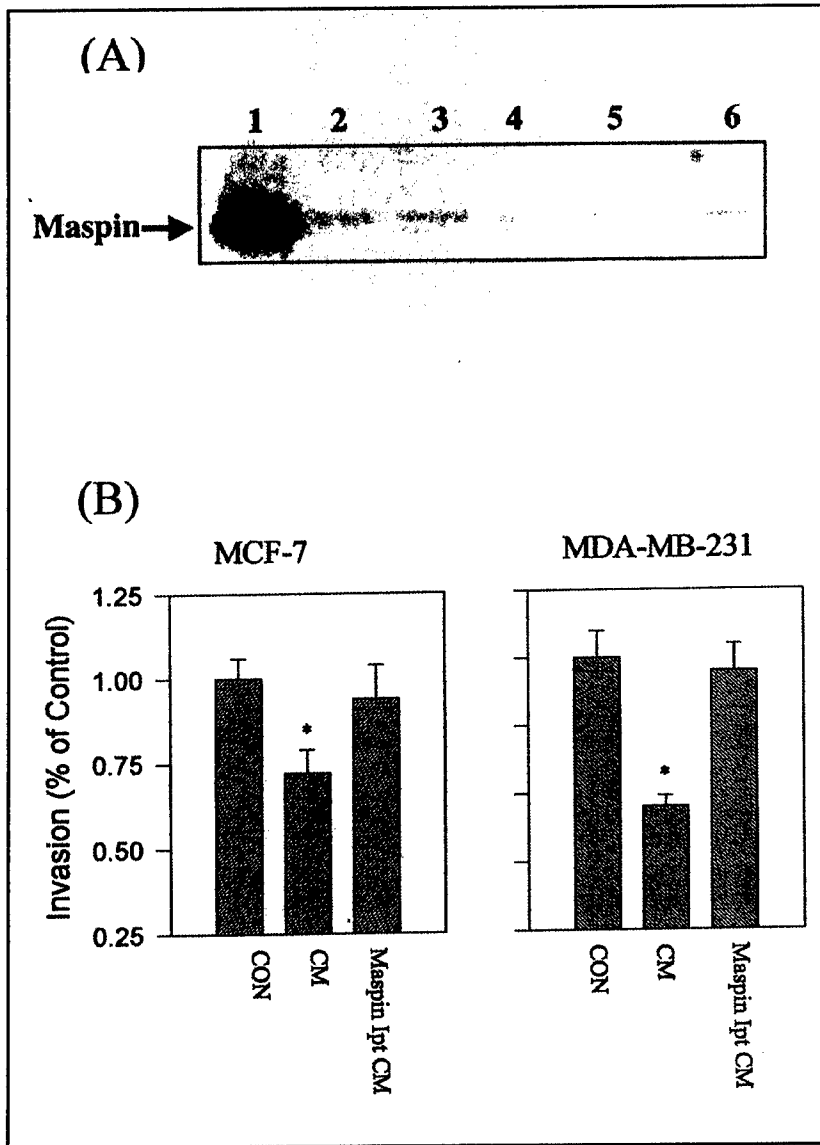


Fig. 2F. Maspin immunoprecipitation fraction [A] at various dilutions of maspin antibody (1/100), lane 1; (1/500), lane 2; (1/1000), lane 3; (1/2000), lane 4. Optimal dilution was 1/100 to achieve nearly 100% immunoprecipitation. Other serpin antibodies used including anti-PAI-1 (lane 5) and anti-PAI-2 (lane 6) resulted in only negligible cross-reacting immunoprecipitation of maspin. [B] Effects of HMS-1 25X CM and maspin-immunoprecipitated CM on breast carcinoma invasion. Control levels of invasion of designated breast carcinoma cell lines, MCF-7 and MDA-MB-231 were assigned arbitrary values of 1.0 and effects of CM and immunoprecipitated CM were expressed relative to these control levels. Results with other myoepithelial cell lines were similar. *indicates statistically significant differences compared to control ($p < 0.05$).

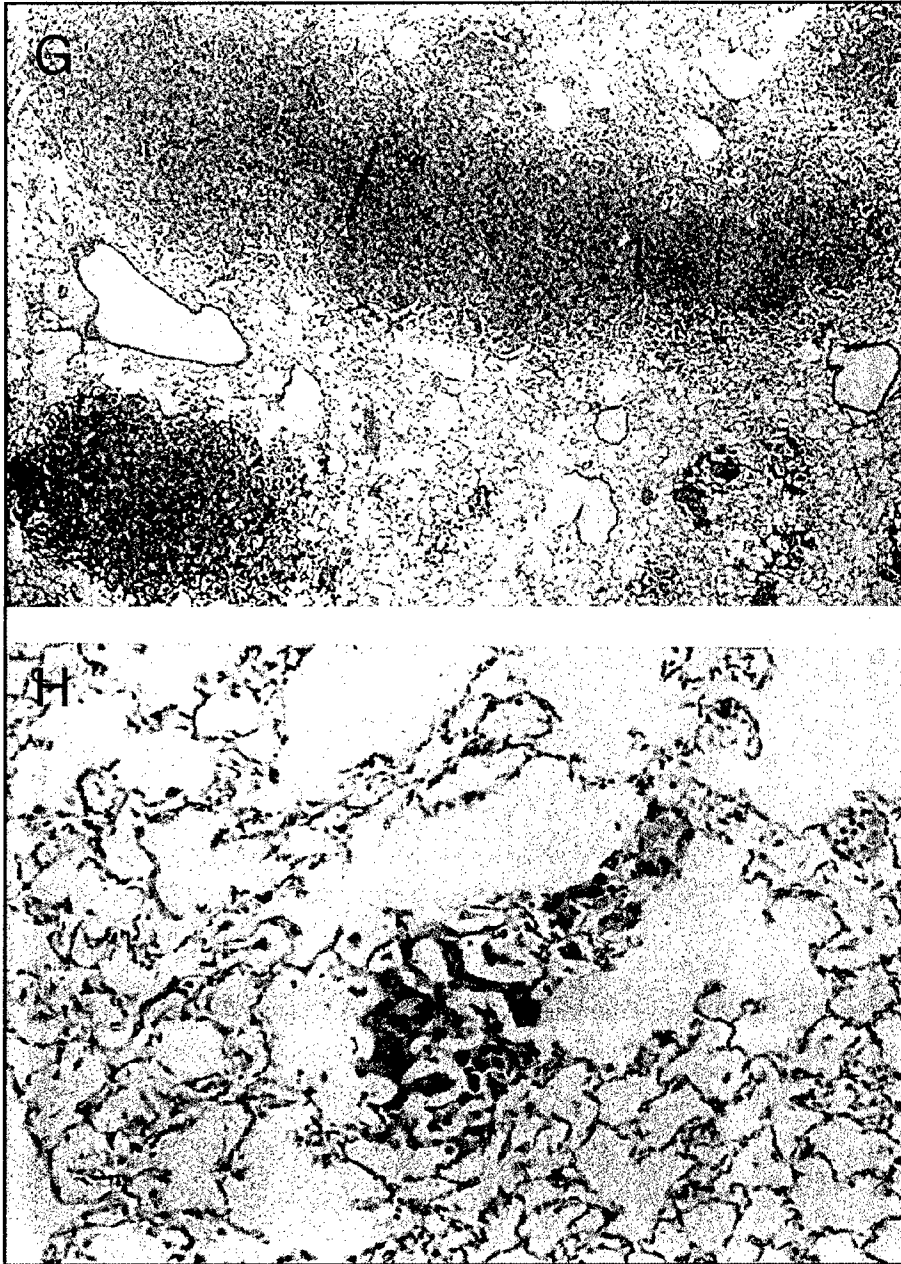


Fig. 2G & H. Differences in hematogenous pulmonary metastases with tail vein injected *neo*C8161 is in evidence in mice harboring non-myoepithelial xenografts (G) *v* myoepithelial xenografts (H). The number and size of metastatic colonies in mid-longitudinal cross section of lung was determined by digital image analysis and expressed as mean \pm standard error.

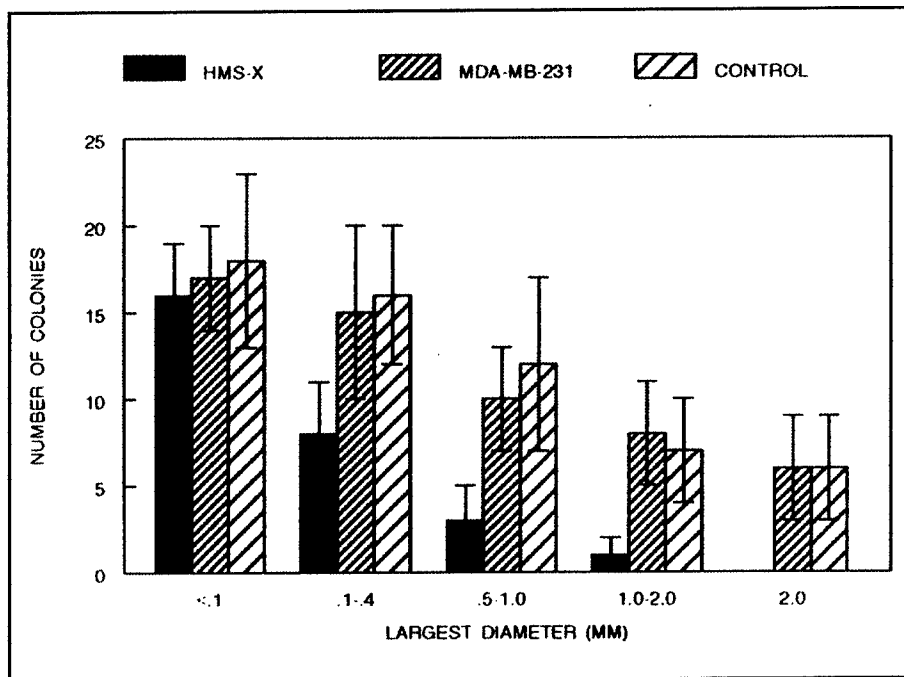


Fig. 21. Quantitation of pulmonary metastases revealed similar numbers of colonies in all three groups but a marked decrease in size in the group harboring the myoepithelial xenografts. Results depict a representative myoepithelial xenograft, HMS-X, a representative non-myoepithelial xenograft, MDA-MB-231, and control (no xenograft). Other myoepithelial and non-myoepithelial xenografts recapitulated these results.

FCS, or bFGF. When mixed with UVE, HMS-1 cells reduced endothelial migration to $12\% \pm 6\%$ of control ($p < 0.01$). HMS-1 concentrated CM reduced migration to $8\% \pm 7\%$ of control ($p < 0.01$). All of the non-myoepithelial malignant human cell lines studied stimulated both endothelial migration and proliferation. Concentrated CM from HMS-1, when fractionated on a heparin-Sepharose column, inhibited endothelial proliferation to $47\% \pm 10\%$ of control ($p < 0.01$). This inhibitory activity was present only in the 1.5-2.0M gradient fraction. Pretreatment of HMS-1 cells with PMA resulted in a 2-5 fold increase in endothelial antiproliferative inhibitory activity in both unfractionated CM as well as in the heparin-Sepharose fraction. Western blot of the heparin-Sepharose column fractions revealed that the 1.5-2.0M NaCl fraction contained thrombospondin-1. Immunoprecipitation of this fraction with anti-thrombospondin was effective at removing all thrombospondin-1 but decreased endothelial antiproliferative activity by only 50% raising the possibility that other angiogenic inhibitors including maspin were present in this fraction. The other myoepithelial cell lines (HMS-2-6) exhibited similar anti-angiogenic inhibitory activity in their fractionated and unfractionated CM. Therefore it is likely that both maspin and thrombospondin-1 are anti-angiogenesis effector molecules of myoepithelial cells.

To further explain our *in vivo* observations of minimal angiogenesis in our myoepithelial xenografts, *in vitro* and *in vivo* hypoxia studies were carried out. Non-myoepithelial xenografts, e.g., MDA-MB-231 exhibited florid hypoxia but only minimal

necrosis when they reached a size of 2.0 cm. In contrast, the myoepithelial xenografts exhibited only minimal hypoxia but prominent necrosis ($p < 0.001$) at the same size of 2.0 cm. Quantitation of the areas of hypoxia (pimonidazole immunoreactivity) and areas of necrosis in the myoepithelial *v* non-myoepithelial xenografts suggested that in the myoepithelial tumors where angiogenesis is minimal hypoxic areas progress to necrosis rapidly whereas in the non-myoepithelial tumors hypoxic areas accumulate but do not progress to necrosis presumably from the angiogenesis which the hypoxia elicits. Comparative analysis of myoepithelial *v* non-myoepithelial cell lines to low O_2 tension revealed that while both cell lines sense hypoxia in that they responded by increasing HIF-1 α , the myoepithelial lines upregulated their steady state mRNA levels of the downstream genes, VEGF and iNOS to a lesser extent than the carcinoma lines suggesting the possibility of decreased transactivation of HRE. Specifically we observed an approximate 1.7-fold increase in VEGF (1.1-fold increase in iNOS) in myoepithelial cells in response to hypoxia compared to an approximate 2.5-fold increase in VEGF (1.5-fold increase in iNOS) in carcinoma cell lines in response to hypoxia. Although these fold differences by themselves were not impressive, the absolute levels of VEGF (and iNOS) expressed in carcinoma cells in response to hypoxia were 2.5-fold greater for VEGF (and 1.7-fold greater for iNOS) than the levels of VEGF (and iNOS) expressed in myoepithelial cells in response to hypoxia. Therefore it can be concluded that myoepithelial cells did not express VEGF or iNOS in response to hypoxia to nearly the same extent as carcinoma cells. To study both local and systemic effects of myoepithelial cells on metastasis, spontaneously metastasizing tumor cells were injected into our myoepithelial xenografts. The highly metastatic *neoC8161* cells injected into the myoepithelial xenografts could be recovered in significant numbers although the numbers of clones recovered were less than those recovered from the nonmyoepithelial xenografts. Histological analysis of the extirpated xenografts revealed *neoC8161* cells actively invading through all of the nonmyoepithelial xenografts in contrast to the appearance the myoepithelial xenografts where the *neoC8161* cells were confined to the immediate areas around the injection site. Pulmonary metastases of *neoC8161* were completely absent in the myoepithelial xenograft-injected group whereas they were quite numerous in the nonmyoepithelial group ($p < 0.001$). Analysis of extirpated myoepithelial xenografts containing injected *neoC8161* cells contained no evidence of murine angiogenesis by either vWf immunocytochemical studies or murine DNA Cot-1 analysis whereas a similar analysis of extirpated *neoC8161* injected-nonmyoepithelial xenografts showed an increase in murine angiogenesis by both methods. This suggested that either the matrices of our myoepithelial xenografts or gene product(s) of the myoepithelial cells or both were inhibiting *neoC8161*-induced angiogenesis *in vivo*. We, in fact, found evidence of maspin, thrombospondin-1, TIMP-1, soluble bFGF receptors, prolactin and plasminogen fragments within 2M urea extracts of our myoepithelial xenografts. In tail vein injection studies of *neoC8161*, in mice harboring the myoepithelial xenografts, *neoC8161* formed smaller pulmonary colonies than in mice harboring non-myoepithelial xenografts or in control mice (no xenografts) ($p < 0.01$) (Fig. 2G, 2H, 2I). In a vWf factor immunocytochemical analysis of these smaller colonies in the mice harboring the myoepithelial xenografts, angiogenesis was minimal. These latter studies suggest the presence of circulating angiogenesis inhibitors released by the myoepithelial xenografts. Just recently we have demonstrated circulating maspin in mice harboring myoepithelial xenografts (see below).

Maspin and Myoepithelial Cells Can Be Manipulated Physiologically

Since PMA and dexamethasone were effective at pharmacologically altering maspin levels and the myoepithelial phenotype, we wondered whether physiological agents could do so as well. Because previous basic and clinical studies had examined the role of estrogen agonists and antagonists on human breast cancer cells and because issues of hormone replacement therapy (HRT) and tamoxifen chemoprevention are such timely issues in breast cancer, we wondered whether or not hormonal manipulations might affect myoepithelial cells in vitro as far as their paracrine suppressive activities on breast cancer were concerned. We recently demonstrated¹² that treatment of myoepithelial cells with tamoxifen but not 17- β estradiol increases both maspin secretion and invasion-blocking ability. 17- β Estradiol however competes with these suppressive effects of tamoxifen suggesting that the mechanism of tamoxifen action is estrogen receptor mediated. Myoepithelial cells lack ER- α but express ER- β . Tamoxifen, but not 17- β estradiol, increases AP-1 CAT but not ERE-CAT activity. Again, 17- β estradiol competes with the transcription-activating effects of tamoxifen. These experiments collectively suggest that the actions of tamoxifen on the increased secretion of maspin by myoepithelial cells may be mediated through ER- β and the transactivation of an ER-dependent AP-1 response element.

As mentioned previously, immunoprecipitation of maspin from HMS-1 CM (Fig. 2F) reversed the anti-invasive effects of myoepithelial CM on breast carcinoma cell invasion in vitro. Tamoxifen treatment of HMS-1 resulted in a 2-3-fold increase in maspin secretion with increasing doses of tamoxifen and increasing times of exposure (Fig. 3A). 17- β Estradiol, in contrast, exerted no effects on maspin secretion and completely abolished the maspin stimulatory effects of tamoxifen in competition experiments. Tamoxifen's increase in maspin secretion was not due to an increase in steady state maspin mRNA levels which were essentially unchanged by this treatment. Myoepithelial cell lines lacked ER- α expression (Fig. 3B) but uniformly expressed ER- β (Figure 3B). Because the action of estrogen agonists/antagonists bound to estrogen receptors (either ER- α or ER- β) activates downstream genes containing either a classical ERE or an ER-dependent AP-1 response element, myoepithelial cell lines were transfected with CAT-reporter constructs fused to heterologous promoters containing the human estrogen response element (ERE-tk-CAT) or AP-1-tk-CAT. Tamoxifen (10^{-7} M) increased AP-1-CAT activity 3 fold (Fig. 3C). This effect was not observed with 17- β estradiol. Furthermore 17- β estradiol (10^{-5} M) competed with and blocked the effects of tamoxifen (10^{-7} M) (Fig. 3C). 17- β estradiol (10^{-7} M) did increase ERE-CAT activity but tamoxifen (10^{-7} M) did not.

Maspin and Myoepithelial Cells Are Potential Surrogate End Point Markers and Tumor Markers

Since maspin and myoepithelial cells seem intimately associated, and since myoepithelial cells are ubiquitous components of the ductal-lobular units of the breast and other organs which exhibit branching morphogenesis, we hypothesized that maspin might be detectable in fluid secreted by these ductal-lobular units. Since there has been a lot of recent interest in breast ductal fluid and breast nipple aspirates, especially, we measured maspin by Western blot and found it to be present in both nipple aspirates




Fig. 3A. Effects of tamoxifen (10^{-7} M) treatment on maspin secretion for various times (hr) of tamoxifen exposure. 17β -Estradiol exerted no stimulatory effects. In competition experiments, increasing concentrations of 17β -estradiol completely blocked tamoxifen's stimulation of maspin secretion.

and ductal fluid (Fig. 4A) (Unpublished observations). This observation indicates that ductal fluid is not a mere transudate of blood or serum and that it is not a product of only epithelial cells (although epithelial protein products such as casein, lactalbumin and carcinoembryonic antigen (CEA) are certainly present). Ductal fluid also reflects a significant contribution from myoepithelial cells. From this observation we are currently studying groups of patients to see if their maspin levels serve to stratify them. We are currently analyzing ductal fluid collected following cannulation and washing of selected ducts in patients with microcalcifications on screening mammography who are about to undergo either excisional or core biopsy. Paired comparisons of maspin levels in ductal fluid obtained from ducts harboring microcalcifications or DCIS and normal ducts from the same patients are also being made. Maspin levels can be correlated with the histopathology surrounding the microcalcifications. It is anticipated that some of these patients will exhibit normal ductal histopathology surrounding their microcalcifications, some will harbor proliferations like hyperplasia, adenosis, ADH, and DCIS and still others invasive carcinoma. The screening value of maspin levels in all of these patients can be determined. Measurements of myoepithelial maspin in ductal fluid will be compared to levels of a breast epithelial cell marker such as CEA. CEA has been observed to be increased in nipple secretions and ductal fluid in patients with ductal hyperplasia. Hence the maspin/CEA ratio might be predictive of risk with increased maspin/CEA correlating with normalcy and decreased maspin/CEA correlating with either high risk, microcalcifications and/or precancerous histopathology. In this sense maspin can be used as a surrogate end point marker to predict either the risk of DCIS or the likelihood that DCIS will progress to invasive breast cancer.

Another interesting observation with respect to the use of myoepithelial maspin as a marker, this time, a tumor marker, is the observation that maspin can be detected in normal saliva but that it is markedly elevated in saliva secreted from a salivary gland neoplasm and that it is also elevated in murine serum in mice harboring human myoepithelial xenografts (Fig. 4B) (unpublished observations). Most salivary gland neoplasms are thought to be myoepithelial in origin. These include mixed tumors, basal

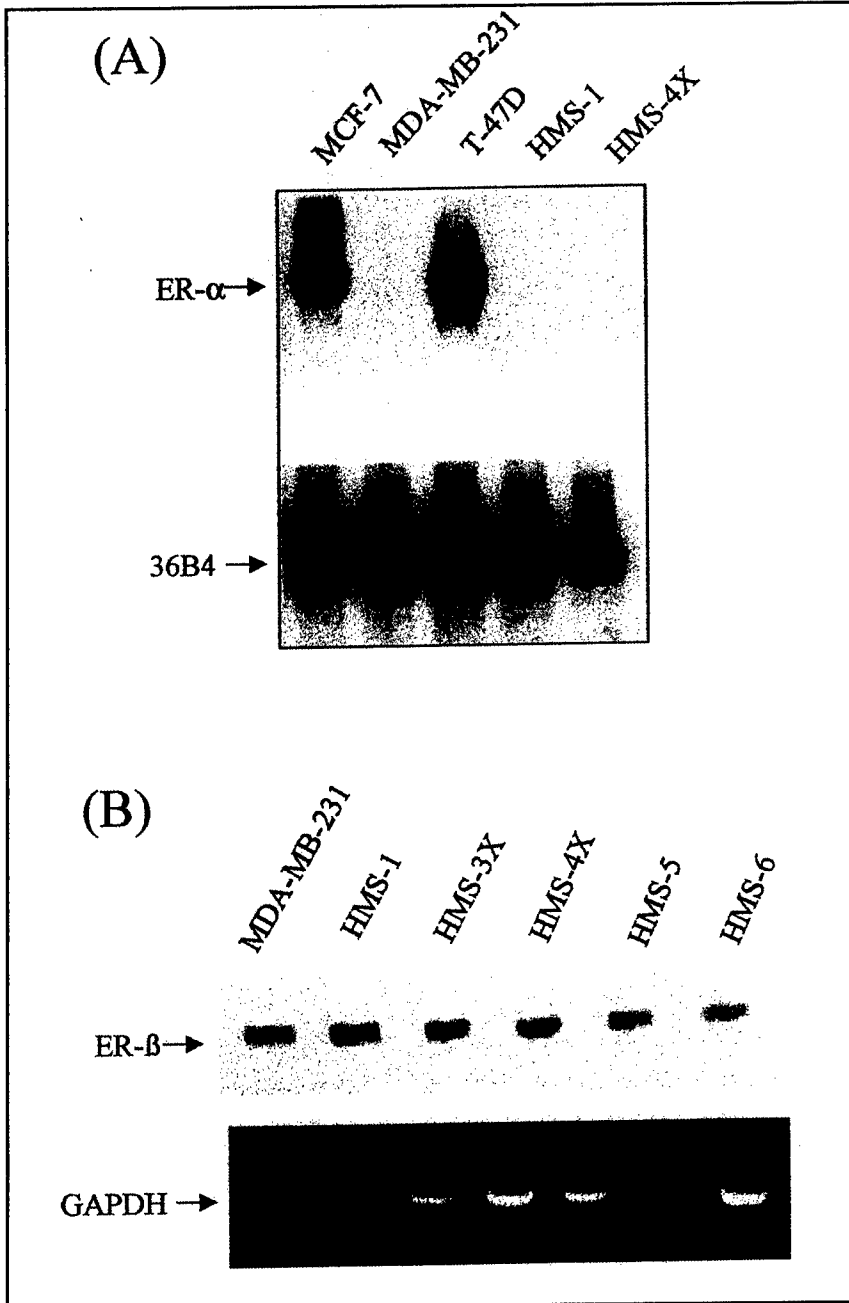


Fig. 3B. Expression of ER- α and ER- β in representative myoepithelial cell lines. [A] Northern blot analysis, ER- α expression. Normalization was with 36B4. [B] ER- β expression by RT-PCR. GAPDH served as a housekeeping control.

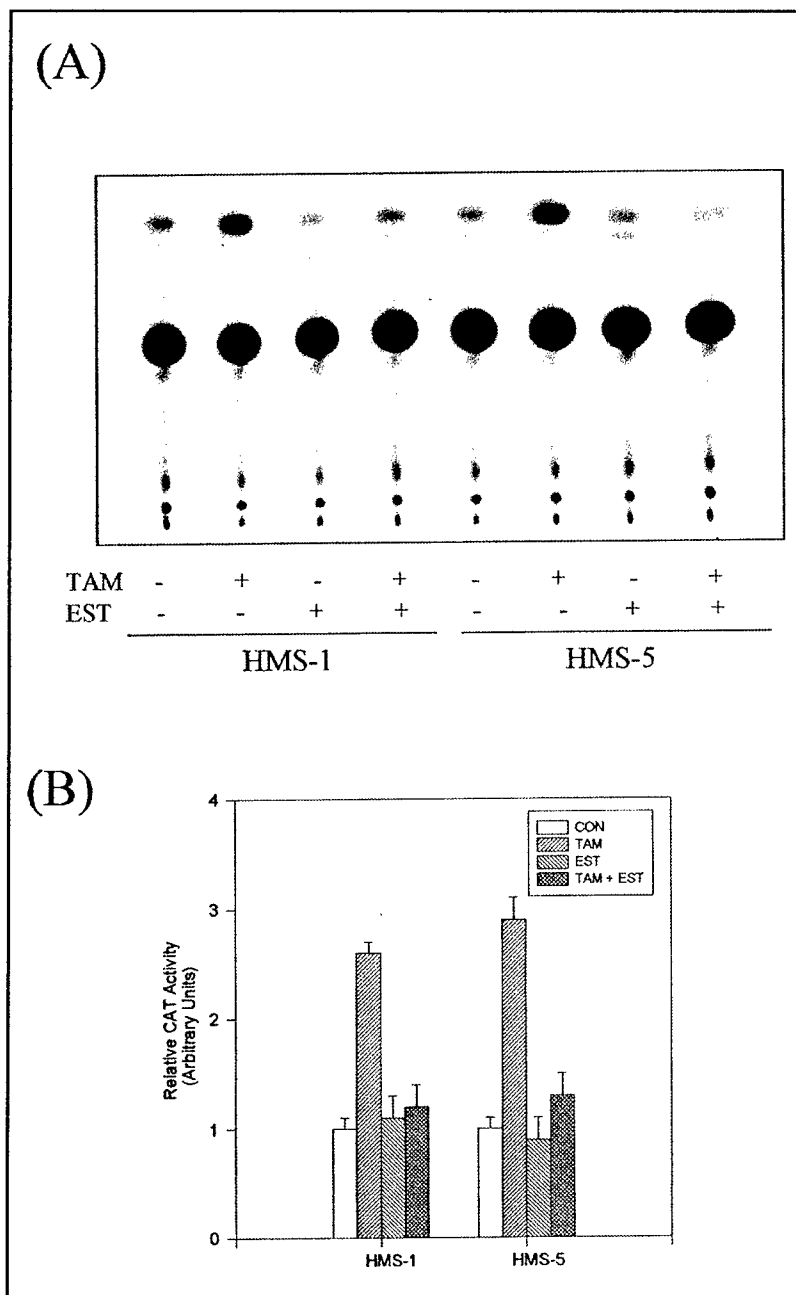


Fig. 3C. Tamoxifen (10^{-7} M) stimulation of AP-1-CAT activity in representative myoepithelial cell lines, HMS-1 and HMS-5 [A]. $17\text{-}\beta$ Estradiol (10^{-7} M) exerted no such stimulatory effects and blocked the effects of tamoxifen at high doses (10^{-5} M). [B] Results depicted are the means of three independent experiments. Error bars represent standard errors

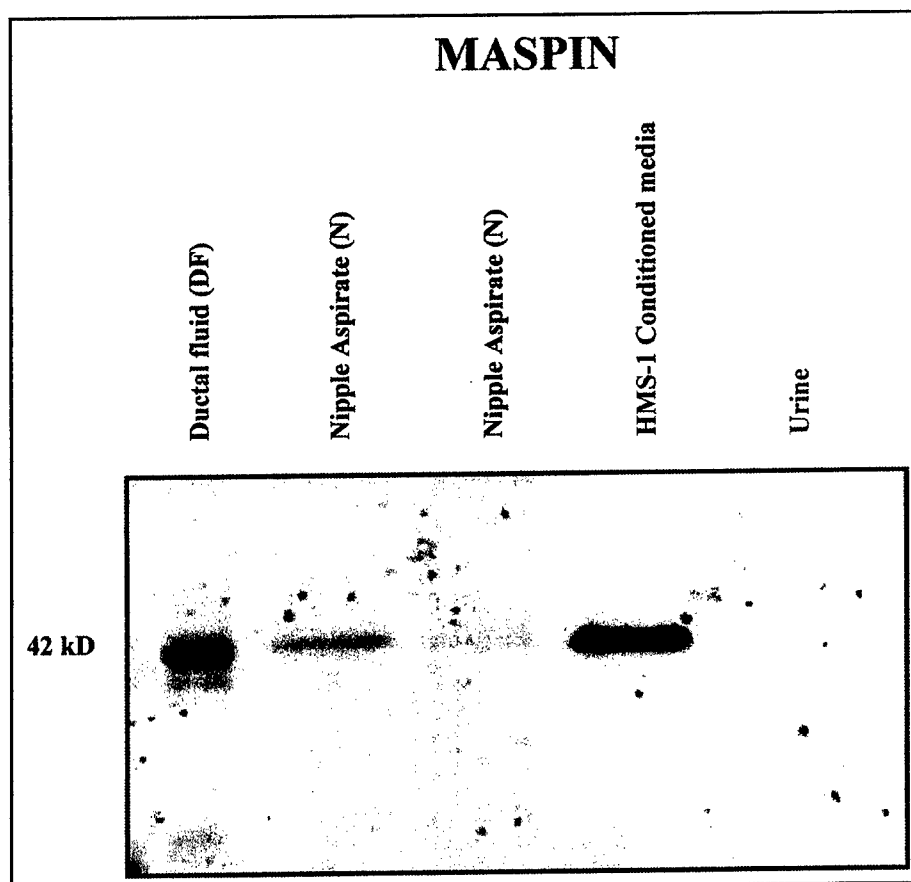


Fig. 4A. Nipple aspirate fluid (N) collected by nipple suction or ductal fluid (DF) collected by selected ductal cannulation can be studied for protein composition. In the former method (nipple aspiration), the contributions of each of the ductal systems can not be distinguished from each other; however in the latter method (ductal cannulation), each of the ductal systems can be separately analyzed and therefore ductal fluid from ducts harboring DCIS, for example, can be compared with ductal fluid from normal ducts in the same patient. Both nipple aspirate fluid and ductal fluid reflect the secretory contributions of the ductal-lobular units which are composed of both myoepithelial cells as well as epithelial cells. Maspin, a secretory product of myoepithelial cells, can be detected as a 42 kDa protein on Western blot from both nipple aspirate fluid (N) as well as ductal fluid (DF). Conditioned media (CM) from HMS-1, a myoepithelial cell line, is also intensely positive for maspin. Urine is negative.

cell adenomas, basal cell adenocarcinomas, and adenoid cystic carcinomas. It was human tumors of these types that originally gave rise to our myoepithelial cell lines/xenografts that led to a dissection of the myoepithelial phenotype and to our observations concerning myoepithelial maspin. If screening saliva for maspin shows promise for detecting small incipient salivary gland neoplasms, then myoepithelial maspin will show its utility as a tumor marker. So, in summary, our findings indicate that maspin and myoepithelial cells contribute to the structural and functional integrity of the ductal-lobular units of different organs, and alterations in maspin levels in fluid from these units may reflect disease states (Fig.4C).

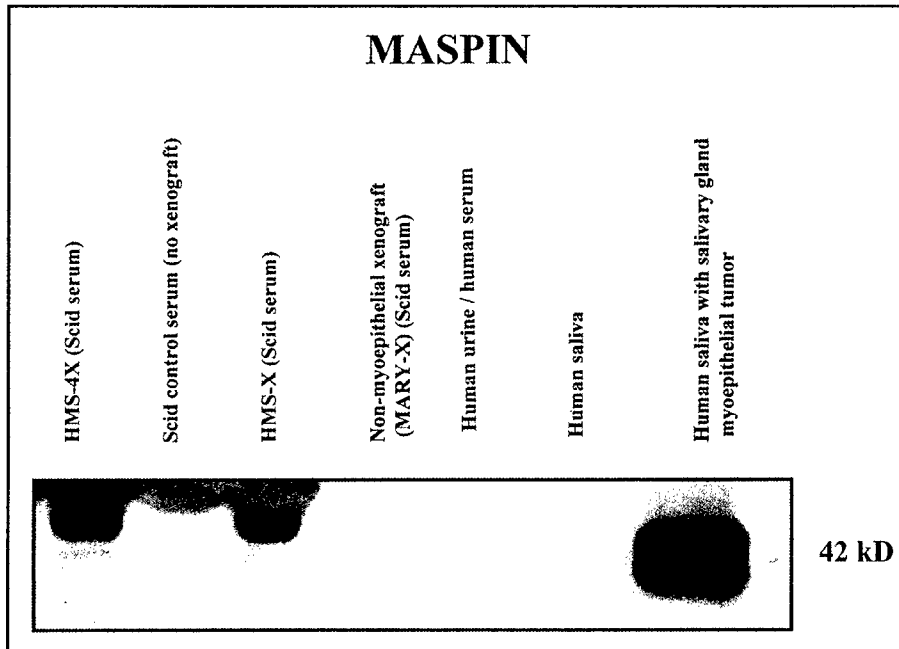


Fig. 4B. The contribution of myoepithelial tumors to maspin secretion in bodily fluids is demonstrated. In the Scid mouse, mice with >1 cm human myoepithelial xenografts (HMS-X, HMS-4X) exhibit circulating maspin levels in serum. Mice harboring no xenograft or a non-myoepithelial xenograft (MARY-X, an inflammatory breast carcinoma xenograft) contain no detectable circulating maspin. Human saliva in normal patients contain low levels of maspin, presumably from the myoepithelial cells in the salivary gland ductal-lobular units. Saliva from patients with benign salivary gland myoepithelial tumors show markedly elevated maspin.

Future Directions

The observations that myoepithelial cells secrete maspin in large quantities whereas carcinoma cells do not suggest that maspin and myoepithelial cells exert pleiotropic suppressive effects on tumor progression. Since maspin is both a proteinase inhibitor, a locomotion inhibitor and an angiogenesis inhibitor, the diverse actions of maspin may largely explain the pronounced anti-invasive and anti-angiogenic effects of myoepithelial cells on carcinoma and pre-carcinoma cells (13-24). Clearly, maspin and myoepithelial cells have more than marker value. Circulating maspin may have value as an anti-angiogenic agent. We need to better understand what it is about the myoepithelial phenotype that allows for high constitutive expression and secretion of maspin. Studies of the maspin promoter and *cis/trans* interactions within the myoepithelial cell seem to be an attractive line of further research. We also need to better understand the mechanism by which certain pharmacological agents such as PMA and certain physiological agents such as tamoxifen bolster myoepithelial secretion of maspin. With this understanding we may be able to design small less toxic molecules that have the same effect. We need to better exploit the intricate paracrine and local relationships which exist between myoepithelial cells and epithelial cells (precancerous and cancerous) in the breast and other organs. This is especially important and timely as

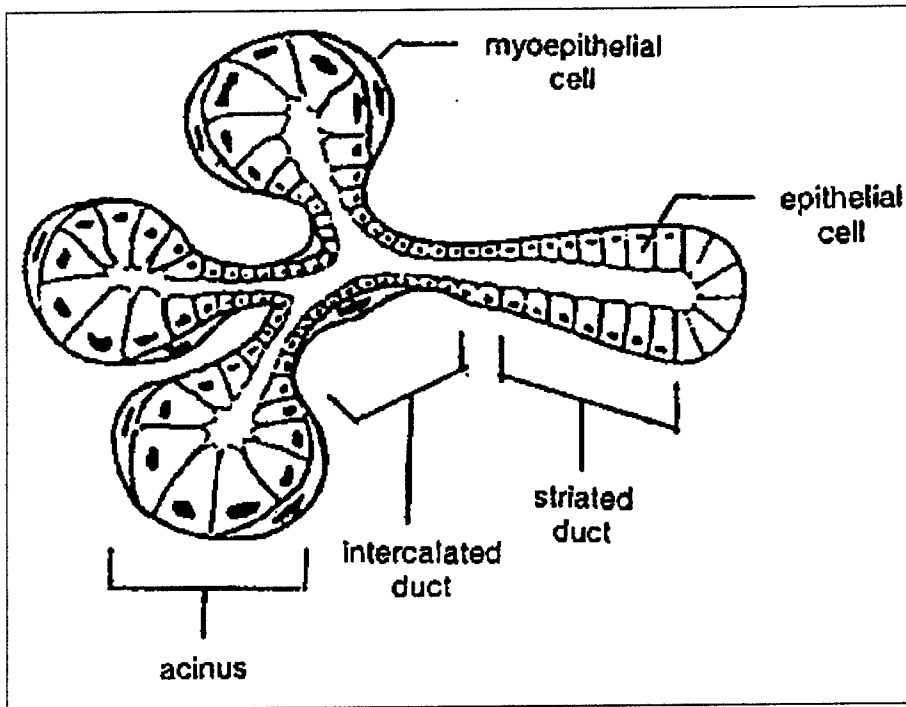


Fig. 4C. Schematic depicts the ductal-lobular unit of the breast and/or salivary gland and emphasizes the point that both myoepithelial cells as well as epithelial cells contribute to the integrity of this unit and to the composition of ductal fluid and saliva. In the case of invasive breast cancer, the integrity of the myoepithelial layer may be compromised and maspin levels may decrease. In the case of a myoepithelial tumor of salivary glands, the secretion of maspin into saliva may serve as a tumor marker.

intraductal approaches through the nipple are gaining in popularity as a means of screening women who are at risk for developing breast cancer. These intraductal approaches really exploit the local myoepithelial/epithelial relationships which exist. Screening for maspin levels as a surrogate end point marker is only the beginning. One could envision delivering intraductal gene therapy designed to exploit the inherent differences between myoepithelial and epithelial cells. One could target and destroy the epithelial cells selectively sparing the myoepithelium or alternately target the myoepithelial cells with a vector which bolsters its secretion of maspin. If the myoepithelial defense can be bolstered in this manner, perhaps this natural barrier which normally inhibits invasion for years can be made into an impervious barrier which inhibits invasion forever. At least that is one vision of scientists who are interested in maspin and myoepithelial cells.

Abbreviations

CM, conditioned medium; FCS, fetal calf serum; DCIS, ductal carcinoma in situ; PN-II/APP, protease nexin II/ β -amyloid precursor protein; MMP, matrix metalloproteinase; TIMP, tissue inhibitor of metalloproteinase; uPA, urokinase-type

plasminogen activator; PAI, plasminogen activator inhibitor; α 1-AT, α 1-antitrypsin; HMEC, human mammary epithelial cells; K-SFM, keratinocyte serum-free medium; vWf, von Willebrand factor; CHX, cyclohexamide; dB-cAMP, N⁶,2'-O-dibutyryladenine 3':5'-cyclic monophosphate; Na-But, sodium butyrate; RA, all *trans* retinoic acid; 5-azaC, 5-azacytidine; PMA, phorbol 12-myristate 13-acetate; UVE, umbilical vein endothelial cells; bFGF, basic fibroblast growth factor.

References

1. Cavenee WK. A siren song from tumor cells. *J Clin Invest* 1993; 91:3.
2. Liotta LA, Steeg PS, Stetler-Stevenson WG. Cancer metastasis and angiogenesis: An imbalance of positive and negative regulation. *Cell* 1991; 64:327-336.
3. Safarians S, Sternlicht MD, Freiman CJ, Huaman JA, Barsky SH. The primary tumor is the primary source of metastasis in a human melanoma/SCID model: Implications for the direct autocrine and paracrine epigenetic regulation of the metastatic process. *Int J Cancer* 1996; 66:151-158.
4. Folkman J, Klagsbrun M. Angiogenic factors. *Science* 1987; 235:442-447.
5. Cornil I, Theodorescu D, Man S, Herlyn M, Jambrosic J, Kerbel RS. Fibroblast cell interactions with human melanoma cells affect tumor cell growth as a function of tumor progression. *Proc Natl Acad Sci USA* 1991; 88:6028-6032.
6. Guelstein VI, Tchypsheva TA, Ermilova VD, Ljubimov AV. Myoepithelial and basement membrane antigens in benign and malignant human breast tumors. *Int J Cancer* 1993; 53:269-277.
7. Cutler LS. The role of extracellular matrix in the morphogenesis and differentiation of salivary glands. *Adv Dent Res* 1990; 4:27-33.
8. Sternlicht MD, Safarians S, Calcaterra TC, Barsky SH. Establishment and characterization of a novel human myoepithelial cell line and matrix-producing xenograft from a parotid basal cell adenocarcinoma. *In Vitro Cell Dev Biol* 1996; 32:550-563.
9. Sternlicht MD, Kedeshian P, Shao ZM, Safarians S, Barsky SH. The human myoepithelial cell is a natural tumor suppressor. Characterizations of the extracellular matrix and proteinase inhibitor content of human myoepithelial tumors. *Clin Cancer Res* 1997; 3:1949-1958.
10. Nguyen M, Lee MC, Wang JL, Tomlinson JS, Shao ZM, Barsky SH. The human myoepithelial cell displays a multifaceted anti-angiogenic phenotype. *Oncogene* 2000; 19:3449-3459.
11. Zhang M, Volpert O, Shi YH, Bouck N. Maspin is an angiogenesis inhibitor. *Nature Med* 2000; 6:196-199.
12. Shao ZM, Radziszewski WJ, Barsky SH. Tamoxifen enhances myoepithelial cell suppression of human breast carcinoma progression by two different effector mechanisms. *Cancer Lett* 2000; 157:133-144.
13. Andreassen PA, Georg B, Lund LR, Riccio A, Stacey SN. Plasminogen activator inhibitors: Hormonally regulated serpins. *Mol Cell Endocrinol* 1990; 68:1-19.
14. Albini A, Iwamoto Y, Kleinman HK, Martin GS, Aaronson SA, Kozlowski JM et al. A rapid *in vitro* assay for quantitating the invasive potential of tumor cells. *Cancer Res* 1987; 47:3239-3245.
15. Kataoka H, Seguchi K, Iwamura T, Moriyama T, Nabeshima K, Kono M. Reverse-zymographic analysis of protease nexin-II/amyloid b protein precursor of human carcinoma cell lines, with special reference to the grade of differentiation and metastatic phenotype. *Int J Cancer* 1995; 60:123-128.
16. Narindrasorasak S, Lowery DE, Altman RA, Gonzalez-DeWhitt PA, Greenberg BD, Kisilevsky R. Characterization of high affinity binding between laminin and Alzheimer's disease amyloid precursor proteins. *Lab Invest* 1992; 67:643-652.
17. Rao CN, Liu YY, Peavey CL, Woodley DT. Novel extracellular matrix-associated serine proteinase inhibitors from human skin fibroblasts. *Arch Biochem Biophys* 1995; 317:311-314.

18. Zou Z, Anisowicz A, Hendrix MJC, Thor A, Neveu M, Sheng S et al. Maspin, a serpin with tumor-suppressing activity in human mammary epithelial cells. *Science* 1994; 263:526-529.
19. Hopkins PCR, Whisstock J. Function of maspin. *Science* 1994; 265:1893-1894.
20. Pemberton PA, Wong DT, Gibson HL, Kiefer MC, Fitzpatrick PA, Sager R et al. The tumor suppressor maspin does not undergo the stressed to relaxed transition or inhibit trypsin-like serine proteases: Evidence that maspin is not a protease inhibitory serpin. *J Biol Chem* 1995; 270:15832-15837.
21. Sheng S, Pemberton PA, Sager R. Production, purification, and characterization of recombinant maspin proteins. *J Biol Chem* 1994; 269:30988-30993.
22. Folkman J. Clinical applications of research on angiogenesis. *N Engl J Med* 1995; 333:1757-1763.
23. Roberts DD. Regulation of tumor growth and metastasis by thrombospondin-1. *FASEB J* 1996; 10:1183-1191.
24. Weinstat-Saslow DL, Zabrenetzky VS, VanHoutte K, Frazier WA, Roberts DD, Steeg PS. Transfection of thrombospondin 1 complementary DNA into a human breast carcinoma cell line reduces primary tumor growth, metastatic potential, and angiogenesis. *Cancer Res* 1994; 54:6504-6511.

Fiberoptic ductoscopy for breast cancer patients with nipple discharge

K.-W. Shen,¹ J. Wu,¹ J.-S. Lu,¹ Q.-X. Han,¹ Z.-Z. Shen,¹ M. Nguyen,² S. H. Barsky,³ Z.-M. Shao¹

¹ Department of Surgery, Cancer Hospital/Cancer Institute, Shanghai Medical University, Shanghai, 200032, People's Republic of China

² Department of Surgery, UCLA School of Medicine, Los Angeles, CA 90024, USA

³ Department of Pathology and Revlon/UCLA Breast Center, UCLA School of Medicine, Los Angeles, CA 90024, USA

Received: 29 November 2000/Accepted in final form: 21 December 2000/Online publication: 7 May 2001

Abstract

Background: Breast cancer and precancer are thought to originate in the lining of the milk duct, but until recently, we have not had direct access to this area other than in tissue removed blindly by core biopsy or fine-needle aspiration. Fiberoptic ductoscopy (FDS) is an emerging technique that allows direct visual access of the ductal system of the breast through nipple orifice cannulation and exploration. To date, this technique has been used only in pilot studies. Previously, we have demonstrated that fiberoptic ductoscopy in patients with and without nipple discharge is a safe and effective means of visualizing the intraductal lesion. When combined with cytology, it is a screening technique that has high predictive value.

Methods: We applied ductoscopy to 415 women with nipple discharge with the specific intent of detecting those patients with nipple discharge who had intraductal carcinoma (DCIS) as the basis of their discharge.

Results: In this cohort of patients, ductoscopy was successful in visualizing an intraductal lesion in 166 patients (40%). In these cases, ductal lavage following ductoscopy increased the yield of cytologically interpretable ductal epithelial cells 100-fold compared to discharge fluid alone. In the majority of these patients, FDS examination detected lesions that had the appearance of typical papillomas. However, in 10 patients, the intraductal lesion exhibited one of several atypical features, including bleeding, circumferential obstruction, and gross fungating projections. In eight of these patients, the subsequent histopathology turned out to be DCIS. In two of these eight patients, endoscopic biopsy revealed cytologically malignant cells; in two others, ductal lavage (washings) revealed cytologically malignant cells. In three additional patients, although FDS examination uncovered a typical papilloma that was not biopsied, ductal lavage (washings) revealed cytologically malignant cells. On surgical pathology review of the extirpated lesions, all 11 patients were subsequently shown to have DCIS. Of these 11

cases of DCIS that were initially detected with a combination of FDS and ductal lavage cytology, six were completely negative on mammogram and physical exam.

Conclusion: Although nipple discharge is an unusual presentation for DCIS, in patients with nipple discharge, FDS with ductal lavage cytology is a useful technique for diagnosing DCIS prior to definitive surgery.

Key words: Nipple discharge — Breast cancer — Fiberoptic ductoscopy — Intraductal carcinoma — Cancer

Breast cancer and precancer are thought to originate in the lining of the milk duct or lobule. Yet until recently we have not had direct access to this area other than by examining tissue removed at biopsy. Fiberoptic ductoscopy (FDS) is an emerging technique that allows direct visual access to the ductal system of the breast through nipple orifice cannulation and exploration [3, 7]. In previous studies [3, 8], we have used FDS successfully in women with and without nipple discharge.

Although nipple discharge is relatively common and usually benign in origin, it can in fact herald the onset of intraductal carcinoma of the breast (DCIS). The incidence of DCIS in patients with nipple discharge varies from 1% to 10% [5]. The diagnostic workup of patients with nipple discharge usually includes clinical history, physical examination, mammography, ductography, and nipple discharge cytology but not FDS [2]. In a previous study, we demonstrated that in patients with nipple discharge, FDS is a safe and effective means of visualizing the intraductal lesion. Moreover, when combined with ductal lavage cytology, it is a screening technique that has a high predictive value [8].

In the present study, we applied ductoscopy to 415 women with nipple discharge with the specific intent of detecting those patients whose nipple discharge was the result of DCIS.

Materials and methods

Patients

Informed patient consent and certification from the Institutional Human Subject Protection Committee of the Cancer Hospital, Shanghai Medical University, was obtained prior to all studies. Between October 1997 and March 2000, 415 patients with nipple discharge consented and were enrolled in the study. These patients were subjected to FDS, endoscopic biopsy when indicated, ductal lavage with cytological analysis, and subsequent surgery when appropriate.

Fiberoptic ductoscopy system (FDS)

The FDS setup (FVS-3000; Fujikura Co. Ltd., Tokyo, Japan) consisted of a silica fiberscope, a light source, an image monitor, and an image recorder, which was capable of videorecording or directly photographing the observed image. An outer air channel of the fiberscope allowed for the installation and irrigation of saline washings and the retrieval of cells from the ductal system of the breast. The outer diameter of the silica fiberscope was 0.72 mm; its maximal exploratory length was 6.5 cm. In select patients, a double-barrel lumen catheter designed to maximize ductal lavage was also used.

FDS procedure

The nipple and areola of the breast were cleaned with 70% ethanol and povidone-iodine disinfectant (Betadine). Bowman's lacrimal dilators with outer diameters of 0.35 mm and 0.45 mm, respectively, were inserted sequentially into the discharging nipple orifice to dilate the ostium of the lactiferous duct. The fiberscope was then inserted into the duct orifice.

The procedure is not at all uncomfortable for the patients. When the patients have nipple discharge, their nipple orifice is already somewhat dilated and easily accessible. The majority of patients required no anesthesia at all; a minority required only the local lubrication of the nipple orifices with xylocaine jelly. No other forms of local or general anesthesia were used. The patients were not given IV sedation. This is a painless procedure.

About 10 ml of normal saline was then perfused into the duct through the air channel of the fiberscope to ensure the patency of the duct during the procedure. The lactiferous duct, lactiferous sinus, and the segmental duct and its branches were visualized in succession. The presence and appearance of any papillary lesions were noted, and the transductal distances from the nipple orifice to both the proximal and distal borders of the lesions were measured and recorded. The presence of atypical papillary lesions were specifically identified by the presence of bleeding, circumferential obstruction, or gross fungating projections.

Endoscopic biopsy

Endoscopic biopsy was performed when the presence of atypical papillary lesions was noted and when the biopsy was technically feasible. The fiberscope, which was covered with an outer cylinder, was inserted into the location of the suspected lesion through the ostium of the duct. Under the guidance of FDS, the outer cylinder was brought just up to the lesion. After the fiberscope was removed, a very thin inserted syringe was used to aspirate the lesion through the outer cylinder. With this technique, the fine-needle aspiration produced tissue fragments having the appearance of endoscopic biopsy specimens. These specimens were placed in 10% formalin for cytopathological examination.

Ductal lavage and cytology

The fiberscope was retracted, and the instilled saline was retrieved and processed for cytology. A double-lumen ductoscope was inserted in selected cases where retrieval of the instilled saline was limited, and ductal washings were obtained by irrigation and processed for cytology. Cytological analysis consisted of standard cytospin preparations and Pap and Diff-Quick staining. The cytological findings were grouped into the four following categories: clumps of ductal cells (>50 cells), clumps with mild atypia, clumps with severe atypia (cytologically malignant cells), and single ductal cells or small clumps. The number of ductal epithelial cells obtained on ductal lavage were compared to the number spontaneously present in the nipple discharge. For the purposes of this study, the four cytological categories were reduced to two—cytologically malignant and cytologically benign.

logical analysis consisted of standard cytospin preparations and Pap and Diff-Quick staining. The cytological findings were grouped into the four following categories: clumps of ductal cells (>50 cells), clumps with mild atypia, clumps with severe atypia (cytologically malignant cells), and single ductal cells or small clumps. The number of ductal epithelial cells obtained on ductal lavage were compared to the number spontaneously present in the nipple discharge. For the purposes of this study, the four cytological categories were reduced to two—cytologically malignant and cytologically benign.

Pathological analysis

Select patients were subsequently subjected to breast surgery. Detailed histopathological analysis of the extirpated tissues was carried out to evaluate the intraductal abnormalities present.

Statistical analysis

Standard tests of significance were carried out. These included comparisons of differences among variables with the two-tailed Student's *t*-test and the Spearman's rank-based correlation to assess the relationship between the variables. The log-rank test was used to assess the univariate effect of certain variables on the presence or absence of an atypical vs typical intraductal lesion. Cox's proportional hazards model was used to assess these effects after adjustment for other covariates.

Results

Overview of findings

In this cohort of patients, ductoscopy was successful in visualizing an intraductal lesion in 166 patients (40%). In the majority of these patients, FDS examination detected lesions having the appearance of typical papillomas. However, in 10 patients, the intraductal lesion exhibited one of several atypical features, including bleeding, circumferential obstruction, and gross fungating projections (Fig. 1). In eight of these patients, the subsequent histopathology turned out to be DCIS (Table 1). In four of these eight patients, cytologically malignant cells were present either on endoscopic biopsy or ductal lavage (Fig. 2). In three additional patients, although FDS examination revealed a typical papilloma that was not biopsied, ductal lavage (washings) revealed cytologically malignant cells. All 11 patients were subsequently shown to have DCIS on surgical pathology review of the extirpated lesions.

Clinical characteristics of the breast cancer patients with nipple discharge

Eleven of 415 patients with nipple discharge (2.7%) were therefore found to have DCIS. The mean age of all 11 DCIS patients was 43 years old (range, 27–56). The average duration of nipple discharge was 3 months and the longest duration was 8 months. The clinical characteristics of the patients are summarized in Table 2: The most prominent symptom of the patients in this study was spontaneous unilateral bloody nipple discharge from a single duct.

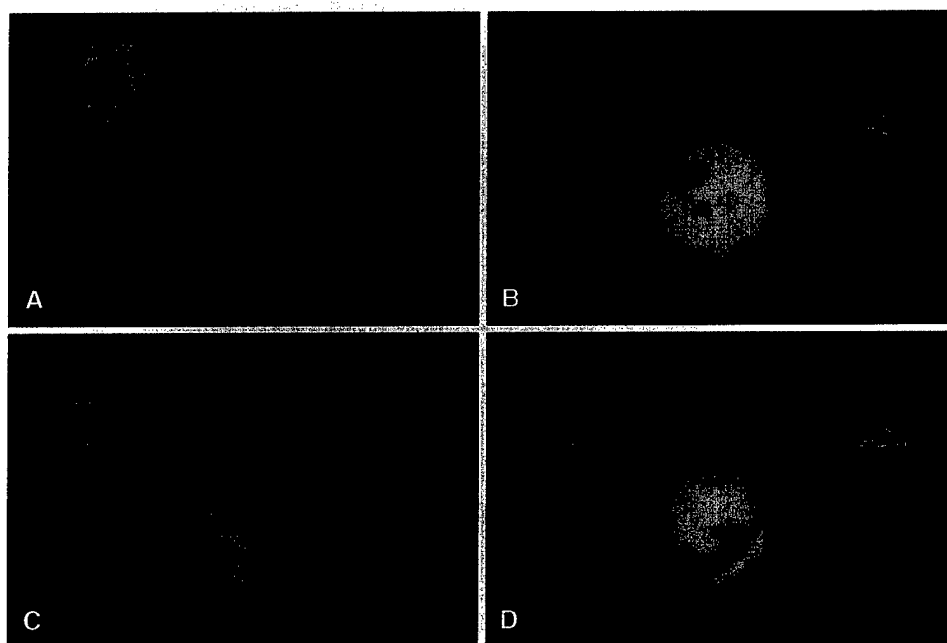


Fig. 1. Various appearances of the atypical intraductal papillary lesion suggesting intraductal carcinoma (DCIS): a a bleeding lesion, b a circumferential obstructive lesion with a roughened surface resembling a snow slide on a mountain, c an irregular fungating mass, d In contrast to these appearances, the typical intraductal papilloma, exhibited a narrow base and a smooth border and appeared as a polyp.

Table 1. + (suspicious) vs - (nonsuspicious) fiberoptic ductoscopy (FDS)^{a,b} in the detection of intraductal carcinoma (DCIS) in women with nipple discharge

Ductoscopy results	+ histopathology (no. of patients)	-histopathology (no. of patients)
+ FDS (<i>n</i> = 10)	8	2
- FDS (<i>n</i> = 156)	3	153

^a + FDS examination refers to the finding of an atypical papillary lesion; - FDS examination refers to the finding of a typical papillary lesion. All patients had a positive FDS examination from the standpoint of an intraductal lesion.

^b Specificity, 99%; sensitivity, 73%; positive predictive value, 80%; negative predictive value, 98%

FDS findings

The intraductal lesions observed in the cases of DCIS tended to lie more distally than their benign papilloma counterparts observed both in this study and in a previous study [8]. The geographic distribution of the eight DCIS lesions detected by FDS were mainly in the first and second branches of the ductal system (Table 3) as opposed to the segmental and first branch, as was the case with intraductal papillomas. Predictably, the transductal distances from the nipple orifice to the lesion were greater for DCIS than for intraductal papillomas. The shortest transductal distance from the suspected lesion to the nipple orifice was 1.5 cm, the longest was 5 cm, and the average was 3.3 cm. In contrast, for intraductal papillomas, the shortest distance was 0.5 cm and the average was 2.7 cm.

The appearance of the eight DCIS lesions was quite different from the typical intraductal papilloma. The DCIS lesions exhibited bleeding (Fig. 1a), circumferential ductal obstruction (Fig. 1b), and irregular fungating masses projecting from the lumen (Fig. 1c). In contrast, the appearance of the intraductal papilloma was polyp-like, with smooth borders and a narrow stalk (Fig. 1d).

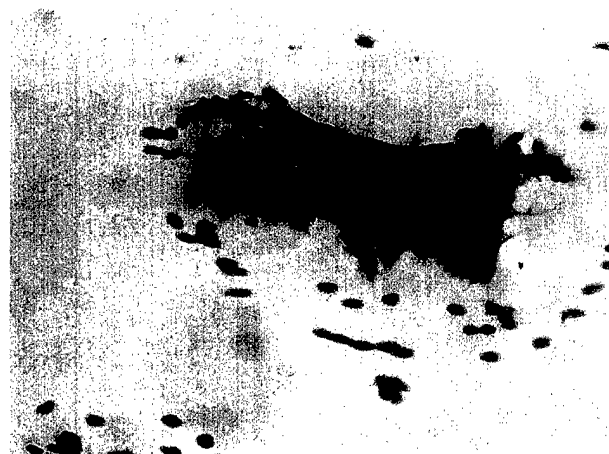

Fig. 2. An endoscopic biopsy specimen of intraductal carcinoma (DCIS) obtained through the ductoscope showing a clump of cytologically malignant cells.

Endoscopic biopsy findings

In two of the eight patients whose FDS examination revealed an atypical intraductal lesion, we were able to obtain a satisfactory endoscopic biopsy, which revealed tissue fragments of cytologically malignant cells (Fig. 2).

Ductal lavage cytology findings

Ductal lavage following ductoscopy in all cases that were studied dramatically increased the yield of cytologically interpretable ductal epithelial cells; it was 100-fold greater than the yield obtained with discharge fluid alone. The number of cells obtained averaged 5000 cells per washed duct, as compared to 50 in discharge fluid alone. The positive predictive value of FDS alone in detecting DCIS was 80%

Table 2. Clinical characteristics of the patients with intraductal carcinoma (DCIS) identified by fiberoptic ductoscopy (FDS) and/or ductal lavage cytology

Clinical characteristics	No. of patients	Percentage (%)
Menopausal status	11	100
Premenopausal	6	54.5
Postmenopausal	5	45.5
History	11	100
Family history of nipple discharge	1	9.1
Family history of breast cancer	3	27.3
Negative history	7	63.6
Localization of discharge	11	100
Unilateral	11	100
Bilateral	0	0
No. of discharge ducts	11	100
Single	10	100
Multiple	0	0
Duration of discharge	11	100
≤1 mo	5	45.4
2-3 mo	3	27.3
4-8 mo	3	27.3
Discharge characteristic	11	100
Bloody ^a	6	54.6
Serosanguineous	4	36.3
Serous	1	9.1
Mass—physical examination	11	100
No	8	72.7
Yes	3	27.3
Mammography	11	100
Microcalcifications	2	18.2
Architectural distortion (mass)	3	27.3
Negative	6	54.5

^a Significant by univariate analysis, $p = .01$; insignificant in multivariate analysis, $p = .20$ when compared to FDS with respect to histopathology

Table 3. Anatomical distribution of lesions in patients with intraductal carcinoma (DCIS) identified by fiberoptic ductoscopy (FDS)

Location	No. of lesions	Percentage (%)
Segmental	1	12.5
First branch	3	37.5
Second branch	3	37.5
Third branch	1	12.5
Fourth branch	0	0
Total	8	100.0

(Table 1), but when combined with ductal lavage cytology, the positive predictive value increased to 100% (Table 4).

Comparison of FDS and ductal lavage with physical examination and mammography

Of the 11 cases of DCIS that were initially detected with a combination of FDS and ductal lavage cytology, six cases were completely negative on mammogram and physical exam (Table 2).

Discussion

FDS is gaining in popularity as thinner, longer, and more flexible fiberoptic scopes become available to permit

greater visualization of the ductal system of the breast. Breast ductoscopy has evolved slowly over the past decade. In 1988, using a rigid endoscope with a 1.7-mm outer diameter [9], Teboul was the first investigator to succeed in observing the duct cavity under the guidance of ultrasound. In 1991, Makita et al. [4] established the use of blind intraductal biopsy of the breast for the pathologic diagnosis of nipple discharge through a rigid endoscope with a 1.25-mm outer diameter. The endoscope that this group used was similar to an arthroendoscope. Later, Okazaki et al. [6], in cooperation with the Fujikura Company, developed the breast fiberoptic ductoscopy system. This system made it possible to visualize the duct cavities and duct walls directly and project them onto a screen. This technique allowed for the visualization of even minute intraductal lesions.

Using this technique [8], we were able to effectively screen women with nipple discharge. In our initial study, we applied ductoscopy to 259 women with nipple discharge and analyzed the visual findings, the cytological washings, and the subsequent histopathology. In 92 of these women (36%), fiberoptic ductoscopy was successful in visualizing an intraductal papillary lesion. Of these visualized cases, 68 (74%) had a single papilloma, 21 (23%) had multiple discrete papillomas, and three (3%) had diffuse intraductal thickening that corresponded to diffuse papillomatosis on histopathological analysis. The overall positive predictive value of FDS screening was 83%. Ductal washings done at the time of ductoscopy were effective at obtaining representative exfoliated ductal cells that could be evaluated for the presence of clumps (>50 cells) or single ductal cells. The presence of clumps with positive FDS increased the positive predictive value to 86%. We concluded that fiberoptic ductoscopy offered a safe alternative to ductography in guiding subsequent breast surgery in the treatment of nipple discharge.

Because nipple discharge can occasionally herald the onset of intraductal carcinoma of the breast (DCIS), we decided to determine whether FDS and postductoscopy lavage might prove useful in determining which patient's nipple discharge was on the basis of DCIS. With this approach, 11 of 415 cases were shown to have DCIS prior to surgical extirpation of the lesion.

Bauer et al. reported that when DCIS is associated with nipple discharge, the discharge becomes a clinical marker for locally confined disease [1]. When the discharge is due to DCIS, extensive ductal spread of the disease may preclude breast conservation. Our results concerning the locations of the lesions and their extent of ductal involvement were not significantly different from what we previously observed for intraductal papillomas [8]. Although DCIS is located slightly more distally from the nipple orifice, it does not involve more than one ductal system and its extent of ductal involvement can be defined with FDS. With the help of FDS, we can determine the location and extent of the DCIS before surgery; this information can be of tremendous assistance in planning breast conservation surgery.

Some investigators have implied that ductography is the best method for preoperative evaluation of the nature and site of the lesion causing nipple discharge, but the accuracy rates reported for the detection of DCIS in the setting of nipple discharge in two recent studies were only 39% and

Table 4. Value of cytology in + (suspicious) vs - (nonsuspicious) fiberoptic ductoscopy (FDS) examination^a

Cytology	Overall (n = 166)		+ FDS (n = 10)		- FDS (n = 156)	
	+ Path	- Path	+ Path	- Path	+ Path	- Path
Malignant cells (no. of patients)	7	0	4	0	3	0
Benign cells (no. of patients)	4	155	4	2	0	153
Specificity	100%		100%		100%	
Sensitivity	64%		50%		100%	
Positive predictive value	100%		100% ^b		100%	
Negative predictive value	97%		33%		100% ^b	

^a Path, pathology + FDS examination refers to the finding of an atypical papillary lesion; - FDS examination refers to the finding of a typical papillary lesion. All patients had a positive FDS examination from the standpoint of an intraductal lesion

^b Value greater than FDS alone (see Table 1)

70%, respectively [1,2]. The main reason for the low rates was that ductography could not discriminate between DCIS and papilloma. In our study, we show that FDS can discriminate effectively between DCIS and intraductal papilloma. Although we did not specifically compare ductoscopy with ductography in the management of patients with nipple discharge, it seems obvious that ductoscopy provides advantages over ductography in the routine management and workup of patients with nipple discharge (Table 5).

Ductoscopy allows direct visualization of the lesion and not just indirect shadowing. In comparison to ductography, ductoscopy allows for more precise localization and mapping of the lesion within the duct. This mapping is not dependent on the presence of obstruction. Ductoscopy, unlike ductography, permits intraductal sampling of the ductal cells through endoscopic biopsy and increases exfoliation of the cells in ductal lavage following ductoscopy 100-fold over that which occurs spontaneously in nipple discharge. In contrast, ductography obscures cytological detail and renders cytological evaluation impossible.

One of our important observations was that >50% of the patients with nipple discharge who had a DCIS lesion visible on FDS and/or detectable by ductal lavage had a negative physical examination and a negative mammogram (Table 2). In a recent study of women presenting with nipple discharge [1], mammography revealed subareolar microcalcifications in 28% and a tissue density in 14%, but it was completely negative in 52% of cases. It is especially in these latter cases that alternative detection methods such as FDS and ductal lavage would find utility. This study dealt with women who present with nipple discharge and the DCIS they harbor. But FDS and ductal lavage may hold greater promise as screening techniques for all women at high risk for breast cancer who are persistently negative on mammogram and physical exam.

In our previous study [8], we demonstrated that in 36% of women with nipple discharge, fiberoptic ductoscopy was successful in detecting an intraductal papillary lesion, with an overall positive predictive value of 83%. Therefore, from the standpoint of numbers of patients, the technique is cost-effective. Most of these intraductal lesions were intraductal papillomas. Only a minority were intraductal carcinomas. But we are advocating the technique for all women with

Table 5. Comparison of breast ductoscopy with breast ductography

Feature	Ductoscopy	Ductography
Proximal limits of lesion	Yes	Yes
Span of the lesion	Yes	No
Distal limits of lesion	Yes	No
Duct obstruction required	No	Yes
Direct visualization	Yes	No
Precise distances	Yes	No
Endoscopic biopsy	Yes	Yes
Cytologic analysis	Yes	No

nipple discharge, not just those whose discharge is due to intraductal carcinomas.

The fiberoptic ductoscope and related equipment cost US \$40,000. This amount represents a one-time cost for the silica fiberscope, the light source, the image monitor, and the image recorder. Each fiberscope can be reused for 100 patients. The cost of a fiberscope replacement is US \$1000. Considering that patients with nipple discharge whose ductoscopy examination visualized a lesion were spared the cost of ductography and that patients whose ductoscopy/lavage were negative were spared the cost of surgical excision, the technique is quite cost-effective.

We cannot yet address the consequences of diagnosing these lesions that are a cause of nipple discharge at a slightly later time when ductoscopy/lavage is not performed but replaced by more frequent screening mammograms or ultrasound examinations. However, considering that DCIS becomes a breast-threatening disease as it grows, and considering that the risk of invasion increases with size and duration, it seems intuitive that earlier diagnosis of DCIS is desirable.

The two techniques of ductoscopy and ductal lavage are intimately associated and should not be separated. Both ductoscopy and ductal lavage are done easily, and ductoscopy facilitates ductal lavage because it dilates the nipple orifices further. Ductoscopy both visualizes the lesion and determines its location and extent—determinations that cannot be made with ductal lavage alone. The cost of doing both techniques at the same time is no greater than doing either technique alone. Since we do not know in advance what the findings will be, it is not possible, nor would it be

desirable, to stratify the patients into receiving only ductoscopy or ductal lavage.

Acknowledgments. This study was supported by the National Natural Science Foundation of China (grant no. 39670803), the Xia Li-Jun Research Foundation, and the United States Department of Defense (grant no. BC 990959).

References

1. Bauer R, Eckhart K, Nemoto T (1998) Ductal carcinoma in situ-associated nipple discharge: a clinical marker for local extensive disease. *Ann Sur Oncol* 5: 452-455
2. Florio MG, Manganaro T, Pollicino A, Scarfo P, Micali B (1999) Surgical approach to nipple discharge: a ten-year experience. *J Surg Oncol* 71: 235-238
3. Love SM, Barsky SH (1996) Breast duct endoscopy to study stages of cancerous breast disease. *Lancet* 348: 997-999
4. Makita M, Sakamoto G, Akiyama F, Namba K, Sugano H, Kasumi F, Nishi M, Ikenaga M (1991) Duct endoscopy and endoscopy biopsy in the evaluation of nipple discharge. *Breast Cancer Res Treat* 18: 179-188
5. Okazaki A, Hirata K, Okazaki M, Svane G, Azavedo E (1999) Nipple discharge disorders: current diagnostic management and the role of fiber-ductoscopy. *Eur Radiol* 9: 583-590
6. Okazaki A, Okazaki M, Asaishi K, Satoh H, Watanabe Y, Mikami T, Toda K, Okazaki Y, Nbeta K, Hirata K (1991) Fiberoptic ductoscopy of the breast: a new diagnostic procedure for nipple discharge. *Jpn J Oncol* 21: 188-193
7. Shen K-W, Wu J-S, Han Q-X, Shen Z-Z (2000) Fiberoptic ductoscopy for patients with intraductal papillary lesions. *Chin J Surg* 38: 275-277
8. Shen K-W, Wu J-S, Han Q-X, Shen Z-Z, Nguyen M, Shao Z-M, Barsky SH (2000) Fiberoptic ductoscopy for patients with nipple discharge. *Cancer* 89: 1512-1519
9. Teboul M (1988) Echo-histological "acino-ductal analysis": preliminary results. *Ultrasound Med Biol* 14 (Suppl 1): 89-95