

AD _____

Award Number: DAMD17-01-1-0178

TITLE: Anti-Angiogenic Therapeutic Indicators in Breast Cancer

PRINCIPAL INVESTIGATOR: Min-Ying L. Su, Ph.D.

CONTRACTING ORGANIZATION: University of California, Irvine
Irvine, California 92697-1875

REPORT DATE: August 2002

TYPE OF REPORT: Annual

PREPARED FOR: U.S. Army Medical Research and Materiel Command
Fort Detrick, Maryland 21702-5012

DISTRIBUTION STATEMENT: Approved for Public Release;
Distribution Unlimited

The views, opinions and/or findings contained in this report are those of the author(s) and should not be construed as an official Department of the Army position, policy or decision unless so designated by other documentation.

20030211 208

REPORT DOCUMENTATION PAGE

Form Approved
OMB No. 074-0188

Public reporting burden for this collection of information is estimated to average 1 hour per response, including the time for reviewing instructions, searching existing data sources, gathering and maintaining the data needed, and completing and reviewing this collection of information. Send comments regarding this burden estimate or any other aspect of this collection of information, including suggestions for reducing this burden to Washington Headquarters Services, Directorate for Information Operations and Reports, 1215 Jefferson Davis Highway, Suite 1204, Arlington, VA 22202-4302, and to the Office of Management and Budget, Paperwork Reduction Project (0704-0188), Washington, DC 20503

1. AGENCY USE ONLY (Leave blank)	2. REPORT DATE August 2002	3. REPORT TYPE AND DATES COVERED Annual (2 Jul 01 - 1 Jul 02)	
4. TITLE AND SUBTITLE Anti-Angiogenic Therapeutic Indicators in Breast Cancer		5. FUNDING NUMBERS DAMD17-01-1-0178	
6. AUTHOR(S) Min-Ying L. Su, Ph.D.			
7. PERFORMING ORGANIZATION NAME(S) AND ADDRESS(ES) University of California, Irvine Irvine, California 92697-1875 E-Mail: msu@uci.edu		8. PERFORMING ORGANIZATION REPORT NUMBER	
9. SPONSORING / MONITORING AGENCY NAME(S) AND ADDRESS(ES) U.S. Army Medical Research and Materiel Command Fort Detrick, Maryland 21702-5012		10. SPONSORING / MONITORING AGENCY REPORT NUMBER	
11. SUPPLEMENTARY NOTES			
12a. DISTRIBUTION / AVAILABILITY STATEMENT Approved for Public Release; Distribution Unlimited			12b. DISTRIBUTION CODE
13. ABSTRACT (Maximum 200 Words) This is an IDEA award to study the therapeutic indicators for anti-angiogenic therapy. In vitro and in vivo strategies will be used to measure treatment efficacy of anti-angiogenic compounds in order to facilitate their clinical development. Dynamic contrast enhanced MRI can be applied to measure vascular changes after therapy. We will also study the immunohistochemical angiogenic biomarkers in tumor tissues before and after therapy. During Yr-01 we studied R3230 AC mammary tumors treated with Taxotere. The treatment did not cause shrinkage of the tumor, rather only slowing down the growth rate. The large size contrast agent Gadomer-17 could detect a reduced vascularity in responders compared to controls. We are also working on developments of immunohistochemical staining procedures for rat tissues. Using available specimens of ENU induced tumors, we stained p53, TSP-1, Factor VIII, and VEGF. The data showed that all ENU induced tumors had wild type p53. The Factor VIII vessel density showed significance differences between malignant and benign tumors. In Yr-02 we will continue the study to treat ENU induced tumors with anti-angiogenic therapeutic agents. All methods to be used in this study have been developed.			
14. SUBJECT TERMS breast cancer, ENV induced tumors, MRI			15. NUMBER OF PAGES 15
			16. PRICE CODE
17. SECURITY CLASSIFICATION OF REPORT Unclassified	18. SECURITY CLASSIFICATION OF THIS PAGE Unclassified	19. SECURITY CLASSIFICATION OF ABSTRACT Unclassified	20. LIMITATION OF ABSTRACT Unlimited

NSN 7540-01-280-5500

Standard Form 298 (Rev. 2-89)
Prescribed by ANSI Std. Z39-18
298-102

Table of Contents

Cover.....	1
SF 298.....	2
Table of Contents.....	3
Introduction.....	4
Body.....	5-9
Key Research Accomplishments.....	10
Reportable Outcomes.....	10
Conclusions.....	11
References.....	
Appendices.....	12-15

(4) Introduction

Anti-angiogenic therapy is a promising alternative for treatment of cancer, also it may be used as maintenance therapy to prevent metastasis or recurrence. While 60% of the approximately 186,000 annual cases of breast cancer now present as node negative, 30% of these cases will recur after local therapy. Although adjuvant chemotherapy has been demonstrated to improve survival in node negative breast cancer, it is still unclear how best to identify those patients whose risk of metastatic disease exceeds their risk of significant therapeutic toxicity. On the other hand, for treatment of locally advanced disease, anticancer chemotherapy has produced only modest gains. Newer therapeutic strategies are greatly needed. Anti-angiogenic therapy maybe used to augment the efficacy of the traditional cytotoxic therapeutic agents. Furthermore, a new line of therapy that has a less side toxicity effect is definitely needed to provide the patients with more options for treatment. Because angiogenesis appears to play an important role in the disease progression, anti-angiogenic agents may have a great potential for treating breast cancer.

While the efficacy of traditional therapeutics has been determined by measuring tumor response and patient survival, these newer approaches may prolong life and improve symptoms by stabilizing tumor progression rather than by causing tumor shrinkage. It is therefore necessary to develop improved endpoints that can determine the clinical activity of these agents during their development. In this project we used in vitro and in vivo strategies to measure the potential efficacy of anti-angiogenic compounds in order to facilitate their clinical development. Two breast cancer models, R3230 AC adenocarcinoma and carcinogen N-ethyl-N-nitrosourea(ENU) induced mammary tumors will be used, and two drugs known to have anti-angiogenesis effect, taxotere and thalidomide, will be used to treat cancers. We will measure the therapy induced changes using the in vivo magnetic resonance imaging and the in vitro immunohistochemistry. Dynamic contrast enhanced MRI has been shown as a non-invasive means to measure the vascular characteristics in tumors. We will apply this technique to measure the longitudinal structural and vascular changes taking place in tumors following treatment. While these structural and vascular changes observed by MRI are macroscopic, they are governed by the underlying biological changes, e.g. the decrease of microvessel density and changes of other angiogenic markers. The vascular changes measured by MRI will be correlated with the neovessel density count (obtained by immunohistochemistry with CD105 staining) and the angiogenesis index (AI, constituting 3 angiogenic markers, p53, TSP-1, CD31) and expression level of VEGF.

After completion of this pilot study we expect to achieve three goals: (1) to assess the feasibility of using these two animal models for testing the efficacy of other potential anti-angiogenic compounds, (2) to identify other therapeutic indicators rather than tumor shrinkage (immunohistochemical markers or MRI cellular and vascular parameters) for determination of therapeutic efficacy, (3) to find early therapeutic indicators which will predict the final outcome.

(5) Body

Five specific aims were proposed. First we will establish the tumor models. For each tumor, when the size reaches 1.0 cm the baseline MRI study will be performed. After the MRI study core needle biopsy will be performed to obtain tissue specimens for analysis of baseline angiogenic biomarkers. Then the tumor will receive treatment. Several MRI studies will be performed to follow the longitudinal changes. At the conclusion of the study the animal will be sacrificed, and the tumor excised for measures of post-treatment angiogenic biomarkers.

- Aim 1.** Establish the R3230 AC adenocarcinoma and ENU induced mammary tumor models.
- Aim 2.** Perform the baseline dynamic contrast enhanced MRI before administration of therapeutic drugs to measure the pre-treatment characteristics of tumors.
- Aim 3.** Perform core needle biopsy to obtain cancer specimens for evaluation of baseline angiogenic activity using immunohistochemical analysis.
- Aim 4.** Apply dynamic contrast enhanced MRI to monitor the longitudinal volumetric, cellular and vascular changes taking place in tumors following therapy.
- Aim 5.** Perform immunohistochemical studies to measure the CD105 neovessel density, VEGF, and the angiogenesis index (AI) markers in tumors for assessment of anti-angiogenic effects.

In Yr-01 we started with R3230AC tumor model treated with taxotere. Twenty three animals have been studied. Also we have injected 53 rats with carcinogen ENU. Meanwhile we are working on development of immunohistochemical analysis procedures using the ENU induced tumor specimens available from another study. The study results are summarized below.

R3230AC tumors treated with Taxotere

Introduction: Anticancer chemotherapy has produced only modest gains in the treatment of solid tumors. Newer therapeutic strategies are greatly needed. Anti-angiogenic therapy is one of the most promising novel approaches. While the efficacy of traditional therapeutics has been determined by measuring tumor response and patient survival, these newer approaches may prolong life and improve symptoms by stabilizing tumor progression rather than by causing tumor shrinkage. It is therefore necessary to develop improved endpoints that can determine the clinical activity of these agents. In this study we investigated whether the vascular parameters measured by dynamic contrast enhanced MRI can differentiate responder vs. non-responders in tumors receiving Taxotere as treatment.

Methods: Seventeen Fischer-344 rats bearing R3230 AC adenocarcinomas were included. The baseline MRI was conducted when the tumor reached 0.7 cm in diameter. The imaging protocol included a T2-weighted sequence for volumetric measurement, and the dynamic study using a small molecular weight agent Gd-DTPA (0.1 mmol/kg), followed by an intermediate molecular weight agent Gadomer-17 (0.05 mmol/kg). After the MRI study was completed the rats received i.v. injection of 4 mg/kg Toxotere. Three follow-up studies were performed weekly. The rats continued to receive weekly Toxotere treatment after each MRI study. Figure 1 shows the growth rates of several tumors, and based on changes between week-3 and week-2, partial responders and responders were separated. T-tests were performed to compare the enhancement kinetics measured at week-1, week-2 vs. the baseline kinetics in each group (controls, partial-responders, responders).

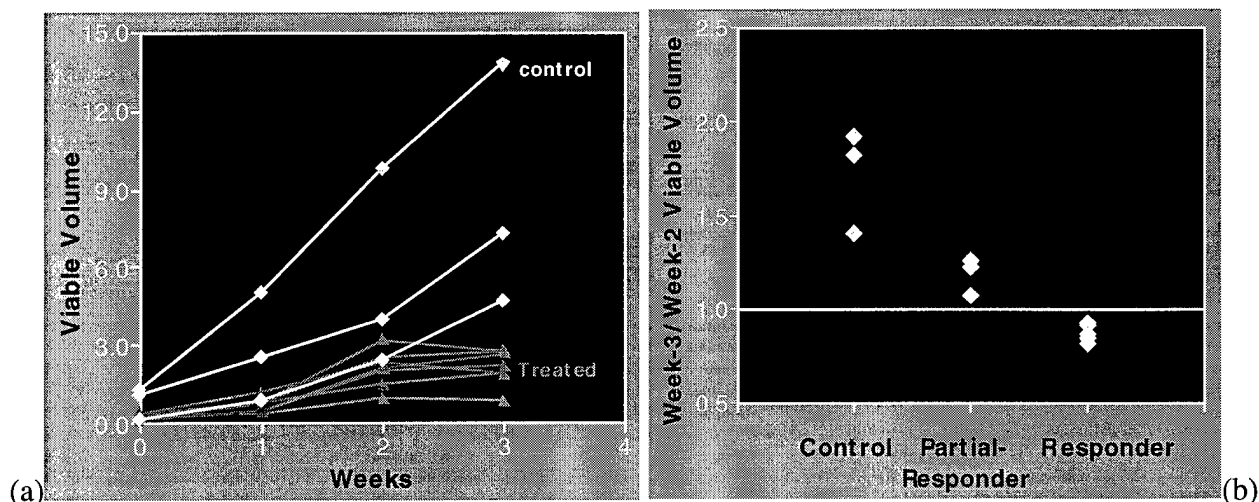


Figure 1: (a) The viable tumor volume of control and treated rats at baseline (week-0) and 3 follow-up studies (weeks 1-3). While the control tumor kept growing larger during week-2 to week-3, treated tumors had slower growth or even regressed. (b) The partial responders and responders were separated based on week-3/week-2 growth ratio.

Results: Figures 2-4 shows the enhancement kinetics measured by Gadomer-17 and Gd-DTPA in controls, partial-responders, responders, respectively. The responders showed a significant decrease in the early enhancements measured by Gadomer-17 in the week-1 follow-up study compared to the baseline. In contrast, the partial-responders did not show significant changes in the follow-up studies. Interestingly, the control tumors showed a significant increase in the early enhancement measured by Gadomer-17. The results measured by Gd-DTPA did not show significant changes in all 3 groups, thus could not differentiate them.

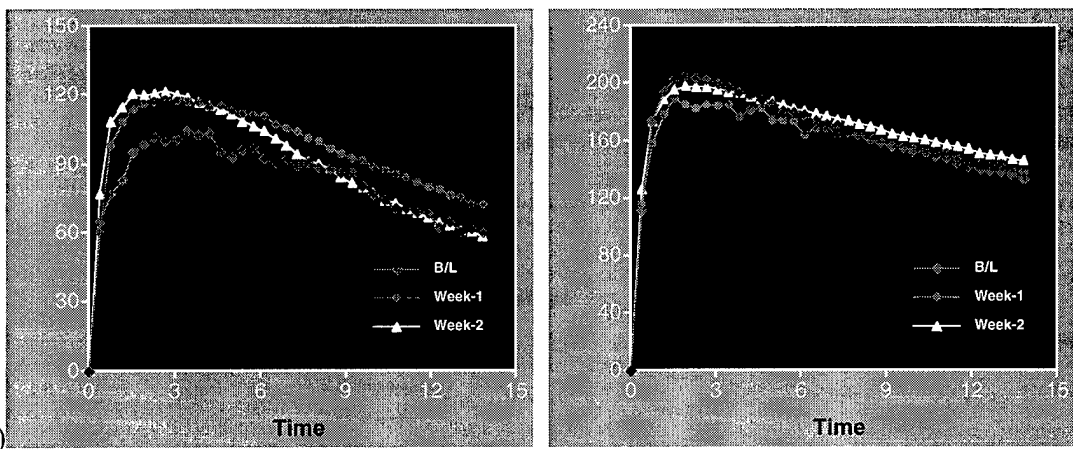


Figure 2: The mean enhancement kinetics measured by Gadomer-17(a) and Gd-DTPA(b) in the control group at baseline and week-1, week-2 follow up studies.

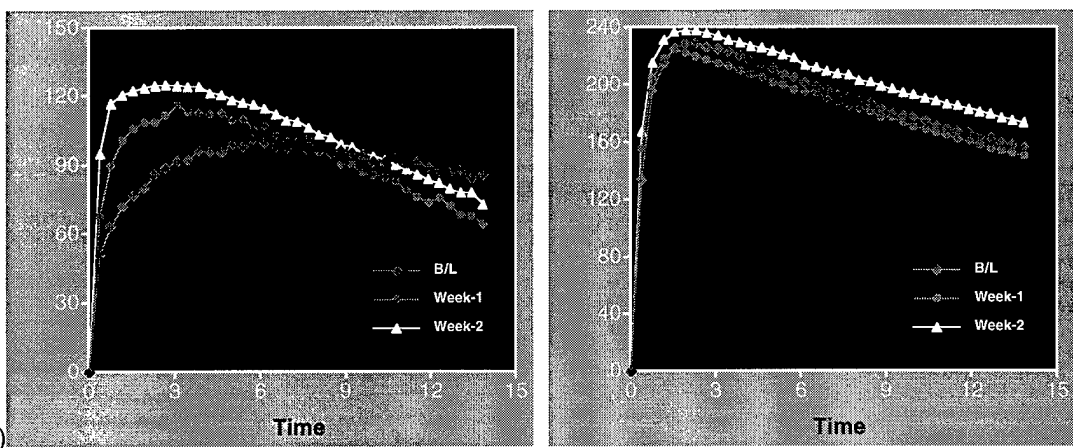


Figure 3: The mean enhancement kinetics measured by Gadomer-17(a) and Gd-DTPA(b) in the partial responders at baseline and week-1, week-2 follow up studies.

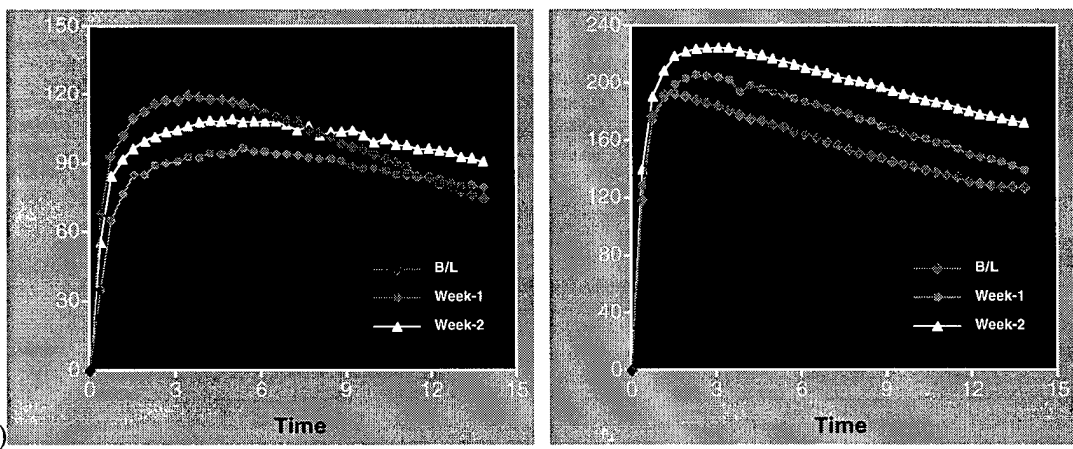


Figure 4: The mean enhancement kinetics measured by Gadomer-17(a) and Gd-DTPA(b) in the responders at baseline and week-1, week-2 follow up studies.

Discussion: The early enhancements measured by dynamic MRI with an intermediate sized contrast agent could differentiate between responders and controls. They may serve as potential indicators for the efficacy of anti-angiogenic therapy.

Characterization of Angiogenesis In ENU Induced Benign And Malignant Mammary Tumors

N-ethyl-N-nitrosourea (ENU, 90 mg/kg) was injected i.p. into 30-day old SPF Sprague-Dawley rats (n=50) to induce mammary tumors. The tumors started to appear 2 months after injection. The baseline MRI study was performed when the tumor reached approximately 1.0 cm in diameter. For each tumor the enhancement kinetics of two contrast agents, the small agent Gd-DTPA and a mid-sized agent Gadomer-17, were measured. The volumetric growth rates, as well as the early (30-sec) and maximum (approximately 2-min) enhancements between benign and malignant tumors were compared. Each tumor was then surgically removed for IHC staining analysis of 5 markers, p53, thrombospondin-1 (TSP-1), factor VIII vessel density, and VEGF. The rats were kept for observation of recurrence, further development of other tumors, and metastasis into other organs, to explore whether this model can be used to study recurrence and metastasis as in human breast cancer.

Ninety three tumors were found in 1 year after injection of ENU. Most tumors belonged to four major types, 2 malignant and 2 benign. The malignant tumors included ductal adenocarcinoma (n=25) and papillary adenocarcinoma (n=21), and the two major benign lesions were fibroadenoma (n=24) and adenosis (n=13). Multiple tumors (up to 5) could develop in one rat, all at different locations. Interestingly no tumor recurrence was observed at the surgical site after removal of a previous tumor. Also, none of the abdominal tumors were from breast origin. We also investigated lymph nodes from some rats, and found no sign of any cancer. The growth rates and the early (30 sec) and maximum (2-min) enhancements measured by Gd-DTPA and Gadomer-17 are listed in table 1. The bar graphs are shown in Figure 5. The two malignant tumors exhibited similar enhancement kinetics, showing rapid early enhancing slope and high enhancement magnitude. The two benign lesions had much slower early enhancing slope (highly significantly). However, adenosis could reach to a higher enhancement at 2-min after contrast administration, almost comparable to that in malignant tumors. The enhancements at 2-min between fibroadenoma and malignant tumors also became closer, but still significantly different.

Table 1: Growth Rate & Enhancements in 4 tumor types

	Papillary AC	Ductal AC	Adenosis	FA
GR (cc/day)	0.07 ± 0.14	0.06 ± 0.13	0.05 ± 0.06	0.03 ± 0.03
Gd-DTPA 30sec	126 ± 68	122 ± 62	57 ± 22	39 ± 14
Gd-DTPA 2min	240 ± 75	251 ± 69	204 ± 65	145 ± 54
Gadomer17 30sec	52 ± 23	47 ± 30	24 ± 11	23 ± 10
Gadomer17 2min	96 ± 32	92 ± 40	73 ± 22	51 ± 19

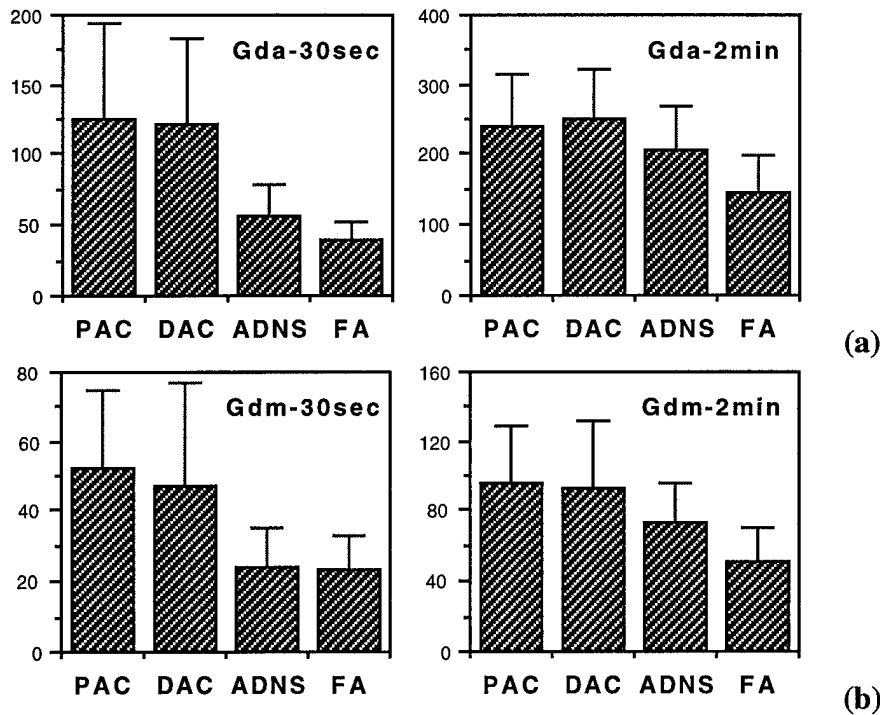


Figure 5: The enhancements at 30-sec and 2-min after injection of Gd-DTPA(Gda, a) and Gadomer-17(Gdm, b) in 4 tumor types. Malignant tumors had higher early enhancements. Results measured by both agents were similar.

In IHC studies, the ductal adenocarcinoma had the highest microvessel density (79 ± 19), then in order was papillary adenocarcinoma (70 ± 20), fibroadenoma (58 ± 18), and the adenosis (53 ± 17) had the lowest microvessel density. All tumors had wild type p53. VEGF and TSP-1 were not significantly different among the 4 types. Higher vessel density was associated with higher MRI enhancement.

Our results demonstrated that all carcinogen ENU induced tumors were primary tumors, and they did not metastasize to lymph nodes or to other organs. A better characterization of this model may aid in future development of diagnostic or therapeutic agents tested on this model.

(6) Key Research Accomplishments

- Established the carcinogen ENU induced tumor model
- Carried out magnetic resonance imaging studies to monitor the taxotere treatment-induced effects in R3230 AC tumors
- Worked with Oncotech Inc. to develop the immunohistochemical methods to stain p53, TSP-1, CD31, Factor VIII, and VEGF in rat tissue
- Correlate the MRI data with the IHC marker data using the specimens available from a previous study

(7) Reportable Outcomes

- Four conference papers related to this project were presented.
- The study design was applied to other projects. Two proposals, one for pancreatic cancer study and the other for cervical cancer study, were prepared and submitted to NIH.

Four Conference Abstracts:

Lydia Su, Anti-Angiogenic Therapeutic Indicators in Breast Cancer, 4th Chao Family Comprehensive Cancer Center Conference, Oxnard, October, 2001.

Min-Ying Su, Michael Samoszuk², Leonard Leoner, Phillip M. Carpenter², and Orhan Nalcioglu, Quantitative Vascular Density Assessed by a Semiautomatic Histological Method in Comparison with MRI Enhancements in Carcinogen Induced Benign and Malignant Mammary Tumors in Rats. . in "Proc., 10th ISMRM Annual Meeting, Hawaii, 2002" p2108.

Hon Yu, Min-Ying Su, Jun Wang, and Orhan Nalcioglu, Longitudinal Taxotere Chemotherapy Treatment Induced Vascular and Structural Changes Measured by Dynamic Enhanced MRI. in "Proc., 10th ISMRM Annual Meeting, Hawaii, 2002" p2131.

Hon Yu, Min-Ying Su, Jun Wang, Phillip M. Carpenter², and Orhan Nalcioglu, Characterization of Carcinogen ENU Induced Benign and Malignant Mammary Tumors in Rats: Volumetric Growth Rates, Contrast Enhancement Kinetics, and Longitudinal Monitoring. in "Proc., 10th ISMRM Annual Meeting, Hawaii, 2002" p2180.

(8) Conclusions

This is an IDEA award to study the therapeutic indicators for anti-angiogenic therapy. Dynamic contrast enhanced MRI can be applied to study the vascular changes after therapy. We will also study the immunohistochemical angiogenic biomarkers in tumor tissues before and after therapy. During Yr-01 we studied R3230 AC mammary tumors treated with Taxotere. The treatment did not cause shrinkage of the tumor, rather only slowing down the growth rate. The large size contrast agent Gadomer-17 could detect a reduced vascularity in responders compared to controls. We are also working on developments of immunohistochemical staining procedures for rat tissues. Using available specimens of ENU induced tumors from another study, we stained p53, TSP-1, Factor VIII, and VEGF. The data showed that all ENU induced tumors had wild type p53. The Factor VIII vessel density showed significance differences between malignant and benign tumors. In Yr-02 we will continue the study to treat ENU induced tumors with anti-angiogenic therapy. All methods to be used in this study have been developed.

(9) Appendices

One abstract presented at the 4th Chao Family Comprehensive Cancer Center Conference, and three abstracts presented at the 10th ISMRM meeting are enclosed.

CHAO FAMILY COMPREHENSIVE CANCER CENTER CONFERENCE

OCTOBER 12-14, 2001

EMBASSY SUITES, MANDALAY BEACH

OXNARD, CA

ABSTRACT FORM

Introduction: Anticancer chemotherapy has produced only modest gains in the treatment of solid tumors. Newer therapeutic strategies are greatly needed. Anti-angiogenic therapy is one of the most promising novel approaches. While the efficacy of traditional therapeutics has been determined by measuring tumor response and patient survival, these newer approaches may prolong life and improve symptoms by stabilizing tumor progression rather than by causing tumor shrinkage. It is therefore necessary to develop improved endpoints that can determine the clinical activity of these agents. In this study we investigated whether the vascular parameters measured by dynamic contrast enhanced MRI can differentiate responder vs. non-responders in tumors receiving Toxotere as treatment.

Methods: Seventeen Fischer-344 rats bearing R3230 AC adenocarcinomas were included. The baseline MRI was conducted when the tumor reached 0.7 cm in diameter. The imaging protocol included a T2-weighted sequence for volumetric measurement, and the dynamic study using a small molecular weight agent Gd-DTPA (0.1 mmol/kg), followed by an intermediate molecular weight agent Gadomer-17 (0.05 mmol/kg). After the MRI study was completed the rats received i.v. injection of 4 mg/kg Toxotere. Three follow-up studies were performed weekly. The rats continued to receive weekly Toxotere treatment after each MRI study. According to the volumetric growth rates of tumors, responders and non-responders were separated. T-tests were performed to compare the enhancement kinetics measured at week-1, week-2 vs. the baseline kinetics.

Results: The responders showed a significant decrease in the early enhancements measured by Gadomer-17 in the week-1 follow-up study compared to the baseline. In contrast, the non-responders did not show significant changes in the follow-up studies. Interestingly, the control tumors showed a significant increase in the early enhancement measured by Gadomer-17. The results measured by Gd-DTPA did not show significant changes in all 3 groups, thus could not differentiate them.

Discussion: The early enhancements measured by dynamic MRI with an intermediate sized contrast agent could differentiate between responders, non-responders, and controls. They may serve as potential indicators for the efficacy of anti-angiogenic therapy.

Abstract Title: Anti-Angiogenic Therapeutic Indicators in Breast Cancer

Presenter's Name: Min-Ying Su, PhD

Department: Health Sciences Research Imaging Center

Mailing Address: RIC, Irvine Hall 164, Zot Code 5020

Telephone No. (949) 824-4925

Fax Number: (949) 824-3481

E-mail Address: msu@uci.edu

Quantitative Vascular Density Assessed by a Semiautomatic Histological Method in Comparison with MRI Enhancements in Carcinogen Induced Benign and Malignant Mammary Tumors in Rats

Min-Ying Su, Michael Samoszuk², Leonard Leoner, Phillip M. Carpenter², and Orhan Nalcioğlu
Center for Functional Onco-Imaging, and ²Department of Pathology, University of California-Irvine, CA, USA

Abstract

The development of therapeutic efficacy markers for anti-angiogenic or anti-vascular therapy is in great need. Assessment of microvascular density by immunohistochemical staining is the most commonly used technique. Imaging can provide a through sampling, but to date there is not a suitable agent and technique whose accuracy has been validated. In this study, we developed a semi-automatic histological analysis method to quantitatively measure the cross-sectional area of vessels in carcinogen ENU induced benign and malignant tumors. The results were compared to enhancements measured by three contrast agents, Gd-DTPA, Gadomer-17, and albumin-Gd-DTPA.

Purpose

As the potential of anti-angiogenic or anti-vascular therapy for cancer treatment becomes more promising, there is an ever increasing need for the development of therapeutic efficacy markers. Assessment of microvascular density by immunohistochemical staining is the most commonly used technique. However, the accuracy is greatly dependent on successful staining of endothelial cells and highly subjective to the heterogeneity. In this study we analyzed the vascular density in a carcinogen induced mammary tumor model, including malignant tumors of various SBR (Scarff-Bloom-Richardson) grades and benign tumors [Stoica et al. *Anticancer Research* 4:5, 1984]. We have previously reported the characteristics of these tumors studied by dynamic contrast enhanced MRI by using three contrast agents of various molecular weights [Su et al. *JMRI* 9:177-186, 1999]. The results indicated that the enhancement kinetics measured by the largest agent Albumin-Gd-DTPA in the high-grade infiltrating ductal carcinoma (IDC) has a higher vascular volume and permeability than that in the low-grade IDC, and fibroadenoma has the lowest vascular volume. In this study we performed quantitative vascular density measurements from the tumor specimens included in that study and investigated the association between the MRI results and the vessel density. A semiautomatic method was developed to measure the vascular area from the H&E stained histological slides. The vascular density between malignant tumors of different grades and 3 different types of benign tumors, fibroadenoma, tubular adenoma and papilloma were also compared.

Methods

The carcinogen N-ethyl-N-nitrosourea (ENU, 45-180 mg/kg) was injected into 50 SPF Sprague-Dawley rats to induce mammary tumors. When the tumor had reached 1.5 cm in diameter, dynamic contrast enhanced MRI studies were carried out by using three agents, Gd-DTPA (0.1 mmol/kg), Gadomer-17 (0.05 mmol/kg), and albumin-Gd-DTPA (0.02 mmol/kg). Gadomer-17 was provided by Schering AG (Berlin, Germany), which is a synthetic dendrimeric gadolinium chelate with an apparent molecular weight of 35 kD. Albumin-Gd-DTPA had a molecular weight of 90 kD. The experiments were performed on a GE 1.5 T Signa scanner. The dynamic images were acquired by using a spin-echo pulse sequence with TR/TE=140/14 ms. Gd-DTPA was injected first, 1 hour later followed by Gadomer-17. Albumin-Gd-DTPA study was conducted on a different day. After the imaging studies were finished, the tumor was removed for pathological examination. For each tumor, tissue samples from 2-6 regions were examined. In the case of infiltrating ductal carcinoma, SBR grade was determined.

For quantitative assessment of vascular density, we developed a digital dissection technique to measure the cross-sectional area of blood vessels in histological sections of tumors. Five micron thickness section was cut then stained with H&E. Ten digital images at 40x power were recorded from each slide. Each image represented a randomly selected, non-overlapping region of tumor and connective tissue. The RGB color

values were defined by the color of red blood cells in the image and by the color of the empty space in the blood vessels. The intravascular area was defined as a combination of red blood cells and clear areas devoid of any staining. To avoid contamination from necrotic debris, glandular lumen, or fat with same color-coding, it is necessary to have an experienced pathologist manually define a region of interest. After the RGB values and ROI were defined, the statistical program counted the number of pixels within the defined area to calculate the % vascular area. The results were compared among different types of lesions, and also correlated with the MRI enhancements measured by 3 contrast agents.

Results

The percent vascular area and the gray level enhancements at 3-min post contrast injection in different types of tumors, including infiltrating ductal carcinoma (IDC), fibroadenoma (FA), tubular adenoma (TA) and papilloma (PAP), are listed in table 1. Although tubular adenoma and papilloma were benign lesions, we found that these two tumors showed very strong enhancements. Interestingly they also had relatively high vascular density. In general, the IDC group had a significantly higher vascular density than the fibroadenoma ($13 \pm 7\%$ vs. $8 \pm 5\%$, $p < 0.05$). We also found 2 benign "epidermal inclusion cyst" in this study, which had a very low vascular area (less than 0.4%) as expected from the nature of the cyst, and also very low MRI enhancements. However, on a one-to-one basis, we failed to obtain a significant correlation between % vascular area and MRI enhancements measured by either of the 3 contrast agents used in this study.

Table 1: % vascular area and enhancements at 3-min post injection

	% Vascular	Gd-DTPA	Gadomer-17	Alb-Gd
IDC-LG (n=7)	13 ± 11 %	205 ± 33	112 ± 39	21 ± 11
IDC-MG (n=7)	14 ± 5 %	214 ± 65	168 ± 43	44 ± 15
IDC-HG (n=6)	13 ± 4 %	194 ± 62	181 ± 42	38 ± 13
FA (n=18)	8 ± 5 %	171 ± 47	103 ± 17	14 ± 10
TA (n=6)	14 ± 8 %	231 ± 61	175 ± 76	35 ± 5
PAP (n=3)	10 ± 6 %	276 ± 92	170 ± 54	38 ± 9

Discussion

A semiautomatic procedure was developed for quantitative measurements of vascular area in the H&E stained tumor slides. The advantage of this technique over the commonly used immunohistochemical staining using Factor-VIII, CD-31 or CD-34 is that it does not count on positive staining of endothelial cells. In addition, we may separately analyze the area occupied by the red blood cells vs. the empty lumen to obtain a measure of functional vessels in which the blood flows through. However, the problem of inadequate sampling still exists due to the nature of the analysis from thin histological sections as compared to the imaging study. Using a lower power field (e.g. 10x instead of 40x) may facilitate more adequate sampling. The difficulty in the investigation of correlation between vascular density and the MRI enhancements has long been recognized. Although the blood pool agent such as albumin-Gd-DTPA may provide a more accurate measurement of vascular volume, a substantial enhancement could be due to the leakage of agents into the interstitial space through vascular permeability. Accurate measurements of vascular volume/ permeability, either with imaging or histological methods, are in great need for the assessment of the therapeutic effect induced by anti-angiogenic (or, anti-vascular) agents.

Acknowledgement.

This work was supported in part by NIH grant # R21 CA86215 and US ARMY DAMD-17-01-1-0178.

Longitudinal Taxotere Chemotherapy Treatment Induced Vascular and Structural Changes Measured by Dynamic Enhanced MRI

Hon Yu, Min-Ying Su, Jun Wang, and Orhan Nalcioglu
Center for Functional Onco-Imaging, University of California, Irvine, CA 92697

Abstract

Chemotherapy induced longitudinal vascular changes taking place during the growth of an animal tumor, R3230 AC adenocarcinoma were investigated using two contrast agents with different molecular weights, Gd-DTPA and Gadomer-17. Treated animals were separated into responders and partial-responders according their viable growth rate 3 weeks after the therapy. In responders a decrease in the vascular volume as well as in the vascular permeability were observed at 2-week post-therapy compared to 1-week's, whereas in controls an increase in both the vascular volume and permeability were observed at 2-week's compared to 1-week's as measured by Gadomer-17 using a pharmacokinetic model on a pixel-by-pixel basis, suggesting that vascular changes assessed by Gadomer-17 could serve as a tumor treatment monitor.

Purpose

Chemotherapy induced vascular and structural changes taking place in tumors were studied by using dynamic contrast enhanced MRI. In this study we investigated the longitudinal vascular changes occurring in tumors receiving Taxotere (an anti-angiogenic drug) treatment in order to find out if the vascular changes can serve as early indices that precede the structural changes (volumetric changes of viable region) in tumors' growth. In order to investigate the longitudinal vascular changes, we applied the dynamic contrast enhanced MRI with two different contrast agents, Gd-DTPA (<1 kD) and Gadomer-17 (35 kD), on the R3230 AC adenocarcinoma model. The baseline study was first performed then the animals received weekly taxotere treatment and weekly follow-up MRI studies. The measured enhancement kinetics of both contrast agents were analyzed with a pharmacokinetic model to derive parameters related to vascular volume (Vb) and permeability (K2) on a pixel-by-pixel basis. In each tumor the pixel population distribution curves of these two measured parameters and the volumetric changes in tumor size were calculated and the longitudinal changes in these two parameters were compared between the control and the treated groups to assess the differences between them.

Methods

Nine female Fisher-344 rats (160 ~ 170 g) bearing the R3230 AC adenocarcinomas were used in the study. When the tumor size grew to about 0.8 cm in diameter, the baseline study was conducted right after which six of the nine rats received the chemotherapy by injection of taxotere (4 mg/kg). At one (post-1), two weeks (post-2) and three weeks (post-3) after the baseline study the experiments were repeated and the rats in the treated group received the chemotherapy again after each MRI study. All of the MRI experiments were performed on a 3.0-T scanner using a Marconi console. The T2-weighted images covering across the tumor were acquired for volumetric measurements and a fast 3-D. Vol. T1-weighted dynamic sequence with TR/TE = 18/3.6 ms was used for the dynamic imaging with sequential injections of Gd-DTPA (0.1 mmol/kg), followed by Gadomer-17 (0.05 mmol/kg, a dendrimeric compound with size equivalent to 35 kD protein, provided by Schering AG, Berlin, Germany). The viable volumes, which were separated by the threshold segmentation from the total tumor volumes, measured at post-3 were normalized to their respective volumes measured at post-2 to calculate the viable growth ratio in each tumor. The enhancement kinetic from the viable region was measured and analyzed on a pixel-by-pixel basis by using a 2-compartmental model and the pixel population curves of Vb and K2 were obtained in each tumor. The longitudinal vascular changes in Vb and K2 were then compared between the control and the treated tumors.

Results

Three of the six treated rats were classified as the responder group as they showed a viable growth ratio of less than 1 (0.82, 0.88 and 0.88), whereas the other three treated rats were classified as partial responder group as their ratios were greater than 1 (1.07, 1.22 and 1.26), but still lower than the control group's (1.92, 1.93 and 2.24). The results obtained from analysis of the Gd-DTPA kinetics did not show any differences between the control and the treated groups and not presented here. Figures 1a and 1b show the pixel population distributions of Vb and K2, respectively, for the control group measured with Gadomer-17 at post-1 and post-2 which preceded the determination of the viable growth rate by one week. In the control group the curve at post-2 for Vb shows an increase throughout the whole population compared to the post-1's, whereas the distribution for K2 at post-2 shows an increase respect to its post-1's throughout the whole population. Figures 2a and 2b show the pixel population distributions at post-1 and post-2 measured with Gadomer-17 for Vb and K2 of the partial responder group, respectively. The partial

responder group still shows an increase in Vb at post-2 respect to post-1's, but mostly in >50% pixel population range and shows a decrease in K2, mostly pronounced in >60% percentile range. The pixel population distribution curves of Vb and K2 for the responder group, which are shown in figures 3a and 3b, respectively, show a decrease in Vb in the entire population, and also show a decrease in K2, markedly in >50% percentile range, going from post-1 to post-2.

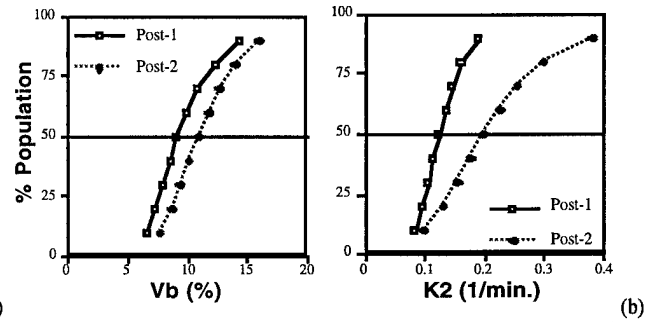


Figure 1. The pixel population distribution curves of Vb(a) and K2(b) from the control group.

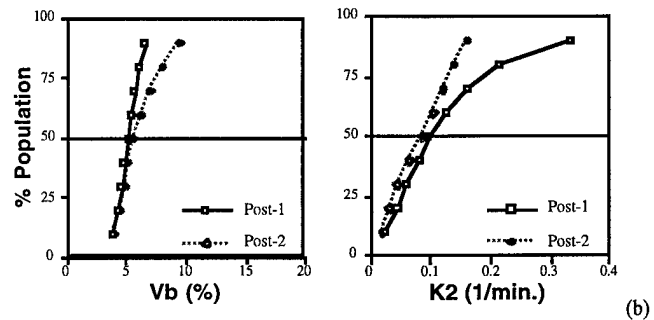


Figure 2. The pixel population distribution curves of Vb(a) and K2(b) from the partial responder group.

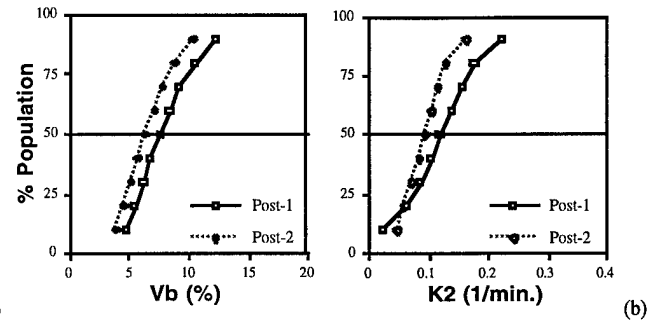


Figure 3. The pixel population distribution curves of Vb(a) and K2(b) from the responder group.

Discussion

The vascular changes after the chemotherapy in this study as measured by Gadomer-17 seem to suggest that these changes could be used to predict the structural changes in tumor that would follow. The tumors in the responder group showed clearly different vascular changes at week-2 post the chemotherapy was initiated, which preceded the week-3 post time point when the viable growth ratio was determined to show the decrease in the viable volume, as measured by the parameters Vb and K2 compared to the control tumors' at the same time point. The results suggest that the early vascular changes in Vb and K2 as measured by Gadomer-17 could possibly serve to predict the treatment efficacy.

Acknowledgement

This work was supported in part by the US ARMY BCRP grant number DAMD17-01-0178.

Characterization of Carcinogen ENU Induced Benign and Malignant Mammary Tumors in Rats: Volumetric Growth Rates, Contrast Enhancement Kinetics, and Longitudinal Monitoring

Hon Yu, Min-Ying Su, Jun Wang, Phillip M. Carpenter², and Orhan Nalcioğlu
Center for Functional Onco-Imaging, and ²Department of Pathology, University of California-Irvine, CA, USA

Abstract

The carcinogen ENU could induce malignant tumors of various nuclear grades and different types of benign tumors, thus it can serve to investigate the sensitivity and specificity of experimental diagnostic agents for differential diagnosis and tumor staging. However, whether it can be used for studies of recurrence or metastasis has rarely been studied. We measured the volumetric growth rate and the enhancement kinetics of Gd-DTPA and Gadomer-17 for each tumor, and differences between malignant and benign tumors were investigated. Each tumor was surgically removed and the rats were kept for longitudinal monitoring for recurrence, development of other tumors, and metastasis.

Purpose

We performed a longitudinal study to characterize carcinogen ENU induced mammary tumor model. ENU can induce benign and malignant tumors in rats, and the malignant tumors came with various SBR (Scarff-Bloom-Richardson) grades, thus it can be used a suitable model for studies of differential diagnosis between benign and malignant tumors as well as malignant tumor grade staging. For each tumor 2 MRI studies were performed. The volumetric growth rates were calculated from the sizes measured in these two studies. The enhancement kinetics of two contrast agents, the small agent Gd-DTPA and a mid-sized agent Gadomer-17, were measured. The volumetric growth rates, as well as the early (30-sec) and maximum (approximately 2-min) enhancements between benign and malignant tumors were compared. Each tumor was surgically removed and the rats were kept for observation of recurrence, further development of other tumors, and metastasis into other organs, to explore whether this model can be used to study recurrence and metastasis as in human breast cancer.

Methods

N-ethyl-N-nitrosourea (ENU, 90 mg/kg) was injected i.p. into 30-day old SPF Sprague-Dawley rats (n=50) to induce mammary tumors [Stoica et al. Anticancer Research 4:5, 1984]. The tumors started to appear 2 months after injection. The baseline MRI study was performed when the tumor reached approximately 1.0 cm in diameter. The experiments were performed on a home-built 3.0 T scanner with technical support provided by Marconi Inc. The protocol included a T2-weighted fast spin echo sequence (TR/TE= 3000/105 ms, echo train=8, FOV=14 cm, 2-mm slice) covering the entire tumor for volumetric measurement, and dynamic contrast enhanced studies using two agents, Gd-DTPA (0.1 mmol/kg) and Gadomer-17 (0.05 mmol/kg). Gadomer-17 was provided by Schering AG (Berlin, Germany), which is a synthetic dendrimeric gadolinium chelate with an apparent molecular weight of 35 kD. The dynamic images were acquired by using a 3D gradient echo pulse sequence with TR/TE=18/3.6 ms, flip angle=20°, FOV=10.5, 5-mm thickness). Gd-DTPA was injected first, and 1 hour later Gadomer-17 was injected. In 1-3 weeks when the tumor size was approximately doubled, the follow-up MRI study was performed. Only the T2-weighted sequence was performed to measure the tumor volume. The volumetric growth rates were expressed in cc/day. The early and maximum enhancements at 30-sec and 2-min after contrast administration was measured. After the imaging studies were finished, the tumor was surgically removed for pathological examination. The rats were kept alive for observation of recurrence or development of additional tumors. If more tumors were found, the same baseline and follow-up MRI studies were performed again. Rats were euthanized when there were tumors found in the abdomen. The abdominal tumor was also removed for pathological examination to determine whether it was a metastasis from the mammary tumor or it was from a different origin.

Results

Ninety three tumors were found in 1 year after the injection of ENU. Most tumors belonged to four major types, 2 malignant and 2 benign. The

malignant tumors included ductal adenocarcinoma (n=25) and papillary adenocarcinoma (n=21), and the two major benign lesions were fibroadenoma (n=24) and adenosis (n=13). Multiple tumors (up to 5) could develop in one rat, all at different locations. Interestingly no tumor recurrence was observed at the surgical site after removal of a previous tumor. Also, none of the abdominal tumors were from breast origin. We also investigated lymph nodes from some rats, and found no sign of any cancer. The growth rates and the early (30 sec) and maximum (2-min) enhancements measured by Gd-DTPA and Gadomer-17 are listed in table 1. The bar graphs are shown in Figure 1. The two malignant tumors exhibited similar enhancement kinetics, showing rapid early enhancing slope and high enhancement magnitude. The two benign lesions had much slower early enhancing slope (highly significantly). However, adenosis could reach to a higher enhancement at 2-min after contrast administration, almost comparable to that in malignant tumors. The enhancements at 2-min between fibroadenoma and malignant tumors also became closer, but still significantly different.

Table 1: Growth Rate & Enhancements in 4 tumor types

	Papillary AC	Ductal AC	Adenosis	FA
GR (cc/day)	0.07 ± 0.14	0.06 ± 0.13	0.05 ± 0.06	0.03 ± 0.03
Gd-DTPA 30s	126 ± 68	122 ± 62	57 ± 22	39 ± 14
Gd-DTPA 2min	240 ± 75	251 ± 69	204 ± 65	145 ± 54
Gadomer17 30s	52 ± 23	47 ± 30	24 ± 11	23 ± 10
Gadomer17 2min	96 ± 32	92 ± 40	73 ± 22	51 ± 19

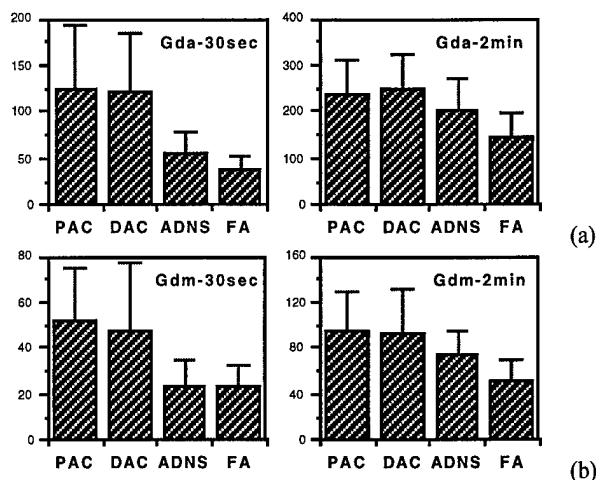


Figure 1: The enhancements at 30-sec and 2-min after injection of Gd-DTPA(a) and Gadomer-17(b) in 4 tumor types. Malignant tumors had higher early enhancements. Results measured by both agents were similar.

Discussion

The carcinogen ENU induced benign and malignant tumors, thus this animal tumor model was suitable for studies of experimental diagnostic agents. A better characterization of this model is needed. Our results demonstrated that all developed tumors were primary tumors, and they did not metastasize to lymph nodes or to other organs. The growth rates showed large variations even within each tumor type, and they were not correlated with the enhancement kinetics of both studied contrast agents. As in human breast tumors, the early enhancement is the best parameter to differentiate benign from malignant tumors.

Acknowledgement

This work was supported in part by NIH grant # R21 CA86215 and US ARMY DAMD-17-01-1-0178.