

AD \_\_\_\_\_

Award Number: DAMD17-02-1-0523

TITLE: Comparison of Image Quality Among Variations in Specimen  
Tissue Compression and Fluid Immersion for Diffraction  
Enhanced Imaging

PRINCIPAL INVESTIGATOR: Christopher A. Parham

CONTRACTING ORGANIZATION: University of North Carolina  
at Chapel Hill  
Chapel Hill, North Carolina 27599-1350

REPORT DATE: June 2003

TYPE OF REPORT: Annual Summary

PREPARED FOR: U.S. Army Medical Research and Materiel Command  
Fort Detrick, Maryland 21702-5012

DISTRIBUTION STATEMENT: Approved for Public Release;  
Distribution Unlimited

The views, opinions and/or findings contained in this report are those of the author(s) and should not be construed as an official Department of the Army position, policy or decision unless so designated by other documentation.

20031212 128

# REPORT DOCUMENTATION PAGE

Form Approved  
OMB No. 074-0188

Public reporting burden for this collection of information is estimated to average 1 hour per response, including the time for reviewing instructions, searching existing data sources, gathering and maintaining the data needed, and completing and reviewing this collection of information. Send comments regarding this burden estimate or any other aspect of this collection of information, including suggestions for reducing this burden to Washington Headquarters Services, Directorate for Information Operations and Reports, 1215 Jefferson Davis Highway, Suite 1204, Arlington, VA 22202-4302, and to the Office of Management and Budget, Paperwork Reduction Project (0704-0188), Washington, DC 20503

<b>1. AGENCY USE ONLY</b> (Leave blank)		<b>2. REPORT DATE</b> June 2003	<b>3. REPORT TYPE AND DATES COVERED</b> Annual Summary (1 Jun 2002 - 31 May 2003)	
<b>4. TITLE AND SUBTITLE</b> Comparison of Image Quality Among Variations in Specimen Tissue Compression and Fluid Immersion for Diffraction Enhanced Imaging			<b>5. FUNDING NUMBERS</b> DAMD17-02-1-0523	
<b>6. AUTHOR(S)</b> Christopher A. Parham				
<b>7. PERFORMING ORGANIZATION NAME(S) AND ADDRESS(ES)</b> University of North Carolina at Chapel Hill Chapel Hill, North Carolina 27599-1350  E-Mail: christopher_parham@med.unc.edu			<b>8. PERFORMING ORGANIZATION REPORT NUMBER</b>	
<b>9. SPONSORING / MONITORING AGENCY NAME(S) AND ADDRESS(ES)</b> U.S. Army Medical Research and Materiel Command Fort Detrick, Maryland 21702-5012			<b>10. SPONSORING / MONITORING AGENCY REPORT NUMBER</b>	
<b>11. SUPPLEMENTARY NOTES</b> Original contains color plates: All DTIC reproductions will be in black and white.				
<b>12a. DISTRIBUTION / AVAILABILITY STATEMENT</b> Approved for Public Release; Distribution Unlimited				<b>12b. DISTRIBUTION CODE</b>
<b>13. ABSTRACT (Maximum 200 Words)</b>  <p>Significant improvements have been made in mammography over the past two decades; however, all current existing radiographic systems rely on x-ray absorption to define the differences between normal and abnormal tissues. Given the complexity of imaging breast tissue, there are characteristics and findings that are difficult to interpret or missed entirely by conventional methods. A new radiographic imaging method, Diffraction Enhanced Imaging (DEI), has been proposed to extend the capabilities of the current standard and increase detection of occult disease.</p> <p>This study is designed to compare the fine structural detail provided by DEI under several tissue preparation conditions. The preparation variables include the pressure used to compress the tissues and the use of air-filled versus water-filled containers for imaging. Our hypothesis is that compression pressure will have no significant effect upon the imaging of fine structural detail. This could reduce the need for breast compression which is a uniformly unpleasant component of conventional mammography.</p> <p>The tissue compression plates have been built and several images have been obtained at Brookhaven National Laboratory characterizing various disease conditions. Tissue specimens will continue to be collected, imaged, and processed for use in an upcoming reader study to determine the effects of compression on visualization.</p>				
<b>14. SUBJECT TERMS</b> Radiological Sciences, Technology Development, Diffraction Enhanced Imaging				<b>15. NUMBER OF PAGES</b> 15
				<b>16. PRICE CODE</b>
<b>17. SECURITY CLASSIFICATION OF REPORT</b> Unclassified	<b>18. SECURITY CLASSIFICATION OF THIS PAGE</b> Unclassified	<b>19. SECURITY CLASSIFICATION OF ABSTRACT</b> Unclassified	<b>20. LIMITATION OF ABSTRACT</b> Unlimited	

## Table of Contents

<b>Cover.....</b>	<b>1</b>
<b>SF 298.....</b>	<b>2</b>
<b>Table of Contents.....</b>	<b>3</b>
<b>Introduction.....</b>	<b>4</b>
<b>Body.....</b>	<b>5</b>
<b>Key Research Accomplishments.....</b>	<b>9</b>
<b>Reportable Outcomes.....</b>	<b>10</b>
<b>Conclusions.....</b>	<b>11</b>
<b>References.....</b>	<b>12</b>
<b>Appendices.....</b>	<b>13</b>

## **INTRODUCTION:**

**Background:** Significant improvements have been made in mammography over the past two decades; however, all current existing radiographic systems rely on X-ray absorption to define the differences between normal and abnormal tissues. Given the complexity of imaging breast tissue, there are characteristics and findings that are difficult to interpret or missed entirely by conventional methods. A new radiographic imaging method, Diffraction Enhanced Imaging (DEI), has been proposed to extend the capabilities of the current standard and increase detection of occult disease.

**Objective/Hypothesis:** This study is designed to compare the fine structural detail provided by DEI under several tissue preparation conditions. The preparation variables include the pressure used to compress the tissues and the use of air-filled versus water-filled containers for imaging. The effects of these conditions will be evaluated for each of the standard DEI output modalities. Our hypothesis is that compression pressure will have no significant effect upon the imaging of fine structural detail. This could reduce the need for breast compression which is a uniformly unpleasant component of conventional mammography.

**Specific Aims:** (1) To determine whether compression is needed with Diffraction Enhanced Imaging to see the same structural detail as in conventional mammography.

**Study Design:** Collect images of mastectomy and breast specimens at different levels of compression using both digital mammography and DEI. Once collected, a reader study will be conducted where radiologist readers will score images taken at different compression levels according to which images yield the most information.

**Relevance:** Differences between healthy and cancerous tissues are very small and scattering of X-rays can lead to blurring and lower contrast, making it difficult to detect small tumors. DEI produces images of the refraction and apparent absorption of an object, which allows for visualization of objects that are difficult to interpret with mammography such as thread-like fibers that characterize some malignant tumors. This project will determine whether DEI is able to produce detailed, high resolution images of breast tissue without compression.

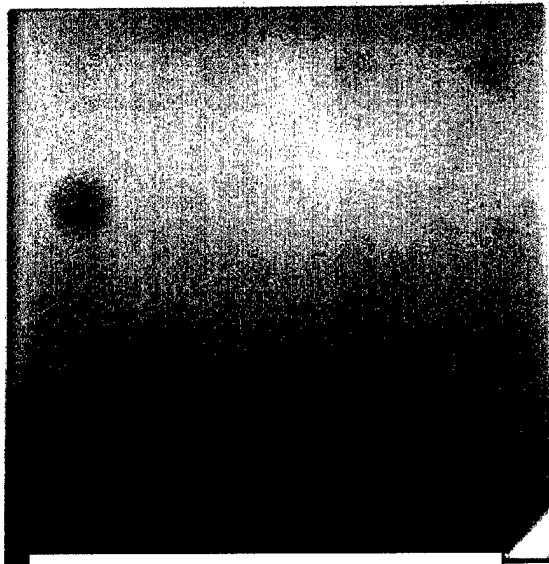
**Training Plan:** The training necessary for completion of this project will be encompassed under the doctoral requirements of the Department of Biomedical Engineering and School of Medicine.

## **BODY:**


Despite recent improvements in mammography imaging systems, breast cancer continues to rank as one of the leading causes of death in women, with an estimated 182,000 new cases and 44,000 deaths each year.<sup>1</sup> The current standard for mammography is a screen-film system, and numerous large randomized screen trials show that screen-film mammography reduces breast cancer mortality by approximately 18-30%.<sup>2,3</sup> In conventional mammography as well as general x-ray imaging, differences in tissue densities and composition are shown, due to absorption, as contrasting areas in the image allowing visualization of tumors or changes in tissue. The problem is that differences between healthy and cancerous tissues are very small, and scattering of x-rays can lead to blurring and lower contrast, making it difficult to detect small tumors. These small tumors, if missed, will continue to grow until such time that their size and density is sufficient for visualization. Given the fact that cancer is a time dependent disease, detecting malignant areas at an early stage is paramount.

What if a second contrast mechanism could be added to the information already obtained through the density of tissue? The unique physical characteristics of Diffraction Enhanced Imaging (DEI) allow for one to investigate both density and refraction. Malignant areas of tissues may have similar densities, which will not produce a great deal of contrast. However, they may have significant differences in the way that they refract x-rays. For example, the fine speculations that extend from cancers are highly refracting and are clearly seen with the DEI imaging technique. Preliminary studies have indicated that DEI offers a significant advantage over conventional x-ray systems. Seven breast cancer specimens were examined with DEI and compared with digital radiographs of the specimen. Six of the seven cases (86%) showed enhanced visibility of surface spiculations that correlated with histopathologic information, including extension of tumor into surrounding tissue<sup>5</sup>

The overall goal of the DEI Development Group is to build a clinical imaging prototype, but the system is currently in a laboratory form at the National Synchrotron Light Source. As currently implemented, using synchrotron radiation, the DEI method uses a single-energy (monochromatic) fan beam of x-rays—instead of the broad polychromatic energy beam of conventional imaging systems. The object or tissue is scanned through the beam and the data is recorded on a detector. This method of line scan imaging reduces scatter and increases visualization of low-contrast areas that otherwise would be lost. An example of the increased visualization ability can be seen in the radiographs below. The American College of Radiology test phantom is often used for quality assurance and testing. Notice the spectacular visualization of both the tumor mass simulations and calcification simulations.



**Conventional X-ray Image**



**Diffraction Enhanced Image**

In contrast to conventional x-ray systems, the DEI system utilizes a perfect silicon crystal to collimate the x-ray photons as they leave the object being imaged. Why is this important? Photons can do several things when they interact with matter, and one of the most common events is scatter. The more photons scatter, the more the image will be blurred. Since many indicators of breast cancer are in the 30-50 micron range, even a minimal amount of scatter will obscure these regions. To counteract this effect breast tissue is compressed for a typical mammogram, thus reducing the change that the photons will scatter. The level of compression needed results in a considerable level of discomfort and pain for patients. The hypothesis set forth in this proposal is that the components of a DEI imaging system will reduce or eliminate the need for breast compression. It is believed that the filtering effect of the silicon analyzer crystal will be far more effective than mechanical compression of the breast.

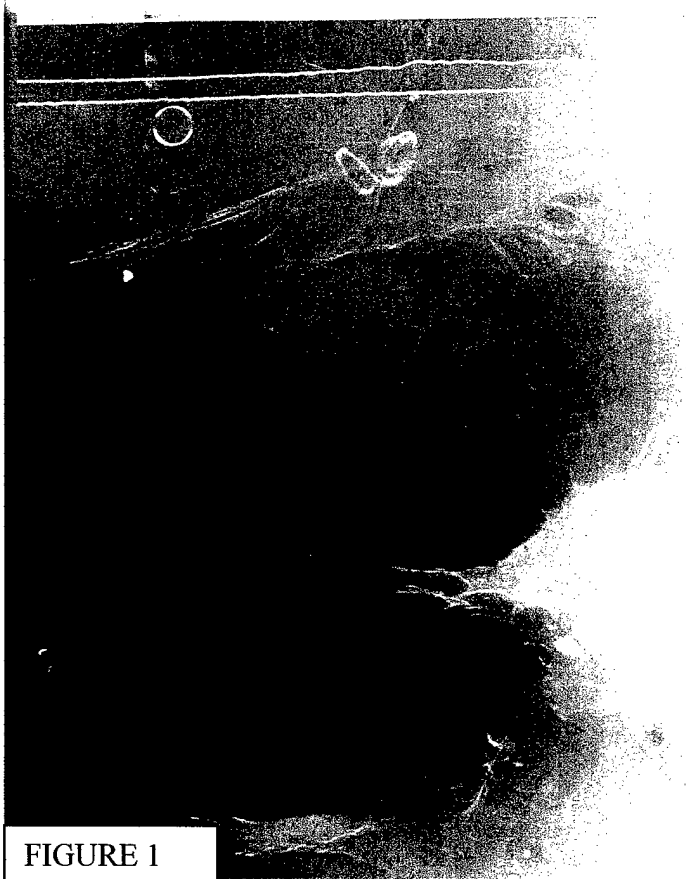The system is still in its experimental stages, so actual patient imaging is still prohibited. In order to ascertain the effects of compression on visualization, it was decided that mastectomy specimens would provide insight into this question. A set of tissue compression plates have been built to simulate the mechanical compression that would occur in a typical mammogram. They have been constructed out of Lucite and have an imaging area of 90mm by 90 mm. Different levels of compression can be applied by adjusting the compression screws on the side of the device.

One problem that has arisen is the availability of adequate mastectomy specimens. Tissues have been and are currently being collected from cadavers as well as from the Surgical Pathology Department, per Institutional Review Board Protocol. Samples obtained from Surgical Pathology are excellent samples, but they are often cut for clinical analysis and are generally  $\frac{1}{2}$  to  $\frac{3}{4}$  the size of an intact breast. Samples from cadavers

have not been cut, but there has been some degree of difficulty finding specimens with appropriate regions of interest. Four samples from Surgical Pathology have been imaged, as well as two cadaver mastectomy specimens. The cadaver specimens have been collected from the UNC School of Medicine, and the remainder of specimens required will be obtained in early August.

In order to maximize efficiency, the image processing tasks required for viewing have been performed on the tissues already imaged. This database of images will be used for a reader study scheduled to begin as soon as a sufficient number of appropriate tissues have been obtained.

Below are examples of the images that have been obtained thus far. Notice the exceptional visualization of the speculations extending from the central cancer in both figure 1 and figure 2. Each of the images is evaluated by an expert breast imager, Etta D. Pisano, M.D., before they are added to the reader study database.



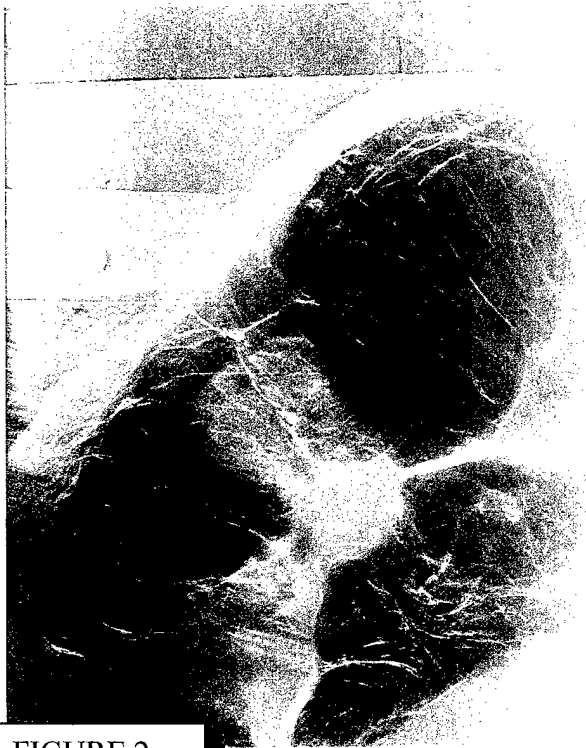

FIGURE 2

Once the remaining samples have been obtained and imaged, they will be processed and analyzed by an experienced pathologist. This will give the pathologic truth necessary to complement the reader study.

#### TRAINING:

The training environment provided by the lab of Dr. Etta Pisano, M.D. and the coursework training from the UNC Department of Biomedical Engineering has been critical to the execution of this grant proposal. Diffraction Enhanced Imaging is a promising but complicated topic, requiring significant training to properly conduct the research. I have now completed two years of engineering coursework focused on x-ray physics and medical imaging. The resources provided by this grant have helped me secure the knowledge necessary to determine this most critical aspect of the Diffraction Enhanced Imaging Development Project.

## KEY RESEARCH ACCOMPLISHMENTS:

- Obtained four breast specimens and two full mastectomy specimens. Continuing search for more specimens from both the UNC Surgical Pathology department and cadaver specimens from the UNC School of Medicine to complete image database
- Created and built 4 tissue compression holders for study
- Imaged four breast specimens and full mastectomy specimens at Brookhaven National Laboratory and on the Fischer Digital Mammography system at UNC Hospitals
- Begun processing of images for reader study including registration of image pairs
- Developed and tested image viewer to be used for reader study

## **REPORTABLE OUTCOMES:**

### **Presentations Based on Research from this Grant:**

Parham, CA. Medical Applications and Physical Characterization of Diffraction Enhanced Imaging. Brookhaven National Laboratory Seminar Series. July 2002.

Parham, CA. Medical Applications and Physical Characterization of Diffraction Enhanced Imaging. UNC Biomedical Engineering Research Review. April 2003.

### **DEI Image Database:**

All of the images obtained for the reader study will also be added to a DEI tissue database that can be used for secondary analysis by other members of the DEI research team. There is an enormous amount of physical information contained in the images, and the database was created to extract as much of this information as possible.

### **Manuscript:**

A manuscript of this project will be written and submitted for publication at the conclusion of this study.

**CONCLUSIONS:**

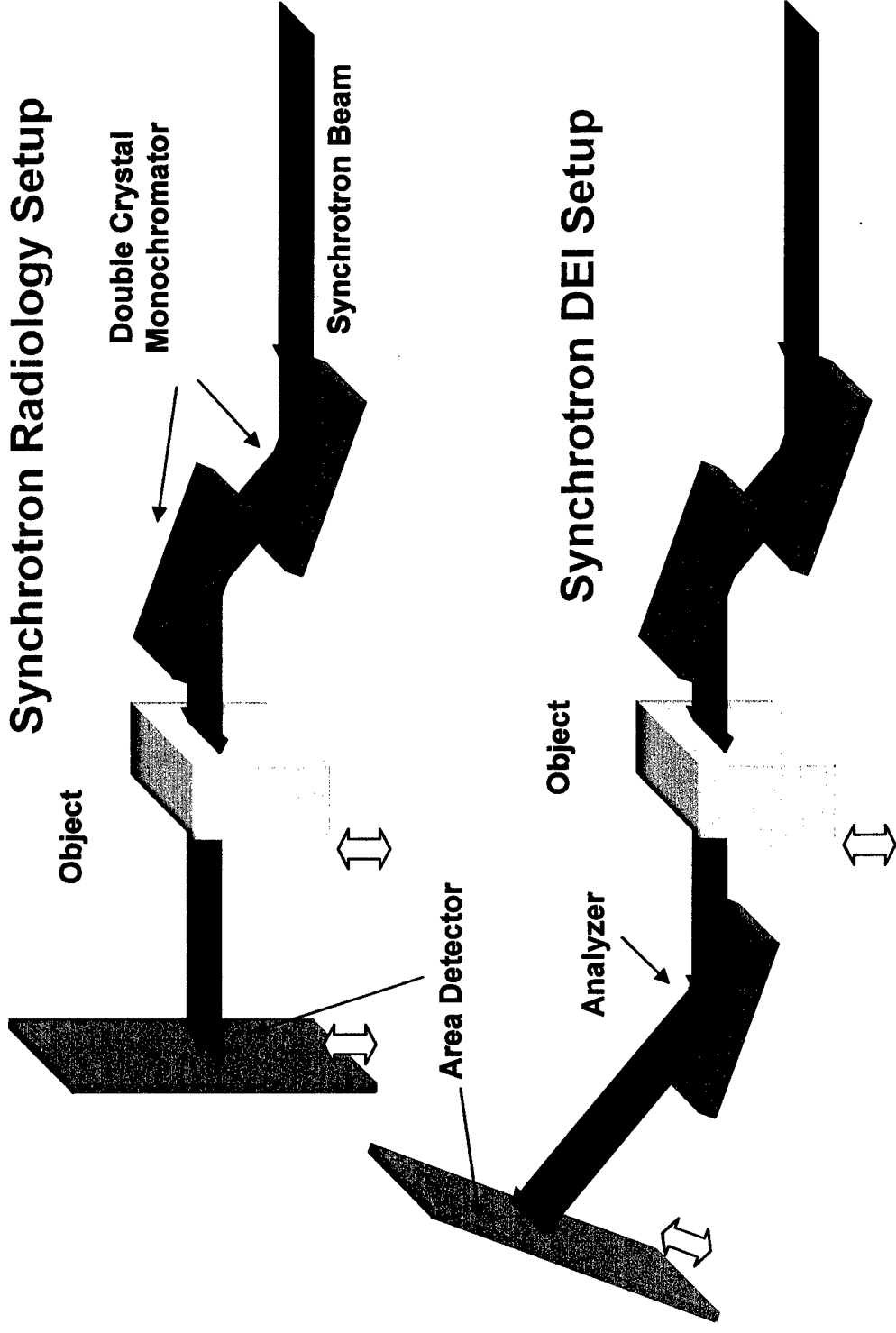
The study is at its mid-point, so there are no conclusions to report at this time.

## REFERENCES:

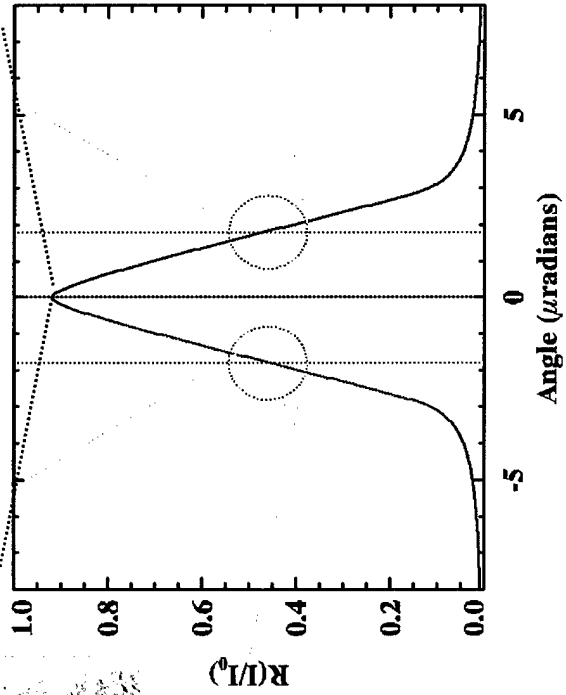
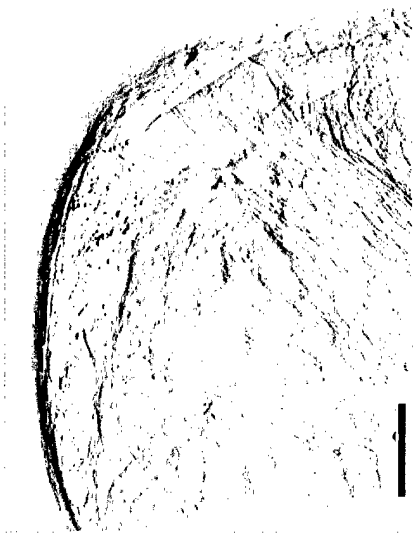
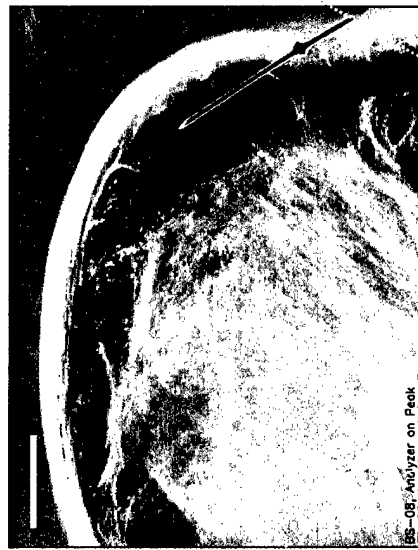
1. Tabar L, Duffy SW, Krusemo UB. Detection method, tumor size and node metastases in breast cancers diagnosed during a trial of breast cancer screening. *Eur J Cancer Clin Oncol* 23:959-962, 1987.
2. Hendrick RE, Smith RA, Rutledge JH. Benefit of screening mammography in women ages 40-49: a new meta-analysis of randomized controlled trials. *Journal of the National Cancer Institute Monograph* 22:87-92, 1997.
3. Nystrom L, Rutqvist LE, Wall S. Breast cancer screening with mammography: overview of Swedish randomized trials. *Lancet* 342(8851): 973-8, 1993.
4. Pisano ED, Parham, CA. Digital Mammography, Sestamibi Breast Scintigraphy, and Positron Emission Tomography Breast Imaging. *Radiologic Clinics of NA.* 38(4): 861-870, 2000.
5. Pisano ED, Johnston, RE, Chapman D, Geradts J, Sayers D, Tomlinson W. Diffraction Enhanced Imaging of Human Breast Cancer Specimens: Improved Conspicuity of Lesion Detail with Histologic Correlation. *Radiology* 241(3); 895-901, 2000.

# APPENDIX

# Synchrotron Radiography and DEI



# Principles of DEI Image Acquisition



size bar = 1 cm