

AD \_\_\_\_\_

Award Number: DAMD17-00-1-0570

TITLE: Characterization of the Chicken Ovarian Cancer Model

PRINCIPAL INVESTIGATOR: Gustavo C. Rodriguez, M.D.

CONTRACTING ORGANIZATION: Evanston Northwestern Healthcare  
Research Institute  
Evanston, IL 60201

REPORT DATE: August 2003

TYPE OF REPORT: Annual

PREPARED FOR: U.S. Army Medical Research and Materiel Command  
Fort Detrick, Maryland 21702-5012

DISTRIBUTION STATEMENT: Approved for Public Release;  
Distribution Unlimited

The views, opinions and/or findings contained in this report are those of the author(s) and should not be construed as an official Department of the Army position, policy or decision unless so designated by other documentation.

20040311 156

**REPORT DOCUMENTATION PAGE**Form Approved  
OMB No. 074-0188

Public reporting burden for this collection of information is estimated to average 1 hour per response, including the time for reviewing instructions, searching existing data sources, gathering and maintaining the data needed, and completing and reviewing this collection of information. Send comments regarding this burden estimate or any other aspect of this collection of information, including suggestions for reducing this burden to Washington Headquarters Services, Directorate for Information Operations and Reports, 1215 Jefferson Davis Highway, Suite 1204, Arlington, VA 22202-4302, and to the Office of Management and Budget, Paperwork Reduction Project (0704-0188), Washington, DC 20503

<b>1. AGENCY USE ONLY</b> (Leave blank)	<b>2. REPORT DATE</b> August 2003	<b>3. REPORT TYPE AND DATES COVERED</b> Annual (15 Jul 2002 - 14 Jul 2003)	
<b>4. TITLE AND SUBTITLE</b> Characterization of the Chicken Ovarian Cancer Model		<b>5. FUNDING NUMBERS</b> DAMD17-00-1-0570	
<b>6. AUTHOR(S)</b> Gustavo C. Rodriguez, M.D.			
<b>7. PERFORMING ORGANIZATION NAME(S) AND ADDRESS(ES)</b> Evanston Northwestern Healthcare Research Institute Evanston, IL 60201  E-Mail: grodriguez@enh.org		<b>8. PERFORMING ORGANIZATION REPORT NUMBER</b>	
<b>9. SPONSORING / MONITORING AGENCY NAME(S) AND ADDRESS(ES)</b> U.S. Army Medical Research and Materiel Command Fort Detrick, Maryland 21702-5012		<b>10. SPONSORING / MONITORING AGENCY REPORT NUMBER</b>	
<b>11. SUPPLEMENTARY NOTES</b>			
<b>12a. DISTRIBUTION / AVAILABILITY STATEMENT</b> Approved for Public Release; Distribution Unlimited		<b>12b. DISTRIBUTION CODE</b>	
<b>13. ABSTRACT (Maximum 200 Words)</b> <p>We believe that the domestic laying hen has great potential as an animal model for ovarian cancer prevention research. Unlike other ovarian cancer models, which require experimental induction of ovarian tumors, chickens develop ovarian adenocarcinoma spontaneously, with an incidence ranging from 13 to 40 percent between four and six years of life. Few investigators have taken advantage of the chicken to study ovarian cancer. Thus, the chicken ovarian cancer model remains to be validated and developed. As part of a prevention trial in chickens funded by the Department of Defense, we have accumulated 1400 chicken reproductive tracts including 140 with adenocarcinomas, and gathered valuable data regarding the natural history of these tumors. This provides the remarkable opportunity to critically evaluate the chicken ovarian cancer animal model and determine its relevance to human ovarian cancer research. The aim of the current proposal is to increase our understanding of the molecular and histologic features of chicken ovarian cancers. In addition, we will develop a histologic classification for chicken ovarian cancers, which is a critically important prerequisite to the widespread use of this animal model for ovarian cancer research.</p>			
<b>14. SUBJECT TERMS</b> Ovarian Cancer, animal model, chemoprevention		<b>15. NUMBER OF PAGES</b> 14	
		<b>16. PRICE CODE</b>	
<b>17. SECURITY CLASSIFICATION OF REPORT</b> Unclassified	<b>18. SECURITY CLASSIFICATION OF THIS PAGE</b> Unclassified	<b>19. SECURITY CLASSIFICATION OF ABSTRACT</b> Unclassified	<b>20. LIMITATION OF ABSTRACT</b> Unlimited

**Table of Contents**

**Cover.....1**

**SF 298.....2**

**Table of Contents.....3**

**Introduction.....4**

**Body.....5**

**Key Research Accomplishments.....9**

**Reportable Outcomes.....9**

**Conclusions.....10**

**References.....10**

**Appendices.....11**

## Introduction

Epithelial ovarian cancer is a highly lethal malignancy. It is the fifth leading cause of cancer deaths among women in the United States and causes 140,000 deaths annually in women worldwide. Despite intensive research efforts over the past decade directed towards improved detection and treatment, the long-term survival of women with ovarian cancer has only improved modestly. Progress in the fight against ovarian cancer has been hampered by a number of factors, including late diagnosis, molecular heterogeneity of tumors, absence of highly curative chemotherapy, and lack of a valid animal model.

We believe that development of effective chemopreventive agents for ovarian cancer represents our best hope for decreasing ovarian cancer mortality in the future. Based on our studies in primates and in the laboratory, we are convinced that the well-known protective effect of oral contraceptives against ovarian cancer is due, in large part, to the molecular biologic effects of progestins on the ovary. We have found that progestins differentially regulate TGF-beta expression and markedly activate the apoptosis pathway in the ovarian epithelium, making it more likely that cells that have incurred genetic damage will be eliminated, rather than develop into cancer. A number of other apoptosis-inducing agents also hold promise for preventing ovarian cancer, including retinoids. Ultimately, it is our goal to develop a preventive strategy using the best chemopreventive agents, either alone or in combination, in order to achieve maximum protection against ovarian cancer.

At this time, the lack of a valid ovarian cancer animal model is a major obstacle to ovarian cancer prevention research. In order to develop pharmacologic preventive strategies for ovarian cancer in a timely fashion, animal models that closely mimic human ovarian cancer are desperately needed. Human prevention trials are costly requiring large numbers of subjects and many years to complete. Development of an animal model for ovarian cancer prevention research would represent a significant breakthrough and lead to expedited evaluation of numerous candidate agents. Ideally, this would lead to rapid identification of a select number of agents, which have the greatest potential for ovarian cancer prevention and that can then be evaluated in human prevention trials.

We believe that the domestic laying chicken has great potential as an animal model for studying chemoprevention of ovarian cancer. Unlike other animal models for ovarian cancer, which generally require the experimental induction of ovarian tumors, the chicken develops ovarian cancer spontaneously. The domestic hen is the only animal with a high incidence of spontaneous ovarian adenocarcinoma, ranging from 13 to 40 percent between four and six years of life. Few investigators have taken advantage of the chicken to study ovarian cancer. Thus, the chicken ovarian cancer model remains to be validated and developed. As part of a chemoprevention grant awarded to us by the Department of Defense in 1998, we have performed a two-year chemoprevention trial in the chicken designed to test the hypothesis that progestins confer chemopreventive effects against ovarian cancer. We are now conducting a second prevention trial in the chicken, funded by the NIH, evaluating progestin and the retinoid 4-HPR as candidate preventives. The terminal necropsy and collection of tissues for analysis from this trial has just been completed (August 2003). In addition, during this past year we had the

opportunity to examine 2004 hens representing different strains that were 28 months of age and subjected to two molting procedures. This was extremely useful as it provided a set of tumors from young birds that were in the early stages of development, in contrast to the advanced tumors in the hens from the chemoprevention studies, which were 48 months of age at the conclusion of the studies. In addition, data from this flock has provided important insights regarding the impact of strain type and flock management on ultimate outcome of reproductive tract tumor incidence.

In the three sets of tumors, we now have 430 cancers obtained from the two groups of older hens, including 314 ovarian tumors, and 185 cancers obtained from the younger hens, including 122 ovarian tumors. Valuable data regarding the natural history, development, and tissue distribution of these tumors has been gathered as part of these studies. Data and tissues that we are gathering provide us with the remarkable opportunity of being able to critically evaluate the chicken ovarian cancer animal model and determine its relevance to human ovarian cancer research. The aim of the current proposal is to increase our understanding of the molecular and histologic features of chicken ovarian cancers. In addition, we will develop a histologic classification for chicken ovarian cancers, which is a critically important prerequisite to the widespread use of this animal model for ovarian cancer research. For this proposal, we plan to characterize and develop the chicken ovarian cancer model by (1) analyzing the molecular and genetic features of chicken ovarian cancers, including alterations in the p53 tumor suppressor gene and the Her-2/neu and Ras oncogenes, (2) classifying the morphologic and histologic features of chicken ovarian cancers, leading to the development of a histologic classification for chicken ovarian adenocarcinomas, and comparing the molecular and histologic features of ovarian cancers that develop in chickens receiving synthetic progestins compared to untreated controls. We hope to gather evidence that chicken ovarian cancers have genetic alterations and morphologic features similar to those identified in human ovarian carcinomas, thereby validating the chicken ovarian cancer model.

## **BODY:**

### **Aim 1: To determine whether the genetic alterations that characterize ovarian cancers in women are also a feature of ovarian cancers in the domestic fowl.**

We have performed genetic analysis for mutations in the p53 and ras genes in 102 chicken reproductive tract cancers that developed during the DOD-sponsored prevention trial described above. The histology was reviewed by a poultry pathologist (Dr. Barnes). PCR was used to amplify the targets from tumor cDNA. The entire p53-coding region was screened for alterations using single stranded conformational analysis and direct sequencing of variant bands. Codons 12 and 13 of H- and K-ras were evaluated for mutations by direct sequencing. Results were compared to wild type sequences using NCBI Accession X13057 (p53) and XO3578 (H-ras). K-ras primers for sequencing were designed from the known sequence for *M. gallopavo* (turkey) Acc. No. X85754.

Clearly deleterious p53 mutations were found in 14/102 (13.7%) of chicken ovarian cancers. Thirteen of these mutations (93%) predict truncated protein products.

There was one missense mutation (codon 368) that resulted in an amino acid substitution. All of the mutations were located between amino acids 101 and 336, which correspond to the DNA binding domains. An additional 14 chicken ovarian cancers had silent single nucleotide or intronic insertion polymorphisms. There was no relationship between the various treatment arms in the chemoprevention trial and the presence of p53 mutations. With regard to the ras gene, Chicken K-ras shared a 90% and 99% homology to the human and turkey K-ras respectively. H- and K-ras mutations were not seen in codons 12 and 13 of H-ras or K-ras. Silent single nucleotide polymorphisms were noted within codon 39 of K-ras (GaC) with a frequency of 36%, and in codon 12 of H-ras in one case. While the frequency of p53 mutation is less than that reported in human ovarian cancers, mutations in both species cluster in the critical DNA binding domains of the p53 gene. Additionally, despite being among the most common targets of mutations in various types of cancers, codons 12 and 13 of H-ras and K-ras are not mutated in chicken ovarian cancers, which is similar to human ovarian cancers that rarely exhibit ras mutations.

#### STUDIES UNDERWAY:

We have been optimizing our staining methods for Her-2/neu. We expect to complete staining and analysis of the chicken tumors for Her-2/neu expression shortly. In addition, through collaboration with Dr. Cliby (Mayo Clinic), we are examining frozen chicken tumor samples for a broad range of genomic alterations thought to be relevant in human ovarian cancers. Over the next 12 months, we expect to complete these studies, including data analysis and manuscript submission.

#### **Aim 2: To classify the morphologic and histologic features of chicken ovarian cancers, leading to the development of a histologic classification of chicken ovarian adenocarcinomas.**

Significant progress continues to be made in the histologic evaluation and classification of reproductive tract tumors accrued from the chemoprevention and strain-molt comparison studies. Reproductive tracts have been obtained from 2076 four-year-old laying hens at the termination of the two chemoprevention trials. Those from the first trial have been processed and evaluated while those from the most recent study will be done during the coming year. A number of cancers also have been collected for histopathologic evaluation from hens that died during the second chemoprevention study. Additionally, reproductive tracts have been obtained from 185 younger hens (28 mos) with gross lesions consistent with adenocarcinoma and 82 randomly selected normal hens (similar age). These samples have been processed and the histopathologic evaluations are in progress.

Gross lesions of most birds with tumors and other reproductive tract pathology have been photographed. Samples from reproductive tracts and other tissues of hens that were euthanized were collected, fixed for 72-hours in 10% buffered neutral formalin, and transferred to 70% alcohol. Additional samples of tumors and normal tissues from selected birds were snap frozen at the time of necropsy for genomic analysis. Slides have been prepared and stained with hematoxylin and eosin following conventional paraffin embedding and sectioning for initial characterization. To provide a 'gold standard' for the accuracy of gross tumor identification, tissues from all birds in two groups (n = 425) in the first study and approximately 10% of birds with normal appearing

reproductive tracts randomly selected from each of the remaining four groups have been examined for tumors. Immunostaining with cytokeratin (AE1/AE3) and ovalbumin (to detect oviductal glandular epithelial characteristics) was done previously on a small group of tumors.

Dr. John Barnes (DVM, Avian Pathologist) and Dr. Stanley Robboy (MD, Gynecologic Pathologist) are performing a meticulous examination of chicken reproductive tract cancers from the trials. Tumors that do not involve the reproductive tract are rare in hens with cancer; over 96% (413/430) had lesions in either the ovary and/or oviduct. Within the chicken reproductive tract, adenocarcinomas are most common in both the ovary and oviduct rather than either site alone. Among 413 reproductive cancers that have been identified to date, 67 (16.2%) were only in the ovary, 99 (24.0%) were only in the oviduct, and 247 (59.8%) were in both the ovary and oviduct. Overall, tumors of the oviduct occur slightly more frequently than tumors of the ovary (76.0% and 83.8% respectively). Hens with reproductive tract adenocarcinomas often have moderate to marked ascites and widespread to generalized coelomic implantation (carcinomatosis). When extensive, implantation and local invasion of the duodenum and pancreas causes fibrosis and distortion of tissues. Unless the tumor is advanced or there is concurrent peritonitis, the birds are generally in good condition. Some hens continue to ovulate from unaffected areas of the ovary and produce eggs.

Tumors in the ovary are firm to hard, multilobular, irregular, solid or pedunculated, and light tan to cream colored. They frequently have a cauliflower-like appearance. Some nodules may be umbilicated. Cysts containing clear, yellow, red, or green fluid are often present. Approximately 10% of ovarian tumors present as cystadenocarcinomas. Primary adenocarcinomas of the ovary are identified by the absence of tumors in the oviduct and/or degree of ovarian involvement. Cancers that are restricted to the cortical surface as small perifollicular, miliary nodules that comprise <25% of the ovarian tissue are considered to be secondary metastatic lesions to the ovary. Primary tumors involve both the cortex and medulla and comprise >25% of the ovary. Typical well-developed primary tumors involve >75% of the ovary. Primary tumors of the ovary often occur in conjunction with primary oviductal tumors suggesting a synchronous (multicentric) origin.

Adenocarcinoma of the oviduct typically occurs as thickened, firm areas with irregular lobular patterns in the oviduct wall. Occasionally nodules extend either extra- or intraluminally but, on microscopic examination, mural oviductal tumors do not breach the mucosal epithelium. Gross features permit differentiation between oviductal adenomas and adenocarcinomas. Adenomas have a smooth surface, are round to oval, generally <1 cm, and uniform color. Usually adenomas present as polyps, but sessile, broad-based lesions also can occur. In contrast, oviductal adenocarcinomas are irregular, generally >1 cm, have areas of different colors, and are sessile to intramural. They tend to be more firm than adenomas and rarely occurs as polyps.

Microscopically, adenocarcinomas in the ovary, oviduct, or both reproductive tissues are similar. The basic pattern is lobules or nodules composed of short tubules or spherules that are lined with a secretory, simple, cuboidal, or low columnar epithelium and usually contain eosinophilic proteinaceous fluid in their lumen. They have variable amounts of interstitial fibrovascular tissue and/or smooth muscle bundles, which accounts for their scirrhous nature grossly. Squamous differentiation, osseous metaplasia, and

cystic and/or papillary patterns occur infrequently. Often tumors can be observed grossly on the surface of ova, but microscopically they are in perifollicular spaces (possibly lymphatics) and do not penetrate the follicle wall. Mitosis is uncommon to rare except in more anaplastic areas where cells may be found in sheets rather than tubules.

The histology is variable and not distinct between ovarian and oviductal adenocarcinomas both among birds and at times within the same bird or even a single tumor. They can be divided into: 1) tubular, secretory, cytoplasmic granules present (well differentiated); 2) tubular, secretory, cytoplasmic granules not found (less differentiated); 3) tubular/follicular, secretory, squamous differentiation, 4) anaplastic. Except for poorly differentiated and anaplastic adenocarcinomas, it is generally possible to find at least a few cells that have cytoplasmic albuminous granules characteristic of those in the oviductal glands. Normal glandular epithelial cells have more abundant albumin granules than neoplastic cells. However, there does appear to be a correlation between reproductive status, albuminous granules in normal glandular epithelium, and similar granules in the cytoplasm of tumor cells suggesting that neoplastic cells are responding to the same hormonal signals as normal epithelium. The presence of albuminous granules in the cytoplasm of ovarian tumor cells should not be interpreted as having arisen first in the oviduct with spread to the ovary. A number of ovarian adenocarcinomas have been obtained in which careful gross and microscopic examination of the oviduct failed to reveal any evidence of neoplasia, but the characteristics of the tumor cells in the ovary are those of oviductal glandular epithelium. Our findings indicate these are true ovarian tumors composed of oviductal-like cells, much like the cells of adenocarcinomas of women can be composed of cells with characteristics of oviductal (serous), uterine (endometrioid), cervical (mucous), or bladder (transitional) epithelium. Similar to ovarian cancers in women, those in chickens also appear to undergo Müllerian duct differentiation. Dissimilarity in cell morphology between chicken and human ovarian tumors can be attributed to anatomical and functional differences. The mammalian reproductive tract provides an environment for fetal development whereas the avian reproductive tract is primarily secretory.

Cells that give rise to ovarian adenocarcinomas in chickens are currently unknown. There is a clear progression of histologic alterations in oviductal glandular epithelium from normal to neoplastic (focal or multifocal hyperplasia → dysplasia → adenoma [usually polypoid] → adenocarcinoma). Such a progression is not evident in oviductal adenocarcinomas. It is prudent to assume that the source of ovarian tumors in the chicken is also the specialized ovarian surface epithelium that is considered the source of ovarian carcinomas in women until proven otherwise. Tumor cells stain positive for cytokeratin, which indicates they are epithelial in origin, but cytokeratins that can differentiate various epithelia in birds have not been identified yet. Cells with cytoplasmic granules typical of those in the albumin-secreting mucosal glands of the oviduct magnum stain positively for ovalbumin. The granules show polychromatic staining with Masson's trichrome stain. Immature granules are deeply basophilic while mature granules are eosinophilic. How the tumors develop and grow on serosal surfaces can be determined by examining the staining character of the cytoplasmic granules.

In the next 12 months, we will continue the detailed histologic examination of the different tumors and examine selected ones by immunohistochemistry, especially for characteristics of oviductal glandular epithelium.

### **Key research accomplishments**

- Establishment of large bio-repository of frozen and formalin fixed chicken reproductive tract cancers from birds of varying ages, strains, reproductive history and chemopreventive drug exposure
- Genetic analysis of chicken ovarian cancers for p53 and ras, with additional genetic analysis underway.
- Basic techniques established for tissue processing and evaluation for histologic characterization
- Tumor collection consisting of 2 sets from 48-month-old chickens and one set from 28-month-old chickens that will form the basis for studies has been established
- Initial characterization of reproductive tract tumors identifying morphologic affinities between well-differentiated tumor cells and normal cells of oviduct glandular epithelium
- Relationship between albumin granules in normal oviductal glandular epithelium and tumor cells identified
- Progression of cellular changes present in development of oviductal but not ovarian cancers
- Trichrome staining characteristics of albumin granules found useful for determining tumor development
- Established the likely relationship between oviduct and ovarian cancers and proposed the theory of a multicentric origin of tumors
- Developed criteria for identifying different tumor types
- Validation of methods underway

This project continues to develop and will be completed in the next 12 months. . The results of these studies will be reported in the future.

### **Reportable outcomes**

- 1) Poster presentation at the The Society of Gynecologic Oncologists regarding the p53 and ras sequencing work in chicken tumors. 2003
- 2) Funding was applied for and granted by the NCI Prevention branch for a prevention trial in the chicken, evaluating the candidate preventives 4-HPR (a retinoids derivative) and levonorgestrel (a progestin). The trial is scheduled to complete 8/03; the primary outcome measure will be the incidence of reproductive tract tumors. In addition, tumors collected during the trial will be analyzed for p53, Ras, and Her-2 neu, similar to what has been performed for the current grant funded by the DOD. The work funded by the NCI will thus provide additional chicken reproductive tract tumor specimens for molecular and analysis, and also allow us to examine whether tumors that arise in birds on different types of hormonal treatment have different molecular phenotypes.
- 3) We have received funding from the Department of Defense under the Duke Program Project Renewal (7/2001) for studies that will include an avian prevention trial in the chicken, evaluating the preventive efficacy of various progestin dosages and schedules, with or without the addition of Vitamin D, on the outcome measure of reproductive tract tumors in the chicken.

- 4) We have received a small grant from the Gynecologic Cancer Foundation for further genomic analysis of chicken tumors (collaboration with Dr. Cliby at Mayo Clinic)

### **Conclusions**

The availability of a valid ovarian cancer animal model, especially one in which epithelial cancers develop spontaneously at a high rate, would represent a critically important breakthrough for ovarian cancer prevention research. An animal which develops spontaneous ovarian cancer would be ideal for ovarian cancer prevention studies, and provide the means through which a large variety of preventive agents can be quickly evaluated, thereby expediting the development of promising chemopreventive agents that could subsequently be tested in human prevention trials. The demonstration that ovarian cancers in the fowl are similar to those seen in women would be a critical step towards establishing the validity of the chicken model for testing chemopreventive agents. Whereas chemoprevention trials for ovarian cancer in women are difficult because of the relatively low annual incidence of the disease, chickens have a high incidence over a relatively short life span. Demonstration of efficacy of an ovarian cancer chemopreventive strategy in chickens would provide a credible rationale and enthusiasm for testing a similar strategy in women.

Our preliminary experience with the chicken supports the feasibility of this animal model for ovarian cancer research. Similar to humans, we have demonstrated a strong association between ovulation and ovarian cancer incidence in chickens. This suggests a common pathogenesis for human and chicken ovarian cancers, related to ovulation-induced genetic damage to the ovarian epithelium. In addition, our first prevention trial has yielded preliminary evidence suggesting an ovarian cancer protective effect from our intervention with progestins, and a possible additive protective effect from Vitamin D, consistent with data supportive of these agents as ovarian cancer preventives in women. Finally, our early genetic analysis of chicken tumors reveals similarities to human ovarian cancers. Hopefully, our continued efforts in developing the chicken ovarian cancer model will help overcome a major obstacle in ovarian cancer prevention research, and provide a means for the rapid development of effective preventives for ovarian cancer.

### **References**

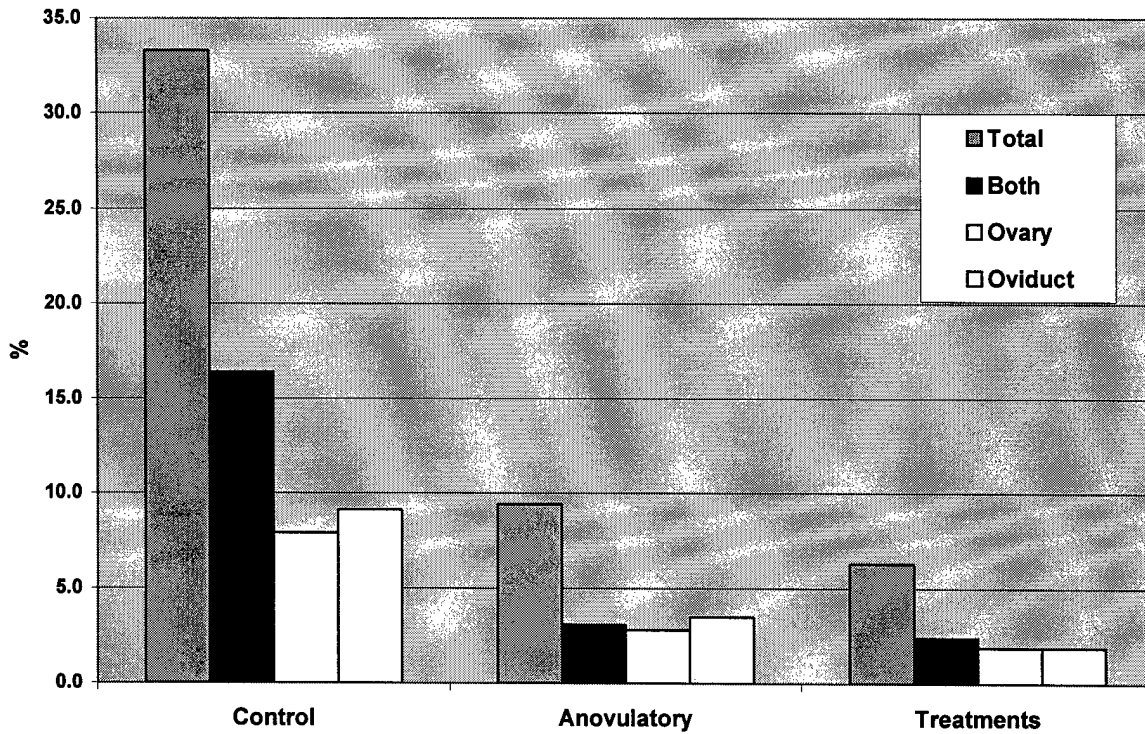
Barnes HJ, Rodriguez GC, Carver DK. Reproductive tract tumors in mature laying hens. Proc. 138<sup>th</sup> Ann Conv Am Assoc Vet Med, Boston, MA, July 14-18, 2001. (<http://www.cvm.ncsu.edu/info/departs/fae/PHM/RTTMLH/intro.html>)

Wenham R, Barnes HJ, Berchuck A, Robboy S, Carver D, Anderson K, Whitaker R, Petite J, Rodriguez GC. Molecular Characterization of Avian Ovarian Cancer. Society of Gynecologic Oncologists, March 2003

# APPENDIX COVER SHEET

Study 1. Results from first chemoprevention trial. Tumors for this work were obtained from these birds. Note that inducing anovulation decreased the occurrence of reproductive tract adenocarcinomas. Treatment of anovulatory birds with progestins and/or vitamin D resulted in a further reduction in the number of birds with cancer.

### Occurrence of Reproductive Tract Adenocarcinomas



Preliminary Classification Scheme for Avian Reproductive Tract Neoplasia  
(HJ Barnes & SJ Robboy,)

---

- A.1 Normal tissue, artifact, inflammation, or other non-neoplastic lesion – Report.
- A.2 Proliferative tissue characteristic of neoplasia – B
  - B.1 Mesenchymal cells – C
  - B.2 Epithelial cells, cytokeratin positive – D
  - B.3 Mesenchymal tissue with embedded neoplastic epithelium – E
  - B.4 Multiple tissue types without defined organization – **Teratoma**
  - B.5 Tubules containing Sertoli cells and/or seminiferous cells –  
**Sex cord tumors (Sertoli, Seminiferous, Mixed types)**
  - B.6 Follicular pattern, individual and small groups of large cells, fine stroma –  
**Granulosa cell tumor**
    - Well differentiated, localized or multifocal in ovary – Benign
    - Poorly differentiated, multiple tissues affected – Malignant
- C.1 Well-differentiated smooth muscle cells – **Leiomyoma**
- C.2 Poorly differentiated, proliferating smooth muscle cells, mitotic figures, tissue invasion – **Leiomyosarcoma**
- C.3 Well-differentiated fibrocytes, collagen production – **Fibroma**
- C.5 Poorly differentiated, proliferating fibroblasts, tissue invasion, collagen production – **Fibrosarcoma**
- D.1 Well-differentiated, expanding, non-invasive – **Adenoma**
- D.2 Invasive, proliferating – **Adenocarcinoma**
  - Differentiation
    - Well-differentiated – mitosis very rare to absent, defined pattern
    - Intermediate – mitosis rare to occasional, architectural pleomorphism, minimal to moderate cellular dysplasia
    - Poorly differentiated – mitosis common, cellular pleomorphism, anaplasia
  - Architecture
    - Tubular
    - Cystic
    - Papillary
    - Combinations of above
    - Lobular
    - Solid
  - Oviductal – cytoplasmic granules, ovalbumin positive
  - Ovarian adenocarcinoma
    - Grade 1: cortical, expanding nodules, <25% (metastatic, secondary)
    - Grade 2: medullary/cortical, infiltrating lobules, >25<75% (probable primary)
    - Grade 3: medullary & cortical, >75% organ involved (primary)
    - Types
      - Albuminous (oviductal cell type)
      - Follicular
      - Squamous differentiation
  - Peritoneal – absence of oviductal tumor, absent or grade 1 ovarian tumor
  - Other primary site – liver, pancreas, other
  - Metastatic – serosal surfaces, liver, pancreas, lung, spleen, heart, kidney
- E.1 Predominantly well differentiated smooth muscle, fibrous tissue and collagen minimal, <25% of tumor composed of neoplastic epithelium embedded within the tumor matrix – **Leiomyocarcinoma**

**P53 Mutations found in 14/102 chicken ovarian cancers screened:**

Bird	Sequence Change
1	G368C
2	451del147
3	451del147
4	393del57
5	649del3
6	803del122/C942A
7	750del51
8	803del202
9	803del122
10	803del122
11	800del122C927A
12	795del107/C927A
13	803del122/C942A
14	1073del15