

REPORT DOCUMENTATION PAGE

Form Approved
OMB No. 0704-0188

Public reporting burden for this collection of information is estimated to average 1 hour per response, including the time for reviewing instructions, searching existing data sources, gathering and maintaining the data needed, and completing and reviewing the collection of information. Send comments regarding this burden estimate or any other aspect of this collection of information, including suggestions for reducing this burden, to Washington Headquarters Services, Directorate for Information Operations and Reports, 1215 Jefferson Davis Highway, Suite 1204, Arlington, VA 22202-4302, and to the Office of Management and Budget, Paperwork Reduction Project (0704-0188), Washington, DC 20503.

1. AGENCY USE ONLY (Leave blank)	2. REPORT DATE 3/26/04	3. REPORT TYPE AND DATES COVERED	
4. TITLE AND SUBTITLE Filovirus Pathogenesis in Nonhuman Primates		5. FUNDING NUMBERS	
6. AUTHOR(S) Thomas W. Geisbert, Peter B. Jahrling, Tom Larsen, Kelly J. Davis, and Lisa Hensley		8. PERFORMING ORGANIZATION REPORT NUMBER	
7. PERFORMING ORGANIZATION NAME(S) AND ADDRESS(ES) USAMRIID		10. SPONSORING / MONITORING AGENCY REPORT NUMBER	
9. SPONSORING / MONITORING AGENCY NAME(S) AND ADDRESS(ES)		11. SUPPLEMENTARY NOTES	
12a. DISTRIBUTION / AVAILABILITY STATEMENT UNLIMITED DISTRIBUTION		12b. DISTRIBUTION CODE	
DISTRIBUTION STATEMENT A Approved for Public Release Distribution Unlimited			
13. ABSTRACT (Maximum 200 words) Infections with ebola and marburg & Marburg viruses cause severe and fatal hemorrhagic disease in humans and nonhuman primates. While progress to define the mechanisms of filoviral pathogenesis has been made in the last decade, cultural mores, and a range of logistical problems, have hindered the systematic pathogenetic analysis of human filoviral infections. Nonhuman primate models of filoviral hemorrhagic fever (HF) have been developed, but with few exceptions, previous investigations examined animals naturally infected or killed when moribund, and shed little light on the pathogenesis of infection during the period before death. More recently, longitudinal analysis of pathogenetic events in nonhuman primate models of Ebola virus (EBOV) HF have revealed new and important findings. Specifically, tissue factor plays an important role in triggering the hemorrhagic complications that characterize EBOV infections, and dysregulation of protein C exacerbates disease. Moreover, replication of EBOV in endothelial cells was not consistently observed until the latter stages of disease, well after the onset of disseminated intravascular coagulation, suggesting that the characteristic coagulation abnormalities are not the direct result of filoviral-induced cytolysis of endothelial cells. Bystander lymphocyte apoptosis, previously described in end-stage tissues, occurred early in the disease course in intravascular as well as extravascular locations. Of note, apoptosis and loss of NK cells was a prominent finding suggesting the importance of innate immunity in determining the fate of the host. Accordingly, nonhuman primate models have been invaluable in identifying several new targets for chemotherapeutic interventions that may ameliorate the effects of filoviral HF.			
14. SUBJECT TERMS Filovirus, Ebola virus, Marburg, pathogenesis, laboratory animals, nohuman primates		15. NUMBER OF PAGES 36	
17. SECURITY CLASSIFICATION OF REPORT		16. PRICE CODE	
18. SECURITY CLASSIFICATION OF THIS PAGE	19. SECURITY CLASSIFICATION OF ABSTRACT	20. LIMITATION OF ABSTRACT	

DISTRIBUTION STATEMENT A
Approved for Public Release
Distribution Unlimited

7

Filovirus Pathogenesis in Nonhuman Primates

Thomas W. Geisbert, Peter B. Jahrling,
Tom Larsen, Kelly J. Davis,
and Lisa E. Hensley

Abstract

20040401 060

Infections with Ebola and Marburg viruses cause severe and fatal hemorrhagic disease in humans and nonhuman primates. While progress to define the mechanisms of filoviral pathogenesis has been made in the last decade, cultural mores, and a range of logistical problems, have hindered the systematic pathogenetic analysis of human filoviral infections. Nonhuman primate models of filoviral hemorrhagic fever (HF) have been developed, but with few exceptions, previous investigations examined animals naturally infected or killed when moribund, and shed little light on the pathogenesis of infection during the period before death. More recently, longitudinal analysis of pathogenetic events in nonhuman primate models of Ebola virus (EBOV) HF have revealed new and important findings. Specifically, tissue factor plays an important role in triggering the hemorrhagic complications that characterize EBOV infections, and dysregulation of protein C exacerbates disease. Moreover, replication of EBOV in

endothelial cells was not consistently observed until the latter stages of disease, well after the onset of disseminated intravascular coagulation, suggesting that the characteristic coagulation abnormalities are not the direct result of filoviral-induced cytolysis of endothelial cells. Bystander lymphocyte apoptosis, previously described in end-stage tissues, occurred early in the disease course in intravascular as well as extravascular locations. Of note, apoptosis and loss of NK cells was a prominent finding suggesting the importance of innate immunity in determining the fate of the host. Accordingly, nonhuman primate models have been invaluable in identifying several new targets for chemotherapeutic interventions that may ameliorate the effects of filoviral HF.

1. Introduction

Among viruses causing hemorrhagic fever (HF), and among emerging infectious diseases with global impact in general, Ebola virus (EBOV) and Marburg virus (MBGV) stand out for their impressive lethality. Along with MBGV, the four species of EBOV (Zaire, Sudan, Reston, Ivory Coast) make up the negative-stranded, enveloped RNA virus family *Filoviridae*. Acute mortality caused by the Zaire species of EBOV is approximately 80% in human outbreaks (Bowen *et al.*, 1977; Johnson *et al.*, 1977; Khan *et al.*, 1999) and greater than 90% in monkey models of the genus *Macaca* (Bowen *et al.*, 1978; Fisher-Hoch *et al.*, 1992; Jaax *et al.*, 1996; Geisbert *et al.*, 2002). There is currently no vaccine or therapy for EBOV or MBGV HF approved for human use. Progress in understanding the origins of the pathophysiological changes that make filoviral infections of humans so devastating have been slow; a primary reason is the status of filoviruses as biosafety level 4 pathogens necessitating study in high-containment settings.

The use of animal models has been invaluable for studying the pathogenesis of numerous infectious diseases as well as for testing the efficacy of experimental prophylactic and therapeutic vaccine and/or drug regimens. Animal models that adequately reproduce human filoviral HF are needed to gain further insight into the pathogenesis of these diseases and to test the efficacy of promising interventions.

Guinea pigs, mice, and hamsters have been employed to study filoviral HF (Bechtelsheimer *et al.*, 1971; Zlotnik, 1971; Ryabchikova *et al.*, 1996; Bray *et al.*, 1998; Connolly *et al.*, 1999). While rodents clearly have utility as models of filoviral disease, we recently showed that rodent models of EBOV HF are not ideal for studying human EBOV HF (Geisbert *et al.*, 2002); others have suggested that guinea pigs are inadequate for analyzing the pathogenesis of human EBOV HF (Ryabchikova *et al.*, 1996). More specifically, neither mice nor guinea pigs exhibit the hemorrhagic manifestations that characterize primate EBOV infections. Also, bystander lymphocyte apoptosis, which is associated with human and nonhuman primate EBOV infections (Geisbert *et al.*, 2000), was not a prominent feature of EBOV infection in mice or guinea pigs (Bray *et al.*, 1998; Connolly *et al.*, 1999). As expected, clinical disease and related pathology in nonhuman primates infected with EBOV appear to more closely resemble features described in human EBOV HF.

The pathophysiology of human filoviral HF is largely unknown because of the limited number of cases being managed in a medical setting equipped for both safe and exhaustive clinical laboratory evaluations. Moreover, there has been a paucity of information regarding the pathology and pathogenesis of filoviral infection in humans. Despite over 1,500 known fatal cases of filoviral infection, only a very limited number of tissues from five cases of MBGV in 1967, one case of MBGV in 1975, two cases of EBOV-Sudan in 1976, three cases of EBOV-Zaire in 1976, single cases of MBGV in 1980 and 1987, and 18 of cases of EBOV-Zaire in 1996 have been examined (Gedigk *et al.*, 1968; Slenczka *et al.*, 1968; Gear *et al.*, 1975; Dietrich *et al.*, 1978; Ellis *et al.*, 1978; Murphy, 1978; Smith *et al.*, 1982; Geisbert and Jaax, 1998; Zaki and Goldsmith, 1999). Recent studies of EBOV-Zaire outbreaks in Kikwit and Gabon have provided valuable information on the inflammatory responses during filoviral infections (Baize *et al.*, 1999; Villinger *et al.*, 1999; Baize *et al.*, 2002) and many of the reported findings are consistent with those of experimentally infected nonhuman primates (Hensley *et al.*, 2002).

While disseminated intravascular coagulation (DIC) is often viewed to be a prominent manifestation of EBOV infection in primates, the

presence of DIC in human filoviral infections has been a controversial topic; cultural mores and logistical problems have hampered systematic studies. No single laboratory test is sufficient to permit a definitive diagnosis of DIC. In most instances, a diagnosis of DIC can be made by taking into consideration the underlying disease in conjunction with a combination of laboratory findings (Levi *et al.*, 1999; Mammen, 2000; Levi, 2001). In human filoviral cases, fibrin deposition has been documented at autopsy (Gedigk *et al.*, 1968; Murphy, 1978; Geisbert and Jaax, 1998); furthermore, clinical laboratory data suggest that DIC is likely to be a prominent feature of human disease (Egbring *et al.*, 1971; Gear *et al.*, 1975; Isaacson *et al.*, 1978; WHO, 1978a,b). The coagulation picture is clearer for nonhuman primates. Numerous studies showed histologic and biochemical evidence of DIC syndrome in EBOV infection in a variety of nonhuman primate species (Bowen *et al.*, 1978; Fisher-Hoch *et al.*, 1985; Fisher-Hoch *et al.*, 1992; Geisbert *et al.*, 1992; Jaax *et al.*, 1996; Ryabchikova *et al.*, 1999a; Bray *et al.*, 2001; Geisbert *et al.*, 2002).

Consumptive coagulopathy was described in several studies of EBOV-Zaire-infected nonhuman primates (Fisher-Hoch *et al.*, 1983; Fisher-Hoch *et al.*, 1985; Bray *et al.*, 2001), and is postulated to be a result of extensive virus-induced tissue injury, and the dysfunction or damage of platelets and endothelial cells. As noted in these and other studies, the increase in the activated partial thromboplastin time was more marked than that of the prothrombin time, consistent with a greater disturbance of the intrinsic than the extrinsic pathway (Fisher-Hoch *et al.*, 1983; Bray *et al.*, 2001). Traditionally, blood coagulation pathways are divided into extrinsic and intrinsic pathways, converging at the point where factor X is activated. The intrinsic pathway is initiated by activation of factor XII, while the extrinsic pathway is activated by tissue factor, a cellular lipoprotein exposed at sites of tissue injury (Semeraro and Colucci, 1997). Such a division, however, is only an artifact of *in vitro* testing; there are, in fact interconnections between the two pathways. For example, a tissue factor-factor VIIa complex also activates factor IX in the intrinsic pathway. Despite progress made during the last decade to identify key modulators of EBOV pathogenesis, there is no universal concept on the triggering mechanism of the hemorrhagic diathesis of EBOV infection.

2. Marburg Virus Infection

The first documented outbreak of hemorrhagic fever virus caused by a filovirus was associated with wild-caught African green monkeys (*Chlorocebus aethiops*, formerly *Cercopithecus aethiops*) that were imported from Uganda to Marburg and Frankfurt, Germany, and to Belgrade, Yugoslavia in 1967 (Hennesen *et al.*, 1968; Martini *et al.*, 1968; Martini *et al.*, 1971; Stojkovic *et al.*, 1971). During the course of the zoonotic outbreak, 31 animal staff and laboratory workers in direct contact with the blood or tissue from the recently imported monkeys became infected with the newly identified MBGV, and seven died. An unusually high mortality rate (21 to 46%) was observed in Belgrade among three groups of imported monkeys during the quarantine period (Stojkovic *et al.*, 1971), but infection rates among the cohort of 500 to 600 monkeys imported from Uganda to a variety of locations during this time remain unknown.

Experimental infection of African green monkeys, rhesus monkeys (*Macaca mulatta*), and squirrel monkeys (*Saimiri sciureus*), with isolates from the 1967 MBGV outbreak, produced a disease identical to that seen in the naturally infected monkeys and similar to the disease seen in human cases (Simpson *et al.*, 1968; Simpson, 1969; Haas and Maas, 1971; Oehlert, 1971; Murphy *et al.*, 1971; Lub *et al.*, 1995). After an incubation period that ranged from 2 to 6 days, animals developed a febrile illness, became anorexic, and some showed hemorrhagic manifestations. Rapid deterioration was followed by hypothermia, shock, and death, which occurred 6 to 13 days after infection; mortality was 100% in experimental animals. Petechial skin rashes on the axillae and groins, forehead, and chest were particularly prominent in the rhesus monkeys, but were not seen in African green monkeys (Simpson, 1969). The appearance of the skin rashes in the rhesus monkeys was consistent with the rashes described in several human cases (Martini *et al.*, 1968). Subsequent experimental infection in rhesus monkeys with a different isolate of MBGV produced similar disease, including the characteristic petechial rash (Johnson *et al.*, 1996).

Lymphopenia, thrombocytopenia, blood coagulation abnormalities, and increased serum aminotransferase activity have been described in animals experimentally infected with MBGV (Simpson *et al.*, 1968; Simpson, 1969; Gonchar *et al.*, 1991; Spiridonov *et al.*, 1992; Johnson *et al.*, 1996). Histopathologic observations included multifocal necrosis of liver parenchyma and depletion of lymphoid tissue (Simpson *et al.*, 1968; Zlotnik, 1969; Oehlert, 1971; Murphy *et al.*, 1971; Gonchar *et al.*, 1991) (Figure 1). Generalized swelling of Kupffer cells and hypertrophy of reticuloendothelial cells in lymphoid tissues were noted (Oehlert *et al.*, 1971; Murphy *et al.*, 1971). Perivascular hemorrhages in different regions of the brain were described in several studies (Zlotnik, 1969; Gonchar *et al.*, 1991). MBGV antigen-positive lesions described in pancreatic islets of a human case of MBGV (Geisbert and Jaax, 1998) have also been noted in rhesus and cynomolgus monkeys (Figure 1). More recently, bystander lymphocyte apoptosis was proposed to be the mechanism of lymphoid depletion in nonhuman primates experimentally infected with MBGV (Geisbert *et al.*, 2000) (Figure 1).

3. Ebola Virus Infection

Several nonhuman primate species have been employed to model EBOV-Zaire HF including African green monkeys (*Chlorocebus aethiops*) (Bowen *et al.*, 1978; Fisher-Hoch *et al.*, 1992; Davis *et al.*, 1997; Ryabchikova *et al.*, 1999a,b), cynomolgus macaques (*Macaca fascicularis*) (Fisher-Hoch *et al.*, 1992; Jahrling *et al.*, 1996a; Jahrling *et al.*, 1999; Sullivan *et al.*, 2000; Geisbert *et al.*, 2002), rhesus macaques (Bowen *et al.*, 1978; Fisher-Hoch *et al.*, 1985; Johnson *et al.*, 1995; P'yankov *et al.*, 1995; Jaax *et al.*, 1996; Geisbert *et al.*, 2002), and hamadryad baboons (*Papio hamadryas*) (Mikhailov *et al.*, 1994; Borisevich *et al.*, 1995; Chepurnov *et al.*, 1995a; Markin *et al.*, 1997; Kudoyarova-Zubavichene *et al.*, 1999; Ryabchikova *et al.*, 1999a,b). Similar pathologic features of EBOV-Zaire infection have been documented among these species; however, a few pathologic features differ. Most notably, African green monkeys do not present with the maculopapular rash that is characteristic of disease in macaques and baboons (Bowen *et al.*, 1978; Fisher-Hoch *et al.*, 1985,

Filovirus Pathogenesis in Nonhuman Primates

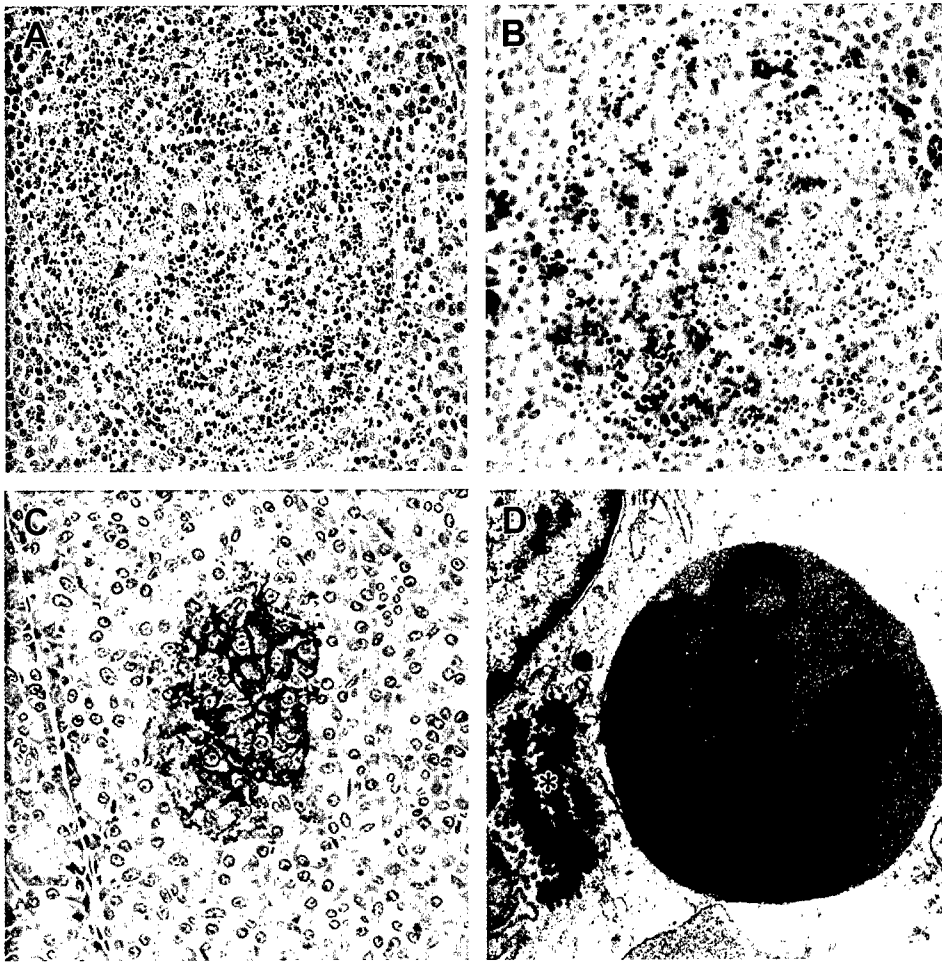
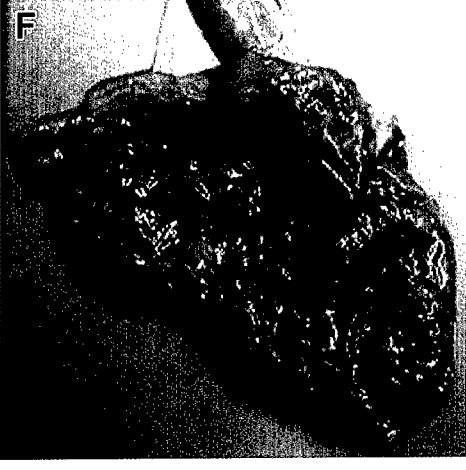
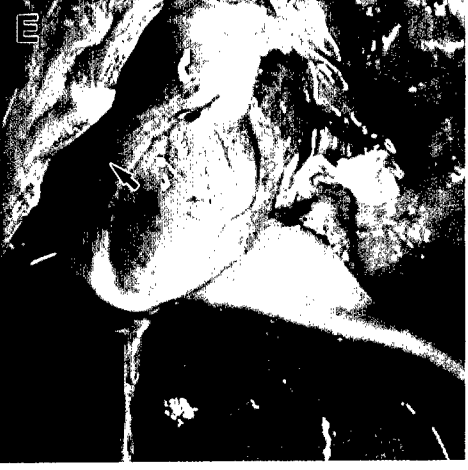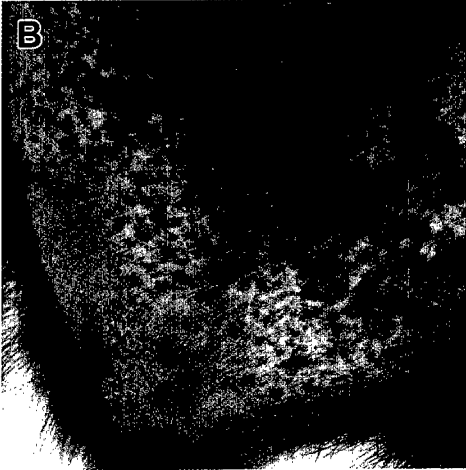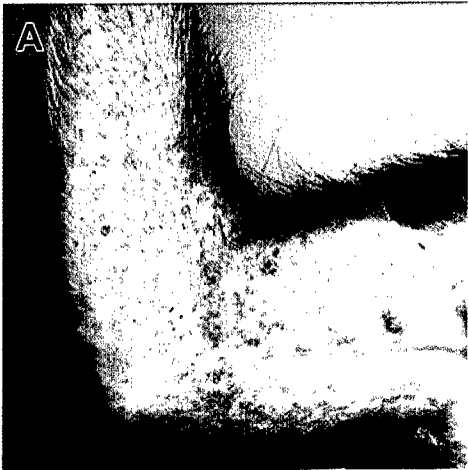


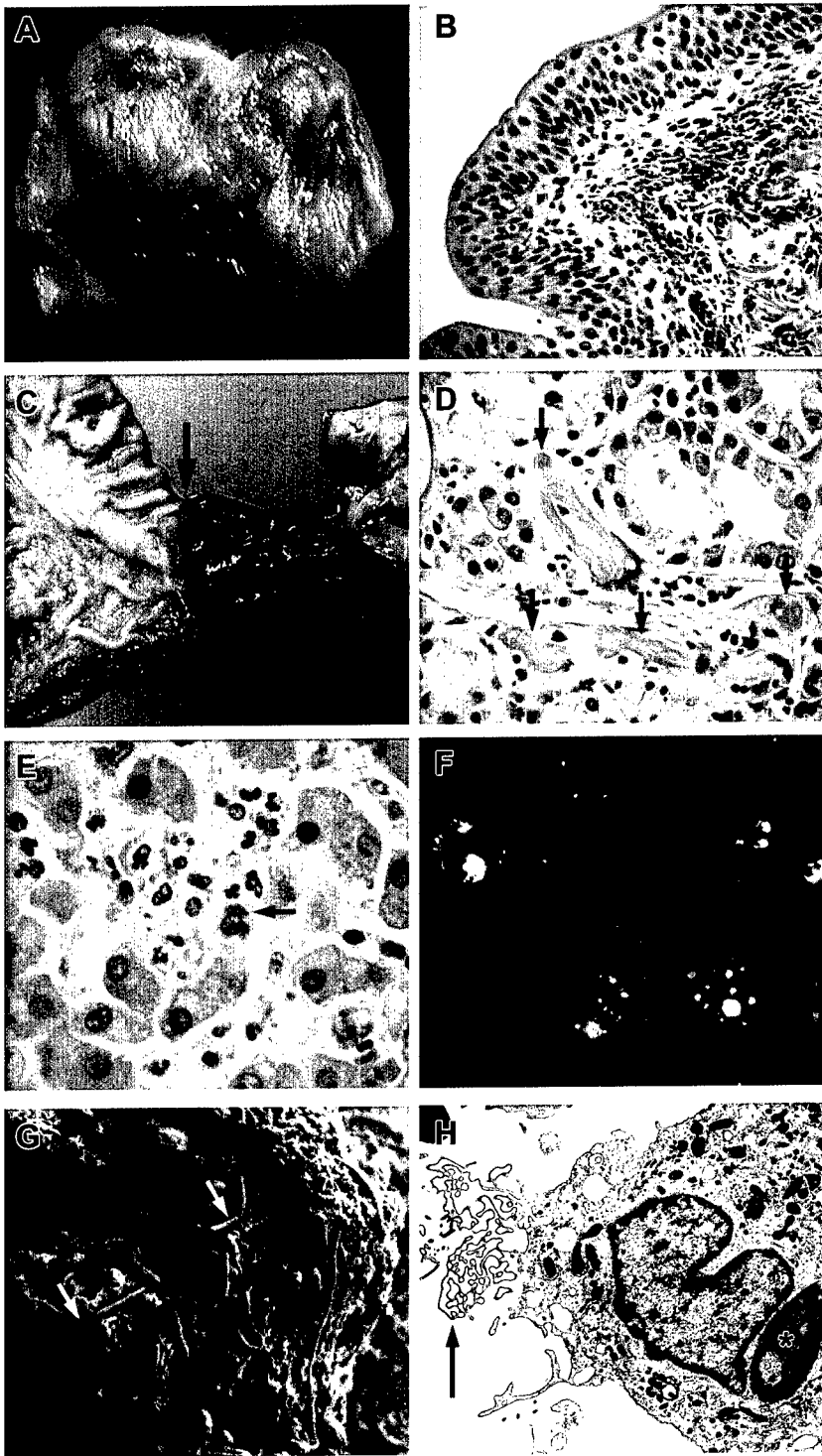
Figure 1. A. Submandibular lymph node; cynomolgus monkey. Note the severe follicular apoptosis induced by MBGV (Musoke). HE. Original magnification 100X. B. Follicle center, inguinal lymph node; MBGV (Musoke)-infected cynomolgus monkey. Single-strand breaks (blue/black) demonstrated by deoxyuridine triphosphate nick-end labeling (TUNEL) showing few tingible body macrophages and abundant free nuclear debris. Original magnification 40X. C. Islet of Langerhans, pancreas; cynomolgus monkey. Immunopositive staining of the islet for MBGV (Ravn). Immunoperoxidase method. Original magnification 100X. D. Inguinal lymph node; MBGV (Musoke)-infected cynomolgus monkey. Transmission electron micrograph showing typical MBGV inclusion (*) in cytoplasm of macrophage apposed to apoptotic bystander lymphocyte in subcapsular sinus. Photos A and C courtesy of Catherine Wilhelmsen.



Fisher-Hoch *et al.*, 1992; Mikhailov *et al.*, 1994; Johnson *et al.*, 1995; P'yankov *et al.*, 1995; Jaax *et al.*, 1996; Jahrling *et al.*, 1996a) (Figure 2); importantly, this rash is also a prominent feature of human disease (Bowen *et al.*, 1978; Davis *et al.*, 1997).

In addition to lymphopenia, thrombocytopenia, and increased serum aminotransferase activity, neutrophilia is prominent in EBOV-Zaire infections of nonhuman primates (Fisher-Hoch *et al.*, 1985; Jaax *et al.*, 1996; Rassadkin *et al.*, 2000). Lymphadenopathy of peripheral lymph nodes (Figure 2) appears relatively early in the disease course (by day 3 in macaques). An enlarged liver with rounded, friable, capsular borders and a reticulated pattern is typically seen at mid- to late-stages of disease in macaques (Figure 2); histologically there is multifocal hepatocellular degeneration and necrosis and hepatocytes frequently contain large (5 to 25 μ M), pleomorphic, acidophilic, intracytoplasmic viral inclusions (Figure 3). Other mid- to late-stage findings include reddening of the ileocecal valve caused by congestion in the gut-associated lymphoid tissue (GALT) (Figure 2), congestion of the proximal colon GALT, congestion of adrenal glands, urinary bladder petechiae (Figure 3), a sharply demarcated zone of congestion at the gastroduodenal junction (Figure 3), and bilateral testicular petechiae and ecchymoses. Lymphoid depletion and impairment of the microcirculation as evidenced by formation of fibrin thrombi in visceral organs is seen to various degrees. Species-specific differences in the appearance of coagulopathies have been reported: fibrin

Figure 2. A. Cynomolgus monkey; day 4. Characteristic petechial rash of the right arm resulting from EBOV-Zaire infection. B. Rhesus monkey; day 9. Severe petechial rash and ecchymosis of the right arm resulting from EBOV-Zaire infection. C. Inguinal region; cynomolgus monkey; day 5. Petechial rash resulting from EBOV-Zaire infection. D. Inguinal lymph nodes; cynomolgus monkey; day 4. The inguinal lymph nodes are mildly enlarged and markedly congested/hemorrhagic due to EBOV-Zaire infection. E. Liver and heart; EBOV-Zaire-infected cynomolgus monkey, day 6. Note the accentuated lobular pattern of the liver. The arrow depicts epicardial hemorrhages that are occasionally seen filovirus-infected monkeys; these hemorrhages are also infrequently observed as a postmortem change in uninfected animals. F. Ileocecal junction and cecum; EBOV-Zaire-infected cynomolgus monkey; day 5. The cecum is opened up and the ileum extends outward from the cecum. Note the congested and thickened appearance of the cecum.



deposition is seen in vessels of African green monkeys while hemorrhages are seen in baboons (Ryabchikova *et al.*, 1999a). We have not seen species-specific differences in coagulopathy among cynomolgus and rhesus macaques experimentally infected with EBOV-Zaire (T.W. Geisbert, unpublished).

Few studies have evaluated the pathogenesis of EBOV-Sudan in nonhuman primates (Ellis *et al.*, 1978; Bowen *et al.*, 1980; Fisher-Hoch *et al.*, 1992). The disease course in experimentally-infected rhesus and cynomolgus macaques appears much slower than that seen in EBOV-Zaire infections (Ellis *et al.*, 1978; Fisher-Hoch *et al.*, 1992) and rates of survival appear consistent with human disease. EBOV-Sudan infection was not lethal in a small cohort of African green monkeys nor was EBOV-Reston (Fisher-Hoch *et al.*, 1992). Similar to EBOV-Sudan, and unlike EBOV-Zaire, the disease course in EBOV-Reston-infected cynomolgus monkeys is protracted (Jahrling *et al.*,

Figure 3. A. Urinary bladder; EBOV-Zaire-infected cynomolgus monkey; day 5. The mucosa has multifocal to coalescing hemorrhages. B. Urinary bladder; EBOV-Zaire-infected cynomolgus monkey day 5. Note the hemorrhage within the submucosa. HE. Original magnification 20X. C. Stomach and duodenum; EBOV-Zaire-infected cynomolgus monkey; day 5. The arrow indicates the gastroduodenal junction demarcating the stomach to the left and the duodenum to the right. The duodenum is markedly congested. Note: this lesion is not pathognomonic for filoviral infections and is seen in other microbial diseases. D. Duodenum; EBOV-Zaire-infected cynomolgus monkey; day 6. The arrows demonstrate the marked fibrin thrombi present in the vessels near the Brunner's glands of the duodenum. HE. Original magnification 40X. E. Liver; EBOV-Zaire-infected cynomolgus monkey; day 5. Note the loss of normal hepatic architecture, necrosis, and neutrophils within the section. The arrow points to viral inclusions that are occasionally present within hepatocytes. HE. Original magnification 60X. F. Mesenteric lymph node; EBOV-Reston-infected cynomolgus monkey. Tingible body macrophages in section double-labeled for CD3 (as a pan T-cell marker) and apoptosis. Single-strand breaks are red/orange, CD3 appears green, and areas positive for both apoptosis and CD3 are stained gold. Original magnification 40X. G. Spleen; EBOV-Zaire-infected rhesus monkey, day 7. Scanning electron micrograph illustrates the large number of Ebola virions (arrowheads) produced by a single infected macrophage. Virions are uniformly 80 nm in diameter. H. Peripheral blood. EBOV-Zaire-infected cynomolgus monkey, day 6. Transmission electron micrograph of circulating monocyte/macrophage with characteristic EBOV inclusion material (*) in cytoplasm and area of virus-induced proliferated membrane (arrow).

1996b). As with MBGV, bystander lymphocyte apoptosis is proposed to be the mechanism of lymphoid depletion in nonhuman primates experimentally infected with EBOV-Reston as well as EBOV-Zaire (Geisbert *et al.*, 2000) (Figure 3). Little is known about the pathogenesis of EBOV-Ivory Coast in nonhuman primates, apart from its high lethality in chimpanzees (*Pan troglodytes verus*) (Formenty *et al.*, 1999; Wyers *et al.*, 1999). The single chimpanzee examined had multifocal necrosis in the liver, diffuse fibrinoid necrosis in splenic red pulp, and increased numbers of immunopositive macrophages (Wyers *et al.*, 1999).

4. Modeling of Filoviral HF in Nonhuman Primates

The selection of an appropriate challenge model requires careful consideration of primate species, sex, age, route of infection, dose administered, and the nature of the challenge virus itself. It is very difficult to compare results among the various published studies of filoviral HF in nonhuman primates because of differences among these factors. For example, some studies used organ homogenates to challenge naïve animals (Bowen *et al.*, 1978; Ellis *et al.*, 1978; Bowen *et al.*, 1980; Fisher-Hoch *et al.*, 1983; Fisher-Hoch *et al.*, 1985; Mikhailov *et al.*, 1994; P'yankov *et al.*, 1995; Ryabchikova *et al.*, 1999a,b), while other studies employed fluids collected from filovirus-infected cell cultures (Fisher-Hoch *et al.*, 1992; Johnson *et al.*, 1995; Jahrling *et al.*, 1996a,b; Jaax *et al.*, 1996; Davis *et al.*, 1997; Jahrling *et al.*, 1999; Sullivan *et al.*, 2000; Geisbert *et al.*, 2002). Some challenge viruses used were passed multiple times in animals and/or cell cultures while other challenge viruses are low passage and closer to the original isolate. To more fully characterize the isolates employed for our nonhuman primate studies, we recently certified that our viral stocks were not contaminated with endotoxins (Hensley *et al.*, 2002). Previously, filoviral isolates used in animal studies were not screened for endotoxins, a confounding variable if present at biologically relevant levels. We did detect elevated levels of endotoxins in several historical isolates, and in organ homogenates.

As noted above, species-specific differences have been shown in some studies of filoviral HF, the most consistent observation being the absence of a maculopapular rash in filovirus-infected African green monkeys. Clearly, there can be important genetic differences even among animals of the same species and consideration should be given to the origin of a particular species when comparing studies. In fact, major allelic differences were observed between rhesus macaques of Indian and Chinese origin (Viray *et al.*, 2001). Furthermore, specific MHC haplotypes shown to influence disease progression were reported in rhesus macaque models of AIDS (Sauermaun, 2001; Muhl *et al.*, 2002). The pathology associated with cynomolgus macaques reported in Russian studies of EBOV-Zaire HF (Ryabchikova *et al.*, 1999b) appears different from that reported in our cynomolgus macaque model (Geisbert *et al.*, 2002). Of course, varying isolates, doses, and routes of infection also may influence the results.

The wide range of challenge doses used in nonhuman primate studies has been a particularly controversial topic. The goal of any nonhuman primate model is to accurately reproduce human disease; however, little is known regarding what constitutes a typical dose and route of exposure in human filoviral infections. Most cases that propagate outbreaks are thought to occur by direct contact with infected patients and/or cadavers (WHO, 1978a,b; Dowell *et al.*, 1999; Khan *et al.*, 1999). Infectious filoviruses and/or RNA have been isolated from semen and genital secretions (Martini, 1971; Rodriguez *et al.*, 1999; Rowe *et al.*, 1999) and detected in skin (Zaki *et al.*, 1999) in human cases; and have also been experimentally demonstrated in body fluids and nasal secretions of nonhuman primates (Jahrling *et al.*, 1996b). Moreover, rhesus macaques were lethally infected with EBOV-Zaire by conjunctival exposure (Jaax *et al.*, 1996). Laboratory exposure through needlestick and filovirus-infected blood has been reported (Breman *et al.*, 1978); these exposures would likely entail doses of at least 1000 PFU if viremias associated with terminal patients are comparable to viremias in EBOV-Zaire-infected nonhuman primates, which often reach levels as high as 10^7 PFU/ml (Jahrling *et al.*, 1999). Human viremia data have been notoriously difficult to generate (Ksizaek *et al.*, 1999), yet the fact that circulating filovirions are readily detected by direct electron microscopic examination of postmortem

tissues (Dietrich *et al.*, 1978; Ellis *et al.*, 1978; Murphy 1978; Geisbert and Jaax, 1998; Zaki and Goldsmith, 1999) suggest comparable levels considering the threshold for ultrastructural detection. Butchering of a chimpanzee for consumption was linked to an outbreak of EBOV-Zaire in Gabon (Georges-Courbot *et al.*, 1997). Contact exposure was the likely route of transmission in this episode, but ingestion of filovirus-contaminated foods cannot be ruled out as a potential route of exposure in natural infections. Organ infectivity titers in filovirus-infected nonhuman primates are frequently in the 10^7 to 10^8 PFU/gram range (Jahrling *et al.*, 1999); thus, it is likely that exposure through the oral route would invariably be associated with very high infectious doses. In fact, EBOV-Zaire is highly lethal when orally administered to rhesus macaques (Jaax *et al.*, 1996).

The role of aerogenic transmission in outbreaks is unknown, but is thought to be uncommon (Peters and LeDuc, 1999). Aerosol transmission in nonhuman primates was implicated in the 1989-1990 epizootic of EBOV-Reston (Jahrling *et al.*, 1996); high concentrations of virus in nasal secretions and ultrastructural visualization of abundant viral particles in alveoli were reported (Jahrling *et al.*, 1996). Filoviruses are moderately stable in aerosol (Bazhutin *et al.*, 1992; Chepurinov *et al.*, 1995b), and intercage transmission, suggesting mediation by small-particle aerosols, was documented for EBOV-Zaire (Jaax *et al.*, 1995) and MBGV (Pokhodyaev *et al.*, 1991). Moreover, EBOV-Zaire is highly infectious by aerosol exposure in rhesus macaques (Johnson *et al.*, 1995; P'yankov *et al.*, 1995) as is MBGV in rhesus (Lub *et al.*, 1995) and African green monkeys (Bazhutin *et al.*, 1992).

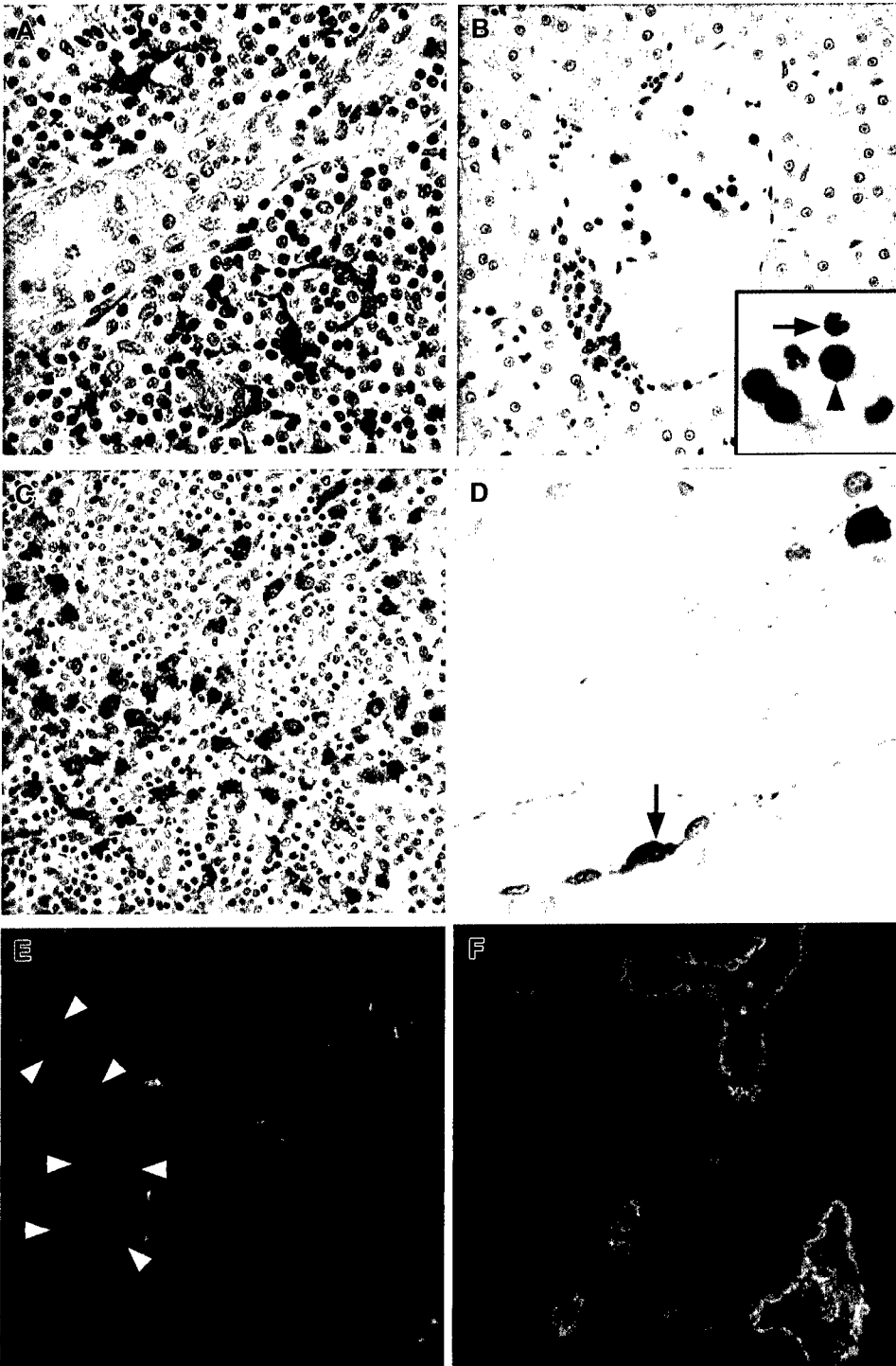
Consideration of challenge dose demands some explanation of infectious units, a subject of debate when comparing various studies. For mouse-adapted EBOV the murine median lethal dose (LD₅₀) was reported to be within the range of 0.025-.04 Vero PFU (*i.e.*, the dose of 1 Vero PFU was equivalent to ~ 30 mouse LD₅₀) (Bray *et al.*, 1998). Direct counting of virions mixed with a known concentration of microspheres revealed that 1 PFU was equivalent to 25-30 virions (Bray *et al.*, 1998). Therefore, 1 LD₅₀ equaled roughly 1 virion in this system. Titration of the 1995 isolate of EBOV-Zaire, used in nonhuman

primate studies, by electron microscopy gave a similar ratio of virions to PFU (Bray *et al.*, 1998). While a systematic titration has not been performed, the LD₅₀ of this isolate in cynomolgus monkeys is less than 10 Vero PFU (T.W. Geisbert, unpublished).

The dose of challenge virus clearly affects the disease course as has been suggested in data collected during outbreaks. In the 1976 EBOV-Zaire outbreak in Yambuku, the incubation period reported for person-to-person transmission exceeded the incubation period for injections or needlestick accidents (Breman *et al.*, 1978), which would presumably be associated with higher exposure levels. We observed similar dosing results in our nonhuman primate models. For example, exposure of cynomolgus monkeys (n = 15) to 1000 PFU of EBOV-Zaire by intramuscular injection produces a 100 percent lethal infection with deaths occurring 6-7 days postinfection (Geisbert *et al.*, 2002). When the challenge dose was lowered to 10 PFU (n = 4), uniform lethality was still achieved, but deaths occurred 9-12 days postinfection (T.W. Geisbert, unpublished). Others have also noted a protracted disease course concomitant with serial dilution of EBOV-Zaire (Rassadkin *et al.*, 2000), and of MBGV (Gonchar *et al.*, 1991). It is not surprising that developing viremia levels appear to be affected by challenge dose. Viremia has been reported as early as 24 hours after subcutaneous infection of rhesus macaques with a high infectious dose (10⁵ PFU) of EBOV-Zaire (Fisher-Hoch *et al.*, 1985). In rhesus and cynomolgus macaques infected with 1000 PFU of EBOV-Zaire, viremia is first detected 3 days after infection (Geisbert *et al.*, 2002), while viremia occurred 4-5 days after infection in baboons exposed to 20-50 newborn mouse LD₅₀ of EBOV-Zaire (Ryabchikova *et al.*, 1999a).

5. Recent Progress in Understanding Pathogenetic Mechanisms of Filoviruses

During the last decade, nonhuman primate models of filoviral HF have proved valuable in providing new information regarding filoviral pathogenesis. For example, the importance of monocytes/macrophages as primary cellular targets was shown in a number of studies (Geisbert



et al., 1992; Jaax *et al.*, 1996; Davis *et al.*, 1997; Ryabchikova *et al.*, 1999a) (Figure 3). However, with few exceptions, previous investigations examined monkeys killed when moribund and shed little light on the pathogenesis of EBOV infection during the period before death. The determinants of filoviral pathogenicity could be better understood if the early events of viral infection *in vivo* were known. To address these shortcomings, we recently performed longitudinal studies in EBOV-Zaire-infected cynomolgus and rhesus macaques to characterize the early stages of EBOV HF (Geisbert *et al.*, 2003). Understanding the kinetics of host-pathogen relationships and identifying critical pathogenetic processes aid the rational development of vaccines and antiviral therapeutics.

We focused much of our recent work on cynomolgus macaques, the species most frequently used for filoviral vaccine studies (Sullivan *et al.*, 2000, Geisbert *et al.*, 2002). Our cynomolgus monkey model uses a challenge dose and route that reflects a likely laboratory exposure

Figure 4. A. Lymph node; EBOV-Zaire-infected cynomolgus monkey; day 4. Immunopositive (red) dendritiform cells surrounding a high endothelial venule; brown-pigmented cells are hemosiderin-laden macrophages. Alkaline phosphatase method. Original magnification 40X. B. Liver; EBOV-Zaire-infected cynomolgus monkey; day 3. The cells with black reaction product are apoptotic mononuclear cells within the lumen of a central vein and to the periphery of the vein. Inset: The arrow points to an unaffected neutrophil and the arrowhead demonstrates the apoptotic lymphocyte. TUNEL method. Original magnification 20X. C. Lymph node; EBOV-Zaire-infected cynomolgus monkey; day 3. Immunopositive mononuclear cells (red) in the medullary sinus of the lymph node. The brown-pigmented cells are hemosiderin-laden macrophages. Alkaline phosphatase method. Original magnification 20X. D. Venule, brachial plexus; EBOV-Zaire-infected cynomolgus monkey; day 5. Rare immunopositive endothelial cell (arrow) and typical immunopositive monocyte (within the lumen). Alkaline phosphatase method. Original magnification 40X. E. Lymph node; EBOV-Zaire-infected cynomolgus monkey; day 5. Immunopositive mononuclear cells (red) and extracellular EBOV antigen in extravascular area. Note absence of EBOV-positive endothelial cells; vessel indicated by arrowheads. DAPI counterstain. Original magnification 40X. F. Lymph node; EBOV-Zaire-infected cynomolgus monkey; day 5. Section double-labeled for Von Willebrand's factor (green), as a marker for endothelial cells, and EBOV antigens (red). Note that endothelium appears intact and there is no evidence of EBOV-positive endothelial cells; EBOV antigens are localized to extravascular foci or fibrinocellular thrombi in vessels. Original magnification 40X.

and has been uniformly lethal with animals dying 6-7 days after exposure (Geisbert *et al.*, 2002). We also directed some recent efforts to rhesus macaques as they are widely used in other fields. Most notably, rhesus monkeys are almost exclusively used by pharmaceutical companies for generating pharmacokinetic data. Availability of these data facilitates testing of compounds with potential anti-filoviral activity. Rhesus macaques may have additional utility in immunological studies as they can be typed across at least 21 MHC class I alleles (Muhl *et al.*, 2002); eight of these can be determined via commercial testing (Wisconsin Regional Primate Center, Madison, WI).

Our most recent longitudinal studies demonstrate, for the first time, that dendritic cells are early and sustained cellular targets of EBOV in macaques (Figure 4); that lymphocyte apoptosis is a relatively early event in disease progression (Figure 4); and furthermore, it is the NK cell fraction that is likely lost by increased apoptosis early in the course of infection. We also observed early and sustained infection of monocytes and macrophages (Figure 4), with EBOV RNA initially detected at day 2 postinfection. As monocytes and macrophages are usually the cells that elicit the response cascade in the acute phase of inflammation (Baumann and Gauldie, 1994), their early infection represents an effective strategy for evasion of the host defense system as well as facilitating dissemination of the virus.

Whether infection of endothelial cells is central to the pathogenesis of EBOV hemorrhagic fever (HF) remains unknown. Several recent studies suggested that the EBOV glycoprotein is the main determinant of vascular cell injury and therefore it is direct infection of endothelial cells that causes the hemorrhagic diathesis (Yang *et al.*, 1998; Yang *et al.*, 2000). This hypothesis has not been rigorously tested *in vitro* or *in vivo*. Viral infections can exert changes in the vascular endothelium in a variety of ways, such as inducing endothelial cell activation indirectly by infecting and activating leukocytes and triggering the synthesis and local production of proinflammatory soluble factors or by directly inducing changes in endothelial cell expression of cytokines, chemokines, and cellular adhesion molecules in the absence of immune mediators (as a direct result of viral infection). Mediators

Filovirus Pathogenesis in Nonhuman Primates

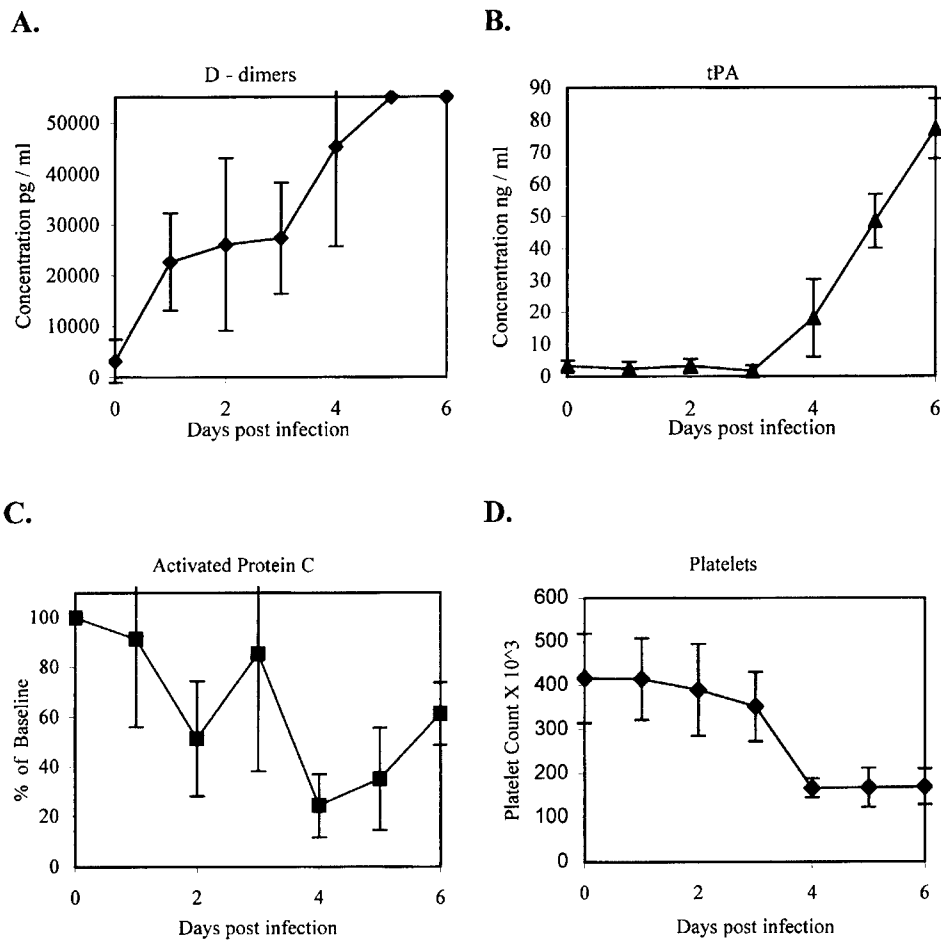


Figure 5. Development of coagulation abnormalities during EBOV infection of cynomolgus monkeys at days 1 through 6 postinfection. A. plasma levels of D-dimers measured by ELISA. B. plasma levels of tPA determined by ELISA. C. plasma levels of activated protein C measured by a chromatic hydrolysis assay. D. Platelet levels.

released from activated endothelial cells that can modulate vascular tone, thrombosis, and/or inflammation include nitric oxide, prostacyclin, interferons, interleukin 1 (IL-1), IL-6, and chemokines such as IL-8 (Mantovani *et al.*, 1992; Laroux *et al.*, 2000). Few studies have evaluated the host gene response of endothelial cells infected with EBOV; work is restricted to a single report of EBOV inhibiting induction of genes by double-stranded RNA (Harcourt *et al.*, 1998).

Previous studies showed EBOV infection of endothelial cells in postmortem tissues from humans and nonhuman primates (Baskerville *et al.*, 1985; Geisbert *et al.*, 1992; Jaax *et al.*, 1996; Davis *et al.*, 1997; Zaki and Goldsmith, 1999). In our most current study, endothelial cells did not appear to be a primary early target of EBOV (Geisbert *et al.*, submitted). Replication of EBOV in endothelial cells was not consistently observed until day 5 postinfection (Figure 4) and, in fact, was an infrequent observation in most tissues at this late stage of disease. Of note, detection of EBOV in endothelial cells occurred a full day after the onset of indicators consistent with DIC, *e.g.*, elevated levels of D-dimers (Figure 5). Electron microscopy confirmed that endothelium remained relatively intact even during terminal stages of disease.

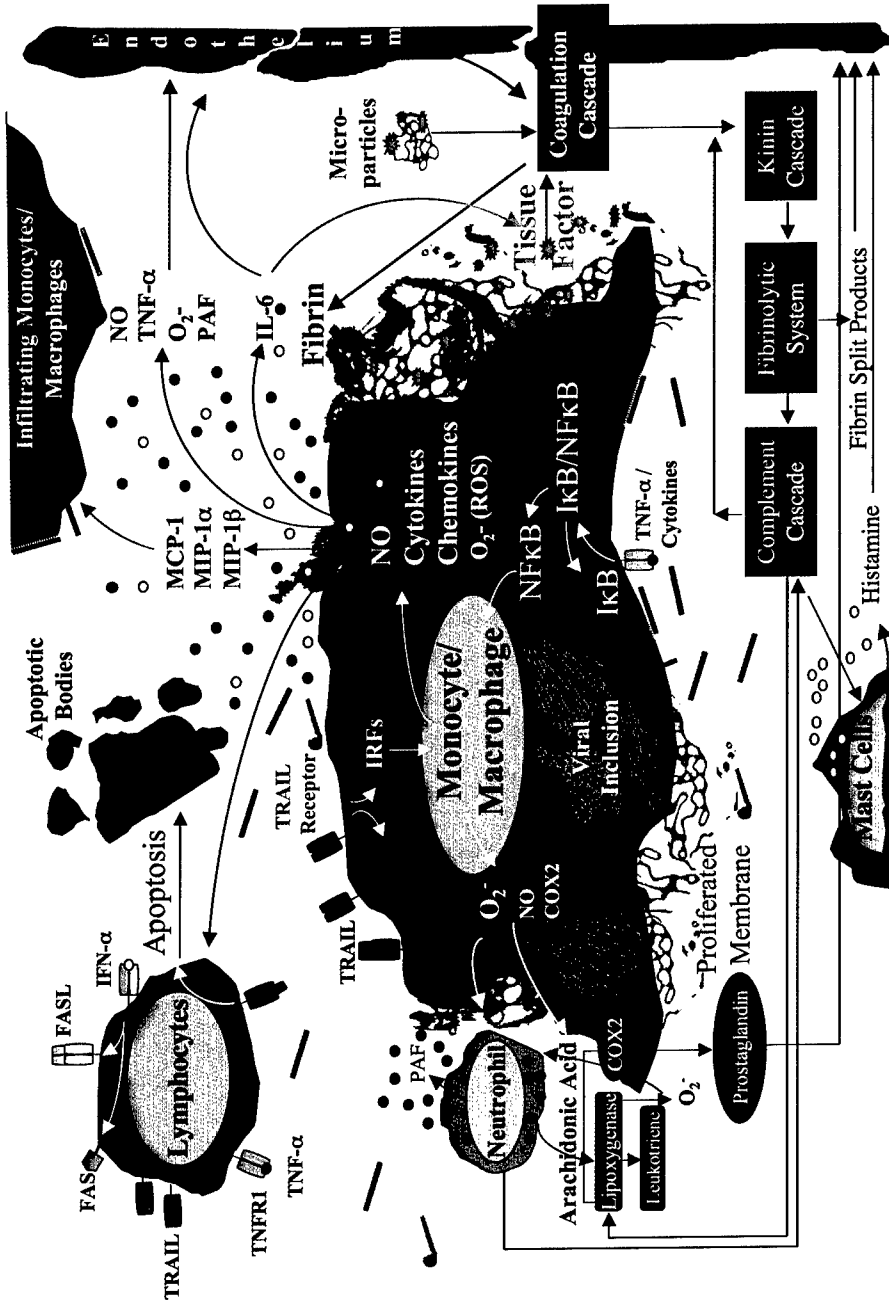
Development of DIC is a characteristic clinical manifestation of EBOV infection in primates, however the mechanism(s) for triggering the coagulation abnormalities remains unknown. Recent studies in our laboratory provided the first insight into the pathogenesis of coagulation system dysregulation, and suggest that development of coagulation abnormalities may occur much earlier than previously thought. Although it is likely that the coagulopathy seen in filoviral HF is caused by multiple factors, particularly during the latter stages of disease, these new findings strongly implicate tissue factor (TF) expression/release from EBOV-infected monocytes/macrophages, and dysregulation of the protein C system, as key factors that induce the development of coagulation irregularities seen in EBOV infections (Geisbert *et al.*, 2003). Moreover, plasma from EBOV-infected monkeys at early- to mid-stages of disease contained increased numbers of TF-expressing membrane microparticles (Geisbert *et al.*, 2003). The procoagulant potential of membrane microparticles is supported by data from clinical studies showing elevated levels of circulating membrane microparticles in patients with an increased risk for thromboembolic events (*e.g.*, DIC) (Nieuwland *et al.*, 2000; Sabatier *et al.*, 2002).

Levels of TF expression may also be affected by the production of various cytokines and chemokines. Proinflammatory cytokines such as IL-6 effectively upregulate TF expression on monocytes (Neumann

et al., 1997; Grignani and Maiolo, 2000). Elevated levels of IL-6 have been reported by day 4 postinfection in EBOV-infected monkeys (Hensley *et al.*, 2002). Splenocyte stimulation with TF also induces the selective release of the monocyte chemoattractant molecule MIP-1 α *in vitro* (Bokarewa *et al.*, 2002). Increased levels of MIP-1 α were previously reported in EBOV-infected monkeys and cultures of infected monocytes/macrophages (Hensley *et al.*, 2002). Taken together, these findings suggest that TF expression can be amplified during the later stages of diseases when EBOV-infected cells, which selectively express TF, release chemokines. Chemokine release may either directly upregulate levels of TF or attract additional preferred target cells to foci of infection, thereby exacerbating activation of the extrinsic coagulation pathway. TF expression may also be amplified in the latter stages of disease as a result of tissue damage caused by the formation of microthrombi. Specifically, development of these microthrombi during disease, as a result of TF overexpression, can produce tissue damage, as evidenced by the strong increase in plasma levels of tissue-type plasminogen activator noted in EBOV-infected monkeys (Geisbert *et al.*, 2003); these areas of tissue damage may then augment the effect by inducing local upregulation of TF.

6. Final Remarks

The results of recent work, and insight gained from historical studies, demonstrate that the nonhuman primate system is an extremely relevant model for studying filoviral pathogenesis. Despite the lack of inbred or pedigreed strains, and practical and ethical considerations that limit sizes of experiments, nonhuman primates remain the most useful and valid model of filoviral HF. Rodent models have been developed, and clearly have utility, but require serial adaptation of the virus to produce lethal disease (Bray *et al.*, 1998; Connolly *et al.*, 1999). Furthermore, because of differences in the disease pathology (Geisbert *et al.*, 2002) there are numerous scientific questions that cannot be satisfactorily addressed by an evaluation only in rodents. Nonhuman primates are phylogenetically closely related to humans and most genes, serum proteins, and other factors that require analysis, are biochemically and antigenically similar to those of humans. Several species of nonhuman



primates have been used to model filoviral HF, and which species most accurately reproduces human disease is debatable. Nonetheless, the cynomolgus and rhesus macaques appear to be excellent animal models for human filoviral HF.

Undoubtedly, the primary cellular targets for filoviruses in primates are cells of the mononuclear phagocyte system (Geisbert *et al.*, 1992; Feldmann *et al.*, 1996). Neither lymphocyte depletion nor lymphopenia is caused by filoviral infection of lymphocytes (Geisbert *et al.*, 1992; Geisbert *et al.*, 2000) and fibrin thrombi/hemorrhages associated with filoviruses do not appear to be the result of direct infection-induced cytolysis of endothelial cells (Geisbert *et al.*, 2003). In summary, the paradigm (Figure 6) that we propose for filoviral pathogenesis in nonhuman primates, based on results of the most recent EBOV-Zaire studies, is as follows: EBOV spreads from the initial infection site via monocytes/macrophages and dendritic cells to regional lymph nodes, likely via lymphatics, and to the liver and spleen via blood. At these sites, EBOV infects tissue macrophages (including Kupffer cells), dendritic cells and fibroblastic reticular cells. EBOV activates killer antigen-presenting cells (*e.g.*, dendritic cells) early in the course of infection by upregulating expression of tumor necrosis factor apoptosis-inducing ligand (TRAIL). Such overexpression of TRAIL, which is sustained over the course of disease by overexpression of IFN- α , participates in T lymphocyte deletion via bystander apoptosis, lymphopenia, and establishment of virus-induced immunosuppression. Concomitantly, EBOV-infected monocytes/macrophages release various soluble factors including proinflammatory cytokines such as MIP-1 α and MCP-1 that recruit additional macrophages to areas of infection making more target cells available for viral exploitation, and further amplifying an already dysregulated host response. As disease

Figure 6. Paradigm showing key cellular events in EBOV pathogenesis in nonhuman primates. EBOV infection of monocytes/macrophages appears to be central to much of the observed pathology. EBOV infection induces monocytes/macrophages to release a variety of soluble factors that likely trigger a host of downstream events including bystander apoptosis of lymphocytes, activation of the coagulation cascade, and disruption of the vascular endothelium. The end result is loss of homeostasis and dysregulation of the host immune response.

progresses, increased levels of oxygen free radicals (*e.g.*, nitric oxide), released by EBOV-infected macrophages at inflammatory sites, trigger apoptosis of bystander NK cells, thwarting the innate immune response and leaving the host little time to mount an adaptive response. Left unchecked, extensive viral replication leads to increased levels of additional proinflammatory cytokines, notably IL-6, which triggers the coagulation cascade likely through upregulation of tissue factor on monocytes/macrophages. Activation of the coagulation cascade, in turn, activates the fibrinogenic and fibrinolytic pathways leading to DIC. Inhibitors of the clotting system, particularly protein C, are consumed at a rate that exceeds synthesis by liver parenchymal cells, many of which by this point may have been rendered dysfunctional by the viral assault. Impairment of the coagulation system results in rapid progression of DIC, hemorrhagic shock, multiple organ failure, and finally death of the host.

This sequence of morphologic, cytologic, virologic, serologic, and inflammatory change following filoviral infection creates a useful model in the study of experimentally induced filoviral HF and the sequence of pathogenetic events identified should provide new targets for rational prophylactic and chemotherapeutic interventions. Because of massive synergism and redundancy in the pathways of inflammation associated with hemorrhagic shock, it is likely that combined or appropriate sequential targeting of the above-listed pathways will be more effective than targeting a single pathway.

Acknowledgements

The authors thank Denise Braun, Joan Geisbert, Lynda Miller, Roswita Moxley, Jeff Brubaker, Steve Moon, Neil Davis, and Larry Ostby for their expert technical assistance. The authors also express thanks to Lance Batey, Doug Reed, Catherine Wilhelmsen, and Howard Young for helpful discussions and comments. The views, opinions, and findings contained herein are those of the authors and should not be construed as an official Department of the Army position, policy, or decision unless so designated by other documentation. In conducting this research, the investigators adhered to the *Guide for the Care and*

Use of Laboratory Animals, prepared by the Institute of Laboratory Animal Resources, National Research Council (National Academy Press, Washington, D.C., 1996). The facilities are fully accredited by the Association for Assessment and Accreditation of Laboratory Animal Care International.

References

- Baize, S., Leroy, E.M., Georges-Courbot, M.-C., Capron, M., Lansoud-Soukate, J., Debre, P., Fisher-Hoch, S.P., McCormick, J.B., and Georges, A.J. 1999. Defective humoral responses and extensive intravascular apoptosis are associated with fatal outcome in Ebola virus-infected patients. *Nature Med.* 5: 423-426.
- Baize, S., Leroy, E.M., Georges, A.J., Georges-Courbot, M.-C., Capron, M., Bedjabaga, I., Lansoud-Soukate, J., and Mavoungou, E. 2002. Inflammatory responses in Ebola virus-infected patients. *Clin. Exp. Immunol.* 128: 163-168.
- Baskerville, A., Fisher-Hoch, S.P., Neild, G.H., and Dowsett, A.B. 1985. Ultrastructural pathology of experimental Ebola haemorrhagic fever virus infection. *J. Pathol.* 147: 199-209.
- Baumann, H., and Gauldie, J. 1994. The acute phase response. *Immunol. Today.* 15: 74-89.
- Bazhutin, N.B., Belanov, E.F., Spiridonov, V.A., Voitenko, A.V., Krivenchuk, N.A., Krotov, S.A., Omel'chenko, N.I., Tereshchenko, A.Iu., and Khomichev, V.V. 1992. The effect of the methods for producing an experimental Marburg virus infection on the characteristics of the course of the disease in green monkeys. *Vopr. Virusol.* 37: 153-156.
- Bechtelsheimer, H., Korb, G., and Gedigk, P. 1971. Marburg virus hepatitis. In: *Marburg Virus Disease*. G.A. Martini, R. Siebert, eds. Springer-Verlag, New York. p. 62-67.
- Bokarewa, M.I., Morissey, J.H. and Tarkowski, A. 2002. Tissue factor as a proinflammatory agent. *Arthritis Res.* 4: 190-195.

- Borisevich, I.V., Mikhailov, V.V., Krasnyanskii, V.P., Gradoboev, V.N., Lebedinskaya, Ye.V., Potryvaeva, N.V., and Timan'kova, G.D. 1995. Creation and study of immunoglobulin to Ebola fever. *Vopr. Virusol.* 40: 270-273.
- Bowen, E.T.W., Lloyd, G., Harris, W.J., Platt, G.S., Baskerville, A., and Vella, E.E. 1977. Viral haemorrhagic fever in southern Sudan and northern Zaire. *Lancet.* 1: 571-573.
- Bowen, E.T.W., Platt, G.S., Simpson, D.I.H., McArdell, L.B., and Raymond, R.T. 1978. Ebola haemorrhagic fever: experimental infection of monkeys. *Trans. R. Soc. Trop. Med. Hyg.* 72: 188-191.
- Bowen, E.T.W., Platt, G.S., Lloyd, G., Raymond, R.T., and Simpson, D.I.H. 1980. A comparative study of strains of Ebola virus isolated from southern Sudan and northern Zaire in 1976. *J. Med. Virol.* 6: 129-138.
- Bray, M., Davis, K., Geisbert, T., Schmaljohn, C., and Huggins, J. 1998. A mouse model for evaluation of prophylaxis and therapy of Ebola hemorrhagic fever. *J. Infect. Dis.* 178: 651-661.
- Bray, M., Hatfill, S., Hensley, L., and Huggins, J.W. 2001. Haematological, biochemical and coagulation changes in mice, guinea-pigs and monkeys infected with a mouse-adapted variant of Ebola Zaire virus. *J. Comp. Pathol.* 125: 243-253.
- Breman, J.G., Piot, P., Johnson, K.M., White, M.K., Mbuyi, M., Sureau, P., Heymann, D.L., van Nieuwenhove, S., McCormick, J.B., Ruppel, J.P., Kintoki, V., Isaacson, M., van der Groen, G., Webb, P.A., and Ngvete, K. 1978. The epidemiology of Ebola haemorrhagic fever in Zaire, 1976. In: *Ebola Virus Haemorrhagic Fever*. S.R. Pattyn, ed. Elsevier/North-Holland, Amsterdam. p. 103-124.
- Chepurnov, A.A., Chernukhin, I.V., Ternovoi, V.A., Kudoyarova, N.M., Makhova, N.M., Azaev, M.Sh., and Smolina, M.P. 1995a. Attempts to obtain a vaccine against Ebola fever. *Vopr. Virusol.* 40: 257-260.
- Chepurnov, A.A., Chuev, Y.P., P'yankov, O.V., and Efimova, I.V. 1995b. Effects of some physical and chemical factors of inactivation of Ebola virus. *Vopr. Virusol.* 40:74-76.

- Connolly, B.M., Steele, K.E., Davis, K.J., Geisbert, T.W., Kell, W.M., Jaax, N.K., and Jahrling, P.B. 1999. Pathogenesis of experimental Ebola virus infection in guinea pigs. *J. Infect. Dis. Suppl.* 179: S203-S217.
- Davis, K.J., Anderson, A.O., Geisbert, T.W., Steele, K.E., Geisbert, J.B., Vogel, P., Connolly, B.M., Huggins, J.W., Jahrling, P.B., and Jaax, N.K. 1997. Pathology of experimental Ebola virus infection in African green monkeys. *Arch. Pathol. Lab. Med.* 121: 805-819.
- Dietrich, M., Schumacher, H.H., Peters, D., and Knobloch, J. 1978. Human pathology of Ebola (Maridi) virus infection in the Sudan. In: *Ebola Virus Haemorrhagic Fever*. S.R. Pattyn, ed. Elsevier/North-Holland, Amsterdam. p. 37-42.
- Dowell, S.F., Mukunu, R., Ksiazek, T.G., Khan, A.S., Rollin, P.E., and Peters, C.J. 1999. Transmission of Ebola hemorrhagic fever: a study of risk factors in family members, Kikwit, Democratic Republic of the Congo, 1995. *J. Infect. Dis. Suppl.* 179: S87-S91.
- Egbring, R., Slenczka, W., and Baltzer, G. 1971. Clinical manifestations and mechanism of the haemorrhagic diathesis in Marburg virus disease. In: *Marburg Virus Disease*. G.A. Martini and R. Siebert, eds. Springer-Verlag, New York. p. 41-49.
- Ellis, D.S., Simpson, D.I.H., Francis D.P, Knobloch, J., Bowen, E.T., Lolik, P., and Deng, I.M. 1978. Ultrastructure of Ebola virus particles in human liver. *J. Clin. Pathol.* 31: 201-208.
- Feldmann, H., Bugany, H., Mahner, F., Klenk, H.-D., Drenckhahn, D., and Schnittler, H.-J. 1996. Filovirus-induced endothelial leakage triggered by infected monocytes/macrophages. *J. Virol.* 70: 2208-2214.
- Fisher-Hoch, S.P., Platt, G.S., Lloyd, G., Simpson, D.I., Neild, G.H., and Barrett, A.J. 1983. Haematological and biochemical monitoring of Ebola infection in rhesus monkeys: implications for patient management. *Lancet.* 2: 1055-1058.
- Fisher-Hoch, S.P., Platt, G.S., Neild, G.H., Southee, T., Baskerville, A., Raymond, R.T., Lloyd, G., and Simpson, D.I.H. 1985. Pathophysiology of shock and hemorrhage in a fulminating viral infection (Ebola). *J. Infect. Dis.* 152: 887-894.

- Fisher-Hoch, S.P., Brammer, L.T., Trappier, S.G., Hutwagner, L.C., Farrar, B.B., Ruo, S.L., Brown, B.G., Hermann, L.M., Perez-Oronoz, G.I., Goldsmith, C.S., Hanes, M.A., and McCormick, J.B. 1992. Pathogenic potential of filoviruses: role of geographic origin of primate host and virus strain. *J. Infect. Dis.* 166: 753-763.
- Formenty, P., Boesch, C., Wyers, M., Steiner, C., Donati, F., Dind, F., Walker, F., and Le Guenno, B. 1999. Ebola virus outbreak among wild chimpanzees living in a rain forest of Côte d'Ivoire. *J. Infect. Dis. Suppl.* 179: S120-S126.
- Gear, J.S.S., Cassel, G.A., Gear, A.J., Trappier, B., Clausen, L., Meyers, A.M., Kew, M.C., Bothwell, T.H., Sher, R., Miller, G.B., Schneider, J., Koornhof, H.J., Gomperts, E.D., Isaacson, M., and Gear, J.H. 1975. Outbreak of Marburg virus disease in Johannesburg. *Br. Med. J.* 4: 489-493.
- Gedigk, P., Bechtelsheimer, H. and Korb, G. 1968. Die pathologische anatomie der Marburg-virus-Krankheit. *Dtsch. Med. Wochenschr.* 93: 590-601.
- Geisbert, T.W., and Jaax, N.K. 1998. Marburg hemorrhagic fever: report of a case studied by immunohistochemistry and electron microscopy. *Ultrastruct. Pathol.* 22: 3-17.
- Geisbert, T.W., Jahrling, P.B., Hanes, M.A., and Zack, P.M. 1992. Association of Ebola related Reston virus particles and antigen with tissue lesions of monkeys imported to the United States. *J. Comp. Pathol.* 106: 137-152.
- Geisbert, T.W., Hensley, L.E., Gibb, T.R., Steele, K.E., Jaax, N.K., and Jahrling, P.B. 2000. Apoptosis induced *in vitro* and *in vivo* during infection by Ebola and Marburg viruses. *Lab. Invest.* 80: 171-186.
- Geisbert, T.W., Pushko, P., Anderson, K., Smith, J., Davis, K.J., and Jahrling, P.B. 2002. Evaluation in nonhuman primates of vaccines against Ebola virus. *Emerg. Infect. Dis.* 8: 503-507.
- Geisbert, T.W., Young, H.A., Jahrling, P.B., Davis, K.J., Kagan, E., and Hensley, L.E. 2003. Mechanisms underlying coagulation abnormalities in Ebola hemorrhagic fever: Overexpression of tissue factor in primate monocytes/macrophages is a key event. *J. Infect. Dis.* In press.

- Georges-Courbot, M.C., Sanchez, A., Lu, C.Y., Baize, S., Leroy, E., Lansout-Soukate, J., Tevi-Benissan, C., Georges, A.J., Trappier, S.G., Zaki, S.R., Swanepoel, R., Leman, P.A., Rollin, P.E., Peters, C.J., Nichol, S.T., and Ksiazek, T.G. 1997. Isolation and phylogenetic characterization of Ebola viruses causing different outbreaks in Gabon. *Emerg. Infect. Dis.* 3: 59-62.
- Gonchar, N.I., Pshenichnov, V.A., Pokhodaev, V.A., Lopatov, K.L., and Firsova, I.V. 1991. Sensitivity of different experimental animals to Marburg virus. *Vopr. Virusol.* 36:435-437.
- Grignani, G., and Maiolo, A. 2000. Cytokines and hemostasis. *Haematologica.* 85: 967-972 .
- Haas, R., and Maas, G. 1971. Experimental infection of monkeys with the Marburg virus. In: *Marburg Virus Disease.* G.A. Martini, R. Siebert, eds. Springer-Verlag, New York. p. 136-143.
- Harcourt, B.H., Sanchez, A., and Offerman, M.K. 1998. Ebola virus inhibits induction of genes by double-stranded RNA in endothelial cells. *Virology.* 252: 179-188.
- Hennesen, W., Bonin, O., and Mauler, R. 1968. Zur epidemiologie der erkrankung von menschen durch affen. *Dtsch. Med. Wochenschr.* 93: 582-589.
- Hensley, L.E., Young, H.A., Jahrling, P.B., and Geisbert, T.W. 2002. Proinflammatory response during Ebola virus infection of primate models: possible involvement of the tumor necrosis factor receptor superfamily. *Immunol. Lett.* 80: 169-179.
- Isaacson, M., Sureau, P., Courteille, G., and Pattyn, S.R. 1978. Clinical aspects of Ebola virus disease at the Ngaliema hospital, Kinshasa, Zaire, 1976. In: *Ebola Virus Haemorrhagic Fever.* S.R. Pattyn, ed. Elsevier/North-Holland Biomedical Press, New York. p. 15-20.
- Jaax, N.K., Davis, K.J, Geisbert, T.W., Vogel, P., Jaax, G.P., Topper, M., and Jahrling P.B. 1996. Lethal experimental infection of rhesus monkeys with Ebola-Zaire (Mayinga) virus by the oral and conjunctival route of exposure. *Arch. Pathol. Lab. Med.* 120: 140-155.

- Jaax, N., Jahrling, P., Geisbert, T., Geisbert, J., Steele, K., McKee, K., Nagley, D., Johnson, E., Jaax, G., and Peters, C. 1995. Transmission of Ebola virus (Zaire strain) to uninfected control monkeys in a biocontainment laboratory. *Lancet*. 346: 1669-1671.
- Jahrling, P.B., Geisbert, J., Swearingen, J.R., Jaax, G.P., Lewis, T., Huggins, J.W., Schmidt, J.J., LeDuc, J.W., and Peters, C.J. 1996a. Passive immunization of Ebola virus-infected cynomolgus monkeys with immunoglobulin from hyperimmune horses. *Arch. Virol. Suppl.* 11: 135-140.
- Jahrling, P.B., Geisbert, T.W., Jaax, N.K., Hanes, M.A., Ksiazek, T.G., and Peters, C.J. 1996b. Experimental infection of cynomolgus macaques with Ebola-Reston filoviruses from the 1989-1990 U.S. epizootic. *Arch. Virol. Suppl.* 11: 115-134.
- Jahrling, P.B., Geisbert, T.W., Geisbert, J.B., Swearingen, J.R., Bray, M., Jaax, N.K., Huggins, J.W., LeDuc, J.W., and Peters, C.J. 1999. Evaluation of immune globulin and recombinant Interferon- α 2b for treatment of experimental Ebola virus infections. *J. Infect. Dis. Suppl.* 179: S224-S234.
- Johnson, E., Jaax, N., White, J., and Jahrling, P. 1995. Lethal experimental infections of rhesus monkeys by aerosolized Ebola virus. *Int. J. Exp. Pathol.* 76: 227-236.
- Johnson, E.D., Johnson, B.K., Silverstein, D., Tukei, P., Geisbert, T.W., Sanchez, A.N., and Jahrling, P.B. 1996. Characterization of a new Marburg virus isolated from a 1987 fatal case in Kenya. *Arch. Virol. Suppl.* 11: 101-114.
- Johnson, K.M., Lange, J.V., Webb, P.A., and Murphy, F.A. 1977. Isolation and partial characterization of a new virus causing acute haemorrhagic fever in Zaire. *Lancet*. 1: 569-571.
- Khan, A.S., Tshioko, K., Heymann, D.L., Le Guenno, B., Nabreth, P., Kerstiens, B., Fleerackers, Y., Kilmarx, P.H., Rodier, G.R., Nkuku, O., Rollin, P.E., Sanchez, A., Zaki, S.R., Swanepoel, R., Tomori, O., Nichol, S.T., Peters, C.J., Muyembe-Tamfum, J.J., and Ksiazek, T.G. 1999. The reemergence of Ebola hemorrhagic fever, Democratic Republic of the Congo, 1995. *J. Infect. Dis. Suppl.* 179: S76-S86.

- Ksiazek, T.G., Rollin, P.E., Williams, A.J., Bressler, D.S., Martin, M.L., Swanepoel, R., Burt, F.J., Leman, P.A., Khan, A.S., Rowe, A.K., Mukunu, R., Sanchez, A., and Peters, C.J. 1999. Clinical virology of Ebola hemorrhagic fever (EHF): Virus, virus antigen, and IgG and IgM antibody findings among EHF patients in Kitwit, Democratic Republic of Congo, 1995. *J. Infect. Dis. Suppl.* 179: S177-S187.
- Kudoyarova-Zubavichene, N.M., Sergeyev, N.N., Chepurnov, A.A., and Netesov, S.V. 1999. Preparation and use of hyperimmune serum for prophylaxis and therapy of Ebola virus infections. *J. Infect. Dis. Suppl.* 179: S218-S223.
- Laroux, F.S., Lefer, D.J., Kawachi, S., Scalia, R., Cockrell, A.S., Gray, L., Van der Heyde, H., Hoffman, J.M., and Grisham, M.B. 2000. Role of nitric oxide in the regulation of acute and chronic inflammation. *Antioxid. Redox. Signal.* 2: 391-396.
- Levi, M. 2001. Pathogenesis and treatment of disseminated intravascular coagulation in the septic patient. *J. Crit. Care.* 16:167-177.
- Levi, M., de Jonge, E., van der Poll, T., and ten Cate, H. 1999. Disseminated intravascular coagulation. *Thromb. Haemost.* 82: 695-705.
- Lub, M.Yu., Sergeev, A.N., P'yankov, O.V., Petrishchenko, V.A., and Kotlyarov, L.A. 1995. Some pathogenetic characteristics of disease in monkeys aerogenically infected with Marburg virus. *Vopr. Virusol.* 40: 158-161.
- Mammen, E.F. 2000. Disseminated intravascular coagulation (DIC). *Clin. Lab. Sci.* 13: 239-245.
- Mantovani, A., Bussolino, F., and Dejana, E. 1992. Cytokine regulation of endothelial cell function. *FASEB J.* 6: 2591-2599.
- Markin, V.A., Mikhailov, V.V., Krasnyanskii, V.P., Borisevich, I.V., and Firsova, I.V. 1997. Development of emergency prophylaxis and treatment of Ebola fever. *Vopr. Virusol.* 42: 31-34.
- Martini, G.A. 1971. Marburg virus disease. Clinical syndrome. In: *Marburg Virus Disease*. G.A. Martini, R. Siebert, eds. Springer-Verlag, New York. p. 1-9.

- Martini, G.A., Knauff, H.G., Schmidt, H.A., Mayer G., and Baltzer, G. 1968. Über eine bisher unbekannte, von affen eingeschleppte infektionskrankheit: Marburg-virus-krankheit. *Dtsch. Med. Wochenschr.* 93: 559-571.
- Mikhailov, V.V., Borisevich, I.V., Chernikova, N.K., Potryvaeva, N.V., and Krasnyanskii, V.P. 1994. An evaluation of the possibility of Ebola fever specific prophylaxis in baboons (*Papio hamadryas*). *Vopr. Virusol.* 39: 82-84.
- Muhl, T., Krawczak, M., Ten Haaf, P., Hunsmann, G., and Sauermann, U. 2002. MHC class I alleles influence set-point viral load and survival time in simian immunodeficiency virus-infected rhesus monkeys. *J. Immunol.* 169: 3438-3446.
- Murphy, F.A. 1978. Pathology of Ebola virus infection. In: *Ebola Virus Haemorrhagic Fever*. S.R. Pattyn, ed. Elsevier/North-Holland Biomedical Press, New York. p. 43-60.
- Murphy, F.A., Simpson, D.I.H., Whitfield, S.G., Zlotnik, I., and Carter, G.B. 1971. Marburg virus infection in monkeys. *Ultrastructural studies. Lab. Invest.* 24: 279-291.
- Neumann, F.-J., Ott, I., Marx, N., Luther, T., Kenngott, S., Gawaz, M., Kotzsch, M., and Schomig, A. 1997. Effect of human recombinant interleukin-6 and interleukin-8 on monocyte procoagulant activity. *Arterioscler. Thromb. Vasc. Biol.* 17: 3399-3405.
- Nieuwland, R., Berckmans, R.J., McGregor, S., Boing, A.N., Romijn, F.P., Westendorp, R.G., Hack, C.E., and Sturk, A. 2000. Cellular origin and procoagulant properties of microparticles in meningococcal sepsis. *Blood.* 95: 930-935.
- Oehlert, W. 1971. The morphological picture in livers, spleens, and lymph nodes of monkeys and guinea pigs after infection with the "vervet agent." In: *Marburg Virus Disease*. G.A. Martini, R. Siebert, eds. Springer-Verlag, New York. p. 144-156.
- Peters, C.J., and LeDuc, J.W. 1999. An introduction to Ebola virus: the virus and the disease. *J. Infect. Dis. Suppl.* 179: ix-xvi.

- Pokhodyaev, V.A., Gonchar, N.I., and Pshenichnov, V.A. 1991. Experimental study of Marburg virus contact transmission. *Vopr. Virusol.* 36: 506-508.
- P'yankov, O.V., Sergeev, A.N., P'yankova, O.G., and Chepurnov, A.A. 1995. Experimental Ebola fever in macaca rhesus. *Vopr. Virusol.* 40: 113-115.
- Rassadkin, Y.N., Gradgdantseva, A.A., and Lutchko, S.V. 2000. Comparative sensitivity to the lowest monkeys species to Ebola virus. In: *Initiatives for Proliferation Prevention. International Science and Technology Center, Ministry of Science and Technologies of Russia, and North Atlantic Treaty Organization, eds. 2nd Session: Emerging and Reemerging Infectious Diseases – Basic Research. Advanced Research Workshop. Assessment of Sponsored Biological Research in Russia for the New Millenium, September 2-4, Novosibirsk, Novosibirsk Region, Russia.*
- Rodriguez, L.L., De Roo, A., Guimard, Y., Trappier, S.G., Sanchez, A., Bressler, D., Williams, A.J., Rowe, A.K., Bertolli, J., Khan, A.S., Ksiazek, T.G., Peters, C.J., and Nichol, S.T. 1999. Persistence and genetic stability of Ebola virus during the outbreak in Kikwit, Democratic Republic of the Congo, 1995. *J. Infect. Dis. Suppl.* 179: S170-S176.
- Rowe, A.K., Bertolli, J., Khan, A.S., Mukunu, R., Muyembe-Tamfum, J.J., Bressler, D., Williams, A.J., Peters, C.J., Rodriguez, L., Feldmann, H., Nichol, S.T., Rollin, P.E., and Ksiazek, T.G. 1999. Clinical, virologic, and immunologic follow-up of convalescent Ebola hemorrhagic fever patients and their household contacts, Kikwit, Democratic Republic of the Congo. *J. Infect. Dis. Suppl.* 179: S28-S35.
- Ryabchikova, E., Kolesnikova L., Smolina, M., Tkachev, V., Pereboeva, L., Grazhdantseva, A., and Rassadkin, Y. 1996. Ebola virus infection of guinea pigs: presumable role of granulomatous infection in pathogenesis. *Arch. Virol.* 141: 909-921.
- Ryabchikova, E.I., Kolesnikova, L.V., and Luchko. S.V. 1999a. An analysis of features of pathogenesis in two animal models of Ebola virus infection. *J. Infect. Dis. Suppl.* 179: S199-S202.

- Ryabchikova, E.I., Kolesnikova, L.V., and Netesov, S.V. 1999b. Animal pathology of filoviral infections. *Curr. Top. Microbiol. Immunol.* 235: 145-173.
- Sabatier, F., Roux, V., Anfosso, F., Camoin, L., Sampol, J., Dignat-George, F. 2002. Interaction of endothelial microparticles with monocytic cells *in vitro* induces tissue factor-dependent procoagulant activity. *Blood* 99: 3962-3970.
- Sauermann, U. 2001. Making the animal model for AIDS research more precise: the impact of major histocompatibility complex (MHC) genes on pathogenesis and disease progression in SIV-infected monkeys. *Curr. Mol. Med.* 1: 515-522.
- Semeraro, N., and Colucci, M. 1997. Tissue factor in health and disease. *Thromb. Haemost.* 78: 759-764.
- Simpson, D.I.H., Zlotnik, I., and Rutter, D.A. 1968. Vervet monkey disease. Experimental infection of guinea pigs and monkeys with the causative agents. *Br. J. Exp. Pathol.* 49:458-464.
- Simpson, D.I.H. 1969. Marburg agent disease: in monkeys. *Trans. R. Soc. Trop. Med. Hyg.* 63: 303-309.
- Slenczka, W., Shu, H.L., Piepenburg, G., and Siegert, R. 1968. Antigen-nachweis des Marburg-virus in den organen infizierter meerschweinchen durch immunofloreszenz. *Dtsch. Med. Wschr.* 93: 612-616.
- Smith, D.H., Johnson, B.K., Isaacson, M., Swanapoel, R., Johnson, K.M., Killey, M., Bagshawe, A., Siongok, T., and Keruga, W.K. 1982. Marburg virus disease in Kenya. *Lancet.* 1: 816-820.
- Spiridonov, V.A., Bazhutin, N.B., Belanov, E.F., Voitenko, A.V., Zolin, V.V., Krivenchuk, N.A., Omel'chenko, N.I., Polikanov, V.P., Tereshchenko, A.Iu., and Khomichev, V.V. 1992. Changes in the blood serum aminotransferase activity in the experimental infection of *Cercopithecus aethiops* monkeys with the Marburg virus. *Vopr. Virusol.* 37:156-157.
- Stojkovic, L.J., Bordjoski, M., Gligic, A., and Stefanovic, Z. 1971. Two cases of *Cercopithecus*-monkeys-associated haemorrhagic fever. In: *Marburg Virus Disease*. G.A. Martini, R. Siegert, eds. Springer-Verlag, New York. p. 24-33.

- Sullivan, N.J., Sanchez, A., Rollin, P.E., Yang, Z.-Y., and Nabel, G.J. 2000. Development of a preventative vaccine for Ebola virus infection in primates. *Nature*. 408: 605-609.
- Villinger, F., Rollin, P.E., Brar, S.S., Chikkala, N.F., Winter, J., Sundstrom, J.B., Zaki, S.R., Swanepoel, R., Ansari, A.A., and Peters, C.J. 1999. Markedly elevated levels of interferon (IFN)- α , IFN- γ , interleukin (IL)-2, IL-10, and tumor necrosis factor- α associated with fatal Ebola virus infection. *J. Infect. Dis. Suppl.* 179: S188-S191.
- Viray, J., Rolfs, B., and Smith, D.G. 2001. Comparison of the frequencies of major histocompatibility (MHC) class-II DQA1 and DQB1 alleles in Indian and Chinese rhesus macaques (*Macaca mulatta*). *Comp. Med.* 51: 555-561.
- WHO. 1978a. Ebola haemorrhagic fever in Sudan, 1976. Report of an international study team. *Bull. World Health Organ.* 56: 247-270.
- WHO. 1978b. Ebola haemorrhagic fever in Zaire, 1976. Report of an international commission. *Bull. World Health Organ.* 56: 271-293.
- Wyers, M., Formenty, P., Cherel, Y., Guigand, L., Fernandez, B., Boesch, C., and Le Guenno, B. 1999. Histopathological and immunohistochemical studies of lesions associated with Ebola virus in a naturally infected chimpanzee. *J. Infect. Dis. Suppl.* 179: S54-S59.
- Yang, Z., Delgado, R., Xu, L., Todd, R.F., Nabel, E.G., Sanchez, A., and Nabel, G.J. 1998. Distinct cellular interactions of secreted and transmembrane Ebola virus glycoproteins. *Science*. 279: 1034-1037.
- Yang, Z-Y., Duckers, H.J., Sullivan, N.J., Sanchez, A., Nabel, E.G., and Nabel, G.J. 2000. Identification of the Ebola virus glycoprotein as the main viral determinant of vascular cell cytotoxicity and injury. *Nature Med.* 6: 886-889.
- Zaki, S.R., and Goldsmith, C.S. 1999. Pathologic features of filovirus infections in humans. *Curr. Top. Microbiol. Immunol.* 235: 97-116.
- Zaki, S.R., Shieh, W.J., Greer, P.W., Goldsmith, C.S., Ferebee, T., Katshitshi, J., Tshioko, F.K., Bwaka, M.A., Swanepoel, R., Calain, P., Khan, A.S., Lloyd, E., Rollin, P.E., Ksiazek, T.G., and Peters, C.J. 1999. A novel immunohistochemical assay for the detection of

Geisbert *et al.*

Ebola virus in skin: implications for diagnosis, spread, and surveillance of Ebola hemorrhagic fever. *J. Infect. Dis. Suppl.* 179: S36-S47.

Zlotnik, I. 1969. Marburg agent disease: Pathology. *Trans. R. Soc. Trop. Med Hyg.* 63: 310-323.

Zlotnik, I. 1971. Marburg virus disease. The pathology of experimentally infected hamsters. In: *Marburg Virus Disease*. G.A. Martini, R. Siegert, eds. Springer-Verlag, New York. p. 129-135.