

AD _____

Award Number: DAMD17-00-1-0537

TITLE: Preclinical Evaluation of Gene Therapy for NF2 Lesions in
Mouse Models Using Amplicon Vectors and Prodrug
Activation

PRINCIPAL INVESTIGATOR: Xandra O. Breakefield, Ph.D.

CONTRACTING ORGANIZATION: The General Hospital Corporation
Boston, Massachusetts 02114

REPORT DATE: November 2003

TYPE OF REPORT: Final

PREPARED FOR: U.S. Army Medical Research and Materiel Command
Fort Detrick, Maryland 21702-5012

DISTRIBUTION STATEMENT: Approved for Public Release;
Distribution Unlimited

The views, opinions and/or findings contained in this report are those of the author(s) and should not be construed as an official Department of the Army position, policy or decision unless so designated by other documentation.

20040415 011

REPORT DOCUMENTATION PAGEForm Approved
OMB No. 074-0188

Public reporting burden for this collection of information is estimated to average 1 hour per response, including the time for reviewing instructions, searching existing data sources, gathering and maintaining the data needed, and completing and reviewing this collection of information. Send comments regarding this burden estimate or any other aspect of this collection of information, including suggestions for reducing this burden to Washington Headquarters Services, Directorate for Information Operations and Reports, 1215 Jefferson Davis Highway, Suite 1204, Arlington, VA 22202-4302, and to the Office of Management and Budget, Paperwork Reduction Project (0704-0188), Washington, DC 20503

1. AGENCY USE ONLY (Leave blank)		2. REPORT DATE November 2003	3. REPORT TYPE AND DATES COVERED Final (1 Oct 2000 - 1 Oct 2003)	
4. TITLE AND SUBTITLE Preclinical Evaluation of Gene Therapy for NF2 Lesions in Mouse Models Using Amplicon Vectors and Prodrug Activation			5. FUNDING NUMBERS DAMD17-00-1-0537	
6. AUTHOR(S) Xandra O. Breakefield, Ph.D.				
7. PERFORMING ORGANIZATION NAME(S) AND ADDRESS(ES) The General Hospital Corporation Boston, Massachusetts 02114 <i>E-Mail:</i> breakfield@hms.harvard.edu			8. PERFORMING ORGANIZATION REPORT NUMBER	
9. SPONSORING / MONITORING AGENCY NAME(S) AND ADDRESS(ES) U.S. Army Medical Research and Materiel Command Fort Detrick, Maryland 21702-5012			10. SPONSORING / MONITORING AGENCY REPORT NUMBER	
11. SUPPLEMENTARY NOTES Original contains color plates: All DTIC reproductions will be in black and white.				
12a. DISTRIBUTION / AVAILABILITY STATEMENT Approved for Public Release; Distribution Unlimited				12b. DISTRIBUTION CODE
13. ABSTRACT (Maximum 200 Words) These studies were designed to characterize tumors in mouse models of NF2 and to evaluate vector mediated therapy. Magnetic resonance, bioluminescence and near-infrared imaging were used in monitoring changes in tumor volume and in tracking gene delivery to there lesions over time in living animals. Several mouse models for NF2 were tested including: transgenic mice which express a dominant mutant form of the NF2 protein and develop spontaneous schwannomas; induction of schwannomas and brain tumors by injection of HSV amplicon vectors expressing Cre recombinase into mice homozygous for a floxed NF2 gene; and implantation of humanschwannoma or meningioma tissue into nude mice. Both schwannomas and meningiomas were shown to be highly infectable with therapeutic vectors derived from herpes simplex virus type-1. Injection of an oncolytic HSV vector G47A into schwannomas of transgenic mice led to a reproducible reduction in tumor volume. An HSV amplicon vector expressing the apoptotic protein, caspase-1, was also developed. These vectors can potentially be used to reduce volume of surgically inaccessible tumors in NF2 patients.				
14. SUBJECT TERMS Neurofibromatosis type 2 (NF2), schwanomma, meningioma			15. NUMBER OF PAGES 32	
			16. PRICE CODE	
17. SECURITY CLASSIFICATION OF REPORT Unclassified	18. SECURITY CLASSIFICATION OF THIS PAGE Unclassified	19. SECURITY CLASSIFICATION OF ABSTRACT Unclassified	20. LIMITATION OF ABSTRACT Unlimited	

Table of Contents

Cover.....	1
SF 298.....	2
Table of Contents.....	3
Introduction.....	4
Body.....	5
Key Research Accomplishments.....	10
Reportable Outcomes.....	11
Conclusions.....	12
References.....	13
Appendices.....	15

INTRODUCTION:

Neurofibromatosis type 2 (NF2) is an inherited condition in which patients have a tendency to develop multiple schwannomas and meningiomas (Eldridge, 1981). Although usually benign, these tumors can compress nerves and tissues leading to hearing loss, pain and obstruction of flow of cerebral spinal fluid. In many cases neurosurgical removal of tumors is not feasible without extensive damage of surrounding normal tissue. These preclinical studies were designed to evaluate the effectiveness of gene therapy for experimental tumors similar to those found in NF2 patients using HSV-1 replicational-conditional and amplicon vectors in mouse models of NF2 tumors. An oncolytic HSV-1 recombinant virus vector, G47 Δ , was used which replicates selectively in and thereby kills tumor cells, and an HSV-1 amplicon vector was generated to express an apoptotic protein, caspase-1, which kills infected cells. Mouse models included a transgenic mouse expressing a dominant mutant form of merlin, a floxed mouse in which the NF2 gene can be inactivated by Cre recombinase, and subcutaneous implantation of human meningiomas and schwannomas in nude mice. Studies monitored the growth and regression of schwannomas and meningiomas in living animals over time with periodic histochemical monitoring of gene delivery efficiency and pathology. Methods for monitoring gene delivery and tumor volumes in living animals included MRI, bioluminescence and near-infrared fluorescence (NIRF) imaging, including development of a novel NIRF probe to allow assessment of gene delivery and tumor apoptosis *in vivo*.

BODY:

Aim I. Evaluate transgene delivery and expression in schwannomas and meningiomas in mice using both HSV amplicon and replication competent vectors.

Task 1. Establish a breeding colony of NF2 transgenic mice.

We received a shipment of 14 transgenic founders (11 males and 3 females ages 13-20 months), from Dr. Marco Giovannini in France in year 1 of these studies. These transgenic mice [PO-Sch- Δ (39-121)] express a dominant mutant form of merlin in Schwann cells similar to a mutant protein found in some human NF2 patients. They typically demonstrate Schwann cell hyperplasias and/or schwannomas in 80% of transgenic mice by 24 months of age, especially in the spinal ganglia and around peripheral nerve endings in skeletal muscle (Messerli et al., 2002).

The transgenic founders went through a 6-week period of quarantine and pathogen testing and were then cleared for entry into the Massachusetts General Hospital (MGH) transgenic facility. Genotyping in the form of tail clipping and PCR analysis was performed on these mice to confirm that they have the mutated NF2 transgene (Fig. 1). A breeding colony was established by backcrossing these transgenic mice to wild-type FVBN mice and then backcrossing the F1 generations with each other. These mutant offspring were maintained for experiments for the remaining two years of the project. This provided an ongoing source of animals for MRI imaging of tumors as they arose and for evaluation of gene delivery and therapeutic efficacy of vectors.

Task 2. Set up meningioma tumor model.

a) Characterization of the merlin status of meningioma cell lines

In order to create a meningioma animal model, we screened 13 cell lines derived from human meningiomas of patients. These meningioma cell lines were tested first for the presence of merlin, the protein encoded by the NF2 tumor suppressor gene by western blotting in collaboration with Dr. Ramesh (Fig. 2). Of these cell lines, eight were positive for immunoreactive merlin, while five were negative by this assessment. For example, the slowly growing benign meningioma cell line, MN-52 did not express merlin, while the malignant meningioma cell line, F5, was merlin positive. Immunocytochemical studies confirmed that this F5 meningioma cell line expressed merlin using a monoclonal antibody to merlin developed in Dr. Ramesh's laboratory. In further studies, we showed that this cell line expressed two markers for meningioma cells: vimentin and the epithelial membrane antigen (EMA).

b) Meningioma cell lines are infectable with HSV amplicon vectors

We also tested whether human meningioma cell lines, both merlin-positive and merlin-negative, were infectable with HSV amplicon vectors, which contained an expression cassette for green fluorescent protein (GFP). Infectability of the meningioma cell lines with HSV amplicon vectors was assessed by Fluorescence Activated Cell Sorting (FACS) analysis, using a fluorescein filter, as a function of Multiplicity of Infection [M.O.I.; transducing units (tu) per cell] or by counting the number of GFP positive cells. The meningioma cell line, MN-52, was found to be highly infectable with HSV-1 virions, with over 50% infection at an M.O.I. of 3 tu per cell. Likewise, the malignant meningioma cell line F5 was also highly infectable, as indicated by the large number of green cells at M.O.I. = 0.5 to M.O.I. = 2, 48 hrs after infection (Fig. 3).

c) *In vivo* studies involving injection of meningioma cell lines into the ventricles of nude mice

We conducted *in vivo* studies to determine whether we could identify a human meningioma line, that could form tumors in mouse brain. Merlin-positive or merlin-negative meningioma cells (5×10^8 cells) were injected into the right brain ventricles of immunodeficient (nude) mice and tumor growth was monitored in these animals by MRI, animal health, and histopathology. Injection of the merlin-negative MN-52 into the ventricles did not result in tumor formation. However, injection of the merlin-positive meningioma cell line F5 generated tumors as assessed by MRI and histology. Histopathology demonstrated a malignant tumor in the right ventricles that invaded the

surrounding parenchyma by 4 weeks following injection of F5 cells into the ventricle (Fig. 4). This model was not deemed optimal for experimental therapeutic studies due to its invasive nature and consequent difficulties in volumetric analyses. To try to restrict growth in the brain to a particular location we also established tumors in a two-step procedure in collaboration with Drs. Samuel Rabkin and Robert Martuza (MGH). Human meningioma cells (line F5) were first implanted subcutaneously into the flanks of nude mice. After tumors were established (about 4 weeks after implantation), they were removed and a portion was implanted into the subdural space in the brains of a new cohort of nude mice. MRI imaging revealed the development of large subdural meningiomas in these mice, which compressed surrounding brain tissue, such as the lateral ventricles.

d) Generation of brain tumors in NF2 floxed mice

In the second year of the grant, we established a colony of NF2 floxed mice, in which exon 2 of the NF2 gene is flanked by lox P sites (Giovannini et al., 2000). This floxed NF2 allele is fully functional in parental mice, but if Cre recombinase is expressed in any cells of the animal, the floxed NF2 allele has a high probability of being inactivated by excision of exon 2. Giovannini et al. (2000) demonstrated that when these mice were crossed with transgenic mice expressing Cre under the PO promoter, which is active in Schwann cells, they form schwannomas at high frequency. Further, when an adenovirus vector expressing Cre was injected into the ventricles of these floxed mice soon after birth, they formed meningiomas (Kalamarides et al., 2002). Given the relative toxicity of adenovirus vectors, we have repeated this later experiment with an HSV-1 amplicon vector expressing Cre by injecting this vector subcutaneously or into the ventricles of NF2 floxed pups or adult mice. So far in 3 newborn pups injected with this vector and screened by MRI we have detected possible brain tumors in 2 of them at 3 months after injection (Table 1). To further characterize these tumors, immunocytochemistry is being conducted to determine if they are vimentin, EMA and/or S100 positive. In 4 adult mice injected with the HSV-1 Cre vector subcutaneously, one developed an intraocular malignant peripheral nerve sheath tumor (MPNST, Fig. 5) detected by MRI 8 months post-injection. This suggests that the vector can travel through the blood stream to Schwann cells throughout the body. Histology showed spindle cells arranged in interlacing whorls and short stacks characteristic of MPNSTs (Fig. 6). Mitotic figures indicated malignancy and the tumor stained positively for S100. This new floxed NF2 model will provide a complementary means of assessing therapeutic efficacy of these vectors and should provide a more abundant source of tumors in a known location for evaluation, thus facilitating assessment of therapeutic paradigms.

Task 3. Evaluate detectability and growth of tumors using MRI and correlative histochemical analysis.

a) Detection of schwannomas in NF2 transgenic mice by MRI

Note. All tables and figures referred to in this section in italics are from Messerli et al., 2002, appendix.

We have conducted MRI in collaboration with Dr. Yi Tang in Dr. Ralph Weissleder's group at MGH on a set of 14 NF2 transgenic mice between 9-18 mo of age (Messerli et al., 2002). Overall, approximately 77% (10/13) of these mice showed putative tumors by MRI. More specifically, 31% (4 of 13) of these mice showed tumors in the intercostal muscles and 15% (2 out of 13) had tumors in the limb muscles (Table 1). Figure 1 from this paper illustrates MRI images of a male mouse, which had tumors in the muscles of the right forelimb (Panels A-C) and in the intercostal muscles (D-F). Imaging sequences included conventional T1 and T2 weighted spin echo sequences with a 512 X 192 matrix, 8 cm field of view, and a 1.5 mm slice thickness, yielding a spatial resolution of 156 μ m X 312 μ m X 1500 μ m. Using a T1 weighted sequence (T1W1), the tumors displayed isointensity with other organs (Fig. 1 A, D). Under the T2W1 fat saturation (FS) sequence, the tumors were hyperintense (Fig. 1 B, E). After contrast administration (GDT1), the tumors demonstrated strong enhancement (Fig. 1 C, F). Since the images resulting from the T1 W1, T2FS, and GDT1 sequences showed a signal intensity characteristic of schwannomas and this transgenic strain of mice has a high incidence of schwannomas (Giovannini et al., 1999), these tumors were thought likely to be NF2 derived schwannomas. This was confirmed by histology (Fig. 2 A-C) and immunohistochemistry (Fig. 2 D-F). For histopathological analysis, H and E staining was performed on

paraffin embedded sections. The tumor was dispersed among the muscle fibers (*Fig. 2 A, B*) of the right forelimb. Schwann cell hyperplasias were also evident within the muscle fibers (*Fig. 2C*).

b) Correlation of MRI imaging and histopathology in NF2 transgenic mice

Those mice, which had tumors as diagnosed by MRI, were sacrificed for histopathological analysis. Necropsy was performed with the help of Dr. Roderick Bronson at Harvard Medical School. Tumor tissue was fixed in 10% formalin prior to being embedded in paraffin, sectioned, and stained with H and E. Immunohistochemistry, using a polyclonal antibody to S-100 (Dako Corporation, Carpinteria, CA), on tumor sections from the right forelimb of this mouse also supported the Schwann cell origin of these tumors (*Fig. 2*). Positive immunostaining was present in paraffin sections from the intramuscular tumor (*Fig. 2D*), but absent in sections from non-tumor tissue (*Fig. 2E*), and absent when incubated with secondary antibody alone (*Fig. 2F*). Histopathology revealed Schwann cell hyperplasias in the nerves innervating the limb muscle (*Fig. 2C*). This data indicates that this intramuscular tumor contained cells of Schwann cell lineage. Overall, histopathology demonstrated that schwannomas and Schwann cell hyperplasias were found in 75% (3 of 4) mice of both sexes examined.

Approximately 66% (2 out of 3 mice imaged by MRI) of the female mice had uterine tumors. *Figure 3* illustrates MRI images of a uterine tumor from one of these mice. Using a T₂W1 weighted image sequence (T1W1), the tumor displays isointensity with other organs (*Panel A*). Using the T₂W1 fat saturation sequence, the tumor has marked hyperintensity (*B-D*) and well-defined with a sharp margin. These imaging characteristics are similar to those observed following the detection of schwannomas in human patients (Abe et al., 2000; Hayasaka et al., 1999; Hayashi et al., 1996; Soderlund et al., 1994). Necropsy, a gross examination, and histology confirmed that uterine tumor in the female mouse was a schwannoma. *Figure 4* illustrates the gross anatomy of this uterine tumor, while *Figure 5* shows the histology confirming the MRI diagnosis. The H and E staining of uterine tumor sections reveals that the cells comprising the tumor have relatively abundant, faintly eosinophilic cytoplasm without discernible cell margins (*Fig. 5A*) and blunt-ended spindle nuclei (*Fig. 5B*), which are characteristic features of Schwann cells in schwannomas (Woodruff et al., 2003). Histology of other tissues removed from the animal confirmed that the large intestine had a colonic polyp with some dysplasia, and the gut had a small leiomyoma and a few tumors, which resembled schwannomas. The uterine tumor illustrated in *Figures 3-6* also stained positively for S-100. These data indicate that the tumors detected by MRI and histology in the NF2 transgenic mice PO-Sch- Δ (39-121) have Schwann cell origin, and are thus, schwannomas. These data are consistent with studies indicating that these NF2 dominant mutant transgenic mice have a high incidence of Schwann cell-derived uterine tumors (Giovannini et al., 1999) and demonstrate that such tumors are detectable in living animals by MRI. In one exception to this, MRI did not detect a tumor in one animal, which was revealed by histology and shown to be a schwannoma in the anterior horn of the spinal cord. In this case, the tumor cells invaded the white matter of the spinal cord and disrupted the normal symmetry of the spinal cord.

c) Further characterization of schwannomas in NF2 transgenic mice

Other immunohistochemical studies confirmed that the tumor sections from NF2 transgenic mice were positive for VSV-G, the antigenic marker incorporated into the mutated NF2 transgene under the control of the Schwann cell-specific PO promoter (*Fig. 7*). Histological staining for myelin indicated that the schwannomas did not have detectable amounts of this protein, consistent with previous evidence of disaggregation of myelin sheaths in vestibular human schwannomas (Sans et al., 1996).

Task 4. Evaluate marker gene delivery and expression in tumors mediated by HSV vectors.

Gene delivery and expression was evaluated using two types of HSV-1 virus vectors: amplicon vectors and recombinant virus vectors. Non-replicating amplicon vectors express genes only in initially infected cells and genes are lost over time if these cells divide. In contrast, recombinant virus vectors express genes in both initially infected and secondarily infected cells, with expression being lost as the virus replicates in thereby kills the infected cells and being extended as progeny virus infect surrounding cells progressively over time. In the first year of funding, both schwannoma cells from the transgenic mice and meningioma cells from human NF2 patients in culture were shown to be highly infectable with HSV vectors. In the second year we tested infectability of

schwannomas in transgenic mice *in vivo* and human meningioma cells in culture and *in vivo*. Schwannomas visualized by MRI were injected with HSV amplicon vector expressing the firefly luciferase gene (5×10^6 tu in 10 μ l). Forty-eight and 72 hrs later animals were injected intraperitoneally with the substrate, luciferin, and imaged using a CCD camera (Fig. 7). A robust signal was seen at 48 hrs, which decreased by 72 hrs post-infection, probably indicating loss of the transgene through cell division.

We have also investigated the infectability of schwannomas with the replication-conditional recombinant virus vector, G47 Δ . This vector is mutated in the genes for ICP6 and γ 34.5, which allows selective replication in dividing cells, while sparing non-dividing cells. Since most cells in the adult nervous system are non-dividing, this cytotoxicity is selective for tumor cells. In addition, the vector is deleted for the gene encoding ICP47, which enhances presentation of viral antigens via MHC Class I, and thus cells infected with this vector are susceptible to tumor infiltrating lymphocytes (Todo et al., 2001). G47 Δ also contains the reporter gene, lacZ, in place of the ICP6 gene to facilitate tracking of vector-infected cells. Several experiments indicate that the schwannomas are highly infectable with this HSV vector. Two months after infection of schwannomas with G47 Δ with consequent regression of tumors, the tumors was removed, fixed, sectioned, and analyzed by immunocytochemistry for β -galactosidase expression (Fig. 8). In order to determine if the infected cells with G47 Δ were schwannomas, we also immunostained sections of tumors, which were infected with G47 Δ with a polyclonal antibody to S-100. The staining pattern for S-100 was similar to that for β -galactosidase (Fig. 8A), suggesting that the schwannoma cells themselves are infectable with HSV-1 virions.

Aim II. Optimize conditions for reduction of tumor mass using vectors encoding prodrug activation enzymes combined with systemic prodrug administration.

Task 1. Generate therapeutic vectors and test vector stocks.

This work has taken three directions. First, based on the high infectability of schwannomas with HSV-1 oncolytic vectors (see Aim I, Task 4, Fig. 8), we decided to explore the direct therapeutic potential of these vectors. For this evaluation we used the recombinant virus vector G47 Δ . High titer stocks [10^{10} plaque forming units (pfu)/ml] of G47 Δ are available through our collaborators, Drs. Samuel Rabkin and Robert Martuza. This vector was injected directly into schwannomas with subsequent reduction in tumor mass, as assessed by MRI. This is shown in Figure 9 for one animal with bilateral, intramuscular schwannomas in which one flanking tumor was injected with 1×10^8 pfu of G47 Δ in each of two injections (30 μ l/injection), while the other tumor on the contralateral side was injected in parallel with a control HSV amplicon vector. MRI imaging was carried out 5, 13 and 21 days following injection of the vectors. The volumes of the tumors injected with therapeutic and control vectors were evaluated using NIH image J analysis. The tumor injected with G47 Δ decreased in size by over 75% in a three-week period following injection, while the tumor injected with the control vector doubled in size over this same period (Fig. 10). We are pursuing these findings in more animals to quantitate volumetric changes over time in untreated tumors, tumors treated with G47 Δ , and tumors treated with control vectors. In addition, we are examining other organs in the animals for vector biodistribution and possible toxicity due to the G47 Δ treatment.

In a second therapeutic paradigm we incorporated a cassette for HSV-1 thymidine kinase (TK) and bacterial cytosine deaminase (CD) into the retrovirus vector component of the HSV/EBV/RV (tribrid) hybrid amplicon vectors (Sena-Esteves et al., 1999; Mydlarz et al., 2002), these vector also bears the latent origin of DNA replication and EBNA1 gene from Epstein Barr Virus (EBV) to allow maintenance of the amplicon DNA in the host cell by replication, and components of retrovirus particles for production of retrovirus vectors. Our proposed strategy was to use this vector to convert neuroprecursor cells into retrovirus vector-producing cells. These cells were chosen as delivery vehicles as they migrate to and infiltrate tumors in the brain and throughout the body (Aboody et al., 2000; Brown et al., in press; Tang et al., 2003). We have shown that the mouse neuroprecursor cell line, C17.2 (Aboody et al., 2000) is highly infectable with HSV amplicon vectors and can produce retrovirus vectors at relatively high titer following infection with the HSV/EBV/RV amplicon vectors (Mydlarz et al., 2002). Further, in a model of experimental brain gliomas, injection of C17.2 cells infected with a tribrid vector encoding

the TK and CD prodrug activating enzymes near the tumors was shown to reduce tumor volume after prodrug administration (Mydlarz et al., 2002). In order to avoid using C17.2 cells, which have been immortalized with an *onc* gene and hence have a small chance of producing tumors in their own right.

In a third therapeutic approach we cloned an expression cassette for the apoptotic protein, caspase-1 into an HSV-1 amplicon vector bearing a GFP reporter gene (Fig. 11) (Messerli et al., submitted). Tumor cells infected with this vector (GFP-positive) underwent apoptosis (TUNEL-positive) and could be imaged using an NIRF probe selectively activated by caspase-1 in culture (Fig. 12) and *in vivo* (Fig. 13). Thus, this vector allows a means to induce death of tumor cells and to image expression of the "death enzyme" *in vivo*. This basic HSV-1 amplicon vector, which lack retrovirus and EBV sequences should be readily compatible with clinical trials.

Task 2. Evaluate retrovirus production by HSV/EBV/RV amplicon vectors in cultured schwannoma and meningioma cells.

This task was not completed in its entirety. We were able to culture normal neural precursor cells from mouse embryos and showed they were infectable with the HSV/EBV/RV amplicon vector and produced retrovirus vectors. However, we chose to concentrate our efforts on Task 4 below due to very encouraging therapeutic results with the oncolytic HSV-1 vectors and the higher potential for translation into clinical trials of a strategy incorporating replication-conditional HSV-1 vectors than one utilizing neuroprecursor cells and amplicon vectors containing multiple viral elements. An HSV-1 recombinant vector similar to G47 Δ , termed G207 (deleted for ICP6 and γ 34.5, but not for ICP47) has been tested in Phase I clinical trials for glioblastoma and prostate cancer (Markert et al., 2000; Martuza et al., ongoing). These trials are designed to test toxicity, and to date no adverse events attributable to the vector have been found at doses up to 10^9 pfu injected directly into the brain. In contrast neither HSV amplicon vectors nor neuroprecursor cells have been tested in clinical trials, and HSV/EBV/RV amplicon vectors present the additional risk of oncogenic mutagenesis by insertion of retroviral genomes into host cells. HSV-1 amplicon vectors also have less potential potency, as compared to recombinant virus vectors, in terms of the number of vector particles that can be delivered into the tumor.

Task 3. Maximize tolerable prodrug treatments in non-tumor bearing animals.

This work was not carried out as part of this study, but was done for another project (Aghi et al., 1998).

Task 4. Test therapeutic efficacy of vectors in tumor models.

We have tested the most promising vector strategy for efficacy in treating experimental NF2 tumors. Recombinant G47 Δ vector has been injected into 5 schwannomas in NF2 transgenic mice. There was a remarkable consistency in response with tumors shrinking in volume (as assessed by MRI) by about 80% within 1 month after injection (Fig. 14). The rate of regression was greatest in the initial 10 days after injection and slowed following that time. This is probably because the immune system curtailed virus spread over time, which although a possible limitation for therapy, is at the same time a safety feature for use of the vector. Vector replication appeared to "smoulder" on in the tumors, however, as 2 months after injection virally infected cells in the tumor could still be detected by β -galactosidase staining (Fig. 8B). Animals were healthy throughout this period. In another tumor model, schwannoma tissue (Fig. 15) removed from a schwannomatosis patient of Dr. Mia McCollin was implanted subcutaneously in nude mice and shown by MRI to form a tumor. Injection of G47 Δ into this tumor resulted in marked regression in tumor volume by 80% within 1 week (Fig. 16). This finding is remarkable in that provides preliminary evidence that human schwannomas are vulnerable to the G47 Δ vector. This effect may have been potentiated to some extent by the immune deficiency of the host, thus allowing virus replication to proceed rapidly.

KEY RESEARCH ACCOMPLISHMENTS:

- Detection and volumetric assessment of schwannomas in a transgenic murine model for NF2 by MRI
- Correlation of tumor diagnosis by MRI and histopathological analysis
- Characterization of Schwann cell origin of schwannomas and Schwann cell hyperplasias found in a transgenic murine model for NF2
- Infectability of schwannomas and meningiomas with HSV-1 amplicon vectors and replicational-conditional virus vectors
- Characterization of merlin status of 13 meningioma cell lines
- Reduction of schwannoma volume in NF2 transgenic mice by injection of oncolytic HSV-1 vector, G47 Δ (n = 5)
- Development of an NF2 meningioma model by implantation of human meningioma tissue into the subdural space of nude mouse brain, and development of schwannoma model by implanting human schwannoma tissue subcutaneously in nude mice
- Testing of new reporter proteins, luciferase and caspase-1, to allow visualization of gene delivery to schwannomas in living mice by bioluminescence imaging and near infrared imaging, respectively
- Demonstration of the specificity of NIRF probe for caspase-1 and ability of HSV amplicon vector to elicit apoptosis in glioma cells in culture

REPORTABLE OUTCOMES:

Manuscripts:

- Messerli, S. M., Prabhakar, Tang, Y., Shah, K., Cortes, M. L., Murthy, V., Weissleder, R., Breakefield, X. O., & Tung, C. A novel method for imaging apoptosis using a caspase-1 (ICE) near infrared fluorescent imaging probe. Submitted to Neoplasia.
- Messerli, S. M., Tang, Y., Giovannini, M., Bronson, R., Weissleder, R., & Breakefield, X. O. (2002). Detection of spontaneous schwannomas by MRI in a transgenic murine model of Neurofibromatosis type 2 (NF2). *Neoplasia* 4, 501-509.
- Tang, Y., Shah, K., Messerli, S. M., Snyder, E., Breakefield, X. O., & Weissleder, R. (2003). In vivo tracking of neural progenitor cell migration to glioblastomas. *Human Gene Therapy*. 14, 1247-1254.

Meeting abstracts:

- Kumar*, S. M., Tang, Y., Giovannini, M., Bronson, R. T., Weissleder, R., & Breakefield, X. O. (2002). Detection of Spontaneous Schwannomas by MRI in a Transgenic Murine Model of Neurofibromatosis Type 2. Abstract No. 299, American Society for Gene Therapy, Boston, MA.
- Messerli, S. M., Tang, Y., Giovannini, M., Bronson, R. T., Weissleder, R., & Breakefield, X. O. (2002). Detection of spontaneous schwannomas by MRI in a transgenic murine model of neurofibromatosis type 2. *Mol Ther* 2, S9-210, Abst. 299.
- Kumar, S. M., Tang, Y., Shah, K., Giovannini, M., Weissleder, R., & Breakefield, X. O. (2002) Gene delivery to schwannomas in a transgenic murine model of neurofibromatosis type 2 (NF2). *Molecular Therapy. Mol Imag* 1, Abst. 284, Boston, MA.
- Mydlarz, W. K., Camp, S. M., Sena-Esteves, M., Snyder, E. Y., Breakefield, X. O., Hampl, J. A. (2002) Migratory neuroprogenitor cells target therapeutic retrovirus vectors to intracranial gliomas in mice. *Mol Ther* 5, Abst. 1356 (American Society for Gene Therapy, Boston, MA).

Note: * indicates a name change from Kumar to Messerli.

Presentations:

X. O. Breakefield – “Gene delivery to spontaneous schwannomas in neurofibromatosis (NF) type 2 mouse model”, Workshop on “Herpes virus vectors for gene transfer to the peripheral nervous system *in vivo*”, American Society of Gene Therapy, Boston, MA, June, 2002.

X.O. Breakefield – “HSV amplicon designs for expanding and regulating gene delivery in the nervous system”, Seminar, University of Rochester School of Medicine and Dentistry, Center for Aging and Developmental Biology, Rochester, N.Y., May, 2002.

Funding:

MGH Fund for Medical Discovery awarded to Shanta M. Kumar for the periods Jan 15, 2002-Jan. 15, 2003, funded by MGH.

Personnel receiving pay from Award # DAMD17-00-1-0537:

Breakefield, Xandra O.
Ramesh, Vijaya
Messerli, Shanta
Prabhakar, Shilpa
Smith, Nicole

CONCLUSIONS:

These studies have made several important contributions to the development of novel therapies for schwannoma and meningioma tumors found in NF2 patients in the areas of characterization of: experimental animal models; evaluation of tumor site, volume and infectability by *in vivo* imaging methods; and development of therapeutic viral vectors designed to “shrink” tumor volumes by direct injection. These studies provide a basis for focused preclinical studies in these experimental mouse models to explore the therapeutic potential of vectors, as well as drugs.

Several mouse models for each of these lesions have been further characterized, including a transgenic and floxed mouse model, originally developed by Dr. Marco Giovannini (Giovannini et al., 1999 and 2000). Spontaneous schwannomas were detected and their growth tracked by MRI in the transgenic model. We also explored injection of HSV-1 amplicon vectors expressing Cre recombinase subcutaneously and into the ventricles of floxed mice, both newborn and adult, with preliminary evidence indicating the formation of brain tumors, including a malignant peripheral nerve sheath tumor. In a parallel approach, human meningioma and schwannoma cells/tissue was implanted subdurally or subcutaneously into the flanks of nude mice, with MRI evidence of tumor growth and correlative histology. These studies support the usefulness of the transgenic NF2 model as a means to reproducibly generate schwannomas with a similar genetic etiology to human NF2 tumors, with most animals developing these tumors between 9 – 18 months of age. The limitations of this model are the time to tumor formation, which increases animal costs, and the disparate location of tumors, which can make injections difficult and may result in intrinsic differences in growth rate. The floxed NF2 model provides the potential to generate tumors in reproducible locations by directed injection of HSV-1 amplicon vectors expressing Cre recombinase, but further studies are needed to determine the frequency of these lesions and their histology. The human tumor implantation models provide a cross check on the ability of these vectors to infect and reduce the size of tumors found in patients.

Small animal MRI imaging proved effective at locating schwannoma and meningioma tumors in mice and tracking volumetric changes in them over time. By defining growth and regression parameters in transgenic lesions, it is now possible to plan a realistic and minimal number of imaging time points to obtain quantitative assessment of therapeutic efficacy using different treatment paradigms. Bioluminescence imaging proved effective in determining the efficiency of gene delivery/expression to lesions in living animals. A novel imaging modality, NIRF, was employed to evaluate gene delivery/expression of a therapeutic gene encoding the apoptotic protein, caspase-1. A novel NIRF probe was developed that was specific to this protease and shown to be effective in imaging gene delivery/expression in tumors in living animals.

Several therapeutic paradigms employing HSV-1 vectors were explored for reducing the mass of schwannomas in mouse models, including use of HSV-1 oncolytic vectors, HSV-1 amplicon vectors expressing cell death proteins, and neuroprecursor cells armed with hybrid amplicon vectors expressing prodrug activating genes. Two of these strategies appear particularly promising based on the high infectability of these tumor cells with HSV-1 vectors and on their potential for translation into clinical trials. The oncolytic HSV-1 vector was shown to lead to an 80% reduction in the volume of schwannomas in transgenic NF2 mice (n = 5) within a few weeks following direct injection. Although more work needs to be done to increase the number of test animals, to include additional controls and to evaluate potential toxicity, this approach appears to be worth pursuing at the preclinical level for potential treatment of inoperable tumors causing pain or compression of vital tissues in NF2 patients. The HSV-1 amplicon vector expressing the apoptotic protein caspase-1 was shown in preliminary studies to be able to kill glioma tumor cells in culture. Although further work is needed to evaluate its potency against schwannomas and meningiomas, it should have less potential toxicity than the oncolytic vectors, and hence also appears worth pursuing in parallel.

For future studies we plan to join forces with Drs. Robert Martuza and Samuel Rabkin at our institution who have pioneered the use of oncolytic HSV-1 vectors for treatment of glioblastomas and have proceeded from the development of these vectors in the laboratory to Phase I clinical trials. The G47 Δ and HSV amplicon caspase-1

vectors will be evaluated for their ability to reduce mass of schwannoma tumors in the NF2 transgenic model, and hopefully also for schwannomas and meningiomas in the floxed NF2 model. This work will include vector biodistribution and toxicity data for presentation to the FDA for consideration of a Phase I clinical trial in NF2 patients bearing inoperable tumors which are life threatening.

REFERENCES:

- Abe, T., Kawamura, N., Homma, H., Sasaki, K., Izumiyama, H., Matsumoto, K. (2000) MRI of orbital schwannomas. *Neuroradiology*, **42**: 466-468.
- Aboody, K.S., Brown, A., Rainov, N.G., Bower, K.A., Liu, S., Yang, W., Small, J.E., Herrlinger, U., Ourednik, V., Black, P.M., Breakefield, X.O., Snyder, D.E.Y. (2000) Neural stem cells display extensive tropism for pathology in adult brain: evidence from intracranial gliomas. *Proc Natl Acad Sci USA*, **97**: 12846-12851.
- Aghi, M., Kramm, C.M., Chou, T.C., Breakefield, X.O., Chiocca, E.A. (1998) Synergistic anticancer effects of ganciclovir/thymidine kinase and 5-fluorocytosine/cytosine deaminase gene therapies. *J Natl Can Inst*, **90**: 370-380.
- Brown, A., Yang, W., Schmidt, N., Carroll, R. Leishear, K.K., Rainov, N.G., Black, P.M., Breakefield, X.O., Aboody, K.S. Intravascular delivery of neural stem cells to target intracranial and extracranial tumors of neural and non-neural origin. *Hum Gene Ther*, in press.
- Eldridge, R. (1981) Central neurofibromatosis with bilateral acoustic neurons. *Adv Neurol*, **29**: 57-65.
- Giovannini, M., Robanus-Maandag, E., Niwa-Kawakita, M., van der Valk, M., Woodruff, J.M., Goutebroze, L., Merel, P., Berns, A., Thomas, G. (1999) Schwann cell hyperplasia and tumors in transgenic mice expressing a naturally occurring mutant NF2 protein. *Genes Dev*, **15**: 978-986.
- Giovannini, M., Robanus-Maandag, E., van der Valk, M., Niwa-Kawakita, M., Abramowski, V., Goutebroze, L., Woodruff, J.M., Berns, A., Thomas, G. (2000) Conditional biallelic NF2 mutation in the mouse promotes manifestations of human neurofibromatosis type 2. *Genes Dev*, **14**: 1617-1630.
- Hayasaka, K., Tanaka, Y., Soeda, S., Huppert, P., Claussen, C.D. (1999) MR findings in primary retroperitoneal schwannoma. *Acta Radiol*, **40**: 78-82.
- Hayashi, M., Kubo, O., Sato, H., Taira, T., Tajika, Y., Izawa, M., Takakura, K. (1996) Correlation between MR image characteristics and histological features of acoustic schwannoma. *Noshuyo Byori*, **13**: 139-144.
- Kalamarides, M., Niwa-Kawakita, M., Leblois, H., Abramowski, V., Perricaudet, M., Janin, A., Thomas, G., Gutmann, D.H., Giovannini, M. (2002) Nf2 gene inactivation in arachnoidal cells is rate-limiting for meningioma development in the mouse. *Genes Dev*, **16**: 1060-1065.
- Markert, J.M., Medlock, M.D., Rabkin, S.D., Gillespie, G.Y., Todo, T., Hunter, W.D., Plamer, C.A., Feigenbaum, F., Tornatore, C., Tufaro, F., Martuza, R.L. (2000) Conditionally replicating herpes simplex virus mutant, G207 for the treatment of malignant glioma: results of a phase I trial. *Gene Ther*, **7**: 867-874.
- Messerli, S.M., Prabhakar, S., Cortes, M.L., Murthy, V., Weissleder, R., Breakefield, X.O., Tung, C.-H. A novel method for apoptosis imaging using an ICE (caspase-1) - near-infrared fluorescent imaging probe: submitted.
- Messerli, S.M., Tang, Y., Giovannini, M., Bronson, R., Weissleder, R., Breakefield, X.O. (2002) Detection of spontaneous schwannomas by MRI in a transgenic murine model of neurofibromatosis type 2. *Neoplasia*, **4**: 501-509.

- Mydlarz, W.K., Camp, S.M., Sena-Esteves, M., Snyder, E.Y., Breakefield, X.O., Hampl, J.A. (2002) Migratory neuroprogenitor cells target therapeutic retrovirus vectors to intracranial gliomas in mice. *Mol Therapy*, **5**: Abst 1356.
- Saeki, Y., Fraefel, C., Ichikawa, T., Breakefield, X.O., Chiocca, E.A. (2001) Improved helper virus-free packaging system for HSV amplicon vectors using an ICP27-deleted, oversized HSV-1 DNA in a bacterial artificial chromosome. *Mol Ther*, **3**: 591-601.
- Sans, A., Bartolami, S., Fraysse, B. (1996) Histopathology of the peripheral vestibular system in small vestibular schwannomas. *Am J Otol*, **17**: 326-334.
- Sena-Esteves, M., Saeki, Y., Camp, S., Chiocca, E.A., Breakefield, X.O. (1999) Single step conversion of cells to retrovirus vector producers with herpes simplex virus-Epstein Barr virus hybrid amplicons. *J Virol*, **73**: 10426-10439.
- Soderlund, V., Goranson, H., Bauer, H.C. (1994) MR imaging of benign peripheral nerve sheath tumors. *Acta Radiol*, **35**: 282-286.
- Tang, Y., Shah, K., Messerli, S.M., Snyder, E., Breakefield, X.O., Weissleder, R. (2003) In vivo tracking of neuronal progenitor cell migration to glioblastomas. *Hum Gene Ther*, **14**: 1247-1254.
- Todo, T., Martuza, R.I., Rabkin, S.D., Johnson, P.A. (2001) Oncolytic herpes simplex virus vector with enhanced MHC class I presentation and tumor cell killing. *Proc Natl Acad Sci USA*, **98**: 6396-6401.
- Woodruff, J.M., Scheithauer, B.W., Kurtkaya-Yapicier, O., Raffel, C., Amr, S.S., LaQuaglia, M.P., Antonescu, C.R. (2003) Congenital and childhood plexiform (multinodular) cellular schwannoma: a troublesome mimic of malignant peripheral nerve sheath tumor. *Am J Surg Pathol*, **27**: 1321-1329.




Figure 1. For genotyping purposes, PCR was performed on DNA isolated from the tails of transgenic mice, [P0-Sch delta(39-121)], which have an in-frame interstitial deletion in the amino terminal domain of NF2, similar to natural mutations observed in humans. These NF2 transgenic mice were obtained from Dr. Marco Giovannini and have been shown to spontaneously form schwannomas and schwann cell hyperplasias (Giovannini et al., 1999). The primers used for this genotyping of the mice were GAP3.3 and TAG.Anti. The 320 bp fragment represents the mutated NF2 transgene found in these transgenic mice. A band is not detected (-) in wildtype FVBN mice.

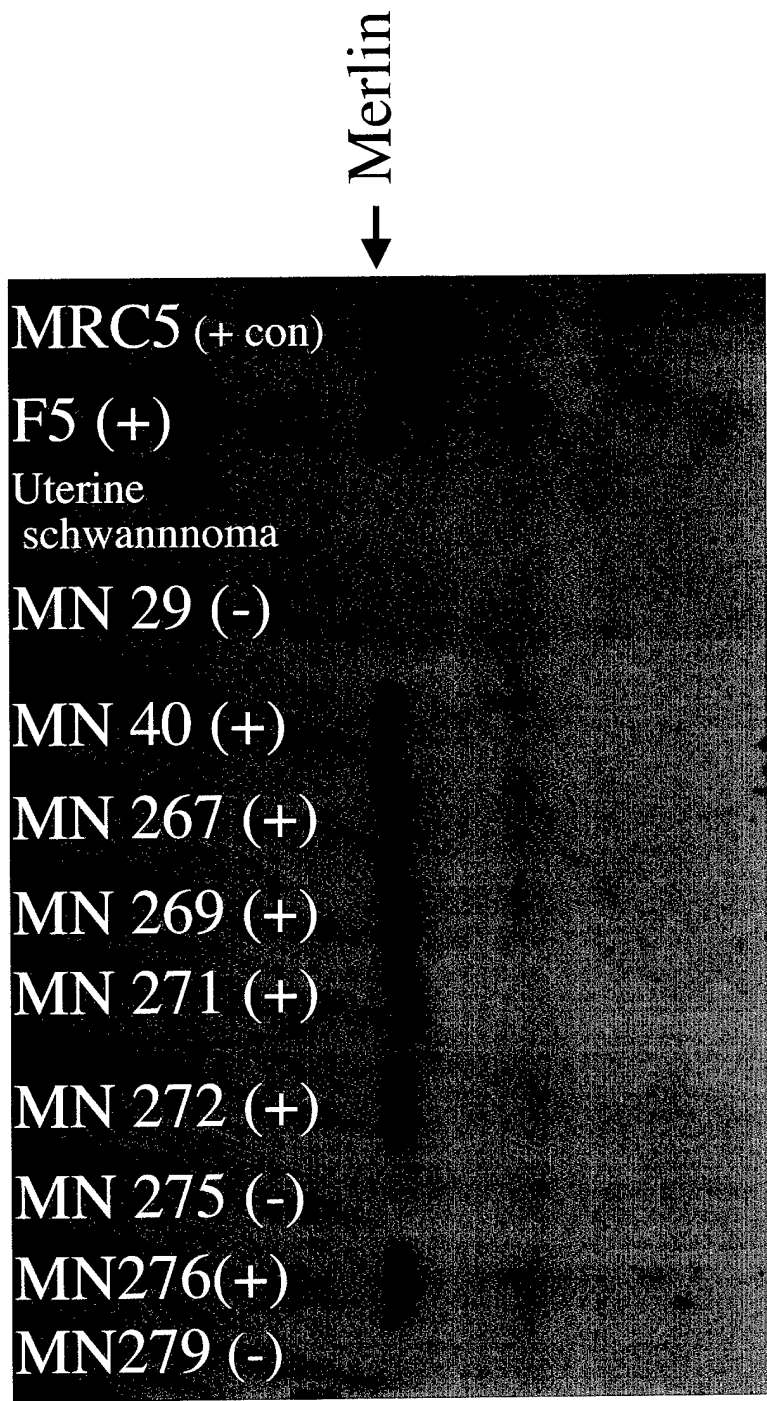


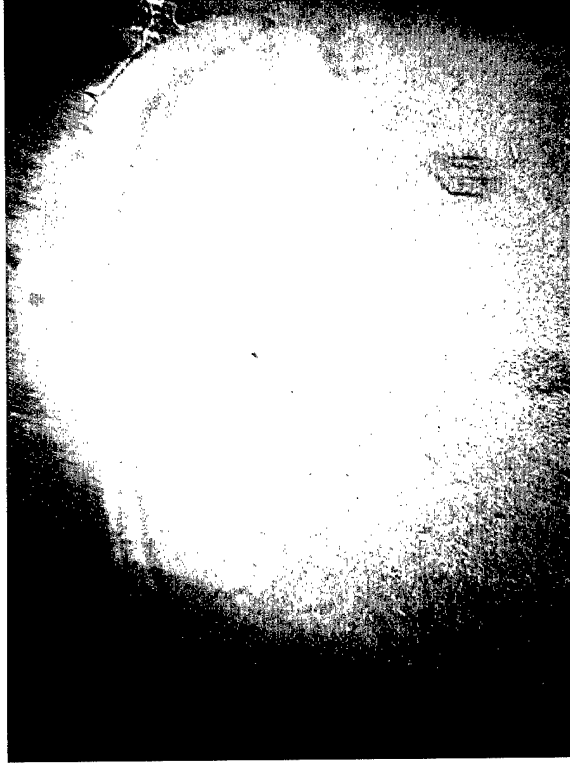Figure 2. Western blot of cell homogenates from 10 different meningioma lines derived from human patients. One hundred micrograms of protein were loaded in each lane of a 10% SDS gel. Ponceau S staining was done to verify that equal amounts of protein were loaded. MRC5 is a human fetal fibroblast cell lysate used as a positive control for merlin. Merlin is the protein product of the NF2 tumor suppressor gene (arrow). Primary antibody, MP8, was used at a dilution of 1:30 (developed in Dr. V. Ramesh's laboratory) and the secondary antibody, goat-anti-rabbit IgG HRP, at a 1:10,000 dilution. Film was exposed for 1 hour.




Figure 3. Infectability of F5 meningioma cells with an HSV amplicon vector containing CMV-driven GFP, 20X. Noninfected cells are represented in Panel A, and infected cells at a MOI = 0.5, 1 and 2 are shown in Panels B, C and D, respectively.



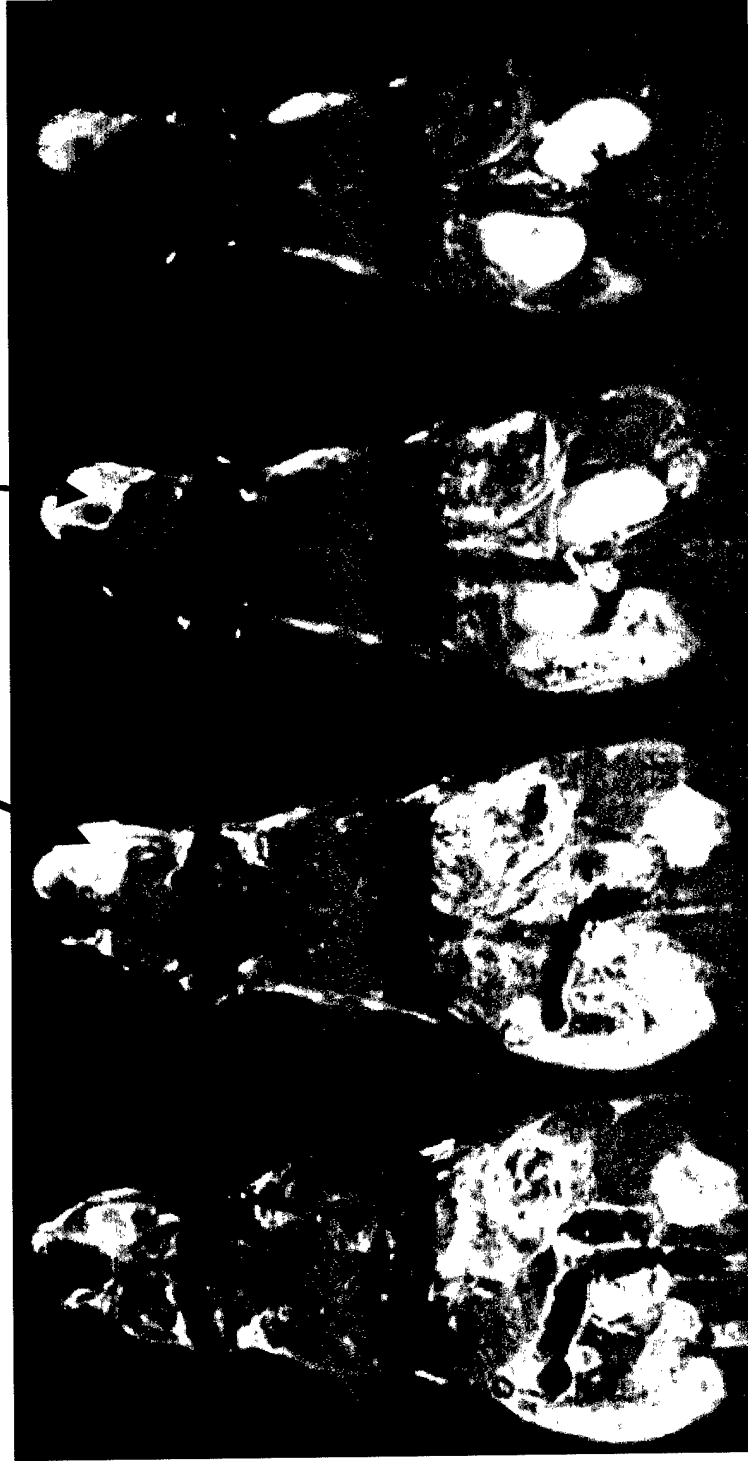
Control injection



F5 injection

Figure 4. Meningioma model showing formation of a tumor invading the parenchyma following intraventricular injection of the malignant F5 cells into brains of nude mice.

Tumor near eye



Section

8

9

10

11

Figure 5. MRI indicating homozygous NF2 floxed mouse which developed a tumor near the eye 6 months after subcutaneous injection of HSV-CRE amplicon vector. Coronal GdT1 slices, 1.5 mm thickness, consecutive slices.

Table 1

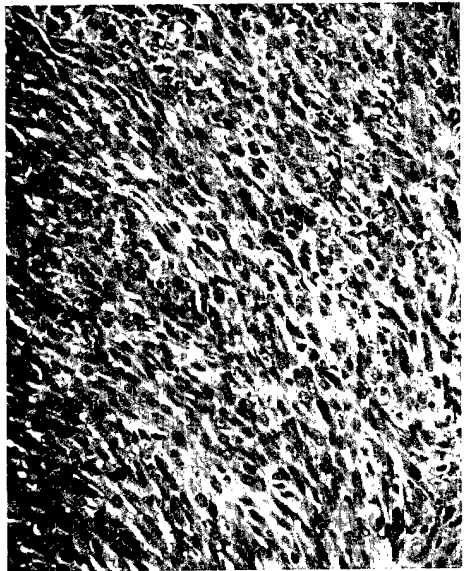
NF2 floxed mice injected with HSV-Cre amplicon vector

NF2 Floxed mice	Age of injection	Site of injection	MR system	MRI date (p.i.)	MR report	Necropsy/Histology report
1	Adult	subcutaneously (s.c.)	Clinical 1.5T	8 months	eye tumor	MPNST/S100 +
2	Adult	s.c.	Bruker 4.7 T	8 months	no tumor	N/A
3	Adult	s.c.	mouse	8 months	no tumor	N/A
4	Adult	s.c.	imaging	8 months	no tumor	N/A
NF2 Floxed mice	Age of injection	Site of injection	MR system	MRI date (p.i.)	MR report	Necropsy/Histology report
1	3 day old pup	s.c., intraventricularly (i.v.)	Bruker 4.7 T	2-3 month, weekly	no tumor	N/A
2	3 day old pup	s.c., i.v.	mouse	2-3 month, weekly	brain & abdominal tumor	fluid filled cysts/putative tumor
3	3 day old pup	s.c., i.v.	imaging	2-3 month, weekly	abdominal	fluid filled cysts/putative tumor
			system			




C

S-100 ab, 10x



D

S-100 ab, 40x



E

No S-100 ab

Figure 6. Histology and S-100 immunostaining of floxed eye tumor indicate Malignant Peripheral Nerve Sheath Tumor (MPNST). Spindle cells are arranged in interlacing whorls and short stacks (A-B). Tumor sections stain positively for S-100 (C,D 10X and 40X respectively).

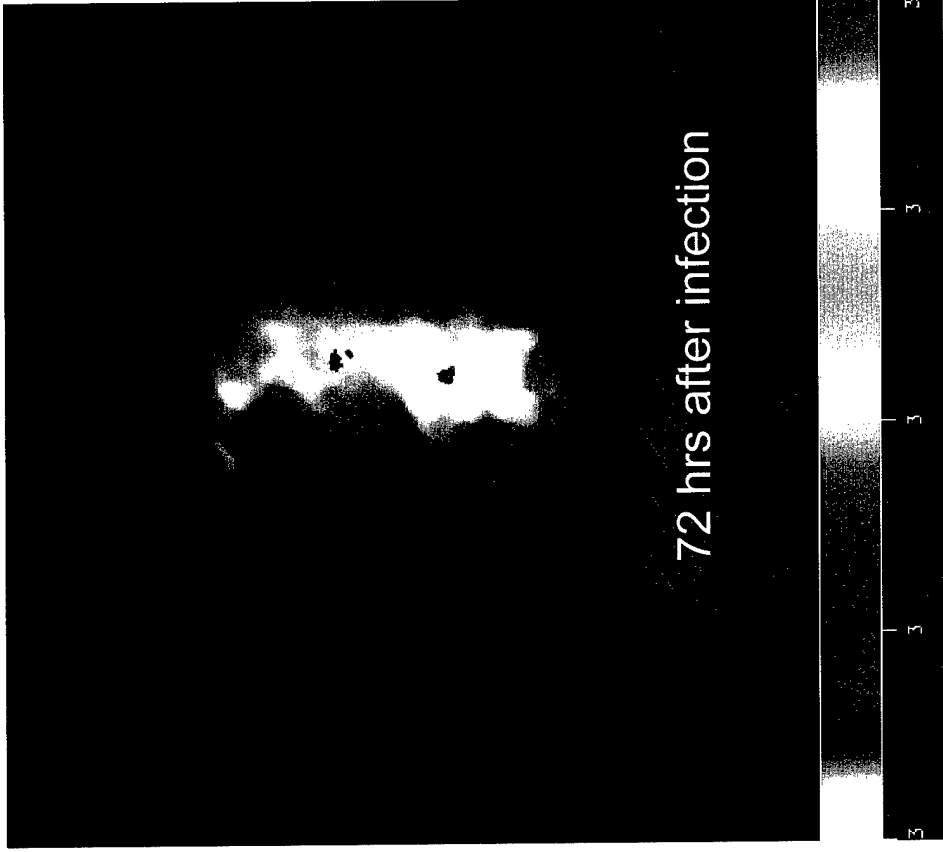

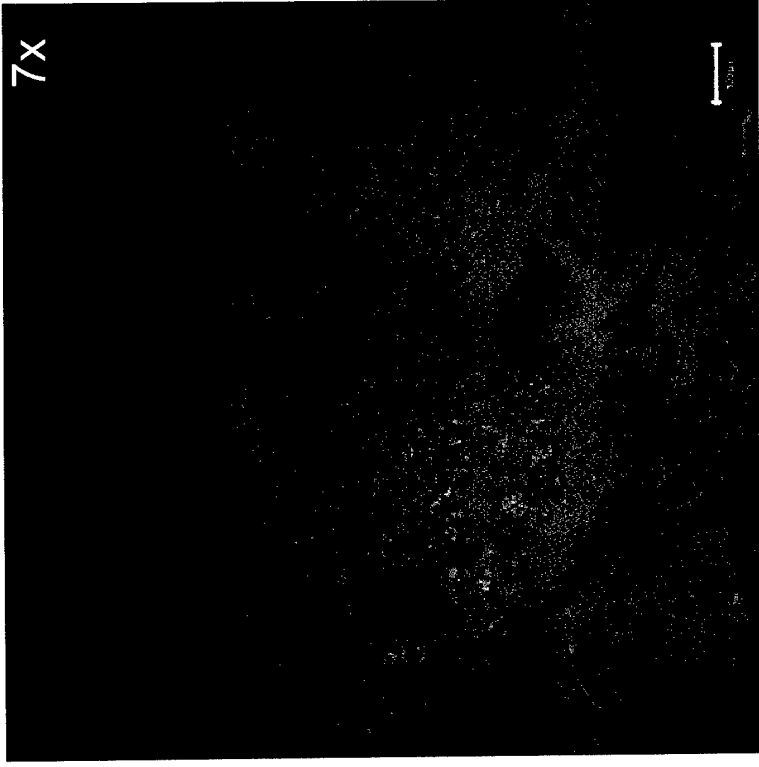



Figure 7. *In vivo* luciferase imaging demonstrating infectability of schwannoma with an HSV amplicon expressing luciferase. 5×10^6 tu of virus was injected in 10 μ l into the tumor and imaged 48 and 72 hrs after intraperitoneal injection of luciferin. The signal peaked at 48 hrs (A) and then decreased by 72 hrs (B) following injection of amplicon.



S-100 ab overlay



β -gal staining, 488nm

Figure 8. Infectability of schwannoma in NF2 transgenic model, which regressed following treatment with G47 Δ , 2 months following infection (2 different sections from same tumor, stained independently for S-100 [left] and β -gal [right]).

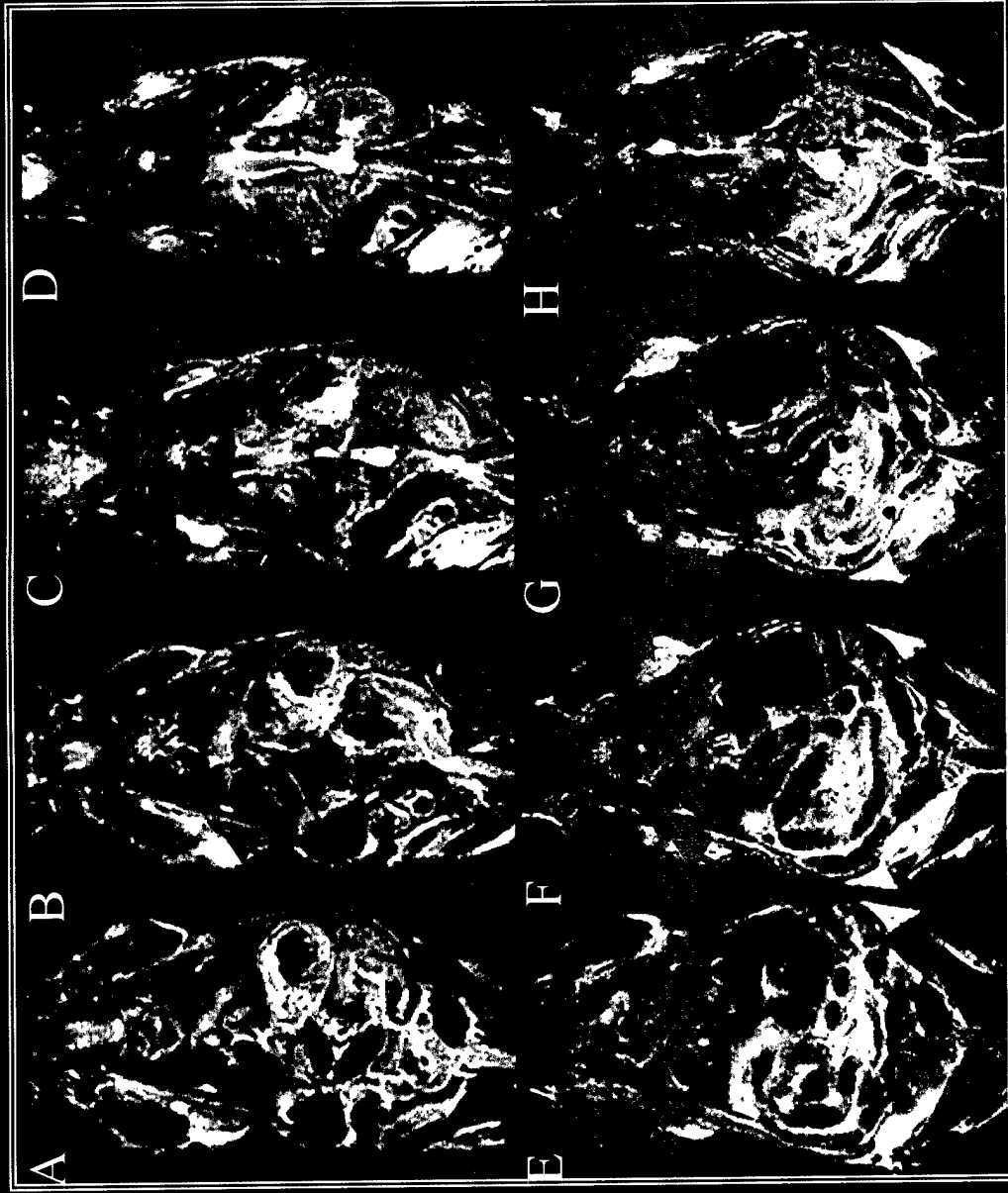


Figure 9. MRI shows regression of tumor treated with G47 Δ . MRI of a male 18 month old NF2 transgenic mouse with bilateral schwannomas (A-D) suggests regression of tumor (E-H) when treated with G47 Δ (tumor on left, indicated by red arrow) 21 days following injection of virus. The tumor treated with a control HSV vector (tumor on right, indicated by blue arrow), continued to grow.

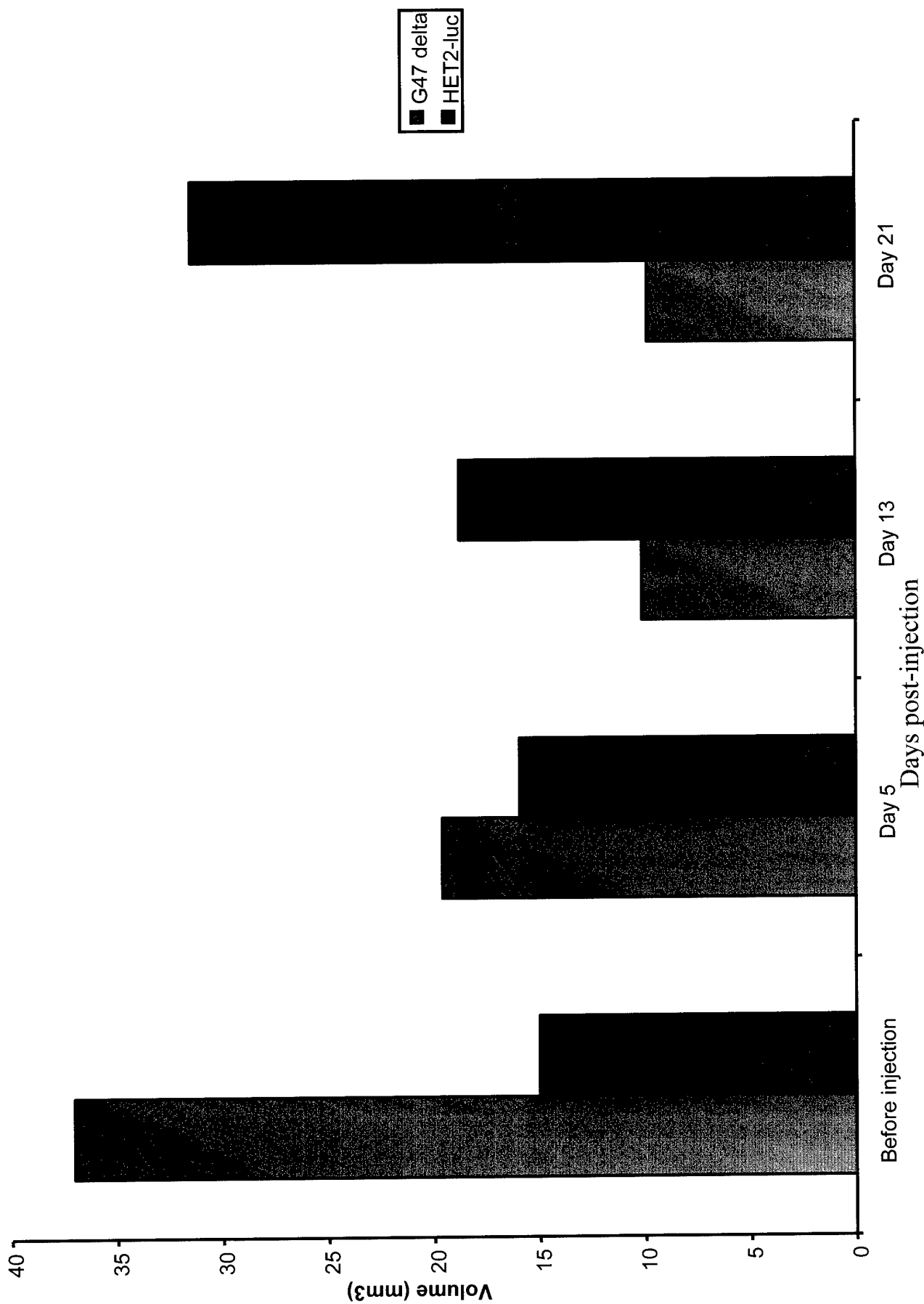


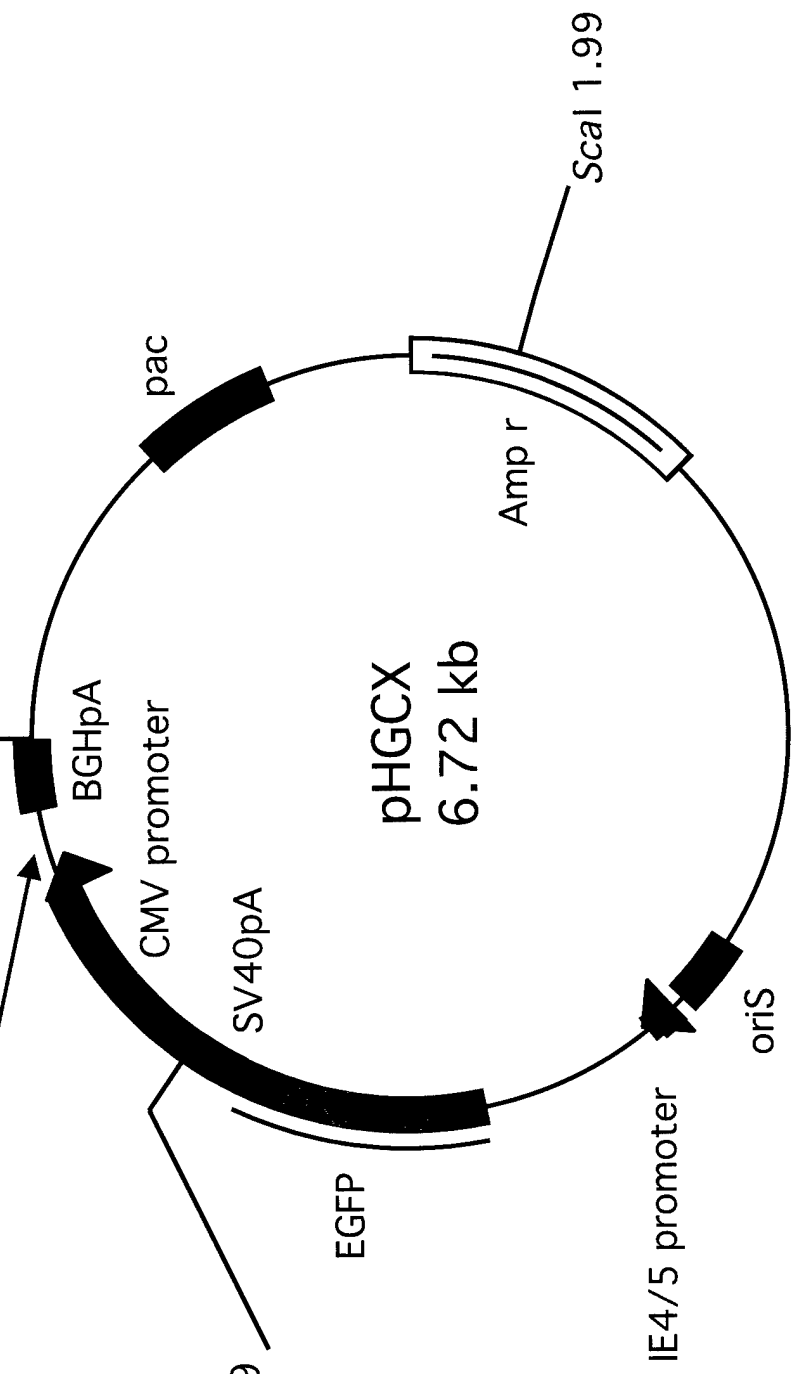
Figure 10. NF2 transgenic male mouse with two subcutaneous schwannomas, one injected with G47 Δ and the other with control HSV-1 vector (HET2-luc)

Figure 11. pHGC-ICE (caspase-1)-lacZ amplicon. An ICE-lacZ cDNA was cloned into the multi-cloning site of the HSV amplicon pHGCX under the control of a CMV promoter. The pHGCX backbone contains an HSV origin of replication (oriS), a cleavage/packaging signal (pac), as well as GFP, under an intermediate early viral promoter, IE4/5 (Saeki et al., 2001).

HSV AMPLICON

*Pac*I 6.72

caspase-1-lacZ
(4.2 kb)



*Bg*III 5.69

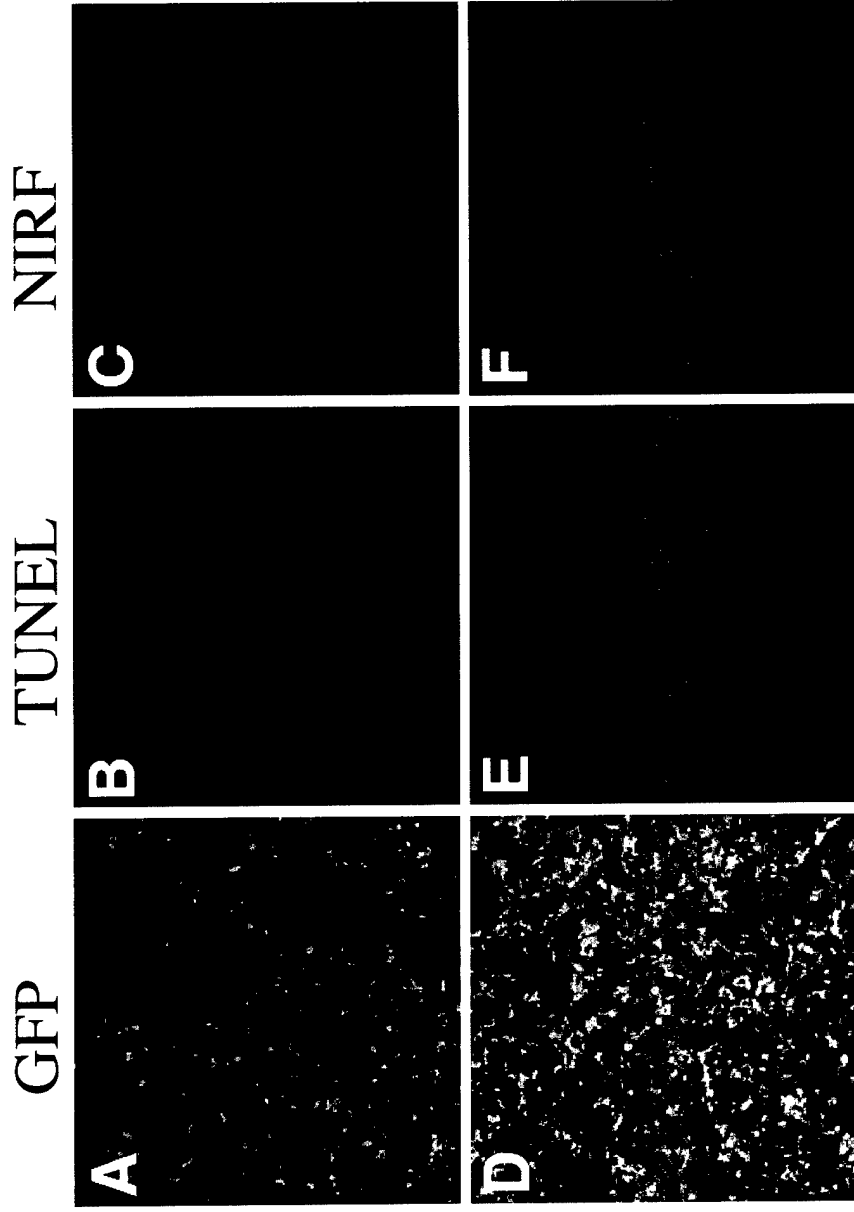


Figure 12. Glioma cells infected with HSV-1 HGC-ICE-lacZ amplicon (caspase-1) vector showed apoptosis and selective activation of NIRF probe for caspase-1. Twenty-four hrs following infection of Gli36 cells with HGC-ICE-lacZ vector (M.O.I. = 1), cells were treated with the ICE-NIRF probe and TUNEL stained. Infection of Gli36 with the HGC-ICE-lacZ vector (A & D GFP fluorescence) induces apoptosis, indicated by positive TUNEL staining (B) and activation of the caspase -1 - NIRF probe (C). Vector induced apoptosis was blocked by co-incubation of the cells with the vector and the caspase-1-inhibitor YVAD-cmk, indicated by a reduced number of TUNEL stained cells (E) and lower level activation of the ICE-NIRF probe (F).




Figure 13. *In vivo* imaging of apoptosis induced by injection of HSV-1 caspase-1 amplicon vector into a primary human glioma explant (left) followed by systemic administration of caspase-1 NIRF probe. Glioma explant, which was injected with control HSV-1 vector (right) did not emit a fluorescent signal.

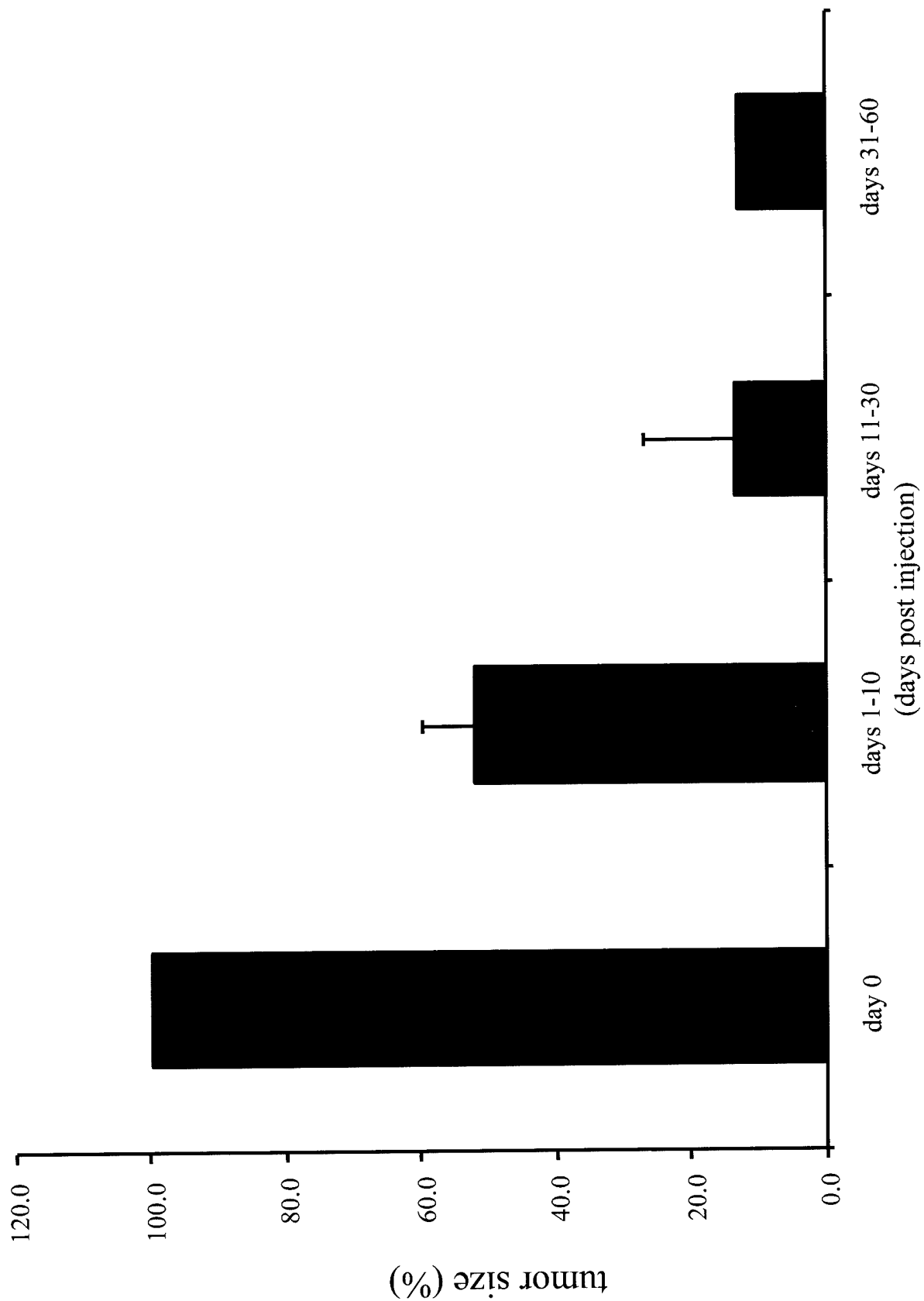


Figure 14. Regression of schwannoma size in NF2 transgenic model as assessed by MRI following single direct injection (day 0) of G47 Δ , (n=5) into tumor mass.


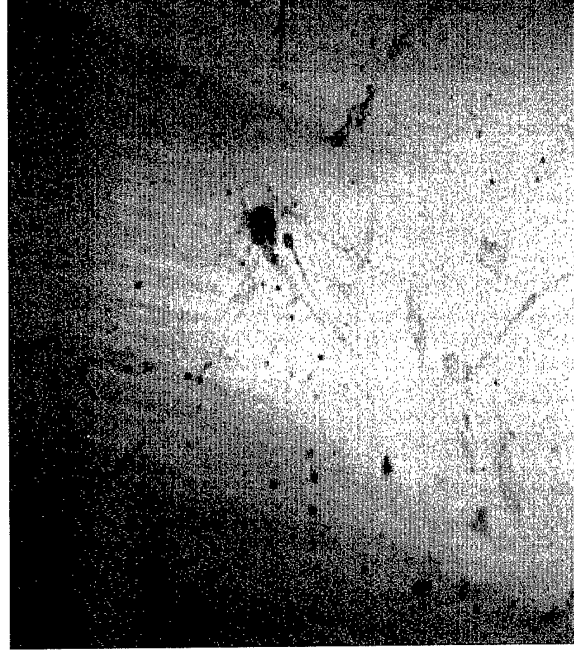




Figure 15. Human schwannoma tissue was implanted into the flank of a nude mouse. The tumor was subsequently removed and H & E stained (A 20X, B 100X). Part of the human tumor was also cultured and stained positively (D) for S100. C is the brightfield image of the same cells stained in panel D.

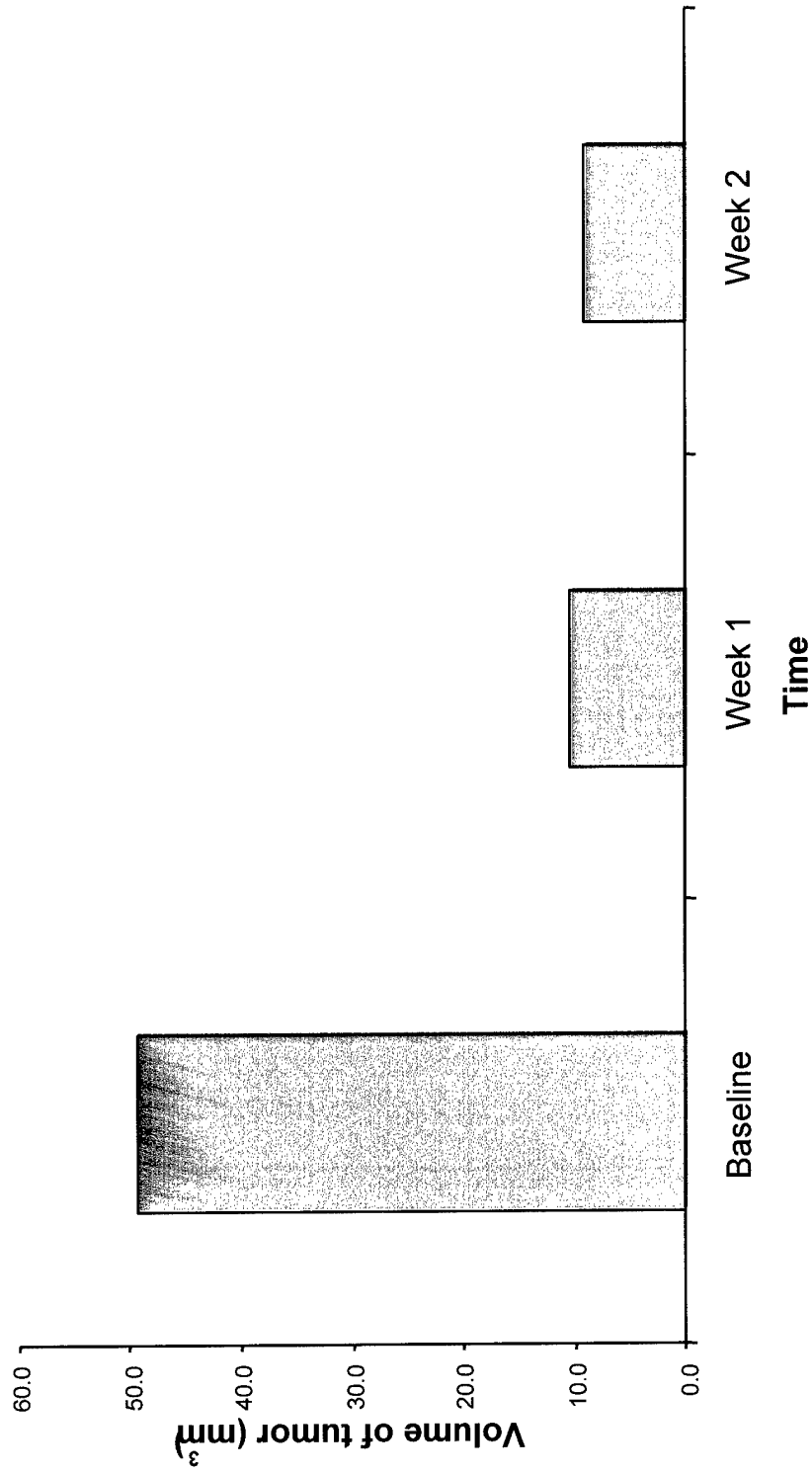


Figure 16. Volume of human schwannoma implant in an immunodeficient mouse assessed by MR imaging over time following direct injection of G47Δ vector on day 0 (baseline).