

REPORT DOCUMENTATION PAGE

Form Approved
OMB No. 0704-0188

Public reporting burden for this collection of information is estimated to average 1 hour per response, including the time for reviewing instructions, searching existing data sources, gathering and maintaining the data needed, and completing and reviewing the collection of information. Send comments regarding this burden estimate or any other aspect of this collection of information, including suggestions for reducing this burden to Washington Headquarters Services, Directorate for Information Operations and Reports, 1215 Jefferson Davis Highway, Suite 1204, Arlington, VA 22202-4302, and to the Office of Management and Budget, Paperwork Reduction Project (0704-0188), Washington, DC 20503.

PLEASE DO NOT RETURN YOUR FORM TO THE ABOVE ADDRESS.

1. REPORT DATE (DD-MM-YYYY) 15-07-2004		2. REPORT TYPE Final Report		3. DATES COVERED 20 May 1999 - 28 Feb 2003	
4. TITLE AND SUBTITLE Assessment of Mechanical Damage to Odontocete Respiratory Tract Tissues after Controlled Exposure to Blasting				5a. CONTRACT NUMBER NO0014-99-1-0815	
				5b. GRANT NUMBER NO014-99-1-0815	
				5c. PROGRAM ELEMENT NUMBER	
6. AUTHOR(S) Reidenberg, Joy S., Laitman, Jeffrey T.				5d. PROJECT NUMBER	
				5e. TASK NUMBER	
				5f. WORK UNIT NUMBER	
7. PERFORMING ORGANIZATION NAME(S) AND ADDRESS(ES) Center for Anatomy and Functional Morphology Box 1007, Mount Sinai School of Medicine New York, NY 10029-6574				8. PERFORMING ORGANIZATION REPORT NUMBER	
9. SPONSORING/MONITORING AGENCY NAME(S) AND ADDRESS(ES) Office of Naval Research 800 N. Quincy St. Arlington, VA 22217-5000				10. SPONSOR/MONITOR'S ACRONYM(S) ONR	
				11. SPONSOR/MONITOR'S REPORT NUMBER(S)	
12. DISTRIBUTION/AVAILABILITY STATEMENT Distribution Unlimited					
13. SUPPLEMENTARY NOTES 20040730 039					
14. ABSTRACT The odontocete respiratory tract is adapted to withstand the gradual pressure changes associated with diving, yet nothing is known about how it responds to the sudden pressure changes of a blast exposure. Our goal is to characterize any respiratory injuries resulting from postmortem blast pressure exposures. Tissues were harvested from 17 freshly dead odontocetes exposed to blast pressures post mortem (supplied by D. Ketten). Blast pressure exposure levels were not revealed to enable unbiased observations. Results indicate that many specimens show dark reddish discoloration of variable intensities that may be evidence of blast-induced trauma. Discoloration was found in the lungs (striped pattern correlating with ribs), larynx (above and below palatopharyngeal sphincter), trachea (uniform throughout lumen), and nasal region (visualized only in unpigmented areas). Histology revealed abnormal accumulation of gas bubbles in tissue and distended blood vessels. Gas containing tissues may exhibit damage due to dramatic compression/expansion to accommodate changing gas volumes. Abrupt edges to discoloration patches indicate protection, possibly conferred by contact with adjacent tissues. Discoloration patterns are consistent in location but have variable intensity, perhaps reflecting different degrees of exposure. This information may be useful in setting critical exposure limits to prevent harm to odontocetes in the vicinity of a blast event.					
15. SUBJECT TERMS anatomy, histology, blast, pressure, respiratory, tissue, nasal, pharynx, larynx, trachea, lung, damage, trauma					
16. SECURITY CLASSIFICATION OF			17. LIMITATION OF ABSTRACT	18. NUMBER OF PAGES	19a. NAME OF RESPONSIBLE PERSON
a. REPORT	b. ABSTRACT	c. THIS PAGE			Joy S. Reidenberg
unclass.	unclass.	unclass.	UL	4 (plus	19b. TELEPHONE NUMBER (Include area code) 212-241-7563

FINAL REPORT

GRANT #: N00014-99-1-0815

PRINCIPAL INVESTIGATOR: Dr. Joy Reidenberg
CO-PRINCIPAL INVESTIGATOR: Dr. Jeffrey Laitman

INSTITUTION: Mount Sinai School of Medicine

GRANT TITLE: Assessment of Mechanical Damage to Odontocete Respiratory Tract Tissues after Controlled Exposure to Blasting

AWARD PERIOD: 20 May 1999 - 28 Feb 2003

OBJECTIVE: Our objective in this study is to determine whether artificially generated blast pressures cause damage to the tissues of the odontocete respiratory tract when exposed post mortem. A second objective is to identify whether there is a passive, mechanical response at the tissue level (possibly an odontocete adaptation to pressure changes encountered during diving) that may be able to accommodate some tissue compression and recoil, thereby minimizing damage at lower blast pressures. If a passive mechanism is present (e.g., elastic fibers), it should function even in the tissues of a post mortem specimen.

APPROACH: The respiratory tract (e.g., nasal cavities, larynx, trachea, lungs) is examined to determine whether blast pressures cause damage, or whether it is naturally protected by diving adaptations. Tissues are harvested from post-mortem odontocete specimens artificially exposed to blast pressures (via collaboration with D. Ketten). Tissues are examined grossly and processed for histology. Tissues are examined for damage and/or ability to react to compression or stretch (e.g., elastic fibers, folded tissues). Mount Sinai researchers have not yet been informed of the blast pressure exposures, or examined pre- and post-blast CT and fluoroscopy images (to be provided by D. Ketten). Images will assist with determining whether any blast-induced tissue damage correlates with gas containing spaces (e.g., gas filled vs. congested lungs may respond differently to blast pressures).

ACCOMPLISHMENTS: We have necropsied and collected fresh tissues from 17 post-mortem, control and/or blast-pressure exposed odontocetes (9 white-sided dolphins, *Lagenorhynchus acutus*; 1 common dolphin, *Delphinus delphis*; 1 striped

dolphin, *Stenella coeruleoalba*; and 6 harbor porpoises, *Phocoena phocoena*). To enable unbiased observations, we have NOT been informed of the experimental status of the specimens (i.e., control or application of various blast pressure exposure levels) supplied by D. Ketten, and have not yet observed the pre- and post-exposure CT or fluoroscopy images. We have made gross observations on all specimens and submitted our reports to Dr. Ketten, who is collating all the data until we are "unblinded." Histology tissue samples were taken from various regions of the following organs: nasal air sacs and plugs (10 samples), pharynx (5 samples), larynx (8 samples), trachea (2 samples), left and right lungs (21 samples), and various other tissues (6 samples). Histological observations on some tissues are complete for all specimens, and we are currently processing the remaining samples.

Gross observations indicate that a few specimens look normal in appearance, while others show variable degrees of dark reddish discoloration that may be evidence of blast-induced trauma. When present, discoloration is most noticeable in the lungs (dark stripes that correlate with overlying intercostal spaces), larynx and trachea (dark red piriform sinuses, epiglottic tip, and lumen). Portions of the nasal region also show some dark red discoloration, but this is difficult to discern where there is black pigment. Histology indicates presence of gas bubbles and dilated vasculature, but no vessel tears or extravascular blood.

CONCLUSIONS: Gas exposed tissue surfaces appear dark red in most specimens. Pattern of patches was consistent, but intensity varied. Gas bubbles were noted in many histological samples, but amount of bubbles observed varied between tissues and among specimens. It is not yet clear whether color and bubble variations will correlate with intensity of blast pressure exposures. Discoloration and bubbles may be indicative of blast damage, but post mortem artifact from pooled blood, dehydration, and fermentation of decomposition can only be ruled out once control specimens are identified. The lack of extravascular blood in histological sections may be a post mortem artifact (hemorrhage requires blood circulation). Laryngeal tissues in contact with other tissues do not appear dark. Thus, lack of exposure to gas may confer tissue protection. Lung tissues adjacent to bone appear lighter than regions adjacent to intercostal spaces, perhaps indicating protection from overlying bone, or lung expansion during rarefaction into the softer intercostal spaces.

SIGNIFICANCE: This project will provide crucial environmental impact information on whether the odontocete respiratory tract is damaged by sudden and large amplitude pressure changes, such as the shock waves that result from underwater blasting. This knowledge is essential for making informed decisions that authorize or deny blasting in proximity to critical cetacean habitats, or setting critical exposure limits to prevent harm to marine mammals in the vicinity of a blast event. If a correlation exists between blast pressure levels and degree of tissue damage observed, then presence of this specific type of tissue damage may be deemed a useful necropsy indicator for determining blast exposure in stranded cetaceans.

PATENT INFORMATION: No patents have been filed.

AWARD INFORMATION:

Basmajian/Williams and Wilkins Award of the American Association of Anatomists (highest national honor for teaching and research in Anatomy), awarded to Joy Reidenberg, 1999.

American Society of Pediatric Otolaryngology, Karl Storz Award (for "Contributions in understanding the comparative anatomy and development of the larynx"), awarded to Jeffrey Laitman, 2000.

Voted "Favorite Lecturer" in the McGrath Lecture Series on Current Topics in Marine Science, Long Island University, Southampton College, NY, awarded to Joy Reidenberg, 2001

First winner of the Institute for Medical Education Excellence in Teaching Award (nominated by several faculty letters), Mount Sinai School of Medicine, awarded to Joy Reidenberg, 2003

PUBLICATIONS AND ABSTRACTS: (Space constraints do not allow listing all work published during grant period, however selections below are representative of the published/in press 9 articles/chapters and 31 abstracts from 1999-2004.)

1. Aroyan, J.L., McDonald, M.A., Webb, S.C., Hildebrand, J.A., Clark, D., Laitman, J.T. and Reidenberg, J.S., (2000) Acoustic models of sound production and propagation. In: W. Au, R. Fay, and A. Popper (eds.), *Hearing in Whales and Dolphins*, Springer-Verlag, NY. pp. 409-469.

2. Reidenberg, J.S. and Laitman, J.T. (2000) From the beach to the bench: Research on mysticete larynges and comparisons with those of odontocetes. Proceedings of the 17th Annual Northeast Region Stranding Conference, May 20 to May 23, 1999, Baltimore, Maryland. p.38, plus "Notes from the presentation."
3. Reidenberg, J.S. and Laitman, J.T. (2000) The mystery of the odontocete larynx. Feature Article, *Upwellings*, Pacific Cetacean Group Newsletter, pp.1,6-8.
4. Ketten, D., S. Cramer, J. Trehey O'Malley, I. Fischer, J. Reidenberg, V. Naples, S. McCall, J. Craig, R. Tussing, K. Rye, W. Lewis, C. Potter, J. Ososky, and C. Merigo (2001) Experimental measures of blast trauma in marine mammals. Biennial Conference on the Biology of Marine Mammals, 14:114-115.
5. Reidenberg, J.S. and Laitman, J.T. (2001) Prenatal development in cetaceans. In: *Encyclopedia of Marine Mammals*, W.F. Perrin, B. Wursig, and H.G.M. Thewissen (eds.), Academic Press, San Diego, pp. 998-1007.
6. Reidenberg, J.S. and Laitman, J.T. (2002) The New Face of Gross Anatomy. *The New Anatomist*, 269:81-88.
7. Som, P.M., Smoker, W.R., Curtin, H.D., Reidenberg, J.S., and Laitman, J.T. (2002) Embryology and Anatomy of the Neck. In: *Head and Neck Imaging*, 4th Edition. P.M. Som and H.D. Curtin (eds.), Mosby, New York, p.1757-1804.
8. Ketten, D., Arruda, J., Cramer, S., O'Malley, J., Reidenberg, J., McCall, S., Naples, V., Craig, J. (2003) Experimental measures of blast trauma in marine mammals. Symposium on Environmental Consequences of Underwater Sound, Office of Naval Research, San Antonio, TX, p.30 (abstract on ONR website)
9. Reidenberg, J.S. and Laitman, J.T. (2003) Appearance of odontocete respiratory tissues after exposure to blast pressures. Symposium on Environmental Consequences of Underwater Sound, Office of Naval Research, San Antonio, TX, p.30 (abstract on ONR website).
10. Reidenberg, J.S., Ketten, D.R., and Laitman, J.T. (2003) Effect of blast derived shock waves on the appearance of odontocete respiratory tissues. Biennial Conf. Biol. Marine Mammals, 15:136.
11. Reidenberg, J.S., Ketten, D.R., and Laitman, J.T. (2004) Effects of blast pressure exposures on the dolphin and porpoise larynx. American Association of Anatomists: Experimental Biology Meeting, FASEB Journal, p.A33 (abstract also published on CD-ROM).

APPENDIX of FIGURES

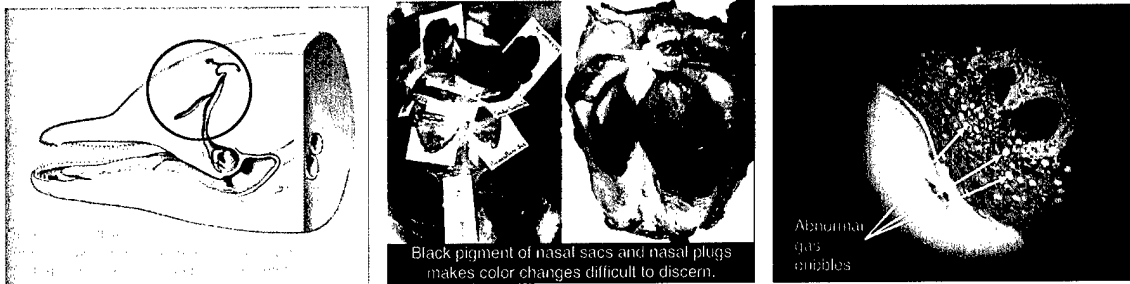


Figure 1: dolphin nasal region (circle, left image), dorsal view of nasal air sacs in situ and ventral view of excised nasal plugs (center image), and light microscopy of the nasal mucosa (right image). Note red discoloration of the nasal sacs and plugs in regions with no black pigment, and abnormal presence of gas bubbles in the histology section.

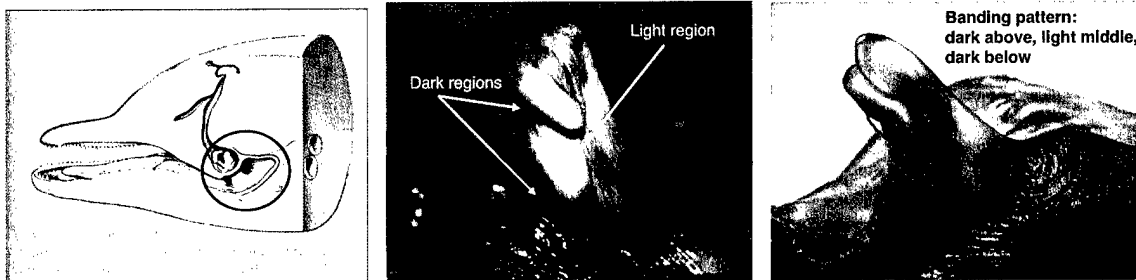


Figure 2: dolphin laryngeal region (circle, left image), and lateral view of two dolphin larynges (center and right images). Note discrete patches of red discoloration in the superior and inferior regions, and the lighter coloration in the middle. The dark color may indicate blast injury or pooled blood. The lighter region corresponds to the area covered by the palatopharyngeal sphincter, which may mask blast damage. This may be due to the tight coupling of the larynx and sphincter, sealing out any gas from this space.

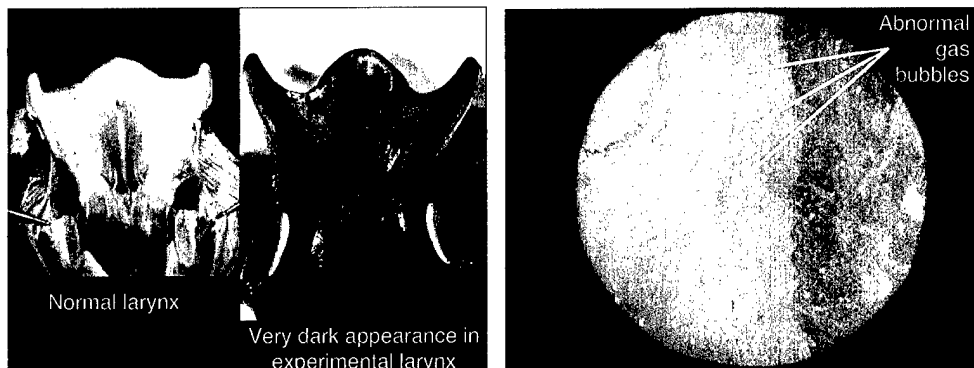


Figure 3: comparison between normal (far-left image) and experimental (middle-left image) larynges that have been opened dorsally in the midline, and a light microscopy

section of pharyngeal tissue (right image) from an experimental specimen. Note the dramatic color difference between the light normal and the dark experimental larynx, and the abnormal presence of gas bubbles in the histological section. (The normal specimen was from our own collection, and thus was not exposed to blast pressure.)

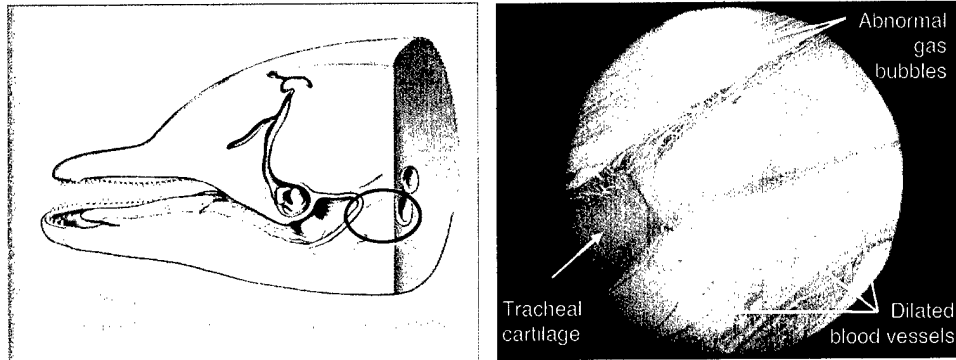


Figure 4: dolphin tracheal region (circle, left image), and light microscopy section of tracheal tissue (right image). Note the abnormal presence of gas bubbles and the greatly dilated vasculature in the histological section. This unusual vasculature may be erectile tissue blood sinuses, and could be an adaptation to diving that accommodates for gas volume loss in closed respiratory spaces at high pressure, thereby protecting them from collapse.

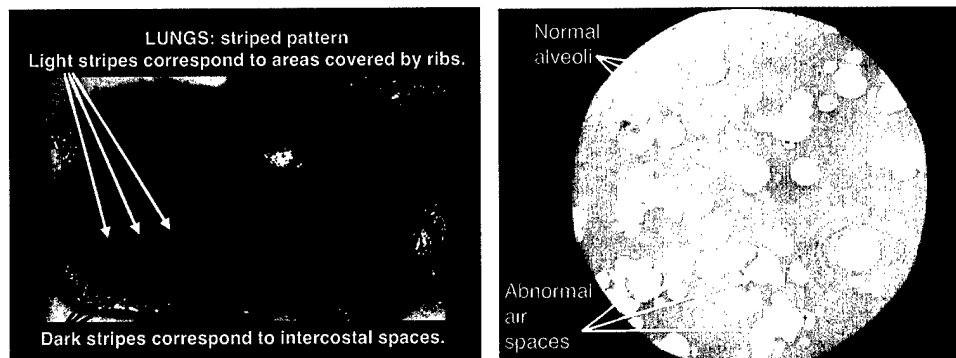


Figure 5: lung exhibiting a striped pattern (left image), and histological section of lung tissue (right image). The dark stripes on the lung were found to correspond to the intercostal spaces. This may indicate that the rib bones may shield the lung from blast damage, or blast pressures are more readily transferred through soft tissues than bones. Alternatively, the flexibility of the intercostal spaces also permits more extensive lung expansion during the rarefactive part of the blast pressure wave, perhaps causing undue stretch and tissue damage or enabling expanding gas to accumulate in the underlying lung tissue.