

AD _____

Award Number: DAMD17-00-1-0597

TITLE: A New Perspective on DCIS Using MRI: Correlation of
Tumor and Vessel Proliferation with MR Signal Enhancement

PRINCIPAL INVESTIGATOR: Laura J. Esserman, M.D.

CONTRACTING ORGANIZATION: The University of California
San Francisco, California 94143-0962

REPORT DATE: April 2004

TYPE OF REPORT: Final

PREPARED FOR: U.S. Army Medical Research and Materiel Command
Fort Detrick, Maryland 21702-5012

DISTRIBUTION STATEMENT: Approved for Public Release;
Distribution Unlimited

The views, opinions and/or findings contained in this report are those of the author(s) and should not be construed as an official Department of the Army position, policy or decision unless so designated by other documentation.

20040907 026

REPORT DOCUMENTATION PAGE

Form Approved
OMB No. 074-0188

Public reporting burden for this collection of information is estimated to average 1 hour per response, including the time for reviewing instructions, searching existing data sources, gathering and maintaining the data needed, and completing and reviewing this collection of information. Send comments regarding this burden estimate or any other aspect of this collection of information, including suggestions for reducing this burden to Washington Headquarters Services, Directorate for Information Operations and Reports, 1215 Jefferson Davis Highway, Suite 1204, Arlington, VA 22202-4302, and to the Office of Management and Budget, Paperwork Reduction Project (0704-0188), Washington, DC 20503

1. AGENCY USE ONLY (Leave blank)		2. REPORT DATE April 2004	3. REPORT TYPE AND DATES COVERED Final (1 Oct 2000 - 31 Mar 2004)	
4. TITLE AND SUBTITLE A New Perspective on DCIS Using MRI: Correlation of Tumor and Vessel Proliferation with MR Signal Enhancement			5. FUNDING NUMBERS DAMD17-00-1-0597	
6. AUTHOR(S) Laura J. Esserman, M.D.				
7. PERFORMING ORGANIZATION NAME(S) AND ADDRESS(ES) The University of California San Francisco, California 94143-0962 <i>E-Mail:</i> laura.esserman@ucsfmedctr.org			8. PERFORMING ORGANIZATION REPORT NUMBER	
9. SPONSORING / MONITORING AGENCY NAME(S) AND ADDRESS(ES) U.S. Army Medical Research and Materiel Command Fort Detrick, Maryland 21702-5012			10. SPONSORING / MONITORING AGENCY REPORT NUMBER	
11. SUPPLEMENTARY NOTES				
12a. DISTRIBUTION / AVAILABILITY STATEMENT Approved for Public Release; Distribution Unlimited			12b. DISTRIBUTION CODE	
13. ABSTRACT (Maximum 200 Words) The purpose of our study was to determine whether MRI features could distinguish biologic characteristics of DCIS. We identified 100 patients at USCF who had a diagnosis of DCIS and underwent MRI scanning prior to definitive surgery. 66 scans were evaluable on PACS and characterized by enhancement patterns, density of lesion, extent of breast involved, dynamic pattern, and size. MRI enhancement characteristics were correlated with pathology characteristics (70 cases) and immunohistochemical markers of proliferation, angiogenesis, and inflammation to assess the value of MRI as a non-invasive, surrogate marker. 57 patients had sufficient tissue for immunohistochemistry analysis. Size, as measured by MRI and pathology, were significantly correlated (0.001). Considering the imprecise nature of measuring the physical size of DCIS lesions, the demonstrated correlation is remarkable, and certainly far better than mammography. We expected that markers of angiogenesis, proliferation, and inflammation would be distinguishable by MR. However, angiogenesis (CD34) did not correlate with any MRI characteristics, or with nuclear grade. In contrast, the inflammatory marker, CD68, strongly correlated with all of the DCIS markers known to be associated with bad outcomes (higher progression rates), including lesion size (on both MRI and pathology), extensive comedonecrosis, high nuclear grade, and the percent of breast involved on MRI (0.001), and MR size (0.01), and regional enhancement pattern. Interestingly, CD68 was also correlated with MRI density (0.001), the measure of a lesion's enhancement concentration developed specifically for this study. Ki67 was correlated with MR wash-out and enhancement patterns. The patterns of MRI enhancement suggest the type of DCIS present—very small focal masses were most likely to be ER positive, whereas regional/multi-regional had a lower ER score, higher grade, much higher CD68 count and extensive comedonecrosis. MR can be used to approximate size of DCIS lesions and patterns of enhancement predict biological features.				
14. SUBJECT TERMS Ductal carcinoma in situ (DCIS), MRI			15. NUMBER OF PAGES 34	
			16. PRICE CODE	
17. SECURITY CLASSIFICATION OF REPORT Unclassified	18. SECURITY CLASSIFICATION OF THIS PAGE Unclassified	19. SECURITY CLASSIFICATION OF ABSTRACT Unclassified	20. LIMITATION OF ABSTRACT Unlimited	

Table of Contents

Cover.....	1
SF 298.....	2
Table of Contents.....	3
Introduction.....	4
Body.....	4
Key Research Accomplishments.....	18
Reportable Outcomes.....	19
Conclusions.....	19
References.....	21
Appendices.....	24

Introduction

The purpose of this study is to correlate breast MR contrast enhancement patterns and density with pathology characteristics and markers of proliferation, angiogenesis, and inflammation in women with ductal carcinoma in situ (DCIS) of the breast. The specific aims of the study are two-fold: 1) to characterize the proliferative, inflammatory, and angiogenic activity of DCIS lesions and 2) Correlate pathologic features of DCIS with MRI characteristics. Our reason for correlating the angiogenic, inflammatory, and proliferative profile with MRI characteristics was to determine whether MR can predict the biological characteristics of DCIS, and thus potentially serve as a surrogate marker of biological behavior. If a non-invasive test such as MRI can help us to characterize DCIS lesions prior to surgical excision, then MR could serve as a predictor of the likelihood and rate for transformation of DCIS to invasive cancer. MRI might serve as a catalyst to help us find more optimal ways to treat DCIS, by providing a tool for measuring size and response to therapy in a neoadjuvant type setting.

We include a description of the project and show the data that was correlated at a significance of $p < 0.05$

Body

Specific Aim 1: Stain a series of 90 DCIS lesions and 20 non-malignant controls with proliferative, epithelial, endothelial and stromal markers.

Accomplishments:

- We have obtained informed consent from 13 patients with a diagnosis of ductal carcinoma in situ (DCIS) who have had an MRI prior to definitive surgery.
- We obtained a waiver of informed consent to analyze samples and MR images from patients who had a preoperative MRI for a diagnosis of DCIS.
- We completed review of 70/100 pathological slides and 57/100 slides stained with each of the selected immunohistochemical markers (Ki67, ER, CD34, CD68). The remaining cases have been withdrawn from the study because of the unavailability of the necessary tissue blocks to complete our pathological and immunohistochemical analyses. These tissue blocks were unavailable because either there was not enough tissue remaining after the diagnostic pathological review to complete a full immunohistochemical review, there was not enough tissue remaining because of the sectioning of tissue slides for other research studies, or because the tissue blocks were currently being held by the investigators of various other research studies that were analyzing the same cases.

Task 1.1: Create a database of 75 patients with DCIS which includes details of physical findings and mammographic presentation.

- We have created a database of 100 patients with DCIS where tissue blocks and MRIs were available. 45 cases include complete information on MRI, pathology, and immunohistochemistry. This database of 45 complete cases was utilized to generate the data in this report, and is included as APPENDIX A. The database includes: MRI size, pathology size, nuclear grade, presence and extent of comedonecrosis, predominant histological type, MRI density, Pathology density, percentage of breast

involved according to MRI, dynamic MRI characteristics, pattern of MRI enhancement, Ki67 score, CD68 score, CD34 score, and ER Score. 30 cases were excluded because tissue blocks were not available; 34 cases were eliminated because their MRI was performed over three years ago and the films were not available on PACS (Picture, Archive, and Communication System-UCSF's imaging database). We required that all films be reviewed on PACS so that the information would be comparable across cases. 13 cases were not included because either their tissue blocks were not available for immunohistochemical staining, there was not enough tissue remaining to stain, or the tissue staining process was unsuccessful (the tissue folded or fell off the slide). A single radiologist reviewed all of the films (Dr. Jessica Leung), a single pathologist reviewed all of the pathology cases (Dr. Yunn-Yi Chen), and a single pathologist reviewed all of the immunohistochemical stains (Dr. Alfred Au). Data sheets were created to collect all of the variables. (SEE APPENDIX C to review the pathology and radiology data sheets). All data elements were put into an excel spread sheet, and a master database was created.

	Reviewed	Unavailable	Total Cases
MRI	66	34	100
Pathology	70	30	100
Immunohistochemistry	57	43	100
Complete MRI, Path, IHC	45	-	-

We were only able to get all of the stains on 45 of the cases, but included data on all cases where MR read was complete for the data base.

Task 1.2: Identify 10 non-malignant controls that do not enhance like cancer and 10 malignant lesions that enhance on MR.

- We identified 16 false positive cases, as we felt that this would give us the most insight to what makes MRI lesions enhance. We also selected 5 samples of benign breast tissue as an internal control to compare against these false positives.
- The pathological and MRI analyses of these “false positives” showed a similar range for staining by proliferative, angiogenic, and inflammatory markers, although the average of the false positives is clearly lower than the DCIS cases. However, the immunohistochemical analysis of the false positive cases revealed the relatively high vascularity, proliferative rates, and inflammation relative to benign breast tissue that does not enhance. This may account for these benign cases enhancing like cancer on MR.

Tissue Type	Ki67 (% Epithelial Staining)	CD68 (Tumor-associated Macrophages)	CD34 (Microvessel Count)	ER (Intensity Score)
Benign Tissue Mean	1.6	1.9	12.9	3.6
Benign Tissue Median	2.0	2.3	13.0	2.0
False Positive Mean	15.1	20.5	48.8	1.9
False Positive Median	19.3	14.3	39.6	2
DCIS Mean	28.1	44.1	69.1	3.5

DCIS Median	22.8	30	65	4
-------------	------	----	----	---

Table 1: The false positive cases have high vascularity, inflammation, and proliferative rates compared to benign breast tissue, but significantly lower values than malignant DCIS cases.

Task 1.3: Review all pathology in terms of grade, extent, size and patterns of tumor vessels by H&E.

- We have completed review of all of the available pathology slides (70/100) under the current lead pathologist, Dr. Yunni Chen, with the help of clinical pathologist, Dr. Alfred Au. (for data sheet, see Appendix C)

Task 1.4: Stain tumor specimens using CD 34 and CD 105 in order to highlight vascularity of tumor lesions.

- A comparison of CD 34 and CD 31 was performed and CD 34 was chosen due to its comparable degree of sensitivity and the fact that it produces less background staining noise.
- CD 105 had been chosen as a potential stain since it was reported as being expressed primarily in vessels characteristic of tumors. However, there is limited tissue available for DCIS and we stained the first 10 cases with both and made a choice of stains after reviewing the first cases. Because of the similarity of the CD34 and CD105 stains, and because CD34 appeared to be more robust as an immunohistochemical stain, the CD105 stains were not performed after the initial 10 cases.

Task 1.5: Add serial section stain and dual stain with proliferative markers to elucidate which areas of tumor are proliferating.

- We chose serial section stains rather than dual stains with proliferative markers (Ki67, cytokeratin, and MCM2) to elucidate whether tumor, epithelial, or endothelial areas are proliferating. The double staining methods added confusion rather than clarity. Out of 57 total Ki67 stains, all 57 had staining in the epithelial cells, and only 7 had stromal staining. Thus, the epithelial cells were the ones proliferating, not the stroma.
- The MCM2 stain was considered because, at the time, it was reported to be a more specific stain of proliferative activity. Again, after 10 cases, we did not see a difference between Ki67 and MCM2, and therefore continued with Ki67 staining since it is the more accepted standard marker of proliferation.

Task 1.6: Compare proliferative patterns of tumor and blood vessels and correlate to grade, extent, and Her2/neu markers.

- Because Her2/neu markers have been shown to have a strong correlation with high nuclear grade and extensive comedonecrosis, and tissue was limited, we instead chose to include an inflammatory marker, CD68 (which stains tissue macrophages), since inflammation is thought to be one of the tissue parameters that cause enhancement on MR. There is increasing interest in inflammatory causes of cancer development and promotion and attention is being directed toward identifying and testing agents that are directed toward inflammatory pathways. The Principle Investigator (Dr. Esserman) is developing a protocol to test statins for their activity in altering DCIS lesions. There are a number of mechanisms by which statins exert their cardiovascular and vascular preventive effects, including cholesterol reduction and C-reactive protein reduction (an inflammatory marker), and a recent article (JAMA

MARCH 2004), suggests that reduction in C-reactive protein may be a better predictor of benefit than change in cholesterol.

- The CD68 inflammation data demonstrated the most interesting and significant correlations with pathological and MRI markers. High levels of inflammation were associated with extensive comedonecrosis (Figure 1), large-sized lesions as determined by both MRI (Figure 2) and pathology, ER negative lesions (Figure 3), the percentage of breast involving DCIS on MR (Figure 4), MR density (Figure 5), and pathology density (Figure 6).

Comedonecrosis vs. CD68

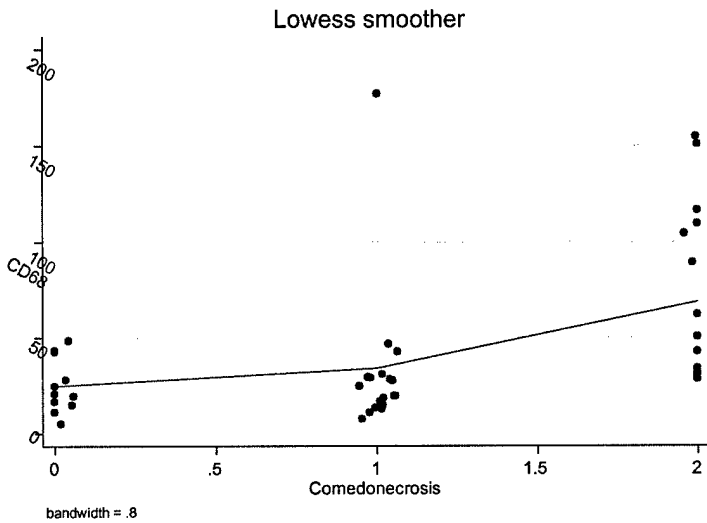


Figure 1: High levels of inflammation correlate with Extensive Comedonecrosis (0 = no comedo, 1 = focal comedo, 2 = extensive comedo)

MR Size vs. CD68

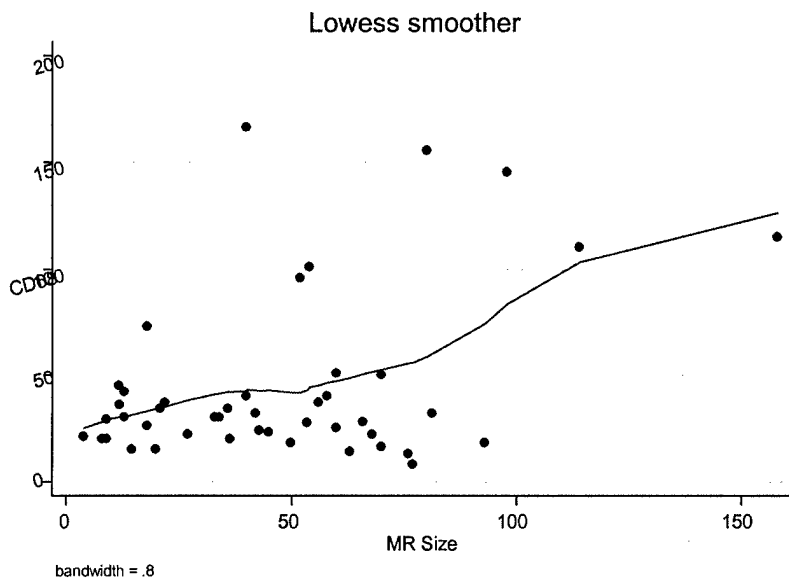


Figure 2: CD68 correlates with MR Size

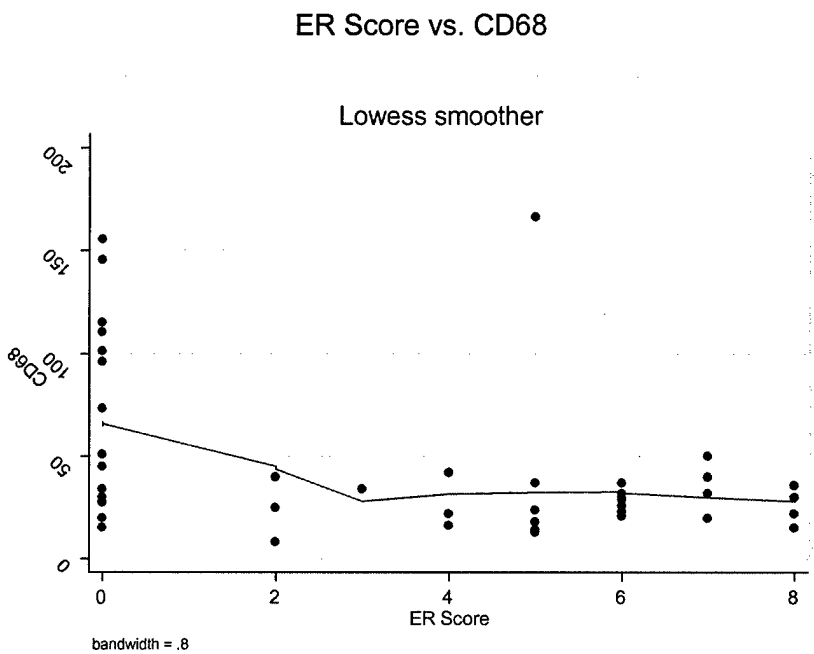


Figure 3: High inflammation correlates with ER negativity.

% Breast Involving DCIS vs. CD68

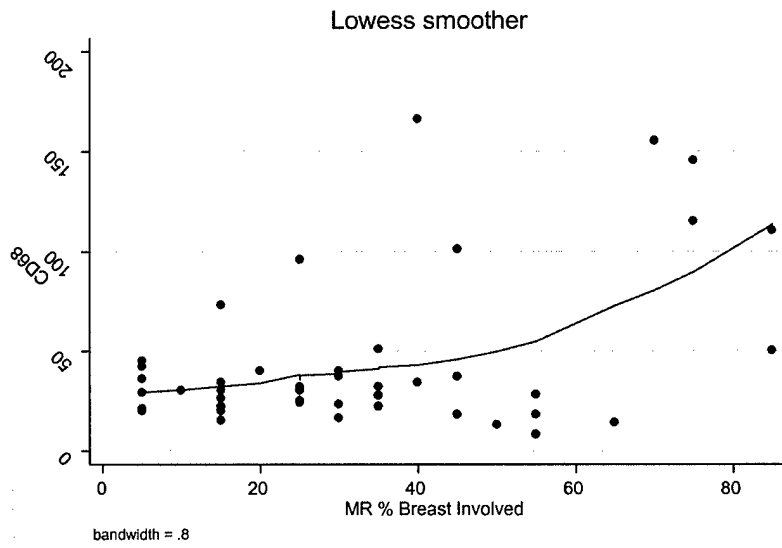


Figure 4: CD68 correlates with Percentage of Breast Involving DCIS on MR.

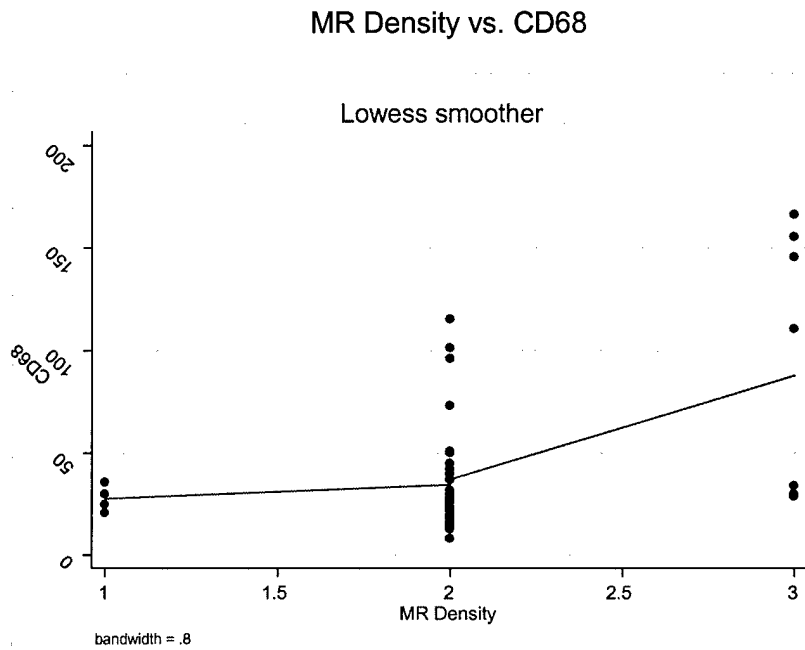


Figure 5: CD68 correlates very well with MR Density

Pathology Density vs. CD68

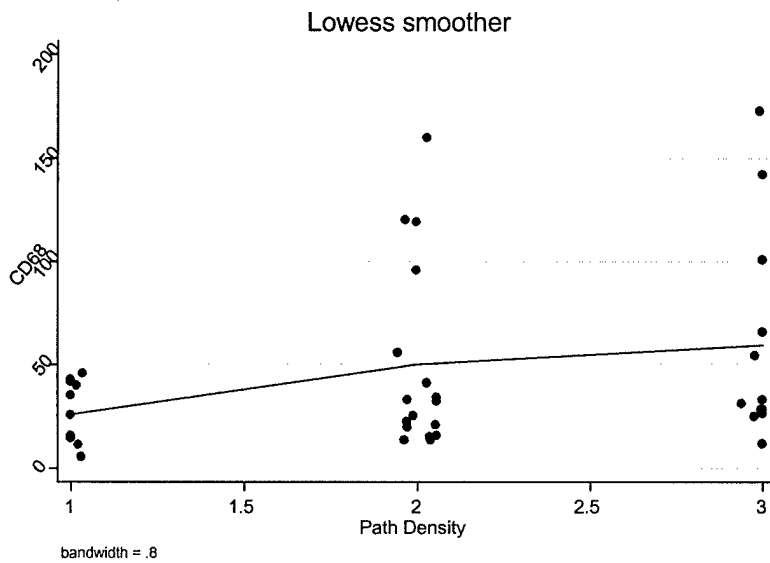


Figure 6: CD68 correlates with pathology density.

Task 1.7: Identify stromal marker to elucidate involvement of stromal cells in tumor lesions.

- We have not yet identified reliable markers for stromal elements that would identify tumor associated fibroblasts. Candidate stains include CD44 and SMA 1 & 2, but data on larger more robust data sets have not shown that these stains are reliable for identifying stromal elements likely to promote tumor growth. This is obviously an important area for further research.

Specific Aim 2: Create a tissue array from DCIS cases to see if this technique can be used to capture the same data described in Specific Aim 1.

Task 2.1: Create tissue array composed of plugs from identified tissue blocks.

- It was determined that the creation of DCIS tissue arrays would simply waste tissue and would not be more efficient. Many of the stains and aims of the study required that the patterns of staining be evaluated, and that the relationships among stroma, vessels be characterized. For example, we needed to determine the pattern of CD34 staining- peritumoral cuffing vs. scattered throughout the tissue. The tissue arrays only allow a small core diameter of tumor tissue to be included, therefore, we elected not to make arrays, and completed all the immunohistochemical stains individually.

Specific Aim 3: Define MRI Characteristics of DCIS

Task 3.1: Examine and compare all MR images; create a stratification and standards of patterns seen based on extent, density, and intensity of contrast enhancement of study cases.

- Size-To measure the size of each DCIS lesion on MR, we used the composite three dimensional view (maximum intensity projections). Using this view, three different lesion measurements were obtained, including an anterior-posterior

measurement, a cranial-caudal measurement, and a transverse measurement. For the data analysis, the largest measured lesion diameter among the three views/measurement was utilized.

- Dynamic Characteristics-The dynamic MR characteristics of the DCIS lesions were measured by using a three time point technique. MR images are acquired prior to intravenous contrast (gadolinium), immediately after contrast (2 minutes), and at one more time point (8 minutes). This technique allows a kinetic assessment of contrast enhancement and is well described in the literature (Hylton). A 1.5 Tesla scanner was used for all scans. The lesions were identified as exhibiting progressive enhancement, washout enhancement, or plateau enhancement. Progressive enhancement is characterized by a gradual increase in signal intensity, with the final image of the sequence enhancing the brightest. Washout enhancement is denoted by a peak enhancement intensity in the middle of the time-lapse sequence, and then a decreased enhancement intensity in the final image. Plateau enhancement is characterized by a rapid increase of signal intensity over the initial image sequences, and then the stabilization and maintenance of that peak signal intensity for the remainder of the sequences.
- Enhancement Pattern-In an attempt to capture the variation in MR patterns, morphology observed when imaging DCIS lesions, the DCIS lesions were separated into four main categories: focal mass; diffuse enhancement, ductal or segmental enhancement; and regional or multi-regional enhancement. A lesion was characterized as a focal mass if it appeared on MR as one singular focus of enhancement, regardless of size. Lesions that were classified as diffuse enhancement demonstrated a random enhancement distribution throughout the breast. Lesions that exhibited ductal or segmental enhancement were those that did not have a clear focal center, but instead demonstrated a pattern of enhancement that appeared to linearly enhance as if tracing the pattern of a duct (often exhibiting the branching qualities of a duct) or exhibited a triangular region of enhancement with the apex pointed towards the nipple, enhancing in a distribution suggesting a duct and its branches. Regionally or multi-regionally enhanced lesions were those that enhanced in a large volume of tissue not conforming to a ductal distribution in one or more quadrants of the breast.

MR Enhancement Pattern	Average Size of Lesions on MR (mm)
Focal Mass	10.0
Ductal/Segmental Enhancement	37.5
Regional/Multi-Regional Enhancement	50.8
Diffuse Enhancement	71.3

Table 2: The average size of lesions on MR separated by MR enhancement pattern.

- Percentage of Breast Involving DCIS-A visual measure of the percentage of breast tissue occupied by the DCIS, assessed by Dr. Jessica Leung, utilizing the three-dimensional features of the digital MRI images. For these cases, the summary projection views were used to estimate extent of breast involved.
- Density-It was not feasible to create a quantitative pixel measure that would elucidate contrast enhancement density on MR, though Dr. Hylton will continue her efforts to develop such a measurement. As a result, a visual 3-point MR and

pathology density categorization was created through the collaboration of Dr. Laura Esserman, Dr. Nola Hylton, Dr. Yunn-yi Chen and Dr. Jessica Leung. The visual density measure stratified lesions on both MR and pathology into three score categories, with a score of 1 (Low density) denoting sparse, stippled enhancement; a score of 2 (Medium density) indicating clumped enhancement; and a score of 3 (High density) representing solid, mass-like enhancement. (See APPENDIX B for an illustrated schema of the density criteria used by the pathologist and radiologist) Unfortunately, because of the qualitative nature of such a measurement, and the difficulty that often arose without any quantitative criteria of distinguishing between borderline cases, the majority of the cases were designated an MR density score of 2. This made it difficult to produce meaningful correlations with the rest of the data, though MR density according to our 3-point categorization did demonstrate a significant correlation with the inflammatory marker, CD68, see Figure 1 above.

- We have completed review of 66/100 MR images, characterizing them by contrast enhancement density, size, percentage of breast involving DCIS, contrast enhancement pattern/morphological type, and the dynamic characteristics of the contrast enhancement. The remainder of the MR images have not been transferred to the Picture Archive and Communication System (PACS) system and therefore were not evaluated, as films and PACS views are not comparable.
- **Task 3.2: Categorize each image according to these patterns of extent, density, SER, and imaging phenotype.**
- The lesions were characterized as described as above. Signal Enhancement Ratio (SER) was not applicable to the overwhelming majority of DCIS lesions because SER requires that a lesion be primarily solid to be accurate. The technique is one of volume averaging, and the nature of DCIS lesions is that the enhancement pattern is scattered throughout the tissue. It was determined that SER would not be helpful or appropriate for DCIS lesions.

Specific Aim 4: Investigate associations between MR, proliferative markers, and standard pathologic prognostic features.

Task 4.1: Correlate MRI characteristics to pathologic and proliferative characteristics identified in Specific Aim 1.

- Upon completion of the data set, we correlated various MRI characteristics that were captured in our data set—MR Size, MR Density, Percentage of Breast Involving DCIS, MR Enhancement Type, and MR Dynamic Characteristics—with the pathological, proliferative, angiogenesis, and inflammatory characteristics identified in Specific Aim 1.
- MR Size correlated with percent of breast involving DCIS on MR ($p < 0.0001$), which is expected. MR size correlated well with pathology size ($p < 0.001$), which is remarkable considering the difficulty and, therefore, imprecise nature of measuring DCIS. This correlation establishes MR as an accurate, and perhaps preferred method of determining lesion size. MR size was also associated with high levels of inflammation ($p = 0.01$).

MR Size vs. Pathology Size

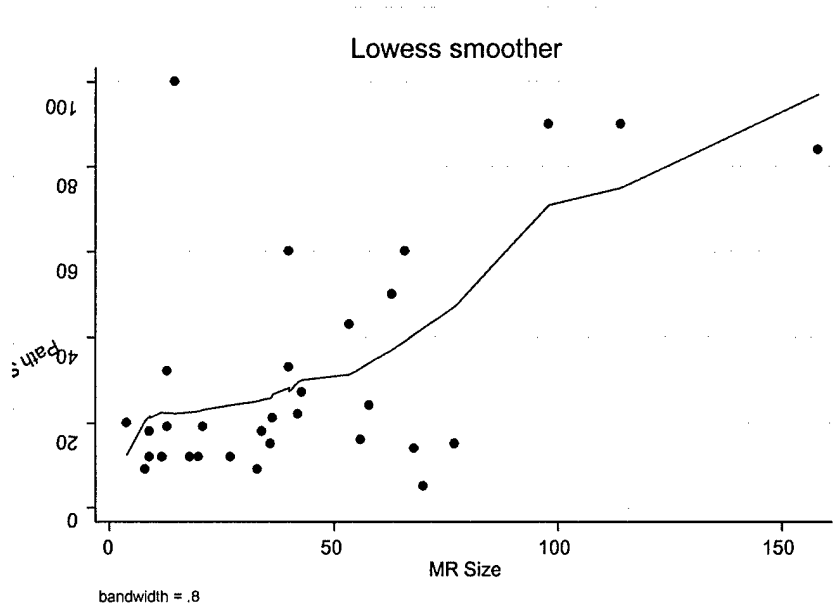


Figure 7: MR Size correlates well with pathology size.

MR Size vs. CD68

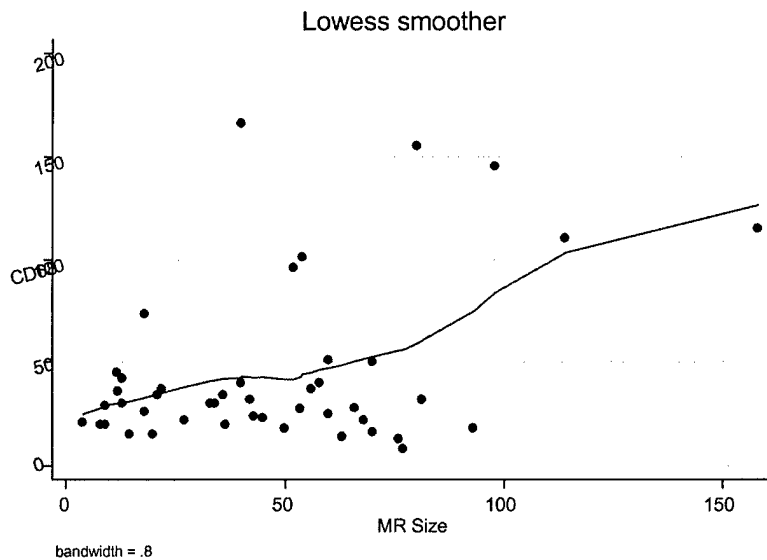


Figure 8: MR Size correlates with inflammation.

- MR Dynamic Characteristics (particularly “Washout” enhancement, which has been associated with poor prognosis in DCIS) failed to demonstrate correlations with the majority of the pathological or immunohistochemical characteristics. The one marker that did correlate with washout enhancement was high levels of proliferation (See Figure 11), which reinforces the idea that proliferation is an important parameter for causing MR enhancement.
- Despite the difficulty in establishing a quantitative pixel/density measurement, MR density demonstrated meaningful correlations with certain pathological and immunohistochemical characteristics. MR density was well correlated with pathology density ($p=0.001$). Density on pathology measures the percent of a high powered field that is involved with DCIS. When the ducts involved with DCIS are numerous and close together, one sees a corresponding increase in the density of enhancement on the MR image. In addition, when MR density was high, inflammation (the number of tumor-associated macrophages) was also high.
- The MR Enhancement pattern was correlated well with nuclear grade (Figure 9) and proliferation (Figure 10). Table 3 compares the average immunohistochemical stain scores of each MR Enhancement pattern category to the average scores of the entire DCIS data set, the false positive cases, and the benign tissue cases.

Table 3: Average immunohistochemical markers separated by tissue type and MR category. An asterisk (*) denotes a statistically significant correlation.

Tissue/MR Category mean values	Ki67 (% Epithelial Staining)	CD68 (Macrophages)	CD34 (Microvessel Count)	ER (Intensity Score)	MR Size (mm)
Benign Tissue	1.6	1.9	12.9	3.6	N/A
False Positive	15.1	20.5	48.8	1.9	31.9
DCIS	28.1	44.1	69.1	3.5	46.5
Focal MR Enhancement	11.9*	26.3	59.3	4.7	10.0
Diffuse MR Enhancement	19.3*	45.3	44.1	2.8	71.3
Ductal/Segmental MR Enhancement	32.3*	33.4	76.0	3.7	37.5
Regional/Multi-Regional MR Enhancement	31.0*	54.9	75.7	3.5	50.8

MR Enhancement vs. Nuclear Grade

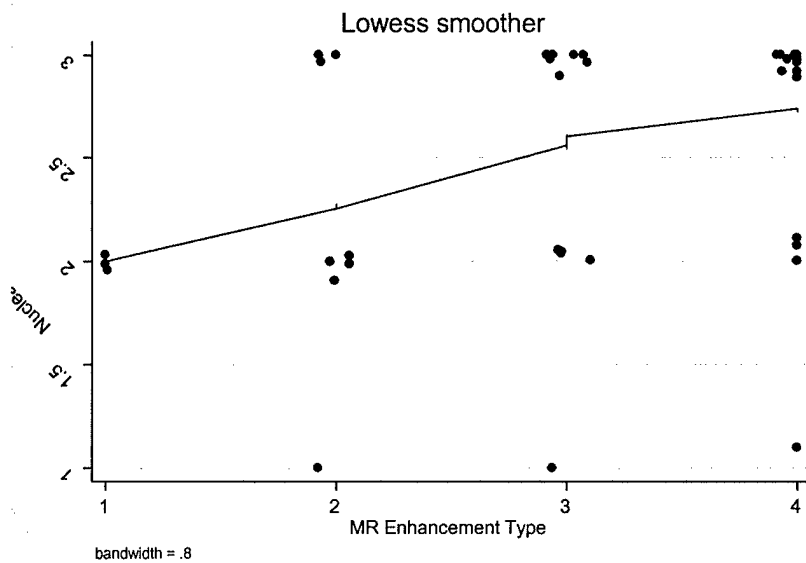


Figure 9: Ductal/Segmental lesions and Regional/Multi-regional lesions correspond with high nuclear grade

MR Enhancement Type vs. Ki67 % Epithelial Staining

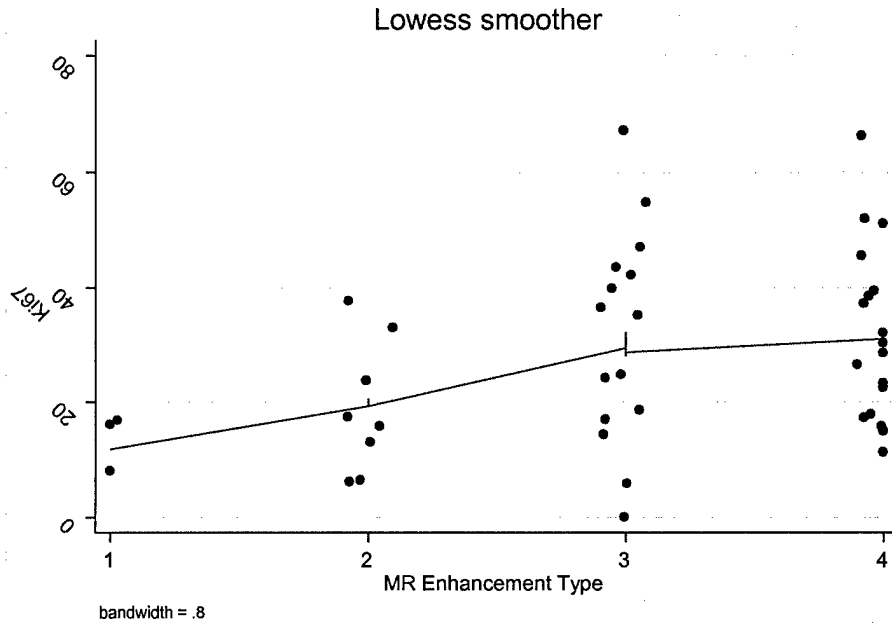


Figure 10: Ductal/Segmental lesions and Regional/Multi-regional lesions correspond to high proliferative rates

Task 4.2: Determine if proliferative activity is associated with standard prognostic features alone.

- The Ki67 proliferation data was highly variable, with the percentage of epithelial proliferation displaying a wide range of values over the entire data set. Despite this variability, the Ki67 proliferation demonstrated that high proliferative rates are associated with ER negativity (p value=0.03), DCIS lesions that exhibit washout on MR (Figure 11), as well as DCIS lesions that have ductal/segmental or regional/multi-regional enhancement on MR (See Figure 10 above). High proliferative rates were also associated, to some extent, with extensive comedonecrosis, but the correlation was not strong enough to be statistically significant. Although the Ki67 data exhibited these correlations, the lack of correlation with other standard prognostic features prevents us from making a determination about whether proliferative activity is a property of grade and/or size, or whether it is a biological parameter which might independently act as a trigger point for progression.

MR Washout vs. Ki67 % Epithelial Staining

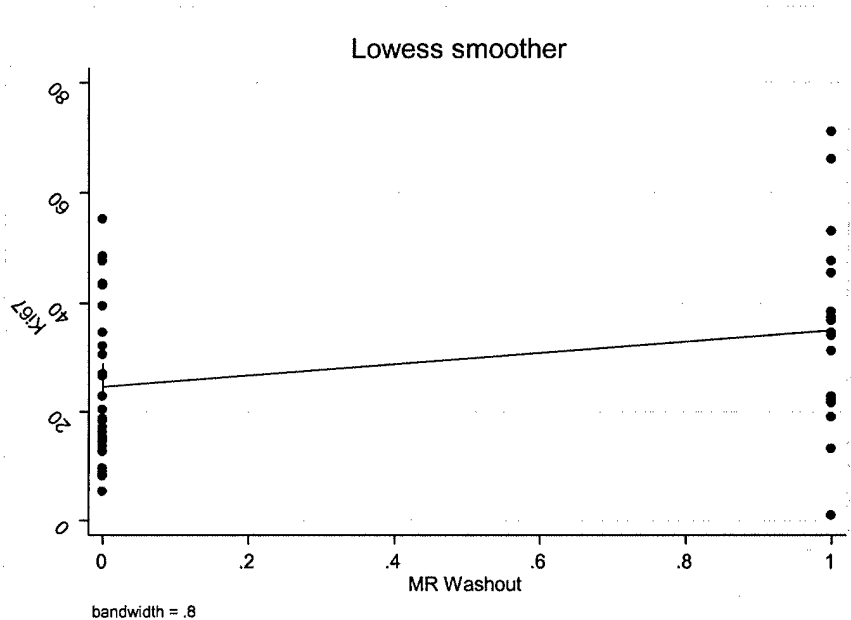


Figure 11: High proliferation rates are correlated with Washout (0 = No washout, 1 = Washout present) on MR.

- There were other significant correlations that did not involve the MR characteristics, but were either interesting or important in establishing the validity of our data set. The most important of these was the correlation between high nuclear grade and comedonecrosis (Figure 12), which has been proven in other data sets and is known to correspond to poor prognosis in women with DCIS. This correlation demonstrates the validity of our data.

Nuclear Grade vs. Comedonecrosis

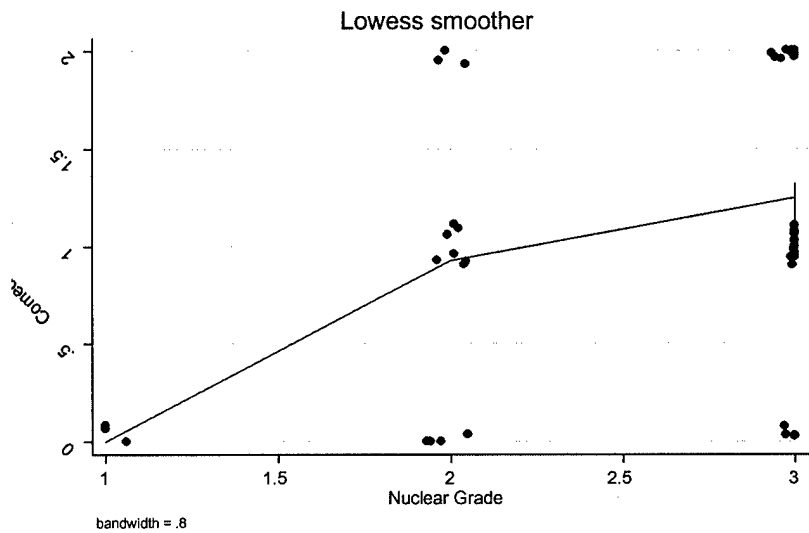


Figure 12: Extent of comedonecrosis (0 = no comedo, 1 = focal comedo, 2 = extensive comedo) increases with nuclear grade.

Tissue/Pathology Category	Ki67 (% Epithelial Staining)	CD68 (Macrophages)	CD34 (Microvessel Count)	ER (Intensity Score)	MR Size (mm)
Benign Tissue Mean	1.6	1.9	12.9	3.6	N/A
False Positive	15.1	20.5	48.8	1.9	31.9
DCIS	28.1	44.1	69.1	3.5	46.5
Low/Intermediate Grade	19.9	32.6	61.0	4.9	40.2
High Grade	33.0	51.1	74.0	2.6	50.4
Extensive Comedo	34.0	68.6*	65.4	2.3	59.6

Table 4: Immunohistochemical stains separated by tissue type and nuclear grade. An asterisk (*) denotes a statistically significant correlation.

Key Research Accomplishments

- Established correlation between lesion size on MR and pathologically-measured size, demonstrating that MRI is a relatively accurate, non-invasive method of determining the size of a DCIS lesion. In further support of this, we established a correlation between our own visual measure of MR density and pathology density.
- High proliferative rates correlated with certain MR enhancement patterns, MR washout ($p=0.03$), and ER negativity ($p=0.03$).
- Established correlation between inflammation and both MR and pathology size, inflammation and MR density, inflammation and percentage of breast involving DCIS on MR, inflammation and extensive comedonecrosis, inflammation and ER negativity as well as a loose correlation between inflammation and high nuclear grade.

- Based on this correlation, we suggest the possibility that inflammation may be an biological parameter. Because macrophages are associated with DCIS that has the characteristics most strongly associated with disease progression, we believe that this association should be pursued both from an etiologic standpoint as well as a therapeutic standpoint.

Reportable Outcomes

We will be completing a manuscript by May 2004 and submitting an abstract for the 2004 San Antonio Breast Cancer Symposium. In addition, we have completed a comprehensive database of 45 DCIS patients (we intend to continue working over the next month to raise the number of completed cases to at least 60) that includes detailed histopathological, MR, and immunohistochemical data, as well as the type of surgery each patient chose, and their age at diagnosis. Furthermore, we have collected a repository of histopathological, MR, an immunohistochemical samples that may be reevaluated and reanalyzed at a future date.

Conclusions

MRI has significant potential as a noninvasive tool to characterize DCIS . It correlates fairly well with size as measured by pathology, and the density of the lesion on MR images correlates with the density of the lesion by light microscopy (% of high power field that is involved with DCIS). We used several biologic markers to characterize DCIS, including markers of proliferation (Ki-67), angiogenesis (CD-34), and inflammation (CD 68), as well as grade and extensive comedo necrosis, known markers of higher recurrence. We hypothesized that these markers might distinguish different DCIS patterns that could be identified using MRI. CD68 was remarkably well correlated with pathologic features of high grade, comedo lesions, that are extensive in size, i.e. features associated with high rates of progression and recurrence. The regional/multi-regional enhancement patterns were characterized by high CD 68 staining. Ki67 rates were higher in the ductal/segmental and regional enhancement lesions, which were also less likely to be ER positive. Suprisingly, CD 34 was not particularly helpful in distinguishing MR types or tumor grade or MR density or pathologic density.

MR enhancement types appear to give a picture of the kind of pathologic lesion present (Table 4). Small focal lesions tend to have low Ki67 rates, smaller overall size, and higher ER staining, whereas the regional lesions have the lowest average ER score, the most CD68, and highest proliferative rates. Efforts to refine the enhancement types need to continue, and it appears that the diffuse enhancement pattern is not a useful category and probably mixes biologic types.

Lesions that enhance on MRI but are not cancer, upon histologic examination, have higher proliferative, angiogenic rates and more inflammation (macrophages) than benign tissue, but lower values than DCIS. Clearly, these false positive lesions have properties like cancer but at lower mean values than DCIS lesions. Many of the false positive cases are benign proliferative processes that are associated with an increase in breast cancer risk (approximately 2 fold). Interestingly, DCIS lesions reflect a very high risk for breast cancer development (with a range of 3-10 fold), so it may be that MR enhancement and

characteristic increase in proliferation, angiogenesis and inflammation reflect breast cancer risk.

There are some limitations of the study. We did not have a very representative sample of low grade lesions. We were not able to automate MR total volume. Our future plans include completing review of the outstanding 10-15 cases. We plan to review the MR patterns of all of the high CD68 lesions to determine if there is a characteristic pattern that is now more distinguishable. We will then refine the MR enhancement categories, and have an independent reader categorize the MRs and repeat the analysis. We anticipate updating our review by the end of May, and hope to submit manuscripts by July of 2004.

This study is of great significance to the field of DCIS management. The ability to characterize DCIS more clearly prior to surgery affords us the opportunity to introduce neoadjuvant approaches to treating DCIS and to identify and test new agents for prevention. The ability to identify patients who have DCIS alone, and to characterize these patients who have very high risk for invasive breast cancer, and to assess the impact of interventions will be critical in moving forward the field of prevention. In particular, this may be our window of opportunity to identify and test agents that impact emerging ER negative disease. We are currently designing a multi-center prospective MRI study of DCIS patients who are going to be randomized pre-operatively to placebo vs 2 doses of statins for 2-3 weeks prior to definitive surgery. Because statins should affect inflammation, and are more effective in decreasing proliferation in ER negative cell lines, it will be very interesting to see if CD68 levels are changed by this intervention and whether the change is observable using MR imaging. Thus, the finding that high CD68 characterizes high grade comedo lesions which are identifiable non-invasively, is very exciting indeed. We are very grateful to have had the opportunity to perform this important work and intend to work to develop

Over the past 4 years, a number of people have been supported by this grant. The project was difficult and harder to accomplish than we anticipated but we were able to complete it using supplemental funding from the Breast Cancer Research Foundation.

People supported by this grant include:

- Laura Esserman (surgery)
- Nola Hylton (radiology)
- Shelley Hwang (surgery)
- Dan Sudilovsky (pathology)
- Alfred Au (pathology)
- Jennifer Hellowel (research assistant)
- Karen Kinkel (radiology)
- Kelly Adduci (senior research staff)
- Karen Chew (tissue bank, pathology)
- Yunn Yi Chen (pathology)
- Meaghan Shayhorn

References:

1. Ernster VL, Barclay J, Kerlikowske K, Grady D, Henderson C. Incidence of and treatment for ductal carcinoma in situ of the breast [see comments]. *Journal of the American Medical Association* 1996; 275:913-8.
2. Fisher ER, Constantino J, Fisher B, Palekar AS, Redmond C, Mamounas E. Pathologic findings from the National Surgical Adjuvant Breast Project (NSABP) Protocol B-17. Intraductal carcinoma (ductal carcinoma in situ). The National Surgical Adjuvant Breast and Bowel Project Collaborating Investigators [see comments]. *Cancer* 1995; 75:1310-9.
3. Lagios MD. Duct carcinoma in situ. Pathology and treatment. *Surg Clin North Am* 1990; 70:853-71.
4. Deng G, Lu Y, Zlotnikov G, Thor AD, Smith HS. Loss of heterozygosity in normal tissue adjacent to breast carcinomas. *Science* 1996; 274:2057-9.
5. Ottesen GL, Graversen HP, Blichert-Toft M, Zedeler L, Anderson JA. Ductal carcinoma in situ of the female breast. Short-term results of a prospective nationwide study. The Danish Breast Cancer Cooperative Group. *Am J Surg Pathol* 1992; 16:1183-96.
6. Habel LA, Daling JR, Newcomb PA. Risk of recurrence after ductal carcinoma in situ of the breast. *Cancer Epidemiol Biomarkers Prev* 1998; 7:689-96.
7. Lagios MD, Margolin FR, Westdahl PR, Rose MR. Mammographically detected duct carcinoma in situ. Frequency of local recurrence following tylectomy and prognostic effect of nuclear grade on local recurrence. *Cancer* 1989; 63:618-24.
8. Silverstein MJ, Poller DN, Barth A. Intraductal breast carcinoma: experiences from the Breast Center in Van Nuys, California. *Recent Results in Cancer Res* 1996; 140:139-53.
9. Silverstein MJ, Barth A, Poller DN. Ten-year results comparing mastectomy to excision and radiation therapy for ductal carcinoma in situ of the breast. *Eur J Cancer* 1995; 9:1425-7.
10. Weidner N. Current pathologic methods for measuring intratumoral microvessel density within breast carcinoma and other solid tumors. *Breast Cancer Res Treat* 1995; 37:169-80.
11. Heimann R, Ferguson D, Powers C, Recant WM, Weichselbaum RR, Hellman S. Angiogenesis as a predictor of long-term survival for patients with node-negative breast cancer. *J Natl Cancer Inst* 1996; 88:1764-69.
12. Gasparini G, Weidner N, Bevilacqua P. Tumor microvessel density, p53 expression, tumor size, and peritumoral lymphatic vessel invasion are relevant prognostic markers in node-negative breast carcinoma. *J Clin Oncol* 1994; 12:454-66.
13. Weidner N. Angiogenesis in cancer. Invited Commentary. *American Journal of Pathology* 1995; 147:9-19.
14. Hanahan D, Folkman J. Patterns and emerging mechanisms of the angiogenic switch during tumorigenesis. *Cell* 1996; 86:353-64.
15. Folkman J. The influence of angiogenesis research on management of patients with breast cancer. *Breast Cancer Res Treat* 1995; 36:109-18.
16. Brown LF, Berse B, Jackman RW, et al. Expression of vascular permeability factor (vascular endothelial growth factor) and its receptors in breast cancer. *Hum Pathol* 1995; 26:86-91.

17. Kim KJ, Li B, Winer J, et al. Inhibition of vascular endothelial growth factor-induced angiogenesis suppresses tumour growth in vivo. *Nature* 1993; 362:841-4.
18. Folkman J. Angiogenesis in cancer, vascular, rheumatoid and other disease. *Nat Med* 1995; 1:27-31.
19. Esserman L, Hylton N, George T, Weidner N. Contrast-enhanced magnetic resonance imaging to assess tumor histopathology and angiogenesis in breast carcinoma. *The Breast Journal* 1999; 5:13-21.
20. Buadu LD, Murakami J, Murayama S, et al. Breast lesions: correlation of contrast medium enhancement patterns on MR images with histopathologic findings and tumor angiogenesis. *Radiology* 1996; 200:639-49.
21. Hulka CA, Edmister WB, Smith BL, et al. Dynamic echo-planar imaging of the breast: experience in diagnosing breast carcinoma and correlation with tumor angiogenesis. *Radiology* 1997; 205:837-42.
22. Stillman B. Cell cycle control of DNA replication. *Science* 1996; 274:1659-64.
23. Diffley JF. Once and only once upon a time: specifying and regulating origins of DNA replication in eukaryotic cells. *Genes Dev* 1996; 10:2819-30.
24. Donaldson AD, Blow JJ. The regulation of replication origin activation. *Curr Opin Genet Dev* 1999; 9:62-8.
25. Leatherwood J. Emerging mechanisms of eukaryotic DNA replication initiation. *Curr Opin Cell Biol* 1998; 10:742-8.
26. Tye BK. MCM proteins in DNA replication. *Annu. Rev. Biochem.*; 68:649-686.
27. Stoeber K, Mills AD, Kubota Y, et al. Cdc6 protein causes premature entry into S phase in a mammalian cell-free system. *Embo J* 1998; 17:7219-29.
28. Wu JR, Keezer SM, Gilbert DM. Transformation abrogates an early G1-phase arrest point required for specification of the Chinese hamster DHFR replication origin. *Embo J* 1998; 17:1810-8.
29. Abdurashidova G, Riva S, Biamonti G, Giacca M, Falaschi A. Cell cycle modulation of protein-DNA interactions at a human replication origin. *Embo J* 1998; 17:2961-9.
30. Williams G, Stoeber K. Clinical applications of a novel mammalian cell-free DNA replication system. *Br J Cancer* 1999; 80 Suppl 1:20-4.
31. Williams GH, Stoeber K. A novel immunoenhanced pap test. *Hospital Healthcare Europe* 1999/2000. London: Campben Publishing Limited, 1999.
32. Williams GH, Romanowski P, Morris L, et al. Improved cervical smear assessment using antibodies against proteins that regulate DNA replication. *Proc Natl Acad Sci U S A* 1998; 95:14932-7.
33. Freeman A, Morris LS, Mills AD, et al. Minichromosome maintenance proteins as biological markers of dysplasia and malignancy [In Process Citation]. *Clin Cancer Res* 1999; 5:2121-32.
34. Solin LJ, Kurtz J, Fourquet A. Fifteen-year results of breast-conserving surgery and definitive breast irradiation for treatment of ductal carcinoma in situ of the breast. *J Clin Oncol* 1996; 14:754-63.

35. Solin LJ, Yeh IT, Kurtz J. Ductal carcinoma in situ (intraductal carcinoma) of the breast treated with breast-conserving surgery and definitive irradiation. Correlation of pathologic parameters with outcome of treatment. *Cancer* 1993; 71:2532-42.

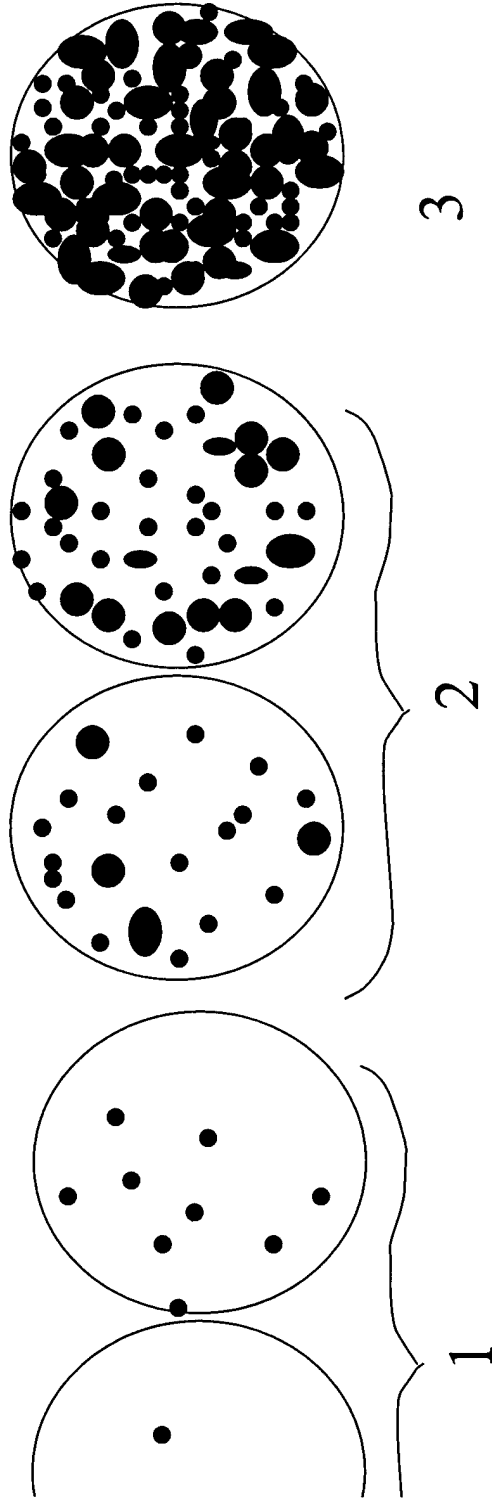
Appendix A: Database of MR, Histopathological, and Immunohistochemical Markers

Study ID	MR Size	MR % Breast Involved	MR Density	MR Washout	MR Enhancement Type	Path Density	Nuclear Grade	Comedo-necrosis	Predominant Histologic Type	Path Size	Ki67	CD68	CD34	IER Score
DC-004	58	30	2	No	Ductal/Segmental	3	2	Focal	Cribriform	24	15.4	40	87	7
DC-016	70	30	2	Yes	Ductal/Segmental	1	3	Focal	Cribriform	5	53	16	105	4
DC-018	33	10	1	No	Regional/Multi-Regional	1	3	None	Solid	9	39.3	30	165	0
DC-020	43	25	2	Yes	Ductal/Segmental	2	3	Extensive	Comedo	27	36.8	24	111	5
DC-021	54	45	2	No	Diffuse	2	3	Extensive	Comedo	N/A	34.6	101	48	0
DC-023	36	40	3	No	Regional/Multi-Regional	2	3	None	Clinging	15	15	34	42	0
DC-028	50	45	2	Yes	Regional/Multi-Regional	2	3	Focal	Solid	N/A	31.2	18	96	5
DC-030	56	45	2	Yes	Regional/Multi-Regional	2	3	Extensive	Solid	16	21.6	37	28	6
DC-032	98	75	3	Yes	Diffuse	3	3	Extensive	Comedo	90	22.8	145	57	0
DC-033	66	55	2	No	Ductal/Segmental	2	3	Extensive	Comedo	60	43.2	28	117	0
DC-035	20	15	2	No	Regional/Multi-Regional	1	3	Focal	Solid	12	55.2	15	46	0
DC-036	27	15	2	No	Regional/Multi-Regional	1	3	Extensive	Comedo	12	48.4	22	42	8
DC-037	60	25	1	No	Ductal/Segmental	1	3	Focal	Cribriform	N/A	17.2	25	17	2
DC-038	12	5	1	Yes	Ductal/Segmental	1	3	Focal	Cribriform	12	34.6	36	198	8
DC-039	13	5	2	No	Ductal/Segmental	1	3	Focal	Comedo	32	22.8	42	33	4
DC-040	18	15	2	Yes	Ductal/Segmental	3	3	Extensive	Comedo	N/A	37.3	73	122	0
DC-041	34	15	2	No	Regional/Multi-Regional	2	3	Focal	Cribriform	18	20.3	30	87	6
DC-042	11.7	5	2	Yes	Ductal/Segmental	1	3	Extensive	Comedo	12	45.3	45	58	0
DC-048	14.7	15	2	Yes	Regional/Multi-Regional	3	1	None	Cribriform	100	66	15	143	8
DC-057	42	25	2	Yes	Ductal/Segmental	2	2	None	Cribriform	22	0.9	32	83.6	7
DC-060	4	5	1	No	Regional/Multi-Regional	N/A	3	Focal	Cribriform	20	16.3	21	140	6
DC-062	8	5	2	No	Focal Mass	1	2	Focal	Cribriform	9	9	20	37	0
DC-063	9	5	2	Yes	Ductal/Segmental	1	1	None	Cribriform	12	71	20	15	0
DC-065	63	65	2	No	Diffuse	3	2	Focal	Solid	50	18.3	14	66	5
DC-067	13	25	3	No	Focal Mass	3	2	Extensive	Cribriform	19	13.6	30	63	8
DC-068	70	85	2	No	Regional/Multi-Regional	3	3	Focal	Cribriform	N/A	32	50	67	7
DC-069	18	15	2	Yes	Ductal/Segmental	2	3	Focal	Solid	12	22.3	26	23	6
DC-070	77	55	2	No	Diffuse	2	1	None	Clinging	15	5.3	8	27	2

Study ID	MR Size	MR % Breast Involved	MR Density	MR Washout	MR Enhancement Type	Path Density	Nuclear Grade	Comedonecrosis	Predominant Histologic Type	Path Size	Ki67	CD68	CD34	ER Score
DC-071	81.2	35	2	Yes	Diffuse	N/A	2	Extensive	Micropapillary	N/A	19	32	21	6
DC-072	36.5	15	2	No	Ductal/Segmental	3	2	Focal	Cribiform	21	27	20	34	7
DC-073	68	35	2	No	Diffuse	2	2	Focal	Cribiform	14	8.1	22	48	4
DC-076	40	20	2	No	Regional/Multi-Regional	2	3	None	Cribiform	33	26.5	40	114	2
DC-077	93	55	2	No	Regional/Multi-Regional	1	3	None	Cribiform	N/A	8.3	18	25	5
DC-079	45	30	2	No	Ductal/Segmental	2	2	Focal	Cribiform	N/A	9.6	23	65	6
DC-085	76	50	2	No	Diffuse	1	2	None	Cribiform	N/A	12.6	13	69	5
DC-086	22	30	2	No	Regional/Multi-Regional	1	2	None	Cribiform	N/A	16.3	37	55	5
DC-088	9	5	3	Yes	Focal Mass	N/A	2	None	Micropapillary	18	13.2	29	78	6
DC-091	40	40	3	No	Regional/Multi-Regional	3	2	Focal	Cribiform	60	18.8	166	80	5
DC-094	158	75	2	Yes	Regional/Multi-Regional	2	3	Extensive	Micropapillary	84	38.3	115	32	0
DC-095	53.5	35	2	Yes	Diffuse	3	3	Focal	Comedo	43	34	27.6	17	0
DC-096	52	25	2	No	Regional/Multi-Regional	3	3	Extensive	Comedo	N/A	47.6	96	66	0
DC-098	60	35	2	Yes	Ductal/Segmental	2	3	Extensive	Clinging	N/A	47.5	51	71	0
DC-099	21	15	3	No	Regional/Multi-Regional	3	2	Extensive	Solid	19	14.5	34	66	3
DC-125	114	85	3	No	Regional/Multi-Regional	2	3	Extensive	Comedo	90	43.4	110	84	0
DC-129	80	70	3	No	Regional/Multi-Regional	2	3	Extensive	Comedo	N/A	30.4	155	60	0

Appendix A

DCIS 3 Point Categorization



Score	1	2	3
Path	5/+ mm apart TDLU, normal ducts in between lesions	2-5 mm apart	1-2 mm apart Very dense/solid
MRI	Sparse, stippled enhancement	Clumped Enhancement	Solid, Wall-to-wall

Appendix B

University of California
San Francisco



Comprehensive
Cancer Center

MRI Form

Patient Study ID

D	C	-				
---	---	---	--	--	--	--

Date of MRI

		-			-		
--	--	---	--	--	---	--	--

MRN

--	--	--	--	--	--	--	--

Accession Number

--	--	--	--	--	--	--	--	--

Patient Name _____

Form completed by _____

Date Review Completed _____

Lesion Number: _____ / _____ .

A. Pre-MRI Work-up

	<i>Yes</i>	<i>No</i>	<i>Date/Notes</i>
FNA	<input type="checkbox"/>	<input type="checkbox"/>	
Core Biopsy	<input type="checkbox"/>	<input type="checkbox"/>	
Incisional Biopsy	<input type="checkbox"/>	<input type="checkbox"/>	
Other	<input type="checkbox"/>	<input type="checkbox"/>	

B. Location of Lesion

	<i>Yes</i>	<i>No</i>
Continuous	<input type="checkbox"/>	<input type="checkbox"/>
Upper	<input type="checkbox"/>	<input type="checkbox"/>
Middle	<input type="checkbox"/>	<input type="checkbox"/>
Lower	<input type="checkbox"/>	<input type="checkbox"/>
Outer	<input type="checkbox"/>	<input type="checkbox"/>
Middle	<input type="checkbox"/>	<input type="checkbox"/>
Inner	<input type="checkbox"/>	<input type="checkbox"/>
Anterior (near nipple)	<input type="checkbox"/>	<input type="checkbox"/>
Mid	<input type="checkbox"/>	<input type="checkbox"/>
Posterior	<input type="checkbox"/>	<input type="checkbox"/>

_____ : % Breast Involved

_____ : 1-3 point DCIS Scale

Laterality: Right

Left

Unknown

C. Diameter of Lesion:

	<i>Yes</i>	<i>Measurement</i>
LD	<input type="checkbox"/>	mm
AP	<input type="checkbox"/>	mm
CC	<input type="checkbox"/>	mm
TRV	<input type="checkbox"/>	mm

D. Nature of Lesion:

	<i>Mass</i>	<i>Enhancement</i>
Nature of Lesion	<input type="checkbox"/> <i>see Part E</i>	<input type="checkbox"/> <i>see Part F</i>

E.1 Characteristics of Mass

	<i>Yes</i>	<i>No</i>
Progressive	<input type="checkbox"/>	<input type="checkbox"/>
Wash-out	<input type="checkbox"/>	<input type="checkbox"/>
Plateau	<input type="checkbox"/>	<input type="checkbox"/>

E.2 Shape of Mass

	<i>Yes</i>	<i>No</i>
Round: spherical ball-shape	<input type="checkbox"/>	<input type="checkbox"/>
Oval: elliptical or egg shaped	<input type="checkbox"/>	<input type="checkbox"/>
Lobulated: undulating contour	<input type="checkbox"/>	<input type="checkbox"/>
Irregular: uneven, bumpy or asymmetrical	<input type="checkbox"/>	<input type="checkbox"/>
Largest Diameter		

E.3 Margins of Mass

	<i>Yes</i>	<i>No</i>
Smooth: well circumscribed, well defined	<input type="checkbox"/>	<input type="checkbox"/>
Irregular: rough, uneven, jagged	<input type="checkbox"/>	<input type="checkbox"/>
Spiculated: characterized by radiating lines	<input type="checkbox"/>	<input type="checkbox"/>
Largest Diameter		

E.4 Internal Enhancement in the Mass

	<i>Yes</i>	<i>No</i>
Homogeneous: confluent, uniform	<input type="checkbox"/>	<input type="checkbox"/>
Heterogeneous: nonspecific mixed enhancement	<input type="checkbox"/>	<input type="checkbox"/>
Heterogeneous rim enhancement: more pronounced at periphery of a mass	<input type="checkbox"/>	<input type="checkbox"/>
Heterogeneous dark septation: dark non-enhancing lines within a mass	<input type="checkbox"/>	<input type="checkbox"/>
Heterogeneous enhancing: enhancing lines within mass	<input type="checkbox"/>	<input type="checkbox"/>
Heterogeneous centrally enhanced: enhancement more pronounced at the center of the mass	<input type="checkbox"/>	<input type="checkbox"/>
Largest Diameter		

F.1 Non-Mass Enhancement Dynamic Characteristics

	<i>Yes</i>	<i>No</i>
Progressive	<input type="checkbox"/>	<input type="checkbox"/>
Wash-out	<input type="checkbox"/>	<input type="checkbox"/>
Plateau	<input type="checkbox"/>	<input type="checkbox"/>

F.2 Non-Mass Enhancement Foci

	<i>Yes</i>	<i>No</i>
Segmental	<input type="checkbox"/>	<input type="checkbox"/>
Regional	<input type="checkbox"/>	<input type="checkbox"/>
Multiple Regions	<input type="checkbox"/>	<input type="checkbox"/>
Homogeneous: confluent, uniform	<input type="checkbox"/>	<input type="checkbox"/>
Heterogeneous: nonspecific, non-uniform enhancement	<input type="checkbox"/>	<input type="checkbox"/>
Stippled, punctuate: punctuate, similar appearing enhancing foci, sand-like	<input type="checkbox"/>	<input type="checkbox"/>
Clumped: regions of cobblestone like enhancement	<input type="checkbox"/>	<input type="checkbox"/>
Dendritic, septal: finger-like enhancement, extending in a ductal distribution	<input type="checkbox"/>	<input type="checkbox"/>
Largest Diameter		

F.3 Non-Mass Like Enhancement

	<i>Yes</i>		<i>No</i>
Linear ductal: enhancement in a line that may have branching	<input type="checkbox"/>		<input type="checkbox"/>
		<i>Yes</i>	<i>No</i>
	<i>Smooth</i>	<input type="checkbox"/>	<input type="checkbox"/>
	<i>Irregular</i>	<input type="checkbox"/>	<input type="checkbox"/>
	<i>Clumped</i>	<input type="checkbox"/>	<input type="checkbox"/>
Segmental: triangular region of enhancement with apex pointing towards nipple, enhancement in a distribution suggesting a duct and its branches	<input type="checkbox"/>		<input type="checkbox"/>
Regional: enhancement in a large volume of tissue not conforming to duct distribution but in ONE quadrant	<input type="checkbox"/>		<input type="checkbox"/>
Multiple Regions: focal large areas of enhancement in at least TWO quadrants of the breast	<input type="checkbox"/>		<input type="checkbox"/>
Diffuse: enhancement distributed randomly throughout the breast	<input type="checkbox"/>		<input type="checkbox"/>
Size			
Largest Diameter			

Notes:



Breast Histology Form

Patient Study ID

D	C	-		
---	---	---	--	--

MRN

--	--	--	--	--	--	--	--

Patient Name _____

Form completed by _____

Date DCIS Review Completed _____

Specimen Information

Specimen Type	<input type="checkbox"/>	<i>Excisional biopsy or lumpectomy</i>	<input type="checkbox"/>	<i>Prophylactic mastectomy</i>
	<input type="checkbox"/>	<i>Excisional biopsy or lumpectomy, with wire localization</i>	<input type="checkbox"/>	<i>Incisional biopsy</i>
	<input type="checkbox"/>	<i>Incisional biopsy, with wire localization</i>	<input type="checkbox"/>	<i>Needle biopsy (tru-cut or core)</i>
	<input type="checkbox"/>	<i>Needle biopsy (tru-cut or core), with wire localization</i>	<input type="checkbox"/>	<i>Mastectomy</i>
	<input type="checkbox"/>	<i>MR-guided Excisional biopsy or lumpectomy</i>	<input type="checkbox"/>	<i>Other, specify _____</i>

Specimen Accession Number

--	--	--	--	--	--	--	--

Specimen Laterality Left Right Unknown/ Not Applicable

Pathology: Assessment of Ductal Carcinoma In Situ (DCIS)

Is DCIS present?	<input type="checkbox"/> Yes	<input type="checkbox"/> No		
Is DCIS present with invasive cancer?	<input type="checkbox"/> Yes	<input type="checkbox"/> No		
If present with invasive disease, Is an extensive intraductal component (EIC) present?	<input type="checkbox"/> Yes	<input type="checkbox"/> No		
Is cancerization of lobules present?	<input type="checkbox"/> Yes	<input type="checkbox"/> No		
Histologic Type (check all that apply)	<input type="checkbox"/>	<i>Comedo</i>	<input type="checkbox"/>	<i>Apocrine</i>
	<input type="checkbox"/>	<i>Solid</i>	<input type="checkbox"/>	<i>Intra-cystic (encysted papillary)</i>
	<input type="checkbox"/>	<i>Cribriform</i>	<input type="checkbox"/>	<i>Papillary carcinoma in situ (papillary)</i>
	<input type="checkbox"/>	<i>Micropapillary</i>	<input type="checkbox"/>	<i>Other, specify _____</i>
	<input type="checkbox"/>	<i>Clinging</i>		

Dominant Histologic Type (check only one)	<input type="checkbox"/>	<i>Comedo</i>	<input type="checkbox"/>	<i>Apocrine</i>
	<input type="checkbox"/>	<i>Solid</i>	<input type="checkbox"/>	<i>Intra-cystic (encysted papillary)</i>
	<input type="checkbox"/>	<i>Cribriform</i>	<input type="checkbox"/>	<i>Papillary carcinoma in situ (papillary)</i>
	<input type="checkbox"/>	<i>Micropapillary</i>	<input type="checkbox"/>	<i>Other, specify _____</i>
	<input type="checkbox"/>	<i>Clinging</i>		

Pathology: Assessment of Ductal Carcinoma In Situ (DCIS) (continued)

Slide Review

Total Number of Slides Reviewed:

Total Number of Slides Positive:

Block Selection:

1st Choice:

2nd Choice:

Size of DCIS

 mm

Continuous (Slide # _____)

Not Continuous (Slide # _____)

Extent of DCIS

- single focus
- more than one focus in a single quadrant
- more than one and up to two quadrants
- three or four quadrants

Nuclear Grade

(check highest grade)

- Grade I (low)
- Grade II (intermediate)
- Grade III (high)
- Unknown

Is necrosis present?

- Yes
- No

Necrosis Type

- Comedonecrosis:
- Non-comedonecrosis
- focal
- extensive (>1/3)

Microcalcifications

- Present, involving benign ducts
- Present, involving DCIS
- None
- Present, involving both benign ducts and DCIS
- Present, involving stroma

Is DCIS at margin?

- Transected
- Less than 1 mm
- > or = 1 mm to 10 mm
- Greater than 10 mm
- Involved, NOS
- Not involved, NOS
- Unknown

Diagnosis

- Malignant
- Benign (false positive)

5 Point Categorization

- 1: Sparse
- 2: Clumped
- 3: Solid

Notes: _____

Pathology: Immunohistochemistry (Optional: For use where protocol includes additional IHC testing)

Marker Name(s) Ki67

Date Review Completed _____

Tissue Type		Blocks	Accession Number
<input type="checkbox"/> Primary		<input type="checkbox"/> <input type="checkbox"/>	_____
(for Blocks, enter 99 for unknown)	<input type="checkbox"/> Regional Nodal	<input type="checkbox"/> <input type="checkbox"/>	_____
	<input type="checkbox"/> Other, specify _____	<input type="checkbox"/> <input type="checkbox"/>	

Method of Evaluation

- Excisional biopsy or lumpectomy
- Sentinel node biopsy
- Mastectomy
- Prophylactic mastectomy
- Other, specify _____

Primary Antibody _____

Antigen Retrieval No Yes, specify _____

Distribution of staining
Within DCIS Peritumoral Cuffing Scattered

Epithelial Staining

	<input type="checkbox"/> <input type="checkbox"/> <input type="checkbox"/>	Percent Malignant	%
•	<input type="checkbox"/> <input type="checkbox"/> <input type="checkbox"/>	Percent Stromal	%

Vessels staining No Yes

Pathology: Breast Tumor Markers

Marker Name(s) CD34

Date Review Completed _____

Tissue Type

Primary

(for Blocks, enter
99 for unknown)

Other, specify _____

Blocks

--	--

--	--

Accession Number

Method of Evaluation

Excisional biopsy or lumpectomy

Sentinel node biopsy

Mastectomy

Prophylactic mastectomy

Other, specify

Primary Antibody _____

Antigen Retrieval No

Yes, specify _____

Microvessel counts _____

Hot Spot Stain/HPF _____

Field 1:

Field 2:

Field 3:

+

/ 3 =

Distribution of staining: Peritumoral Cuffing

Scattered

Other

Location: Adjacent

Far

Intermixed

Pathology: Breast Tumor Markers

Marker Name(s) ER

Date Review Completed _____

Tissue Type Primary
(for Blocks, enter Other, specify _____
99 for unknown)

Blocks

Accession Number

Disease Description

Proportion Score (PS) of stained malignant nuclei

- 0
- 1 (1/100)
- 2 (1/10)
- 3 (1/3)
- 4 (2/3)
- 5 (1.0)

Intensity Score (IS) of stained malignant nuclei

- 0 (negative)
- 1 (weak)
- 2 (intermediate)
- 3 (strong)

Total Score (TS) = PS + IS =

--	--

Pathology: Breast Tumor Markers

Marker Name(s) CD68

Date Review Completed _____

Tissue Type Primary Other, specify _____
(for Blocks, enter 99 for unknown)

Blocks

 Accession Number _____

Method of Evaluation

- Excisional biopsy or lumpectomy
- Sentinel node biopsy
- Mastectomy
- Prophylactic mastectomy
- Other, specify _____

Primary Antibody _____

Antigen Retrieval No Yes, specify _____

Tumor-associated Macrophages (TAMs) _____

Hot Spot Stain/HPF _____

Field 1:

Field 2:

Field 3:
+ / 3 =

Distribution of staining: Peritumoral Cuffing Centralized Scattered Other

Location : Adjacent Tumor Core Far Intermixed