

AD \_\_\_\_\_

Award Number: DAMD17-01-1-0713

TITLE: Proton MR Spectroscopic Imaging in NF-1

PRINCIPAL INVESTIGATOR: Peter B. Barker, Ph.D.

CONTRACTING ORGANIZATION: Johns Hopkins University  
Baltimore, Maryland 21205

REPORT DATE: July 2004

TYPE OF REPORT: Annual

PREPARED FOR: U.S. Army Medical Research and Materiel Command  
Fort Detrick, Maryland 21702-5012

DISTRIBUTION STATEMENT: Approved for Public Release;  
Distribution Unlimited

The views, opinions and/or findings contained in this report are those of the author(s) and should not be construed as an official Department of the Army position, policy or decision unless so designated by other documentation.

20050105 042

**REPORT DOCUMENTATION PAGE**Form Approved  
OMB No. 074-0188

Public reporting burden for this collection of information is estimated to average 1 hour per response, including the time for reviewing instructions, searching existing data sources, gathering and maintaining the data needed, and completing and reviewing this collection of information. Send comments regarding this burden estimate or any other aspect of this collection of information, including suggestions for reducing this burden to Washington Headquarters Services, Directorate for Information Operations and Reports, 1215 Jefferson Davis Highway, Suite 1204, Arlington, VA 22202-4302, and to the Office of Management and Budget, Paperwork Reduction Project (0704-0188), Washington, DC 20503

<b>1. AGENCY USE ONLY</b> (Leave blank)		<b>2. REPORT DATE</b> July 2004	<b>3. REPORT TYPE AND DATES COVERED</b> Annual (1 Jul 2003 - 30 Jun 2004)	
<b>4. TITLE AND SUBTITLE</b> Proton MR Spectroscopic Imaging in NF-1			<b>5. FUNDING NUMBERS</b> DAMD17-01-1-0713	
<b>6. AUTHOR(S)</b> Peter B. Barker, Ph.D.				
<b>7. PERFORMING ORGANIZATION NAME(S) AND ADDRESS(ES)</b> Johns Hopkins University Baltimore, Maryland 21205  E-Mail: barker@mri.jhu.edu			<b>8. PERFORMING ORGANIZATION REPORT NUMBER</b>	
<b>9. SPONSORING / MONITORING AGENCY NAME(S) AND ADDRESS(ES)</b> U.S. Army Medical Research and Materiel Command Fort Detrick, Maryland 21702-5012			<b>10. SPONSORING / MONITORING AGENCY REPORT NUMBER</b>	
<b>11. SUPPLEMENTARY NOTES</b> Original contains color plates: All DTIC reproductions will be in black and white.				
<b>12a. DISTRIBUTION / AVAILABILITY STATEMENT</b> Approved for Public Release; Distribution Unlimited				<b>12b. DISTRIBUTION CODE</b>
<b>13. ABSTRACT (Maximum 200 Words)</b>  Neurofibromatosis Type 1 (NF-1) is the most common autosomal dominant genetic disorder, affecting the skin, central (CNS) and peripheral nervous systems. Children with NF-1 have an increased risk of developing significant learning disability (LD), cognitive impairment, and optic or brain stem gliomas. Cerebral magnetic resonance imaging (MRI) in NF-1 reveals regions of high signal intensity (often called "unidentified bright objects", or UBOs). The pathophysiology of UBOs is poorly understood, and it is controversial to what extent they are involved in cognitive impairment. The aims of this proposal are to characterize the underlying metabolic abnormalities in NF-1 with proton MR spectroscopic imaging (MRSI). We have developed a rapid, quantitative MR spectroscopic imaging (MRSI) protocol for the evaluation of cerebral metabolite levels in NF-1. Metabolite levels will be determined both in UBOs and other brain regions, both in order to improve understanding of the etiology of UBOs, and to understand the relationship between regional brain metabolism and LD. 60 subjects with NF1 and 60 control subjects will be evaluated with proton MRSI and detailed neuropsychological testing. Ultimately, proton MRSI may be a useful test for identifying children with NF-1 at risk of developing LD, and also help in distinguishing UBOs from other, malignant lesions which require therapeutic intervention.				
<b>14. SUBJECT TERMS</b> Neurofibromatosis type 1, magnetic resonance spectroscopy, magnetic resonance imaging, diagnosis			<b>15. NUMBER OF PAGES</b> 11	
			<b>16. PRICE CODE</b>	
<b>17. SECURITY CLASSIFICATION OF REPORT</b> Unclassified	<b>18. SECURITY CLASSIFICATION OF THIS PAGE</b> Unclassified	<b>19. SECURITY CLASSIFICATION OF ABSTRACT</b> Unclassified	<b>20. LIMITATION OF ABSTRACT</b> Unlimited	

## Table of Contents

<b>Cover</b> .....	<b>1</b>
<b>SF 298</b> .....	<b>2</b>
<b>Table of Contents</b> .....	<b>3</b>
<b>Introduction</b> .....	<b>4</b>
<b>Body</b> .....	<b>5</b>
<b>Key Research Accomplishments</b> .....	<b>7</b>
<b>Reportable Outcomes</b> .....	<b>8</b>
<b>Conclusions</b> .....	<b>9</b>
<b>References</b> .....	<b>10</b>
<b>Appendices</b> .....	<b>11</b>

## Introduction

Neurofibromatosis Type 1 (NF-1) is the most common autosomal dominant genetic disorder, affecting the skin, central (CNS) and peripheral nervous systems. Children with NF-1 have an increased risk of developing significant learning disability (LD), cognitive impairment, and optic or brain stem gliomas. Cerebral T<sub>2</sub>-weighted magnetic resonance imaging (MRI) in NF-1 reveals regions of high signal intensity (often called “unidentified bright objects”, or UBOs) in the basal ganglia, brain stem and cerebellum. The pathophysiology of UBOs is poorly understood, and it is controversial to what extent they are involved in cognitive impairment. Proton magnetic resonance spectroscopic imaging (MRSI) is a relatively new non-invasive metabolic imaging technique that can provide information about the cellular composition and metabolism of brain tissue. Our pilot data of proton MRSI in NF-1 indicate highly significant perturbations in thalamic metabolism in NF-1, regardless of presence or absence of UBOs. UBOs themselves were metabolically more similar to normal brain tissue. These data indicate dissociation between imaging and metabolic findings, and may indicate more widespread cerebral involvement in NF-1 than that indicated by MRI.

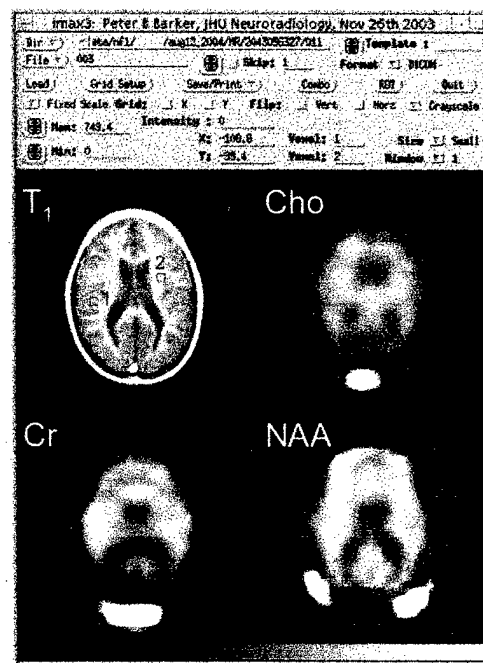
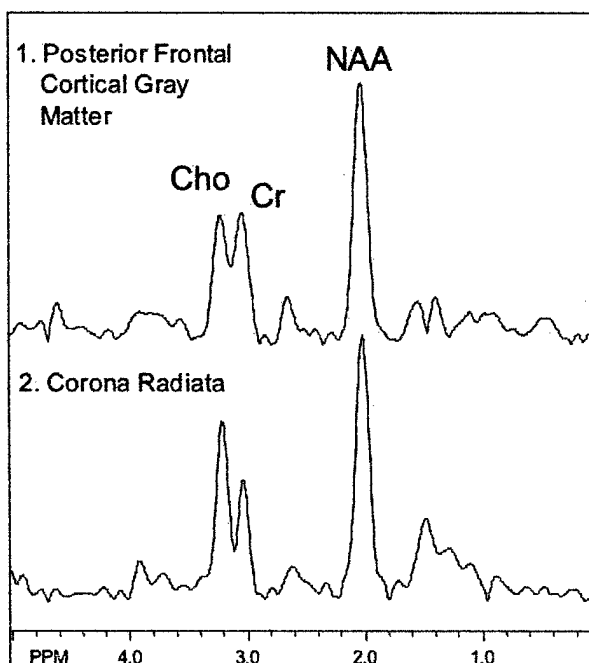
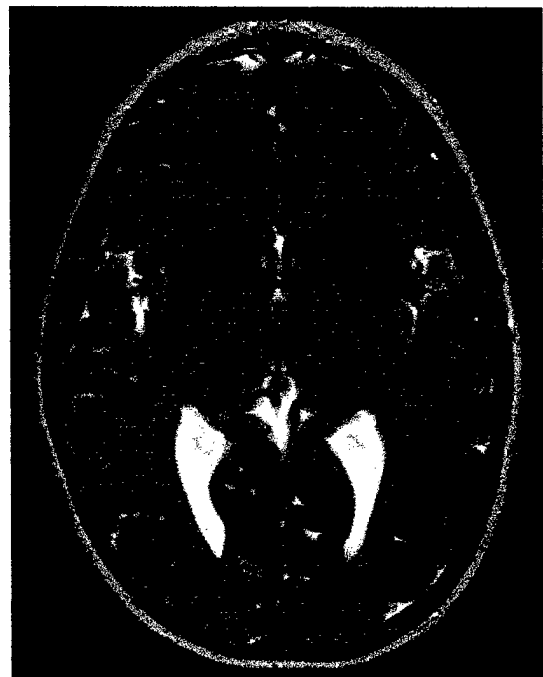
In this proposal, we are extending these preliminary findings to investigate the hypotheses that: (1) thalamic metabolism is abnormal in NF-1 and evolves with age, (2) proton MRSI measures of thalamic metabolism will correlate with neuropsychological performance, and (3) metabolic abnormalities in NF-1 are more diffuse and widespread than abnormalities visualized by MRI. The study design to test these hypotheses involves the performance of proton MRSI, MRI and neuropsychological testing in 60 subjects with NF-1 and 60 age-matched control subjects. To test hypothesis (1), thalamic metabolite levels will be compared between NF-1 subjects and controls in 3 different age ranges, and regression analysis performed with respect to age. To test hypothesis (2) thalamic metabolite levels in NF-1 patients will be correlated with results of a battery of neuropsychological tests. To test hypothesis (3), multiple regions of interest in the basal ganglia and cerebellum will be evaluated both by MRI and MRSI, and compared between NF-1 and control subjects.

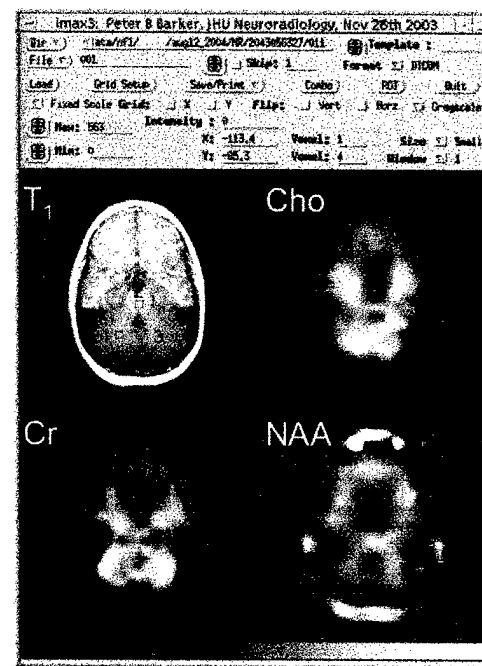
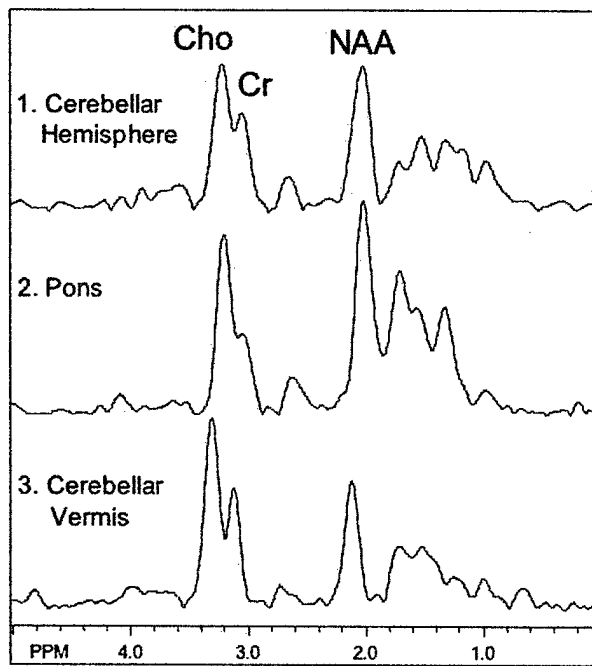
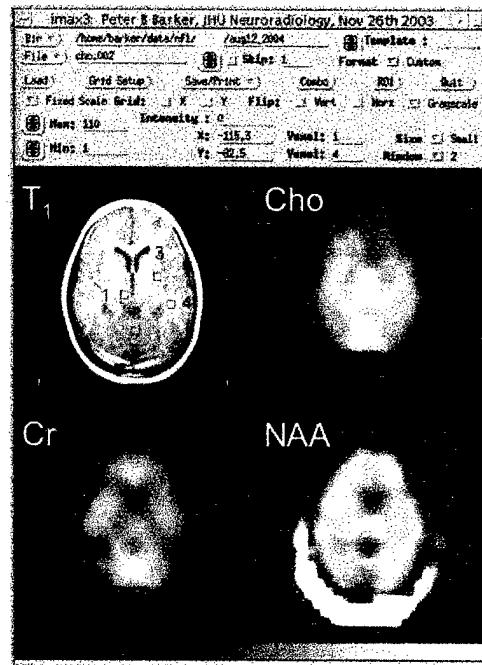
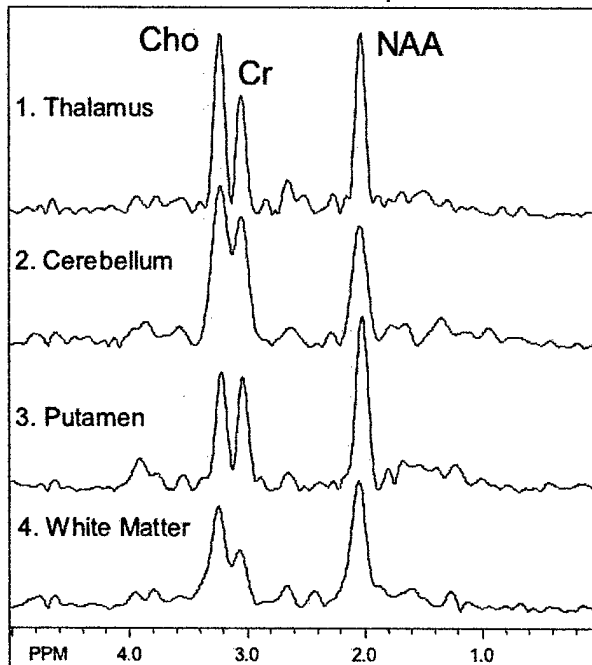
In addition to improving the understanding of the pathophysiology of NF-1 brain lesions, this proposal will establish the relationship between regional cerebral metabolism and cognitive impairment in NF-1. If successful, MRSI may serve as a screening tool for young children with NF-1; the observation of normal MRSI may be reassuring prognostic information for normal subsequent development, while children with abnormal MRSI may be identified for early intervention for possible learning or developmental problems.

## Body

As described in last years progress report, the initial work in year 1 of the project was on establishing the protocol for quantitative brain MRI and MRSI in children with NF1 and controls, and in year 2 data collection was initiated. As stated above, the research protocol consists of brain MRI and MRSI, as well as detailed neuropsychological testing (Boston Naming test, judgment of line orientation, IQ). Progress has been limited this year by protracted problems with the institutional IRB committee regarding privacy issues related to the HIPAA regulations. These problems were finally resolved by May 2004. However, delay to the project in terms of patient recruitment required that we sought (and received) approval for a one-year no cost extension to complete the study. So far, 27 patients and 18 control subjects have been studied. Examples of MRI and MRSI data from one case are illustrated in the figures.

The patient is a 9 year old female with NF1. T<sub>2</sub>-MRI (right) exhibits a UBO in the left globus pallidus and more subtle abnormal signal intensity and bilaterally in the pulvinar (posterior thalamus), and moderate enlargement of the posterior horns of the lateral ventricles. Proton MRSI was collected in three slices as described in the proposal, with the central slice at the level of the thalamus. Spectroscopic images and representative spectra from different brain regions are presented below:





Compared to control subjects, the MRSI exhibits reduced ratios of NAA/Cho (consistent with those seen in our prior work) in white matter, the thalamus, and cerebellar vermis and hemispheres. Work is on going to correlate these spectroscopic changes with neuropsychological test scores. The example represented here shows the high quality MRSI of the posterior fossa possible on children recorded on the 1.5T MR system at the Kennedy Krieger Institute/Johns Hopkins Department of Radiology.

### **Key Research Accomplishments**

- Established MRSI and neuropsychological test methodology
- Collected data so far in 27 NF1 and 18 control subjects
- The demonstration of abnormal, age-dependent thalamic metabolism in children with NF-1

## **Reportable Outcomes**

Since we are in the data collection phase of the project, there have been no publications this year regarding results in NF1.

## **Conclusions**

The collection of data for the evaluation of the relationship between neurometabolism, in particular thalamic NAA and choline levels (and the ratio of NAA/Cho), and LD in NF-1 as described in the proposal is continuing. This work is important for the clinical evaluation of patients with NF-1 in two respects. Firstly, proton MRSI may allow for a quantitative biochemical determination of the degree of brain involvement in children with NF-1, the observation of normal MRSI may be reassuring prognostic information for normal subsequent development, while children with abnormal MRSI may be identified for early intervention for possible learning or developmental problems. Secondly, the characterization of UBO metabolism is important for the diagnostic reasons; since patients with NF-1 are at increased risk for development of brain and optic gliomas, it can sometimes be difficult to distinguish these very different pathologies using conventional magnetic resonance imaging. Early, non-invasive diagnosis of a malignant glioma (and distinguishing it from a benign UBO) is extremely important in improving therapeutic outcome in these patients.

## References

- Wang PY, Kaufman WE, Koth CW, Denckla MB, Barker PB. *Thalamic Involvement In Neurofibromatosis Type 1: Evaluation With Proton MR Spectroscopic Imaging.* Ann Neurol 2000; **47**:477-484
- Golay X, Gillen J, van Zijl PCM, Barker PB. *Scan Time Reduction in Proton Magnetic Resonance Spectroscopic Imaging of the Human Brain.* Magnetic Resonance in Medicine 2002; **47**:384-7

**Appendices**

None