

REPORT DOCUMENTATION PAGE			Form Approved OMB No. 0704-0188	
Public reporting burden for this collection of information is estimated to average 1 hour per response, including the time for reviewing instructions, searching existing data sources, gathering and maintaining the data needed, and completing and reviewing the collection of information. Send comments regarding this burden estimate or any other aspect of this collection of information, including suggestions for reducing this burden, to Washington Headquarters Services, Directorate for Information Operations and Reports, 1215 Jefferson Davis Highway, Suite 1204, Arlington, VA 22202-4302, and to the Office of Management and Budget, Paperwork Reduction Project (0704-0188), Washington, DC 20503.				
1. AGENCY USE ONLY (Leave blank)	2. REPORT DATE 13.Dec.04	3. REPORT TYPE AND DATES COVERED MAJOR REPORT		
4. TITLE AND SUBTITLE THE USE OF ULTRASOUND IN PLACEMENT OF INTRAVENOUS CATHETERS (CO-AUTHORS HECTOR APONTE AND SAID ACOSTA)			5. FUNDING NUMBERS	
6. AUTHOR(S) CAPT ACOSTA SAID R				
7. PERFORMING ORGANIZATION NAME(S) AND ADDRESS(ES) UNIFORMED SERVICES UNIV OF HEALTH SCIENC			8. PERFORMING ORGANIZATION REPORT NUMBER CI04-919	
9. SPONSORING/MONITORING AGENCY NAME(S) AND ADDRESS(ES) THE DEPARTMENT OF THE AIR FORCE AFIT/CIA, BLDG 125 2950 P STREET WPAFB OH 45433			10. SPONSORING/MONITORING AGENCY REPORT NUMBER	
11. SUPPLEMENTARY NOTES				
12a. DISTRIBUTION AVAILABILITY STATEMENT Unlimited distribution In Accordance With AFI 35-205/AFIT Sup 1			12b. DISTRIBUTION CODE	
13. ABSTRACT (Maximum 200 words)				
<p>DISTRIBUTION STATEMENT A Approved for Public Release Distribution Unlimited</p>				
<div style="border: 1px solid black; padding: 10px; width: fit-content; margin: 0 auto;"> <p>20050107 007</p> </div>				
14. SUBJECT TERMS			15. NUMBER OF PAGES 17	
			16. PRICE CODE	
17. SECURITY CLASSIFICATION OF REPORT	18. SECURITY CLASSIFICATION OF THIS PAGE	19. SECURITY CLASSIFICATION OF ABSTRACT	20. LIMITATION OF ABSTRACT	

Abstract

Ultrasound has been used to aid cannulation of veins of the neck, chest, antecubital fossa as well as the femoral vein. This investigation compared the traditional method of peripheral intravenous (IV) cannulation of veins of the hands and forearms to ultrasound-guided IV cannulation of these veins.

Subjects were adults of either gender who reported a history of difficult IV cannulation or, based on examination, suspected to be difficult to establish venous access in the veins of the hands and forearms. After obtaining Institutional Review Board approval and written informed consent, 35 subjects were prospectively enrolled with 16 subjects randomly assigned to the traditional group and 19 subjects to the ultrasound group. Patient demographics data included age, gender, and body mass index. Time taken for successful venous cannulation and number of attempts between the groups were compared using a Mann-Whitney U Test. The number of subjects where IV cannulation was successful on the first attempt was compared between the groups using the Fisher's Exact Test.

No significant differences were noted between the groups in relation to demographics, time to successful cannulation, number of attempts, and number of subjects where IV cannulation was successful on the first attempt. Ultrasound was as efficacious as the traditional method of IV cannulation in this subset of patients. Future investigations should examine the efficacy of the ultrasound-guided technique of IV cannulation of these veins in patients who failed the traditional method.

Introduction

Placement of peripheral intravenous (IV) catheters for administration of fluids and/or medications is a common procedure. These catheters are typically inserted by palpating or directly visualizing the target vein. Patients may lack visual and/or palpable venous anatomy necessary for successful IV cannulation. Patients' medical history, body habitus, fluid status, and extremes of age are all factors that can pose challenges to practitioners attempting IV cannulation.¹ Aids to intravenous catheter placement include locally applied vasodilators, use of a blood pressure cuff as a tourniquet, and using ultrasound to locate potential peripheral veins.²

Ultrasound has been used for placement of central venous catheters for many years.³ Its use in placement of central venous catheters has been established in adults as well as in infants and children.⁴ The use of ultrasound for central venous catheterization has been endorsed by a National Institute for Clinical Excellence in the United Kingdom and Agency for Healthcare Research and Quality in the United States.^{5,6} Ultrasound has also been used to place IV catheters in the femoral veins as well as veins in the antecubital fossa for routine as well as emergency conditions.⁷⁻⁹ While the results of these previous investigations support the use of ultrasound in placement of IV catheters in the upper extremities, previous investigators have generally limited the use of the technique to veins of the antecubital fossa.

The purpose of this investigation was to compare the success rate and time to successful placement of IV catheters placed in hand and forearm veins of adults with potentially difficult peripheral venous access using a traditional and ultrasound-guided method of IV cannulation.

Materials and Methods

After Institutional Review Board approval, written informed consent was obtained from 35 subjects, greater than 18 years of age. A power analysis revealed 35 subjects were required for the investigation (power of 0.80 with an alpha of 0.05). Subjects were included in the study if during the preoperative interview they reported past difficulties with peripheral IV access or if the anesthesia provider identified them as having the potential for difficulty with intravenous access. Enrolled subjects were randomly assigned to have the IV catheter placed using the traditional or ultrasound-guided method.

All IV attempts and ultrasound imaging were conducted by two Certified Registered Nurse Anesthetists (CRNAs) with greater than three years of experience. The intravenous catheters used in the study ranged from 18 to 22 gauge (Insyte, BD Medical, Sandy, UT). The size was determined by the CRNA based on the clinical situation. Ultrasound imaging was performed with the portable Site-Rite[®] 3 Ultrasound Unit (Bard Access Systems, Salt Lake City, UT) equipped with a 9.0 MHz probe. Each CRNA had training in the use of the ultrasound device and had previously used the device as an aid in peripheral venous cannulation successfully five or more times. When attempts at intravenous cannulation failed using either method, an alternative anatomical site was selected and subsequent attempts used the same method.

Traditional Method

A tourniquet was applied to an upper extremity. Procedure start time was defined when the CRNA started identifying potential target veins visually and/or by palpation. Prior to cannulation of the chosen vessel, the skin was cleansed with alcohol

and 0.25 to 1 ml of 1% lidocaine was infiltrated intradermally and the catheter was inserted. Successful IV cannulation, as determined by the CRNA performing the procedure, was defined as advancement of the catheter into the vein confirmed by blood return from the catheter. Procedure stop time was defined as successful IV cannulation.

Ultrasound-Guided Method

As in the traditional method, a tourniquet was applied to an upper extremity. Procedure start time was defined when the transducer was placed onto the skin and a vein identified on the ultrasound monitor (Figure 1). Prior to cannulation of the chosen vein, the skin was cleansed and localized as in the traditional method. The IV catheter was inserted distal to the transducer, guided via the ultrasound image. Successful IV cannulation and procedure stop time was defined as for the traditional technique.

The CRNA inserting the catheter determined failure of either technique. In these circumstances, timing continued until successful insertion, using the same method.

Statistical analysis was performed with the aid of a commercially available software package (SAS[®]8.2, SAS Institute, Inc, Cary, NC). Demographic data (age, gender, body mass index), size of IV catheter of successful cannulation, time to cannulation, and number of attempts were recorded. The Student *t*-test was used to compare age and BMI. The traditional group had four male and twelve female subjects while the ultrasound group had four male and fifteen female subjects. Time to successful cannulation, time to successful cannulation when success was obtained on the first attempt and number of attempts per subject were compared between the groups using the Mann-Whitney U Test. The number of successful IV catheter placements on the first attempt was compared between the groups using the Fisher Exact Test. All data is

expressed as the mean \pm standard deviation. An alpha value of less than 0.05 was considered significant.

Results

A total of 35 subjects were enrolled into the study, 16 subjects were randomly assigned to the traditional group and 19 to the ultrasound-guided group. Demographic data are shown in Table 1. While the mean age of the subjects was statistically significant between the groups, the difference is not clinically significant.

In both groups catheter sizes ranged from 18-22 gauge (See Table 2 for breakdown.). The time to successful IV cannulation, number of attempts, number of subjects where IV cannulation was successful on the first attempt, and time to successful IV cannulation when successful on the first attempt did not differ significantly between the groups (See Table 2.).

Discussion

Obtaining IV access in patients can be problematic and require multiple attempts. If the vein cannot be located by visualization and/or palpation, the practitioner may resort to blindly cannulating the vein. That is, insertion of the catheter based on landmarks in a trial and error fashion. Blind insertion of peripheral IV catheters, besides potentially painful and time consuming, may result in arterial puncture and nerve damage, and paresthesias.² Venous cutdown, central venous and interosseous routes may be considered, however the practitioner must weigh the risks and benefits of each route given the specific clinical situation.^{10, 11} Ultrasound-guided peripheral IV cannulation offers the practitioner another technique to aid in gaining venous access.

The use of ultrasound is advantageous in that it lacks adverse biological effects, provides real-time images, gives a quantitative imaging and measurement of blood flow, and does not use ionizing radiation.¹² The results of previous investigations have indicated that the use of ultrasound as aid in the placement of central venous catheters via veins in the neck and chest lessens the risk of complications such as arterial puncture and pneumothorax.⁴ The evidence supporting the use of the ultrasound as an aid in placing central venous catheters by lessening the frequency of complications has led to its endorsement by health care agencies in the United Kingdom and United States.^{5,6}

Ultrasound has also been used as an aid in cannulation of veins outside of the neck and chest. It has been shown to be effective in a wide array of clinical scenarios. Using a convenience sample of 20 patients presenting in cardiopulmonary arrest, Hilty et al. found the use of ultrasound compared to a landmark technique to place a femoral venous catheter resulted in a higher success rate with less needle passes and a lower rate of arterial puncture. Ultrasound was only slightly faster than the landmark technique.⁷

The use of ultrasound in IV cannulation of the deep brachial or basilic vein has been successful when traditional attempts at peripheral vein cannulation fail. In an investigation of 101 adult patients presenting to the emergency department who had undergone two or more unsuccessful attempts at peripheral IV cannulation, Keyes et al. used ultrasound to guide placement of an IV catheter into the deep brachial or basilic vein.⁹ Cannulation was successful 91% of the time, with 73% of the cannulations successful on the first attempt and a mean time to successful cannulation of 77 ± 129 seconds (mean \pm SD). The investigators noted problems in securing the catheter in the deep brachial or basilic vein due to arm movement with the catheter falling out or

intravenous fluid infiltrating in 8% of patients.⁹ Complications of cannulating the deep brachial vein can preclude its future use for long-term vascular access or dialysis.¹³

Cannulation of veins in the hand and forearm may offer a decreased likelihood of these complications.

Using two-dimensional ultrasound, the veins of the hand and forearm can be easily identified (Fig 1). The veins are projected onto the monitor as a black circle that is compressible onto a white background. Unlike an artery, which projects as a pulsating black circle and is not compressible, the veins can be compressed with the ultrasound transducer. The Site-Rite[®] 3 Ultrasound Unit is a battery-powered portable device marketed as a aide in placing vascular catheters and for locating landmarks when performing nerve blocks. Its small size and ease of use are attributes that make it ideal for use as a guide in venous cannulation.

The results of this investigation indicate that ultrasound-guided peripheral IV cannulation is as efficacious as the traditional method of IV cannulation in subjects with a self-reported history of difficult IV cannulation or suspicion of difficult IV cannulation. A possible explanation for this finding is while the subjects reported a history of difficult IV cannulation or IV cannulation was suspected to be difficult, IV cannulation of subjects in both groups was truly not difficult - difficulty of IV cannulation was not assessed in this study. A more rigorous comparison would be to compare the use of ultrasound-guided peripheral IV cannulation to continued traditional IV cannulation techniques using subjects who have failed initial IV cannulation.

Limitations of this investigation include not adding the time to transport the ultrasound device into the procedure time. It should be noted the device is not a part of

the usual IV insertion equipment. Cost of the procedure, including cost of the ultrasound device and the CRNA time was not analyzed in this investigation. The CRNAs placing the catheters were well experienced in the use of the ultrasound device, limiting the generalization of the findings to novice practitioners.

Future investigations should not only examine the ultrasound-guided technique as a rescue in instances when the traditional approach fails, but also should examine the total time and cost of the procedure as mentioned above. Operators with a range of experience in both the specialty and technique should be included in future investigations. Future subjects should be followed longitudinally and examined for complications such as longevity of the catheter, phlebitis, and infection. In addition, future investigations should include children and infants.

An incidental finding was the visibility the investigation brought to the ultrasound-guided method among anesthesia practitioners of the conducting facility. After conclusion of the investigation, there was an increase use of the ultrasound device in placement of potentially difficult or proven difficult peripheral IV catheters. Reasons provided by the practitioners included the perceived avoidance of blind IV catheter insertion with decreased incidence of complications.

Ultrasound is a potentially useful adjunct in placing peripheral IV catheters in the veins of the wrist and forearm. Its use may decrease the need to place IV catheters in the veins of the antecubital fossa that are uncomfortable for the patient and suffer from stabilization problems. Ultrasound used in this fashion may also decrease the need for placement of central venous catheters. A number of future investigations are indicated,

including its use as a rescue in cases of failure in the placement of peripheral IV catheters
in the hands and/or forearm by traditional techniques.

References

1. Vyskocil JJ, Kruse JA, Wilson RF. Alternative techniques for gaining venous access. What to do when peripheral intravenous catheterization is not possible. *J Crit Illn.* 1993;8:435-442.
2. Liu S, Zane R. Peripheral intravenous access. In: Roberts J, Hedges J, eds. *Clinical Procedures in Emergency Medicine.* 4th ed. Philadelphia: Saunders; 2004:401-411.
3. Denys BG, Uretsky BF, Reddy PS, Ruffner RJ, Sandhu JS, Breishlatt WM. An ultrasound method for safe and rapid central venous access. *N Engl J Med.* Feb 21 1991;324(8):566.
4. Hind D, Calvert N, McWilliams R, et al. Ultrasonic locating devices for central venous cannulation: meta-analysis. *BMJ.* Aug 16 2003;327(7411):361.
5. Guidance on the use of ultrasound locating devices for placing central venous catheters. London: National Institute for Clinical Excellence; 2002:21.
6. Making Health Care Safer: A Critical Analysis of Patient Safety Practices. Rockville, MD: Agency for Healthcare Research and Quality, U.S. Department of Health and Human Services; July 20, 2001 2001. Evidence Report/Technology Assessment Number 43.
7. Hilty WM, Hudson PA, Levitt MA, Hall JB. Real-time ultrasound-guided femoral vein catheterization during cardiopulmonary resuscitation. *Ann Emerg Med.* 1997;29:331-336; discussion 337.
8. LaRue GD. Efficacy of ultrasonography in peripheral venous cannulation. *J Intraven Nurs.* 2000;23(1):29-34.

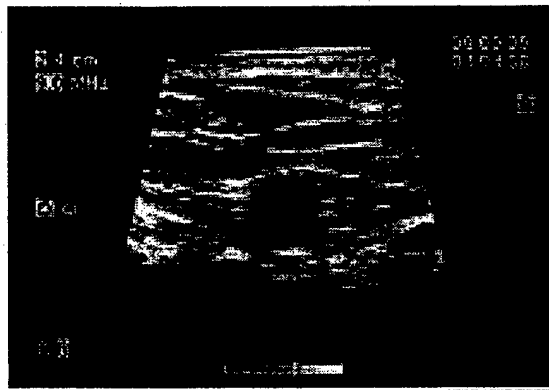
9. Keyes LE, Frazee BW, Snoey ER, Simon BC, Christy D. Ultrasound-guided brachial and basilic vein cannulation in emergency department patients with difficult intravenous access. *Ann Emerg Med.* 1999;34:711-714.
10. Mark J, Slaughter T, Reves J. Cardiovascular monitoring. In: Miller R, Cucchiara RF, Miller ED, Reves JG, Roizen MF, Saverese JJ, eds. *Anesthesia.* Vol 1. 5th ed. Philadelphia: Churchill Livingstone; 2000:1117-1206.
11. Kovarik W, O'Rourke P. Pediatric and neonatal intensive care. In: Miller R, Cucchiara RF, Miller ED, Reves JG, Roizen MF, Saverese JJ, eds. *Anesthesia.* Vol 2. 5th ed. Philadelphia: Churchill Livingstone; 2000:2443-2498.
12. Hedrick W, Hykes D, Starchman D. *Ultrasound Physics and Instrumentation.* 3 ed. St Louis: Mosby; 1995.
13. Ault MJ. Ultrasound-guided brachial and basilic vein cannulation. *Ann Emerg Med.* 2000;36:399.

Figure Legend

Figure 1. Ultrasound image showing lumen of vein.

Figures

Figure 1.



Tables

Table 1. Demographic data of 35 subjects

	Traditional Group	Ultrasound Group	<i>p</i> value
Age (yrs)	57.3 ± 18.9	55.5 ± 15.7	0.025
Gender	Male = 4 Female = 12	Male = 4 Female = 15	
BMI	28.0 ± 7.3	29.4 ± 10.2	0.649

Data are given as mean ± SD, except for sex, which is given as number of subjects. The ultrasound group included 19 subjects and the traditional group included 16 subjects.

Table 2. Comparison of size of IV catheter of successful cannulation, time to successful IV cannulation, number of attempts per subject, number of subjects with successful IV cannulation on first attempt, mean time to successful IV cannulation when successful on the first attempt*

	Traditional Group	Ultrasound Group	p value
Location of successful cannulation	Hand = 4 Wrist = 2 Forearm = 8 Antecubital = 2	Hand = 0 Wrist = 2 Forearm = 12 Antecubital = 5	--
Size of IV catheter of successful cannulation (ga)	18 ga = 8 20 ga = 7 22 ga = 1	18 ga = 4 20 ga = 12 22 ga = 3	--
Time to successful IV cannulation, (seconds)	172.1 ± 222.1	303.7 ± 294.6	0.15
Number of attempts per subject	1.3 ± 0.9	1.4 ± 0.7	0.98
Number of subjects with successful IV cannulation on first attempt	13 (81%)	14 (74%)	0.70
Mean time to successful IV cannulation when successful on the first attempt (seconds)	78.0 ± 33.1	187.3 ± 228.3	0.59

Data are given as mean ± SD.

Acknowledgements

We thank the following individuals for their contributions to this research: Capt Henry Spradlin, Capt, USAF, NC, CRNA and Jeff Blise, LtCol, USAF, NC, CRNA for their assistance with conducting the research. We would also like to thank the following nurse anesthesia students for their help in data collections: Rob Scholes, Capt, USAF, NC; Dean Gilmer, Capt, USAF, NC; Mark Stevenson Capt, USAF, NC; Brian Molloy, Capt, USAF, NC; Gary Wells Capt, USAF, NC and Joe Skinner, Capt, USAF, NC. We also thank the Anesthesia Department, Post-anesthesia Care Unit, Medical-Surgical Unit, Intensive Care Unit, and Emergency Department at Wright-Patterson Medical Center, WPAFB, Ohio for their assistance in data collection.

Short Biographical Sketch

Captain Hector Aponte, SRNA, BSN, NC, USAF, and Captain Said Acosta, SRNA, BSN, NC, USAF are nurse anesthesia students, Nurse Anesthesia Program, Graduate School of Nursing, Uniformed Services University of the Health Sciences, Bethesda, MD. They are completing Phase II Clinical Training at Wright-Patterson Medical Center at Wright-Patterson AFB, OH.

Drs. Barbara Sylvia and Donald Rigamonti are Associate Professors of Nursing, Graduate School of Nursing, Uniformed Services University of the Health Sciences.

Major Timothy Samolitis, is the Assistant Clinical Site Director, Nurse Anesthesia Clinical Training, Wright-Patterson AFB, OH and Adjunct Assistant Professor, Graduate School of Nursing, Uniformed Services University of the Health Sciences.

The Use of Ultrasound for Placement of Intravenous Catheters

Hector Aponte, Captain, USAF, NC (Nurse Anesthesia Student)

Said Acosta, Captain, USAF, NC (Nurse Anesthesia Student)

Barbara Sylvia, PhD, RN (Associate Professor)

Donald Rigamonti, PhD (Associate Professor)

Timothy Samolitis, Major, USAF, NC (Adjunct Assistant Professor)

Nurse Anesthesia Program

Graduate School of Nursing

Uniformed Services University of the Health Sciences

The views expressed in this article are those of the authors and do not reflect the official policy or position of the Uniformed Services University of the Health Sciences, Department of the Air Force, Department of Defense, or the U.S. Government.

Key words:

Adult

Ultrasonography

Peripheral catheterization

Human