

AD _____

Award Number: DAMD17-03-1-0715

TITLE: Role of Mast Cells in Mammary Gland Carcinogenesis

PRINCIPAL INVESTIGATOR: Theoharis Theoharides, M.D., Ph.D.

CONTRACTING ORGANIZATION: Tufts University School of Medicine
Boston, MA 02111

REPORT DATE: September 2004

TYPE OF REPORT: Final

PREPARED FOR: U.S. Army Medical Research and Materiel Command
Fort Detrick, Maryland 21702-5012

DISTRIBUTION STATEMENT: Approved for Public Release;
Distribution Unlimited

The views, opinions and/or findings contained in this report are those of the author(s) and should not be construed as an official Department of the Army position, policy or decision unless so designated by other documentation.

20050302 151

REPORT DOCUMENTATION PAGE

Form Approved
OMB No. 074-0188

Public reporting burden for this collection of information is estimated to average 1 hour per response, including the time for reviewing instructions, searching existing data sources, gathering and maintaining the data needed, and completing and reviewing this collection of information. Send comments regarding this burden estimate or any other aspect of this collection of information, including suggestions for reducing this burden to Washington Headquarters Services, Directorate for Information Operations and Reports, 1215 Jefferson Davis Highway, Suite 1204, Arlington, VA 22202-4302, and to the Office of Management and Budget, Paperwork Reduction Project (0704-0188), Washington, DC 20503

1. AGENCY USE ONLY (Leave blank)		2. REPORT DATE September 2004	3. REPORT TYPE AND DATES COVERED Final (1 Sep 2003 - 31 Aug 2004)	
4. TITLE AND SUBTITLE Role of Mast Cells in Mammary Gland Carcinogenesis			5. FUNDING NUMBERS DAMD17-03-1-0715	
6. AUTHOR(S) Theoharis Theoharides, M.D., Ph.D.				
7. PERFORMING ORGANIZATION NAME(S) AND ADDRESS(ES) Tufts University School of Medicine Boston, MA 02111 E-Mail: theoharis.theoharides@tufts.edu			8. PERFORMING ORGANIZATION REPORT NUMBER	
9. SPONSORING / MONITORING AGENCY NAME(S) AND ADDRESS(ES) U.S. Army Medical Research and Materiel Command Fort Detrick, Maryland 21702-5012			10. SPONSORING / MONITORING AGENCY REPORT NUMBER	
11. SUPPLEMENTARY NOTES				
12a. DISTRIBUTION / AVAILABILITY STATEMENT Approved for Public Release; Distribution Unlimited			12b. DISTRIBUTION CODE	
13. ABSTRACT (Maximum 200 Words) Wistar-Furth rats were treated with carcinogen (NMU) and mammary glands were collected at different time points during 6 months. Mast cell (MC) deficient rats (Ws/Ws) were also employed in this study, in which the incidence of tumor development was also investigated. Normal and malignant tissues were analyzed for the type and number of MC as well as for the mRNA expression of MC specific genes. We found that in the normal mammary gland, MC appeared sparse and rat mast cell protease (RMCP) I type was the most abundant. In tumors MC form clusters. Varied degranulation was seen and electron microscopy further confirmed activation of MC without overt degranulation in NMU treated tissue. However, in contrast to what we expected, MC-deficient rats did develop tumors over the same time period as Wistar-Furth rats, whereas their wild type counterparts seem resistant to tumor development. Further studies are needed in order to confirm the exact role of MC in early carcinogenesis. At present it remains unclear whether MC release mediators protective or detrimental to the tumor, but we are quite certain that the presence of MC regulates mammary carcinogenesis in some way.				
14. SUBJECT TERMS Breast Cancer			15. NUMBER OF PAGES 20	
			16. PRICE CODE	
17. SECURITY CLASSIFICATION OF REPORT Unclassified	18. SECURITY CLASSIFICATION OF THIS PAGE Unclassified	19. SECURITY CLASSIFICATION OF ABSTRACT Unclassified	20. LIMITATION OF ABSTRACT Unlimited	

Table of Contents

Cover.....	1
SF 298.....	2
Table of Contents.....	3
Introduction.....	4
Body.....	5
Key Research Accomplishments.....	9
Reportable Outcomes.....	
Conclusions.....	9
References.....	10
Appendices.....	11

TITLE: ROLE OF MAST CELLS IN MAMMARY GLAND CARCINOGENESIS

INTRODUCTION

It has been established that the stroma is a crucial target of carcinogens (1). Many of the cellular and intercellular components in the stroma are, thus, singly or collectively potential important targets of intervention for first to comprehend the disease and eventually to remedy its consequences. Mast cells, known for their involvement in allergic and inflammatory processes, are one potential target of carcinogens in the stroma: numerous reports have implicated them in tumor growth and metastasis. In this context, the involvement of mast cells was studied as an important target of investigation for mammary carcinogenesis (2). A correlation has been established between the accumulation of mast cells and tumor aggressiveness in breast carcinoma (2). In our studies, we have shown that the chemokine RANTES can induce mast cell accumulation (3) and others have identified tumor-derived chemotactic peptides (4). Mast-cell deficient W/W^v mice exhibited a decreased rate of tumor angiogenesis (5). Additionally, inhibition of mast cell activation was reported to reduce by 70% tumor growth at the primary site of rat mammary adenocarcinoma (5).

This project aimed at answering 'why' and 'how' malignant tumors develop from cells that are otherwise normal? We proposed to investigate the effect of stromal mast cells on epithelial transformation by comparing mammary gland carcinogenesis and the number/activation of mast cells in carcinogen-treated normal Wistar-Furth rats and in mast cell-deficient Ws/Ws rats.

The rat mammary gland was used as a surrogate model for breast carcinogenesis since it most closely resembles the pathogenesis of human breast cancer (1). We investigated the appearance, subtypes, and the degree of activation of mast cells in areas of mammary tumor development over 6 months in carcinogen-treated (NMU (50 mg/kg body weight, i.p.) Wistar-Furth or Ws/Ws mast cell deficient rats. Paraffin embedded sections and whole mounts of mammary gland samples were analyzed immunohistochemically for the mast cell-specific proteases RMCP-I and RMCP-II, as well as electron microscopy to document mast cell activation that could not be discerned with light microscopy. RT-PCR was also employed to identify presence and regulation of mRNA expression of mast cell specific genes.

MAIN BODY

Approved Statement of work: To investigate if mammary gland carcinogenesis can occur in mast cell deficient Ws/Ws rats, as well as in normal Wistar/Furth rats in which the appearance, subtypes, and the degree of activation of mast cells in areas of mammary tumor development will be studied over 6 months. If it appears that mast cells are necessary, carcinogen-treated cleared fat pads will be transplanted with normal epithelium, or normal saline-treated fat pads will be transplanted with carcinogen-treated epithelium and the same observations will be repeated.

(A) Use of Ws/Ws mast cell deficient rats. It will be critical to show that carcinogenesis induced by NMU (50 mg/kg body weight, i.p.) is either absent or delayed in mast cell deficient Ws/Ws rats in which no mast cells were detected in any organs examined. These rats are from the Donryu and Brown Norway strains and were bred in Japan; breeding pairs will be made available to us for breeding in Boston.

(Corresponding data is shown in Results 3)

(B) The 4th and 5th mammary glands will be harvested at different times in order to collect the tissue to be analyzed. We will obtain and examine mammary gland at 10, 20, 30, 45, 60, 90, 120, 150 and 180 days either after carcinogen or vehicle administration. We will use 6 animals per time point from day 10 to 60, as we believe this to be the most critical period in carcinogenesis, and 3 animals from day 90 to 180. We have previously employed the immunocytochemical techniques to investigate mast cell development in bladder and brain. In both cases, the fixation method was critical, as the mucosal mast cells cannot be recognized after aldehyde fixation. We will, therefore, freeze the samples immunohistochemistry for the mast cell-specific proteases RMCP-I and RMCP-II, as well as electron microscopy to document mast cell activation that could not be discerned with light microscopy as reported before.

(Corresponding data is shown in Results 1)

(C) RT-PCR will also be performed for these enzymes, as well as for RANTES, histamine, IL-6 and heparin-like proteoglycans that have been shown to induce angiogenesis.

(Corresponding data is shown in Results 2)

Results 1

“Characterization of mast cells in normal and malignant tissue sections from rat mammary glands”: Wistar-Furth rat mammary glands were stained with toluidine blue to label heparin in resident mast cells; using this technique we showed that there was sparse distribution of mast cells in normal mammary glands (Fig. 1). The same pattern was confirmed with immunohistochemistry for two rat mast cell proteases, namely, RMCP-I and RMCP-II. The highest percentage of mast cells were positive for RMCP-I (Fig. 2A and C), indicating that they are of the connective tissue type; there were, however, fewer positive stained cells for RMCP-II (Fig. 2B and D), which also suggested the presence of mucosal type mast cells.

In contrast to normal mammary glands, inside mammary tumors toluidine blue staining revealed more abundant and clustered mast cells (Fig. 3). As shown in the right panel insert of Fig. 3, the degree of mast cell staining clearly varied representing differences in the level of degranulation.

“Electron microscopy studies to document mast cell activation that could not be discerned with light microscopy”: Electron microscopy images were obtained in strips of mammary gland that were administered at different time points either NMU or vehicle. The results indicated that mast cells from carcinogen-treated samples had altered granules indicative of secretion (Fig. 4) but without overt degranulation as seen in anaphylactic reactions.

“Determination of mast cell number present in mammary glands obtained at different time points after treatment”: There was a statistically significant increased number of mast cells in Wistar-Furth rats during the time points of D=10, D=20, D=30, and D=45, as well as for the cumulative period Day=5-45. (Fig 5A is a bar graph, while Fig. 5B is a scatter plot of the same results).

Total mast cell count expressed as % volume fraction

- 1- overall counting for NMU-treated rats: 0.378 ± 0.015
- 2- overall counting for VEH-treated rats: 0.277 ± 0.011 , $p=0.038$
- 3- cumulative counting between days 5-45 for NMU: 0.476 ± 0.021
- 4- cumulative counting between days 5-45 for VEH: 0.300 ± 0.014 , $p<0.01$
- 5- cumulative counting between days 60-180 for NMU: 0.154 ± 0.009
- 6- cumulative counting between days 60-180 for VEH: 0.180 ± 0.011 , $p=0.147$

Total mast cell count expressed as % volume fraction per individual time points

Day after treatment	% volume fraction per treatment		p value
	NMU	VEH	
5	0.800 ± 0.077	0.424 ± 0.043	<0.001
10	0.471 ± 0.033	0.322 ± 0.023	0.001
20	0.507 ± 0.029	0.315 ± 0.025	<0.001
30	0.301 ± 0.024	0.269 ± 0.046	0.033
45	0.284 ± 0.041	0.148 ± 0.016	0.026
60	0.169 ± 0.019	0.165 ± 0.019	0.862
90	0.113 ± 0.017	0.181 ± 0.028	0.030
120	0.172 ± 0.027	0.148 ± 0.019	0.360
150	0.138 ± 0.018	0.145 ± 0.025	0.818
180	0.204 ± 0.035	0.266 ± 0.026	0.141

Immunohistochemistry for mast cell subtypes indicated that the mast cells in the NMU-treated mammary glands had more RMCP-I cells in D= 5 and 10 (Fig. 6).

Results 2

RT-PCR analysis was carried out in rat mammary gland tissue collected at different time points following NMU or vehicle administration. The RNA was quantified by spectrophotometry and 2 µg were used for cDNA synthesis. This was amplified for rat histidine decarboxylase (RHDC) mRNA expression; this is the enzyme that makes histamine. As internal control, the β-actin housekeeping gene was also amplified by RT-PCR in parallel and the levels of amplification between different time points were compared by semi-quantitative analysis. There was RHDC expression in all samples; there was an increase in most NMU-treated samples up to D=90 (Fig. 7A). In another experiment, we expanded the early time points for Day=0 and Day=5 where it could be seen again that the NMU-treated samples had higher RHDC expression (Fig. 7B).

We also searched for vascular endothelial growth factor (VEGF) mRNA expression in the same samples. The three main VEGF isoforms 189, 165 and 121 were all expressed in our samples, but the pattern of expression was inconsistent in spite of equal β-actin expression (same preparation as Fig. 7A).

In order to investigate directly whether NMU could stimulate VEGF release, human leukemic mast cells- 1 (HMC-1) cultures were treated with NMU (50 µg/ml) for 6 hours and the supernatants were assayed by ELISA. NMU increased VEGF release in culture from 0.5 pg/ml (basal untreated) to 1.7 pg/ml (Fig.8, lower panel).

Results 3

Tumor incidence in Ws/Ws rats and +/+ wild type

Table 1 shows the tumor incidence in the different rat strains we used. All Ws/Ws rats developed palpable tumors (Fig. 9), while their respective +/+ wild-type controls did not (Fig. 10). Nevertheless, most of the controls contained microscopic lesions that have yet to be evaluated histologically to determine whether they contain tumor cells.

Supporting data

Treatment of peritoneal mast cells, from either vehicle-treated or NMU-treated rats, with NMU *in vitro* and measure mediator release

Rat peritoneal mast cells were purified from tumor susceptible rats and Donryu/Norway +/+ wild type rats that had been injected with either NMU or vehicle *in vivo*. The collected mast cells were treated *in vitro* at 37°C with 50µg/ml of NMU. Histamine release was measured after 6 hours by ELISA. Compound 48/80 was used as positive control to show activation of mast cells under the same conditions.

% Histamine release from peritoneal rat cells

NMU-injected +/+ wild type Rats		Added NMU
No further treatment in cell suspension	2.40%	1.70%
Vehicle added in cell suspension	3%	1.80%
C48/80 (positive control) added in cell suspension	55.20%	67.10%
Vehicle-injected +/+ wild type Rats		Added NMU
No further treatment in cell suspension	8.20%	3.90%
Vehicle added in cell suspension	8.70%	4.70%
C48/80 (positive control) added in cell suspension	37.90%	40.70%
NMU-injected tumor-susceptible Rats		Added NMU
No further treatment in cell suspension	2.10%	2.40%
Vehicle added in cell suspension	2.00%	3.00%
C48/80 (positive control) added in cell suspension	36.60%	47.90%
Vehicle-injected tumor-suscept Rats		Added NMU
No further treatment in cell suspension	1.80%	2.00%
Vehicle added in cell suspension	1.60%	2.10%
C48/80 (positive control) added in cell suspension	38.00%	41.00%

"So what"

1. Mast cells were increased in the sites of tumor development in Wistar-Furth animals. A recent publication also reported that there are *increased* numbers of mast cells associated with human breast carcinoma (7).
2. Mast cell deficient rats developed tumors while the +/+ wild type did not. These data concurs with results from an old publication showing that there was an increased skin tumor incidence in mast cell deficient mice injected with MCA than in controls (8).

This conclusion contrasts with what we had hypothesized; however, it is not inconsistent with the potential role of mast cells. For instance, we recently proposed that mast cells may potentially exercise either a promotional or an inhibitory role in breast cancer growth depending on selectively distinct signals, such as tumor-derived oxidized polyamines or nitric oxide from new endothelial cells; these signals may in turn regulate release from separate granules or much smaller vesicles of distinct mediators (9).

It is intriguing why the Wistar-Furth rats developed tumors while the +/+ wild type (i.e., Donryu/Norway rats) did not. There are still some options to consider:

1. Even though we did not examine the number or state of activation in the +/+ rats because this outcome was not anticipated, the number of mast cells, their degree of activation or the type of mediators released could be different than what we report in the tumor susceptible rats -presumably protective against tumor formation. In either case, these possibilities could be answered experimentally.

Alternative option: to inject the fat pads of +/+ wild type rats with either the mast cell chemoattractant RANTES or the mast cell secretagogue compound 48/80.

2. There is some genetic or epigenetic defect in the Ws/Ws rats that permits tumor growth other than mast cell deficiency.

Alternative option: to reconstitute the Ws/Ws rats with normal bone marrow progenitors as has been successfully carried out for mast cell-deficient W/W^v mice.

3. The +/+ wild type rats may behave like the Copenhagen rats that also do not develop tumors (10).

Key Accomplishments

- We studied tumor growth in two rat models injected i.p. with NMU or vehicle: Wistar-Furth strain rats and Ws/Ws mast cell-deficient rats over a 6 months period.
- We analyzed whole mounts and paraffin-embedded tissue sections using histochemistry and immunohistochemistry of Wistar-Furth mammary glands from different time-points up to 180 days after carcinogen treatment and of isolated mammary tumors.
- We determined the numbers and types of mast cells present in normal and carcinogen-treated rat mammary glands of both rat models.
- We collected data from both light and electron microscopy of the varied degranulation seen in the normal and carcinogen treated samples.

Conclusions

- High numbers of mast cells are present in early stages of carcinogenesis, days 5-45.
- Electron microscopy images and light microscopy of toluidine blue-stained paraffin embedded sections, showed varied degranulation in carcinogen-treated mammary gland samples at different stages of tumor development.
- Mast cells present in both normal and malignant tissue samples were mainly positive for RMCP-1 protein.
- Rat histidine decarboxylase was expressed in the tissue samples collected from Wistar-Furth rats at different time points with more prominent mRNA expression in the NMU treated samples.
- Mast cells deficient rats developed tumors whereas their wild type counterparts grew microscopically identifiable lesions that are going to be analyzed to determine whether they contain tumor cells or not.

No research publication of our results is in preparation yet.

References

1. Maffini MV, Soto AM, Calabro JM, Ucci AA, Sonnenschein C. The stroma as a crucial target in rat mammary gland carcinogenesis. *J Cell Sci.* 2004 5;117:1495-502.
2. Sonnenschein C, Soto AM. The somatic mutation theory of carcinogenesis: Why it should be dropped and replaced. *Molecular Carcinogenesis* 2000; 29:1-7.
3. Theoharides TC. Neuroimmunology of tumor growth: the role of mast cells. *Int J Immunopath Pharmacol* 1988; 1:89-98.
4. Conti P, Reale M, Barbacabe BC, Letourneau R, Theoharides TC. Intramuscular injection of hrRANTES causes mast cell recruitment and increased transcription of histidine decarboxylase in mice: lack of effects in genetically mast cell-deficient W/W^v mice. *FASEB (Fed Am Soc Exp Biol) J* 1998; 12:1693-1700.
5. Starkey JR, Crowle PK, Taubenberger S. Mast-cell-deficient W/W^v mice exhibit a decreased rate of tumor angiogenesis. *Int J Cancer* 1998; 42:48-52
6. Theoharides T.C. Antidepressants and risk of cancer: a case of misguided associations and priorities. *J. Clin. Psychopharmacol.* 2002; 13: 1-4.
7. Kashiwase et al. Quantitative analysis of mast cells in benign and malignant breast lesions. *Int. Arch Allergy Immunol.* 134:199-205, 2004
8. Tanooka et al. Evidence of mast cells in tumor suppression in mice. *J. Natl. Cancer Inst.* 69: 1305-1309, 1982
9. Theoharides TC, Conti P. Mast cells: the Jekyll and Hyde of tumor growth. *Trends Immunol* 25:235-241, 2004.
10. Quan C, Wang HL, Lu SJ. Resistance to mammary carcinogenesis in Copenhagen rats: potential roles of vascular endothelial growth factor and mast cells. *Cancer Lett.* 5;186(2):165-75, 2002.

Appendices

Appendix 1: Figures

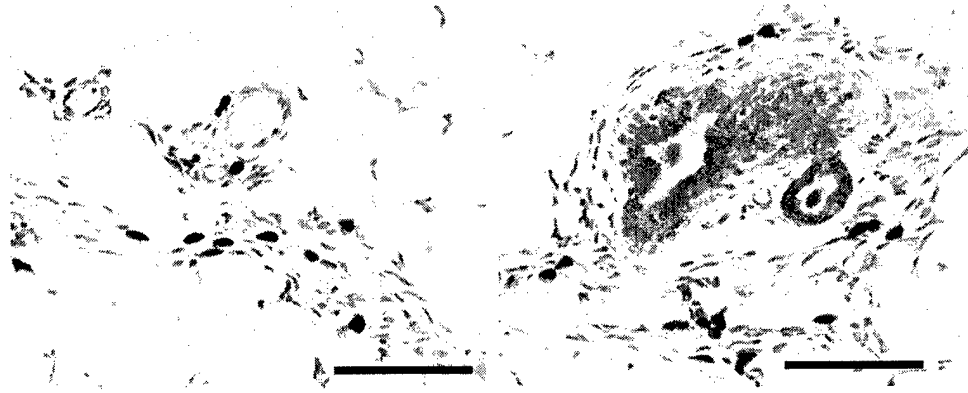


Figure 1: Toluidine blue staining showing mast cell distribution in normal Wistar-Furth rat mammary glands. The mast cells are more abundant in the periductal stroma and in near blood vessels. Scale bar: 100 μm

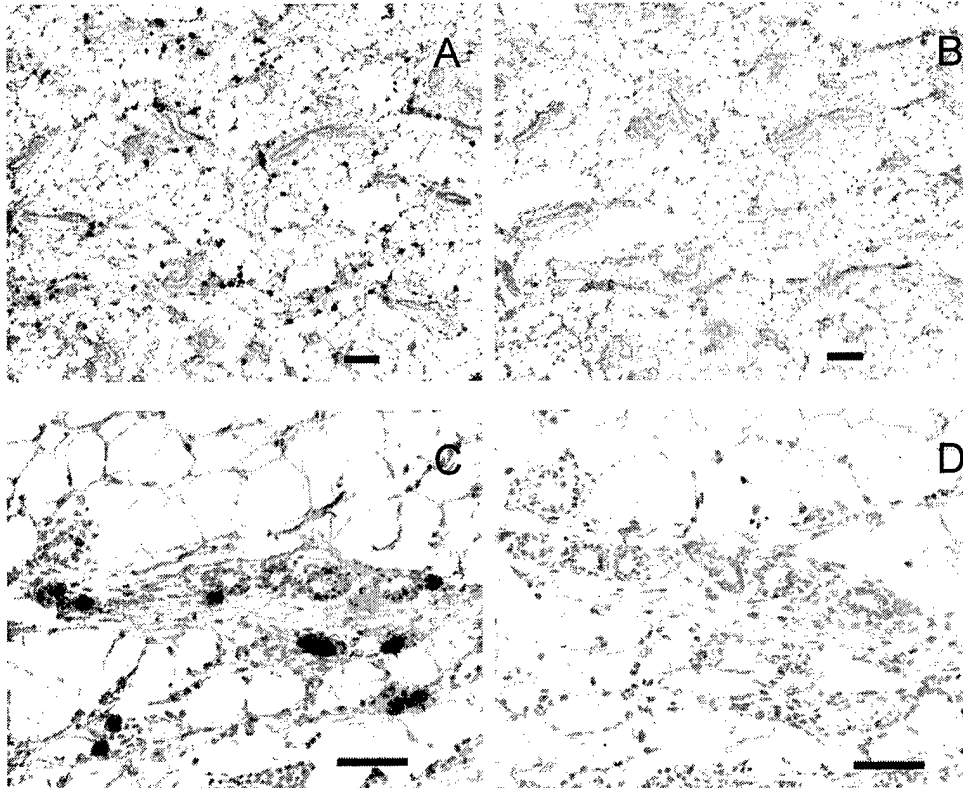


Figure 2: Immunohistochemistry using antibodies against the rat mast cell proteinase (RMCP) I and II. Scale bars: Panels A and B 100 μm ; Panels C and D: 50 μm

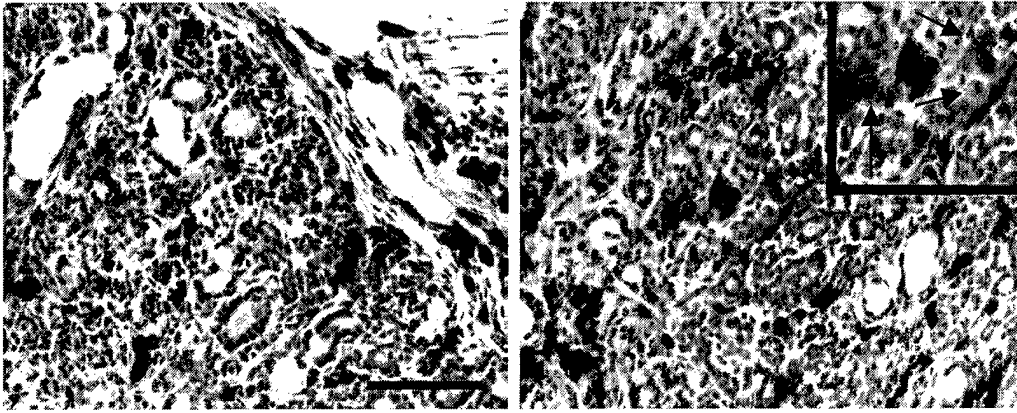


Figure 3: Toluidine blue staining of a mammary tumor showing invasion of mast cells, clusters and degranulation (Right panel, inset with arrows). Scale bar: 100 μm

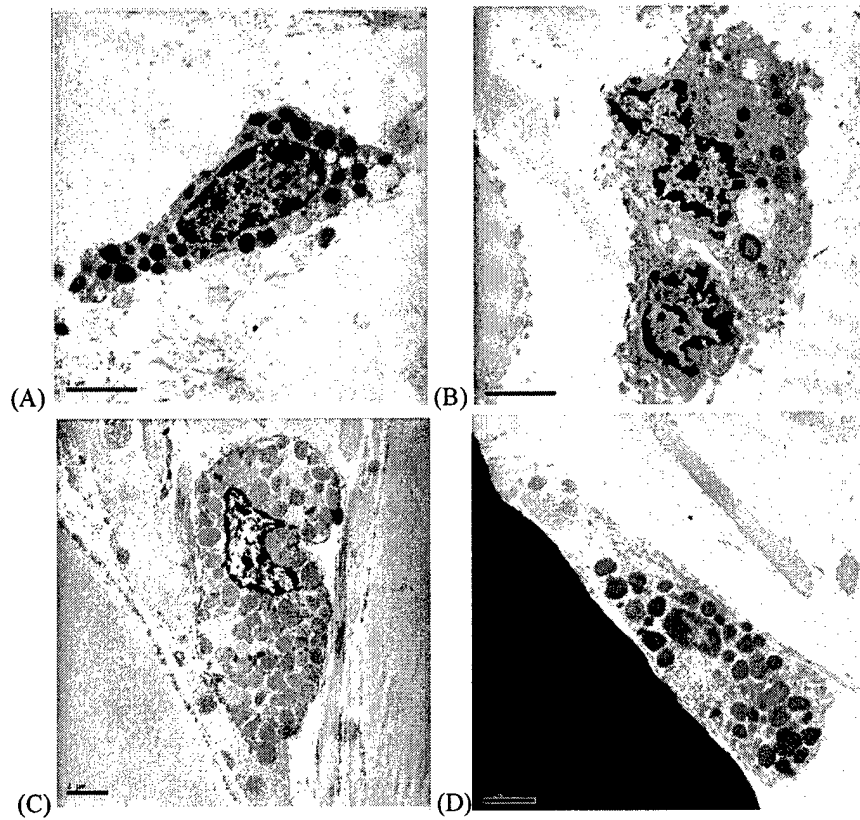
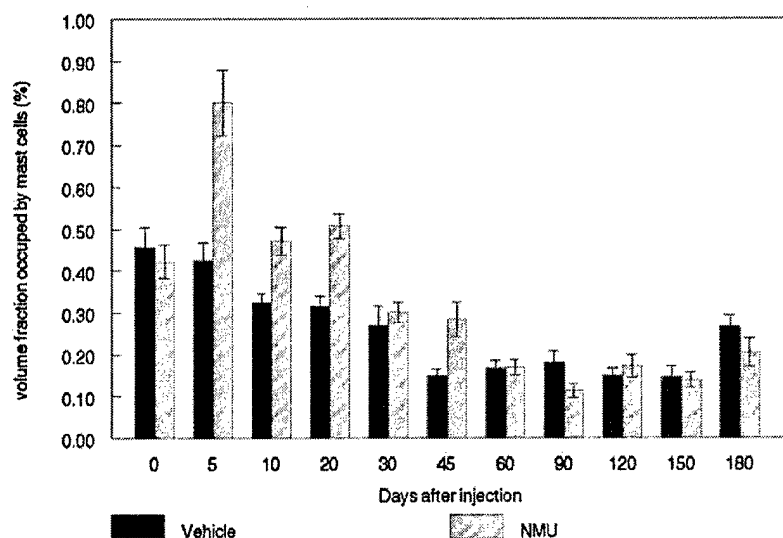


Figure 4: Electron microscopy of mast cells present in rat mammary gland tissue collected at different time points after NMU or vehicle administration. Representative pictures show in (A) non activated mast cell from vehicle treated, day 45, sample; (B) activated mast cell from NMU treated day 45 sample; (C) non activated mast cell from vehicle day 60 and (D) partly degranulated mast cell from NMU treated sample. Scale bar: 2 μ m

A Average of Mast Cell counts by field



B Mast Cell Distribution

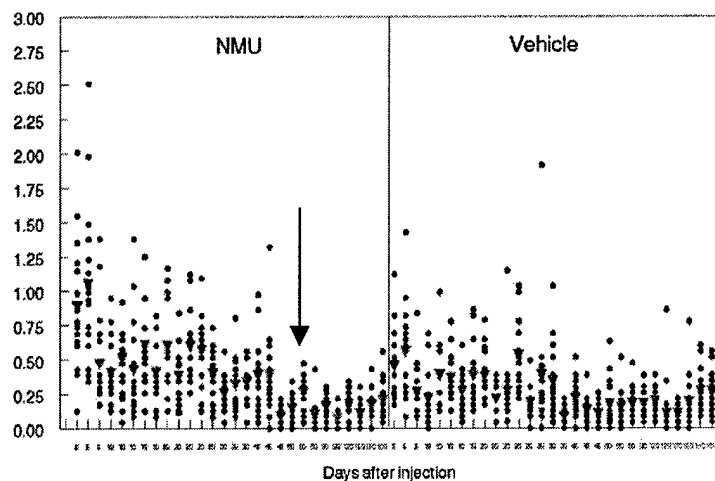
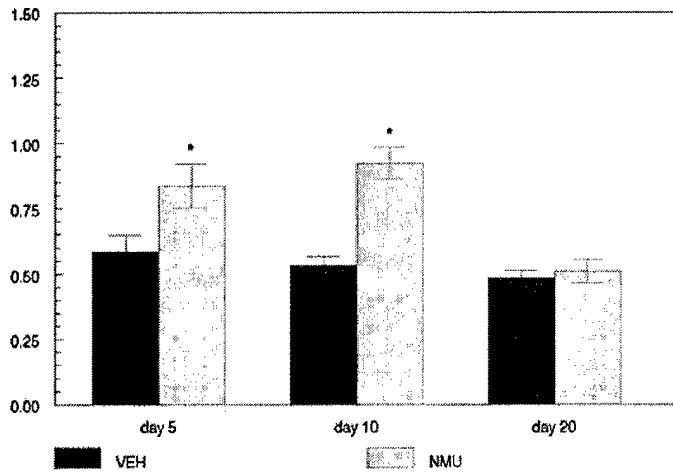


Figure 5: There was a statistically significant increase in the number of mast cells in Wistar-Furth rats treated with NMU during the time points of D=10 ($p < 0.001$), D=20 ($p = 0.001$), D=30 ($p = 0.033$), and D=45 ($p = 0.026$), as well as for the cumulative period Day=0-45 ($p < 0.001$). Fig. 5B is a scatter plot of the results shown in A.

% Total RMCP I



% Total RMCP II

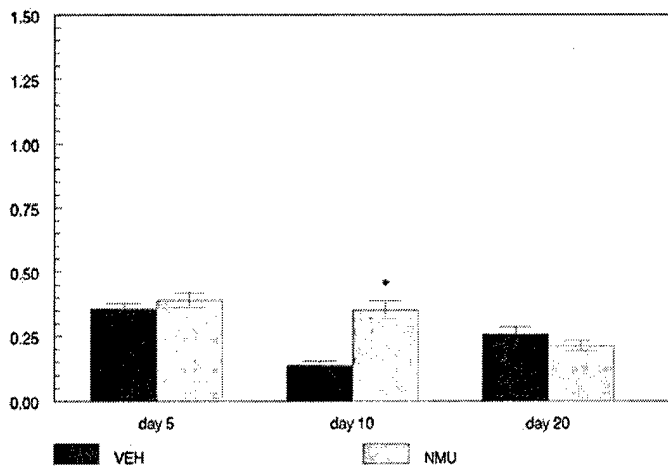


Figure 6: Immunohistochemistry for mast cell subtypes indicated that there was a statistically significant difference (*) in RMCP I positive cells in the mammary glands collected 5 and 10 days after the NMU-treatment. RMCP II positive cells were significant only at day 10.

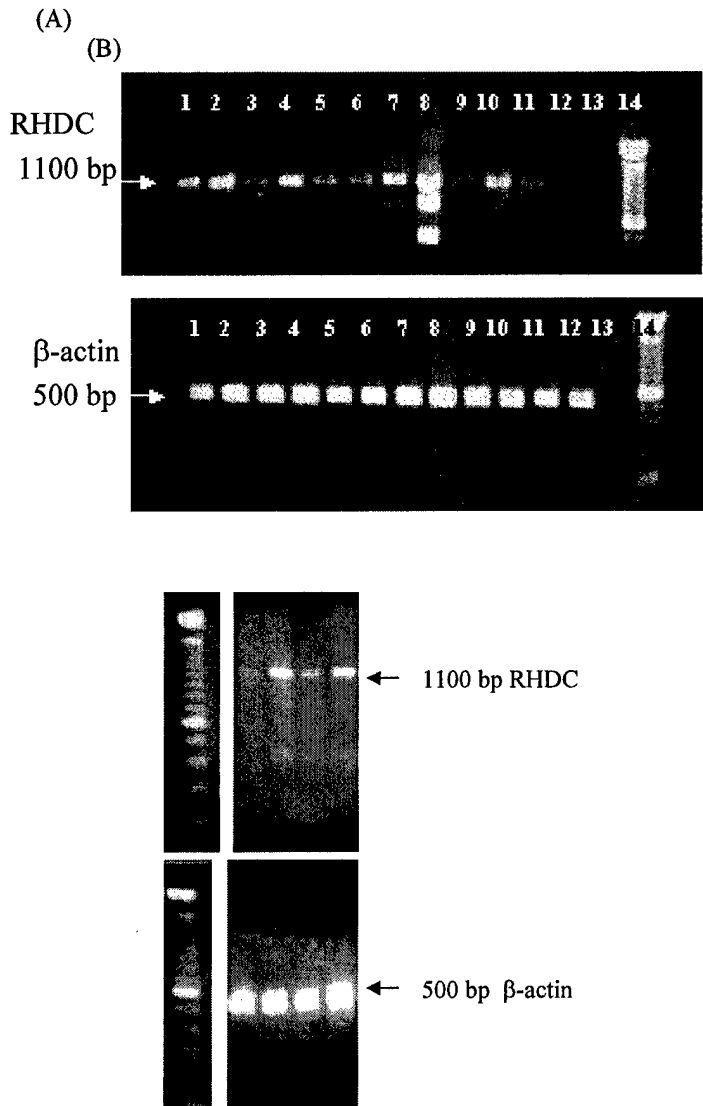


Figure 7. RT PCR analysis of rat mammary gland tissue collected at different time points after NMU administration. (A) Rat histidine decarboxylase (RHDC) mRNA was expressed in all samples at expected size 1100 bp. Lanes: 1) Vehicle D0, 2) NMU D0, 3) Vehicle D30, 4) NMU D30, 5) Vehicle D45, 6) NMU D45, 7) Vehicle D60, 8) NMU D60, 9) Vehicle D90, 10) NMU D90, 11) Vehicle D120, 12) NMU D120, 13) -RT, negative control for genomic contamination, 14): DNA Marker 100 bp. Amplification of the housekeeping gene β -actin in the same preparations was used as an internal control of the PCR reaction (lower panel). Expected band 500 bp. (B) RT PCR in early time points Lanes:1) DNA marker; 2) Vehicle D0; 3) NMU D0; 4) Vehicle D5; 5) NMU D5.

VEGF ISOFORMS

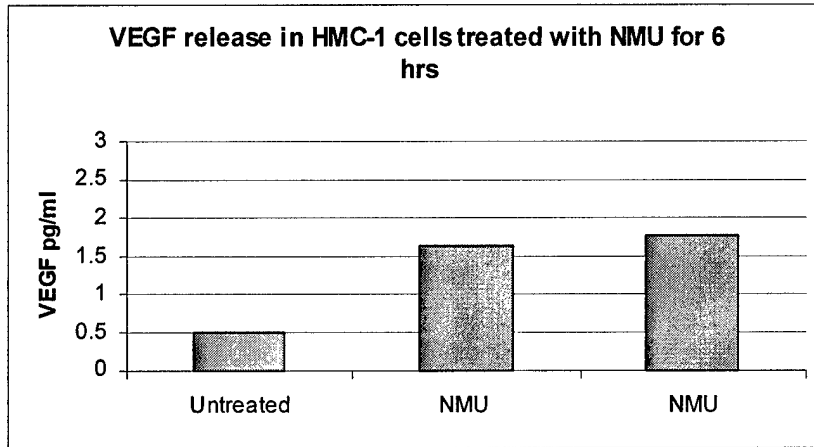




Figure 8. Investigation of VEGF-mediated effect of mast cell in carcinogenesis. Top poanel: RT PCR analysis of rat mammary gland tissue collected at different time points after NMU or vehicle administration. Messenger RNA expression of 189, 165, and 121 VEGF isoforms corresponding to products of 635 bp, 564 bp, and 432 bp respectively. Lanes: 1) Vehicle D0, 2) NMU D0, 3) Vehicle D30, 4) NMU D30, 5) Vehicle D45, 6) NMU D45, 7) Vehicle D60, 8) NMU D60, 9) Vehicle D90, 10) NMU D90, 11) Vehicle D120, 12) NMU D120, and lane (M): DNA Marker 100 bp. Amplification of the housekeeping gene β -actin in the same preparations was homogeneous.

A



B

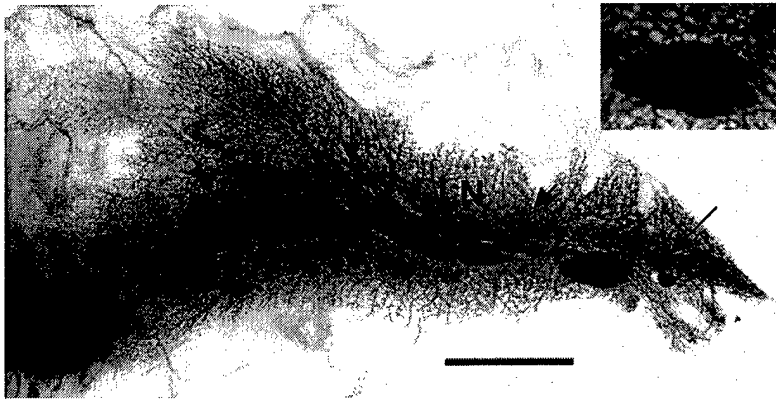


Figure 9: Whole mounts of mammary glands from Ws/Ws rats. Panel A: vehicle treated rat; Panel B: NMU-treated rats. These animals developed palpable tumors as well as multiple microscopic lesions. Scale bar: 1 cm. LN: lymph nodes

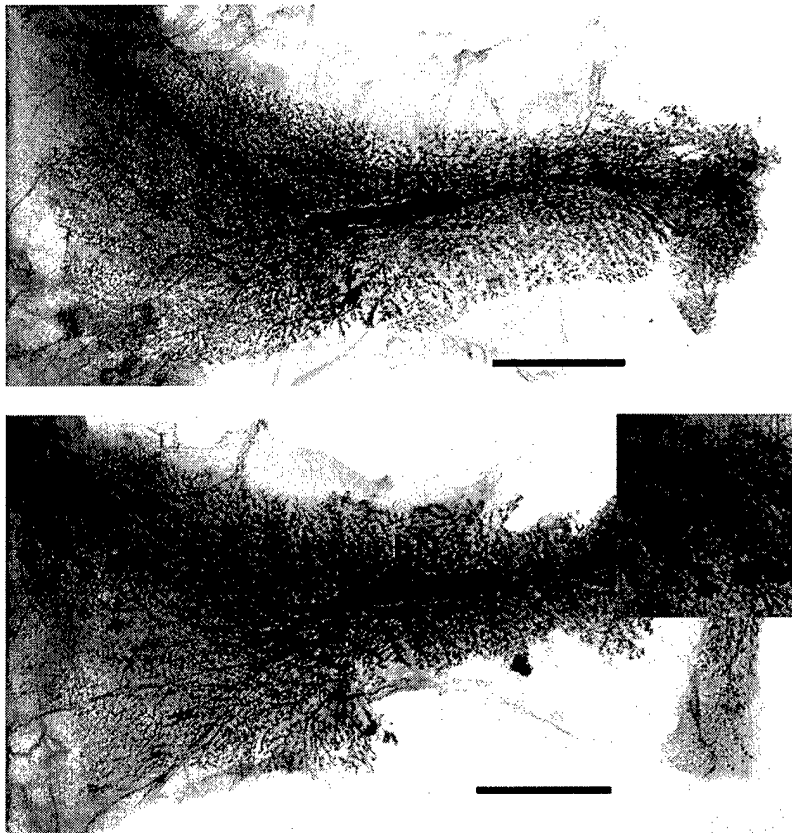


Figure 10: Whole mounts of mammary glands from wild type control rats. Panel A: vehicle treated rat; Panel B: NMU-treated rats. These animals did not develop palpable tumors; however, some microscopic lesions were observed. Scale bar: 1 cm. LN: lymph nodes

Table 1: Incidence of tumors in Ws/Ws and wild type rats

Rat #	Microscopic lesions	Palpable tumors	Latency (weeks)
Ws/Ws			
771	4 or more	322-04T 325-04T	19
	4 or more		
769	2 or more	482-04T	19
	3 or more		
770	3 or more		
	3 or more		
772	5 or more	484-04T 485-04T 486-04T	12
	5 or more		
773	3 or more	229-04T 483-04T	11
	3 or more		
778	Premature dead		
Wild type			
776	2		
777	2		
778	8		
779	5		
780	2		
781			