

AD \_\_\_\_\_

Award Number: DAMD17-02-1-0400

TITLE: Intraoperative Imaging for Sentinel Lymph Nodes

PRINCIPAL INVESTIGATOR: Carmen M. Greene  
John N. Aarsvold, Ph.D.  
Nolan Hertel, Ph.D.

CONTRACTING ORGANIZATION: Georgia Institute of Technology  
Atlanta, Georgia 30332-0420

REPORT DATE: August 2004

TYPE OF REPORT: Annual Summary

PREPARED FOR: U.S. Army Medical Research and Materiel Command  
Fort Detrick, Maryland 21702-5012

DISTRIBUTION STATEMENT: Approved for Public Release;  
Distribution Unlimited

The views, opinions and/or findings contained in this report are those of the author(s) and should not be construed as an official Department of the Army position, policy or decision unless so designated by other documentation.

20050516 085

# REPORT DOCUMENTATION PAGE

Form Approved  
OMB No. 074-0188

Public reporting burden for this collection of information is estimated to average 1 hour per response, including the time for reviewing instructions, searching existing data sources, gathering and maintaining the data needed, and completing and reviewing this collection of information. Send comments regarding this burden estimate or any other aspect of this collection of information, including suggestions for reducing this burden to Washington Headquarters Services, Directorate for Information Operations and Reports, 1215 Jefferson Davis Highway, Suite 1204, Arlington, VA 22202-4302, and to the Office of Management and Budget, Paperwork Reduction Project (0704-0188), Washington, DC 20503

<b>1. AGENCY USE ONLY</b> (Leave blank)		<b>2. REPORT DATE</b> August 2004	<b>3. REPORT TYPE AND DATES COVERED</b> Annual Summary (1 Aug 2003 - 31 Jul 2004)	
<b>4. TITLE AND SUBTITLE</b> Intraoperative Imaging for Sentinel Lymph Nodes			<b>5. FUNDING NUMBERS</b> DAMD17-02-1-0400	
<b>6. AUTHOR(S)</b> Carmen M. Greene, John N. Aarsvold, Ph.D. and Nolan Hertel, Ph.D.				
<b>7. PERFORMING ORGANIZATION NAME(S) AND ADDRESS(ES)</b> Georgia Institute of Technology Atlanta, Georgia 30332-0420  E-Mail: gte432w@prism.gatech.edu			<b>8. PERFORMING ORGANIZATION REPORT NUMBER</b>	
<b>9. SPONSORING / MONITORING AGENCY NAME(S) AND ADDRESS(ES)</b> U.S. Army Medical Research and Materiel Command Fort Detrick, Maryland 21702-5012			<b>10. SPONSORING / MONITORING AGENCY REPORT NUMBER</b>	
<b>11. SUPPLEMENTARY NOTES</b>				
<b>12a. DISTRIBUTION / AVAILABILITY STATEMENT</b> Approved for Public Release; Distribution Unlimited			<b>12b. DISTRIBUTION CODE</b>	
<b>13. Abstract (Maximum 200 Words) (abstract should contain no proprietary or confidential information)</b>  The main objective of this investigation is to determine the feasibility and value of the use of a small field of view camera gamma camera intraoperatively for sentinel lymph node (SLN) localization in breast cancer patients. A camera with a 5 in x 5 in field of view (FOV) is being investigated. Clinical experience with 14 subjects using the 1 in x 1 in FOV and 15 subjects using the 5 in x 5 in FOV suggests that the 5 x 5 FOV is more valuable to SLN localization in breast cancer patients. The task of verifying the content of two databases one consisting of one hundred and twenty-one breast cancer patients and the other consisting of 50 was carefully done. Data from database consisting of 50 patients was presented at the 8 <sup>th</sup> Congress of the World Federation of Nuclear Medicine and Biology 2002 in Santiago, Chile by the senior nuclear medicine technologist at Atlanta VAMC. Preliminary data from the probe alone versus probe and camera study was analyzed and an abstract was submitted for Sentinel Node 2004. From the work accomplished this far having a small FOV camera intraoperatively for SLN localization cases that do not make use of preoperative imaging might have some value.				
<b>14. SUBJECT TERMS</b>  sentinel lymph node, nuclear medicine, introoperative imaging, surgery			<b>15. NUMBER OF PAGES</b> 19	
			<b>16. PRICE CODE</b>	
<b>17. SECURITY CLASSIFICATION OF REPORT</b> Unclassified	<b>18. SECURITY CLASSIFICATION OF THIS PAGE</b> Unclassified	<b>19. SECURITY CLASSIFICATION OF ABSTRACT</b> Unclassified	<b>20. LIMITATION OF ABSTRACT</b> Unlimited	

## Table of Contents

Cover.....	
SF 298.....	
Table of Contents.....	
Introduction.....	1
Body.....	1
Key Research Accomplishments.....	4
Reportable Outcomes.....	4
Conclusions.....	5
References.....	6
Appendices.....	7

## INTRODUCTION:

Sentinel lymph node (SLN) biopsy is the standard of care for the staging of some melanoma patients and is likely to soon be the standard of care for breast cancer patients. There are several approaches to SLN resection, some are more extensive than others. Some approaches use preoperative nuclear medicine imaging and intraoperative gamma counting. Others rely solely upon intraoperative gamma counting. Localization of SLNs is very important to this process. When preoperative imaging is done correctly it can be very useful in localizing the SLNs. However, performing preoperative imaging on some patients in some environments is difficult thus it is not performed on some patients. The use of intraoperative imaging in addition to gamma counting might be a better approach to SLN localization than using only a gamma counting probe. The long-term objective of this project is to determine the feasibility and value of using a small field of view (FOV) gamma camera for intraoperative localization of SLNs in breast cancer patients who may or may have not received preoperative imaging.

## BODY:

As an introduction and part of the PI's educational training on SLN localization, the PI spent time analyzing data from melanoma studies that were being conducted at Atlanta Veterans Affairs Medical Center (VAMC) and Emory University. As a result of assisting with analysis of the data the PI participated and presented at the 3<sup>rd</sup> International Congress on Sentinel Node in Japan and the 53<sup>rd</sup> annual Sentinel Node Conference in Philadelphia. The information presented in Japan was submitted in the previous report and the information presented in Philadelphia is located in the appendix. Attending the meeting proved to be very informative and helpful educationally in regards to the tasks of this research.

There is an existing database of one hundred and twenty-one breast cancer patients cared for between the October 1998 and December 2000. The database was meticulously checked with the PI's assistance and three other people to verify the validity of the contents of the database. Various statistical methods were used to analyze the data. Correlations and differences between two different injection techniques for the radiotracers were compared. A comparison of filtration size of the colloid was also being investigated in conjunction with various other characteristics such as; average age, correlation between time to visualization and positive nodes, location of tumor, bra size and other factors for breast cancer patients. A summary/ publication is being written based upon the results of the analysis.

A clinical evaluation of a small pinhole hand-held gamma camera using 14 patients was completed. All the surgery and pathology information on the 14 patients was collected and reviewed. Data were acquired from 14 surgery patients during preoperative imaging and surgery. The full report, A clinical evaluation of a hand-held gamma camera, including images taken with the camera was previously submitted. A small hand-held pinhole camera was used to try and localize the sentinel node during pre-operative imaging. Of the 14 patients that enrolled images of ten patients were taken. The small hand-held camera used has a field of view of 2-cm x 2-cm.

The camera uses 14 x 14 array of NaI(Tl) scintillation crystals. Each crystal is 1mm x 1mm x 5mm; the crystals are separated by 0.25mm thick optically opaque material. The scintillation crystals are coupled to position sensitive photomultiplier tube. The hand-held camera has a stainless steel handle, which acts as a housing unit for the wires and electronics. The hand-held device without the collimators weighs 0.74kg. Two types of collimators/apertures were evaluated. The pinhole aperture has a 3-mm diameter pinhole and 30-mm focal length and the parallel hole collimator has a field of view that is the same as that of the scintillation crystal array. The parallel hole collimator has a FOV with that has the same crystal scintillation array. The users found the device difficult to locate and image the SLN, they found it heavy and cumbersome. It was difficult for the users to hold and direct. The users found the sensitivity of the pinhole aperture too low to easily conduct the task of sentinel node localization. Noise from the injection site often interfered with the images.

As a result of the difficulties with the use of the 1" x 1" FOV hand-held camera, with a pinhole aperture, a larger FOV camera was acquired and is now being used in this project. seen in figure 1, is being used to finish the investigation. The current camera has a 5 in x 5 in field of view. The FOV of the 5" x 5" camera is proving to be more appropriate for the task of SLN localization as specified for this project. The camera is heavy, fourteen pounds, and cannot be held by hand; therefore it is attached to a surgical microscope support arm and mobile stand. The system also has the computer monitor and CPU attached. Since we have switched cameras 21 breast surgeries have been completed. The first six breast cases done were both camera and probe in the operating room. The surgeon was not blinded to the preoperative images because the first few cases allowed the surgeon to get acclimated to the camera. The remaining cases were blinded to preoperative imaging and they were split between probe alone and probe and camera. Currently the data from the fifteen breast surgeries has been recorded and processed. The data has been transferred from the instruments into a data file. Various quantitative data will be extracted and statistically analyzed.

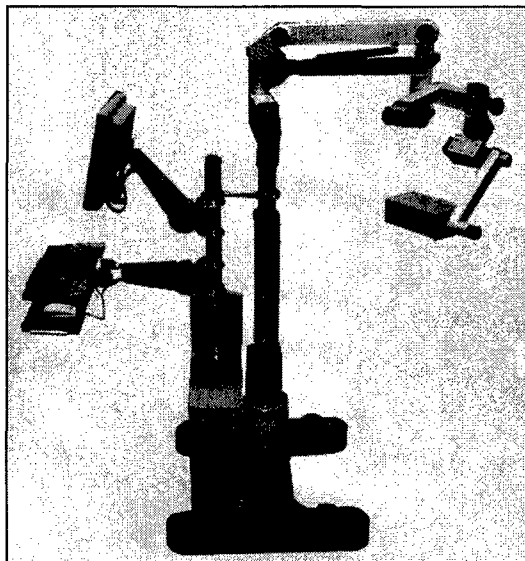


Fig. 1 Gamma Medica 5 x 5 system.(right side) 5 x 5 camera mounted on the microscope arm. (left side of pole) The monitor, keyboard and cpu

As regards the status of the Tasks of the Statement of Work, the following summary is provided.

**Task 1. Analysis of an existing breast cancer/sentinel lymph node (SLN) patient database.**

To date we have completed the verification of the contents of the database, inclusive of all three subsets, consisting of 175+ patients. Many key factors were selected from the database, put into a separate spreadsheet and analyzed. The more important and significant results were reported.

[Grant SF et al., 2002 is a preliminary report of data and analysis of the second sub-study. Preliminary reports of data and analysis of the first sub-study were reported before initiation of this project.]

**Task 2. Characterization of small field-of-view (FOV) intraoperative gamma cameras.**

Two small FOV gamma cameras have been used in the study. The first, the LumaGem Hand Held Probe (Gamma Medica, Inc., Northridge, CA) has a 1"x1" FOV. The second, the GammaCAM/OR (Gamma Medica, Inc., Northridge, CA) has a 5"x5" FOV. Preliminary data characterizing the devices and preliminary data obtained on 29 breast cancer patients and on 19 melanoma patients (separate funding) suggest that for the task of SLN localization in the context of this project the 5"x5" FOV device is better than the 1"x1" FOV device. Thus, it has been decided that the 5"x5" FOV device will be used for the remaining effort of this project.

[Greene C, 2002, and Yamaguchi Y, et al., 2002, are summaries of experience to date of the 1"x1" device; Greene C, et al., 2002, Aarsvold JN, et al., 2002, and Aarsvold JN, et al., 2003, are summaries of experience to date of the 5"x5" device.]

**Task 3. Acquisition of images/data from breast cancer patients using small FOV intraoperative gamma cameras.**

Images/data for Emory University breast cancer patients were acquired using the 5"x5" FOV device in Surgical Suites at Emory University. The oncology surgeon involved in this preliminary assessment concluded the device was acceptable for additional investigation. Based on this assessment, pursuit of data acquisition for the main objective of the study-comparison of intraoperative SLN localization using a gamma counting probe alone and using a gamma counting probe and small FOV gamma camera-was initiated using the 5"x5" FOV device. Images/data for a total of 21 Emory University breast cancer patients were acquired for the objective of task 3. An additional 9 patients will be enrolled in the study for data analysis. Upon completion of the data collection of the additional patients a complete analysis will be done to complete task 3. Thus task 3 is to be completed by the end of year 2004.

[Greene C, 2002, Greene C, et al., 2003, Aarsvold JN, et al., 2002, and Aarsvold JN, et al., 2003, report aspects of this task and of similar tasks for SLN localization in melanoma patients.]

**Task 4. Analysis of preliminary data of Task 3.**

Aspects of the data of the 21 patients enrolled to date have been considered and summarized. Other aspects of the data of the 21 patients are of the same form as 50

patients of the existing database; key factors have been identified and analyzed. The results will be reported as part of task 6 when the data collection is complete.

Task 5. Analysis of the data of the primary sub-study of Task 3.

A database with the current data from task three has been established and a preliminary analysis has been completed. A final statistical analysis using the database will be completed when the additional patient data has been collected.

Task 6. Develop a PhD dissertation.

An independent project report has been submitted to the Georgia Institute of Technology (Greene C, 2002). Development of a PhD dissertation is on track to be completed as proposed.

#### KEY RESEARCH ACCOMPLISHMENTS:

- Verification of contents of an existing database and initiation of statistical analysis of the data.
- Completion of statistical analysis of existing database consisting of 175+ patients.
- Analysis of hand-held gamma camera with the use of 14 patients has been completed.
- Acquired and analyzed images and data for 10 breast patients in preliminary investigation of 5" x 5" camera.
- Acquired and analyzed images and data for 11 patients comparing intraoperative probe only and probe and camera.
- Developed a summary/publication for analysis of existing 11 patients completed.

#### REPORTABLE OUTCOMES:

##### Research

##### Manuscripts

- Yamaguchi Y, MacDonald LR, Patt BE, Iwanczyk JS, Aarsvold JN, Mintzer RA, Greene C, and Alazraki NP. Evaluation of hand-held gamma camera with 1-mm NaI(Tl) pixels. SPIE Proceedings, 4786:103-113, 2002.
- Aarsvold JN, Mintzer RA, Greene C, Grant SF, Murray DR, Styblo TM, Alazraki NP, Halkar RK, MacDonald LR, Iwanczyk JS, and Patt BE. Sterile-field imaging of sentinel nodes: Initial experience. J Nucl Med, 43(5):156P, 2002.

##### Abstracts

- Grant SF, Mintzer RA, Greene CM, Aarsvold JN, Styblo TM, and Alazraki NP. Effects of Tc-99m sulfur colloid filtration on axillary node visualization during preoperative breast lymphoscintigraphy. 8th Congress of the World Federation of Nuclear Medicine and Biology, Santiago, Chile, 2002
- Aarsvold JN, Mintzer RA, Greene C, Grant SF, Styblo TM, Murray DR, Alazraki NP, Halkar RK, MacDonald LR, Iwanczyk JS, and Patt BE. Gamma cameras for intraoperative localization of sentinel nodes: Technical

requirements identified through operating room experience. Conference Record of the 2002 IEEE NSS/MIC, 2003.

- Greene CM, Aarsvold JN, Mintzer RA, Murray DR, Grant SF, Halkar RK, Alazraki NP, Patt BE, Iwanczyk JS, Li J, Caravaglia GM, and MacDonald LR. Intraoperative imaging during melanoma sentinel node biopsy. SNM Annual Meeting, 2004.
- Greene C, Aarsvold JN, Mintzer RA, Grant SF, Murray DR, Styblo RM, Halkar RK, Alazraki NP, MacDonald LR, Iwanczyk JS, and Patt BE. Intraoperative nuclear medicine imaging for localization of sentinel lymph nodes in melanoma patients. Sentinel Node 2002 Abstract Book, 2002.
- Aarsvold JN, Greene CM, Mintzer RA, Grant SF, Styblo TM, Alazraki NP, Patt BE, Caravaglia GM, Li J, Iwanczyk JS. Intraoperative imaging of axillary sentinel lymph nodes in breast cancer patients. International Workshop on Nuclear Radiology of Breast Cancer, 2004, submitted.
- Aarsvold JN, Greene CM, Mintzer RA, Grant SF, Styblo TM, Alazraki NP, Patt BE, Caravaglia GM, Iwanczyk JS, Li j. Intraoperative localization of axillary sentinel lymph nodes in patients with breast cancer: Probe vs camera and probe. Sentinel Node 2004, submitted.

## CONCLUSION

User experience suggests that a field of view (FOV) less than 5" x 5" would not be useful in SLN localization especially for breast cancer cases. Preliminary analysis of acquired data and user experience suggest a 5" x 5" FOV has some usefulness in SLN localization procedures. Assessment of our use of a 5" x 5" FOV system suggests that use of camera and probe intraoperatively results in the surgeon having more confidence of localization and the removal of all radioactive nodes than use of a probe. This assessment is preliminary as acquisition of study data to support or refute this is on-going. The focus of our data collection is acquisition of the data for the primary sub-study, the study comparing localization using only a probe with localization using a small FOV camera and probe.

## REFERENCES

- M. G. Staitus Muller, P.A.M. van Leeuwar, P.J. Borgstein, R. Pijpers, S. Meijer. "The sentinel node procedure in cutaneous melanoma: an overview of 6 years' experience" *Eur. J Nucl Med* 26(suppl):S20-S25, 1999.
- A. J. Wilhelm, G. Mijnhout, F. Sophie, J.F. Eric. "Radiopharmaceuticalls in sentinel lymph node detection an overview." *Eur. J Nucl Med* 26(soppl):S36-S42, 1999.
- M.R.S. Keshtgar, W.A. Waddington, S.R. Lakhani, P.J. Ell. *The sentinel node in surgical oncology* Springer 1999.
- O. E. Nieweg, L. Jansen, R A. Valdes Olmos, E. J. T. Rutgers, J. L Peterse, K. A. Hoefnagel, Bin B.R. Kroon. "Lymphatic mapping and sentinel lymph node biopsy in breast cancer" *Eur J Nucl Med* 26(Suppl):S11-S16, 1999.
- P. Zanzonico, S. Heller. "The Intraoperative Gamma Probe: Basic principles and choices available" *Sem Nucl Med* 30(1):33-48, 2000.
- A. J. Britten. "A method to evaluate intraoperative gamma probes for sentinel lymph node localization" *Eur J Nucl Med* 26:76-83, 1999.
- T. Tiourina, B. Arends, D. Huysmans, H. Rutten, B. Lemaire, Sa. Muller. "Evaulation of surgical gamma probes for radioguided sentinel node localization" *Eur J Nucl Med* 25:1224-1231, 1998.
- D. P. McElroy, E. J. Hoffman, L. R. MacDonald, B. E. Patt, J. S. Iwanczyk. "Evaluation of Performance of Dedicated, Compact Scintillation Cameras" *Proc. SPIE*, vol. 4142:231-241, 2000.
- L. R. Macdonald, B. E. Patt, J. S. Iwanzyck, Y. Yamaguchi, D. P. McElroy, E. J. Hoffman, J. N. Aarsvold, R. A. Mintzer, N. P. Alazraki. "High-resolution hand-held gamma camera" *SPIE*. 4142:242-253, 2000.
- Gershenwald, Jeffrey E., Buzaid, Antonio C., Ross, Merrick I. Classification and Staging of Melanoma. *Hematology/Oncology Clinics of North America*. Vol 12:4, August 1998.

**Appendix I**  
**Sentinel Node 2004 Power Point Presentation:**

**Intraoperative Imaging During Melanoma Sentinel Node Biopsy**

# Intraoperative Imaging During Melanoma Sentinel Node Biopsy

CM Greene<sup>1</sup>, JN Aarsvold<sup>2,3</sup>, RA Mintzer<sup>2</sup>, SF Grant<sup>3</sup>  
DR Murray<sup>2</sup>, RK Halkar<sup>2,3</sup>, NP Alazraki<sup>2,3</sup>  
JS Iwanczyk<sup>4</sup>, BE Patt<sup>4</sup>, J Li<sup>4</sup>, GM Caravaglia<sup>4</sup>  
LR MacDonald<sup>4</sup>

<sup>1</sup>Georgia Institute of Technology, Atlanta, GA;

<sup>2</sup>Emory University, Atlanta, GA,

<sup>3</sup>Atlanta Veterans Affairs Medical Center, Atlanta, GA


<sup>4</sup>Gamma Medica Division, Photon Imaging Inc, Northridge, CA

## Objective

Systematic investigation of the use of a small FOV gamma camera during intraoperative procedures for the detection, localization, and excision of SLNs in melanoma patients

- **Prototype technology assessment**
- **Preliminary procedure assessment**

## Small FOV Gamma Camera



Gamma Medica  
GammaCAM/OR



pre- & post-excision imaging

5" x 5" FOV gamma camera

56x56 array of 2x2 mm NaI(Tl) crystals

5x5 array of 1x1 in PSPMTs

## The study

Patient injected preoperatively

Patient imaged preoperatively

**Patient imaged intraoperatively**

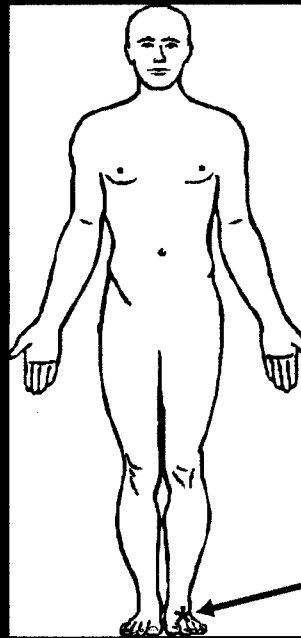
**pre-incision**

**post-excision**

Tissue sent to pathology

## Methods

- *Subjects:* 11
- *Injections:* 100  $\mu$ Ci of  $^{99m}$ Tc-antihuman CD45 antibody (100  $\mu$ Ci of  $^{99m}$ Tc-antihuman CD45 antibody)
- *Preoperative Imaging:* GE 500/GE 400, LEAP, dynamic & static
- *Intraoperative Counting:* Neoprobe 1000/1500
- *Intraoperative Imaging:* Gamma Medica GammaCAM/OR, pre & post excision
- *Specimen Imaging:* Gamma Medica GammaCAM/OR
- *Pathology:* IHC of SLNs, H&E of non-SLNs



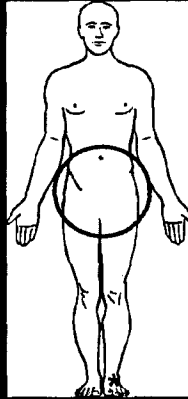
primary

# Case 1

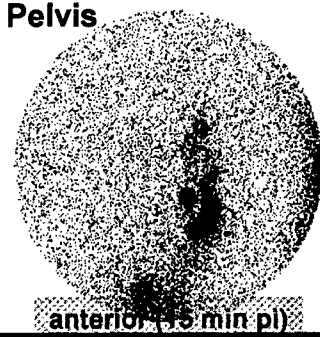
## Preop Images




GE 400



## Pelvis



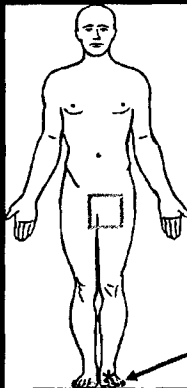
anterior (15 min pi)



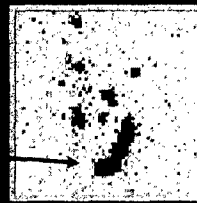
left lateral (20 min pi)

## Case 1 Intraop Images

51 yo male  
primary on distal  
dorsum of left foot

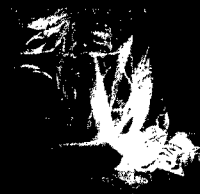

anterior  
inguen



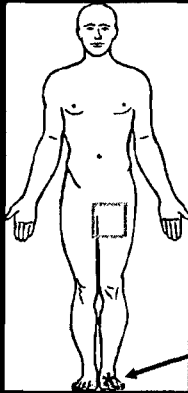
pre-incision

primary

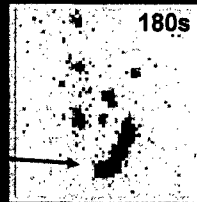


# Case 1 Intraop Images

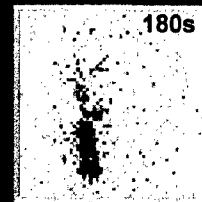
51 yo male  
primary on distal  
dorsum of left foot



anterior  
inguen



pre-incision

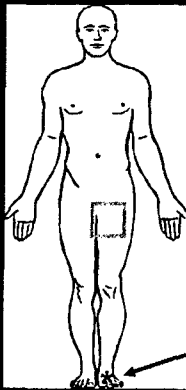


pre-incision  
(left lateral)

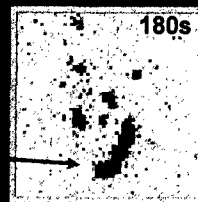
primary

# Case 1 Intraop Images

51 yo male  
primary on distal  
dorsum of left foot



anterior  
inguen

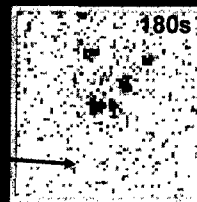


pre-incision

intraoperative  
camera useful  
in confirming  
focus removal

primary

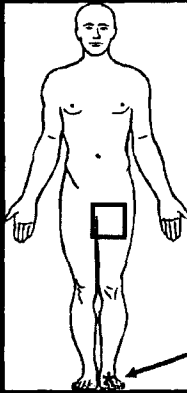
1 focus  
removed



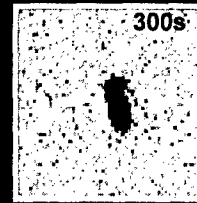
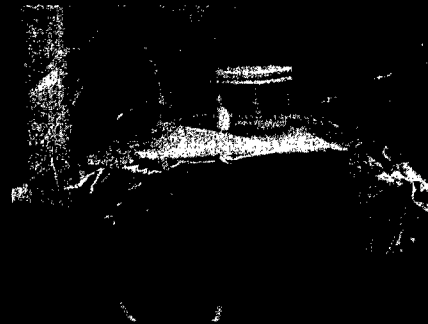post-excision

# Case 1 Intraop Images

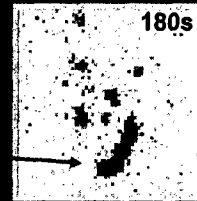
51 yo male  
primary on distal  
dorsum of left foot



## Specimen Imaging



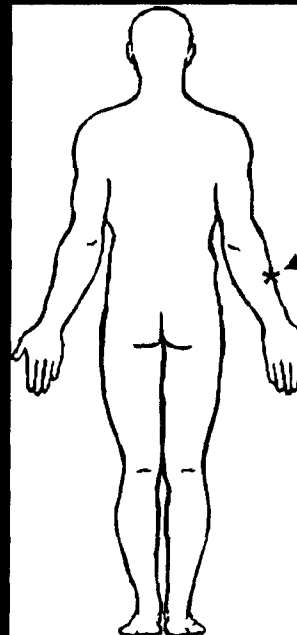
excised focus  
(4.0x2.3x0.9 cm)



pre-incision

# Case 2

56 yo male  
primary on right forearm




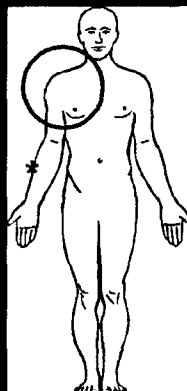
primary

## Case 2

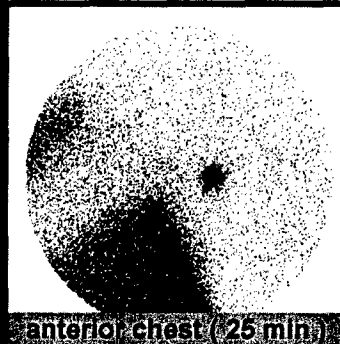
### Preop Images



GE 400



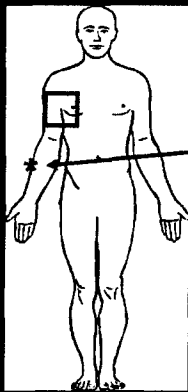
axilla (15 min)



anterior chest (25 min)

## Case 2 Intraop Images

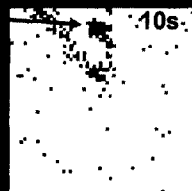56 yo male  
primary on right forearm




primary

right  
axillary

radioactive  
marker



10s  
pre-incision,  
marker



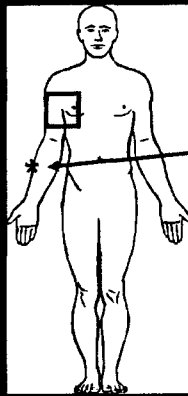
120s  
pre-incision,  
marker removed

A radioactive marker is used to compensate for lack of anatomic reference:

- First, a marker is positioned in FOV
- Second, the location is inked in surgical field
- Third, the marker removed and image is taken

## Case 2 Intraop Images

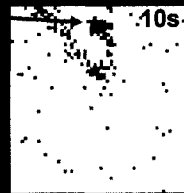
56 yo male  
primary on right forearm




primary

right  
axillary

radioactive  
marker




marker,  
pre-incision




pre-incision

1 focus  
removed

radioactive  
marker




marker,  
post-excision




post-excision

radioisotope markers were  
useful in camera repositioning

## Specimen Images



case1



case 2

case- focus	post-ex cts (10s) (probe)	post-ex cts (camera)	activity (nCi)	focus activity/ injected activity (%)
1-1	10,817	2350	3481	4.29 (2 nodes)
2-1	4630	1471	2180	2.56
2-2	482	90	133	0.16

## Conclusion I

**Increased camera sensitivity more important than high resolution:**

- Low nodal uptake & attenuation
- Small camera allows proximity
- LEAP collimator rather than LEHR

## Conclusion II

**We were successful in using the camera intraoperatively to verify excision of SLN foci.**

- Lack of anatomic reference / small FOV
- Repositioning camera / markers
- Software tailored to pre/post registration?