

Award Number: DAMD17-00-1-0649

TITLE: Assessment of Risk Reduction for Lymphedema Following Sentinel Lymph Noded Guided Surgery for Primary Breast Cancer

PRINCIPAL INVESTIGATOR: Andrea L. Cheville, M.D.

CONTRACTING ORGANIZATION: University of Pennsylvania Health System  
Philadelphia, PA 19104

REPORT DATE: October 2006

TYPE OF REPORT: Final

PREPARED FOR: U.S. Army Medical Research and Materiel Command  
Fort Detrick, Maryland 21702-5012

DISTRIBUTION STATEMENT: Approved for Public Release;  
Distribution Unlimited

The views, opinions and/or findings contained in this report are those of the author(s) and should not be construed as an official Department of the Army position, policy or decision unless so designated by other documentation.

# REPORT DOCUMENTATION PAGE

*Form Approved*  
*OMB No. 0704-0188*

Public reporting burden for this collection of information is estimated to average 1 hour per response, including the time for reviewing instructions, searching existing data sources, gathering and maintaining the data needed, and completing and reviewing this collection of information. Send comments regarding this burden estimate or any other aspect of this collection of information, including suggestions for reducing this burden to Department of Defense, Washington Headquarters Services, Directorate for Information Operations and Reports (0704-0188), 1215 Jefferson Davis Highway, Suite 1204, Arlington, VA 22202-4302. Respondents should be aware that notwithstanding any other provision of law, no person shall be subject to any penalty for failing to comply with a collection of information if it does not display a currently valid OMB control number. **PLEASE DO NOT RETURN YOUR FORM TO THE ABOVE ADDRESS.**

<b>1. REPORT DATE (DD-MM-YYYY)</b> 01-10-2006			<b>2. REPORT TYPE</b> Final		<b>3. DATES COVERED (From - To)</b> 1 OCT 2000 - 30 SEP 2006	
<b>4. TITLE AND SUBTITLE</b>  Assessment of Risk Reduction for Lymphedema Following Sentinel Lymph Noded Guided Surgery for Primary Breast Cancer					<b>5a. CONTRACT NUMBER</b>	
					<b>5b. GRANT NUMBER</b> DAMD17-00-1-0649	
					<b>5c. PROGRAM ELEMENT NUMBER</b>	
<b>6. AUTHOR(S)</b> Andrea L. Cheville, M.D.  E-Mail: cheville.andrea@mayo.edu					<b>5d. PROJECT NUMBER</b>	
					<b>5e. TASK NUMBER</b>	
					<b>5f. WORK UNIT NUMBER</b>	
<b>7. PERFORMING ORGANIZATION NAME(S) AND ADDRESS(ES)</b> University of Pennsylvania Health System Philadelphia, PA 19104					<b>8. PERFORMING ORGANIZATION REPORT NUMBER</b>	
<b>9. SPONSORING / MONITORING AGENCY NAME(S) AND ADDRESS(ES)</b> U.S. Army Medical Research and Materiel Command Fort Detrick, Maryland 21702-5012					<b>10. SPONSOR/MONITOR'S ACRONYM(S)</b>	
					<b>11. SPONSOR/MONITOR'S REPORT NUMBER(S)</b>	
<b>12. DISTRIBUTION / AVAILABILITY STATEMENT</b> Approved for Public Release; Distribution Unlimited						
<b>13. SUPPLEMENTARY NOTES</b>						
<b>14. ABSTRACT</b> Lymphedema is a common complication of primary breast cancer therapy. It is a chronic, insidiously progressive, and potentially devastating condition. Radiation increases patients' lymphedema risk as conventional fields encompass functioning lymphatics. Imaging technologies may identify these lymphatics and allow tailoring of radiation fields to minimize radiation exposure while preserving regional tumor control. This study uses SPECT scanning to localize lymphatics critical for arm drainage after surgical removal of axillary lymph nodes. The study has established the feasibility of fusing SPECT images with high resolution CT scans used in radiation simulation. Furthermore the study has demonstrate that fusing allows precise quantification of radiation dosimetry delivered to lymph nodes critical for arm drainage. The study will test the hypothesis that increased arm volume correlates with high levels of radiation dosimetry. The fact that higher doses of radiation and larger radiation ports are associated with an increased incidence of lymphedema (volume ↑ > 150ml.), particularly severe lymphedema (volume ↑ > 400ml.), supports this hypothesis. The proposed study realizes the BCRP goals by elucidating a novel means of refining breast cancer treatment to minimize patients' risk of developing the most prevalent and dreaded complication of conventional therapy, lymphedema.						
<b>15. SUBJECT TERMS</b> Lymphedema, Radiation Therapy, Survivorship, Prevention, Lymphoscintigraphy, Breast Cancer						
<b>16. SECURITY CLASSIFICATION OF:</b>				<b>17. LIMITATION OF ABSTRACT</b>	<b>18. NUMBER OF PAGES</b>	<b>19a. NAME OF RESPONSIBLE PERSON</b>
<b>a. REPORT</b> U	<b>b. ABSTRACT</b> U	<b>c. THIS PAGE</b> U	USAMRMC			
				UU	43	<b>19b. TELEPHONE NUMBER (include area code)</b>

## Table of Contents

<b>Introduction.....</b>	<b>5</b>
Body.....	6
<b>Key Research Accomplishments.....</b>	<b>9</b>
<b>Reportable Outcomes.....</b>	<b>10</b>
<b>Conclusions.....</b>	<b>11</b>
<b>References.....</b>	<b>12</b>
<b>Appendices.....</b>	<b>13</b>

### ***Introduction:***

This aim of this award involves completion of a prospective cohort study to determine whether radiation dosimetry delivered to lymphatics essential for arm drainage correlates with increased arm volume. Lymphedema is the number one survivorship issue in breast cancer (American Cancer Society). Affected patients experience diminished quality of life and are more likely to develop social, vocational, psychological and functional decline (Maunsell, Passik). Current imaging approaches, e.g. SPECT scanning, may permit the precise localization of lymphatics critical for arm draining after axillary surgery (Czerniecki, Joensuu, Witte). Fusion of SPECT images with CT scans used in radiation simulation offers the potential to precisely quantify radiation dosimetry to lymphatics (Chao). Quantification allows biostatistical testing of the hypothesis that increased radiation exposure will correlate with increased arm volume (Liljegren, Meek). Testing of this hypothesis and establishing the feasibility of SPECT-CT fusions are requisite initial steps in the development of radiation planning techniques that exclude lymphatics critical for arm drainage, thereby reducing lymphedema risk.

The recipient of grant DAMD17-00-1-0649, Dr. Andrea Cheville subsequently received a career development award from the Department of Defense, BC022257:DAMD17-03-1-0622. Receipt of the second award allowed expansion of the scope and size of the initial project. Work is ongoing in data collection, statistical analysis, and manuscript preparation. Data collection will be complete by 12/31/07. Statistical analysis and manuscript preparation will continue for 6 months. Details of the ongoing work are available in the Interim Report on BC022257:DAMD17-03-1-0622.

## ***Body:***

**Task.** Conduct a prospective cohort study to estimate the risk of lymphedema associated with radiation dosimetry to lymph node critical for arm drainage. (Months 1-36)

### *a. Subject enrollment*

Thirty seven subjects have enrolled in the study. This is 13 subjects less than the initial recruitment goal of 50 subjects. Subject recruitment was delayed by the need for the approval of three regulatory bodies; the USAMRMC Review Board, the University of Pennsylvania Institutional Review Board, and the Abramson Family Cancer Institute Clinical Trials Committee. Recruitment was further delayed by the need to determine the optimal: amount of radiolabeled tracer for subdermal injection, upper extremity injection sites, and interval between tracer injection and SPECT scanning. Recruitment was slower than anticipated.

An interim power analysis with updated variance data indicates that with 37 subjects and a two-sided  $\alpha$  of .05, we can detect a 4.7% change in inter-limb volume discrepancy with 80% power, a 5.5% discrepancy with 90% power, and a 7.4% discrepancy with 99% power. Each of these limb volume discrepancies is far smaller than the 15% difference which is generally considered clinically significant. Therefore, we are adequately powered with 37 subjects to address the specific aims outlined in the initial proposal. Given the cost to subjects of time and energy, in the face of little associated personal benefit, no additional subject recruitment is necessary or ethically defensible.

### *b. Data collection*

Complete 12-month data has been collected on 31 subjects. It is anticipated that data collection will be complete by 12/31/07.

### *c. Institutional Review Board approval*

Approvals for the study have been obtained and appropriately renewed from the USAMRMC Review Board, the University of Pennsylvania Institutional Review Board, and the Abramson Family Cancer Institute Clinical Trials Committee.

### *d. Data Entry*

A Microsoft Access database has been constructed which includes subjects' sociodemographic and cancer treatment-related variables. The database contains missing values which will require further chart extraction to remedy. Complete data will be entered by 12/31/07.

e. Data Analysis

Descriptive statistics of cancer treatment-related, SPECT scan and dosimetry results have been calculated for preparation of platform and poster presentations. Almost 50% (18) of the enrolled subjects had sentinel lymph node dissections alone, while the other 50% underwent  $\geq 2$ -level surgical axillary clearing. Sixteen subjects (53%) had right-sided breast cancer. Thirteen subjects (43%) underwent modified radical mastectomies, while seventeen (57%) elected for breast conservation therapy. Thirteen patients (43%), a slightly different subgroup, received radiation to breast tangents while the remaining subjects received four field) irradiation tangents, posterior axillary boost, and supraclavicular fields).

The number of lymph nodes (LNs) visualized ranged from 1-10 with a mean of 3 LNs/patient distributed through out axillary and supraclavicular LN beds. No LNs were visualized in 3 patients (8.1%). We suspect this may reflect a technical error rather than true absence of LNs. None of the three patients experienced arm, breast, or axillary swelling. Level I nodes were visualized in the lateral axilla in 62.5% of cases and in the medial axilla in 68.8% of cases. Level II/III nodes were detected in 50% of patients. Supraclavicular lymph nodes were visualized in 56.3% of cases.

Dosimetry measurements in the 22 subjects that have been carefully analyzed indicate that the LNs draining the arm frequently receive the full prescribed radiation isodose (46 – 50 Gy) irrespective of location. Sixty seven LNs were identified among 22 subjects, for a mean of 3.05 LN per subject. The mean radiation dose per LN was 28.47 (SD 22.01). The distribution of LN dosimetry is graphically illustrated (Figure 1) by radiation treatment groups. LNs in subjects undergoing 4-field (35.72 Gray) versus breast tangent (19.54 Gray) radiation, on average, received significantly greater dosimetry ( $p=0.0001$ , ttest). However, in 63.3% of subjects treated with breast tangents, at least 1 LN

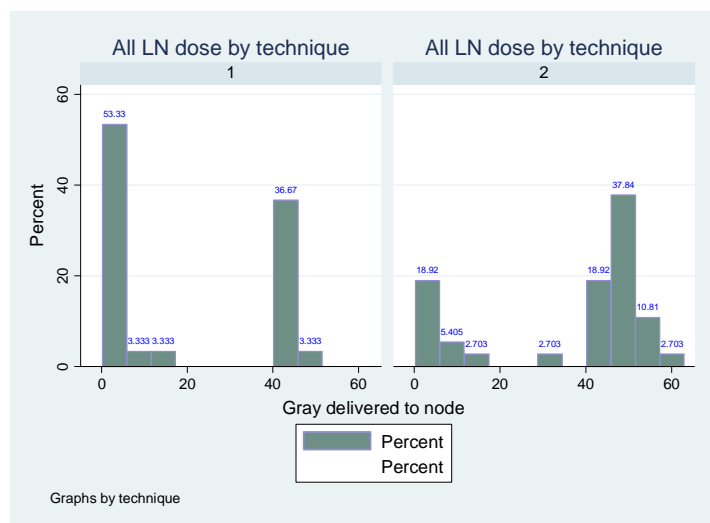


Figure 1

Subjects who had undergone two-level axillary dissections were more likely to have  $>4$  LNs identified on CT-SPECT ( $p = 0.006$ ,  $X^2$ ). This finding is physiologically relevant. It has been long appreciated that roughly 40% of breast cancer patients who undergo aggressive treatment, e.g. modified radical mastectomy, full surgical axillary LN clearing, and four-field irradiation, do not develop lymphedema. The mechanism by which the

lymphatic system compensates for extensive lymph node loss has remained obscure. Our results suggest that collateral drainage pathways involving multiple LNs develop after surgical removal of the LNs congenitally ‘assigned’ to drain the arm. This finding is clinically relevant since it supports the need to develop clinical strategies to enhance lymphatic collateralization during and immediately following primary breast cancer treatment.

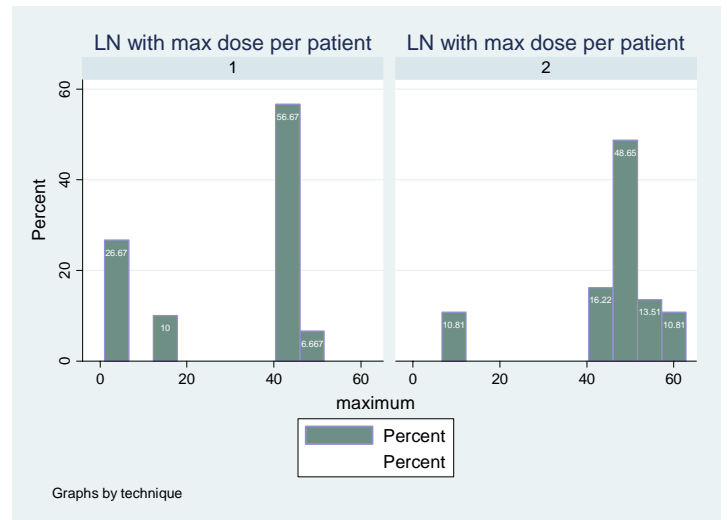


Figure 2

#### f. Manuscript Preparation

The results of this study are relevant to audiences from different medical disciplines including nuclear medicine, radiation physics and oncology, and lymphology. For this reason three manuscripts with separate emphases have been prepared. The first describing the lymph node mapping and SPECT scanning techniques has been submitted to the European Journal of Nuclear Medicine and Molecular Imaging (Appendix A). The second manuscript describes the SPECT and simulation CT image fusion strategy used for quantification of radiation dosimetry for a radiation oncology audience. This paper reports radiation doses delivered to LN critical for arm drainage following breast cancer surgeries. It is the first report to describe delivery of potentially harmful radiation doses to essential normal tissues in LN negative breast cancer patients. The second paper is currently in the review process (Appendix B). The third manuscript describes how our findings support current unsubstantiated beliefs regarding the collateralization of lymph pathways following surgical resection of axillary nodes. This manuscript is in preparation.

## ***Key Research Accomplishments***

1. Development of mapping strategy to identify LN essential for arm drainage after surgical axillary LN removal for primary breast cancer.
2. Precise anatomic localization of LNs draining the arm using eINTEGRA SPECT scanning.
3. Fusion of eINTEGRA scans with CT simulation images used in radiation planning with the potential to develop individually tailored precision radiation fields based on the location of physiologically relevant LNs.
4. Accurate quantification of radiation dosimetry delivered to LN essential for arm drainage following surgical manipulation of the axillary LN bed (e.g. sentinel LN biopsy or 2-level axillary clearing).
5. Construction of individually tailored fields that minimize radiation exposure to the LNs draining the arm using conventional intensity modulated radiation therapy techniques.
6. Discovery of the evidence supporting lymphatic collateralization following removal of LNs congenitally predisposed to drain the arm.

## ***Reportable Outcomes***

1. Presentation of Grand Rounds to the Department of Physical Medicine and Rehabilitation at the Mayo Clinic, Rochester Minnesota. November, 2005.
2. Presentation of Grand Rounds to the Department of Physical Medicine and Rehabilitation at the Medical College of Wisconsin. June, 2006
3. Platform presentation at the American Society of Nuclear Medicine. June, 2006
4. Poster presentation at the European Society of Therapeutic Radiation Oncology meeting in October, 2006.
5. Platform presentation accepted for the National Lymphedema Network meeting in November, 2006.
6. Platform presentation at the European Society of Therapeutic Radiation Oncology meeting in Barcelona, Spain September, 2007 entitled *SPECT/CT Imaging in Breast Cancer for Temporal Response of Arm Edema*.
7. Manuscript submitted to the European Journal of Nuclear Medicine and Molecular Imaging entitled *Novel SPECT/CT-based Lymph Node Imaging Technique in Patients with Breast Cancer: Implications for Preventing Arm Lymphedema following Radiation Therapy* (Appendix A).
8. Manuscript in review entitled *Use of Lymphoscintigraphy for Evaluation of Lymphedema Risk Reduction in Radiation Treatment of Primary Breast Cancer for submission to International Journal of Radiation Oncology, Biology, Physics* (Appendix B).

## ***Conclusion***

Work to date has established that LNs draining the arm after surgical manipulation of the axilla in the context of primary breast cancer can be localized using eINTGRA SPECT scanning. The radiation dose delivered to LNs can be quantified by fusing eINTEGRA SPECT images with radiation simulation CT scan images. This work creates the possibility of constructing radiation fields that minimize dosimetry to LNs draining the arm and reduces patients' risk of developing lymphedema. Customized radiation fields may be considered for patients with 'low risk' breast cancers (e.g. small tumor, hormone receptor positive, benign histopathological characteristics, and negative sentinel LNs). At this point the association between reduced LN dosimetry and reduced lymphedema risk remains theoretical. Complete data collection will allow empiric evaluation of the proposed association. The fact that more LNs were visualized in patients who underwent  $\geq 2$ -level axillary clearing suggests that lymph collateralization is an important means of re-establishing lymphatic homeostasis. This finding justifies the development of techniques to enhance this endogenous compensatory mechanisms.

## ***References:***

American Cancer Society - Cancer Facts and Figures 2002

Chao KS. Protection of salivary function by intensity-modulated radiation therapy in patients with head and neck cancer. *Semin Radiat Oncol* 2002 Jan;12(1 Suppl 1):20-5.

Czerniecki BJ, Bedrosian I, Faries M, Alavi A. Revolutionary impact of lymphoscintigraphy and intraoperative sentinel node mapping in the clinical practice of oncology. *Semin in Nuc Med* 2001;31(2):158-164

Joensuu H. Novel cancer therapies: more efficacy, less toxicity and improved organ preservation. *Ann Med* 2000 Feb;32(1):31-3.

Liljegren G, Holmberg L. Arm morbidity after sector resection and axillary dissection with or without postoperative radiotherapy in breast cancer stage I. Results from a randomized trial. Uppsala-Orebro Breast Cancer Study Group. *Eur J Cancer* 1997;33:193-9.

Maunsell E, Brisson J, Deschenes L. Arm problems and psychological distress after surgery for breast cancer. *Can J Surg* 1993;36:315-20.

Meek, AG. Breast radiotherapy and lymphedema. *Cancer*. 1998 Dec 15;83(12 Suppl American):2798-802. Review.

Passik S, Newman M, Brennan M, Holland J. Psychiatric consultation for women undergoing rehabilitation for upper-extremity lymphedema following breast cancer treatment. *J Pain Symptom Manage* 1993;8:226-33.

Witte CL, Witte MH, Unger EC, et al. Advances in imaging of lymph flow disorders. *Radiographics* 2000 20:1697-1719.

## ***Appendix A:***

### **Novel SPECT/CT-based Lymph Node Imaging Technique in Patients with Breast Cancer: Implications for Preventing Arm Lymphedema following Radiation Therapy**

Andrea L Cheville, MD, MSCE<sup>1</sup>, Indra Das, PhD<sup>2</sup>, Shyam Srinivas, MD, PhD<sup>3</sup>, Josh Schuerman, MS<sup>4</sup>, Luke Velders, BA<sup>5</sup>, Larry Solin, MD<sup>2</sup>, Basu, Sandip, MBBS (Hons), DRM, DNB<sup>6</sup>, Abass Alavi, MD<sup>4</sup>

1. Department of Physical Medicine and Rehabilitation, Mayo Clinic, 200 First Street SW, Rochester, MN 55905
2. Department of Radiation Oncology, University of Pennsylvania Health System, 3400 Spruce Street, Philadelphia, PA 19104
3. Department of Nuclear Medicine, Cleveland Clinic, 9500 Euclid Avenue | Cleveland, OH 44195
4. Division of Nuclear Medicine, Department of Radiology, University of Pennsylvania Health System, 3400 Spruce Street, Philadelphia, PA 19104
5. Division of Medical Oncology, Department of Medicine, University of Pennsylvania Health System, 3400 Spruce Street, Philadelphia, PA 19104
6. Radiation Medicine Centre (BARC), Tata Memorial Centre Annexe, Parel, Bombay 400012, India.

Corresponding and First Author:

Andrea Cheville, MD, MSCE

Mayo Clinic

200 First Street SW

Rochester, MN 55905

Tel.: (507) 266-8913

Fax: (507) 266-1561

Email: [Cheville.andrea@mayo.edu](mailto:Cheville.andrea@mayo.edu)

## ***ABSTRACT***

**Objective:** Arm lymphedema, a frequent complication of breast cancer treatment, may be prevented by minimizing the irradiation of critical lymph nodes (LNs). Conventional imaging techniques cannot localize LNs with sufficient precision for image-guided radiation planning. However, SPECT/CT may have this capacity, allowing for contoured, LN sparing-radiation with minimal lymphedema risk.

**Methods:** Prior to radiation therapy, thirty-two consecutive patients with breast cancer underwent scanning with a hybrid camera which combined a dual-head SPECT camera and a low-dose, single slice CT scanner, (GE Hawkeye®) after injection of 0.5 mCi of filtered <sup>99m</sup>Tc-sulfur colloid into their hands and forearms. The number of visualized LNs, LN locations (e.g. lateral/medial axilla, or supraclavicular area), and each LN's maximum counts and total uptake were recorded. SPECT/CT derived coordinates were used to map LN locations onto the 3D radiation treatment planning system to quantify radiation dose.

**Results:** A mean of 3.4 (SD 2.0) lymph nodes were detected on 32 scans. More lateral axillary LNs were detected following sentinel lymph node biopsy, and more supraclavicular nodes were detected following axillary clearing ( $p < 0.001$ ). SPECT-CT derived LN coordinates were successfully mapped onto radiation simulation CT scans to quantify LN dosimetry. Fifty six percent of subjects with LN negative cancers received  $>40\text{Gy}$  to  $\geq 1$  LN, while 25% of these subjects received  $>40$  Gy to all visualized LNs.

**Conclusions:** SPECT/CT fusion images precisely localize the LNs crucial for arm drainage and can be utilized in image-guided radiation planning to minimize LN irradiation and lymphedema risk.

## ***INTRODUCTION***

Localization of lymph nodes (LN) draining the arm may prevent lymphedema by sparing functionally vital tissues during radiation therapy for breast cancer. The benefits of LN mapping are evident in the improved outcomes achieved with sentinel lymph node biopsy (SLNB) procedures.<sup>1 2, 3</sup> LN mapping in this context permits identification of patients whose LNs are free of metastases and do not require further axillary surgery. Unfortunately, the LNs spared by SLNB procedures may be aggressively irradiated and rendered dysfunctional by conventional radiation therapy. Developing the capacity to localize LNs that drain critical territories (e.g. the upper extremity and truncal quadrant) represents an essential first step if these nodes are to be spared during radiation for primary breast cancer.

Current LN imaging techniques offer insufficient information to reliably guide radiation planning. Gamma camera-based lymphoscintigraphy images lymph vessels and nodes, and provides information about their drainage territories. However, scintigraphic images lack anatomical landmarks and therefore cannot be used to accurately determine LN locations.<sup>4</sup> Computed tomography (CT) and magnetic resonance (MR) imaging, on the other hand, provide exquisite detail of LNs' anatomical surroundings, but offer no information about their drainage territories or physiological relevance.<sup>5</sup> Thus, lymphoscintigraphy provides functional information that compliments the structural detail of CT and MR scans. Fusion imaging, e.g. SPECT-CT, combines the advantages of both anatomical and functional imaging in a single examination such that structures with functional or pathophysiological relevance can be placed in their anatomic context. Fusion imaging can therefore be of incremental value in refining patient management to a degree not possible with the use of lymphoscintigraphy or CT/MRI alone.

Radiation therapy plays a pivotal role in the combined modality treatment of breast cancer.<sup>6, 7</sup> Similar to SLNB procedures, radiation treatments should ideally spare aesthetically- and functionally-important structures to improve outcomes and patients' quality of life.<sup>8</sup> Advances in image-guided precision radiotherapy [e.g. intensity modulated radiation therapy (IMRT)] have made significant strides towards this goal. Such approaches offer sufficient precision to maximally spare normal tissue while delivering adequate dosimetry to disease sites. Image-guided precision radiotherapy has remained limitedly integrated into breast cancer treatment. However, SPECT-CT and other fusion techniques may offer incentive to move in this direction by supplying the information needed to create contoured radiation fields that spare LNs and other vital normal tissues. Such LN sparing would represent a meaningful advance in the prevention of lymphedema, a highly morbid, chronic and common sequelae of breast cancer treatment.<sup>9-22</sup>

To explore the potential contribution of fusion imaging to radiation planning, we investigated a novel approach which combines the output of a dual-head SPECT camera and a low-dose, single slice CT scanner, (GE Hawkeye®). This prospective study was designed to establish proof of concept that SPECT/CT fusion scanning can localize LNs draining the arm and generate images of sufficient precision to allow lymphatic sparing during radiation.

## ***MATERIALS AND METHODS***

### **Population**

Patients with histologically confirmed breast cancer who were candidates for external beam radiation therapy were screened for study enrollment. Patients with prior histories of breast cancer, ductal carcinoma in situ, Stage IV breast cancer, positive pregnancy tests, renal insufficiency, and lymphedema were excluded. Patients with localized disease were deemed eligible irrespective of the stage of the disease. All eligible patients had undergone either modified radical mastectomy (MRM) or lumpectomy, and sentinel lymph node biopsy and/or surgical axillary LN clearing. Prior chemo- or hormonal therapy was not considered an exclusion criterion. Eligible subjects were approached within one month prior to radiation simulation, with the majority of subjects being approached the day of simulation. Among the 215 subjects screened for participation, 59 (27.4%) were ineligible, 120 (55.8%) declined to participate, and 36 (16.7%) were enrolled. Study participants did not differ in demographic or cancer-related variables from non-participants. The study protocol was approved by the Institutional Review Board (IRB) and was HIPPA compliant. Prior to enrollment, all participating subjects carefully reviewed and signed the IRB-approved consent form. The study results did not influence subjects' planned radiation treatment as SPECT/CT results were reviewed following the completion of radiation therapy in all cases.

### **Image Acquisition**

On the day of the study, patients underwent intradermal injection of  $^{99m}\text{Tc}$ -sulfur colloid (CIS-US, Bedford, MA) at two sites by an experienced nuclear medicine technologist. Radiopharmaceutical preparation took place under a strict protocol using a 0.22 micron filter to ensure small particle size. Patients received 2 injections of 18.5 MBq (0.5 mCi) in 0.25mL in the upper extremity ipsilateral to their breast cancer. The first injection was made into the 2<sup>nd</sup> dorsal inter-digital webspace, and the second into the medial epicondyle of the humerus. Subjects were given no direction regarding upper extremity activity during the interval between tracer injection and the imaging procedure. The injection-to-imaging time interval varied from 5 to 8.5 hours depending upon logistics and patient convenience.

In order to conform integration of SPECT/CT scans to the radiation planning simulation CT scans, patients were positioned with their shoulders abducted to 135° and externally rotated to 90° during image acquisition. Positioning of patients' shoulders and arms during SPECT/CT scanning closely approximated that used during radiation treatments.

SPECT/CT images were obtained by using a dual-head Millennium VG gamma camera (GE Healthcare, Waukesha WI) with Hawkeye single-slice CT. For the SPECT acquisition, counts from a 20% wide energy window centered at 140 keV were acquired into a 128 x 128 matrix (pixel size, 4.42 x 4.42 mm). Camera heads were separated by 180° and 120 18-s frames were acquired in step and shoot mode at 3° per step angular sampling over 360° (60x2). The camera heads were equipped with high-resolution low-energy parallel-hole collimators (VPC-45). The CT scanning parameters included 140 kVp (range 120 – 140 kVp), a 13.6-s rotation time, and a 1x10 mm collimation. The tube current was 2.5 mA (the maximum available) for CT scanning.

Reconstruction was performed iteratively on an eNTEGRA workstation (GE Healthcare, Waukesha WI) using ordered-subsets expectation maximization (OSEM) with 2 iterations and 10 subsets and CT-based attenuation correction. Images were then smoothed with a 3D postfilter (Hanning 0.5, 10).

### **Image Data Analysis**

The SPECT/CT scans were reviewed interactively at a viewing station in 3D-scroll-through mode by a nuclear medicine physician experienced in lymph node mapping, a medical physicist from radiation oncology, and a physiatrist expert in upper extremity lymph drainage pathways. Each SPECT/CT scan was evaluated for the total number of visualized LNs and their locations. LNs were localized to the lateral axilla, medial axilla, or supraclavicular bed by comparing their positional relationship to the coracoid process, sternum and clavicle.

### **Calculation of LN coordinates for radiation dosimetry**

The DICOM format exported by the SPECT/CT system could not be used directly in the Oncentra treatment planning system (Nucletron, Veenendaal, Netherlands), so image fusion and co-registration was not directly possible in this analysis. Instead, each visible lymph node in the SPECT/CT image was numbered and its x, y, and z coordinates were recorded. The SPECT/CT-derived coordinates were then used to map LN locations onto our 3D treatment planning system utilizing CT-CT image fusion (CT from radiation therapy simulation and CT from SPECT/CT). Calculation of LN coordinates was generally performed following completion of radiation. Radiation dosimetry was not altered on the basis of SPECT/CT data. Patients treatment plans were retrospectively utilized to estimate the radiation dose to each LN based on the treatment technique; number of

treatment fields: 2-fields (tangential breast fields), 3-fields (tangents + supraclavicular field), or 4-fields (3-fields + posterior axillary boost); beam energy; wedges; beam weights and other parameters used for treatment planning.

### **Statistical Analysis**

A p-value  $\leq 0.05$  was considered significant and all tests were 2-tailed. T-tests and  $X^2$  tests were used for continuous and binary variables, respectively. A nonparametric equality of medians test was used to analyze LN counts between groups. Subgroup analysis of progressive decrease or increase in the number of LNs across LN sites (e.g. lateral axilla, medial axilla, and supraclavicular LN bed) was performed with a nonparametric test for trend across ordered groups.<sup>23</sup> Linear regression analyses were performed to determine whether subject body mass index (BMI) [body weight (kg) divided by height ( $m^2$ )] or the time elapsed between tracer injection and SPECT/CT scanning was associated with total LN activity or the number of LNs visualized on SPECT/CT images. Skewness was detected in the distribution of both number of surgically resected and SPECT/CT imaged LNs. Logarithmic transformations were performed prior to performing regression analyses. Analyses were adjusted for number of LNs removed and type of axillary surgery. All analyses were performed using STATA v9.0 (Stata Corporation, College Station Texas; www.stata.com).

### **RESULTS**

Subject demographic and cancer treatment-related variables are listed in Table 1. Mean subject age was 54.4 (SD 15.4) years. Fifty-two percent of patients were Caucasian, 39% Afro-American, and 9% Hispanic. Mean subject BMI was 28.3 (SD 5.4). Prior to SPECT/CT scanning a majority of the cohort underwent lumpectomies (58.3%) and the remainder underwent MRMs (41.7%). Forty-seven percent of the subjects underwent SLNB alone, and the rest of the patients underwent surgical axillary lymph node dissection (ALND) of levels I-II or I-III. A mean of 8.7 (SD 7.5) axillary LNs were resected per subject. Significantly fewer LNs were removed in subjects who underwent SLNB alone than ALND, mean 2.8 (SD 1.5) versus 14.6 (SD 6.3) ( $p < 0.0001$ ).

Of the 32 patients scanned, a mean of 3.4 (SD 2.0) LNs were identified per subject. SPECT/CT images from 2 subjects are presented in Figures 1 and 2. Significant intra-subject variation was noted in LN number and location. Table 2 details LN locations in the entire cohort and among subgroups defined by axillary surgical technique. Subjects who underwent SLNB had fewer visualized LNs (mean 2.9, SD 1.5) than subjects who underwent ALND (mean 3.8, SD 2.4), however this difference did not reach statistical significance. The absolute number and percentage of total LNs located at the axillary and supraclavicular sites was influenced by axillary surgery. Table 2 lists the percentage of total LNs and absolute number of LNs by anatomic site for the entire cohort, as well as for subgroups based on axillary surgery. A statistically significant trend was detected

with greater numbers of lateral axillary LNs being noted among SLNB subjects and greater number of supraclavicular LNs among ALND subjects ( $p < 0.001$ ). Analyses failed to demonstrate significant associations between subjects' BMI or injection-SPECT/CT scanning interval and LN number or location.

Mapping of SPECT/CT-derived LN spatial coordinates onto the CT scans utilized for radiation simulation permitted quantification of dosimetry. As illustrated in Figure 3, LN radiation dose displayed a bimodal pattern with 70% of LNs receiving either greater than 45 Gy or less than 5 Gy. Mean radiation exposure did not significantly differ between locations; lateral axilla 26.2 (SD 22.8) Gy, medial axilla 30.0 (SD 20.4) Gy, and supraclavicular bed 26.7 (SD 23.0) Gy. Table 3 groups radiation dosimetry into 10 Gy intervals and lists the number of LNs and subjects that fall within each interval. Nine of 16 subjects with LN negative breast cancer (56%) received over 40Gy to at least one LN. In 4 of these subjects all visualized LNs received over 40Gy, a dose associated with lymphatic compromise.<sup>24</sup> Among the entire study cohort, 11 of 32 subjects (34%) received 40 Gy to all visualized LNs. A post-treatment simulated IMRT planning process in patients with negative LNs allowed significant radiation dose reduction to visualized LNs while ensuring adequate treatment of the tumor bed.

## ***DISCUSSION***

Although various methods have been employed to image LNs, this study, to our knowledge, represents the first attempt to utilize SPECT/CT fusion imaging to localize LNs draining the arm after surgery for primary breast cancer. Our findings indicate that SPECT/CT images afford sufficient precision to allow determination of LN spatial coordinates for integration into radiation treatment planning. Further, this approach can be utilized to distinguish LNs draining the arm from those at risk for harboring occult metastases. This distinction is critical if the former group is to be spared while preserving loco-regional control rates. SPECT/CT also permits precise quantification of LN activity. Inferences based on LN activity may help to define the relative importance of specific LNs for arm drainage and thereby prioritize them for sparing.

The significant differences in LN locations between patients who underwent SLNB versus ALND are in accordance with current theories of how lymphatic homeostasis is re-established following injury. Collateral drainage pathways, either latent, newly formed, or both, are thought to underlie the capacity of many patients who undergo extensive axillary disruption to remain free from lymphedema.<sup>30</sup> Up to 50% of patients treated with full axillary clearing and aggressive irradiation never develop lymphedema.<sup>31</sup> Our findings suggest that collateral drainage pathways reroute arm lymph via supraclavicular LNs following ALND.

Technical uncertainty persists regarding the optimal volume of radioactive tracer, number of injection sites, injection to imaging time interval, and approach to quantification of LN activity. The approach presented in this paper was based on practices used in analogous imaging situations and expert opinion. For example, 0.5 mCi of  $^{99m}\text{Tc}$ -sulfur colloid in 0.25 mL was injected per site based on the conventional approaches of lymphoscintigraphy and sentinel lymph node mapping.<sup>32</sup>

Our purpose was not to characterize the physiologic status of the lymphatic system, but rather to identify all LNs contributing to arm drainage. Upper extremity lymphoscintigraphy typically involves the injection of tracer into the 1<sup>st</sup> and 2<sup>nd</sup> inter-digital webspaces of the hand.<sup>33, 34</sup> We deviated from this practice in an effort to ensure that all relevant LNs would be visualized. Lymph vessels arise from discrete drainage territories on the arm (e.g. dorsal hand, volar forearm) which dictate their somatotopic positions as they converge, course proximally and terminate in axillary LNs.<sup>35</sup> Only LNs receiving lymph from tracer injection sites will be visualized on scintigraphic images.<sup>35</sup> The decision to inject multiple sites was prompted by concern that LNs draining the peri-cubital region and upper arm may not be visualized if tracer was solely injected in the hand. This concern is supported by the clinical observation that lymphedema is often confined to discrete upper extremity locations while other segments are entirely spared.<sup>30</sup> Presumably the spared regions have lymph drainage patterns which are distinct from the lymphedematous areas. It is possible that more LNs would have been visualized if a 3<sup>rd</sup> injection site on the upper arm had been utilized.

Our initial study design included a 2-hour interval prior to SPECT/CT scanning. LNs were inconsistently visualized in the initial pilot patients. Hence the interval was extended to  $\geq 5$  hours. The results from this study suggest that a 5 to 8.5 hour time interval after tracer injection is adequate to visualize all relevant LNs, however shorter intervals may suffice for some patients.

The accuracy of the estimated LN coordinates may be subject to skepticism given the non-diagnostic CT scans and, in some cases, the large size of intense LN. Despite the relatively low resolution of these non-diagnostic CT scans, osseous structures and visceral contours were clearly defined. Spatial coordinates were determined in the transverse, sagittal, and coronal planes and were based on the relationships of LNs to anatomical landmarks. The use of multiple clearly defined and visually distinct landmarks in three spatial planes afforded extensive data with which to estimate spatial coordinates, allowing a high level of precision. LNs were consistently identified on the high-resolution radiation simulation CTs at the sites indicated by the SPECT/CT-estimated coordinates suggesting that these LNs corresponded to the physiologically relevant LNs detected on SPECT/CT.

Our results suggest that reducing radiation exposure to the LNs critical for arm drainage with SPECT/CT-guided treatment planning may be warranted as more than half of the patients with LN negative disease received doses associated with lymphatic compromise.<sup>24</sup> Patients with negative LNs have negligible risk of local recurrence, hence the decision to limit LN radiation is relatively straightforward in this cohort.<sup>37-39</sup> The decision process becomes considerably more complex in LN positive patients. Failure to adequately irradiate these patients' LNs may compromise loco-regional control and is an issue that requires further investigation..

Our study was exploratory and subjects were recruited without regard to their nodal status or recurrence risk. In the absence of preliminary data, the authors felt it was not defensible to alter their treatment plans. Criteria were therefore not developed to determine which patients would be eligible for LN sparing. Formulation of such criteria will be essential if SPECT/CT is to influence the radiation treatment of LN positive patients. An important next step will be determination of the achievable dose reduction using this approach in patient subgroups defined by tumor and LN characteristics. Ultimately, SPECT/CT may solely benefit LN negative patients. However since approximately 70% of patients currently present with LN negative breast cancer, the impact will still be significant.

Application of the technique described in this paper is not limited to breast cancer treatment and has potential utility in other cancer populations. LN irradiation is an integral part of the treatment of many cancers including head and neck, cervical, endometrial, prostate, and colon. Lymphedema complicates the post-treatment course of these malignancies and SPECT/CT-guided radiation has the potential to reduce survivors' long-term morbidity. Additionally, the consequences of lymphatic injury extend well beyond lymphedema. Lymphostasis has been implicated in fibrosis, joint contractures and chronic pain.<sup>40</sup> By mitigating these sequelae, LN sparing may offer substantial benefits unrelated to lymphedema. Conversely, localization of LNs draining discrete territories can potentially be used to target nodes suspected of harboring metastases.

The capacity to plan radiation treatments based on the locations of critical, disease-free LNs has important implications for image-guided precision radiotherapy approaches like IMRT. Various investigators have discussed the merits of IMRT in breast cancer treatment; however, none have looked into selectively modulating dose to LNs.<sup>41-46</sup> Our results suggest that the SPECT/CT approach provides critical information for the application of IMRT to LN sparing, e.g. LN functional significance and location. Simulated IMRT-based plans for the study subjects corroborated that IMRT can achieve significant reductions in LN radiation dosimetry.

## ***CONCLUSION***

SPECT/CT fusion imaging provides a promising method of precisely localizing the axillary and supraclavicular LNs responsible for arm drainage following breast cancer surgery. This information can be integrated into radiation treatment planning to minimize irradiation of critical, normal LNs. Since radiation is a major contributor to the development of lymphedema,<sup>17, 47</sup> the SPECT/CT approach may offer meaningful benefit to breast cancer survivors by substantially reducing their lymphedema risk and enhancing their quality of life.

## **ACKNOWLEDGEMENTS**

Dr Cheville has received support from Department of Defense Congressionally Directed Breast Cancer Research Program Award numbers DAMD17-03-1-0622 and DAMD17-00-1-0649. The authors have no financial or other conflicts of interest to declare.

The experiments described in this article comply with the current laws of the United States and were approved with regards to human subjects and ethics considerations by the Institutional Review Board of the University of Pennsylvania.

1. Early Breast Cancer Trialists' Collaborative Group. Favourable and unfavourable effects on long-term survival of radiotherapy for early breast cancer: an overview of the randomised trials. Early Breast Cancer Trialists' Collaborative Group. *Lancet*. May 20 2000;355(9217):1757-1770.
2. Purushotham AD, Upponi S, Klevesath MB, et al. Morbidity after sentinel lymph node biopsy in primary breast cancer: results from a randomized controlled trial. *J Clin Oncol*. Jul 1 2005;23(19):4312-4321.
3. Czerniecki BJ, Bedrosian I, Faries M, Alavi A. Revolutionary impact of lymphoscintigraphy and intraoperative sentinel node mapping in the clinical practice of oncology. *Semin Nucl Med*. Apr 2001;31(2):158-164.
4. O'Mahony S, Rose SL, Chilvers AJ, et al. Finding an optimal method for imaging lymphatic vessels of the upper limb. *Eur J Nucl Med Mol Imaging*. Apr 2004;31(4):555-563.
5. Vinnicombe SJ, Norman AR, Nicolson V, Husband JE. Normal pelvic lymph nodes: evaluation with CT after bipedal lymphangiography. *Radiology*. Feb 1995;194(2):349-355.
6. Clarke M, Collins R, Darby S, et al. Effects of radiotherapy and of differences in the extent of surgery for early breast cancer on local recurrence and 15-year survival: an overview of the randomised trials. *Lancet*. Dec 17 2005;366(9503):2087-2106.
7. Chang JH, Vines E, Bertsch H, et al. The impact of a multidisciplinary breast cancer center on recommendations for patient management: the University of Pennsylvania experience. *Cancer*. Apr 1 2001;91(7):1231-1237.
8. Mehta PS, Harrison LB. Function and organ preservation in adult cancers of the head and neck. *Expert Rev Anticancer Ther*. Mar 2007;7(3):361-371.
9. Maunsell E. *Facteurs de risque de la détresse psychologique chez les patientes atteintes de cancer du sein*. Ottawa: Bibliothèque nationale du Canada; 1989.
10. Passik SD, McDonald MV. Psychosocial aspects of upper extremity lymphedema in women treated for breast carcinoma. *Cancer*. Dec 15 1998;83(12 Suppl American):2817-2820.
11. Reed DR, Lindsley SK, Mann GN, et al. Axillary lymph node dose with tangential breast irradiation. *Int J Radiat Oncol Biol Phys*. Feb 1 2005;61(2):358-364.

12. Recht A, Siddon RL, Kaplan WD, Andersen JW, Harris JR. Three-dimensional internal mammary lymphoscintigraphy: implications for radiation therapy treatment planning for breast carcinoma. *Int J Radiat Oncol Biol Phys*. Mar 1988;14(3):477-481.
13. Coen JJ, Taghian AG, Kachnic LA, Assaad SI, Powell SN. Risk of lymphedema after regional nodal irradiation with breast conservation therapy. *Int J Radiat Oncol Biol Phys*. Apr 1 2003;55(5):1209-1215.
14. Larson D, Weinstein M, Goldberg I, et al. Edema of the arm as a function of the extent of axillary surgery in patients with stage I-II carcinoma of the breast treated with primary radiotherapy. *Int J Radiat Oncol Biol Phys*. Sep 1986;12(9):1575-1582.
15. Pezner RD, Patterson MP, Hill LR, et al. Arm lymphedema in patients treated conservatively for breast cancer: relationship to patient age and axillary node dissection technique. *Int J Radiat Oncol Biol Phys*. Dec 1986;12(12):2079-2083.
16. Erickson VS, Pearson ML, Ganz PA, Adams J, Kahn KL. Arm edema in breast cancer patients. *J Natl Cancer Inst*. Jan 17 2001;93(2):96-111.
17. Johansson S, Svensson H, Denekamp J. Dose response and latency for radiation-induced fibrosis, edema, and neuropathy in breast cancer patients. *International Journal of Radiation Oncology, Biology, Physics*. 2002;52(5):1207-1219.
18. Bentzen SM, Dische S. Morbidity related to axillary irradiation in the treatment of breast cancer. *Acta Oncologica*. 2000;39(3):337-347.
19. Meric F, Buchholz TA, Mirza NQ, et al. Long-term complications associated with breast-conservation surgery and radiotherapy. *Ann Surg Oncol*. Jul 2002;9(6):543-549.
20. Deutsch M, Flickinger JC. Shoulder and arm problems after radiotherapy for primary breast cancer. *Am J Clin Oncol*. Apr 2001;24(2):172-176.
21. Deutsch M, Flickinger JC. Arm edema after lumpectomy and breast irradiation. *Am J Clin Oncol*. Jun 2003;26(3):229-231.
22. Kocak Z, Overgaard J. Risk factors of arm lymphedema in breast cancer patients. *Acta Oncol*. 2000;39(3):389-392.
23. Cusick J. A Wilcoxon-type test for trend. *Statistics in Medicine*. 1985;4:87-90.
24. Ariel IM, Resnick MI, Oropeza R. The effects of irradiation (external and internal) on lymphatic dynamics. *Am J Roentgenol Radium Ther Nucl Med*. Feb 1967;99(2):404-414.
25. Scrimger RA, Connors SG, Halls SB, Starreveld AA. CT-targeted irradiation of the breast and internal mammary lymph nodes using a 5-field technique. *Int J Radiat Oncol Biol Phys*. Nov 1 2000;48(4):983-989.
26. Hunt MA, Shank B, McCormick B, Yahalom J, Graham M, Kutcher GJ. The use of lymphoscintigraphy in treatment planning of primary breast cancer. *Int J Radiat Oncol Biol Phys*. Sep 1989;17(3):597-606.
27. Mudun A, Aslay I, Aygen M, Muslumanoglu M, Bozfakioglu Y, Cantez S. Can preoperative lymphoscintigraphy be used as a guide in treatment planning of breast cancer? *Clin Nucl Med*. May 2001;26(5):405-411.
28. Balch GC, Mithani SK, Richards KR, Beauchamp RD, Kelley MC. Lymphatic mapping and sentinel lymphadenectomy after preoperative therapy for stage II and III breast cancer. *Ann Surg Oncol*. Jul 2003;10(6):616-621.
29. Lovrics PJ, Chen V, Coates G, et al. A prospective evaluation of positron emission tomography scanning, sentinel lymph node biopsy, and standard axillary dissection for axillary staging in patients with early stage breast cancer. *Ann Surg Oncol*. Sep 2004;11(9):846-853.
30. Stanton AW, Svensson WE, Mellor RH, Peters AM, Levick JR, Mortimer PS. Differences in lymph drainage between swollen and non-swollen regions in arms with breast-cancer-related lymphoedema. *Clin Sci (Lond)*. Aug 2001;101(2):131-140.
31. Petrek JA, Senie RT, Peters M, Rosen PP. Lymphedema in a cohort of breast carcinoma survivors 20 years after diagnosis. *Cancer*. Sep 15 2001;92(6):1368-1377.
32. Scarsbrook AF, Ganeshan A, Bradley KM. Pearls and pitfalls of radionuclide imaging of the lymphatic system. Part 2: Evaluation of extremity lymphoedema. *Br J Radiol*. Aug 2 2006.

33. Stanton AW, Modi S, Mellor RH, et al. A quantitative lymphoscintigraphic evaluation of lymphatic function in the swollen hands of women with lymphoedema following breast cancer treatment. *Clin Sci (Lond)*. May 2006;110(5):553-561.
34. Weissleder H, Weissleder R. Lymphedema: evaluation of qualitative and quantitative lymphoscintigraphy in 238 patients. *Radiology*. Jun 1988;167(3):729-735.
35. Kubik S. Anatomy of the Lymphatic System. In: Foldi M FE, Kubik S, ed. *Textbook of Lymphology*. Munich: Elsevier; 2003:88-90.
36. Yeung HW, Cody IH, Turlakow A, et al. Lymphoscintigraphy and sentinel node localization in breast cancer patients: a comparison between 1-day and 2-day protocols. *J Nucl Med*. Mar 2001;42(3):420-423.
37. Fisher B, Redmond C, Fisher ER, et al. Ten-year results of a randomized clinical trial comparing radical mastectomy and total mastectomy with or without radiation. *N Engl J Med*. Mar 14 1985;312(11):674-681.
38. Palesty JA, Foster JM, Hurd TC, Watroba N, Rezaishiraz H, Edge SB. Axillary recurrence in women with a negative sentinel lymph node and no axillary dissection in breast cancer. *J Surg Oncol*. Feb 1 2006;93(2):129-132.
39. Pejavar S, Wilson LD, Haffty BG. Regional nodal recurrence in breast cancer patients treated with conservative surgery and radiation therapy (BCS+RT). *Int J Radiat Oncol Biol Phys*. Dec 1 2006;66(5):1320-1327.
40. Tabibiazar R, Cheung L, Han J, et al. Inflammatory manifestations of experimental lymphatic insufficiency. *PLoS Med*. Jul 2006;3(7):e254.
41. Freedman GM, Anderson PR, Li J, et al. Intensity modulated radiation therapy (IMRT) decreases acute skin toxicity for women receiving radiation for breast cancer. *Am J Clin Oncol*. Feb 2006;29(1):66-70.
42. Fogliata A, Nicolini G, Alber M, et al. IMRT for breast. a planning study. *Radiother Oncol*. Sep 2005;76(3):300-310.
43. Fogliata A, Bolsi A, Cozzi L. Critical appraisal of treatment techniques based on conventional photon beams, intensity modulated photon beams and proton beams for therapy of intact breast. *Radiother Oncol*. Feb 2002;62(2):137-145.
44. Lomax AJ, Cella L, Weber D, Kurtz JM, Miralbell R. Potential role of intensity-modulated photons and protons in the treatment of the breast and regional nodes. *Int J Radiat Oncol Biol Phys*. Mar 1 2003;55(3):785-792.
45. Kestin LL, Sharpe MB, Frazier RC, et al. Intensity modulation to improve dose uniformity with tangential breast radiotherapy: initial clinical experience. *Int J Radiat Oncol Biol Phys*. Dec 1 2000;48(5):1559-1568.
46. Vicini F, Sharpe M, Kestin L, Wong J, Remouchamps V, Martinez A. The use of intensity modulated radiation therapy in the treatment of breast cancer: evolving definition, misdirected criticism, and untoward effects. *Int J Radiat Oncol Biol Phys*. Apr 1 2004;58(5):1642-1644.
47. Meek AG. Breast radiotherapy and lymphedema. *Cancer*. Dec 15 1998;83(12 Suppl American):2788-2797.

<b>Age</b> Mean (SD)	55.3 (15.3)
<b>Ethnicity</b> N (%)	
Caucasian	16 (50.0%)
Afro-American	14 (43.8%)
Hispanic	2 (6.25%)
<b>Basal Metabolic Index</b> Mean (SD)	28.2 (5.7)
<b>Side of cancer</b> N (%)	
Right	17 ( 53.1%)
Left	15 (46.9%)
<b>Surgery for 1° breast cancer</b> N (%)	
Lumpectomy	18 (56.3%)
Mastectomy	14 (43.8%)
<b>Axillary surgery</b> N (%)	
Sentinel lymph node biopsy only	16 (50.0%)
Axillary clearing	16 (50.0%)
<b>Number of axillary LN resected</b> Mean (SD)	
Total Cohort	8.7 (7.5)
Sentinel lymph node biopsy only	2.8 (1.5)
Axillary clearing	14.6 (6.3)
<b>Chemotherapy*</b> N(%)	19 (59.4%)
<b>Hormonal therapy†</b> (N%)	6 (18.8)%
<b>Elapsed interval between tracer injection and SPECT/CT scan</b> N (SD)	323.1 (46.7) min

Table 1. Demographic and cancer treatment characteristics of the study cohort.

\* 3 subjects received Adriamycin & Cytosin alone while 16 subjects received Adriamycin & Cytosin followed by a taxane.

† All 6 subjects were taking Arimidex

SD, Standard Deviation; LN, Lymph Node

	All Subjects	Sentinel LN Biopsy	Axillary LN Clearing	p value*
	N=32	N=16	N=16	
Median number of LN	3.0	3.0	4.0	NS†
Lateral axilla	1.0	1.0	1.0	NS†
Medial axilla	1.0	1.0	1.0	NS†
Supraclavicular	1.0	0	1.5	0.006†
Proportion of total LN				0.02‡
Lateral axilla	47.7% (34.9)	62.9% (32.4)	31.6% (30.7)	0.01†
Medial axilla	26.8% (29.4)	26.5% (31.2)	27.1% (28.5)	NS†
Supraclavicular	25.5% (29.2)	10.6% (20.2)	41.3% (29.6)	0.005†
Location of LN with greatest activity				0.05‡
Lateral axilla	20 (61.3%)	13 (81.3%)	7 (43.8%)	
Medial axilla	5 (16.1%)	2 (12.5%)	3 (18.8%)	
Supraclavicular bed	7 (22.6%)	1 (6.3%)	6 (37.5%)	

Table 2. Results of SPECT/CT scan analyses including LN number and LN location for all subjects, subjects post SLNB, and subject post ALND

\* p values  $\leq 0.1$  were reported, otherwise they are listed as non-significant (NS)

† p values are for comparisons of subjects who underwent sentinel LN biopsy versus axillary clearing

‡ p value for a test for trend across ordered groups.

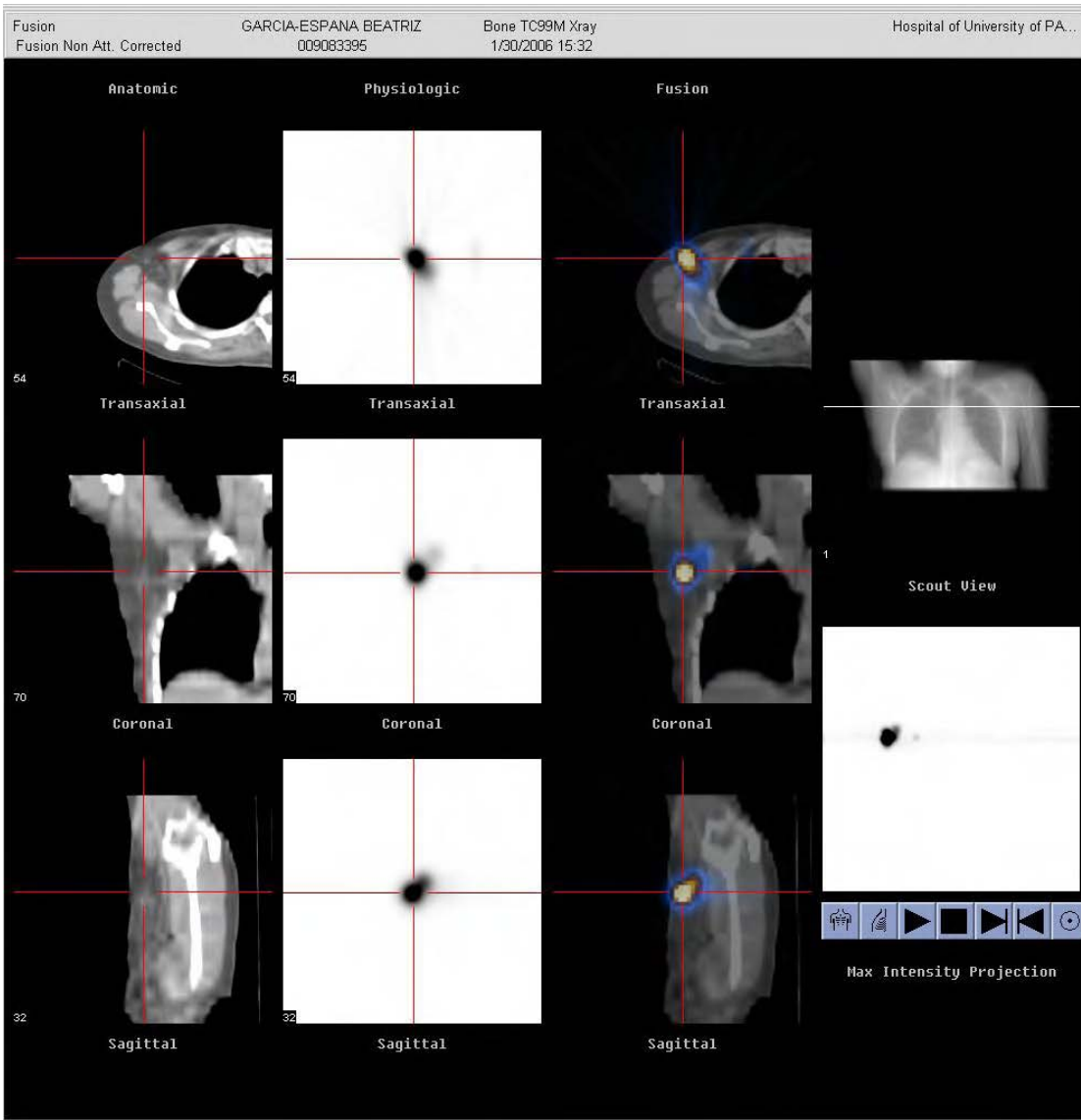


Figure 1. SPECT/CT images in transaxial, coronal, and sagittal planes of a breast cancer patient status post lumpectomy and SNLB with 2 visible LNs in the lateral axilla

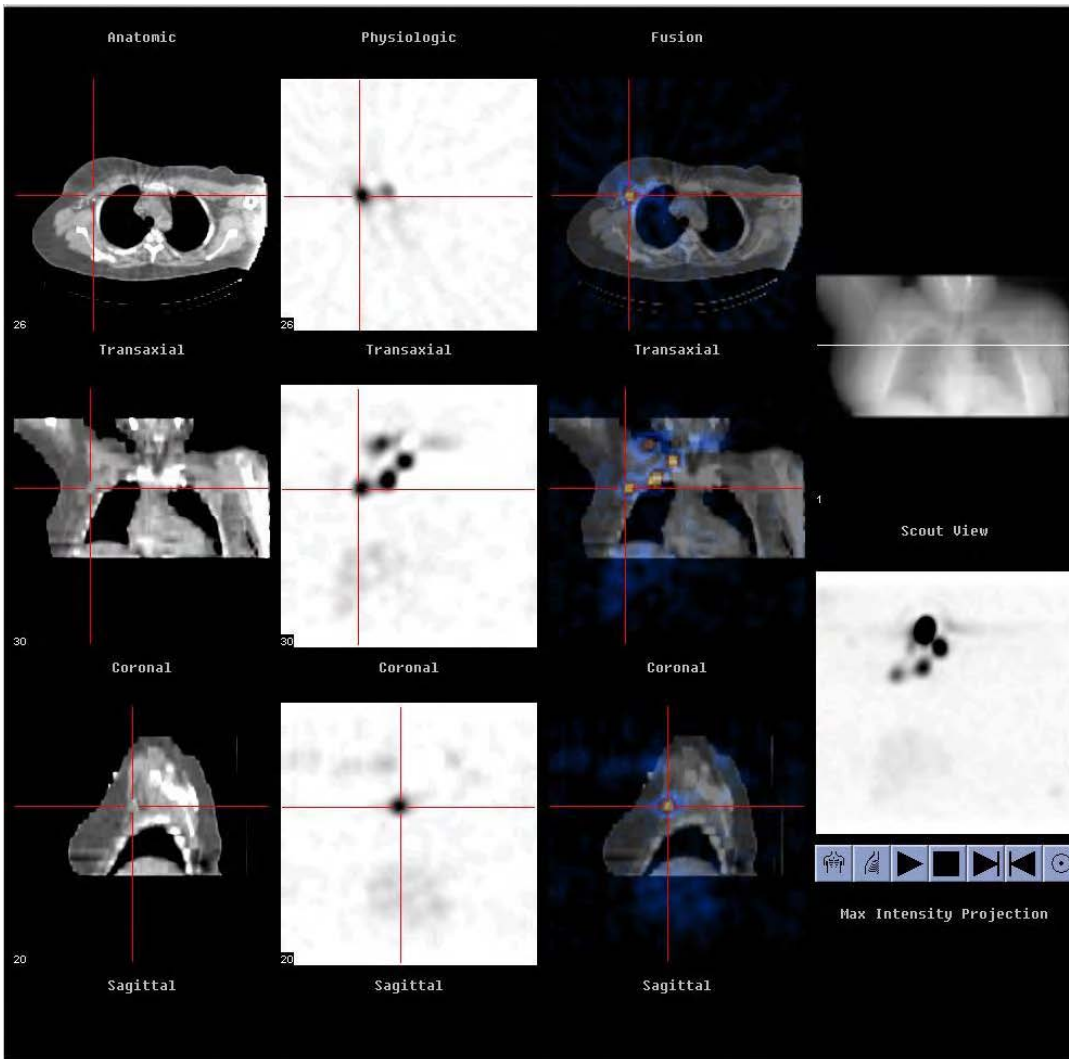


Figure 2. SPECT/CT images in transaxial, coronal, and sagittal planes of a breast cancer patient status post lumpectomy and level I and II axillary clearing with 5 visible LNs; 2 medial axillary and 3 supraclavicular.

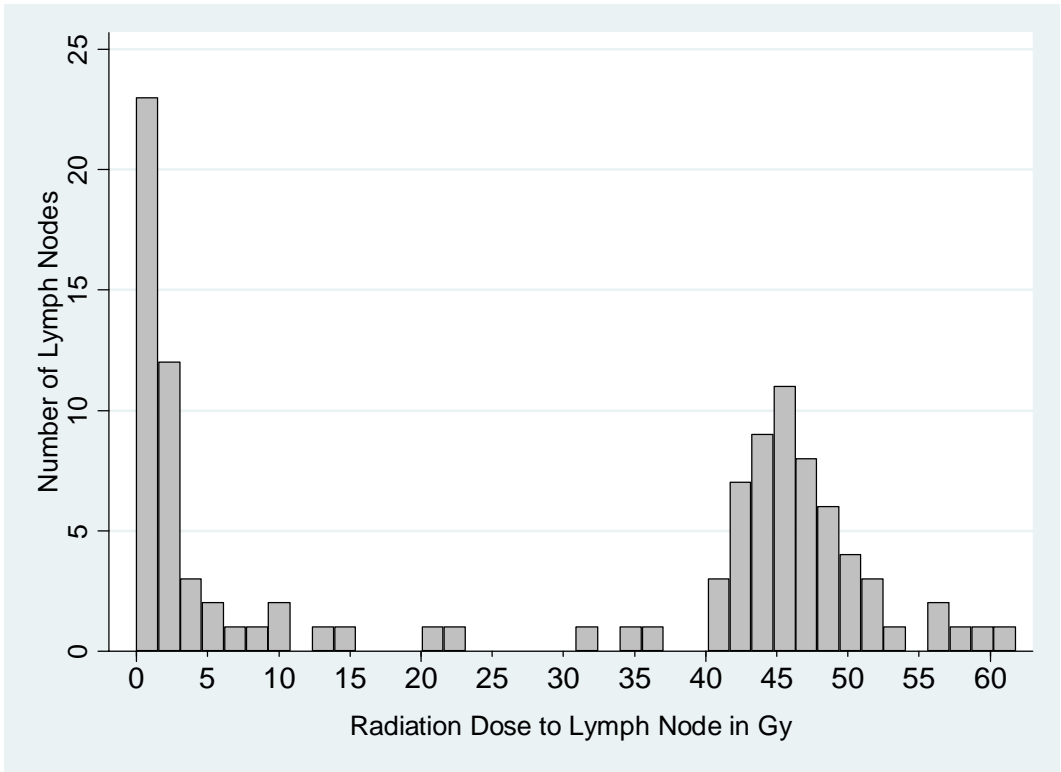


Figure 3. Bimodal distribution of radiation dose, in Gy, delivered to lymph nodes draining the upper extremity following surgery for primary breast cancer.

Radiation Dose in Gy	LN	Subjects	Number of LN per location	
>50	10	6	Lat Ax	4
			Med Ax	2
			SC	4
41-50	47	21	Lat Ax	17
			Med Ax	16
			SC	14
31-40	3	2	Lat Ax	0
			Med Ax	2
			SC	1
21-30	2	2	Lat Ax	0
			Med Ax	2
			SC	1
11-20	3	3	Lat Ax	2
			Med Ax	0
			SC	1
0-10	43	19	Lat Ax	17
			Med Ax	11
			SC	15

Table 3. Number of lymph nodes, subjects, and lymph nodes by area grouped by radiation exposure in 10 Gy intervals.

***Appendix B:***

**Version 3: (Nov 16, 2007)**

**Use of Lymphoscintigraphy for Evaluation of Lymphedema Risk Reduction in Radiation Treatment of Primary Breast Cancer**

Indra J. Das, PhD, FACR<sup>1\*</sup>, Andrea Cheville, MD, MSCE<sup>2,a</sup>, Joshua Scheuermann, MS<sup>3</sup>, Shyam M. Srinivas, MD<sup>3</sup>, Abass Alavi, MD<sup>3</sup>, Lawrence J. Solin, MD, FACR<sup>1</sup>

Departments of Radiation Oncology<sup>1</sup>, Rehabilitation Medicine<sup>2</sup>, Nuclear Medicine<sup>3</sup>, University of Pennsylvania, Philadelphia, PA, 19104, USA

***\*Reprint Request:*** *Indra J. Das, Radiation Oncology, University of Pennsylvania, 2 Donner Building, 3400 Spruce St, Philadelphia, PA 19104, USA*

*Phone: 215-662-6572, Fax: 215-349-5978*

*Email: [Das@xrt.upenn.edu](mailto:Das@xrt.upenn.edu)*

<sup>a</sup>Present Address:

Department of Physical Medicine and Rehabilitation, Mayo Clinic, Rochester, MN 55905

Acknowledgement:

This study was supported in part from a DOD Grant No. DAMD17-03-1-0622

## **ABSTRACT**

**Purpose:** Lymph node irradiation combined with surgery and chemotherapy increases the risk of arm lymphedema in the management of breast cancer. To evaluate this complication, a SPEC-CT scintigraphic device commonly used in cardiology study is investigated to map the lymphatic drainage in radiation treatment.

**Materials and Methods:** Under Institutional Review Board (IRB) approval, 36 patients that were planned for radiation treatment for breast cancer were enrolled in a feasibility of SPEC/CT lymphoscintigraphy study. There were 4 cases treated without CT data (2D) and the remaining 32 cases were treated with CT data in 3D conformal treatment planning. A 0.5 mCi Sulphur-collidal tagged with  $^{99m}\text{Tc}$  were injected in the ipsilateral arm. After 5-8 hrs post injection, patients were positioned close to the radiation treatment setup and the SPECT-CT scans were taken that provided CT data co-registered with SPECT images. Imaging analysis was performed on an ENTRGRA system. The visualized lymph nodes were marked and their coordinates were recorded. The SPEC-CT images were transferred for to the radiation treatment planning system for registration. Based on the coordinates from SPECT-CT system, the visualized lymph nodes were delineated on the radiation treatment planning CT data. The original treatment plan was recreated for dose to nodes were estimated. Intensity modulated radiation therapy (IMRT) planning was performed to see the efficacy of reducing dose to lymph nodes that may be involved in the potential development of arm lymphedema as a complication after radiation treatment.

**Results:** The number of lymph nodes varied from 0-10 with a mean value of  $3.4 \pm 5.4$  nodes. The location of nodes varied in the axillary, supraclavicular, and breast regions depending upon the surgical procedure and the extent of the disease. The prescribed radiation dose to the breast varied from 45Gy-50.4Gy depending on the disease pattern in 32 evaluated patients. The dose to lymph nodes varied from 0-61.8Gy depending upon the location and the technique used. Although not used to treat patients, IMRT plans were performed for (n?) patients to demonstrate that the information provided by the SPECT/CT could be used to tailoring the nodal dose in order to decrease the risk of development of arm lymphedema.

**Conclusions:** The SPEC-CT device provides a novel method to map the lymph nodes in the radiation treatment fields. Depending upon individual patient treatment planning requirements, the SPECT/CT method could be used to tailor the radiation dose using modern radiation treatment planning techniques.

**Key Words:** Breast cancer, Lymphedema, Scintigraphy, SPECT/CT, IMRT, Lymph nodes

## INTRODUCTION

The combined modality management of the breast cancer is commonly used, with radiation treatment playing an increasingly critical role in the management of breast cancers (1, 2). The long term complications of such treatments are often misleading and debated as reflected in the recent literatures (not clear what you mean here) (3, 4). Cardiac toxicities, pneumonitis, plexopathy, breast seroma, fibrosis, neuropathy and edema are known potential complications of radiation treatment of breast cancer (3-19). Unfortunately, lymphedema typically is an incurable, insidiously progressive and debilitating complication of combined modality treatment that adversely affects quality of life. The factors that has been demonstrated to contribute to arm lymphedema are surgery technique, radiation treatment technique, chemotherapy, obesity and age (14, 15, 20-22). The lymphedema rate has dropped from the days of Halsted (62%) to a significantly lower rate (4-30%) in modern days with combined modality treatment (4, 10-13, 17, 23). A relatively smaller percentage (1-16%) of lymphedema is attributed to the traditional radiation treatments alone.

Despite surgical sparing of lymph nodes with sentinel node biopsy, lymphedema remains prevalent in breast cancer management. Radiation treatment often increases patients' lymphedema risk since conventional fields encompass residual functioning lymphatics. The ability to localize axillary lymph nodes with specific drainage patterns is gaining momentum in radiation oncology (not clear what you mean here). This is partially driven by the trend on minimal surgery to spare aesthetically- and functionally-important structures and augment patient care with combined modality including radiation to improve survival and more importantly cosmetic outcome and the quality of life. Lymphatic drainage mapping has been attempted by various methods mainly with high resolution gamma camera with Au-198 colloids or Sb, Re sulfide colloids tagged with  $^{99}\text{Tc}$  (21, 24). Scrimger et al (25) provided an innovative approach using MRI to locate internal mammary vessels and then mapping the lymphatics based on anatomical patterns.

In general, the severity of lymphedema is a function of radiation dose, fraction size, treatment fields and technique (13). Various studies have indicated that tangential fields in general do not cover all of the level I and II axillary nodes with full dose (20, 26, 27). The efficacy of the posterior axillary boost fields have also been criticized (28). Typically,  $2/3$  (may be higher in some studies) of the level-I and  $1/2$  of the level-II lymph nodes are included in the tangential breast treatment. With the inclusion of supraclavicular and posterior axillary boost axillary radiation treatment fields, the number of nodes included in the radiation treatment could be significantly large (29). Substantial fraction (13-44%) of patients who are irradiated with such techniques develop arm lymphedema and it is believed that lymphedema rate is even much higher (16). Goodman *et al.* (30) indicated that for adequate coverage of the target and sparing lymphatics, individualized CT scan and lymph drainage mapping should be performed; however, some lymphatics are hard to visualize on CT scan and a different approach needs to be taken.

Technological advances in image guided precision radiotherapy such as stereotactic radiation techniques, CyberKnife, and intensity modulated radiation therapy (IMRT) have enhanced the potential for sparing normal tissue while eradicating malignant tissues. This has opened an avenue to precisely contour the target volumes for radiation fields from imaging tools and creates the possibility of modulating radiation dose to axillary nodes. Such approaches have not been fully implemented in the management of breast cancer where still 2-dimensional (2D) without CT data approach is widely used (31). However, specific and individualized radiation fields based on imaging can limit the radiation dose to the lymph nodes that do not harbor cancer cells and that support valuable physiological functions. Compromise of these lymph nodes increases patients' risk of lymphedema, a functionally morbid and incurable complication of breast cancer therapy. Conversely, selected patients may be judged to require nodal irradiation, and the radiation treatment planning volumes can be adjusted to include such nodal regions in the target volume for these selected patients. (Indra, suggest pointing out that this data can be used both ways: to EXCLUDE the LN's in some patients to reduce lymphedema risk, but also to INCLUDE the LN's in other patients judged to be at high risk and requiring nodal radiation.

The use of lymphoscintigraphy had been attempted for radiation treatment planning to include occult lymphatics in the radiation treatment fields (21, 32, 33). Lymphoscintigraphy has provided a manual geometrical method to map the lymphatics on 2D simulation film for treatment planning. Special attention was paid to the placement of field size to include the lymphatics that were deemed occult from scintigraphy. Such manual approaches are labor intensive and prone to error. Modern imaging technologies may identify these lymphatics and allow the construction of radiation fields that minimize their radiation exposure while preserving loco-regional tumor control. Dual modality imaging, SPECT-CT, has been used for cardiac imaging for quantitative measurement (34, 35) and now commonly used in breast cancer imaging (36-41) with high degree of specificity for sentinel node verifications (42). Such approach using a hybrid camera combining a dual-head SPECT camera with a low-dose, single slice CT scanner, (Hawkeye®, GE Medical system) is attempted in this study. This device is widely available in cardiology community and has the potential to localize lymph nodes with specific drainage patterns after surgical removal of axillary lymph nodes. Thus lymphoscintigraphy could provide functional information to supplement other imaging modalities.

The aim of this study was to determine whether SPECT/CT scanning can be used to determine spatial coordinates for lymph nodes draining the arm after primary breast cancer surgery and whether this information could be incorporated into radiation treatment planning with SPECT-CT and CT fusion to quantify nodal dosimetry.

## **MATERIALS & METHODS**

A dual imaging hybrid SPECT-CT system (Hawkeye, GE Medical Systems) is used to image lymphatic nodes. This device was mainly developed for quantitative imaging and provided unique correlations between spatial coordinates and anatomical structure (CT) with physiological information (SPECT). The co-registered image provides voxel-by-voxel space that is properly mapped with SPECT space to the CT data. Details of such system have been described by several investigators (35, 38, 41, 43, 44) and briefly described here. (suggest that you reference the Cheville paper #49 early in the Methods section)

Hybrid imaging SPECT system utilizes a GE Millennium dual-headed gamma camera (VG8) with Hawkeye low dose CT on a common single gantry. It provides corrections for collimator blurring, and attenuation corrections with an iterative reconstruction algorithm. For the SPECT acquisition, counts from the 15% energy windows at 140 keV are acquired into a 128 x 128 (pixel size, 4.6 x 4.6 mm). Sixty (30x2) frames are acquired at 6°/step angular sampling over 360° rotations. The camera head is equipped with a high-resolution low-energy parallel-hole collimator. The CT detector consists of 384 crystals and photodiodes mounted on the gamma camera rotating module. The CT data is acquired in a single slice mode over 180° rotations. The CT device is a low powered low exposure system that takes 10 mm thick slice with 256x256 (1.5x1.5 mm) matrix size. It typically acquires 40 slices at the end of SPECT images by translating the table. The scanner parameters include, 140 kVp (range 120 – 140 kVp), tube current range 1.0 – 2.5 mA, for low radiation exposure. The entire process typically takes 30 minutes. Reconstruction is performed by back projection method using iterative filtered ordered subset expectation maximization (OSEM) technique. Images are smoothed with a 3D spatial Gaussian filter. The image fusion and processing of SPECT and CT data is performed on eNTEGRA or Xeleris system (GE Medical Systems). It analyzes and displays the images in three planes in axial, coronal and sagittal slices.

Institutional Review Board (IRB) approval was obtained for this study. A total of 215 patients were approached and screened for this pilot study participation. Thirty-six patients were recruited within 2 weeks (this isn't clear – some of the patients were recruited and studied during the first week or two of radiation treatment) prior to radiation treatment for primary breast cancer who consented to be on this study. These patients were planned for radiation treatment in traditional method based on either 2D or 3D treatment planning with proper immobilization using angled board and Alpha-Cradle system. This study did not alter the planned radiation treatments and was conducted within (same comment as above about timing) 2 weeks of the radiation treatment. The treatment planning was optimized based on beam energy (31), beam weight, and wedge. The dose was prescribed to an isodose line that covers entire breast tissue that has been described by Das *et al.* (45). The treatment fields were 2-fields (tangents), 3-fields (tangents + supraclavicular field), or 4-fields (3-fields + posterior axillary boost) to suit the need of the patients depending upon the disease status.

In order to facilitate integration of SPECT/CT scans with the radiation planning simulator CT scan patients were positioned with their shoulders abducted to 135° and externally rotated to 90° in their immobilization cast that was created for radiation simulation and treatment in radiation oncology department. The SPECT/CT position was very closely approximated with proper shoulder and arm configuration utilized during radiation therapy.

To identify lymph nodes draining the arm, 1mCi <sup>99m</sup>Tc- labeled sulfur colloid (2 injection of 0.5mCi) was injected subdermally into the dorsal hand and medial cubit ipsilateral to primary breast cancer. A specially designed Hawkeye system as described above was used for scintigraphic and CT imaging ≥ 5 hours after sulfur colloid injection using positioning identical to the radiation therapy CT-simulation. These images permitted spatial location of the lymph nodes. The x, y, z coordinates of the lymph nodes were determined. The CT images from eNTEGRA were transferred to the radiation treatment planning system and fused with the CT-simulation images. The lymph node loci were drawn on the simulation images to quantify dosimetry. The SPECT/CT system improves quantitative imaging since CT and SPECT are integrated in a single gantry allowing the co-registration of the SPECT images with CT anatomy without fiducial marking or image fusion that has been attempted in the past. SPECT/CT system integration have been reported in the literature for various disease site for the quantitative imaging (34, 38, 39, 43, 44).

The SPECT/CT data were not compatible with the DICOM-RT format and there was no easy method to transfer the fused images of SPECT/CT to the radiation treatment planning process. The CT data from SPECT-CT was fused with the simulation CT on the Oncentra (Nucletron Corp, Holland) radiation treatment planning system. This was carried out manually by recoding the location of lymph nodes on a SPECT/CT slices. Each lymph node was given a name (?unique identifier?) and its x,y,z coordinate was recorded. The SPECT/CT data was transferred to our 3D radiation treatment planning system. Image fusion between simulation CT and SPECT/CT was carried out. Based on the recorded coordinates of the lymphatic system, these nodes were mapped to the treatment planning system.

Since most patients were already treated, their treatment plans were retrospectively transferred to the mapped lymphatic coordinates for the estimation of dose to each lymph node based on the radiation treatment techniques; 2-fields (tangential breast fields) 3-fields (Tangents + supraclavicular field), and 4-fields (3-fields+ posterior axillary boost), beam energy, wedges, beam weights and other parameters for dosimetric evaluation and analysis.

For a few select cases (can you give number here?), IMRT planning was performed using 6-fields technique with 6 MV photon beam (reference or description?). The beams were distributed manually using beam's eye view approach rather earlier published techniques of evenly distributed beams (46-48). Target volume was defined as the palpable breast tissue anterior to the chest wall to within 3 mm of skin surface. Lung and the lymph nodes were delineated as the organs at risk (OAR). The IMRT optimization was carried out using inverse planning routine of the Oncentra treatment planning system (Nucletron, Columbia, MD) based on the ray-search technique. The dose-

volume constraints were set with proper weight to provide adequate dose to full breast tissues and <10% dose to the lymph nodes.

## RESULTS

Among 36 patients in this study 32 were treated with 3-D conformal therapy with CT data. Prior to the SPECT/CT and radiation therapy, surgical treatment was that 58% of the patients underwent lumpectomy and the remaining 42% modified radical mastectomy. An average of 3.38 (SD 2.01) lymph nodes was identified among these patients with lymph node distribution of 0-10 nodes/patient. Hybrid SPECT/CT scan from one of the patients is presented in Figure 1. Significant intra-subject variation was noted in LN number and location. (Possibly attach a table). Patients who underwent sentinel lymph node (SLN) biopsy had fewer visualized lymph nodes ( $2.94 \pm 1.53$ ) than subjects who underwent axillary lymph node dissections (ALND) ( $3.81 \pm 2.37$ ), however this difference was not statistically significant ( $p = 0.22$ ). The absolute number and percentage of total lymph nodes located at axillary and supraclavicular sites was influenced by axillary surgery. A statistically significant trend was detected with greater numbers of lateral (not clear what you mean by “lateral”) axillary lymph nodes being noted among SLN patients and greater number of supraclavicular lymph nodes among ALND subjects ( $p = 0.001$ ). Neither body mass index, affected side (right vs. left), nor elapsed time between tracer injection and SPECT/CT scanning was significantly associated with either the number of visualized lymph nodes, LN locations, or total LN activity. A detailed analysis is presented elsewhere by Cheville *et al.*(49).

The treatment planning process included either 2-field (44%), 3-field (5%) or 4-field (51%) treatments. The node distribution through the Scintigraphy study was distributed through out breast, axillary and supraclavicular lymph node beds. Subjects receiving 4-field treatment were more likely to have >4 lymph nodes identified on SPECT/CT ( $p = 0.006$ ).

Dosimetric evaluation with SPECT/CT imaging, radiation fields and lymph node levels is shown in figure 2 for 32 evaluated patients(Not a great figure – hard to understand). It shows that 4-field technique was use more frequently with level III nodes with higher doses. The variation of combined dose from various fields varied from 0-61.8 Gy among the patients. When analyzed further, a bimodal dose distribution was noted in most cases studied as shown in Figure 3 for various locatrions (supraclavicular, axillary and axially dissection).

Figure 4 (eliminate: arrow, “red volume”, and DVH for breast scar)shows an IMRT plan where 2 nodes were located in the superior aspect of the breast near supraclavicular region. In traditional technique (tangential fields) these nodes will receive full dose, however, IMRT provided selectively dose reduction in the selected node. The different panels in Figure 4 shows dose in axial, sagittal, coronal and the dose-volume histogram (DVH). Note that dose to breast is adequately covered and the node dose are reduced. The lung dose is also reduced as optimized.

This feasibility of SPECT/CT incorporation into IMRT opens a new horizon in patient care where lymphedema can be reduced if the statuses of the lymph nodes are known. (again, suggest you include the other situation and possibility to cover the LN's if indicated clinically)

## ***DISCUSSION***

Various methods, CT, MRI (25), lymphoscintigraphy (20, 21, 24, 32, 37) and PET (36) has been used to localize and help in treatment planning. To our knowledge this is the first study to demonstrate that hybrid SPECT/CT scanning following intradermal injection of <sup>99m</sup>Tc-sulfur colloid allows precise localization of the lymph nodes draining the arm. Inferences regarding the relative contributions and pathophysiological significance of visualized lymph nodes can be made by quantifying lymph node activity. SPECT/CT scans allow precise determination of each visualized lymph nodes' spatial coordinates. The spatial coordinates can be integrated into radiation dosimetry planning in order to target or spare lymph nodes contingent on their clinical significance.

The purpose of this study was not to study the physiological status of the lymphatic system rather to identify lymph nodes that is involved in arm drainage that could affect lymphedema. Typically lymphoscintigraphy of the arm is performed by injecting tracer into the 1<sup>st</sup> and 2nd inter-digital webspaces of the hand. We modified this injection technique in an effort to ensure that all relevant lymph nodes were radioactively labeled. Lymph collecting vessels arise from discrete drainage territories on the arm. The anatomic origins of lymph vessels' dictate their positions relative to one another as they converge, course proximally, and terminate in axillary lymph nodes. Both the collecting vessels and lymph nodes are somatotopically organized. Due to this organization, only lymph nodes draining the territory where tracer has been injected will appear on scintigraphic images. The decision to inject multiple sites was prompted by concern that lymph nodes draining the peri-cubital region and upper arm would not be visualized if tracer was solely injected in the hand. This concern is supported by the clinical observation that lymphedema is generally confined to discrete portions of the upper extremity while other portions remain unaffected.(50) Presumably the uninvolved sections have lymph drainage distinct from the lymphedematous areas.

Our results suggest that acquisition of SPECT/CT scans between 5 to 8.5 hours following tracer injection permits adequate LN visualization. Several factors were considered in selecting the post-injection interval. The interval must be long enough to allow tracer to reach all axillary and supraclavicular lymph nodes. Our initial study design included a 2-hour interval prior to SPECT/CT scanning. However lymph nodes were inconsistently visualized in pilot patients and the interval was extended to  $\geq 5$  hours. The potential for impaired LN visualization due to radioactive decay with extended post-injection intervals was also considered. Qualitatively and quantitatively, no gross differences were appreciated between subjects scanned at the either end of the 5-8.5 hour post-injection interval. However, the absence of repeat or serial scans makes it impossible to estimate the time-associated variance in LN visualization and activity within our cohort. It has been reported that sentinel lymph nodes in breast

cancer patients can be localized equally well when tracer is injected  $\geq 16$  versus 2 hours prior to surgery.(51) Longer post-injection intervals would offer substantial logistical and convenience benefits.

If clinical inferences and management decisions are to be based on LN activity, then refinement of the technique is needed and its reliability must be assessed. A greater degree of standardization is required for certain test parameters which we did not control. These include the interval between tracer injection and SPECT/CT scanning and the extent of subjects' post-injection arm use. Upper extremity muscle recruitment can significantly increase lymph flow and thereby alter the rate of radioactive uptake in lymph nodes.(52) Additionally, activity must be adjusted for signal attenuation due to varying amounts of soft tissue between the gamma camera and lymph nodes (Not clear why you are making the following recommendations – based on what?)\_(We recommend expressing LN activity as a percentage of total injected activity. The amount of tracer injected at each deposition site inevitably varies due to technical limitations. To adjust for inconsistent injectate volumes, we recommend that the difference in syringe activity pre- and post-injection be summed across sites. This sum of differences is the total injected radioactivity. Activity per LN can be expressed as a percentage of this total to indicate the lymph nodes relative contribution to total drainage.

The accuracy of the estimated LN coordinates may be subject to skepticism given the non-diagnostic CT scans and in some cases the large size of intense LN. Despite the CT scans' relatively low resolution, osseous structures and some visceral outlines were clearly defined. Spatial coordinates were based on lymph nodes' relationships to the SPECT/CT slice and measured coordinates of each lymph node that were determined in the transverse, sagittal, and coronal planes. The use of multiple clearly defined and visually distinct landmarks in three spatial planes afforded extensive data with which to estimate spatial coordinates, allowing a high level of precision. Lymph nodes were consistently identified on the high-resolution radiation simulation CT at the site indicated by the estimated coordinates from SPECT/CT. Therefore these lymph nodes were determined to correspond to the physiologically relevant lymph nodes detected on SPECT/CT.

The SPECT/CT approach provides another venue to localize and provide method to reduce radiation dose to axillary and supraclavicular lymph nodes that may offer meaningful benefit to breast cancer survivors. It has been noted that surgery and radiation play a fine balance in lymphedema (13, 16, 17, 53). Lymphedema has been identified as a primary survivorship concern since lymphedema can produce severe medical, social, and psychological morbidity. Radiation dose has been a major contributor to the development of lymphedema(4, 54) The potential to reduce LN dosimetry may afford substantial lymphedema risk reduction, and mitigate the severity of lymphedema should it occur. This offers survivors the potential for improved health-related quality of life (HRQOL), and society the opportunity for substantial medico-economic savings. (also, cover LN's when clinically indicated and necessary based on status of disease)

The ability to localize lymph nodes draining the upper truncal quadrant and arm has important clinical applications in the management of the breast cancer. The benefits of lymphatic mapping in the breast cancer are evident in the widespread use of sentinel lymph node biopsy with limited surgical intervention allowing for combined modality treatment that has shown to produce superior outcome (55). Scintigraphic identification of sentinel nodes increases the probability that all nodal metastases will be respected, permits surgical sparing of uninvolved lymph nodes and reduces post-operative morbidity(56).

Gamma camera-based lymphoscintigraphy permits imaging of lymph nodes and, more limitedly, lymph collecting vessels without inherent anatomical reference. The absence of anatomic detail makes precise determination of LN locations challenging and in many cases impossible. To overcome the spatial information external radioactive markers are used that provides crude reference points that do not offer sufficient accuracy to guide therapeutic interventions. Improved imaging methods; Computed tomography (CT) and magnetic resonance (MR) imaging allow visualization of sufficiently large lymph nodes (>3mm), but small, non-pathological lymph nodes are challenging to reliably localize. Even though CT and MRI scans may reveal enlarged lymph nodes, but the drainage territories and metabolic activity of these lymph nodes remain unknown. In many cases temporal distribution of the lymph nodes depicting, the physiological and pathophysiological relevance of specific lymph nodes cannot be determined by anatomic imaging techniques alone.

It has been observed that IMRT reduces radiation complications of the breast treatment (9, 57). Harsolia et al (9) compared 3D conformal versus IMRT for breast cancer and observed that among other complications breast edema was significantly reduced 25% versus 1% respectively. If such an observation is true then, lymph nodes mapping could reduce the risk of arm lymphedema altogether by tailoring the radiation doses.

Application of the technique described in this paper need not be confined to breast cancer treatment. LN irradiation is an integral part of the treatment of many cancers, for example, head and neck, cervical, endometrial, prostate, and rectal.

**Conclusions:** This study provides a feasibility of SPEC-CT imaging device that is used in cardiology for mapping lymphatics that could be used for patient treatment in radiation oncology. This study provides the knowledge that dose in these lymph nodes is variable from 0-full prescribed dose in treatment fields. This dosimetric variability may have impact in the onset of lymphedema. Lymphoscintigraphy SPECT data provide unique information allowing radiation fields to be tailored for preservation of lymphatic structures draining the arm. Radiation techniques such as IMRT could be used to modulate radiation dose to lymphatic system based on scintigraphic imaging. This study provides a clear advantage in non-invasive mapping of the lymph nodes for the management of the breast cancer using radiation treatment. (and LN's can be selectively included or excluded based on the clinical indications)

**Figure Captions:**

**Figure 1.** Part of lymphoscintigraphy images as seen on GE-Hawkey Spect/CT system. Four visible nodes that are identified are shown.

**Figure 2.** Scattergram of the type of treatment techniques, estimated dose to the lymph nodes and node level (I, II, III).

**Figure 3.** shows frequency distribution of dose estimations in (a) supraclavicle, (b) axilla, (c) breast.

**Figure 4.** IMRT plan showing the sparing of lymph nodes and lung.

## References

1. Clarke M, Collins R, Darby S, Davies C, Elphinstone P, Evans E, et al. Effects of radiotherapy and of differences in the extent of surgery for early breast cancer on local recurrence and 15-year survival: an overview of the randomised trials. *Lancet* 2005;366(9503):2087-2106.
2. Chang JH, Vines E, Bertsch H, Fraker DL, Czerniecki BJ, Rosato EF, et al. The impact of a multidisciplinary breast cancer center on recommendations for patient management: the University of Pennsylvania experience. *Cancer* 2001;91(7):1231-7.
3. Toledano A, Garaud P, Serin D, Fourquet A, Bosset JF, Breteau N, et al. Concurrent administration of adjuvant chemotherapy and radiotherapy after breast-conserving surgery enhances late toxicities: long-term results of the ARCOSEIN multicenter randomized study. *Int J Radiat Oncol Biol Phys* 2006;65(2):324-332.
4. Johansson S, Svensson H, Denekamp J. Dose response and latency for radiation-induced fibrosis, edema, and neuropathy in breast cancer patients. *Int J Radiat Oncol Biol Phys* 2002;52(5):1207-1219.
5. Pierce SM, Recht A, Lingos TI, Abner A, Vicini F, Silver B, et al. Long-term radiation complications following conservative surgery (CS) and radiation therapy (RT) in patients with early stage breast cancer. *Int J Radiat Oncol Biol Phys* 1992;23:915-923.
6. Gagliardi G, Lax I, Ottolenghi A, Rutqvist LE. Long-term cardiac mortality after radiotherapy of breast cancer-application of the relative seriality model. *Br J Radiol* 1996;69:839-846.
7. Rothwell RI, Kelly SA, Joslin CA. Radiation pneumonitis in patients treated for breast cancer. *Radiation Oncol* 1985;4(1):9-14.
8. Danoff BF, Goodman RL, Glick JH, Haller DH, Pajak TF. The effect of adjuvant chemotherapy on cosmesis and complications in patients with breast cancer treated by definitive irradiation. *Int J Radiat Oncol Biol Phys* 1983;9:1625-1630.
9. Harsolia A, Kestin L, Grills I, Wallace M, Jolly S, Jones C, et al. Intensity-modulated radiotherapy results in significant decrease in clinical toxicities compared with conventional wedge-based breast radiotherapy. *Int J Radiat Oncol Biol Phys* 2007;68(5):1375-1380.
10. Deutsch M, Flickinger JC. Shoulder and arm problems after radiotherapy for primary breast cancer. *Am J Clin Oncol* 2001;24(2):172-6.
11. Bentzen SM, Dische S. Morbidity related to axillary irradiation in the treatment of breast cancer. *Acta Oncol* 2000;39(3):337-347.
12. Meric F, Buchholz TA, Mirza NQ, Vlastos G, Ames FC, Ross MI, et al. Long-term complications associated with breast-conservation surgery and radiotherapy. *Ann Surg Oncol* 2002;9(6):543-549.
13. Kocak Z, Overgaard J. Risk factors of arm lymphedema in breast cancer patients. *Acta Oncol* 2000;39(3):389-392.
14. Pezner RD, Patterson MP, Hill LR, Lipsett JA, Desai KR, Vora N, et al. Arm lymphedema in patients treated conservatively for breast cancer: relationship to patient age and axillary node dissection technique. *Int J Radiat Oncol Biol Phys* 1986;12(12):2079-2083.
15. Larson D, Weinstein M, Goldberg I, Silver B, Recht A, Cady B, et al. Edema of the arm as a function of the extent of axillary surgery in patients with stage I-II carcinoma of the breast treated with primary radiotherapy. *Int J Radiat Oncol Biol Phys* 1986;12(9):1575-1582.
16. Senkus-Konefka E, Jassem J. Complications of breast-cancer radiotherapy. *Clin Oncol (R Coll Radiol)* 2006;18(3):229-35.
17. Erickson VS, Pearson ML, Ganz PA, Adams J, Kahn KL. Arm edema in breast cancer patients. *J Natl Cancer Inst* 2001;93(2):96-111.
18. Markiewicz DA, Schultz DJ, Haas JA, Harris EER, Fox KR, Glick JH, et al. The effects of sequence and type of chemotherapy and radiation therapy on cosmesis and complications after breast conservation therapy. *Int J Radiat Oncol Biol Phys* 1996;35:661-668.

19. Hardenbergh PH, Recht A, Gollamudi S, Come SE, Hayes DF, Shulman LN, et al. Treatment-related toxicity from a randomized trial of the sequencing of doxorubicin and radiation therapy in patients treated for early stage breast cancer. *Int J Radiat Oncol Biol Phys* 1999;45(1):69-72.
20. Reed DR, Lindsley SK, Mann GN, Austin-Seymour M, Korssjoen T, Anderson BO, et al. Axillary lymph node dose with tangential breast irradiation. *Int J Radiat Oncol Biol Phys* 2005;61(2):358-364.
21. Recht A, Siddon RL, Kaplan WD, Andersen JW, Harris JR. Three-dimensional internal mammary lymphoscintigraphy: implications for radiation therapy treatment planning for breast carcinoma. *Int J Radiat Oncol Biol Phys* 1988;14(3):477-481.
22. Coen JJ, Taghian AG, Kachnic LA, Assaad SI, Powell SN. Risk of lymphedema after regional nodal irradiation with breast conservation therapy. *Int J Radiat Oncol Biol Phys* 2003;55(5):1209-1215.
23. Deutsch M, Flickinger JC. Arm edema after lumpectomy and breast irradiation. *Am J Clin Oncol* 2003;26(3):229-231.
24. Mudun A, Aslay I, Aygen M, Muslumanoglu M, Bozfakioglu Y, Cantez S. Can preoperative lymphoscintigraphy be used as a guide in treatment planning of breast cancer? *Clin Nucl Med* 2001;26(5):405-411.
25. Scrimger RA, Connors SG, Halls SB, Starreveld AA. CT-targeted irradiation of the breast and internal mammary lymph nodes using a 5-field technique. *Int J Radiat Oncol Biol Phys* 2000;48(4):983-989.
26. Schlembach PJ, Buchholz TA, Ross MI, Kirsner SM, Salas GJ, Strom EA, et al. Relationship of sentinel and axillary level I-II lymph nodes to tangential fields used in breast irradiation. *Int J Radiat Oncol Biol Phys* 2001;51(3):671-678.
27. McCormick B, Botnick M, Hunt M, Petrek J. Are the axillary lymph nodes treated by standard tangent breast fields? *J Surg Oncol* 2002;81(1):12-16.
28. Bentel GC, Marks LB, Hardenbergh PH, Prosnitz LR. Variability of the depth of supraclavicular and axillary lymph node in patients with breast cancer: is a posterior axillary boost field necessary? *Int J Radiat Oncol Biol Phys* 2000;47(3):755-758.
29. Aristei C, Chionne F, Marsella AR, Alessandro M, Rulli A, Lemmi A, et al. Evaluation of level I and II axillary nodes included in the standard breast tangential fields and calculation of the administered dose: results of a prospective study. *Int J Radiat Oncol Biol Phys* 2001;51(1):69-73.
30. Goodman RL, Grann A, Saracco P, Needham MF. The relationship between radiation fields and regional lymph nodes in carcinoma of the breast. *Radiother Oncol* 2001;50:99-105.
31. Das IJ, Shikama N, Cheng CW, Solin LJ. Choice of beam energy and dosimetric implications for radiation treatment in a subpopulation of women with large breasts in the United States and Japan. *Med Dosim* 2006;31(3):216-223.
32. Hunt MA, Shank B, McCormick B, Yahalom J, Graham M, Kutcher GJ. The use of lymphoscintigraphy in treatment planning of primary breast cancer. *Int J Radiat Oncol Biol Phys* 1989;17(3):597-606.
33. Jones D, Hanelin L, Christopherson D, Hafermann MD, Richardson RG, Taylor WJ. Radiotherapy treatment planning using lymphoscintigraphy. *Int J Radiat Oncol Biol Phys* 1986;12(9):1707-1710.
34. Kalki K, Blankespoor SC, Brown JK, Hasegawa BH, Dae MW, Chin M, et al. Myocardial perfusion imaging with a combined x-ray CT and SPECT system. *J Nucl Med* 1997;38(10):1535-1540.
35. Hasegawa B, Tang HR, Da Silva AJ, Wong KH, Iwata K, Wu MC. Dual-modality imaging. *Nucl Instr Meth Phys Res A* 2001;471:140-144.
36. Lovrics PJ, Chen V, Coates G, Cornacchi SD, Goldsmith CH, Law C, et al. A prospective evaluation of positron emission tomography scanning, sentinel lymph node biopsy, and standard axillary dissection for axillary staging in patients with early stage breast cancer. *Ann Surg Oncol* 2004;11(9):846-853.
37. Balch GC, Mithani SK, Richards KR, Beauchamp RD, Kelley MC. Lymphatic mapping and sentinel lymphadenectomy after preoperative therapy for stage II and III breast cancer. *Ann Surg Oncol* 2003;10(6):616-621.
38. O'Connor MK, Kemp BJ. Single-photon emission computed tomography/computed tomography: basic instrumentation and innovations. *Semin Nucl Med* 2006;36(4):258-266.

39. Lerman H, Lievshitz G, Zak O, Metser U, Schneebaum S, Even-Sapir E. Improved sentinel node identification by SPECT/CT in overweight patients with breast cancer. *J Nucl Med* 2007;48(2):201-206.
40. Even-Sapir E, Flusser G, Lerman H, Lievshitz G, Metser U. SPECT/multislice low-dose CT: a clinically relevant constituent in the imaging algorithm of nononcologic patients referred for bone scintigraphy. *J Nucl Med* 2007;48(2):319-24.
41. Even-Sapir E, Lerman H, Lievshitz G, Khafif A, Fliss DM, Schwartz A, et al. Lymphoscintigraphy for sentinel node mapping using a hybrid SPECT/CT system. *J Nucl Med* 2003;44(9):1413-20.
42. Lerman H, Metser U, Lievshitz G, Sperber F, Shneebaum S, Even-Sapir E. Lymphoscintigraphic sentinel node identification in patients with breast cancer: the role of SPECT-CT. *Eur J Nucl Med Mol Imaging* 2006;33(3):329-337.
43. Hasegawa BH, Wong KH, Iwata K, Barber WC, Hwang AB, Sakdinawat AE, et al. Dual-modality imaging of cancer with SPECT/CT. *Technol Cancer Res Treat* 2002;1(6):449-458.
44. Keidar Z, Israel O, Krausz Y. SPECT/CT in tumor imaging: technical aspects and clinical applications. *Semin Nucl Med* 2003;33(3):205-218.
45. Das IJ, Cheng C-W, Fein DA, Fowble B. Patterns of dose variability in radiation prescription of breast cancer. *Radiother Oncol* 1997;44:83-89.
46. Lomax AJ, Cella L, Weber D, Kurtz JM, Miralbell R. Potential role of intensity-modulated photons and protons in the treatment of the breast and regional nodes. *Int J Radiat Oncol Biol Phys* 2003;55(3):785-792.
47. Johansson J, Isacson U, Lindman H, Montelius A, Glimelius B. Node-positive left-sided breast cancer patients after breast-conserving surgery: potential outcomes of radiotherapy modalities and techniques. *Radiother Oncol* 2002;65(2):89-98.
48. Fogliata A, Bolsi A, Cozzi L. Critical appraisal of treatment techniques based on conventional photon beams, intensity modulated photon beams and proton beams for therapy of intact breast. *Radiother Oncol* 2002;62(2):137-145.
49. Cheville AL, Das IJ, Srinivas S, Schuerman J, Velders L, Solin L, et al. Novel SPECT/CT based lymph node imaging technique in patients with breast cancer: Implications for preventing arm lymphedema following radiation therapy. *Eur J Nucl Med Mol Imaging* 2007;(submitted).
50. Stanton AW, Svensson WE, Mellor RH, Peters AM, Levick JR, Mortimer PS. Differences in lymph drainage between swollen and non-swollen regions in arms with breast-cancer-related lymphoedema. *Clin Sci (Lond)* 2001;101(2):131-140.
51. Yeung HW, Cody IH, Turlakow A, Riedel ER, Fey J, Gonen M, et al. Lymphoscintigraphy and sentinel node localization in breast cancer patients: a comparison between 1-day and 2-day protocols. *J Nucl Med* 2001;42(3):420-423.
52. Casley-Smith JR, Boris M, Weindorf S, Lasinski B. Treatment for lymphedema of the arm--the Casley-Smith method: a noninvasive method produces continued reduction. *Cancer* 1998;83(12 Suppl American):2843-2860.
53. Punglia RS, Harris JR. Integrating surgery and radiotherapy to reduce toxicity while maintaining local control for breast cancer: a fine balance. *Ann Surg Oncol* 2002;9(6):526-528.
54. Meeks SL, Buatti JM, Bova FJ, Friedman WA, Mendenhall WM, Zlotecki RA. Potential clinical efficacy of intensity-modulated conformal therapy. *Int J Radiat Oncol Biol Phys* 1998;40(2):483-495.
55. Early Breast Cancer Trialists' Collaborative Group. Favourable and unfavourable effects on long-term survival of radiotherapy for early breast cancer: an overview of the randomised trials. *Early Breast Cancer Trialists' Collaborative Group. Lancet* 2000;355(9217):1757-1770.
56. Purushotham AD, Upponi S, Klevesath MB, Bobrow L, Miller K, P. MJ, et al. Morbidity after sentinel lymph node biopsy in primary breast cancer: results from a randomized controlled trial. *J Clin Oncol* 2005;23:4312-4321.
57. Freedman GM, Anderson PR, Li J, Eisenberg DF, Hanlon AL, Wang L, et al. Intensity modulated radiation therapy (IMRT) decreases acute skin toxicity for women receiving radiation for breast cancer. *Am J Clin Oncol* 2006;29(1):66-70.