

AWARD NUMBER: W81XWH-05-1-0570

TITLE: Integration of Diagnostic and Interventional MRI for the Study of Persistent Prostate Cancer After External Beam Radiotherapy

PRINCIPAL INVESTIGATOR: Cynthia Ménard, M.D.

CONTRACTING ORGANIZATION: University Health Network
Toronto, Canada, M5G 1Z5

REPORT DATE: October 2008

TYPE OF REPORT: Annual

PREPARED FOR: U.S. Army Medical Research and Materiel Command
Fort Detrick, Maryland 21702-5012

DISTRIBUTION STATEMENT: Approved for Public Release;
Distribution Unlimited

The views, opinions and/or findings contained in this report are those of the author(s) and should not be construed as an official Department of the Army position, policy or decision unless so designated by other documentation.

REPORT DOCUMENTATION PAGEForm Approved
OMB No. 0704-0188

Public reporting burden for this collection of information is estimated to average 1 hour per response, including the time for reviewing instructions, searching existing data sources, gathering and maintaining the data needed, and completing and reviewing this collection of information. Send comments regarding this burden estimate or any other aspect of this collection of information, including suggestions for reducing this burden to Department of Defense, Washington Headquarters Services, Directorate for Information Operations and Reports (0704-0188), 1215 Jefferson Davis Highway, Suite 1204, Arlington, VA 22202-4302. Respondents should be aware that notwithstanding any other provision of law, no person shall be subject to any penalty for failing to comply with a collection of information if it does not display a currently valid OMB control number. **PLEASE DO NOT RETURN YOUR FORM TO THE ABOVE ADDRESS.**

1. REPORT DATE 1 October 2008		2. REPORT TYPE Annual		3. DATES COVERED 15 Sep 2007 – 14 Sep 2008	
4. TITLE AND SUBTITLE Integration of Diagnostic and Interventional MRI for the Study of Persistent Prostate Cancer After External Beam Radiotherapy				5a. CONTRACT NUMBER	
				5b. GRANT NUMBER W81XWH-05-1-0570	
				5c. PROGRAM ELEMENT NUMBER	
6. AUTHOR(S) Cynthia Ménard, M.D. E-Mail: cynthia.menard@rmp.uhn.on.ca				5d. PROJECT NUMBER	
				5e. TASK NUMBER	
				5f. WORK UNIT NUMBER	
7. PERFORMING ORGANIZATION NAME(S) AND ADDRESS(ES) University Health Network Toronto, Canada, M4G 1Z5				8. PERFORMING ORGANIZATION REPORT NUMBER	
9. SPONSORING / MONITORING AGENCY NAME(S) AND ADDRESS(ES) U.S. Army Medical Research and Materiel Command Fort Detrick, Maryland 21702-5012				10. SPONSOR/MONITOR'S ACRONYM(S)	
				11. SPONSOR/MONITOR'S REPORT NUMBER(S)	
12. DISTRIBUTION / AVAILABILITY STATEMENT Approved for Public Release; Distribution Unlimited					
13. SUPPLEMENTARY NOTES					
14. ABSTRACT This study involves the technical development and clinical testing of a novel technique for magnetic resonance imaging (MRI) guided prostate biopsy in a 1.5T horizontal bore scanner using a dedicated interventional table. We primarily hypothesize that the integration of diagnostic and interventional MRI enables needle biopsy targeting to foci of tumor recurrence after radiotherapy, and will enable a determination of the diagnostic accuracy of MRI in mapping sub-sites of tumor recurrence after radiotherapy. From September 2007 to September 2008, accrual to stages 1 and 2 of the trial was completed. One patient was also accrued to stage 3 of the trial. Here we report tasks 1e and 2a of Aims1 and 2. Clinical needle targeting accuracy has been maintained at 2mm, and motion improved. A method for 3D mapping of tumor using FEM analysis has been developed and reported here.					
15. SUBJECT TERMS prostate cancer, magnetic resonance imaging, image-guidance					
16. SECURITY CLASSIFICATION OF:			17. LIMITATION OF ABSTRACT UU	18. NUMBER OF PAGES 9	19a. NAME OF RESPONSIBLE PERSON USAMRMC
a. REPORT U	b. ABSTRACT U	c. THIS PAGE U			19b. TELEPHONE NUMBER (include area code)

Table of Contents

Introduction.....	4
Body.....	4-8
Key Research Accomplishments.....	8
Reportable Outcomes.....	8
Conclusions.....	8
References.....	8

INTRODUCTION:

This study involves the technical development and clinical testing of a novel technique for magnetic resonance imaging (MRI) guided prostate biopsy in a 1.5T horizontal bore scanner using a dedicated interventional table. We primarily hypothesize that the integration of diagnostic and interventional MRI enables needle biopsy targeting to foci of tumor recurrence after radiotherapy, and will enable a determination of the diagnostic accuracy of MRI in mapping sub-sites of tumor recurrence after radiotherapy.

This study will enroll up to 50 patients with suspicion of locally recurrent prostate cancer after external beam radiotherapy in a pilot, three-stage trial design. The first stage will include technical development and optimization of the imaging technique. The second stage will include technical development of optimization of the biopsy technique, followed by a clinical evaluation stage. This preliminary data will be critical for the judicious conduct of a subsequent phase I-II trial.

BODY:

USAMRCMC approval for the conduct of this study was obtained on October 13 2006, therefore the statement of work was been delayed by one year for regulatory approval. The first year report, submitted November 2007, reported Year 1 of the Statement of work, Specifically Tasks 1a-1d. Here, we report on Aims 1 and 2 from Year 2 of the Statement of work, specifically tasks 1e and 2a. The remaining tasks (2b, 2c, 3a, 3b) will be reported in the Year 3 annual report.

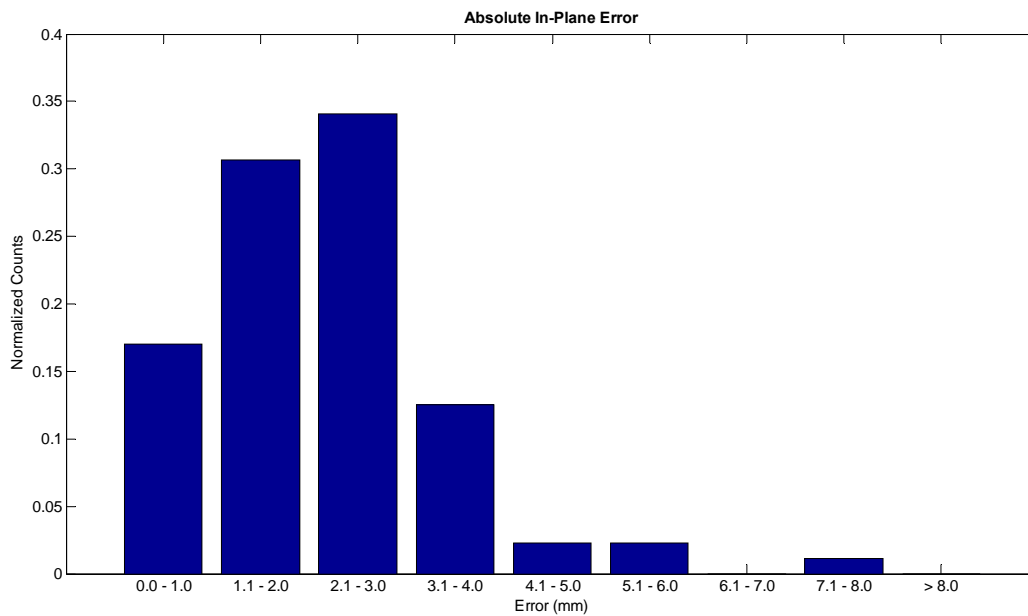
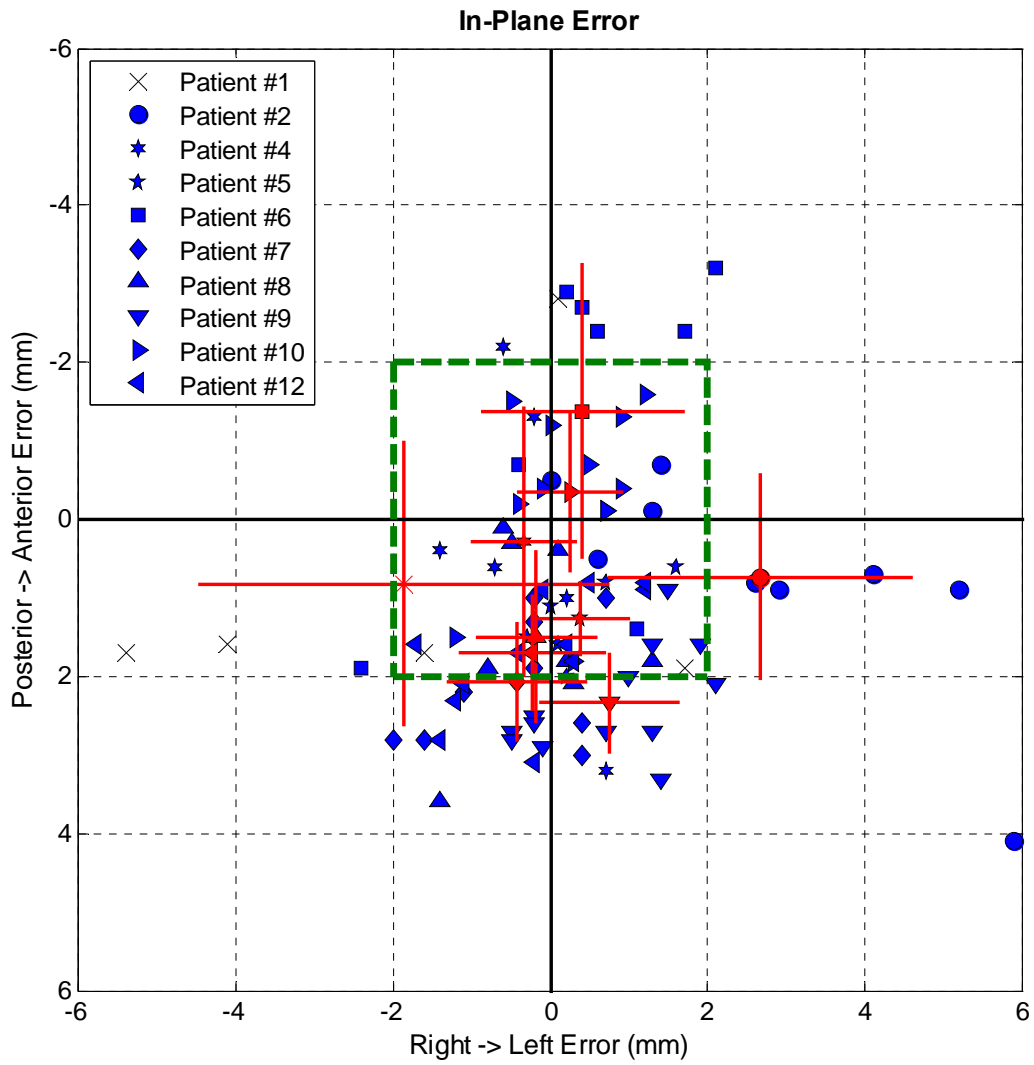
Aim 1: To test the hypothesis that stereotactic MRI-guided prostate needle biopsies can be performed with improved anatomic targeting accuracy and tolerability when patients are positioned supine in a conventional MR scanner. To test this hypothesis we plan:

Task 1e. To test the geometric and anatomic needle targeting accuracy of the supine trans-perineal system in patients with suspected local persistence of prostate cancer after external beam radiotherapy.

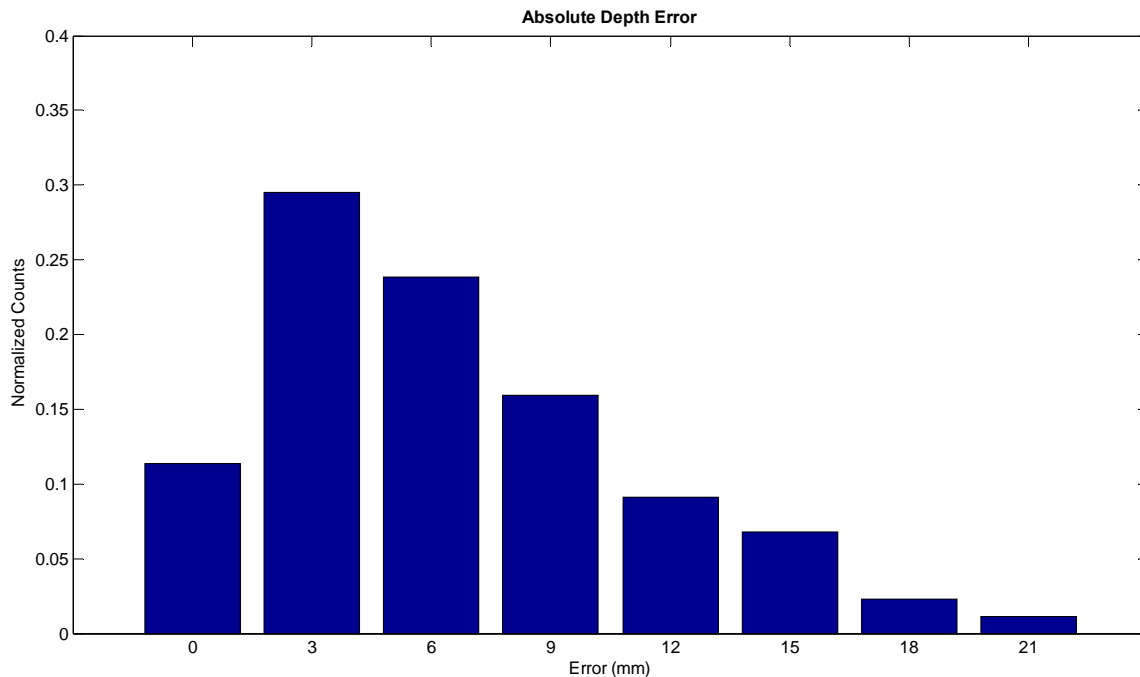
The location of the needle tip void on biopsy needle verification images will be compared to the projected needle tip location to measure the clinical geometric needle targeting accuracy of the system. The prostate gland will be contoured on diagnostic T2-weighted images and biopsy verification images. Biopsy verification images will be deformably registered to diagnostic T2 images using FEM analysis. The differences between the desired and achieved anatomical biopsy target points will be computed to derive measures of anatomical targeting inaccuracy stemming from tissue deformation during needle insertion and/or organ motion.

Deliverable: Demonstration that a mean geometric targeting accuracy of 2mm is clinically maintained with the supine approach. Determination of the mean anatomic targeting error introduced by needle deformation of the prostate gland and/or organ motion.

Progress to date: Needle targeting data has been collected from 10 biopsy patients. The in-plane device targeting accuracy was calculated by finding the distance between the actual needle and the intended target location in MRI coordinates. The actual needle location was recorded as the center of the signal void in the needle verification images. The mean in-plane coordinate needle-targeting error for 10 patients analyzed to date was 2.2 mm with standard deviation 1.2 mm.



The needle depth error was measured as the number of 3 mm slices between the actual needle tip and the depth calculated by the needle targeting software, Aegis. This method of assessing depth error is to some extent not ideal because of the slice thickness but the depth error is not as crucial as the in-plane error since the length of the biopsy core (1.5 cm) is nearly 10 times the diameter of the biopsy core. Also, the markings on the needle are at 1 cm intervals which ultimately limits the accuracy of needle insertion depth. The clinical needle insertion depth error produces a negative value to indicate the needle was shallow, or not deep enough, and a positive value to indicate the needle was too deep. The mean absolute depth error was 6.5 mm with standard deviation 4.7 mm.



A system for MRI-guided needle navigation in prostate cancer targeting has been developed and shows promise in early clinical evaluations of technical performance. The mean absolute in-plane error was 2.2 mm and the mean absolute depth error was 6.5 mm. Prospective problems and issues with the system hardware and registration methodology were detected and corrective measures were taken to improve technical performance. However, motion of the patient and system hardware remains as a contributing factor toward MRI coordinate needle targeting error. The combination of accurate registration and management of patient motion are expected to enhance the technical performance of this approach. Ongoing developments include testing of several new arrangements of fiducial registration markers, automated registration schemes, and an imaging method to capture and adapt to motion of the prostate prior to needle insertion. The testing of new fiducial registration schemes will be discussed in the following chapter. Analysis of the needle navigation system revealed that the magnitude of the depth error was of particular concern as well as the potential posterior bias in the in-plane needle to MRI coordinate targeting error. Another issue is the consistency and time required for manual registration. These issues will be addressed by the alternative registration schemes. Although device targeting accuracy is a fundamental measure of the navigation system performance, the importance of 3D imaging to document the actual location of the needle in reference to prostatic anatomic boundaries cannot be overstated.

Some patients possessed previously implanted gold fiducial markers in the prostate. The motion of these fiducial markers was measured in a similar manner as the hardware motion, by comparing the position of the implanted gold fiducial marker in the original diagnostic image set with the position in each needle verification image. This produced a 3D vector. The results are summarized in **Error! Reference source not found.** Patient #2 had the largest mean motion. Patient #4 had the largest difference between maximum and minimum motion values.

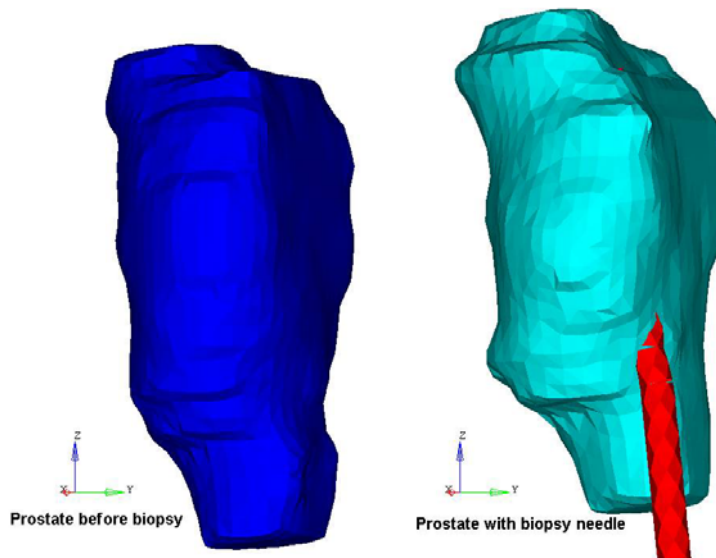
Patient	Mean Motion (mm)			Maximum / Minimum Motion (mm)		
	Left - Right	Posterior - Anterior	Superior - Inferior	Left - Right	Posterior - Anterior	Superior - Inferior
#2	-1.8	4.4	13.5	-0.7 / -2.8	4.7 / 4.0	16.0 / 12.9
#4	-0.8	-0.1	1.9	0.6 / -1.5	0.2 / -0.7	3.2 / 0.1
#5	0.1	-0.2	-0.1	0.7 / -0.7	-0.1 / -0.3	0.0 / -0.1
#6	-0.1	-0.8	-0.1	0.3 / -0.8	-0.3 / -1.0	0.0 / -0.1
#7	0.7	-0.4	0.4	1.1 / 0.0	-0.3 / -0.7	0.4 / 0.3

Aim 2: To test the hypothesis that stereotactic MRI-guided needle biopsies will enable the spatial delineation of local prostate cancer persistence after radiotherapy. For this purpose, we plan:

Task 2a. To create 3D maps of malignant biopsy sites in reference to MRI prostate anatomy. The prostate gland will be contoured on diagnostic T2-weighted and biopsy verification images, along with the biopsy core location on the latter. Biopsy images will be registered to diagnostic T2 images using FEM, whereby individual organ deformation can be accurately modeled by deforming the surface of the organ. In this case, the prostate gland contours on the T2-weighted images and biopsy verification images will be converted into finite element meshes, which comprise the entire volume of the structure. The material models will be optimized to provide the most accurate solution of the prostate deformation. Malignant and benign biopsy sites will then be outlined in reference to prostatic anatomical boundaries.

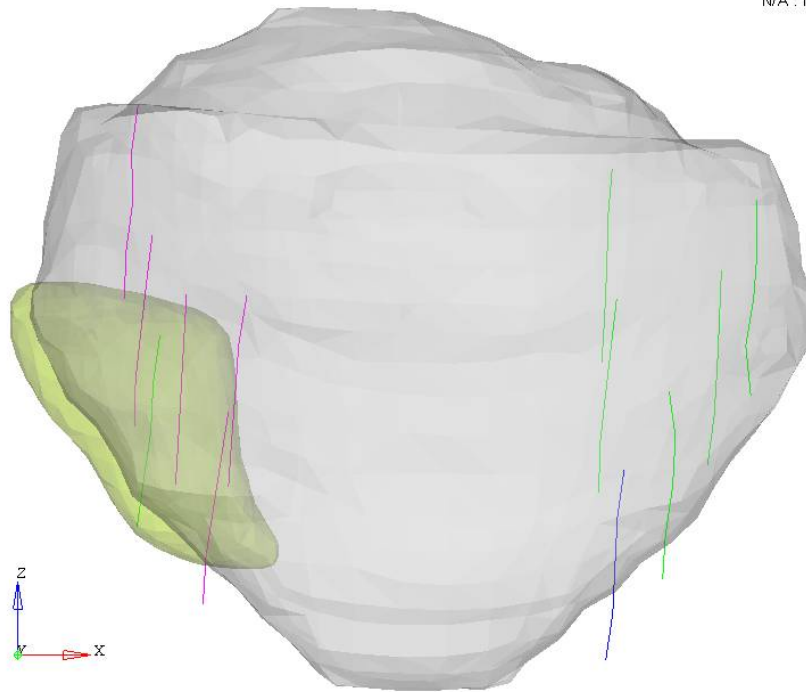
Deliverable: 3D tumor maps projected onto T2-weighted anatomical MR images.

Progress to date: A methodology for FEM-based deformable registration and 3D tumor mapping has been developed. FEM analysis confirms suspected deformation of the prostate gland, as demonstrated in this case example:

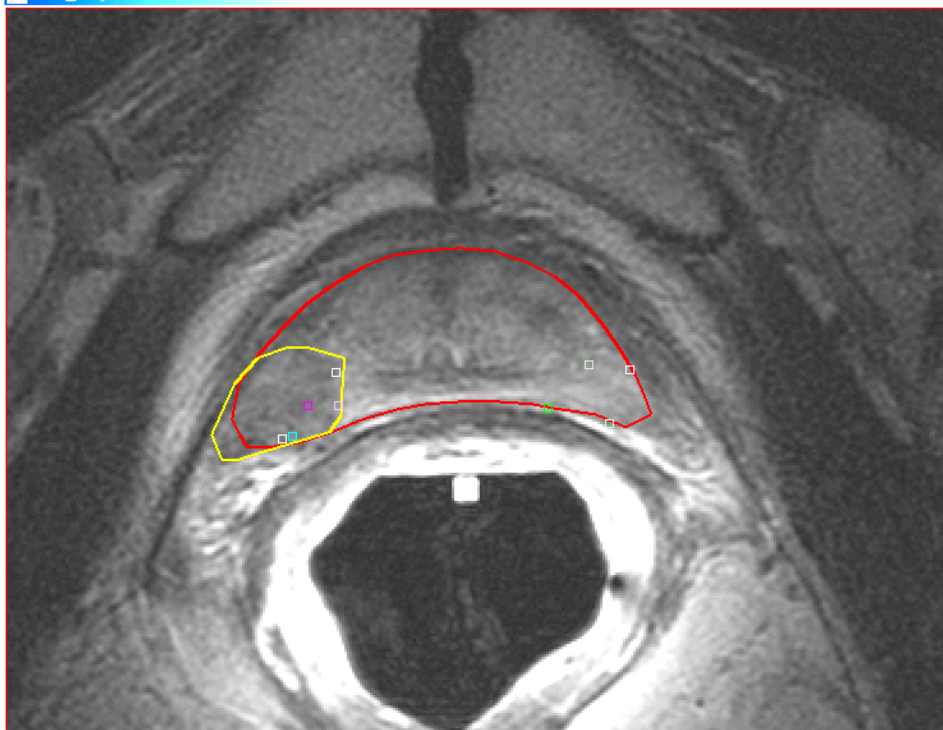


Using FEM techniques, the location of benign and malignant biopsy cores can be mapped on T2 FSE contours as depicted below, as an AP projection of the prostate volume and biopsy core locations. Malignant cores are depicted in pick, and benign cores are depicted in green. Non-diagnostic core are depicted in blue. The yellow volume corresponds to the suspicious region identified on MRI for tumor burden, and is later modified to account for malignant core tracks.

G:\JennyStuff\NeedleWork\PatientsData\RR\test.h3d
Result : N/A
N/A : Model Step
N/A



Final results are projected onto T2 FSE images of the prostate gland.



KEY RESEARCH ACCOMPLISHMENTS:

- Demonstrated clinical needle targeting accuracy of the system
- Methodology developed and achieved for 3D tumor mapping onto MRI
- Ongoing accrual to stage 3 of the trial

REPORTABLE OUTCOMES: Clinical outcomes reporting will ensure after accrual and analysis is complete for the entire cohort of patients.

CONCLUSION: The statement of work has been delayed by one year for regulatory approval, and work to date has met projected deliverables for years 1 and 2.

REFERENCES:

1. Bootsma, G.J., Krieger, A., Iordachita, I.I., Piron, C., Richmond, J., Sela, G., Filletti, M., Rocca, C., Kirilova, A., Brock, K., Jaffray, D.A., Haider, M.A., Ménard, C. A System for Prostate Interventional in a 1.5T MRI Scanner in the Supine Position. *Proc. Intl. Soc. Mag. Reson. Med.* 15 (2007), p.483.
2. Ménard, C., Bootsma, G., Piron, C., Sela, G., Richmond, J., Gallop, D., Filletti, M., Rocca, C., Kirilova, A., Iordachita, I., Krieger, A., Jaffray, D., Haider, M. A Supine System for Needle-Based Prostate Interventions in a Cylindrical MRI Scanner. *Radiother Oncol* 2007 84(2):S4
3. Suljendic D., Lee J., Chopra S., Kirilova A., Publicover, J., Abed J., Haider M., Krieger, A., Fichtinger G., Brock K., Ménard C. MRI Guided Needle Navigation in Prostate Cancer Targeting. *Focal Therapy and Imaging in Prostate and Kidney Cancer.* Amsterdam, Netherlands. June 2009