

AD \_\_\_\_\_

Award Number: W81XWH-07-1-0016

TITLE: Q ] | [ ç^âÁ@!æ^ çÄ^\* ä ^} •Á |Á/!æç ^} of -Á] •É/æ { æÄ& |æÁQ-^&ç } •

PRINCIPAL INVESTIGATOR: T æ@||^Ôæ^\* æ

CONTRACTING ORGANIZATION: University of U\|æQ { æP^æ@U&a } & /O^ } ç!  
U\|æQ { æÔæ ÈUSA HFFI Á

REPORT DATE: T æ ÁæFF

TYPE OF REPORT: Annual

PREPARED FOR: U.S. Army Medical Research and Materiel Command  
Fort Detrick, Maryland 21702-5012

DISTRIBUTION STATEMENT: Approved for public release; distribution unlimited

The views, opinions and/or findings contained in this report are those of the author(s) and should not be construed as an official Department of the Army position, policy or decision unless so designated by other documentation.

# REPORT DOCUMENTATION PAGE

*Form Approved*  
OMB No. 0704-0188

Public reporting burden for this collection of information is estimated to average 1 hour per response, including the time for reviewing instructions, searching existing data sources, gathering and maintaining the data needed, and completing and reviewing this collection of information. Send comments regarding this burden estimate or any other aspect of this collection of information, including suggestions for reducing this burden to Department of Defense, Washington Headquarters Services, Directorate for Information Operations and Reports (0704-0188), 1215 Jefferson Davis Highway, Suite 1204, Arlington, VA 22202-4302. Respondents should be aware that notwithstanding any other provision of law, no person shall be subject to any penalty for failing to comply with a collection of information if it does not display a currently valid OMB control number. **PLEASE DO NOT RETURN YOUR FORM TO THE ABOVE ADDRESS.**

<b>1. REPORT DATE (DD-MM-YYYY)</b> 01-05-2011			<b>2. REPORT TYPE</b> Annual		<b>3. DATES COVERED (From - To)</b> 15 APR 2010 - 14 APR 2011	
<b>4. TITLE AND SUBTITLE</b>  Improved Therapeutic Regimens for Treatment of Post-Traumatic Ocular Infections					<b>5a. CONTRACT NUMBER</b>	
					<b>5b. GRANT NUMBER</b> W81XWH-07-1-0280	
					<b>5c. PROGRAM ELEMENT NUMBER</b>	
<b>6. AUTHOR(S)</b>  Michelle Callegan  E-Mail: michelle-callegan@ouhsc.edu					<b>5d. PROJECT NUMBER</b>	
					<b>5e. TASK NUMBER</b>	
					<b>5f. WORK UNIT NUMBER</b>	
<b>7. PERFORMING ORGANIZATION NAME(S) AND ADDRESS(ES)</b> University of Oklahoma Health Sciences Center Oklahoma City, OK 73117					<b>8. PERFORMING ORGANIZATION REPORT NUMBER</b>	
<b>9. SPONSORING / MONITORING AGENCY NAME(S) AND ADDRESS(ES)</b> U.S. Army Medical Research and Materiel Command Fort Detrick, Maryland 21702-5012					<b>10. SPONSOR/MONITOR'S ACRONYM(S)</b>	
					<b>11. SPONSOR/MONITOR'S REPORT NUMBER(S)</b>	
<b>12. DISTRIBUTION / AVAILABILITY STATEMENT</b> Approved for Public Release; Distribution Unlimited						
<b>13. SUPPLEMENTARY NOTES</b>						
<b>14. ABSTRACT</b> Greater than 10% of battlefield injuries occur to the eyes, resulting in significant morbidity. The potential for ocular infection by trauma is high, due to the types of organisms encountered in arid environments and the delay between injury and adequate treatment. This proposal was designed to analyze the effectiveness of antibiotics, anti-inflammatory drugs, and non-conventional agents targeting bacterial and host virulence factors, with the goal of improving the outcome of infections that would otherwise result in vision loss. The 4th-year results highlight prompt and aggressive intravitreal and surgical therapy in preventing inflammation and vision loss. Delays in treatment result in vision loss, but may not result in loss of the eye, a cosmetic benefit. Analysis of additional anti-inflammatory agents with antibiotics suggests that these drugs are of little therapeutic benefit. The use of vitrectomy to clear intraocular inflammation and damaged tissue was of some benefit, but only when used in the early stages of infection. To date, early vitrectomy with antibiotics has been the only successful therapy in this model of severe endophthalmitis. We have been granted a 1-year no-cost extension to extend our studies. In the fifth year, we will complete our analysis of non-conventional therapies to identify those that may be implemented for future treatment of blinding bacterial infections of the eye.						
<b>15. SUBJECT TERMS</b> Trauma, eye, infections, therapy, antibiotics, anti-inflammatory drugs						
<b>16. SECURITY CLASSIFICATION OF:</b>				<b>17. LIMITATION OF ABSTRACT</b>	<b>18. NUMBER OF PAGES</b>	<b>19a. NAME OF RESPONSIBLE PERSON</b>
<b>a. REPORT</b>	<b>b. ABSTRACT</b>	<b>c. THIS PAGE</b>	<b>USAMRMC</b>			
U	U	U	UU	44	<b>19b. TELEPHONE NUMBER (include area code)</b>	

## Table of Contents

	<u>Page</u>
Introduction.....	4
Body.....	4
Key Research Accomplishments.....	8
Reportable Outcomes.....	8
Conclusion.....	8
References.....	8
Figures.....	10
Appendices.....	12

**Proposal PR064081 Department of Defense CDMRP  
Improved Therapeutic Regimens for Treatment of Post-Traumatic Ocular Infections  
Michelle C. Callegan, Ph.D. Principle Investigator  
University of Oklahoma Health Sciences Center, Oklahoma City OK**

**YEAR FOUR ANNUAL PROGRESS REPORT**

---

**INTRODUCTION**

Greater than 10% of the total number of battlefield injuries occurs to the eyes, resulting in significant morbidity.<sup>1</sup> The potential for ocular infection by penetrating injuries is significant, due to the nature of the organisms encountered in battlefield environments and the delay between the time of injury and adequate therapeutic intervention. This proposal was designed to analyze the effectiveness of antibiotics, anti-inflammatory drugs, and non-conventional agents that target bacterial and host virulence factors, with the goal of improving the outcome of infections that typically result in significant vision loss. The goal is to sterilize the eye, arrest inflammation, and preserve vision following post-traumatic endophthalmitis.

It should be noted that we requested and received a one-year no-cost extension in order to continue our studies on non-conventional therapeutics. No additional funds or animals were requested. This report is therefore an annual progress report, not a final project report.

**BODY OF RESEARCH**

**Statement of Work (Abbreviated).** Project tasks (experiments) included 7 experiments outlined in 2 specific aims that focused on testing conventional and non-conventional therapeutic regimens for experimental post-traumatic *B. cereus* endophthalmitis. All experiments were performed using an experimental rabbit model of *Bacillus cereus* endophthalmitis. In the model, 100 bacilli/0.1 ml are injected into the mid-vitreous of one eye, while the contralateral eye is injected with 0.1 ml PBS (surgical control) or is left undisturbed (absolute control). At designated time points during infection, treatment is administered (intravitreal drug and/or surgery, with proper controls). At designated time points, eyes are electroretinographed (measurement of retinal function) and removed after euthanasia for analysis of myeloperoxidase activity (from inflammatory cells), drug concentrations, bacterial growth, and histology. The specific experiments in the Statement of Work are: 1) analysis of the efficacy of antibiotics or antibiotic combinations against experimental *Bacillus* endophthalmitis, 2) analysis of the efficacy of antibiotics against *B. cereus* spores in the eye before and after germination, 3) analysis of the efficacy of vitrectomy in conjunction with the most effective antibiotic for treatment of *B. cereus* endophthalmitis, 4) analysis of the efficacy of an anti-inflammatory agent, prednisolone acetate, in conjunction with the most effective antibiotic for *B. cereus* endophthalmitis, 5) analysis of the efficacy of anti-TNF $\alpha$  in conjunction with the most effective antibiotic for *B. cereus* endophthalmitis, 6) analysis of the efficacy of polyclonal antibody generated against *B. cereus* toxins (anti-toxin) in conjunction with the most effective antibiotic for *B. cereus* endophthalmitis, and 7) analysis of the efficacy of polyclonal antibody generated against *B. cereus* flagella (anti-flagella) in conjunction with the most effective antibiotic for *B. cereus* endophthalmitis.

All Appendices and Figures can be found at the end of the text.

**Experiment 1: Analysis of the efficacy of antibiotics or antibiotic combinations against experimental *Bacillus* endophthalmitis.**

*Summary:* In Wiskur *et al.*<sup>2</sup>, we published that intravitreal administration of antibiotics at 2 h or 4 h postinfection successfully preserved vision following experimental *B. cereus* endophthalmitis. These studies were expanded to analyze the fate of the eye after our latest analysis point of 8 h postinfection to determine whether delayed treatment prevented loss of the eye.

*Experimental Design Summary:* Eyes were intravitreally infected with 100 CFU *B. cereus*. 0.1 mL of gatifloxacin (0.3%), vancomycin (1.0%), or a combination of both antibiotics at these concentrations was intravitreally injected at 2, 4, or 6 h

postinfection. Eyes were analyzed at 12, 24, and 36 or 48 h postinfection by bacterial quantitation, electroretinography, inflammatory cell quantitation, and histology (N $\geq$ 5 eyes per group).

*Progress To Date:* These experiments are complete and published. Please refer to Appendix 1.

*Data Not Shown:* None.

*Experiments Remaining:* None.

*Relevance:* These results reiterate that early intravitreal treatment of posterior segment bacterial infections is critical for salvaging not only vision, but also the architecture of the globe itself. In the battlefield where treatment delays are expected, intravitreal administration of antibiotics immediately following post-traumatic ocular injury may pre-empt infection and improve visual outcome.

### **Experiment 2: Analysis of the efficacy of antibiotics against *B. cereus* spores in the eye before and after germination.**

*Summary:* During post-traumatic *Bacillus* endophthalmitis, spores likely enter the eye and germinate into viable bacteria that produce toxins and incite an explosive inflammatory response that is usually refractory to treatment. Our preliminary data demonstrates that spores can remain within the eye for up to 6 h and are not cleared. We propose to analyze the efficacy of antibiotics against *B. cereus* spores in the eye before and after germination.

*Progress to Date:* Dose-response experiments show that an intravitreal injection of 100 *B. cereus* spores can be cleared, but injections of 500 or 1000 spores are not cleared, resulting in endophthalmitis (Figures 1 and 2). Eyes injected with 1000 spores result in approximately 30% overall retinal function loss and 10<sup>6</sup> viable organisms per infected eye at 24 h postinfection. These results are compared to infection initiated with 100 vegetative *B. cereus*, where eyes have 10<sup>7</sup> CFU and <20% retinal function at 12 h postinfection.<sup>2</sup> Therapeutic intervention of these infections with gatifloxacin was successful, sterilizing eyes infected with 1000 spores within 24 h postinfection and protecting these eyes from retinal function loss (Figures 3 and 4).

*Data Not Shown:* None.

*Experiments Remaining:* Because eyes do not demonstrate noticeable signs of endophthalmitis until after 24 h postinfection in untreated eyes, the original time points will be shifted. Treatment times will be extended to 9 and 12 h postinfection, with analysis time points extended to 24 and 48 h postinfection. If time allows, the efficacy of vancomycin will be tested in experiments identical to those described. These efficacy studies will include bacterial counts, retinal function analysis, histology sections, and photographs of eyes from each treatment group at all endpoints.

*Relevance:* Our results demonstrate that spores can germinate in the eye, but a threshold of ~500 spores is needed for infection. Intravitreal therapy of spore-initiated endophthalmitis can be successfully treated at 6 h postinfection, a time we reported to be too late to treat endophthalmitis initiated by vegetative *B. cereus*<sup>2</sup>. Spores injected into the rabbit eye take some time to germinate and replicate, potentially representing a window of opportunity during which intravitreal therapy could be administered following penetrating injury to pre-empt infection.

### **Experiment 3: Analysis of the efficacy of vitrectomy in conjunction with the most effective antibiotic for treatment of *B. cereus* endophthalmitis.**

*Summary:* As noted in Experiment 1, antibiotic treatment at 6 h postinfection resulted in loss of retinal function and a severe degree of inflammation, but ocular architecture remained intact. In clinical cases of this severity, vitrectomy is used to remove posterior segment debris in order to potentially salvage vision. This study analyzed the effectiveness of vitrectomy used in conjunction with antibiotics for treatment of late-stage *B. cereus* endophthalmitis.

*Experimental Design Summary:* Rabbits were injected in the mid-vitreous with 100 CFU of vegetative *B. cereus*. Vitrectomy and intravitreal administration of vancomycin (1%) was performed at 4 h, 5 h, or 6 h postinfection. Controls included intravitreal vancomycin-treatment groups and vitrectomy alone in uninfected eyes.

*Progress To Date:* These experiments are complete and published. Please refer to Appendix 2.

*Data Not Shown:* None.

*Experiments Remaining:* None.

*Relevance:* These results demonstrate that vitrectomy may be of therapeutic benefit in the treatment of *B. cereus* endophthalmitis, but only during the early stages of infection. Of future interest are the combinations of other antibiotics with vitrectomy in endophthalmitis caused by staphylococci.

**Experiment 4: Analysis of the efficacy of an anti-inflammatory agent, prednisolone acetate, in conjunction with the most effective antibiotic for *B. cereus* endophthalmitis.**

*Summary:* In Wiskur *et al.*<sup>2</sup>, we reported that intravitreal administration of dexamethasone (1.0%) with gatifloxacin (0.3%) or vancomycin (1.0%) did not limit inflammation or improve the outcome of infection compared with treatments with antibiotics alone. The present studies analyzed the effectiveness of prednisolone acetate in improving the outcome of experimental *B. cereus* endophthalmitis.

*Experimental Design Summary:* Eyes were intravitreally infected with 100 CFU *B. cereus*. 0.1 mL of vancomycin (1.0%), gatifloxacin (0.3%), or a combination of these antibiotics with prednisolone acetate (PredForte, Bausch & Lomb, 1.0%) was intravitreally injected at 2, 4, or 6 h postinfection. Eyes were analyzed at 12, 24, and 36 or 48 h postinfection by bacterial quantitation, electroretinography, inflammatory cell quantitation, and histology (N ≥ 5 eyes per group).

*Progress To Date:* These experiments are complete and published. Please refer to Appendix 1.

*Data Not Shown:* None.

*Experiments Remaining:* None.

*Relevance:* Loss of retinal function was similar in eyes treated with antibiotics with or without prednisolone. These results further suggest that the addition of corticosteroids to antibiotics is not beneficial for *B. cereus* endophthalmitis. Although gatifloxacin likely sterilizes the eye faster, vancomycin therapy resulted in less inflammation, so its use may be preferable. Of note is the intact state of globes even after 6 h antibiotic treatment, suggesting that although retinal function is lost, globe architecture was intact following this therapeutic regimen.

**Experiment 5: Analysis of the efficacy of anti-TNF $\alpha$  in conjunction with the most effective antibiotic for *B. cereus* endophthalmitis.**

*Summary:* TNF $\alpha$  is one of the pro-inflammatory cytokines synthesized in the eye during *B. cereus* endophthalmitis.<sup>10</sup> Using transgenic mice deficient in TNF $\alpha$ , we identified this cytokine as being important in recruitment of inflammatory cells into the eye during *B. cereus* endophthalmitis.<sup>11</sup> Pilot experiments in mice demonstrated that anti-TNF $\alpha$  reduced the inflammatory cell load when administered intravitreally alone at the time of infection, but the reduction was minimal. We proposed to analyze whether anti-TNF $\alpha$  combined with antibiotics effectively reduced inflammation and sterilized the eye during the early stages of *B. cereus* endophthalmitis.

*Experimental Design Summary:* Eyes were intravitreally infected with 100 CFU *B. cereus*. 0.1 mL of vancomycin (1.0%), a combination of vancomycin and anti-TNF $\alpha$  (Remicade, 0.5 ng), or anti-TNF $\alpha$  alone were intravitreally injected at 2, 4, or 6 h postinfection. Eyes were analyzed at 12 h postinfection by electroretinography and inflammatory cell quantitation (N ≥ 3 eyes per group).

*Progress To Date:* Pilot studies reported in previous progress reports indicated that the combination of anti-TNF $\alpha$  + vancomycin did not improve B-wave function loss or extent of infiltrating inflammatory cells compared to vancomycin alone. As expected, treatment with anti-TNF $\alpha$  (Remicade) alone resulted in near complete retinal function loss and significant inflammation. In the last progress report, we proposed to change reagents to anti-rabbit TNF $\alpha$ , in case species specificity was the problem. A repeat study with anti-rabbit TNF $\alpha$ /vancomycin combinations yielded similar results -- no improvement in therapeutic outcome was noted. Because of the lack of efficacy seen with anti-TNF $\alpha$  in this model, we will not pursue this line of experimentation further.

*Data Not Shown:* Pilot studies (reported in previous progress reports).

*Experiments Remaining:* None.

*Relevance:* To date, no studies have analyzed the value of cytokine blockade in the treatment of endophthalmitis, but studies do describe the use of anti-TNF $\alpha$  drugs in treating intraocular inflammation during uveitis.<sup>12-14</sup> Our preliminary results demonstrate that TNF $\alpha$  blocking after infection may not improve the clinical outcome. This is not surprising considering our findings of the production of additional chemotactic cytokines in the eye during experimental endophthalmitis in the mouse.<sup>11</sup> Future studies may involve combination anti-cytokine intervention, but those experiments are beyond the scope of this proposal.

**Experiment 6: Analysis of the efficacy of polyclonal antibody generated against *B. cereus* toxins (anti-toxin) in conjunction with the most effective antibiotic for *B. cereus* endophthalmitis.**

*Summary:* Toxin production in the eye during *B. cereus* endophthalmitis is responsible for the majority of retinal function loss during infection.<sup>5,6</sup> Others have reported that antisera raised to another ocular pathogen, *Staphylococcus aureus*, was effective in abrogating toxic effects during experimental endophthalmitis caused by that organism.<sup>7,8</sup> We proposed a similar approach for treating *B. cereus* – combining anti-*B. cereus* toxin antisera with antibiotics during treatment at the early stages of infection when toxins are produced. The key is to kill the organism and arrest toxin activity in order to prevent toxin-induced retinal function loss.

*Progress to date:* We now have on hand neutralizing polyclonal antibody to *B. cereus* toxins. This anti-toxin antibody neutralizes hemoglobin release caused by the many cytolytic toxins synthesized by *B. cereus* (Figure 5). Preliminary *in vivo* toxicity studies demonstrate no inflammation following injection of 50  $\mu$ L neat anti-toxin into rabbit eyes. Preliminary drug combination studies with gatifloxacin showed no precipitation when each are mixed in solution at 37°C.

*Data Not Shown:* None.

*Experiments Remaining:* Experiments in the *B. cereus* endophthalmitis model involve the following groups: 1) anti-toxin + gatifloxacin at 4 h postinfection, 2) anti-toxin alone at 4 h postinfection, 3) gatifloxacin alone at 4 h postinfection, 4) pre-immune serum + gatifloxacin at 4 h postinfection, 5) pre-immune serum alone at 4 h postinfection. These experiments will determine whether anti-toxin and antibiotics are more beneficial than antibiotics alone against *B. cereus* endophthalmitis. If these experiments should be successful, we will test the same groups at 6 h postinfection, a time when antibiotics alone are therapeutically ineffective.

*Relevance:* Antibiotic and anti-inflammatory drugs may abrogate the effects of endophthalmitis when administered early, but these drugs do not affect the toxin activity that has been shown to negatively affect retinal function during intraocular infection.

**Experiment 7: Analysis of the efficacy of polyclonal antibody generated against *B. cereus* flagella (anti-flagella) in conjunction with the most effective antibiotic for *B. cereus* endophthalmitis.**

*Summary:* We reported that *B. cereus* migration throughout the eye was important to the virulence of the organism.<sup>6,9</sup> In an approach similar to that in Experiment 6, we proposed to combine anti-*B. cereus* flagella antisera with antibiotics

during treatment at the early stages of infection when bacteria are moving within the posterior segment of the eye. The key is to prevent migration of the organism into niches where they may circumvent antibiotic action, while also killing the organisms.

*Progress To Date:* We have purified *B. cereus* flagella and have sent our preparations to Rockland Inc. for generation of anti-flagellar polyclonal antibody. This antibody will be administered with antibiotics during experimental *B. cereus* endophthalmitis following the same therapeutic strategy as in Experiment 6. *In vivo* testing has not yet begun.

### KEY RESEARCH ACCOMPLISHMENTS

- Early and aggressive (i.e. intravitreal) antibiotic treatment of intraocular infection is critical in salvaging vision.
- Delayed treatment (i.e. at 6 h postinfection) does not prevent significant vision loss but does arrest deterioration of the globe itself.
- Addition of prednisolone acetate to vancomycin or gatifloxacin in the treatment of *B. cereus* endophthalmitis does not offer a therapeutic benefit over that of antibiotics used alone.
- Vitrectomy offers a therapeutic benefit, but only during the early stages of infection. Vitrectomy may also offer a cosmetic, but not therapeutic benefit when employed during the later stages of *B. cereus* endophthalmitis.
- Adjunct use of anti-TNF $\alpha$  does not alter the outcome of infection, likely due to other important proinflammatory cytokine activity in the absence of TNF $\alpha$ .
- Neutralizing antibody to *B. cereus* toxins has been generated and will be tested in the experimental endophthalmitis model.

### REPORTABLE OUTCOMES

Experiments 1 and 4 were presented in part at the Military Health Research Forum (September 2009). Experiment 3 was completed and presented (along with some of the data from Experiments 1 and 4) at the International Society for Ocular Pharmacology and Therapeutics meeting (ISOPT December 2009). Experiment 1 and 4 data were published in the Proceedings for ISOPT 2009 (Appendix 1). Portions of these studies were also included in a review published in *Expert Opinions in Ophthalmology* (2010, Appendix 3). Experiment 3 data is in press in the journal *Retina* (2011, Appendix 2). Experiment 2 was presented during an invited presentation at the American Society for Ophthalmology and Therapeutics (February 2011, Fort Worth TX).

### CONCLUSIONS

Early intravitreal administration of antibiotics is key to preventing significant vision loss and loss of the eye itself following penetrating injury and potential intraocular infection. The importance of these studies lies in identifying the timing in which an eye can be salvaged, even though sight may be lost. On the battlefield, as well as during accidental trauma off the battlefield, the timing from injury to treatment is critical, as is the type of treatment administered. Numerous studies have demonstrated that for posterior segment infections, systemic and/or topical antibiotic treatment is relatively useless (reviewed in reference 15). Intravitreal administration of antibiotics (with or without anti-inflammatory drugs) salvages vision if given early and can rescue the globe if treatment is delayed. Although our work analyzes treatment of *B. cereus* endophthalmitis – the most devastating form of bacterial endophthalmitis – the results of these studies can be extrapolated toward treatment of infections with other vicious pathogens such as *Staphylococcus aureus* or *Streptococcus pneumoniae*, where courses of infection are slower but infection outcomes are just as devastating. The use of anti-inflammatory agents to alter inflammation remains controversial, and our results of prednisolone acetate/vancomycin or anti-TNF $\alpha$ /vancomycin administration do not help to clarify the issue. Future work targeted at virulence factor inhibition may aid in alleviating the issue of early retinal function loss despite antibiotic treatment.

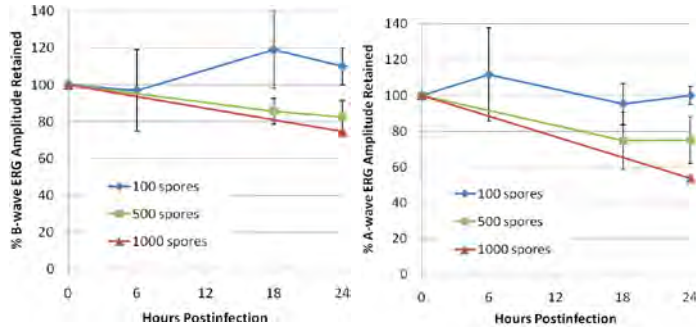
### REFERENCES

1. Heier JS, Enzenauer RW, Wintermeyer SF, Delaney M, LaPiana FP. Ocular injuries and diseases at a combat support hospital in support of Operations Desert Shield and Desert Storm. *Arch Ophthalmol*. 1993 Jun;111(6):795-8.

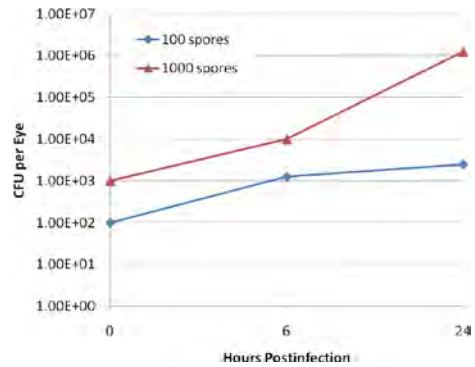
2. Wiskur BJ, Robinson ML, Farrand AJ, Novosad BD, Callegan MC. Toward improving therapeutic regimens for *Bacillus endophthalmitis*. *Invest Ophthalmol Vis Sci*. 2008 Apr;49(4):1480-7.
3. Das T, Choudhury K, Sharma S, Jalali S, Nuthethi R. Clinical profile and outcome in *Bacillus endophthalmitis*. *Ophthalmology* 2001;108:1819-1825.
4. David DB, Kirkby GR, Noble BA. *Bacillus cereus* endophthalmitis. *Br J Ophthalmol* 1994;78:577-580.
5. Callegan MC, Kane ST, Cochran DC, Gilmore MS, Gominet M, Lereclus D. Relationship of plcR-regulated factors to *Bacillus endophthalmitis* virulence. *Infect Immun*. 2003 Jun;71(6):3116-24.
6. Callegan MC, Kane ST, Cochran DC, Novosad B, Gilmore MS, Gominet M, Lereclus D. *Bacillus endophthalmitis*: roles of bacterial toxins and motility during infection. *Invest Ophthalmol Vis Sci*. 2005 Sep;46(9):3233-8.
7. Han DP. Intravitreal human immune globulin in a rabbit model of *Staphylococcus aureus* toxin-mediated endophthalmitis: a potential adjunct in the treatment of endophthalmitis. *Trans Am Ophthalmol Soc*. 2004;102:305-20.
8. Perkins SL, Han DP, Burke JM, Schlievert PM, Wirostko WJ, Tarasewicz DG, Skumatz CM. Intravitreally injected human immunoglobulin attenuates the effects of *Staphylococcus aureus* culture supernatant in a rabbit model of toxin-mediated endophthalmitis. *Arch Ophthalmol*. 2004 Oct;122(10):1499-506.
9. Callegan MC, Kane ST, Cochran DC, Gilmore MS. Molecular mechanisms of *Bacillus endophthalmitis* pathogenesis. *DNA Cell Biol* 2002 May-Jun;21(5-6):367-73
10. Ramadan RT, Ramirez R, Novosad BD, Callegan MC. Acute inflammation and loss of retinal architecture and function during experimental *Bacillus endophthalmitis*. *Curr Eye Res*. 2006 Nov;31(11):955-65.
11. Ramadan RT, Moyer AL, Callegan MC. A role for tumor necrosis factor-alpha in experimental *Bacillus cereus* endophthalmitis pathogenesis. *Invest Ophthalmol Vis Sci*. 2008 Oct;49(10):4482-9.
12. Ardoin SP, Kredich D, Rabinovich E, Schanberg LE, Jaffe GJ. Infliximab to treat chronic noninfectious uveitis in children: retrospective case series with long-term follow-up. *Am J Ophthalmol*. 2007 Dec;144(6):844-849. Epub 2007 Oct 22.
13. Diaz-Llopis M, García-Delpech S, Salom D, Udaondo P, Bosch-Morell F, Quijada A, Romero FJ, Amselem L. High-dose infliximab prophylaxis in endotoxin-induced uveitis. *J Ocul Pharmacol Ther*. 2007 Aug;23(4):343-50.
14. Gallagher M, Quinones K, Cervantes-Castañeda RA, Yilmaz T, Foster CS. Biological response modifier therapy for refractory childhood uveitis. *Br J Ophthalmol*. 2007 Oct;91(10):1341-4. Epub 2007 Jun 7.
15. Callegan MC, Gilmore MS, Gregory M, Ramadan RT, Wiskur BJ, Moyer AL, Hunt JJ, Novosad BD. Bacterial endophthalmitis: therapeutic challenges and host-pathogen interactions. *Prog Retin Eye Res*. 2007 Mar;26(2):189-203.

**FIGURES (UNPUBLISHED DATA)**

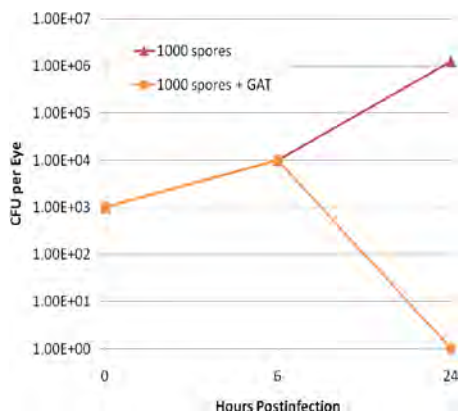
**Figure 1.** Retinal function analysis following injection of *B. cereus* spores into rabbit eyes. Following injection of 100, 500, or 1000 *B. cereus* spores, eyes were analyzed by electroretinography at 6, 12, and 24 h postinfection. Values represent the mean  $\pm$  SEM of  $N \geq 3$  eyes per group.



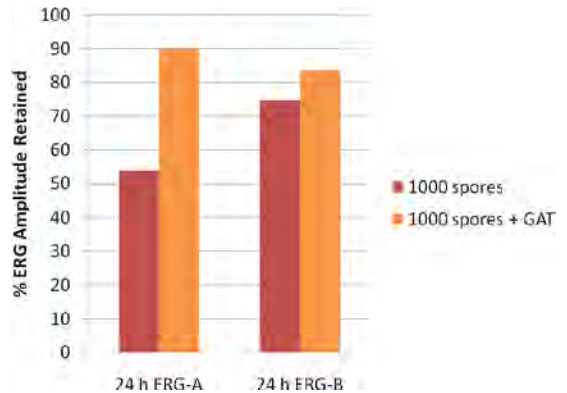
**Figure 2.** Germination of *B. cereus* spores in rabbit eyes. Following intravitreal injection with 100 or 1000 *B. cereus* spores, eyes were removed and vitreous was harvested for bacterial counts. Increasing numbers indicated germination of spores in the eye. Values represent the mean  $\pm$  SEM of  $N \geq 3$  eyes per group.



**Figure 3.** Sterilization of eyes infected with *B. cereus* spores. Eyes were injected with 1000 spores of *B. cereus*. One group was treated with intravitreal gatifloxacin (100  $\mu$ L of 0.3% ophthalmic solution) while the other group was left untreated. Eyes treated with gatifloxacin were sterile by 24 h postinfection. Values represent the mean  $\pm$  SEM of  $N \geq 3$  eyes per group.



**Figure 4.** Retinal function of eyes infected with *B. cereus* spores treated with gatifloxacin. Eyes were injected with 1000 spores of *B. cereus*. One group was treated with intravitreal gatifloxacin (100  $\mu$ L of 0.3% ophthalmic solution) while the other group was left untreated. The retinal function in gatifloxacin-treated eyes was significantly greater than that of untreated eyes at 24 h postinfection. Values represent the mean  $\pm$  SEM of  $N \geq 3$  eyes per group.





## APPENDICES

**Appendix 1.** Wiskur BD, Woods DC, Wheatley NR, **Callegan MC**. Update on Improvements for Therapy of Severe Bacterial Endophthalmitis. Proc 8th Intl Soc Ocul Pharmacol Ther 2010, 25-38.

**Appendix 2. Callegan MC**, Woods D, Guess S, Wheatley N, Leonard R. Efficacy of Vitrectomy and Intravitreal Vancomycin for the Treatment of Bacillus cereus Endophthalmitis. Retina. In press.

**Appendix 3.** Novosad B, **Callegan MC**. Severe Bacterial Endophthalmitis: Towards Improving Clinical Outcomes. Exp Rev Ophthalmol 5(5):689-698, 2010.

# Update on Improvements for Therapy of Severe Bacterial Endophthalmitis

Wiskur B. J., Ph.D.<sup>1A</sup>, Woods D. C., B.S.<sup>1B</sup>, Wheatley N. R.<sup>2</sup>,  
Callegan M. C., Ph.D.<sup>1C,2</sup>

Oklahoma Center for Neuroscience<sup>A</sup>, College of Medicine<sup>B</sup>, Department of Microbiology and Immunology<sup>C</sup>, University of Oklahoma Health Sciences Center, Oklahoma City, OK<sup>1</sup>; Ophthalmology, Dean A. McGee Eye Institute, Oklahoma City, OK<sup>2</sup>.

**Funding Disclosure:** This study was funded entirely by the Department of Defense Congressionally Directed Medical Research Program (W81XWH-07-1-0280 to MCC). Our research is also supported in part by NIH Grants P30EY12191 (NIH CORE grant to Robert E. Anderson, OUHSC), Research Resources Grant P20RR17703 (NCRR COBRE grant to Robert E. Anderson, OUHSC), and an unrestricted grant to the Dean A. McGee Eye Institute from Research to Prevent Blindness.

## Summary

*Bacillus cereus* causes severe endophthalmitis resulting in significant vision loss despite prompt and aggressive treatment. We analyzed the efficacy of combinations of prednisolone, vancomycin, and gatifloxacin in the treatment of experimental *B. cereus* endophthalmitis. Rabbit eyes were intravitreally injected with 100 CFU *B. cereus*, then intravitreally injected at 2, 4, or 6 h with combinations of prednisolone, vancomycin, and gatifloxacin, with proper controls. Retinal function, bacterial growth, inflammation, and antibiotic penetration were measured. All antibiotic treatments sterilized infected eyes within 12 h. Infection severities after prednisolone/antibiotic treatment were similar to that of antibiotics alone. Eyes treated at 2 h with antibiotics maintained greater retinal function than eyes treated at 4 or 6 h. The addition of prednisolone to antibiotics did not offer a clear therapeutic benefit, and vancomycin-treated eyes fared better clinically than those treated with gatifloxacin. Further testing is needed to identify therapies that rapidly sterilize, abrogate inflammation, neutralize toxic effects, and prevent blindness during *B. cereus* endophthalmitis.

## Introduction

Bacterial endophthalmitis can occur following surgery, a penetrating injury, or

from metastatic spread of infection into the eye from the bloodstream.<sup>1,2</sup> Secondary infections following penetrating eye injuries range from 3-17%.<sup>3,4</sup> *Bacillus cereus* causes the most virulent form of post-traumatic bacterial endophthalmitis, with rapid vision loss within 1- 2 days, and often, loss of the eye itself.<sup>1</sup> Nearly half of *B. cereus* endophthalmitis patients require enucleation or evisceration, necessitating further cosmetic and prosthetic intervention.<sup>5-7</sup> Despite the susceptibility of *B. cereus* to commonly-used antibiotics<sup>8-11</sup>, this invariably poor outcome indicates that effective treatment regimens for *B. cereus* endophthalmitis have not been established.

To date, no studies have analyzed the potential anti-inflammatory efficacy of prednisolone for endophthalmitis. Prednisolone (in either the acetate or phosphate formulations) is topically and/or systemically administered as an effective anti-inflammatory drug following cataract surgery. Topical administration of prednisolone acetate has been shown to cause a decrease in inflammation during experimental bacterial keratitis<sup>12,13</sup>, but its clinical effectiveness when administered for bacterial ocular infections is less clear.<sup>12-16</sup> We hypothesized that prednisolone, by virtue of its anti-inflammatory activity, may prevent or reduce host inflammation, resulting in an improved therapeutic outcome for *B. cereus* endophthalmitis.

For experimental *B. cereus* endophthalmitis, vancomycin and gatifloxacin each sterilized infected eyes when intravitreally administered as late as 6 h postinfection.<sup>11</sup> However, significant vision was lost if either antibiotic was administered after 4 h postinfection in this model, indicating that early treatment was critical for salvaging vision. Previous studies analyzing vancomycin<sup>17,18</sup> or ciprofloxacin<sup>19,20</sup> suggested that these antibiotics can be effective against experimental *B. cereus* endophthalmitis, but time courses of these infections may not have been clinically similar to that seen in rapid human infections.

We analyzed the therapeutic effectiveness of combinations of prednisolone, gatifloxacin, and vancomycin, or those drugs used alone in a well-established *B. cereus* endophthalmitis rabbit model.<sup>11, 21-24</sup> Infections were analyzed up to 48 h postinfection to better determine prolonged therapeutic effectiveness.

## Methods

### *Animals*

The New Zealand White rabbits (body weight, 2-4 kg) used in this study were maintained in accordance with institutional guidelines and the Association for Research in Vision and Ophthalmology Statement on the Use of Laboratory Animals in Ophthalmic Research. Rabbits were anesthetized with an intramuscular injection of ketamine (KetaVed™; Phoenix Scientific Inc., St. Joseph, MO; 35 mg/kg of body weight) and xylazine (Rompun™; Bayer Corp., Shawnee Mission, KS; 5mg/kg of body weight). Proparacaine HCl (Ophthetic™; Allergan; 0.5%) was used to topically anesthetize the eyes prior to paracentesis and intravitreal injection.

### **Bacteria and Drugs**

Rabbit eyes were intravitreally injected with 100 CFU *B. cereus* strain ATCC 14579 as previously described.<sup>11</sup> The following drugs were used: prednisolone sodium

phosphate (PredForte® 1.0%, Bausch & Lomb, Tampa, FL), gatifloxacin (Zymar® 0.3%, Allergan, Irvine, CA), and vancomycin (1.0% final concentration in PBS, Hospira, Lake Forest, IL).

## Experimental Design

100 CFU/0.1 ml *B. cereus* were injected into the mid-vitreous of one eye of each rabbit and the contralateral eye served as a control, as previously described.<sup>11,21-24</sup> Rabbits were anesthetized, underwent paracentesis, and were intravitreally injected at 2 h, 4 h, or 6 h postinfection with 0.1 ml of each antibiotic alone, 0.15 ml of combined drugs at their appropriate final concentrations, or were left untreated. Rabbits were randomly divided into treatment groups as follows: vancomycin (1.0%) and prednisolone (1.0%), gatifloxacin (0.3%) and prednisolone, vancomycin and gatifloxacin, vancomycin alone, gatifloxacin alone, or prednisolone alone. At 12, 24, and 36 h (for eyes treated at 6 h) or 12, 24, and 48 h (for eyes treated at 2 h or 4 h) postinfection, eyes were analyzed as described below.

## Analysis of Therapeutic Efficacy

Retinal function was measured and recorded (UTAS3000; LKC Technologies, Inc., Gaithersburg, MD) by scotopic electroretinography (ERG) as previously described (N=5 eyes/group).<sup>11,21-24</sup> Immediately following ERG, an operating biomicroscope (Zeiss S7; Zeiss Inc, Thornwood, NY) was used to visualize and photograph rabbit eyes (N≥2 representative eyes/group). Changes in anterior and posterior segment inflammation and retinal architecture were scored in a masked independent fashion based on a scale from 0 (no change) to 4+ (significant inflammation and retinal architecture damage) (N=5 eyes/group).<sup>25</sup> Eyes used for histology were enucleated and prepared as previously described (N≥2 representative eyes/group).<sup>11</sup> At 12, 24, and 36 or 48 h postinfection, viable bacteria in aspirated vitreous were quantified, as previously described (N=5 eyes/group).<sup>11,21-24</sup> Antibiotic concentrations were quantified in the vitreous and aqueous humor, as previously described (N≥4 eyes/group).<sup>11,26</sup> Myeloperoxidase (MPO) activity estimated the extent of infiltrating polymorphonuclear leukocytes (PMN), as previously described (N≥3 eyes/group).<sup>27,28</sup> All values represent the mean ± standard error of the mean (SEM), as indicated. Two-tailed, two-sample t-tests were used to statistically compare groups. A P-value of ≤ 0.05 was considered significant.

## Results

All eyes treated with antibiotics were sterile at 12 h. Eyes in the untreated and 2-h prednisolone treatment groups had approximately 7.3 log<sub>10</sub> CFU/ml and 7.4 log<sub>10</sub> CFU/ml, respectively, when analyzed at 12 h, values that were similar to that of PBS-injected vehicle and untreated infected controls.<sup>11,21-24</sup>

Retinal function analysis of eyes infected with *B. cereus* is summarized in Figure 1. Eyes that were untreated or treated with prednisolone alone at 2 h retained <5% A- and B-wave function at 12 h. Uninfected eyes treated with prednisolone alone maintained a range of 99%-128% A-wave and 97%-126% B-wave function throughout 48 h of analysis (data not shown). Eyes treated with vancomycin alone or gatifloxacin

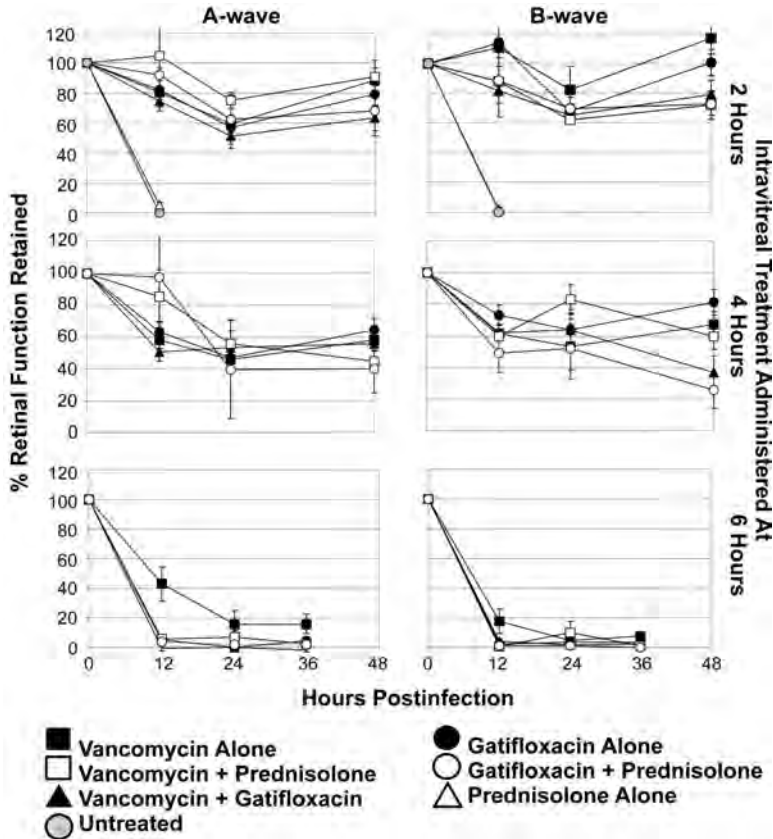


Figure 1. Retinal function analysis following antibiotic and/or prednisolone treatment of experimental *B. cereus* endophthalmitis.

alone at 2 h retained significant and similar levels of A-wave ( $P=0.45$ ) and B-wave ( $P=0.27$ ) function at 48 h. The 2-h prednisolone/vancomycin combination resulted in 91% A-wave function ( $P=0.86$  vs. 2-h vancomycin alone) but only 72% B-wave function ( $P=0.01$  vs. 2-h vancomycin alone) at 48 h. The 2-h prednisolone/gatifloxacin treatment resulted in 68% A-wave function ( $P=0.57$  vs. 2-h gatifloxacin alone) and 72% B-wave function ( $P=0.20$  vs. 2-h gatifloxacin alone). When vancomycin/gatifloxacin were administered at 2 h, eyes maintained less A-wave and B-wave function compared to either antibiotic used alone, but the differences were not significant ( $P \geq 0.06$ , except for vancomycin/gatifloxacin vs. vancomycin alone B-wave,  $P=0.03$ ). Eyes treated with vancomycin alone at 4 h had decreased function compared to treatment at 2 h. The prednisolone/vancomycin 4-h treatment resulted in 44% A-wave function ( $P=0.18$  vs. 4-h vancomycin alone) and 60% B-wave function ( $P=0.56$  vs. 4-h vancomycin alone) at 48 h. Eyes treated with gatifloxacin alone at 4 h retained 64% A-wave function and 81% B-wave function at 48 h. The prednisolone/gatifloxacin 4-h treatment resulted in 40% A-wave function ( $P=0.19$  vs. 4-h gatifloxacin

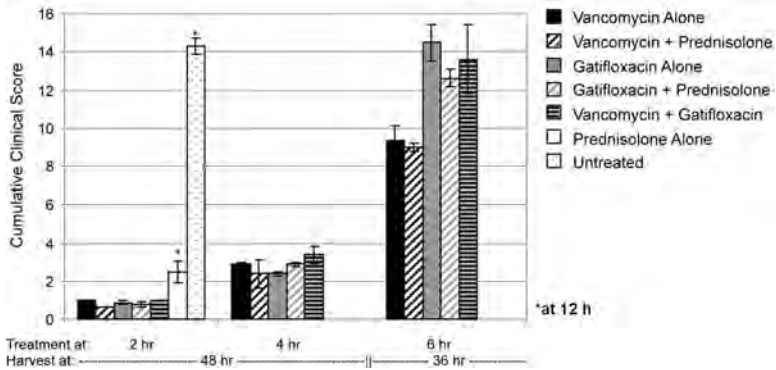


Figure 2. Clinical scoring of pathology following treatment of experimental *B. cereus* endophthalmitis.

alone) and 26% B-wave function ( $P=0.004$  vs. 4-h gatifloxacin alone). Eyes treated with vancomycin alone or gatifloxacin alone at 4 h retained similar levels of A-wave ( $P=0.53$ ) and B-wave ( $P=0.27$ ) function at 48 h. When vancomycin/gatifloxacin were administered at 4 h, eyes maintained less A-wave and B-wave function compared to either antibiotic used alone, but the differences were not significant ( $P \geq 0.05$ , except for vancomycin/gatifloxacin vs. gatifloxacin alone B-wave,  $P=0.01$ ). Eyes that received antibiotic treatment with or without prednisolone at 6 h had significant A-wave and B-wave loss, with the vancomycin-alone group maintaining higher A-wave ( $P \leq 0.01$ ) and B-wave ( $P \leq 0.05$ ) function at 12 h compared with the other treatment groups. After 12 h, retinal function was retained to  $<20\%$  in eyes of all 6-h treatment groups.

Scoring and photographs of infected eyes are summarized in Figures 2 and 3A, respectively. Biomicroscopic analysis of infected eyes treated at 2 h with gatifloxacin alone, vancomycin alone, or either antibiotic with prednisolone presented with minor iritis, no reduction in red reflex, no posterior chamber haze, and no reduction in retinal clarity at 48 h. Eyes treated at 2 h with prednisolone alone had minor iritis, a slight reduction in red reflex, slight posterior segment haze, and no reduction in retinal clarity at 12 h. Cumulative clinical scores of eyes treated with prednisolone alone were greater than that of all other treated infection groups ( $P \leq 0.01$ ). In contrast, untreated eyes at 12 h had significant accumulation of inflammatory cells in the anterior chamber and severe iritis, no red reflex or clarity, and a dense vitreal haze, findings similar to previous reports of untreated infection at 12 h in this model.<sup>11, 21-24</sup> Cumulative clinical scores of untreated infected eyes were greater than that of all other groups ( $P < 0.0001$ ). Infected eyes treated at 4h with vancomycin alone, gatifloxacin alone, or antibiotic/prednisolone combinations had minor iritis and aqueous flare, a slight reduction in red reflex, a slight vitreal haze, and no reduction in retinal clarity at 48 h. All eyes in these groups had moderate conjunctival injection and edema. The cumulative clinical scores of vancomycin alone vs prednisolone/vancomycin ( $P=0.66$ ) and gatifloxacin alone vs. prednisolone/gatifloxacin ( $P=0.25$ ) were similar. Eyes treated at 6 h with prednisolone/vancomycin had moderate flare and significant iritis, a reduction in red reflex and retinal clarity, and a mild posterior segment haze at 36 h. Eyes treated at 6 h with vancomycin alone had significant anterior chamber flare and iritis, a moderate reduction of red reflex, a mild vitreal haze, and a

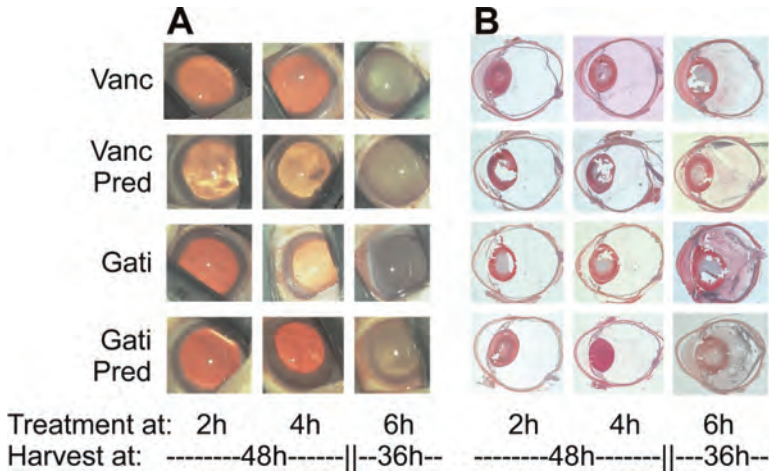


Figure 3. Biomicroscopy and histology following treatment of experimental *B. cereus* endophthalmitis.

moderate reduction in retinal clarity at 36 h. Eyes treated at 6 h with gatifloxacin alone, gatifloxacin/vancomycin, or prednisolone/gatifloxacin had intense flare and severe iritis, a moderate to complete loss of red reflex, a dense vitreal haze, and a significant reduction in retinal clarity at 36 h. Eyes treated at 6 h with prednisolone/antibiotic combinations had less conjunctival edema and injection at 36 h compared to eyes treated with antibiotics alone. The cumulative clinical scores of vancomycin alone vs prednisolone/vancomycin ( $P=0.41$ ) and gatifloxacin alone vs. prednisolone/gatifloxacin ( $P=0.13$ ) were similar.

Representative histology sections are provided in Figure 3B. Histologic analysis of treated infected eyes reflected the clinical observations summarized in Figures 2 and 3A. Eyes treated with antibiotics with or without prednisolone at 2 h or 4 h were less inflamed than those treated at 6 h. Retinas of eyes treated at 6 h exhibited retinal folding with inflammatory cells visible beneath the retina and retinal detachments. The gatifloxacin alone and prednisolone/gatifloxacin 6-h treatment groups had significant numbers of posterior segment inflammatory cells and fibrin accumulation. Adding prednisolone to vancomycin or gatifloxacin treatment at 6 h appeared to reduce corneal inflammation, but resulted in reduced anterior chamber fibrin accumulation when administered with vancomycin only. Eyes treated at 6 h with the vancomycin/gatifloxacin combination had significant fibrin accumulation and inflammatory cells in the posterior chamber and significant corneal inflammation.

Intraocular inflammation was estimated using the myeloperoxidase (MPO) assay, as summarized in Figure 4. Eyes treated at 2 h or 4 h with antibiotics had less MPO activity than those treated at 6 h ( $P\leq 0.001$ ), with the exception of eyes treated at 4 h or 6 h with the vancomycin/gatifloxacin combination ( $P=0.21$ ). Excluding the 2-h prednisolone alone and untreated groups, all eyes treated prior to 6 h postinfection had  $< 50$  MPO units/eye, indicating minimal inflammation. The 2-h prednisolone alone treatment resulted in inflammation similar to that of untreated eyes ( $P=0.32$ ). Eyes treated at 6 h with vancomycin alone had reductions in MPO compared to all other 6-h treatment groups ( $P\leq 0.03$ ). Eyes treated at 6 h with gatifloxacin alone or

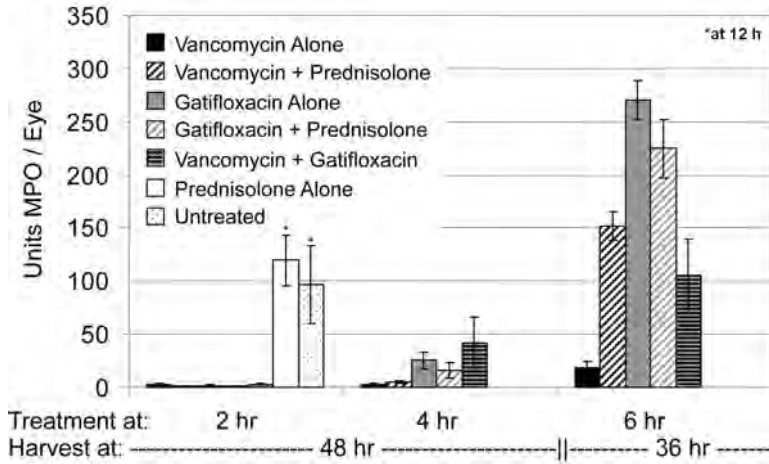


Figure 4. Myeloperoxidase (MPO) activity in eyes following treatment of *B. cereus* endophthalmitis.

prednisolone/gatifloxacin had greater MPO activity than any other treatment regimen ( $P \leq 0.01$ ). The addition of prednisolone to vancomycin increased the MPO in those eyes compared to vancomycin alone ( $P = 0.0002$ ), but had no effect when added to gatifloxacin ( $P = 0.34$ ) at 6 h.

Concentrations of vancomycin and gatifloxacin in the aqueous or vitreous of infected eyes are summarized in Figure 5. Vitreous gatifloxacin levels were below the MIC for *B. cereus* at 24 and 36 or 48 h, while aqueous gatifloxacin concentrations were below the MIC for *B. cereus* at 12, 24, and 36 or 48 h regardless of the time of treatment or whether prednisolone was included. Vancomycin treatment at 2 h resulted in higher vitreous drug levels at all time points tested and higher aqueous levels at 12 h compared to that of 4-h or 6-h treatment groups at those same time points ( $P \leq 0.001$ ). In general, the addition of prednisolone to vancomycin resulted in greater vancomycin concentrations in the aqueous and vitreous ( $P \leq 0.001$ ), an effect that was most pronounced following treatment at 2 h. Vitreous vancomycin concentrations remained well above the MIC for *B. cereus* throughout 36 or 48 h in groups treated with vancomycin alone. Similar results were seen in eyes treated with vancomycin and prednisolone, except in the 6-h treatment group assayed at 36 h. Aqueous concentrations following vancomycin alone were above the MIC for *B. cereus* regardless of the treatment time at 12 h only. When combined with prednisolone, aqueous vancomycin concentrations were well above the MIC for *B. cereus* at all time points assayed following 2 h treatment, but fell below the MIC for *B. cereus* at 48 h following treatment at 4 h or 6 h.

## Conclusions

*B. cereus* endophthalmitis can result in explosive intraocular inflammation and rapid vision loss. Even when vision is lost, retaining an intact globe is of primary anatomic and cosmetic importance. It is therefore critical that effective treatment

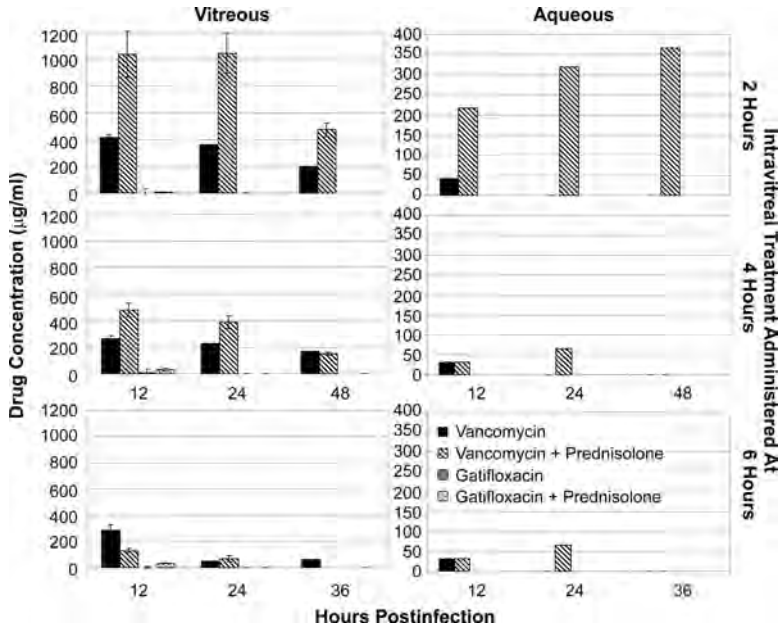


Figure 5. Intraocular antibiotic penetration following treatment of experimental *B. cereus* endophthalmitis.

regimens be initiated as early after injury as possible. We previously demonstrated that early treatment with gatifloxacin or vancomycin effectively killed intraocular *B. cereus*, but at later treatment times, significant vision loss occurred.<sup>11</sup> In that study, treatment with antibiotic/dexamethasone combinations did not improve the overall clinical outcome of infection.<sup>11</sup> Therefore, analysis of an alternate anti-inflammatory agent was of value in identifying a companion drug for clinical improvement of this highly inflammatory infection.

Prednisolone ophthalmic solutions are commonly used to control inflammation following surgery. Intramuscular and systemic methylprednisolone have been beneficial in models of *Staphylococcus aureus* endophthalmitis.<sup>29,30</sup> A postoperative clinical study evaluating the efficacy of intramuscular prednisolone following vitrectomy reported improved visual acuity.<sup>31</sup> To our knowledge, ours is the first study to analyze the efficacy of prednisolone via intravitreal administration as an adjunctive therapy for endophthalmitis. Eyes treated at 2 or 4 h with all antibiotic regimens maintained significant retinal function throughout 48 h. Together, the results from this and our previous study<sup>11</sup> suggest that when antibiotic treatment is administered at 4 h or earlier, retinal function may decline but remains significant for at least 2 days. These early regimens also preserved ocular architecture. However, the addition of prednisolone to either antibiotic did not affect the retention of retinal function, even at these early treatment times.

When treatment was delayed to 6 h, significant retinal function was lost regardless of the treatment regimen, as expected. Treatment with gatifloxacin alone or combined with vancomycin or prednisolone at 6 h resulted in greater MPO activity, a higher clinical score, and more severe inflammation when compared to vancomycin alone

at 36 h. Histologically, eyes treated with vancomycin at 6 h had less inflammation than those treated with gatifloxacin at 6 h. Together these results suggested that vancomycin treatment resulted in a better clinical outcome. These results also suggest that with use of either antibiotic, later treatment may not salvage useful vision, but can preserve ocular architecture up to 36 h.

All antibiotic treatments sterilized all infected eyes by 12 h. In our previous study, eyes subjected to 6-h vancomycin treatment retained  $2.5 \log_{10}$  CFU of *B. cereus* at 8 h.<sup>11</sup> Together these results suggest that vancomycin killing in the eye was slower than that of gatifloxacin, since all eyes treated with gatifloxacin were sterile at 8 h.<sup>11</sup> *In vitro* time-kill studies clearly demonstrate the relative speed at which the 4<sup>th</sup>-generation fluoroquinolones kill pathogens.<sup>32-25</sup> However, Harper *et al.*<sup>36</sup> reported that vancomycin was more effective than gatifloxacin in terms of pharmacokinetic indices *in vitro*. To our knowledge, no studies have compared relative kill rates of vancomycin with that of gatifloxacin. Studies in *in vitro* pharmacodynamic models<sup>37-39</sup> and our own data suggest that the kill rate of vancomycin is slower than that of gatifloxacin.

Of note was the lack of substantial inflammation and better intraocular clarity in vancomycin-treated eyes, suggesting some beneficial level of anti-inflammatory activity. Vancomycin does not have anti-inflammatory activity *per se*, but can affect PMN phagocytic and chemotactic function<sup>40,41</sup> and inhibit proinflammatory cytokine responses *in vitro*<sup>42,43</sup>. If PMN recruitment or chemotaxis in the eye are affected by vancomycin, inflammation may be arrested during infection. Immunomodulatory effects of some fluoroquinolones have been reported.<sup>44,45</sup> Given this potential activity, infections treated with these antibiotics should be of greater severity if immune suppression occurred. We reported that delay of ocular inflammation in a TNF $\alpha$  knockout mouse resulted in a more severe infection.<sup>46</sup> Of course, the mechanisms of potential immune suppression are likely different. Nevertheless, the present data do not support the idea of immune suppression following gatifloxacin treatment. Although the data would support the idea of immunosuppression in the vancomycin-treated groups, less inflammation in these eyes could be attributed to more efficient bacterial killing.

Because of vitreous and aqueous turnover one would expect lower antibiotic concentrations in an eye from 2-12 h than from 6-12 h. To the contrary, greater antibiotic concentrations were retained in eyes treated at 2 h than in eyes treated at 4 or 6 h. We recently reported the extent of blood ocular barrier permeability in response to untreated *B. cereus* endophthalmitis<sup>47</sup>, so it follows that higher levels of antibiotics would be retained in eyes with less inflammation because of early treatment. Vancomycin diffusion from the eye may have also been limited by the presence of prednisolone. Prednisolone's mechanism of action includes potent anti-inflammatory effects and prevention of blood-ocular barrier breakdown. If this were the case, one would expect less inflammation in eyes treated with the vancomycin/prednisolone combination if the presence of prednisolone affected barrier permeability. The extent of blood retinal barrier permeability following these treatment regimens should be determined to identify whether prednisolone itself affected permeability.

In our ongoing efforts to determine the mechanism of vision loss in *B. cereus* endophthalmitis, we hypothesized that toxins were involved in the rapid loss of retinal function observed in this disease.<sup>21-24</sup> One can postulate that early treatments kill bacteria before significant levels of toxins are present, limiting retinal function loss. However, *B. cereus* endophthalmitis also results in explosive inflammation within

12 h<sup>11,21-25</sup> and bystander products of inflammation could negatively impact retinal function. Loss of retinal function directly correlated with an increase in bacterial replication and influx of PMN into the posterior segment.<sup>25</sup> In the present study, 4-h antibiotic treatment regimens resulted in some loss of retinal function without significant inflammation. For eyes treated with vancomycin at 6 h, retinal function rapidly declined, but again, inflammation was limited. We were therefore unable to correlate retinal function decline with posterior segment inflammation. These results suggest that inflammation may not contribute to the rapid vision loss observed at early times during *B. cereus* endophthalmitis, leaving toxins or other secreted bacterial products as the likely culprits responsible for rapid retinal function loss.

In summary, the addition of prednisolone to antibiotics in this model did not offer a clear therapeutic benefit, suggesting that corticosteroids as a whole may not be a viable option for reducing inflammation during severe endophthalmitis. Vancomycin killed *B. cereus* slower than did gatifloxacin, but eyes treated with vancomycin were less inflamed, a clinical advantage. Although antibiotic treatments were not as effective in protecting vision when used later in infection, these regimens did preserve globe architecture, an anatomic and cosmetic benefit. It is clear from these and previous studies that further testing of different antibiotic/anti-inflammatory and surgical regimens is needed in order to identify therapies that will kill bacteria rapidly, abrogate inflammation, neutralize toxic effects, and prevent blindness during fulminant *B. cereus* endophthalmitis.

## References

1. CALLEGAN MC, GILMORE MS, GREGORY M, RAMADAN RT, WISKUR BJ, MOYER AL, HUNT JJ, NOVOSAD BD. Bacterial endophthalmitis: therapeutic challenges and host-pathogen interactions. *Prog Retin Eye Res* 26:189-203, 2007.
2. GREGORY M, CALLEGAN MC, GILMORE MS. Role of bacterial and host factors in infectious endophthalmitis. *Chem Immunol Allergy* 92:266-275; 2007.
3. MEREDITH TA. Posttraumatic endophthalmitis. *Arch Ophthalmol* 117:520-521, 1999.
4. THOMPSON ST, PARVER LM, ENGER CL, MEILER WF, LIGGET PE. Infectious endophthalmitis after penetrating injuries with retained intraocular foreign bodies. *Ophthalmology* 100:1468-1474, 1993.
5. DAVEY RJ, TAUBER WB. Posttraumatic endophthalmitis: the emerging role of *Bacillus cereus* infection. *Rev Infect Dis* 9:110-123, 1987.
6. DAVID DB, KIRKBY GR, NOBLE BA. *Bacillus cereus* endophthalmitis. *Br J Ophthalmol* 78:577-580, 1994.
7. O'DAY DM, SMITH RS, GREGG CR, TURNBULL PC, HEAD WS, IVES JA, HO PC. The problem of *Bacillus* species infection with special emphasis on the virulence of *Bacillus cereus*. *Ophthalmology* 88:833-838, 1981.
8. CALLEGAN MC, COCHRAN DC, KANE ST, RAMADAN RT, CHODOSH J, MCLEAN C, STROMAN DW. Virulence factor profiles and antimicrobial susceptibilities of ocular *Bacillus* isolates. *Curr Eye Res* 31:693-702, 2006.
9. CHHABRA S, KUNIMOTO DY, KAZI L, REGILLO CD, HO AC, BELMONT J, MAGUIRE J, VANDER J, BROWN GC. Endophthalmitis after open globe injury: microbiologic spectrum and susceptibilities of isolates. *Am J Ophthalmol* 142:852-854, 2007.
10. MILLER JJ, SCOTT IU, FLYNN JR HW, SMIDDY WE, MURRAY TG, BERROCAL A, MILLER D. Endophthalmitis caused by *Bacillus* species. *Am J Ophthalmol* 145:883-888, 2008.

11. WISKUR BJ, ROBINSON ML, FARRAND AJ, NOVOSAD BD, CALLEGAN MC. Toward improving therapeutic regimens for *Bacillus* endophthalmitis. *Invest Ophthalmol Vis Sci* 49:1480-1487, 2008.
12. ENGEL LS, CALLEGAN MC, HOBDEN JA, REIDY JJ, HILL JM, O'CALLAGHAN RJ. Effectiveness of specific antibiotic/steroid combinations for therapy of experimental *Pseudomonas aeruginosa* keratitis. *Curr Eye Res* 14:229-234, 1995.
13. HOBDEN JA, ENGEL LS, HILL JM, CALLEGAN MC, O'CALLAGHAN RJ. Prednisolone acetate or prednisolone phosphate concurrently administered with ciprofloxacin for the therapy of experimental *Pseudomonas aeruginosa* keratitis. *Curr Eye Res* 12:469-473, 1993.
14. SRINIVASAN M, LALITHA P, MAHALAKSHMI R, PRAJNA NV, MASCARENHAS J, CHIDAMBARAM JD, LEE S, HONG KC, ZEGANS M, GLIDDEN DV, MCLEOD S, WHITCHER JP, LIETMAN TM, ACHARYA NR. Corticosteroids for bacterial corneal ulcers. *Br J Ophthalmol* 93:198-202; 2009.
15. KERNACKI KA, BERK RS. Characterization of the inflammatory response induced by corneal infection with *Pseudomonas aeruginosa*. *J Ocul Pharmacol* 10:281-288, 1994.
16. LEE EJ, TRUONG TN, MENDOZA MN, FLEISZIG SM. A comparison of invasive and cytotoxic *Pseudomonas aeruginosa* strain-induced corneal disease responses to therapeutics. *Curr Eye Res* 27:289-299, 2003.
17. LIU F, KWOK AK, CHEUNG BM. The efficacy of intravitreal vancomycin and dexamethasone in the treatment of experimental *Bacillus cereus* endophthalmitis. *Curr Eye Res* 33:761-768, 2008.
18. LIU SM, WAY T, RODRIGUES M, STEIDL SM. Effects of intravitreal corticosteroids in the treatment of *Bacillus cereus* endophthalmitis. *Arch Ophthalmol* 118:803-806, 2000.
19. ALFARO DV, DAVIS J, KIM S, BIA F, BOGARD JF, BRIGGS JW, LIGGETT PE. Experimental *Bacillus cereus* post-traumatic endophthalmitis and treatment with ciprofloxacin. *Br J Ophthalmol* 80:755-758, 1996.
20. ALFARO DV, HUDSON SJ, STEELE JJ, BEVIN AA, MINES M, LAUGHLIN RM, SCHODERBEK RJ. Experimental posttraumatic *Bacillus cereus* endophthalmitis in a swine model: efficacy of intravitreal ciprofloxacin, vancomycin, and imipenem. *Retina* 16:317-323, 1996.
21. CALLEGAN MC, JETT BD, HANCOCK LE, GILMORE MS. Role of hemolysin BL in the pathogenesis of extraintestinal *Bacillus cereus* infection assessed in an endophthalmitis model. *Infect Immun* 67:3357-3366, 1999.
22. CALLEGAN MC, COCHRANE DC, KANE ST, GILMORE MS, GOMINET M, LERECLUS D. Contribution of membrane-damaging toxins to *Bacillus* endophthalmitis pathogenesis. *Infect Immun* 70:5381-5389, 2002.
23. CALLEGAN MC, KANE ST, COCHRAN DC, NOVOSAD B, GILMORE MS, GOMINET M, LERECLUS D. *Bacillus* endophthalmitis: roles of bacterial toxins and motility during infection. *Invest Ophthalmol Vis Sci* 46:3233-3238, 2005.
24. CALLEGAN MC, KANE ST, COCHRAN DC, GILMORE MS, GOMINET M, LERECLUS D. Relationship of plcR-regulated factors to *Bacillus* endophthalmitis virulence. *Infect Immun* 71:3116-3124, 2003.
25. RAMADAN RT, RAMIREZ R, NOVOSAD BD, CALLEGAN MC. Acute inflammation and loss of retinal architecture and function during experimental *Bacillus* endophthalmitis. *Curr Eye Res* 31:955-965, 2006.
26. ENGEL LS, CALLEGAN MC, HILL JM, O'CALLAGHAN RJ. Bioassays for quantitating ciprofloxacin and tobramycin in aqueous humor. *J Ocul Pharm* 9:311-320, 1993.
27. BRADLEY PP, PRIEBAT DA, CHRISTENSEN RD, ROTHSTEIN G. Measurement of cutaneous inflammation; estimation of neutrophil content with an enzyme marker. *J Invest Dermatol* 78:206-209, 1982.

28. WILLIAMS RN, PATTERSON CA, EAKINS KE. Quantitation of ocular inflammation: evaluation of polymorphonuclear leukocyte inflammation by measuring myeloperoxidase activity. *Curr Eye Res* 2:465-470, 1983.
29. AGUILAR HE, MEREDITH TA, DREWS C, GROSSNIKLAUS H, SAWANT AD, GARDNER S. Comparative treatment of experimental *Staphylococcus aureus* endophthalmitis. *Am J Ophthalmol* 121:310-317, 1996.
30. YOSHIKUMI MO, KASHANI A, PALMER J, LEE G, MONDINO B. High dose intramuscular methylprednisolone in experimental *Staphylococcus aureus* endophthalmitis. *J Ocul Pharmacol Ther* 15:91-96, 1999.
31. REHAK M, BLATZ R, WIEDEMANN P, MEIER P. Primary vitrectomy with intraocular antibiotic application in postoperative endophthalmitis. *Ophthalmologie* 104:958-64, 2007.
32. CALLEGAN MC, NOVOSAD BD, RAMADAN RT, WISKUR B, MOYER AL. Rate of bacterial eradication by ophthalmic solutions of fourth-generation fluoroquinolones. *Adv Ther* 26:447-454, 2009.
33. KOWALSKI RP, KOWALSKI BR, ROMANOWSKI EG, MAH FS, THOMPSON PP, GORDON YJ. The *in vitro* impact of moxifloxacin and gatifloxacin concentration (0.5% vs 0.3%) and the addition of benzalkonium chloride on antibacterial efficacy. *Am J Ophthalmol* 142:730-735, 2006.
34. PENDLAND SL, NEUHAUSER MM, GAREY KW, PRAUSE JL, JUNG R. Comparative killing rates of gatifloxacin and ciprofloxacin against 14 clinical isolates: impact of bacterial strain and antibiotic concentration. *Diagn Microbiol Infect Dis* 44:59-61, 2002.
35. TAKEI M, YAMAGUCHI Y, FUKUDA H, YASUDA M, DEGUCHI T. Cultivation of *Neisseria gonorrhoeae* in liquid media and determination of its *in vitro* susceptibilities to quinolones. *J Clin Microbiol* 43:4321-4327, 2005.
36. HARPER T, MILLER D, FLYNN JR HW. In vitro efficacy and pharmacodynamic indices for antibiotics against coagulase-negative *Staphylococcus* endophthalmitis isolates. *Ophthalmology* 114:871-875, 2007.
37. LAPLANTE KL, LEONARD SN, ANDES DR, CRAIG WA, RYBAK MJ. Activities of clindamycin, daptomycin, doxycycline, linezolid, trimethoprim-sulfamethoxazole, and vancomycin against community-associated methicillin-resistant *Staphylococcus aureus* with inducible clindamycin resistance in murine thigh infection and *in vitro* pharmacodynamic models. *Antimicrob Agents Chemother* 52:2156-2162, 2008.
38. LEONARD SN, CHEUNG CM, RYBAK MJ. Activities of ceftobiprole, linezolid, vancomycin, and daptomycin against community-associated and hospital-associated methicillin-resistant *Staphylococcus aureus*. *Antimicrob Agents Chemother* 52:2974-2976, 2008.
39. WOOTTON M, MACGOWAN AP, WALSH TR. Comparative bactericidal activities of daptomycin and vancomycin against glycopeptide-intermediate *Staphylococcus aureus* (GISA) and heterogeneous GISA isolates. *Antimicrob Agents Chemother* 50:4195-4197, 2006.
40. CAPODICASA E, SCARINGI L, ROSATI E, DE BELLIS F, SBARAGLIA G, MARCONI P, DEL FAVERO A. *In-vitro* effects of teicoplanin, teicoplanin derivative MDL 62211 and vancomycin on human polymorphonuclear cell function. *J Antimicrob Chemother* 27:619-626, 1991.
41. MORÁN FJ, PUENTE LF, PÉREZ-GIRALDO C, BLANCO MT, HURTADO C, GÓMEZ-GARCÍA AC. Activity of vancomycin and teicoplanin against human polymorphonuclear leucocytes: a comparative study. *J Antimicrob Chemother* 28:415-418, 1991.
42. ENGLISH BK, MARYNIW EM, TALATI AJ, MEALS EA. Diminished macrophage inflammatory response to *Staphylococcus aureus* isolates exposed to daptomycin versus vancomycin or oxacillin. *Antimicrob Agents Chemother* 50:2225-2227, 2006.
43. KREHMEIER U, BARDENHEUER M, VOGGENREITER G, OBERTACKE U, SCHADE FU, MAJETSCHAK M. Effects of antimicrobial agents on spontaneous and endotoxin-induced cytokine release of human peripheral blood mononuclear cells. *J Infect Chemother* 8:194-197, 2002.

44. DALHOFF A. Immunomodulatory activities of fluoroquinolones. *Infection* 33 Suppl 2:55-70, 2005.
45. URIARTE SM, MOLESTINA RE, MILLER RD, BERNABO J, FARINATI A, EIGUCHI K, RAMIREZ JA, SUMMERSGILL JT. Effects of fluoroquinolones on the migration of human phagocytes through *Chlamydia pneumoniae*-infected and tumor necrosis factor alpha-stimulated endothelial cells. *Antimicrob Agents Chemother* 48:2538-2543, 2004.
46. RAMADAN RT, MOYER AL, CALLEGAN MC. A role for tumor necrosis factor-alpha in experimental *Bacillus cereus* endophthalmitis pathogenesis. *Invest Ophthalmol Vis Sci*. 49:4482-4489, 2008.
47. MOYER AL, RAMADAN RT, NOVOSAD BD, ASTLEY R, CALLEGAN MC. *Bacillus cereus*-induced permeability of the blood ocular barrier during experimental endophthalmitis. *Invest Ophthalmol Vis Sci* 50:3783-3793, 2009.



NUMBER 1 OF 1

## **AUTHOR QUERIES**

DATE 3/10/2011

JOB NAME IAE

ARTICLE IAE201933

QUERIES FOR AUTHORS Callegan et al

### **THIS QUERY FORM MUST BE RETURNED WITH ALL PROOFS FOR CORRECTIONS**

- AU1) Please provide academic degrees for the author “Nanette R. Wheatley.”
- AU2) Please check if the edits to the sentence “*Bacillus cereus* is susceptible ...”
- AU3) Please check if “these infections” can be changed to “the microbial infections” in the sentence “Previous efficacy studies ...”
- AU4) Please define “PMN” in its first occurrence in the text. Also, please spell out the same in the beginning of sentence and in section heads.
- AU5) Please check if the edits to the sentence “Conversely, findings from ...” retain the intended meaning.
- AU6) Please clarify “conjunctival injection caused by speculum” in the sentence “Immediately after the surgical ...”
- AU7) Please spell out “GFAP.”
- AU8) Please specify the reference numbers (if any) indicating “previous therapeutic studies” in the sentence “In comparing our ...”
- AU9) Please clarify the journal title and update Ref. 15.
- AU10) Please note that Refs. 17 and 19 were identical. Hence, the repetition has been removed and references have been renumbered both in the text and in the list. Please check.
- AU11) Please update Ref. 36
- AU12) Please clarify the sentence “PMN were quantified from ...” in the caption of Figure 3.

# EFFICACY OF VITRECTOMY IN IMPROVING THE OUTCOME OF *BACILLUS CEREUS* ENDOPHTHALMITIS

AQ : 1 MICHELLE C. CALLEGAN, PhD,\*†‡ SCOTT GUESS, MD,\* NANETTE R. WHEATLEY,\*  
DUSTIN C. WOODS, BS,§ GABE GRIFFIN, BS,§ BRANDT J. WISKUR, PhD,¶ ROBERT LEONARD, MD\*‡§

**Purpose:** To evaluate the efficacy of vitrectomy with vancomycin for the treatment of experimental *Bacillus cereus* endophthalmitis.

**Methods:** Endophthalmitis was initiated in rabbits via intravitreal injection of 100 colony-forming unit *B. cereus*. Treatment groups included 25-gauge transconjunctival sutureless vitrectomy with intravitreal vancomycin (1 mg) or vancomycin alone. Groups were treated at 4, 5, or 6 hours after infection. At 48 hours (for 4-hour and 5-hour groups) or 36 hours (for the 6-hour group) after infection, eyes were analyzed by electroretinography, histology, and inflammatory cell counts.

**Results:** Treatment with vitrectomy/vancomycin at 4 hours resulted in significantly greater retinal function compared with that of vancomycin alone. Intraocular inflammation after treatment at 4 hours was minimal for both the treatment groups. Treatment with vitrectomy/vancomycin or vancomycin alone at 5 hours or 6 hours after infection resulted in similar levels of retinal function loss (i.e., >90%) and significant intraocular inflammation.

**Conclusion:** These results demonstrate that vitrectomy may be of therapeutic benefit in the treatment of *B. cereus* endophthalmitis but only during the early stages of infection.

RETINA X:1-7, 2011

Bacterial endophthalmitis is an infection that can result from contamination of the posterior segment after eye surgery, a penetrating eye injury, or septic spread of infection into the eye from the bloodstream.<sup>1,2</sup> The incidence of posttraumatic endophthalmitis varies from 3% to 17% after a penetrating injury.<sup>3,4</sup> *Bacillus cereus* is a common bacterial cause of posttraumatic bacterial endophthalmitis.

From the Departments of \*Ophthalmology, and †Microbiology and Immunology, University of Oklahoma Health Science Center, Oklahoma City; ‡Dean A. McGee Eye Institute, Oklahoma City, Oklahoma; and §College of Medicine, and ¶Oklahoma Center for Neuroscience, University of Oklahoma Health Science Center, Oklahoma City, Oklahoma.

This study was funded by the Department of Defense Congressionally Directed Medical Research Program (W81XWH-07-1-0280 to MCC).

The study was also supported in part by the National Institutes of Health grants P30EY12191 (NIH CORE grant to Robert E. Anderson, OUHSC), Research Resources grant P20RR17703 (NCCR COBRE grant to Robert E. Anderson, OUHSC), and an unrestricted grant to the Dean A. McGee Eye Institute from the Research to Prevent Blindness.

The authors have no proprietary interest in any of the commercial products used in this article.

Reprint requests: Michelle C. Callegan, PhD, Department of Ophthalmology DMEI 418, 608 Stanton L. Young Boulevard., Oklahoma City, OK 73104 e-mail: michelle-callegan@ouhsc.edu

Patients with *B. cereus* endophthalmitis often present with severe ocular pain, periorbital swelling, proptosis of the globe, polymorphonuclear leukocytosis, and fever.<sup>5-7</sup> Only 9% of patients with *B. cereus* endophthalmitis retain 20/70 vision or better, and nearly half require enucleation or evisceration of the infected eye.<sup>6</sup> *Bacillus cereus* is susceptible to commonly used antibiotics, such as aminoglycosides, fluoroquinolones, and vancomycin.<sup>8-10</sup> However, the regularity of treatment failures necessitates improvements in therapy of this blinding infection.

Vitrectomy is widely used to remove intravitreal contents after ocular injuries, inflammation, and other diseases. Microincision vitrectomy, such as 23-gauge and 25-gauge vitrectomy, is often described as being minimally invasive.<sup>11,12</sup> The main concept of sutureless vitrectomy is to decrease postoperative inflammation, potentially resulting in an early recovery and an improvement in patient comfort. In rabbits, inflammation induced by 25-gauge vitrectomy was less than that induced by 20-gauge or 23-gauge vitrectomy.<sup>13</sup> Vancomycin is a commonly administered intravitreal antibiotic for treating intraocular infections, with reported 100% effectiveness against

AQ : 2

the most common gram-positive ocular pathogens, including *B. cereus*.<sup>8–10</sup> In an experimental *B. cereus* endophthalmitis model, vancomycin sterilized infected eyes when intravitreally administered as late as 6 hours after infection.<sup>14,15</sup> However, significant vision was lost if vancomycin was administered after 4-hour postinfection in this model, indicating that early treatment was critical for salvaging vision. Recently, we reported the potential vancomycin-based anti-inflammatory activity in this model.<sup>15</sup> Vitrectomy and injection of intravitreal vancomycin sterilized the vitreous cavity after an experimental staphylococcal endophthalmitis, resulting in minimal inflammation.<sup>16</sup> Previous efficacy studies<sup>17,18</sup> suggested that vancomycin can be effective against experimental *B. cereus* endophthalmitis, but time courses of these infections may not have been clinically similar to that seen in rapid human infections.

AQ:3

The majority of recent studies analyzing the potential benefits of vitrectomy for the treatment of endophthalmitis have used experimental fungal infection models.<sup>19–21</sup> For bacterial or fungal endophthalmitis, vitrectomy can be used as an effective strategy to remove not only dead organisms and cellular debris but also damaging toxins and other inflammogenic factors that may exacerbate infection.<sup>22</sup> Therefore, we hypothesized that additional surgical measures to remove offending toxic contents in the vitreous may improve the visual outcome of infection, which is important if treatment is delayed. To this end, we analyzed the therapeutic effectiveness of vitrectomy and intravitreal vancomycin with that of vancomycin alone in a well-established *B. cereus* endophthalmitis rabbit model<sup>14,15</sup> to determine whether vitrectomy and antibiotics offered an improved therapeutic benefit over that of antibiotics alone.

## Subjects and Methods

### *Subjects and Drugs*

Specific pathogen-free New Zealand white rabbits (male, 2–4 kg; Myrtle's Rabbitry, Thompson's Station, TN) were used in this study and were maintained in accordance with institutional guidelines and the Association for Research in Vision and Ophthalmology Statement on the Use of Laboratory Animals in Ophthalmic Research (online). Before intravitreal injection and retinal function analysis (electroretinography), rabbits were anesthetized with an intramuscular injection of ketamine (35 mg/kg of body weight; Ketamine HCl injection; Bioniche Pharma, Lake Forest, IL) and xylazine (5 mg/kg of body weight;

Rompun; Bayer, Corp, Shawnee Mission, KS. Proparacaine HCl (0.5%; Ophthetic; Allergan, Hormigueros, PR) was used to topically anesthetize the eyes before paracentesis and intravitreal injection. Vancomycin (1 mg final concentration in 100  $\mu$ L of phosphate-buffered saline, Hospira, Lake Forest, IL) was administered by intravitreal injection or immediately after vitrectomy. Vancomycin (1 mg) was previously demonstrated to be effective against *B. cereus* and nontoxic in this model.<sup>14,15</sup>

### *Experimental Endophthalmitis*

Rabbit eyes were intravitreally infected with *B. cereus* as previously described.<sup>14,15,23,24</sup> Briefly, an overnight culture of *B. cereus* strain ATCC 14579 (American Type Tissue Culture, Manassas, VA) was subcultured into brain heart infusion media (Difco Laboratories, Detroit, MI) and serially diluted to 100 colony-forming unit/0.1 ml for intravitreal injections. Contralateral eyes served as a noninfection control eyes. The minimum inhibitory concentration of *B. cereus* ATCC 14579 for vancomycin was 1.95  $\mu$ g/mL, as reported previously.<sup>14</sup>

### *Vitrectomy/Vancomycin Therapy*

The treatment regimens chosen for this study sought to mimic an elapsed time when a patient experiencing a penetrating injury may reasonably expect to receive treatment. Previous studies<sup>14,15</sup> have demonstrated that at and before 4 hours, intravitreal administration of vancomycin can reduce inflammation and salvage significant vision. We sought to determine whether vitrectomy further reduced the inflammation and vision loss associated with delayed treatment.

A total of 44 New Zealand white rabbits were randomized to 7 treatment groups. At 4-, 5-, or 6-hour postinfection, one eye of each rabbit underwent either 25-gauge transconjunctival sutureless vitrectomy (TSV-25 Millennium System; Bausch & Lomb, Inc, Rochester, NY) with intravitreal instillation of vancomycin or intravitreal instillation of vancomycin alone. A noninfected vitrectomy/vancomycin group was included as a control.

Vitrectomy was performed as follows. After general and topical anesthesia, a standard 3-ports pars plana vitrectomy was performed with removal of all visible vitreous gel and inflammatory debris. One-step transconjunctival cannula insertion was achieved using a beveled trochar at 2.0 mm from the corneoscleral limbus. Three incisions were made, and the infusion cannula was inserted into the inferotemporal cannula. Core vitrectomies removed vitreous using the Millennium 25-gauge high-speed vitrector for 10 minutes by

a combination of cutting (1,500 cuts/minute) and suction (400 mmHg), while continually supplying balanced salt solution irrigating solution at an ocular fluid pressure of 30 mmHg. On completion of the surgical procedure, the vitreous was infused through the cannula with 0.1 mL of 1.0% vancomycin. The surgical time required from opening to closure was an average of 20 minutes. The surgical procedure was completed by the removal of the entry site cannulas without scleral suturing. An experienced vitreoretinal surgeon performed all vitrectomies and was masked to the identity of the groups. There were no complications during the surgical procedure.

At 12, 24, and 48 hours (for eyes treated at 4 hours or 5 hours) or 12, 24, and 36 hours (for eyes treated at 6 hours) after infection, eyes were analyzed as described below.

#### *Analysis of Therapeutic Efficacy*

**Retinal Function Analysis.** Retinal function was measured and recorded (UTAS3000; LKC Technologies, Inc, Gaithersburg, MD) for both eyes of each rabbit by scotopic electroretinography as previously described.<sup>14,23–26</sup> Before electroretinography, eyes were dilated with phenylephrine HCl (AK-Dilate; Akorn, Inc, Buffalo Grove, IL) and dark adapted for 10 minutes. *a*-wave amplitudes were measured from the prestimulus baseline to the *a*-wave trough, while *b*-wave amplitudes were measured from the trough of the *a* wave to the peak of the *b* wave. The following equations were used to calculate the percentage of retinal function retained, where experimental denotes infected and absolute control denotes uninfected eyes:

$$100 - \{[1 - (\text{experimental } a\text{-wave amplitude} / \text{absolute control } a\text{-wave amplitude})] \times 100\} \text{ or}$$

$$100 - \{[1 - (\text{experimental } b\text{-wave amplitude} / \text{absolute control } b\text{-wave amplitude})] \times 100\}.$$
<sup>14,23–26</sup>

**Biomicroscopy and Histology.** An operating biomicroscope (Zeiss S7; Zeiss, Inc, Thornwood, NY) was used to visualize and photograph rabbit eyes. Changes in the anterior and posterior segment inflammation and retinal architecture were scored in a masked independent fashion based on a scale from 0 (no change) to 4+ (significant inflammation and retinal architecture damage).<sup>27</sup> Eyes used for histology were enucleated, fixed in 10% formalin for 24 hours, placed in 70% alcohol for 48 hours, paraffin sectioned, and stained with hematoxylin and eosin by standard procedures.

**Bacterial Quantitation.** Viable bacteria in aspirated vitreous were quantified, as described previously.<sup>14,23–26</sup> Briefly, eyes were harvested after euthanasia, vitreal contents were aspirated and homogenized, aspirates

were serially diluted in phosphate-buffered saline, and aliquots were plated out in triplicate on brain heart infusion media agar for quantitation.

**PMN Quantitation.** Quantitation of infiltrating PMN into the aqueous humor is a direct measure of the progression of intraocular inflammation throughout the eye.<sup>24–26</sup> Before harvest, eyes underwent paracentesis, aqueous samples were loaded onto a hemocytometer, and PMN were manually counted after trypan blue staining.

**Antibiotic Penetration into the Eye.** Antibiotic diffusion assays were used to quantify the concentration of antibiotics in the vitreous and aqueous humor, as previously described.<sup>14</sup> Indicator strains ( $10^5$  colony-forming unit/mL of *Staphylococcus aureus* or *Klebsiella pneumoniae*) were inoculated onto brain heart infusion media agar for vancomycin or gatifloxacin bioassays, respectively. Sterile filter disks loaded with 10  $\mu$ L of aqueous humor, vitreous, or antibiotic standards were placed onto the inoculated agar. Standards and samples were prepared and analyzed in triplicate. Assays were incubated at 37°C for 24 hours, and zones of inhibition were measured to the nearest 0.1 mm. A standard curve of zone of inhibition size versus log<sub>10</sub> concentration was plotted and used to determine antibiotic concentrations, the slope of which was determined from a best-fit curve by least square means method.

**Statistics.** For the PMN quantitation and antibiotic penetration assays, all values represent the mean  $\pm$  standard error of the mean for  $\geq 4$  replicate samples per time point. All other reported values represent the mean  $\pm$  standard error of the mean for  $\geq 5$  eyes per time point. Two-tailed, two-sample Student's *t*-tests were used to statistically compare groups. A *P* value of  $\leq 0.05$  was considered significant.

## Results

### *Bacterial Killing*

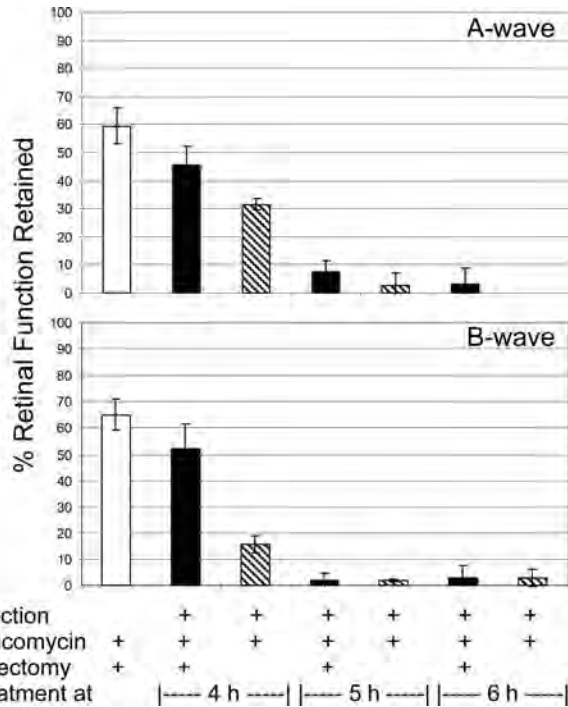
All eyes treated with vancomycin, with or without vitrectomy, were sterile at 12-hour postinfection. These results are consistent with previous reports<sup>14,15</sup> of vancomycin treatment in this infection model.

### *Retinal Function*

Retinal function retained after each treatment is summarized in Figure 1. In uninfected eyes, vitrectomy with vancomycin resulted in an approximate 40% decrease in *a*-wave amplitude and 35% decrease in *b*-wave amplitude at 48 hours after the surgical procedure.

AQ : 4

F1



**Fig. 1.** Retinal function analysis after treatment of experimental *B. cereus* endophthalmitis with vitrectomy and vancomycin. Eyes were infected with *B. cereus* and treated with vancomycin (1%) and vitrectomy or vancomycin alone at various times postinfection. The control group included uninfected eyes treated with vitrectomy and vancomycin. Eyes were analyzed by electroretinography at 36-hour or 48-hour postinfection. Values represent the mean  $\pm$  standard error of the mean of  $n \geq 5$  eyes per group.

Treatment at 4-hour postinfection with vitrectomy and vancomycin resulted in a 45% reduction in *a*-wave amplitude and a 50% reduction in *b*-wave amplitude at 48 hours. These values are less than but similar to those of the uninfected vitrectomy/vancomycin-treated group (*a* wave,  $P = 0.07$ ; *b* wave,  $P = 0.13$ ). These values are significantly greater than that of the vancomycin alone group, which resulted in 70% and 85% reductions in *a*-wave and *b*-wave amplitudes, respectively (*a* wave,  $P = 0.02$ ; *b* wave,  $P = 0.004$ ). Treatment for 5 hours or 6 hours resulted in significant loss of vision (i.e., >95% loss) regardless of whether vitrectomy was part of the vancomycin treatment regimen. These results demonstrate that vitrectomy can reduce the vision loss associated with experimental *B. cereus* endophthalmitis, but only if treatment is begun no later than 4-hour postinfection in this model.

**Biomicroscopy and Histology.** Representative biomicroscopy and histology data are presented in Figure 2. Before vitrectomy, infected eyes at 4-, 5-, and 6-hour postinfection demonstrated mild iritis and mild to moderate vitritis (scores of 1+ to 2+). Conversely, findings from the uninfected eyes were normal.

Immediately after the surgical procedure, these observations were unchanged, except for minimal conjunctival injection caused by speculum placement.

Uninfected eyes treated with vitrectomy and vancomycin demonstrated mild iritis and vitritis (scores of 1+) at 48-hour postinfection. The histology data corroborate this observation, with fibrin and cellular infiltrate seen in the posterior segment and intact retinas. Infected eyes treated with vitrectomy and vancomycin appeared similar to that of the uninfected treated eyes at 4 h, with mild iritis and mild to moderate vitritis (scores of 1+ to 2+). The histology data demonstrated significant infiltrate into the anterior and posterior segments, but retinas remained relatively intact. Vitrectomy/vancomycin treatment at 6 hours resulted in eyes with moderate cell and flare and vitritis (scores of 3+), with the occasional hypopyon. The histology results of the vitrectomy/vancomycin 6-hour treatment directly corroborate these findings. Biomicroscopy and histology of vancomycin-treated eyes at 4-hour and 6-hour postinfection have been reported elsewhere,<sup>14,15</sup> with similarities in biomicroscopy scores and histology findings between the 2 treatment groups at each time point. As with the 6-hour treatment groups, eyes treated with vitrectomy/vancomycin or vancomycin alone at 5-hour postinfection were similar in both the rate of evolution and severity of endophthalmitis signs. These findings were corroborated by histology data.

**Inflammation.** Intraocular inflammation was estimated by counting PMN in harvested aqueous. The results are summarized in Figure 3. Vitrectomy/vancomycin treatment of uninfected eyes resulted in infiltration of PMN detected at 48-hour postsurgery. The numbers of PMN in this group were similar to that in infected eyes treated with vitrectomy/vancomycin at 4-hour postinfection ( $P = 0.22$ ). The numbers of PMN in infected eyes treated with vitrectomy/vancomycin were significantly less than that in infected eyes treated with vancomycin alone at 4-hour postinfection ( $P = 0.02$ ). The numbers of PMN recovered from infected eyes treated at 5-hour or 6-hour postinfection with vitrectomy/vancomycin or vancomycin alone were similar ( $P \geq 0.08$ ). Recall that eyes treated at 5 hours were recovered at 48-hour postinfection, while eyes treated at 6 hours were recovered at 36-hour postinfection. These results further corroborate that either type of treatment after 4-hour postinfection leads to significant inflammation in this model.

**Intraocular Antibiotic Levels**

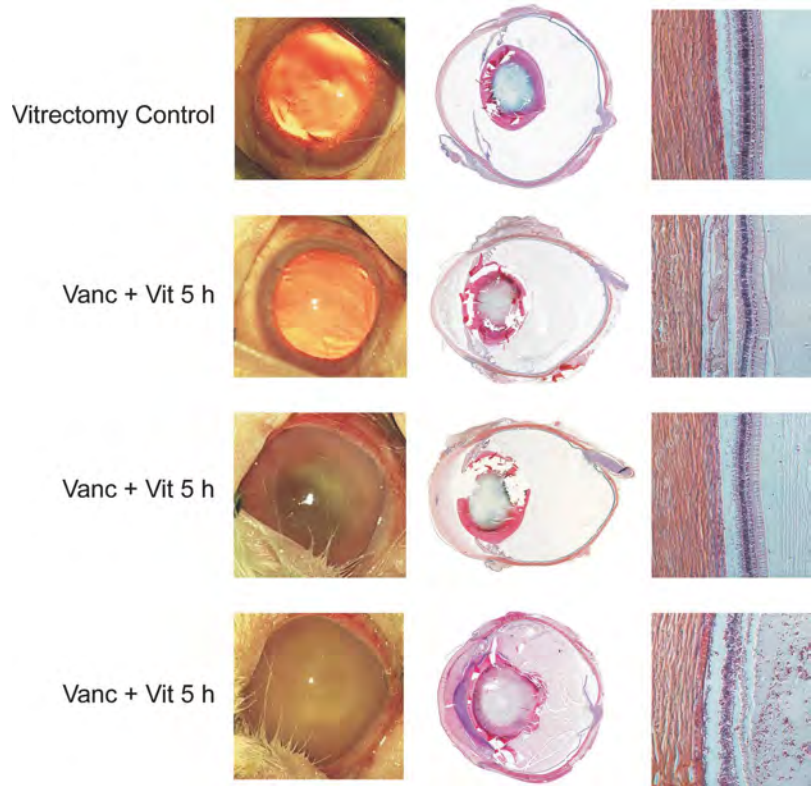
Significant bactericidal levels must be achieved in an infected eye after antibiotic treatment to prevent the

AQ : 6

F3

F2

AQ : 5



**Fig. 2.** Photography and histology of eyes after treatment of experimental *B. cereus* endophthalmitis with vitrectomy and vancomycin (1%) at various times postinfection. The control group included uninfected eyes treated with vitrectomy and vancomycin. Eyes were photographed and then harvested for histology and hematoxylin and eosin staining. Figures are representative of  $n = 3$  eyes per group. Vanc, vancomycin; Vit, vitrectomy. Magnification of retina sections, 100 $\times$ .

C  
O  
L  
O  
R

F4

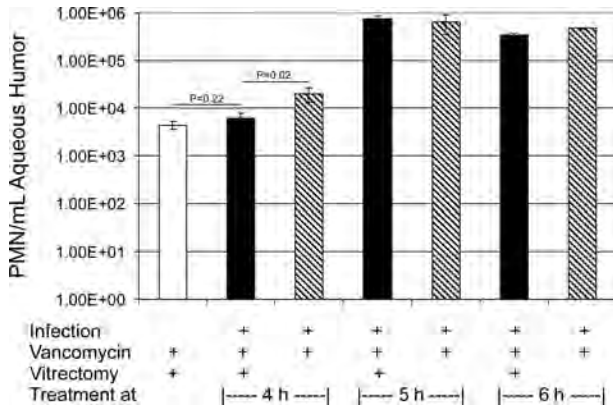
infection from progressing. In vitrectomy-treated infected eyes, intraocular contents were removed and replaced with balanced salt solution containing vancomycin, and vancomycin levels were later quantified (Figure 4). No vancomycin was detected in the aqueous humor at 48-hour postinfection regardless of the time of treatment or whether vitrectomy was involved in the regimen. Vancomycin was detected in the vitreous of infected eyes treated at 4-hour or 5-hour postinfection but not in the vitreous of infected eyes treated at 6-hour postinfection. Although there was a trend toward decreased vancomycin levels in eyes treated at 5-hour postinfection, these values were not significantly different from those after treatment at 4-hour postinfection ( $P \geq 0.08$ ). Vancomycin levels were also similar at these time points regardless of whether vitrectomy was involved in the regimen ( $P \geq 0.3$ ). When vancomycin was detected, these concentrations were well above the minimum inhibitory concentration for this particular *B. cereus* strain.

### Discussion

Vitrectomy is designed to remove potentially harmful contents and pathogens from the inside of

the eye in an effort to minimize inflammation and salvage vision during many types of ocular infections. This study demonstrates the efficacy of vitrectomy and vancomycin over that of vancomycin alone for the salvaging vision and limiting inflammation in experimental *B. cereus* endophthalmitis. However, vitrectomy and vancomycin were more effective than vancomycin alone only when treatment was initiated before 4-hour postinfection. After that time, all treatments were relatively ineffective, resulting in a significant inflammation and vision loss.

In this model, 4-hour postinfection is the critical time within which intravitreal treatment must be initiated to salvage useful vision. *Bacillus cereus* endophthalmitis is unique in its rapid course and invariably devastating outcome. The experimental rabbit model used herein reproducibly mimics that course. *Bacillus cereus* synthesizes multiple toxins in the eye during experimental infection,<sup>22</sup> and we have demonstrated that toxins are involved in vision loss in this disease.<sup>23,24</sup> Which toxins are involved, the kinetics of their synthesis, and the specific activities on the retina are all open questions. However, considering the in vitro and in vivo findings of the importance of quorum sensing to *B. cereus* toxin production and virulence,<sup>24,28-31</sup> one can envision a scenario in which *B. cereus* reaches a threshold

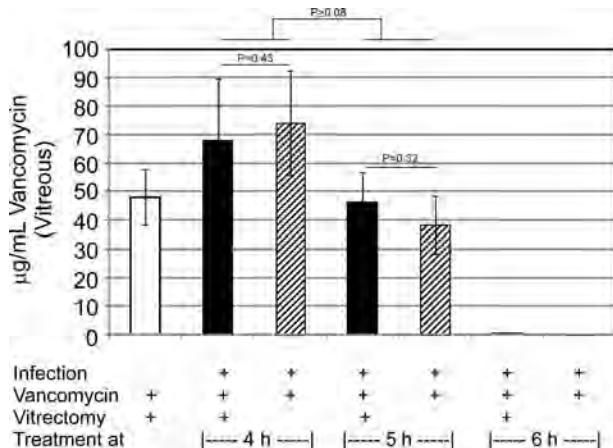


**Fig. 3.** PMN infiltration into the anterior segment after treatment of experimental *B. cereus* endophthalmitis with vitrectomy and vancomycin. PMN were quantified from aqueous humor samples at 48-hour postinfection for eyes treated and 4 hours and 5 hours or at 36-hour postinfection for eyes treated at 6-hour postinfection. The values represent the mean  $\pm$  standard error of the mean of  $n \geq 3$  eyes per group.

AQ : 12

quorum in the eye between 2-hour and 4-hour postinfection, begins to synthesize toxins, affects the retina, and vision loss occurs. Once treatment is begun, the eye is sterilized, toxins are no longer produced, and the retinal damage and vision loss are limited to that already done.

In uninfected control eyes, vitrectomy with vancomycin caused inflammation and retinal function loss. Vitrectomy has been associated with blood-retinal barrier breakdown and other physiologic changes.<sup>32-34</sup> Recently, Inoue et al<sup>13</sup> reported that vitreal protein concentrations decreased from 1 day to 7 days after 20-, 23-, or 25-gauge vitrectomy, indicating that surgically induced inflammation began to resolve within a week in this



**Fig. 4.** Ocular vancomycin concentrations after treatment of experimental *B. cereus* endophthalmitis with vitrectomy and vancomycin. Aqueous and vitreous were harvested at 48-hour postinfection for eyes treated and 4 hours and 5 hours or at 36-hour postinfection for eyes treated at 6-hour postinfection. Vancomycin concentrations were quantified using a standard bioassay. The values represent the mean  $\pm$  standard error of the mean of  $n \geq 3$  eyes per group. Vancomycin was not detected in any aqueous samples, so only vitreous results are shown.

model. Wallentén et al<sup>35</sup> demonstrated significant reductions in retinal function that were detected up to 28 days after vitrectomy. In that study, upregulation of retinal GFAP, an indicator of vitrectomy-related retinal trauma, was also detected in vitrectomy-treated rabbit eyes. The majority of recent studies<sup>36-38</sup> on retinal function after vitrectomy have been short-term toxicity or clearance experiments. Intravitreal injection of phosphate-buffered saline, bacterial media, or vancomycin alone can cause a transient posterior segment inflammation that, in the rabbit eye, resolves within 4 hours (data not shown). Therefore, any changes observed in the uninfected eyes treated with vitrectomy and vancomycin are likely attributed to vitrectomy alone.

AQ : 7

In comparing our results in this study with that of our previous therapeutic studies, we noted that retinal function loss was greater, eyes appeared to be clinically worse, and antibiotic concentrations were less in comparable treatment groups. The difference between this study and the previous two therapeutic studies<sup>14,15</sup> was the animal model. All three studies used New Zealand white rabbits of similar age. Nevertheless, the present study used specific pathogen-free rabbits, while the previous studies used rabbits raised in conventional conditions. Therefore, it is possible that the difference in the pathogenicity and clinical outcome seen in this study lie in the overall immune status of the rabbit. An animal raised in a pathogen-free environment may be more susceptible to infections with organisms that have not previously been encountered and may not be able to quickly mount the degree of immune response needed to fight the infection.<sup>39</sup> This may account for the elevated severity of infection at an earlier time point in the present study compared with our previous studies. Although our results draw clear comparisons among efficacies of the treatment regimens tested, careful interpretation of potential model-to-model variations must be considered when comparing the effectiveness of a particular experimental regimen. Nevertheless, these results reinforces the critical necessity for early antibiotic treatment of *B. cereus* endophthalmitis and indicates that timely vitrectomy in addition to antibiotics may result in a better therapeutic outcome than the use of antibiotics alone.

AQ : 8

**Key words:** Bacillus, infection, eye, vancomycin, vitrectomy.

**Acknowledgments**

The authors acknowledge Mark Dittmar (Dean A. McGee Eye Institute, Oklahoma City, OK) for his assistance in animal husbandry and experiments and Paula Pierce (Excalibur Pathology, Moore, OK) for histology expertise.

## References

1. Callegan MC, Gilmore MS, Gregory M, et al. Bacterial endophthalmitis: therapeutic challenges and host-pathogen interactions. *Prog Retin Eye Res* 2007;26:189–203.
2. Gregory M, Callegan MC, Gilmore MS. Role of bacterial and host factors in infectious endophthalmitis. *Chem Immunol Allergy* 2007;92:266–275.
3. Meredith TA. Posttraumatic endophthalmitis. *Arch Ophthalmol* 1999;117:520–521.
4. Thompson ST, Parver LM, Enger CL, Meiler WF, Liggett PE. Infectious endophthalmitis after penetrating injuries with retained intraocular foreign bodies. *Ophthalmology* 1993;100:1468–1474.
5. Davey RJ, Tauber WB. Posttraumatic endophthalmitis: the emerging role of *Bacillus cereus* infection. *Rev Infect Dis* 1987;9:110–123.
6. David DB, Kirkby GR, Noble BA. *Bacillus cereus* endophthalmitis. *Br J Ophthalmol* 1994;78:577–580.
7. O'Day DM, Smith RS, Gregg CR, et al. The problem of *Bacillus* species infection with special emphasis on the virulence of *Bacillus cereus*. *Ophthalmology* 1981;88:833–838.
8. Callegan MC, Cochran DC, Kane ST, et al. Virulence factor profiles and antimicrobial susceptibilities of ocular *Bacillus* isolates. *Curr Eye Res* 2006;31:693–702.
9. Chhabra S, Kunimoto DY, Kazi L, et al. Endophthalmitis after open globe injury: microbiologic spectrum and susceptibilities of isolates. *Am J Ophthalmol* 2007;142:852–854.
10. Miller JJ, Scott IU, Flynn Jr HW, et al. Endophthalmitis caused by *Bacillus* species. *Am J Ophthalmol* 2008;145:883–888.
11. Fujii GY, De Juan E Jr, Humayun MS, et al. Initial experience using the transconjunctival sutureless vitrectomy system for vitreoretinal surgery. *Ophthalmology* 2002;109:1814–1820.
12. Fine HF, Iranmanesh R, Iturralde D, Spaide RF. Outcomes of 77 consecutive cases of 23-gauge transconjunctival vitrectomy surgery for posterior segment disease. *Ophthalmology* 2007;114:1197–1200.
13. Inoue Y, Kadonosono K, Yamakawa T, et al. Surgically-induced inflammation with 20-, 23-, and 25-gauge vitrectomy systems: an experimental study. *Retina* 2009;29:477–480.
14. Wiskur BJ, Robinson ML, Farrand AJ, Novosad BD, Callegan MC. Toward improving therapeutic regimens for *Bacillus* endophthalmitis. *Invest Ophthalmol Vis Sci* 2008;49:1480–1487.
15. Wiskur BJ, Woods DC, Wheatley NR, Callegan MC. Updates on improvements for therapy of severe bacterial endophthalmitis. *Proc Int Soc Ophth Pharmacol Ther*. In press.
16. Aguilar HE, Meredith TA, Drews C, Grossniklaus H, Sawant AD, Gardner S. Comparative treatment of experimental *Staphylococcus aureus* endophthalmitis. *Am J Ophthalmol* 1996;121:310–317.
17. Liu F, Kwok AK, Cheung BM. The efficacy of intravitreal vancomycin and dexamethasone in the treatment of experimental *Bacillus cereus* endophthalmitis. *Curr Eye Res* 2008;33:761–768.
18. Liu SM, Way T, Rodrigues M, Steidl SM. Effects of intravitreal corticosteroids in the treatment of *Bacillus cereus* endophthalmitis. *Arch Ophthalmol* 2000;118:803–806.
19. Cheng CK, Yang CH, Hsueh PR, Liu CM, Lu HY. Vitrectomy with fluconazole infusion: retinal toxicity, pharmacokinetics, and efficacy in the treatment of experimental candidal endophthalmitis. *J Ocul Pharmacol Ther* 2004;20:430–438.
20. Yang X, Dong XG, Liu AM, Sun SY, Xie LX, Wang SG. A pharmacodynamics study of an intravitreal amphoteribin B drug delivery system for the treatment of experimental *Aspergillus fumigatus* endophthalmitis. *Zhonghua Yan Ke Za Zhi* 2007;43:546–553.
21. Koçak N, Kaynak S, Kirdar S, Irmak O, Bahar IH. Comparison of different antifungal treatment regimens for experimental *Candida* endophthalmitis in rabbit models. *Mikrobiyol Bul* 2009;43:619–626.
22. Pollack JS, Beecher DJ, Pulido JS, Lee Wong AC. Failure of intravitreal dexamethasone to diminish inflammation or retinal toxicity in an experimental model of *Bacillus cereus* endophthalmitis. *Curr Eye Res* 2004;29:253–259.
23. Callegan MC, Kane ST, Cochran DC, Novosad B, Gilmore MS, Gominet M, Lereclus D. *Bacillus* endophthalmitis: roles of bacterial toxins and motility during infection. *Invest Ophthalmol Vis Sci* 2005;46:3233–3238.
24. Callegan MC, Kane ST, Cochran DC, Gilmore MS, Gominet M, Lereclus D. Relationship of *plcR*-regulated factors to *Bacillus* endophthalmitis virulence. *Infect Immun* 2003;71:3116–3124.
25. Callegan MC, Jett BD, Hancock LE, Gilmore MS. Role of hemolysin BL in the pathogenesis of extraintestinal *Bacillus cereus* infection assessed in an endophthalmitis model. *Infect Immun* 1999;67:3357–3366.
26. Callegan MC, Cochran DC, Kane ST, Gilmore MS, Gominet M, Lereclus D. Contribution of membrane-damaging toxins to *Bacillus* endophthalmitis pathogenesis. *Infect Immun* 2002;70:5381–5389.
27. Ramadan RT, Ramirez R, Novosad BD, Callegan MC. Acute inflammation and loss of retinal architecture and function during experimental *Bacillus* endophthalmitis. *Curr Eye Res* 2006;31:955–965.
28. Declerck N, Bouillaut L, Chaix D, et al. Structure of *PlcR*: Insights into virulence regulation and evolution of quorum sensing in gram-positive bacteria. *Proc Natl Acad Sci U S A* 2007;104:18490–18495.
29. Gohar M, Faegri K, Perchat S, et al. The *PlcR* virulence regulon of *Bacillus cereus*. *PLoS One* 2008;3:e2793.
30. Hsueh YH, Somers EB, Lereclus D, Wong AC. Biofilm formation by *Bacillus cereus* is influenced by *PlcR*, a pleiotropic regulator. *Appl Environ Microbiol* 2006;72:5089–5092.
31. Ramarao N, Lereclus D. Adhesion and cytotoxicity of *Bacillus cereus* and *Bacillus thuringiensis* to epithelial cells are *FlhA* and *PlcR* dependent, respectively. *Microbes Infect* 2006;8:1483–1491.
32. Garner WH, Scheib S, Berkowitz BA, et al. The effect of partial vitrectomy on blood-ocular barrier function in the rabbit. *Curr Eye Res* 2001;23:372–381.
33. Stefánsson E. Physiology of vitreous surgery. *Graefes Arch Clin Exp Ophthalmol* 2009;247:147–163.
34. Sparrow JR, Chang S, Vinals AF. Evaluation of the blood-aqueous barrier after vitreous replacement with perfluoropropane gas and liquid silicone. *Retina* 1992;12:370–375.
35. Wallentén KG, Andréasson S, Ghosh F. Retinal function after vitrectomy. *Retina* 2008;28:558–563.
36. Lee SS, Ghosh C, Yu Z, et al. Vitreous VEGF clearance is increased following vitrectomy. *Invest Ophthalmol Vis Sci*. 2009. Epub ahead of print.
37. Shimoda Y, Hamano R, Ishihara K, et al. Effects of intraocular irrigation with melphalan on rabbit retinas during vitrectomy. *Graefes Arch Clin Exp Ophthalmol* 2008;246:501–508.
38. Yamashita T, Sakamoto T, Yamakiri K, et al. Polylactic acid for visualizing the vitreous body during vitrectomy. *Invest Ophthalmol Vis Sci* 2007;48:3277–3282.
39. Gordon HA, Pesti L. The gnotobiotic animal as a tool in the study of host microbial relationships. *Bacteriol Rev* 1971;35:390–429.

AQ : 9

AQ : 10

AQ : 11

EXPERT  
REVIEWS

# Severe bacterial endophthalmitis: towards improving clinical outcomes

*Expert Rev. Ophthalmol.* 5(5), 689–698 (2010)

Billy D Novosad<sup>1</sup> and  
Michelle C Callegan<sup>1,2,3</sup>

<sup>1</sup>Department of Microbiology and Immunology, University of Oklahoma Health Sciences Center, Oklahoma City, OK, USA

<sup>2</sup>Department of Ophthalmology, University of Oklahoma Health Sciences Center, Oklahoma City, OK, USA

<sup>3</sup>Dean A McGee Eye Institute, Oklahoma City, OK, USA

<sup>†</sup>Author for correspondence:

Tel.: +1 405 271 3674

Fax: +1 405 271 8781

michelle-callegan@ouhsc.edu

Endophthalmitis is an infection and inflammation of the interior of the eye that can result in significant vision loss. This infection occurs as a result of the seeding of organisms into the interior of the eye following surgery (postoperative), trauma (post-traumatic) or an infection in another site in the body (endogenous). The general rate of endophthalmitis has remained steady over the past several years. However, the increased use of intraocular injections to treat various degenerative and inflammatory ocular diseases, in addition to the already large and growing number of invasive ocular surgeries, may increase the opportunities in which organisms can gain access to the eye. In most cases of endophthalmitis, useful vision can be retained if proper treatment is instituted. However, in severe cases of bacterial endophthalmitis, blindness often occurs despite treatment. This article summarizes information on endophthalmitis epidemiology, treatment issues and current regimens, and recent experimental and clinical efforts to improve the outcome of severe and blinding forms of bacterial endophthalmitis.

**KEYWORDS:** antibiotics • corticosteroids • endophthalmitis • infection • inflammation • intravitreal therapy • vitrectomy

**Medscape**CME™ Medscape: Continuing Medical Education Online

This activity has been planned and implemented in accordance with the Essential Areas and policies of the Accreditation Council for Continuing Medical Education through the joint sponsorship of Medscape, LLC and Expert Reviews Ltd. Medscape, LLC is accredited by the ACCME to provide continuing medical education for physicians. Medscape, LLC designates this educational activity for a maximum of 0.75 **AMA PRA Category 1 Credits™**. Physicians should only claim credit commensurate with the extent of their participation in the activity. All other clinicians completing this activity will be issued a certificate of participation. To participate in this journal CME activity: (1) review the learning objectives and author disclosures; (2) study the education content; (3) take the post-test and/or complete the evaluation at [www.medscapecme.com/journal/expertophth](http://www.medscapecme.com/journal/expertophth); (4) view/print certificate.

#### Learning objectives

- Describe the clinical characteristics of, risk factors for, and prevention of bacterial endophthalmitis
- Examine the role of varying management strategies, including topical, systemic, and intravitreal antibiotics; anti-inflammatory medications; and vitrectomy, in the management of bacterial endophthalmitis

## Financial & competing interests disclosure

### EDITOR

*Elisa Manzotti*

*Editorial Director, Future Science Group, London, UK.*

*Disclosure: Elisa Manzotti has disclosed no relevant financial relationships.*

### CME AUTHOR

*Laurie Barclay, MD*

*Freelance writer and reviewer, Medscape, LLC.*

*Disclosure: Laurie Barclay has disclosed no relevant financial relationships.*

### AUTHORS AND CREDENTIALS

*Billy D Novosad*

*Departments of Microbiology and Immunology, University of Oklahoma Health Sciences Center, Oklahoma City, Oklahoma, OK, USA.*

*Disclosure: Billy D Novosad has disclosed that portions of the work presented in this article were supported by US Health Service Grants R01EY01985, the Department of Defense Congressionally Directed Medical Research Program (W81XWH-07-1-0280), Allergan Inc., and an unrestricted grant to the Dean A McGee Eye Institute from Research to Prevent Blindness, Inc.*

*Michelle C Callegan*

*Departments of Microbiology and Immunology, and Ophthalmology, University of Oklahoma Health Sciences Center, Oklahoma City, OK, USA; Dean A McGee Eye Institute, Oklahoma City, OK, USA.*

*Disclosure: Michelle C Callegan, PhD, has disclosed that portions of the work presented in this article were supported by US Health Service Grants R01EY01985, the Department of Defense Congressionally Directed Medical Research Program (W81XWH-07-1-0280), Allergan Inc., and an unrestricted grant to the Dean A McGee Eye Institute from Research to Prevent Blindness, Inc.*

## Endophthalmitis: epidemiology & incidence

Endophthalmitis is an infection that occurs as a result of seeding of organisms into the interior of the eye following surgery (post-operative), trauma (post-traumatic) or an infection elsewhere in the body (endogenous). While the general rate of endophthalmitis has remained somewhat constant over the past several years, the increased use of intravitreal injections for the treatment of various degenerative and inflammatory ocular diseases, as well as the growing number of invasive ocular surgeries, may create a clinical environment in which organisms have a greater opportunity to infect the eye. Endophthalmitis cases can be treated successfully if properly managed, and useful vision can be retained. However, in severe cases of bacterial endophthalmitis, significant vision loss can occur rapidly, despite prompt and proper treatment.

During the last two decades, postoperative endophthalmitis rates have risen. The rates of infection after cataract surgery in the 1990s were 0.1% or 1 in 1000, but increased to 0.2% or 1 in 500 surgeries in the early 2000s [1]. Cataract surgery results in more cases of postoperative endophthalmitis than any other type of ocular surgery [1]. The vast majority of postoperative endophthalmitis cases (48–70%) are caused by coagulase-negative staphylococci. Many other Gram-positive bacteria have also been isolated from postoperative endophthalmitis cases, including streptococci, enterococci and *Staphylococcus aureus*. Rates of endophthalmitis following traumatic injury are more common, occurring in 3–17% of ocular traumatic events [2–5]. For post-traumatic endophthalmitis, staphylococci other than coagulase-negative staphylococci are the most common cause, followed by *Bacillus cereus*. *B. cereus* is ten-times more likely to be isolated from cases of post-traumatic endophthalmitis than from cases of endophthalmitis following surgery [6]. Endogenous endophthalmitis (also known as metastatic endophthalmitis) results from spread of the organism into the eye from an infection elsewhere

in the body. Compared with endophthalmitis following trauma or surgery, endogenous endophthalmitis is relatively rare, accounting for only 2–8% of all reported endophthalmitis cases [7–11]. However, endogenous endophthalmitis carries with it the danger of bilateral infection in 15–25% of cases [7]. Fungal organisms account for at least 50% of all endogenous cases, with *Candida albicans* (75–80% of fungal cases) being the leading causative agent [8,9]. Gram-negative organisms cause 32–37% of all endogenous endophthalmitis cases and typically have poor visual outcomes because these infections are difficult to treat [7].

In any type of endophthalmitis, bacteria are introduced into the intraocular environment, encountering a site of immunological inactivity. The intraocular environment is termed an ‘immune-privileged site’, devoid of inflammatory mediators and cells present that would otherwise fight infection [12,13]. In this environment, initial immune responses that would typically handle infection are delayed or absent, providing an optimal growth medium for organisms that reach the area. Eventually, bacteria are recognized and inflammation initiates in an effort to handle the infection. The extent of inflammation in the eye during endophthalmitis has been shown to be organism dependent, with relatively avirulent organisms (e.g., *Staphylococcus epidermidis*) causing mild and treatable inflammation, and virulent toxin-producing pathogens (e.g., *B. cereus*, *S. aureus* or streptococci) causing severe and intractable inflammation [14–16].

## Clinical presentation affects outcome

The course of endophthalmitis, treatment effectiveness and visual outcome can be unpredictable. Clinical presentation of the disease depends, in part, on the relative virulence of the infecting pathogen, the mechanism of introduction into the eye and how quickly treatment is initiated. Other factors that affect the outcome

of infection include the patient's age, how vulnerable the infecting agent is to antibiotic therapy, and the anatomic condition of the eye during infection. Clinical studies have reported that increased time between infection and treatment is associated with a worse visual outcome [7,17–19], but this is not always the case [20]. At presentation, the infecting agent is not typically known, and because treatment must begin immediately, broad-spectrum antibiotics are generally used. Currently, broad-spectrum antibiotic coverage for endophthalmitis includes a two-drug regimen: vancomycin to cover Gram-positive organisms and a third-generation cephalosporin (ceftazidime) to cover Gram-negative organisms. Fluoroquinolones are also considered broad spectrum and readily penetrate the eye, but are at present not considered mainstays for the treatment of endophthalmitis. In addition, the rapid development of fluoroquinolone resistance in ocular isolates may preclude their routine use [21–25].

Regardless of the antibiotic chosen, studies suggest that these drugs must be injected directly into the vitreous for the most direct and effective treatment [24,26,27] because antibiotics may not reach the posterior segment at concentrations great enough or fast enough to be effective when these drugs are administered by systemic, oral or topical routes. The blood–ocular barriers provide a necessary and important obstruction to the penetration of potentially harmful cells, drugs and other toxic substances into the eye, but prevent systemic or topical antibiotics and other useful drugs from reaching the intraocular infection site. Bactericidal antibiotic levels achieved at the site of infection as soon after infection as possible are critical to sterilizing the eye and minimizing intraocular damage and inflammation during severe cases of endophthalmitis.

### Therapeutic limitations: the blood–ocular barrier & drug toxicity

The blood–ocular barrier facilitates maintenance of a sterile environment in the interior of the eye, creating an immune-privileged site [12,13,28–30]. Narrow intercellular tight junctions between endothelial cells and the basement membrane impair paracellular transport of hydrophilic compounds, requiring transport via intracellular routes. Tight junctions of the blood–ocular barrier protect the intraocular space from a myriad of compounds but, as stated earlier, also limit the entrance of potentially helpful systemic antimicrobial and anti-inflammatory drugs. This restrictive environment leaves clinicians with few treatment options, the best being circumvention of the blood–ocular barrier by injection of the drugs directly into the intraocular space. However, intraocular injections carry their own risk of vitreous or subretinal hemorrhaging, retinal toxicity, corneal abrasions, central artery occlusion, uveitis or lens opacification [31–35]. The critical factor for clinicians to assess is whether the potential for significant vision loss from infection outweighs the minimal risk of complications from intravitreal injection of antibiotics that would otherwise quickly sterilize the eye.

Very helpful drugs can sometimes be toxic and damaging to the sensitive structures of the retina [36,37]. The sensitive nature of photoreceptor cells and other retinal cells limits the drugs and concentrations that can be used for treatment [36–38]. Amikacin or low-dose gentamicin at doses of 0.4 mg have been reported to cause macular infarction [36,38]. Owing to the potential toxicity of

aminoglycosides, ceftazidime has been a preferred choice for Gram-negative cases of endophthalmitis due to its lack of toxicity [7,36]. The unique challenges presented by the blood–ocular barrier and the potential for intraocular drug toxicity requires careful consideration in determining the most effective treatment regimens for salvaging vision while reducing treatment risks during endophthalmitis.

### The danger of systemic infections

As stated earlier, endogenous endophthalmitis is relatively rare, comprising only a small percentage of all types of endophthalmitis [9,11]. In the West, the majority of endogenous endophthalmitis cases are fungal in origin, with *Candida* being the primary infecting agent, while *S. aureus* is the most common bacterial cause among several different types of bacteria [8,11,39,40].

Underlying risk factors associated with an immunocompromised state are highly associated with cases of endogenous endophthalmitis, with only a limited number of the cases reported in otherwise healthy individuals [11,41,42]. The risk factors themselves are broad and range from underlying diabetes mellitus to infection with HIV [8,11,39,40,43]. Jackson *et al.* reported that 56% of patients with endogenous bacterial endophthalmitis also had an underlying immunocompromise [7]. Of those immunocompromised patients, many were diabetic. Type 2 diabetes is the most common underlying condition in endogenous endophthalmitis patients, especially those with secondary *Klebsiella pneumoniae* liver abscesses [7]. Prolonged intravenous drug use and immunosuppressive treatment have also been associated with endogenous endophthalmitis cases [7].

Patients with systemic fungemia, specifically candidemia, have a reported mortality rate of 77%, suggesting that the progression of infection into the eye may be a mortality indicator in systemically ill patients with endogenous *Candida* endophthalmitis [44]. Noting the potential for endogenous endophthalmitis in those patients with bacteremia or fungemia is critical in preventing ocular sequelae of systemic infection. In patients with endogenous endophthalmitis, initial ocular changes may not be addressed until a complaint of ocular pain or vision loss, because the systemic infection is the main priority [11,40]. Shankar *et al.* concluded that endogenous endophthalmitis in healthy individuals leads to a poor visual outcome [44]. Okada *et al.* demonstrated that 78% of patients with endogenous endophthalmitis had a final visual acuity of 20/400 or worse [8]. Schiedler *et al.* reported the number of final visual acuities of 20/400 or worse at 50% [11], while Jackson *et al.* reported the number of patients with 20/20 vision after endogenous endophthalmitis at only 5% [7]. Despite improvements in the drugs used for treating such infections, the visual outcome of endogenous endophthalmitis has not improved over the past 55 years [7,45].

### Current treatment regimens for endophthalmitis

#### Antibiotics

As stated earlier, current treatment regimens for bacterial endophthalmitis include direct intravitreal injections of vancomycin (1.0 mg/0.1 ml) and ceftazidime (2.2 mg/0.1 ml) for broad-spectrum coverage of Gram-positive and Gram-negative organisms, respectively. Systemic antibiotics are administered for cases of endogenous endophthalmitis. At present, vancomycin has 99%

susceptibility against all Gram-positive organisms causing endophthalmitis [19,25,46]. Recent reports have emerged regarding endophthalmitis cases caused by vancomycin-resistant *Enterococcus* [47,48]. The potential effectiveness of commonly used antibiotics can be variable owing to the development of resistance. Sensitivities of Gram-negative ocular isolates to ceftazidime, a third-generation cephalosporin, were reported to be 100% [25]. However, Han *et al.* reported a series of Gram-negative endophthalmitis cases in which 89% of patients were successfully treated, but the remaining 11% were infected with Gram-negative bacteria resistant to both amikacin and ceftazidime [49]. Structural improvements made to the cephalosporin drug class have improved the efficacy of these drugs against Gram-negative organisms. Second-generation (cefoxitin, cefamandole, cefotetan) and third-generation (ceftriaxone, ceftazidime, moxolactam) cephalosporins have superior activity against Gram-negative bacteria, but decreased activity against Gram-positive bacteria [50]. Intravitreal ceftazidime has been reported to be safer than aminoglycosides, with toxicity observed only when ceftazidime was administered at high dosages [38,51]. A recent clinical report demonstrated that the risk of endophthalmitis was reduced by 93% when the second-generation cephalosporine cefuroxime was used as an intracameral prophylactic injected prior to surgery [52]. Synergy between antibiotic combinations is important to consider, especially for a rapidly blinding infection such as endophthalmitis. Vancomycin/amikacin and vancomycin/ceftazidime are synergistic in combination. However, Roth and Flynn suggested that synergy in antibiotic combinations may not be as important for endophthalmitis due to the high levels of the individual drugs injected at the site of infection [53].

The fluoroquinolone class of antibiotics shows good potential for the treatment of bacterial endophthalmitis. Third-generation (levofloxacin) and fourth-generation (gatifloxacin, moxifloxacin) fluoroquinolones have enhanced and broad-spectrum activity against most ocular pathogens, especially Gram-positive bacteria. Compared with second- and third-generation fluoroquinolones, the fourth-generation fluoroquinolones have demonstrated high efficacy in killing Gram-positive and -negative organisms [54–56]. Although these drugs exhibit superior killing against common ocular pathogens [57,58], resistance to these antibiotics is on the rise [21–25]. The increased emergence of multidrug-resistant staphylococci or other resistant organisms may eventually increase the frequency of treatment failures.

Fluoroquinolones have been shown to penetrate readily into the eye, making these antibiotics candidates for the treatment of intraocular infections. However, topical prophylactic use of fluoroquinolones for surgery and for potential use in treatment of postoperative endophthalmitis are controversial. Data from clinical and experimental studies on the penetrative ability of the various fluoroquinolones varies widely, owing primarily to differences in dosing schedules. This variation makes drawing solid conclusions difficult. Results vary on the topical dosing regimens necessary to achieve concentrations greater than the MIC<sub>90</sub> for most ocular pathogens [59–61]. Of the fourth-generation fluoroquinolones, moxifloxacin was shown to readily penetrate into the eye after topical administration, resulting in concentrations greater than that of

gatifloxacin [61]. Studies have shown that topical moxifloxacin effectively treated or prevented experimental staphylococcal endophthalmitis [62–64], suggesting that topical moxifloxacin may have reached the interior of the eye at sufficient levels to be effective in these models. As stated earlier, when administered systematically, most antibiotics do not reach clinically acceptable levels in the vitreous because of blood–ocular barrier impermeability. Results also differ as to the efficacy of orally administered fourth-generation fluoroquinolones in delivering adequate bactericidal concentrations to the vitreous [65–67]. Gatifloxacin for systemic use is no longer available due to potential associations with dysglycemia [68].

The ability of fluoroquinolones to cross the blood–ocular barrier without direct intravitreal injection makes these drugs invaluable in the appropriate situations. Fluoroquinolones are most commonly administered as topical drops for ocular surface infections, so their use for endophthalmitis would be considered ‘off-label’. Experimental studies have documented their safety and efficacy in killing intraocular organisms following intravitreal injection [69–74]. Considering these results collectively, intravitreal administration of these and other antibiotics appears to be a very effective choice of treatment for intraocular infections, especially when adequate bactericidal concentrations are needed immediately at the site of infection.

#### **Anti-inflammatory drugs**

Inflammation, typically necessary to clear infections, may cause damage to the retina. Intravitreal administration of bacterial wall components induces significant intraocular inflammation, but only a mild and recoverable loss in retinal function [75–78]. Because the intraocular inflammatory response has the potential to cause collateral intraocular damage, arresting the immune response with intravitreal steroids may serve as an adjunct to antibiotic therapy. Clinical and experimental studies on the value of intravitreal corticosteroids have been controversial and generally conflict on the benefit of these drugs for use in endophthalmitis. Most clinical and experimental reports agree that the corticosteroid dexamethasone is not toxic to the retina when intravitreally injected [72,79–82]. However, clinical reports conflict on whether intravitreal dexamethasone is helpful [82,83] or of little use [84,85] as an adjunct to antibiotic therapy for bacterial endophthalmitis. Experimental results on the effectiveness of intravitreal steroids during bacterial endophthalmitis also vary. Intravitreal dexamethasone/antibiotic combinations have been shown to be effective [86,87] or ineffective [72,88,89] in reducing inflammation during experimental bacterial endophthalmitis. Intravitreal prednisolone/antibiotic combinations were also ineffective in reducing inflammation during experimental *Bacillus* endophthalmitis compared with that of intravitreal antibiotics alone [73]. Although there is a lack of definitive evidence for either position, corticosteroids (i.e., dexamethasone at 0.4 mg) are commonly used in conjunction with antibiotics for the treatment of endophthalmitis.

#### **Vitrectomy**

In severe cases of endophthalmitis, vitrectomy is often used to remove dead bacteria, damaged tissue, the inflammatory milieu and other toxic substances from the interior of the eye. Clearing

the posterior segment facilitates recovery and maintenance of transparency and vitreal diffusion, leading to faster recovery of vision. Microincision vitrectomy surgery, including 23- and 25-gauge vitrectomy, is often described as being minimally invasive. However, since vitrectomy remains a complicated intraocular surgery despite technical improvements, the procedure is not without some risk [90,91].

Vitrectomies became a more acceptable adjunct to endophthalmitis treatment following the Endophthalmitis Vitrectomy Study report demonstrating that endophthalmitis patients with visual light perception experienced a threefold increase in 20/40 vision when vitrectomies were performed [92]. Varying theories exist for the success of vitrectomies in endophthalmitis cases with light perception vision. Results from clinical pars plana vitrectomy studies suggest that this type of surgery may induce blood–ocular barrier breakdown, allowing systemically administered antibiotics to enter more easily [93,94].

Intravitreal antibiotics with immediate vitrectomy have been recommended for post-traumatic endophthalmitis cases with retained intraocular foreign bodies (IOFBs) [19,95]. Early administration of vancomycin and ceftazidime, and prompt vitrectomy to remove the contaminating IOFB, resulted in a 53.5% improvement in vision, while 40% of patients experienced a decrease in vision with the same treatment [19,95]. Prompt vitrectomy has been shown to improve the visual outcome of endophthalmitis following non-cataract ocular surgery and the visual outcome of endophthalmitis following cataract surgery where infections were initially refractory to treatment [96]. For endogenous endophthalmitis, vitrectomy also contributed to improvements in visual outcome, but only when vitrectomy surgery was performed early during infection [97]. The majority of clinical reports agree that vitrectomy performed in conjunction with the proper intravitreal antibiotics should be initiated immediately in severe cases of endophthalmitis. This degree of aggressive therapy is critical to a successful visual outcome, especially in those endophthalmitis cases involving IOFBs.

The majority of recent experimental studies on the benefit of vitrectomy for endophthalmitis have tested the efficacy of vitrectomy in experimental fungal infection models [98,99]. For bacterial endophthalmitis, vitrectomy can be an efficient technique to remove dead organisms, tissue and cellular debris, and damaging toxins and other substances that are not affected by antibiotic or anti-inflammatory drug activity. Newer office-based sutureless vitrectomy systems may prove to be useful, but are not yet indicated for the treatment of endophthalmitis. To date, few experimental studies have analyzed the effectiveness of vitrectomy for the treatment of bacterial endophthalmitis. However, given the need for clarity of the posterior segment in facilitating healing following infection, further studies assessing the benefits of this surgical procedure are warranted.

### Prevention

The most effective therapy for endophthalmitis is prevention. Sterile technique during all phases of surgery is paramount. Care must be taken in preventing contamination at each preparation step during any type of ocular surgery, including preparation of outpatient intravitreal injections. Povidone–iodine preparation of

the eye and the use of proper prophylactic antibiotics and antiseptics is important. New therapies are being investigated for both prophylaxis and treatment. Biodegradable scleral plugs impregnated with antibiotic, antiviral and anti-inflammatory drugs have been tested for extent of sustained drug release *in vitro* [100,101]. The safety and cost–effectiveness of intracameral antibiotics have also been reported, but their penetration into the posterior segment remains an open question [102,103]. The use of antibiotics in the irrigation and infusion fluid is also an option. Careful attention to instituting preventative measures prior to surgery is important in reducing the potential for infection.

### Summary

Endophthalmitis can be a rapidly blinding complication of ocular surgery, trauma to the eye or systemic infection. In reviewing and comparing results from various clinical and experimental reports regarding the efficacies of different endophthalmitis therapeutic regimens, it is clear that no single universal therapy exists that is highly effective for all cases of bacterial endophthalmitis. Variables involved in the nature of the pathogen itself, routes of entry into the eye and underlying medical conditions greatly confound the situation, resulting in severe cases of bacterial endophthalmitis that are difficult to manage and refractory to treatment. Variables in dosing regimens in humans and different animal models also prevent solid conclusions from being drawn regarding the best treatment regimens for this disease. However, rapid diagnosis and treatment is critical, even though identification by culture may not be immediately available. Identification of the more virulent organisms is preferable to identify pathogens capable of rapidly destroying the eye. Intravitreal antimicrobial therapy is a preferred route in terms of delivering high levels of the appropriate drugs directly to the site of infection. The use of anti-inflammatory agents remains controversial. Vitrectomy, implemented as an adjunct in moderate or severe cases, effectively clears the vitreous of toxic and inflammatory substances. Intravitreal injections and vitrectomy are not without risk, however, and their use must be carefully considered in light of the potential for significant vision loss if these regimens are not used. The key to successful therapy for endophthalmitis is rapid sterilization of the posterior segment and arrest of potentially harmful inflammation, while concurrently limiting risks associated with penetration of the eye by injections or surgery. Future design of better and/or novel therapeutic regimens that achieve these goals is critical to successfully combating this blinding disease.

### Expert commentary

A review of the current state of endophthalmitis therapy and management indicates that, while most cases of endophthalmitis are successfully treated, those cases that are refractory typically result in significant vision loss. The difficulty in devising a successful universal therapeutic strategy for endophthalmitis lies in the variations in conditions during which these infections occur. Translating the results of experimental studies to improving therapeutic regimens in the clinical setting is also difficult owing to the absence of variations that may not always be included in experimental models. In the context of bacterial endophthalmitis, intravitreal

administration of antibiotics can sterilize the eye. The effectiveness of anti-inflammatory drugs in arresting inflammation during endophthalmitis remains an open question. Neither of these types of drugs target toxic factors synthesized by the organism; factors that can irreversibly damage fragile retinal tissue. Vitrectomy is the only current therapy to approach the elimination of toxic factors, theoretically removing all vitreal contents in order to clear the infection and begin the healing process. It is clear from experimental and clinical studies that instillation of potent antibiotics into the eye as soon after infection as possible is the best strategy, but this must be evaluated by clinicians in terms of the risks involved with intravitreal injections.

### Five-year view

Although potent broad-spectrum antibiotics are available for the treatment of ocular surface infections, the use of these antibiotics is more critical for endophthalmitis because of the potential for rapid and irreversible vision loss once these infections commence. Improvements in therapeutic outcome of endophthalmitis will depend upon faster identification of the infection itself and rapid and aggressive intervention. Diligence in proper training and prevention of contamination in the ocular surgery setting will decrease the number of postoperative cases, as will the use of intravitreal antibiotics upon presentation of post-traumatic injuries that may include contamination of the posterior segment.

### Key issues

- Bacterial endophthalmitis is an infection and inflammation of the posterior segment of the eye that can rapidly evolve into a sight-threatening situation.
- During endophthalmitis, bacteria enter the posterior segment following trauma, surgery or from spread into the eye through the bloodstream from a distant focus of infection.
- Most topical and systemic antibiotics cannot penetrate into the eye fast enough or in high enough concentrations to be effective during endophthalmitis.
- Intravitreal administration of antibiotics ensures delivery of high concentrations directly at the site of infection.
- Experimental and clinical studies disagree on the effectiveness of anti-inflammatory drugs in affecting inflammation during endophthalmitis.
- Vitrectomy removes vitreal contents which, during endophthalmitis, may include bacteria, bacterial products, inflammatory cells and other toxic factors that may damage the retina.
- Improvements in the clinical outcome of endophthalmitis depend largely upon faster identification of the infection, and rapid and aggressive intervention.
- Prevention of contamination in the surgical setting will decrease the number of postoperative cases of endophthalmitis.

### References

Papers of special note have been highlighted as:

- of interest

- West ES, Behrens A, McDonnell PJ, Tielsch JM, Schein OD. The incidence of endophthalmitis after cataract surgery among the US Medicare population increased between 1994 and 2001. *Ophthalmology* 112, 1388–1394 (2005).
- Jonas JB, Knorr HL, Budde WM. Prognostic factors in ocular injuries caused by intraocular or retrobulbar foreign bodies. *Ophthalmology* 107, 823–828 (2000).
- Meredith TA. Posttraumatic endophthalmitis. *Arch. Ophthalmol.* 117, 520–521 (1999).
- O'Brien TP, Choi S. Trauma-related ocular infections. *Int. Ophthalmol. Clin. N. Am.* 8, 667–679 (1995).
- Thompson ST, Parver LM, Enger CL, Meiler WF, Liggett PE. Infectious endophthalmitis after penetrating injuries with retained intraocular foreign bodies. *Ophthalmology* 100, 1468–1474 (1993).
- Das T, Kunimoto DY, Sharma S *et al.* Relationship between clinical presentation and visual outcome in postoperative and posttraumatic endophthalmitis in south central India. *Ind. J. Ophthalmol.* 53, 5–16 (2005).
- Jackson TL, Eykyn SJ, Graham EM, Stanford MR. Endogenous bacterial endophthalmitis: a 17-year prospective series and review of 267 reported cases. *Surv. Ophthalmol.* 48, 403–423 (2003).
- **Comprehensive review of endogenous bacterial endophthalmitis.**
- Okada AA, Johnson RP, Liles WC, D'Amico DJ, Baker AS. Endogenous bacterial endophthalmitis, report of a 10-year retrospective study. *Ophthalmology* 101, 832–838 (1994).
- Romero CF, Rai MK, Lowder CY, Adal KA. Endogenous endophthalmitis: case report and brief review. *Am. Fam. Phys.* 60, 510–514 (1999).
- Bohigian GM, Olk RJ. Factors associated with a poor visual result in endophthalmitis. *Am. J. Ophthalmol.* 101, 332–334 (1986).
- Schiedler V, Scott I, Flynn HW, Janet DL, Benz MS, Miller D. Culture-proven endogenous endophthalmitis clinical features and visual outcomes. *Am. J. Ophthalmol.* 137, 725–731 (2004).
- Medawar P. Immunity to homologous grafted skin. III. The fate of skin homografts transplanted to the brain to subcutaneous tissue, and to the anterior chamber of the eye. *Br. J. Exp. Pathol.* 29, 58–69 (1948).
- Taylor AW. Ocular immune privilege. *Eye* 23, 1885–1889 (2009).
- **Updated review on ocular immune privilege.**
- Aaberg TM, Flynn HW, Schiffman J, Newton J. Nosocomial acute-onset postoperative endophthalmitis survey. A 10-year review of incidence and outcomes. *Ophthalmology* 105, 1004–1010 (1998).
- Josephberg RG. Endophthalmitis: the latest in current management. *Retina* 26, S47–S50 (2006).

- 16 Ng JQ, Morlet N, Pearman JW *et al.* Management and outcomes of postoperative endophthalmitis since the endophthalmitis vitrectomy study: the Endophthalmitis Population Study of Western Australia (EPSWA)'s fifth report. *Ophthalmology* 112, 1199–1206 (2005).
- 17 Takebayashi H, Mizota A, Tanaka M. Relation between stage of endogenous fungal endophthalmitis and prognosis. *Graefes Arch. Clin. Exp. Ophthalmol.* 244, 816–820 (2006).
- 18 Al-Orman AM, Abboud EB, Abu El-Asrar AM. Microbiologic spectrum and visual outcome of posttraumatic endophthalmitis. *Retina* 27, 236–242 (2007).
- **Comprehensive review of post-traumatic endophthalmitis.**
- 19 Abu El-Asrar AM, Al-Amro SA, Al-Mosallam AA, Al-Obeidan S. Post-traumatic endophthalmitis: causative organisms and visual outcomes. *Eur. J. Ophthalmol.* 9, 21–31 (1999).
- 20 Leng T, Flynn HW, Miller D, Murray TG, Smiddy WE. Endophthalmitis caused by proteus species: antibiotic sensitivities and visual outcomes. *Retina* 29, 1019–1024 (2009).
- 21 Benz MS, Scott IU, Flynn HW Jr, Unonius N, Miller D. Endophthalmitis isolates and antibiotic sensitivities: a 6-year review of culture-proven cases. *Am. J. Ophthalmol.* 137, 38–42 (2004).
- 22 Bertino JS. Impact of antibiotic resistance in the management of ocular infections: the role of current and future antibiotics. *Clin. Ophthalmol.* 3, 507–521 (2009).
- 23 Miller D, Flynn PM, Scott IU, Alfonso EC, Flynn HW Jr. *In vitro* fluoroquinolone resistance in staphylococcal endophthalmitis isolates. *Arch. Ophthalmol.* 124, 479–483 (2006).
- 24 Busbee BG. Endophthalmitis: a reprisal of incidence and treatment. *Curr. Opin. Ophthalmol.* 17, 286–291 (2006).
- 25 Recchia FM, Busbee BG, Pearlman RB, Carvalho-Recchia CA, Ho AC. Changing trends in the microbiologic aspects of postcataract endophthalmitis. *Arch. Ophthalmol.* 123, 341–346 (2005).
- 26 Baum J, Peyman GA, Barza M. Intravitreal administration of antibiotic in the treatment of bacterial endophthalmitis. III. Consensus. *Surv. Ophthalmol.* 26, 204–206 (1982).
- 27 Knox FA, Best RM, Kinsella F *et al.* Management of endophthalmitis with retained intraocular foreign body. *Eye* 18, 179–182 (2004).
- 28 Cunha-Vaz JG. The blood–ocular barrier. Past, present, and future. *Doc. Ophthalmol.* 93, 149–157 (1997).
- 29 Cunha-Vaz JG. The blood–retinal barriers system. Basic concept and clinical evaluation. *Exp. Eye Res.* 78, 715–721 (2004).
- 30 Niederkorn JY, Stein-Streilein J. History and physiology of immune privilege. *Ocul. Immunol. Inflamm.* 18, 19–23 (2010).
- **Updated review on ocular immune privilege.**
- 31 Moshfeghi AA, Scott IU, Flynn HW Jr, Puliafito CA. Pseudohypopyon after intravitreal triamcinolone acetonide injection for cystoid macular edema. *Am. J. Ophthalmol.* 138, 489–492 (2004).
- 32 Moshfeghi DM, Kaiser PK, Bakri SJ *et al.* Presumed sterile endophthalmitis following intravitreal triamcinolone acetonide injection. *Ophthalmic Surg. Lasers Imaging* 36, 24–29 (2005).
- 33 Martidis A, Duker JS, Greenberg PB *et al.* Intravitreal triamcinolone for refractory diabetic macular edema. *Ophthalmology* 109, 920–927 (2002).
- 34 Antcliff RJ, Spalton DJ, Stanford MR, Graham EM, Pfyfche TJ, Marshall J. Intravitreal triamcinolone for uveitic cystoid macular edema: an optical coherence tomography study. *Ophthalmology* 108, 765–772 (2001).
- 35 Young S, Larkin G, Branley M, Lightman S. Safety and efficacy of intravitreal triamcinolone for cystoid macular oedema in uveitis. *Clin. Exp. Ophthalmol.* 29, 2–6 (2001).
- 36 Campochiaro PA, Lim JJ. Aminoglycoside toxicity in the treatment of endophthalmitis. *Arch. Ophthalmol.* 112, 48–53 (1994).
- 37 Libert J. Toxicity of intravitreal injections of antibiotics and antivirals. *Bull. Soc. Belge Ophthalmol.* 304, 89–97 (2007).
- 38 Thomas T, Galiani D, Brod RD. Gentamicin and other antibiotic toxicity. *Ophthalmol. Clin. North Am.* 14, 611–624 (2001).
- 39 Essman TF, Flynn WH Jr, Smiddy WE *et al.* Treatment outcomes in a 10-year study of endogenous fungal endophthalmitis. *Ophthalmic Surg. Lasers* 28, 185–194 (1997).
- 40 Binder MI, Chua J, Kaiser PK, Procap GW, Isada CM. Endogenous endophthalmitis, an 18-year review of culture-positive cases at a tertiary care center. *Medicine* 82, 97–105 (2003).
- 41 Kostick DA, Foster RE, Lowder CY, Meyers SM, McHenry MC. Endogenous endophthalmitis caused by *Candida albicans* in a healthy woman. *Am. J. Ophthalmol.* 113, 593–595 (1992).
- 42 Shankar K, Gyanendra L, Hari S, Dev Narayan S. Culture proven endogenous endophthalmitis in apparently healthy individuals. *Ocular Immun. Inflamm.* 17, 396–399 (2009).
- 43 Flynn HW Jr, Brod RD, Han DP, Miller D. Endophthalmitis: diagnosis, treatment, prevention. In: *Ophthalmic Surgery, Principles and Practice (3rd edition)*. Spaeth GL (Ed.). WB Saunders, PA, USA, 663–677 (2003).
- 44 Menezes AV, Sigismund DA, Demajo WA, Devenyi RG. Mortality of hospitalized patients with *Candida* endophthalmitis. *Arch. Intern. Med.* 154, 2093–2097 (1994).
- 45 Smith SR, Kroll AJ, Lou PL, Ryan EA. Endogenous bacterial and fungal endophthalmitis. *Int. Ophthalmol. Clin.* 47, 173–183 (2007).
- 46 Fan JC, Niederer RL, Von Lany H, Polkinghorne PJ. Infectious endophthalmitis: clinical features, management and visual outcomes. *Clin. Exp. Ophthalmol.* 36, 631–636 (2008).
- 47 Bains HS, Weinberg DV, Feder RS, Noskin GA. Postoperative vancomycin-resistant *Enterococcus faecium* endophthalmitis. *Arch. Ophthalmol.* 125, 1292–1293 (2007).
- 48 Esmaeli B, Holtz ER, Ahmadi MA, Krathen RA, Raad II. Endogenous endophthalmitis secondary to vancomycin-resistant enterococci infection. *Retina* 23, 118–119 (2003).
- 49 Han DP, Wisniewski SR, Wilson LA *et al.* Spectrum and susceptibilities of microbiologic isolates in the Endophthalmitis Vitrectomy Study. *Am. J. Ophthalmol.* 122, 1–17 (1996).
- 50 Peyman GA, Lad EM, Moshfeghi DM. Intravitreal injection of therapeutic agents. *Retina* 29, 875–912 (2009).
- 51 Lemley CA, Han DP. Endophthalmitis: a review of current evaluation and management. *Retina* 27, 662–680 (2007).
- 52 García-Sáenz MC, Arias-Puente A, Rodríguez-Caravaca G, Bañuelos JB. Effectiveness of intracameral cefuroxime in preventing endophthalmitis after cataract surgery. *J. Cataract Refract. Surg.* 36, 203–207 (2010).

- 53 Roth DB, Flynn HW. Antibiotic selection in the treatment of endophthalmitis: the significance of drug combinations and synergy. *Surv. Ophthalmol.* 41, 395–401 (1997).
- 54 Mather R, Karenchak LM, Romanowski EG, Kowalski RP. Fourth generation fluoroquinolones: new ophthalmic antibiotics. 133, 463–466 (2002).
- 55 Reddy AK, Garg P, Alam MR, Gopinathan U, Sharma S, Krishniah S. Comparison of *in vitro* susceptibilities from ocular infections against the second and fourth generation quinolones at a tertiary eye care centre in South India. *Eye* 24, 170–174 (2010).
- 56 Scoper SV. Review of third- and fourth-generation fluoroquinolones in ophthalmology: *in vitro* and *in vivo* efficacy. *Adv. Ther.* 25, 979–994 (2008).
- **Review of ophthalmic fluoroquinolones.**
- 57 Callegan MC, Ramirez R, Kane ST, Cochran DC, Jensen H. Antibacterial activity of the fourth-generation fluoroquinolones gatifloxacin and moxifloxacin against ocular pathogens. *Adv. Ther.* 20, 246–252 (2003).
- 58 Callegan MC, Novosad BD, Ramadan RT, Wiskur B, Moyer AL. Rate of bacterial eradication by ophthalmic solutions of fourth-generation fluoroquinolones. *Adv. Ther.* 26, 447–454 (2009).
- 59 Lai WW, Chu KO, Chan KP *et al.* Differential aqueous and vitreous concentrations of moxifloxacin and ofloxacin after topical administration one hour before vitrectomy. *Am. J. Ophthalmol.* 144, 315–318 (2007).
- 60 Costello P, Bakri S, Beer P *et al.* Vitreous penetration of topical moxifloxacin and gatifloxacin in humans. *Retina* 26, 191–195 (2006).
- 61 McCulley JP, Caudle D, Aronowicz JD, Shine WE. Fourth-generation fluoroquinolone penetration into the aqueous humor in humans. *Ophthalmology* 113, 955–959 (2006).
- 62 Kowalski RP, Romanowski EG, Mah FS, Sasaki H, Fukuda M, Gordon YJ. A comparison of moxifloxacin and levofloxacin topical prophylaxis in a fluoroquinolone-resistant *Staphylococcus aureus* rabbit model. *Jpn. J. Ophthalmol.* 52, 211–216 (2008).
- 63 Kowalski RP, Romanowski EG, Mah FS, Yates KA, Gordon YJ. Topical 0.5% moxifloxacin prevents endophthalmitis in an intravitreal injection rabbit model. *J. Ocul. Pharmacol. Ther.* 24, 1–7 (2008).
- 64 Kowalski RP, Romanowski EG, Mah FS, Yates KA, Gordon YJ. Topical prophylaxis with moxifloxacin prevents endophthalmitis in a rabbit model. *Am. J. Ophthalmol.* 138, 33–37 (2004).
- 65 Vedantham V, Lalitha P, Velpandian T, Ghose S, Mahalakshmi R, Ramasamy K. Vitreous and aqueous penetration of orally administered moxifloxacin in humans. *Eye* 20, 1273–1278 (2006).
- 66 Hariprasad SM, Mieler WF, Holz ER. Vitreous and aqueous penetration of orally administered gatifloxacin in humans. *Arch. Ophthalmol.* 121, 345–350 (2004).
- 67 Hariprasad SM, Shah GK, Mieler WF *et al.* Vitreous and aqueous penetration of orally administered moxifloxacin in humans. *Arch. Ophthalmol.* 124, 178–182 (2006).
- 68 Park-Wyllie LY, Juurlink DM, Kopp A *et al.* Outpatient gatifloxacin therapy and dysglycemia in older adults. *N. Engl. J. Med.* 354, 1352–1361 (2006).
- 69 Kazi AA, Jermak CM, Peyman GA, Aydin E, Riazi-Esfahani M. Intravitreal toxicity of levofloxacin and gatifloxacin. *Ophthalmic Surg. Lasers Imaging* 37, 224–229 (2006).
- 70 Aydin E, Kazi AA, Peyman GA, Esfahani MR. Intravitreal toxicity of moxifloxacin. *Retina* 26, 187–190 (2006).
- 71 Gao H, Pennesi ME, Qiao X *et al.* Intravitreal moxifloxacin: retinal safety study with electroretinography and histopathology in animal models. *Invest. Ophthalmol. Vis. Sci.* 47, 1606–1611 (2006).
- 72 Wiskur BJ, Robinson ML, Farrand AJ, Novosad BD, Callegan MC. Toward improving therapeutic regimens for *Bacillus* endophthalmitis. *Invest. Ophthalmol. Vis. Sci.* 49, 1480–1487 (2008).
- 73 Wiskur BJ, Woods DC, Wheatley NR, Callegan MC. Update on improvements for therapy of severe bacterial endophthalmitis. Presented at: *8th International Symposium on Ocular Pharmacology and Therapeutics, 2009.* 25–37. Rome, Italy, 3–6 December 2009.
- 74 Ermis SS, Cetinkaya Z, Kiyici H, Inan UU, Ozturk F. Effects of intravitreal moxifloxacin and dexamethasone in experimental *Staphylococcus aureus* endophthalmitis. *Curr. Eye Res.* 32, 337–344 (2007).
- 75 Callegan MC, Booth MC, Jett BD, Gilmore MS. Pathogenesis of Gram-positive bacterial endophthalmitis. *Infect. Immun.* 67, 3348–3356 (1999).
- 76 Callegan MC, Engelbert M, Parke DW 2nd, Jett BD, Gilmore MS. Bacterial endophthalmitis: epidemiology, therapeutics, and bacterium–host interactions. *Clin. Microbiol. Rev.* 15, 111–124 (2002).
- 77 Fox A, Hammer ME, Lill P, Burch TG, Burrish G. Experimental uveitis. Elicited by peptidoglycan–polysaccharide complexes, lipopolysaccharide, and muramyl dipeptide. *Arch. Ophthalmol.* 102, 1063–1067 (1984).
- 78 Kufoy EA, Fox K, Fox A, Parks C, Pakalnis VA. Modulation of the blood–aqueous barrier by Gram positive and Gram negative bacterial cell wall components in the rat and rabbit. *Exp. Eye Res.* 50, 189–195 (1990).
- 79 Hida T, Chandler C, Arena JE, Machemer R. Experimental and clinical observations of the intraocular toxicity of commercial corticosteroid preparations. *Am. J. Ophthalmol.* 101, 190–195 (1986).
- 80 Peyman G, Schulman J. *Intravitreal Surgery: Principles and Practice (2nd Edition)*. Appleton & Lange, CT, USA (1994).
- 81 Graham RO, Peyman GA. Intravitreal injection of dexamethasone. Treatment of experimentally induced endophthalmitis. *Arch. Ophthalmol.* 92, 149–154 (1974).
- 82 Gan IM, Ugahary LC, van Dissel JT *et al.* Intravitreal dexamethasone as adjuvant in the treatment of postoperative endophthalmitis: a prospective randomized trial. *Graefes Arch. Clin. Exp. Ophthalmol.* 243, 1200–1205 (2005).
- 83 Das T, Jalali S, Gothwal VK, Sharma S, Naduvilath TJ. Intravitreal dexamethasone in exogenous bacterial endophthalmitis: results of a prospective randomised study. *Br. J. Ophthalmol.* 83, 1050–1055 (1999).
- 84 Hall EF, Scott GR, Musch DC, Zacks DN. Adjunctive intravitreal dexamethasone in the treatment of acute endophthalmitis following cataract surgery. *Clin. Ophthalmol.* 2, 139–145 (2008).
- 85 Shah GK, Stein JD, Sharma S *et al.* Visual outcomes following the use of intravitreal steroids in the treatment of postoperative endophthalmitis. *Ophthalmology* 107, 486–489.
- 86 De Kaspar HM, Ta CN, Engelbert M, Mette M, Thiel M, Kampik A. Effects of intravitreal corticosteroid in the treatment of *Staphylococcus aureus*-induced experimental endophthalmitis. *Retina* 28, 326–332 (2008).

- 87 Liu SM, Way T, Rodrigues M, Steidl SM. Effects of intravitreal corticosteroids in the treatment of *Bacillus cereus* endophthalmitis. *Arch. Ophthalmol.* 118, 803–806 (2000).
- 88 Ermis SS, Cetinkaya Z, Kiyici H, Ozturk F. Treatment of *Staphylococcus epidermidis* endophthalmitis with intravitreal moxifloxacin in a rabbit model, Tohoku. *J. Exp. Med.* 205, 223–229 (2005).
- 89 Pollack JS, Beecher DJ, Pulido JS, Wong ACL. Failure of intravitreal dexamethasone to diminish inflammation or retinal toxicity in an experimental model of *Bacillus cereus* endophthalmitis. *Curr. Eye Res.* 29, 253–259 (2004).
- 90 Fujii GY, De Juan E Jr, Humayun MS *et al.* Initial experience using the transconjunctival sutureless vitrectomy system for vitreoretinal surgery. *Ophthalmology* 109, 1814–1820 (2002).
- 91 Fine HF, Iranmanesh R, Iturralde D, Spaid RF. Outcomes of 77 consecutive cases of 23-gauge transconjunctival vitrectomy surgery for posterior segment disease. *Ophthalmology* 114, 1197–1200 (2007).
- 92 Endophthalmitis Vitrectomy Study Group. Results of the Endophthalmitis Vitrectomy Study. A randomized trial of immediate vitrectomy and of intravenous antibiotics for the treatment of postoperative bacterial endophthalmitis. *Arch. Ophthalmol.* 113, 1479–1496 (1995).
- 93 Garner WH, Scheib S, Berkowitz BA, Suzuki M, Wilson CA, Graff G. The effect of partial vitrectomy on blood–ocular barrier function in the rabbit. *Curr. Eye Res.* 23, 372–381 (2001).
- 94 Sakamoto T, Miyazaki M, Hisatomi T *et al.* Triamcinolone-assisted pars plana vitrectomy improves the surgical procedures and decreases the postoperative blood–ocular barrier breakdown. *Graefes Arch. Clin. Exp. Ophthalmol.* 240, 423–429 (2002).
- 95 Yang CS, Lu CK, Lee FL, Hsu WM, Lee YF, Lee SM. Treatment and outcome of traumatic endophthalmitis in open globe injury with retained intraocular foreign body. *Ophthalmologica* 224, 79–85 (2010).
- 96 Maguire JI. Postoperative endophthalmitis: optimal management and the role and timing of vitrectomy surgery. *Eye* 22, 1290–1300 (2008).
- **Discusses the value of vitrectomy for postoperative endophthalmitis.**
- 97 Yoon YH, Lee SU, Sohn JH, Lee SE. Result of early vitrectomy for endogenous *Klebsiella pneumoniae* endophthalmitis. *Retina* 23, 366–370 (2003).
- 98 Cheng CK, Yang CH, Hsueh PR, Liu CM, Lu HY. Vitrectomy with fluconazole infusion: retinal toxicity, pharmacokinetics and efficacy in the treatment of experimental *Candida* endophthalmitis. *J. Ocul. Pharmacol. Ther.* 20, 430–438 (2004).
- 99 Kocak N, Kaynak S, Kirdar S, Irmak O, Bahar IH. [Comparison of different antifungal treatment regimens for experimental *Candida* endophthalmitis in rabbit models.] *Mikrobiyol Bul.* 43, 619–626 (2009).
- 100 Liu SJ, Kau YC, Liaw CW, Peng YJ. *In vitro* elution of vancomycin/amikacin/steroid from solvent-free biodegradable scleral plugs. *Int. J. Pharm.* 370, 75–80 (2009).
- 101 Peng YJ, Wen CW, Chiou SH, Liu SJ. Sustained release of ganciclovir and foscarnet from biodegradable scleral plugs for the treatment of cytomegalovirus retinitis. *Biomaterials* 31, 1773–1779 (2010).
- 102 Choi JA, Chung SK. Safety of intracameral injection of gatifloxacin, levofloxacin on corneal endothelial structure and viability. *J. Ocul. Pharmacol. Ther.* 25, 425–431 (2009).
- 103 Sharifi E, Porco TC, Naseri A. Cost–effectiveness analysis of intracameral cefuroxime use for prophylaxis of endophthalmitis after cataract surgery. *Ophthalmology* 116, 1887–1896 (2009).

## Medscape CME™ Severe bacterial endophthalmitis: towards improving clinical outcomes

To obtain credit, you should first read the journal article. After reading the article, you should be able to answer the following, related, multiple-choice questions. To complete the questions and earn continuing medical education (CME) credit, please go to [www.medscapecme.com/journal/expertophth](http://www.medscapecme.com/journal/expertophth). Credit cannot be obtained for tests completed on paper, although you may use the worksheet below to keep a record of your answers. You must be a registered user on Medscape.com. If you are not registered on Medscape.com, please click on the New Users: Free Registration link on the left hand side of the website to register. Only one answer is correct for each question. Once you successfully answer all post-test questions you will be able to view and/or print your certificate. For questions regarding the content of this activity, contact the accredited provider, [CME@medscape.net](mailto:CME@medscape.net). For technical assistance, contact [CME@webmd.net](mailto:CME@webmd.net). American Medical Association's Physician's Recognition Award (AMA PRA) credits are accepted in the US as evidence of participation in CME activities. For further information on this award, please refer to [www.ama-assn.org/ama/pub/category/2922.html](http://www.ama-assn.org/ama/pub/category/2922.html). The AMA has determined that physicians not licensed in the

US who participate in this CME activity are eligible for AMA PRA Category 1 Credits™. Through agreements that the AMA has made with agencies in some countries, AMA PRA credit is acceptable as evidence of participation in CME activities. If you are not licensed in the US and want to obtain an AMA PRA CME credit, please complete the questions online, print the certificate and present it to your national medical association.

### Activity Evaluation

Where 1 is strongly disagree and 5 is strongly agree

	1	2	3	4	5
1. The activity supported the learning objectives.					
2. The material was organized clearly for learning to occur.					
3. The content learned from this activity will impact my practice.					
4. The activity was presented objectively and free of commercial bias.					

1. A 72-year-old, black woman developed bacterial endophthalmitis following cataract surgery. Which of the following statements about her condition is most likely correct?

- A Bacterial endophthalmitis is an infection of the anterior segment of the eye
- B Bacterial endophthalmitis almost never causes irreversible vision loss
- C Eye surgery is not a known risk factor for bacterial endophthalmitis
- D Prevention of contamination in the surgical setting should help reduce the number of postoperative cases of endophthalmitis

2. Which of the following statements about the role of topical and systemic antibiotics and anti-inflammatory drugs is most likely to apply to the management of the above-described patient?

- A In most cases of endophthalmitis, useful vision can be retained if proper treatment is started quickly
- B Topical or systemic antibiotics are usually effective
- C Anti-inflammatory drugs are definitely indicated
- D Fluoroquinolones are the mainstay of treatment

3. Which of the following statements about the use of intravitreal antibiotics and vitrectomy is most likely to apply to the management of the patient?

- A Intravitreal injection of antibiotics ensures delivery of high concentrations directly at the site of infection
- B Experimental studies have suggested that immediate vitrectomy is the best approach
- C Removing vitreal contents may impede healing of bacterial endophthalmitis
- D Intravitreal injection and vitrectomy have no known risks