

AWARD NUMBER: W81XWH-10-1-0888

TITLE: Enhanced Healing of Segmental Bone Defects by Modulation of the Mechanical Environment

PRINCIPAL INVESTIGATOR: Christopher H. Evans

CONTRACTING ORGANIZATION: Beth Israel Deaconess Medical Center
Boston, MA 02215

REPORT DATE: October 2013

TYPE OF REPORT: Final

PREPARED FOR: U.S. Army Medical Research and Materiel Command
Fort Detrick, Maryland 21702-5012

DISTRIBUTION STATEMENT: Approved for Public Release;
Distribution Unlimited

The views, opinions and/or findings contained in this report are those of the author(s) and should not be construed as an official Department of the Army position, policy or decision unless so designated by other documentation.

REPORT DOCUMENTATION PAGE			<i>Form Approved</i> <i>OMB No. 0704-0188</i>		
Public reporting burden for this collection of information is estimated to average 1 hour per response, including the time for reviewing instructions, searching existing data sources, gathering and maintaining the data needed, and completing and reviewing this collection of information. Send comments regarding this burden estimate or any other aspect of this collection of information, including suggestions for reducing this burden to Department of Defense, Washington Headquarters Services, Directorate for Information Operations and Reports (0704-0188), 1215 Jefferson Davis Highway, Suite 1204, Arlington, VA 22202-4302. Respondents should be aware that notwithstanding any other provision of law, no person shall be subject to any penalty for failing to comply with a collection of information if it does not display a currently valid OMB control number. PLEASE DO NOT RETURN YOUR FORM TO THE ABOVE ADDRESS.					
1. REPORT DATE October 2013		2. REPORT TYPE Final		3. DATES COVERED 30 Sep 2010 – 29 Sep 2013	
4. TITLE AND SUBTITLE Enhanced Healing of Segmental Bone Defects by Modulation of the Mechanical Environment			5a. CONTRACT NUMBER		
			5b. GRANT NUMBER W81XWH-10-1-0888		
			5c. PROGRAM ELEMENT NUMBER		
6. AUTHOR(S) Christopher H. Evans E-Mail: cevans@bidmc.harvard.edu			5d. PROJECT NUMBER		
			5e. TASK NUMBER		
			5f. WORK UNIT NUMBER		
7. PERFORMING ORGANIZATION NAME(S) AND ADDRESS(ES) Beth Israel Deaconess Medical Center, Boston, MA 02215			8. PERFORMING ORGANIZATION REPORT NUMBER		
9. SPONSORING / MONITORING AGENCY NAME(S) AND ADDRESS(ES) U.S. Army Medical Research and Materiel Command Fort Detrick, Maryland 21702-5012			10. SPONSOR/MONITOR'S ACRONYM(S)		
			11. SPONSOR/MONITOR'S REPORT NUMBER(S)		
12. DISTRIBUTION / AVAILABILITY STATEMENT Approved for Public Release; Distribution Unlimited					
13. SUPPLEMENTARY NOTES					
14. ABSTRACT Large, osseous segmental defects do not heal well and are a major clinical problem. Our research is based upon the hypothesis that healing of such defects is sensitive to the mechanical environment, particularly the axial stiffness; in particular, we postulate that healing will be accelerated by first fixing the defect under conditions of low axial stiffness and then increasing the stiffness once bone begins to form. We call this "reverse dynamization". A rat model was developed in which a critical size, femoral, diaphyseal defect was surgically created, treated with BMP-2 and stabilized with a custom-designed external fixator whose stiffness could be altered while still attached to a living animal. Three different axial stiffnesses were tested: low (114 N/mm), medium (185 N/mm) and high (254 N/mm). Pilot studies showed that, under non-dynamized conditions, low stiffness fixation provided the best outcome. Reverse dynamization was explored with low stiffness fixation for the first 14 days, during which time bone began to form in the defect, followed by high stiffness fixation for the remaining 6 weeks of the experiment. Reverse dynamization had a dramatic effect on healing, leading to accelerated bridging and advanced remodeling of the newly formed bone. After 8 weeks the strength of the healed bone under reverse dynamization was considerably enhanced, suggesting an early return to normal mechanical properties. Experiments to test this empirically are underway, but could not be completed in time for this report. Another possibility, that reverse dynamization could reduce the need for BMP-2, was tested empirically but this did not appear to be the case. Reverse dynamization accelerated and improved the healing of a defect treated with an effective dose of BMP-2 but was unable to initiate healing in a defect treated with an inactive dose of BMP-2.					
15. SUBJECT TERMS Reverse dynamization; BMP-2; external fixator; rat model; segmental defect					
16. SECURITY CLASSIFICATION OF:			17. LIMITATION OF ABSTRACT UU	18. NUMBER OF PAGES 30	19a. NAME OF RESPONSIBLE PERSON USAMRMC
a. REPORT U	b. ABSTRACT U	c. THIS PAGE U			19b. TELEPHONE NUMBER (include area code)

Table of Contents

	<u>Page</u>
Introduction.....	3
Body.....	3
Key Research Accomplishments.....	5
Reportable Outcomes.....	6
Conclusion.....	6
References.....	7
Appendices.....	7

INTRODUCTION

Although there is a considerable literature on the effects of mechanical forces on fracture healing¹⁻⁶, at the outset of this project there were no prior publications on the effects of such forces on the healing of large, segmental, osseous defects. The latter are of particular relevance to warriors. This research project investigated the effect of fixator stiffness on the healing of a critical size, femoral defect in the rat under the influence of bone morphogenetic protein-2 (BMP-2). We designed and constructed a novel external fixator that allowed the axial stiffness to be adjusted while still attached to the living animal. This allowed us to test our hypothesis that healing would be accelerated by a process we call reverse dynamization, in which the defect is initially fixed under conditions of low stiffness and high stiffness is then imposed after repair bone begins to form. This is the contrary of conventional dynamization, where fixation is initially stiff and is then reduced⁷⁻⁹. Additional experiments were undertaken to determine whether reverse dynamization allows lower amount of BMP-2 to be used to achieve healing and whether full mechanical strength is recovered earlier. Translated to a clinical setting, lowering the need for BMP-2 would reduce costs and shortening the time needed to recover mechanical strength would allow earlier weight-bearing.

BODY

Methods

Adjustable external fixator

The custom-made, adjustable, external fixator¹⁰ comprised a main frame made from polyethylethylketone with two connection elements and two main modules (figure 1). Different stiffnesses were produced using connection elements of different thicknesses. The ones used in these studies generated the following stiffnesses: 114 N/mm (low stiffness), 185 N/mm (medium stiffness) and 254 N/mm (high stiffness).

Experimental model

Male, Sprague-Dawley rats (325-400g) were anesthetized with isoflurane and given prophylactic antibiotics and analgesics. The diaphysis of the femur was surgically exposed and the external fixator used as a positioning guide for four drill-holes to accommodate the screws used to secure the fixator. A saw guide was then used to generate a 5 mm, mid-diaphyseal defect with a 0.22 mm wire Gigli saw. A collagen sponge impregnated with recombinant, human bone morphogenetic protein-2 (BMP-2) was then inserted into the defect¹¹. For most experiments, 11 µg BMP-2 was used. When testing different doses, 5.5 µg and 1.1 µg were also used. Control defects contained the collagen sponge lacking any BMP-2.

Outcome measures

Healing of defects was monitored by weekly X-ray. Most experiments were allowed to continue for 8 weeks; certain experiments were terminated before this to enable study of the early stages of healing. After euthanasia, femora were removed from animals and examined by several complementary analyses.

Non-destructive techniques included dual energy X-ray absorptiometry (DXA) and micro-computed tomography (µCT). Destructive techniques included histology of decalcified

specimens using hematoxylin-eosin and safranin orange- fast green stains, and torsional mechanical testing.

Results

The results are presented as they relate to the tasks identified in the Statement of Work.

Task 1. Obtain Regulatory Review and Approval of Animal Research

This was accomplished

Task 2. Determine the effect of fixator stiffness on healing

By all outcome measures, the high stiffness fixator produced the worst healing. Inspection of figure 2 reveals that after 9 days, bone was forming in the defects stabilized with low and medium stiffness fixators, but not in defects stabilized with high stiffness fixators. At 14 days, bone had formed within defects stabilized by high stiffness defects, but was less extensive than in the other two groups. Although all groups ultimately healed their defects, healing was more rapid in defects stabilized under conditions of low stiffness (figure 3).

The histological analyses (figure 4, figure 5) confirmed the X-ray data. Defects healing under conditions of low stiffness showed earlier osteogenesis and marrow formation. Defects healing under conditions of medium stiffness manifest a peculiar gap in the middle of the healing defect, while defects healing under high stiffness had little sign of early marrow formation and were much thinner in cross section. The histological differences were still evident at the end of the experiment at 8 weeks, where regenerates formed under conditions of high stiffness contained extensive bands of cartilage and those formed under conditions of medium stiffness retained the gap in the middle (figure 6).

These findings were in agreement with the μ -CT images showing better cortication and more mature bone formed under conditions of low stiffness. These images also confirmed the presence of a gap in the middle of regenerates formed under conditions of medium stiffness. Under conditions of high stiffness, the new bone was disorganized and the intramedullary region contained abundant trabecular bone.

Task 3. Optimize healing by altering the mechanical environment at different stages.

Based upon the data obtained in task 2, we decided to implement the following mechanical regimen. Defects were initially fixed under conditions of low stiffness, as this provided the most rapid onset of new bone formation in the defect. At 14 days, the stiffness was changed to high stiffness to promote the consolidation of the new bone that was forming. As noted, we call this modulation of stiffness “reverse dynamization” (RD). The results were dramatic.

As shown in figure 7, implementation of reverse dynamization greatly accelerated healing and led to more advanced remodeling, as noted by the smooth contours of the regenerate from 4 weeks onwards and the reduced callus size. Histology confirmed this (figure 8). Defects subject to reverse dynamization had advanced cortication, reduced callus size, and more mature marrow. Images provided by μ CT (figure 9) were in good agreement with the histological images.

Quantification of the DXA and μ CT data (figure 10) confirmed that the properties of defects healed under reverse dynamization were closer to the normal, contralateral femur than those not subject to this process.

Mechanical testing (figure 11) showed that defects healed by reverse dynamization were considerably stronger than normal bone, consistent with our hypothesis that full restoration of mechanical strength occurred at an early time point.

Task 4. *Determine whether optimized method accelerates recovery of full mechanical strength*

This component of the study has not yet been completed. The rats have undergone surgery and will be euthanized and evaluated shortly.

Task 5. *Determine whether optimized method reduces amount of BMP-2 needed*

To address this issue, we first conducted a dose-response experiment to determine the effect of BMP-2 amount on healing. Against our standard dose of 11 μ g BMP-2, we tested 5.5 μ g BMP-2 and 1.1 μ g BMP-2. Surprisingly, the results with 5.5 μ g BMP-2 were similar to those obtained with 11 μ g BMP-2, apart from a smaller callus size (figure 12) and slightly slower rate of healing, whereas 1.1 μ g BMP-2 produced no healing whatsoever (figure 13). Reverse dynamization was unable to induce healing when used in conjunction with 1.1 μ g BMP-2, although it was able to accelerate healing in defects containing sufficient BMP-2 to induce a healing response (figure 14). This suggests that reverse dynamization is unlikely to reduce the need for BMP-2, as we had hoped, and that its major effect is to accelerate, rather than initiate, healing.

Summary and Conclusions

In this rat model system, 11 μ g BMP-2 healed critical sized, femoral, segmental defects by 8 weeks. When defects were stabilized under conditions of constant stiffness, the least stiff fixator produced the most rapid and complete healing. However, when the stiffness was increased after two weeks to effect reverse dynamization, healing was strikingly accelerated and maturation of bone, cortices and marrow was considerably enhanced¹².

The dose-response to BMP-2 in this model was surprisingly steep in that 5.5 μ g BMP-2 was almost as effective as 11 μ g BMP-2, but 1.1 μ g BMP-2 was completely ineffective. Reverse dynamization was unable to rescue healing in response to 1.1 μ g BMP-2, suggesting that although stiffness modulation accelerates healing and maturation of defects that might otherwise heal poorly, it cannot initiate healing in a defect with no healing capacity.

Because defects healed under the influence of reverse dynamization are stronger than normal after 8 weeks, there is a likelihood that full mechanical strength is recovered at an early time point. The study to determine whether this is so (Task 4) is still underway.

KEY RESEARCH ACCOMPLISHMENTS

- Establishment of an experimental system with which to study the effects of fixator stiffness and reverse dynamization on the healing of critical size, segmental defects.

- Demonstration that the least stiff fixator produced the most rapid healing in response to BMP-2.
- Demonstration that reverse dynamization had a dramatic effect on bone healing, producing accelerated healing and maturation of bone that was far superior to any single-stiffness regimen.
- Demonstration that reverse dynamization does not initiate healing at sites that lack the ability to heal. Rather, the main effect is to accelerate healing.
- Preliminary data suggest that reverse dynamization accelerates the restoration of full mechanical strength. (Confirmatory experiments are underway).
-

REPORTABLE OUTCOMES

Manuscripts, abstracts, presentations

1. Glatt V, Evans CH, Matthys R: Design, characterisation and *in vivo* testing of a new, adjustable stiffness, external fixator for the rat femur. *Eur Cells Mater* 23: 289 - 299, 2012
2. Glatt V, Miller M, Ivkovic A, Liu F, Parry N, Griffin D, Vrahas M, Evans CH: Improved healing of large segmental defects in the rat femur by reverse dynamization in the presence of bone morphogenetic protein-2. *J Bone Jt Surg Am* 94: 2063-2073, 2012
3. Glatt V, Liu F, Neumann, M, Schuetz M, Evans CH.: Effect Of Mechanical Environment On The BMP-2 Dose-Response Of Large Segmental Defect Healing. Abstract to be presented at the 2014 meeting of the Orthopaedic Research Society.
4. Glatt, V, Liu F, Neumann M, Schuetz M, Evans CH: Effect of mechanical environment on the BMP-2 dose-response of large segmental defect healing. Podium Presentation, "Where science meets clinics" Davos, Switzerland, September 2013
5. Evans CH: Enhanced Healing of a Rat Segmental Defect Model by Reverse Dynamization/Grand Rounds Hofstra - Long Island Jewish School of Medicine, Manhasset NY. September, 2012

Funding applied for based on work supported by this award

Translational Research Partnership Award OR120192 - "Improved Healing of Large, Osseous, Segmental Defects by Reverse Dynamization: Evaluation in a Sheep Model" (Evans, CH – PI)

Employment opportunities received based upon experience/training supported by this award

Partly based upon her research during the completion of this project, Vaida Glatt PhD was able to secure a position as a Senior Research Fellow at Queensland University of Technology, Australia.

CONCLUSION

This study confirms the utility of reverse dynamization in accelerating the healing of a critical size, diaphyseal defect in a rat model. However, it appears unable to initiate healing in a defect that lacks any intrinsic ability to heal.

So what section

If reverse dynamization can be shown to work in a large animal model, its clinical translation should be rapid. This is because the envisaged external fixator would use pins that are already in

clinical use to secure the device to the bone. The “external” part of the external fixator would be inexpensive and re-usable, leading to major cost savings and widespread use.

REFERENCES

1. **Claes LE, Heigele CA, Neidlinger-Wilke C, Kaspar D, Seidl W, Margevicius KJ, Augat P.** Effects of mechanical factors on the fracture healing process. *Clin Orthop Relat Res* 1998;355 Suppl:S132-47.
2. **Goodship AE, Cunningham JL, Kenwright J.** Strain rate and timing of stimulation in mechanical modulation of fracture healing. *Clin Orthop Relat Res* 1998;355 Suppl:S105-15.
3. **Goodship AE, Kenwright J.** The influence of induced micromovement upon the healing of experimental tibial fractures. *J Bone Joint Surg Br* 1985;67-4:650-5.
4. **Kenwright J, Goodship AE.** Controlled mechanical stimulation in the treatment of tibial fractures. *Clin Orthop Relat Res* 1989;241:36-47.
5. **Perren SM.** Evolution of the internal fixation of long bone fractures. The scientific basis of biological internal fixation: choosing a new balance between stability and biology. *J Bone Joint Surg Br* 2002;84-8:1093-110.
6. **Perren SM, Rahn BA.** Biomechanics of fracture healing. *Can J Surg* 1980;23-3:228-32.
7. **Larsson S, Kim W, Caja VL, Egger EL, Inoue N, Chao EY.** Effect of early axial dynamization on tibial bone healing: a study in dogs. *Clin Orthop Relat Res* 2001;388:240-51.
8. **Claes L, Blakytyn R, Gockelmann M, Schoen M, Ignatius A, Willie B.** Early dynamization by reduced fixation stiffness does not improve fracture healing in a rat femoral osteotomy model. *J Orthop Res* 2009;27-1:22-7.
9. **Claes L, Blakytyn R, Besse J, Bausewein C, Ignatius A, Willie B.** Late dynamization by reduced fixation stiffness enhances fracture healing in a rat femoral osteotomy model. *J Orthop Trauma*;25-3:169-74.
10. **Glatt V, Evans CH, Matthys R.** Design, characterisation and in vivo testing of a new, adjustable stiffness, external fixator for the rat femur. *Eur Cell Mater*;23:289-98; discussion 99.
11. **Yasko AW, Lane JM, Fellingner EJ, Rosen V, Wozney JM, Wang EA.** The healing of segmental bone defects, induced by recombinant human bone morphogenetic protein (rhBMP-2). A radiographic, histological, and biomechanical study in rats. *J Bone Joint Surg Am* 1992;74-5:659-70.
12. **Glatt V, Miller M, Ivkovic A, Liu F, Parry N, Griffin D, Vrahas M, Evans C.** Improved healing of large segmental defects in the rat femur by reverse dynamization in the presence of bone morphogenetic protein-2. *J Bone Joint Surg Am*;94-22:2063-73.

APPENDIX

Copy of the following article is to be found at the end of this report.

Glatt V, Miller M, Ivkovic A, Liu F, Parry N, Griffin D, Vrahas M, Evans C. Improved healing of large segmental defects in the rat femur by reverse dynamization in the presence of bone morphogenetic protein-2. *J Bone Joint Surg Am*;94-22:2063-73.

SUPPORTING DATA

Figures

Figure 1

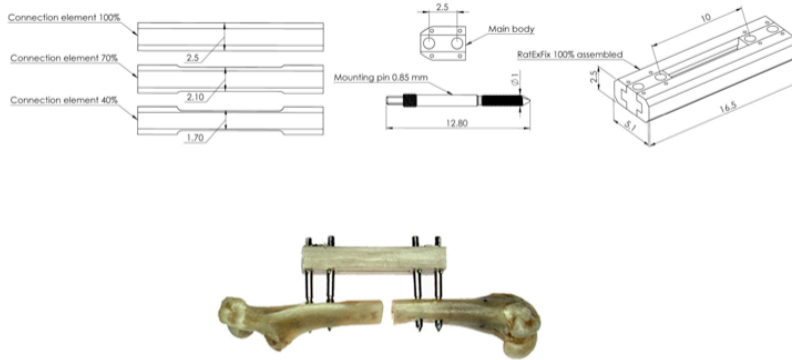


Figure 1

Components of the novel external fixator

Top: Stiffness is determined by connection elements of different thicknesses (left hand side). Bottom: Assembled fixator in place on rat femur with 5 mm defect

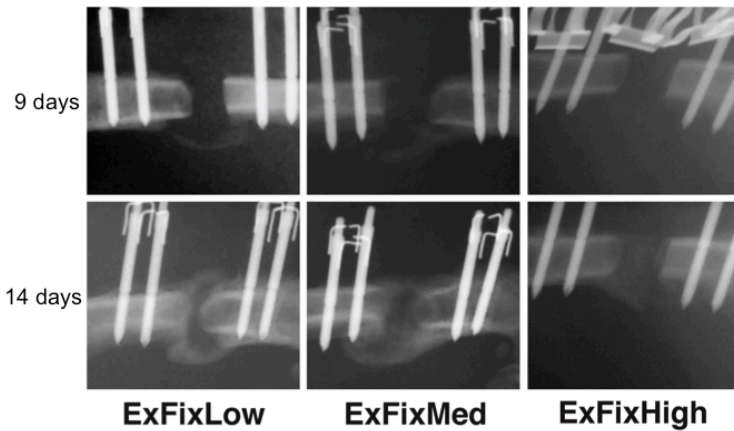


Figure 2

Radiographs made at 9 and 14 days of defects stabilized with fixators of different stiffnesses

ExFixLow: Low stiffness
 ExFixMed: Medium stiffness
 ExFixHigh: High stiffness

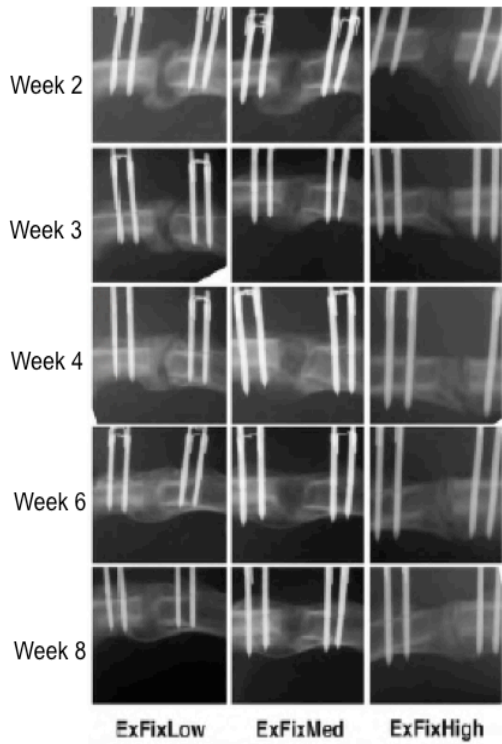


Figure 3
Radiographs made during the course of healing of defects stabilized with fixators of different stiffnesses

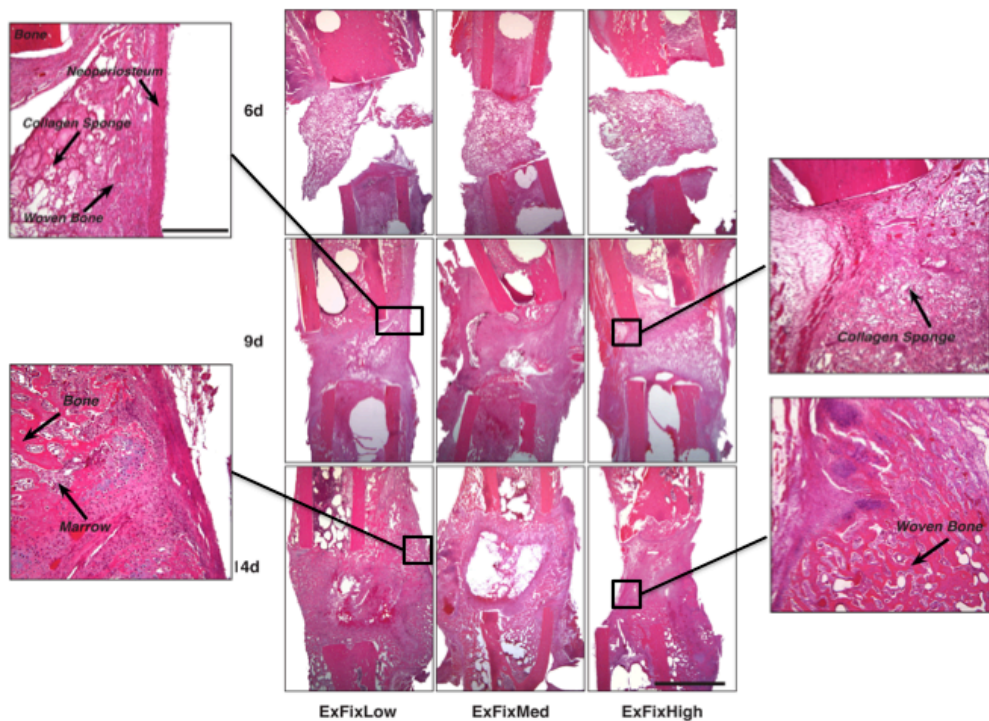


Figure 4 *Histological appearance of defects stabilized with low (ExFixLow), medium (ExFixMed) and high (ExFixHigh) stiffness fixators at 6, 9 and 14 days. H&E staining*

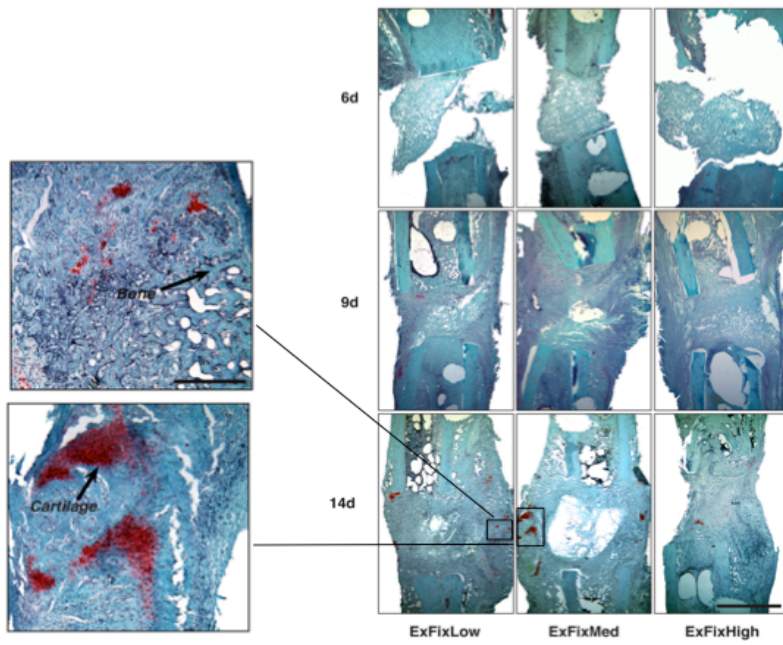


Figure 5 Histological appearance of defects stabilized with low (*ExFixLow*), medium (*ExFixMed*) and high (*ExFixHigh*) stiffness fixators at 6, 9 and 14 days. SOFG staining

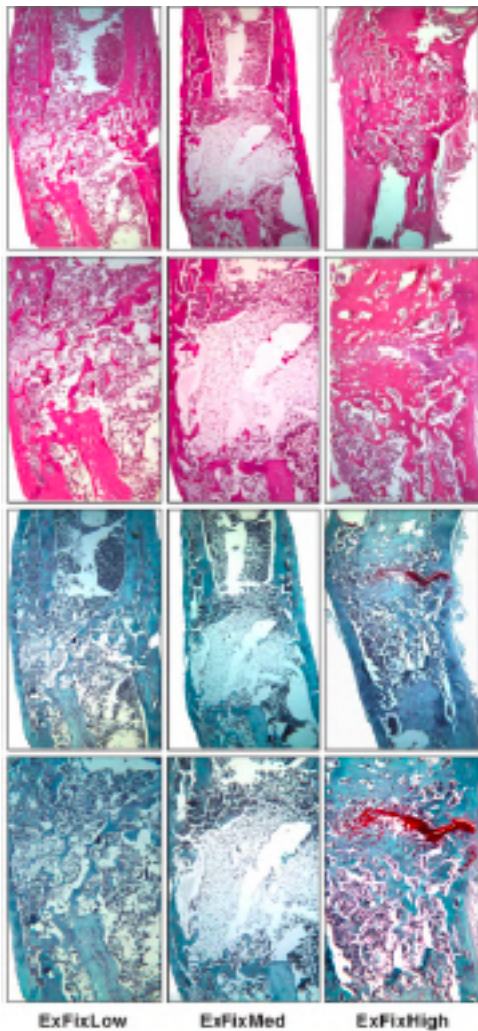


Figure 6 Histological appearance after 8 weeks of defects healed under conditions of low (*ExFixLow*), medium (*ExFixMed*) and high (*ExFixHigh*) stiffness

Top two rows: Hematoxylin and Eosin staining
 Bottom two rows: Safranin-orange and Fast green

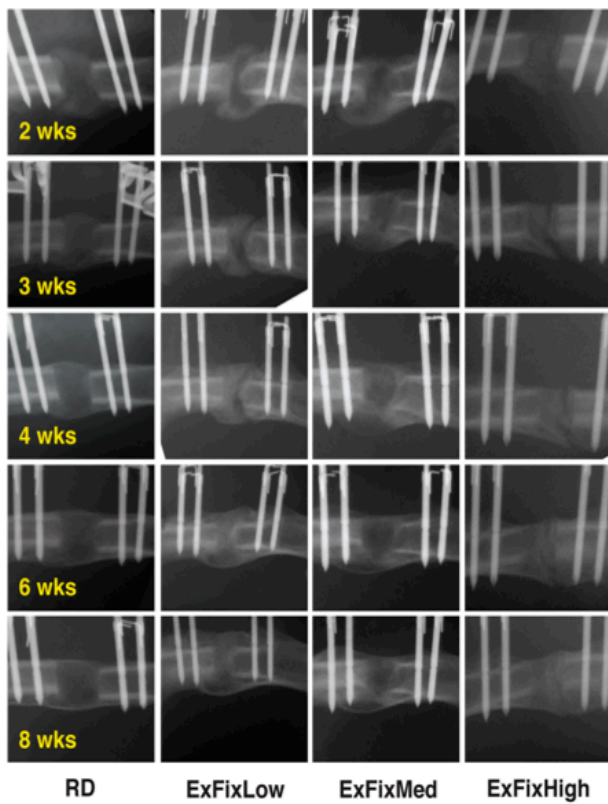


Figure 7 Serial radiographs of defects stabilized with low (ExFixLow), medium (ExFixMed) and high (ExFixHigh) stiffness fixators and subjected to reverse dynamization (RD)

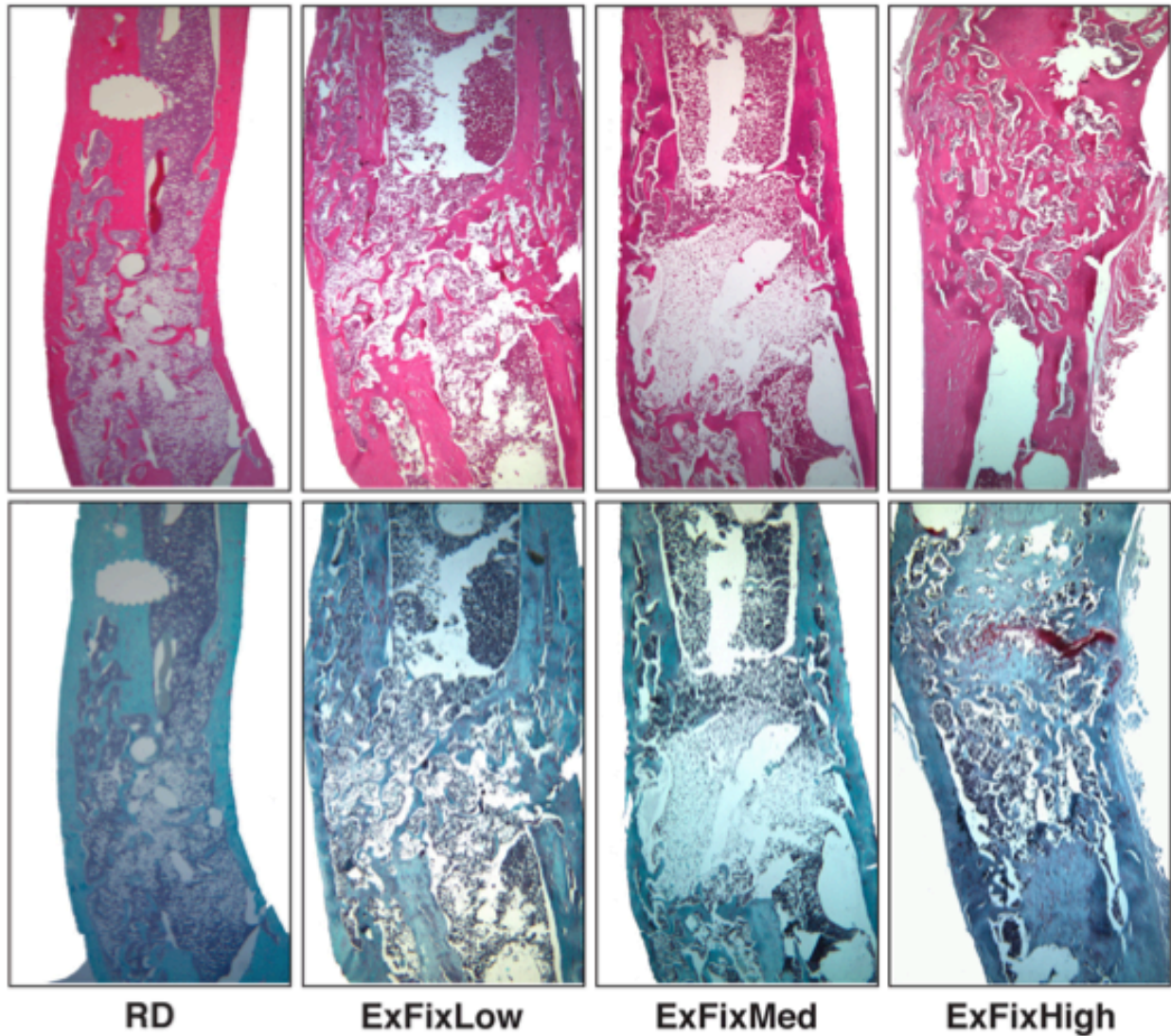


Figure 8 *Histological appearance of defects at eight weeks after stabilization with low (ExFixLow), medium (ExFixMed) and high (ExFixHigh) stiffness fixators and subjected to reverse dynamization (RD).*

Top row: Hematoxylin and Eosin staining

Bottom row: Safranin orange – fast green staining

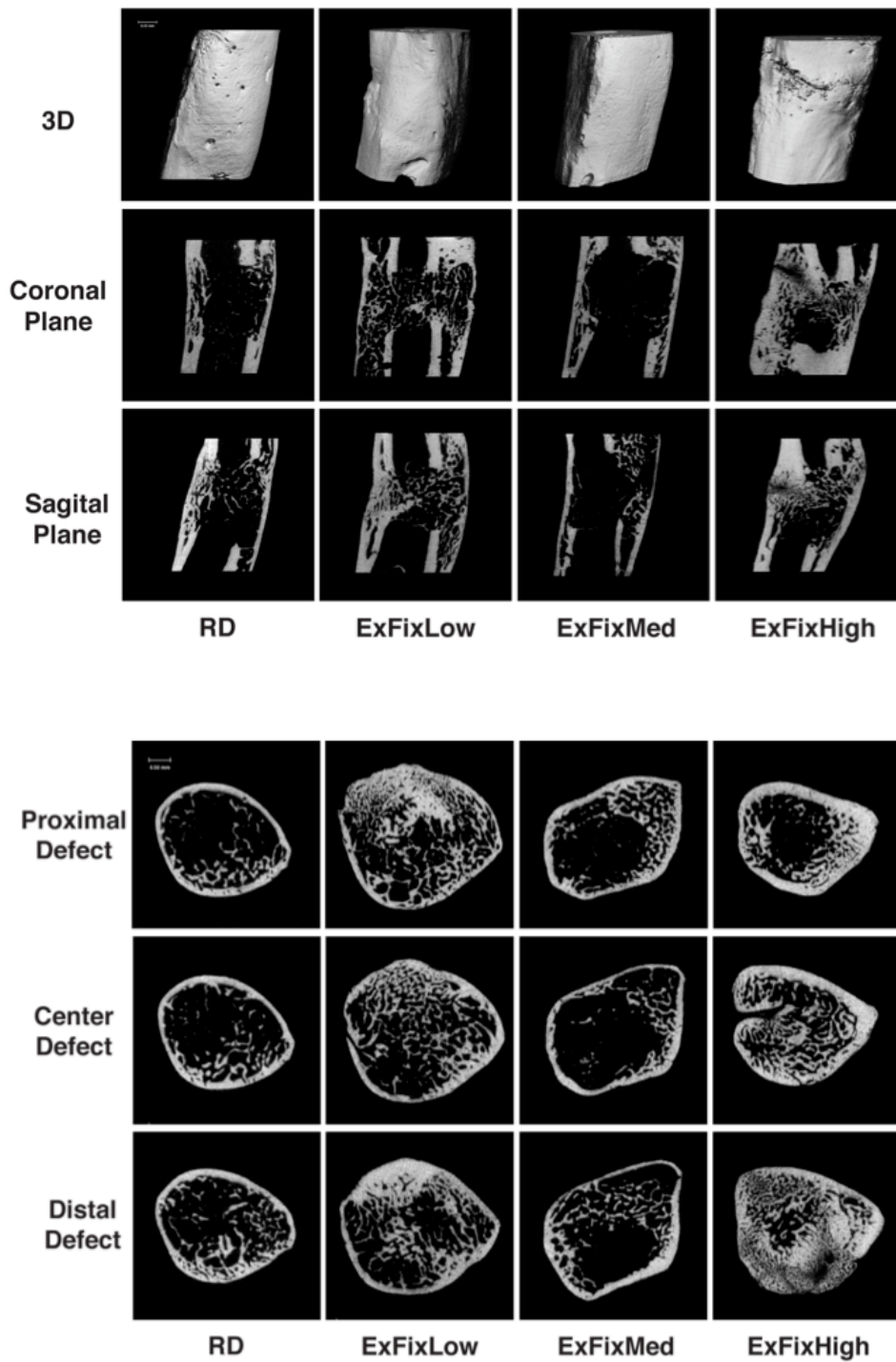


Figure 9 *Microtomographic images of defects after 8 weeks of stabilization with low (ExFixLow), medium (ExFixMed) or high (ExFixHigh) stiffness fixators or subjected to reverse dynamization (RD).*

Top panels: Three dimensional(3D), saggital and coronal images.

Bottom panels: Cross sections images showing the proximal, center and distal areas of defects

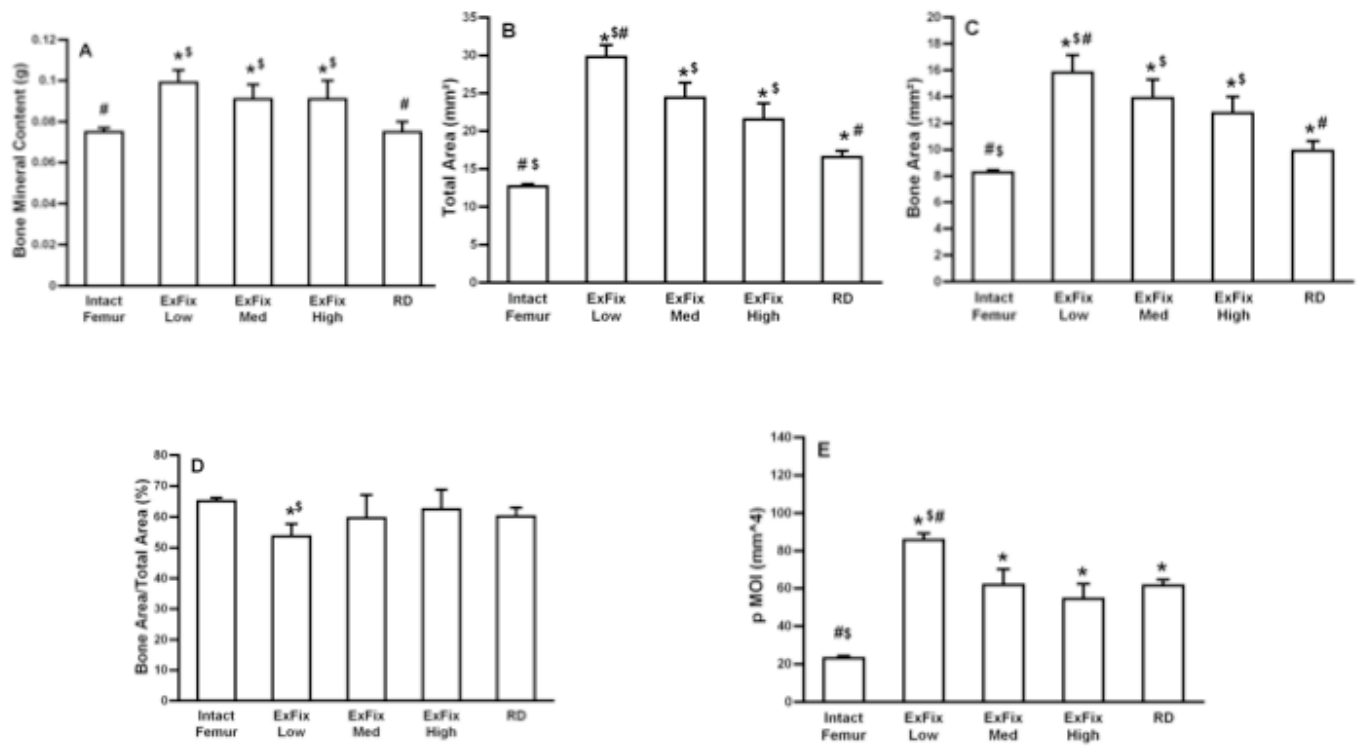


Figure 10 Effects of low (RxFixLow), medium (ExFixMed), and high (ExFixHigh) fixation and reverse dynamization (RD) on DXA and μ CT values at 8 weeks.

Panel A: Bone mineral content

Panel B: Total callus area

Panel C: Bone area

Panel D: Ration of bone area to total area

Panel E: Polar moment of inertia (pMOI)

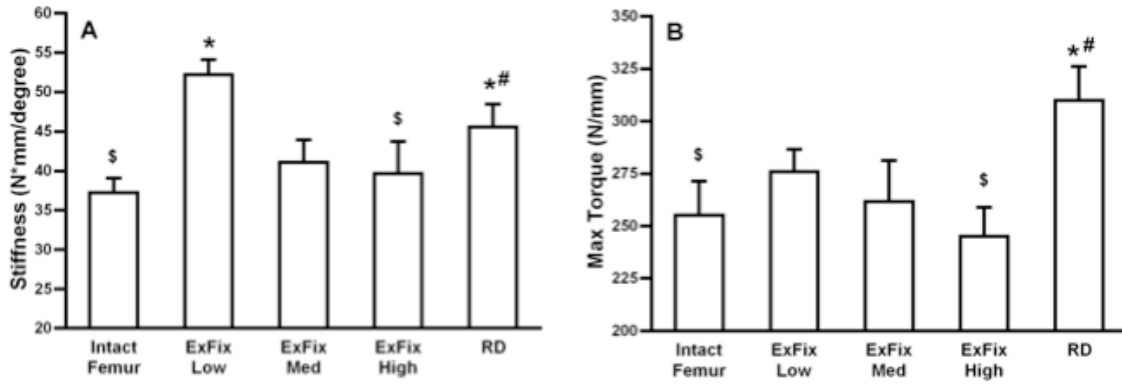


Figure 11 *Effect of low (ExFixLow), medium (ExFixMed) and high (ExFixHigh) stiffness fixation and reverse dynamization (RD) on the mechanical properties of the healed bone at 8 weeks.*

Panel A: Stiffness

Panel B: Strength

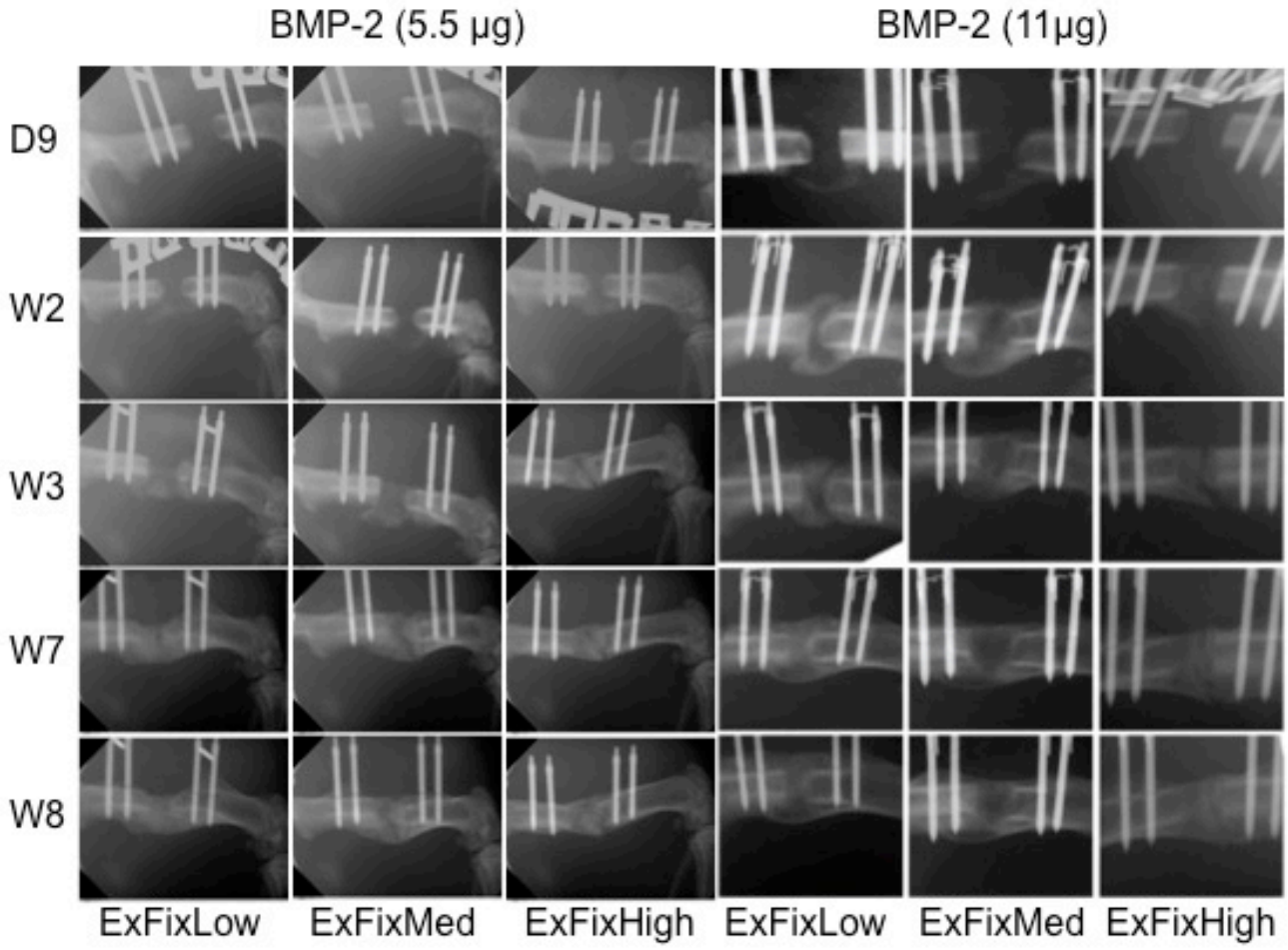


Figure 12 X-ray images of defects healed under conditions of low (*ExFixLow*), medium (*ExFixMed*) and high (*ExFixHigh*) stiffness using 11 μ g or 5.5 μ g BMP-2

D: Day 9 W: week

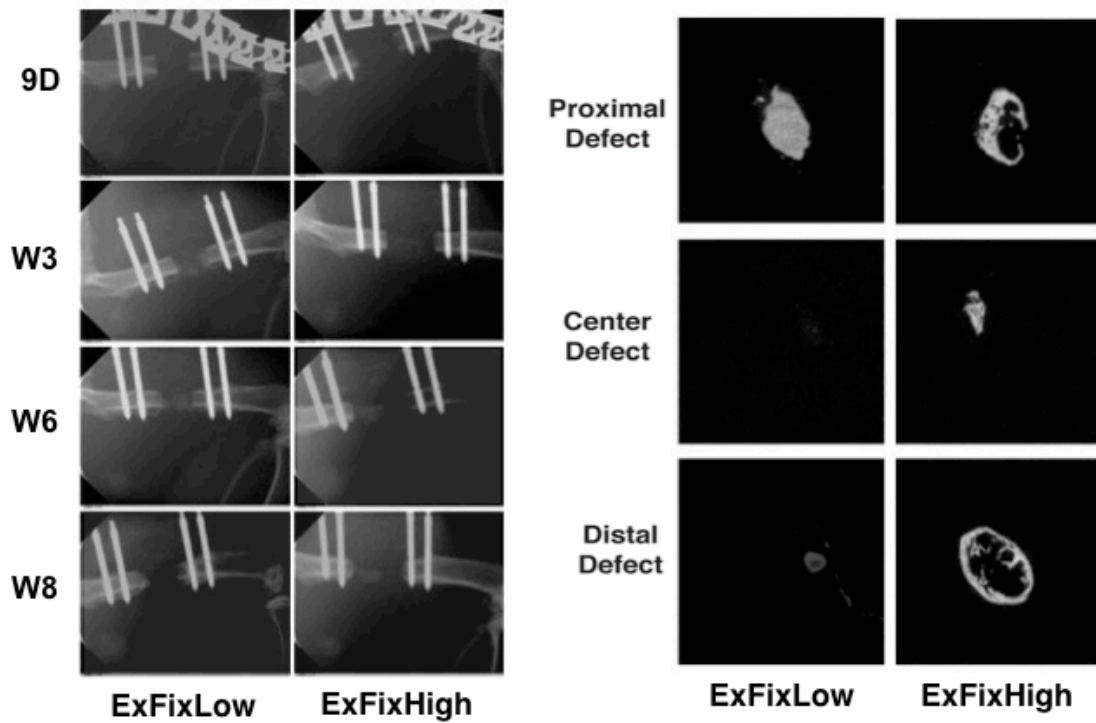


Figure 13 *Healing of defect in response to 1.1 µg BMP-2 under conditions of low (ExFixLow) and high (ExFixHigh) stiffness*

Left Panels: X-rays; D= Day W= week
 Right Panels: Micro-CT images at 8 weeks

TV = 81.17
 BV = 26.63
 BV/TV = 0.397

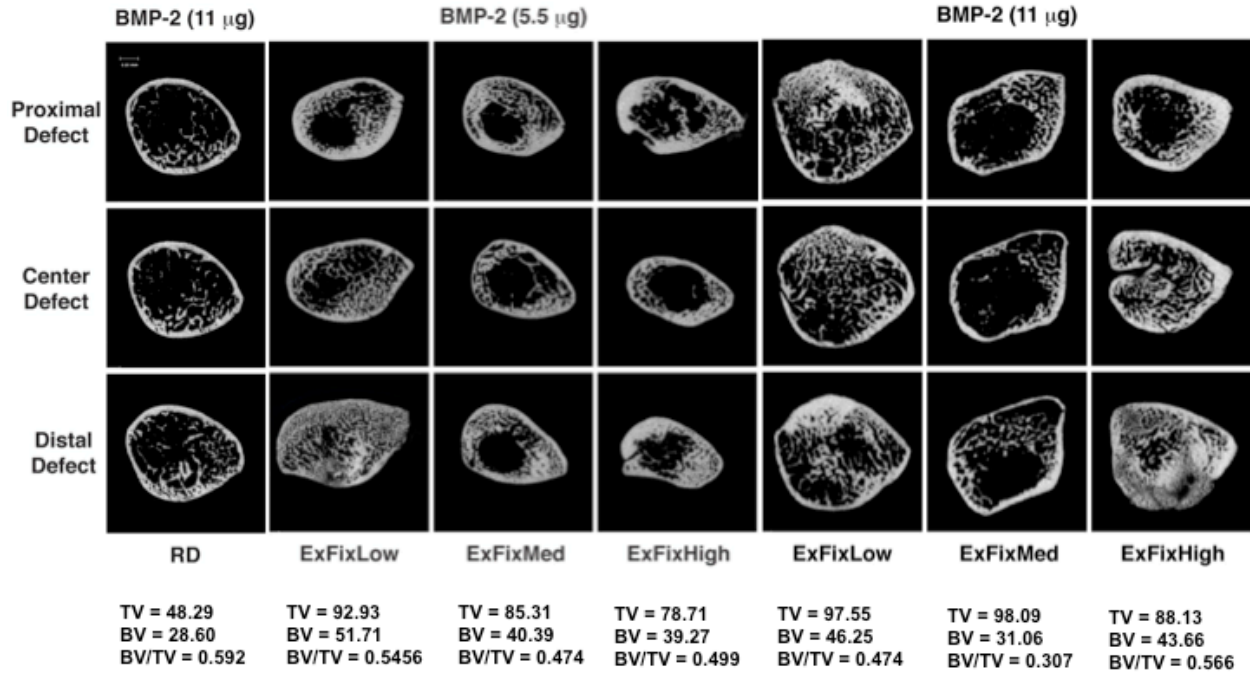


Figure 14. Cross sectional μ CT images after 8 weeks of healing with 11 μ g or 5.5 μ g BMP-2 under conditions of low (ExFixLow), medium (ExFixMed) or high (ExFixHigh) stiffness fixation or reverse dynamization (RD)

Improved Healing of Large Segmental Defects in the Rat Femur by Reverse Dynamization in the Presence of Bone Morphogenetic Protein-2

Vaida Glatt, PhD, Micah Miller, BS, Alan Ivkovic, MD, PhD, Fangjun Liu, MD, PhD, Nicola Parry, DVM, Damian Griffin, MD, Mark Vrahas, MD, and Christopher Evans, PhD

Investigation performed at the Center for Advanced Orthopaedic Studies, Beth Israel Deaconess Medical Center, Boston, Massachusetts

Background: Large segmental defects in bone do not heal well and present clinical challenges. This study investigated modulation of the mechanical environment as a means of improving bone healing in the presence of bone morphogenetic protein (BMP)-2. Although the influence of mechanical forces on the healing of fractures is well established, no previous studies, to our knowledge, have described their influence on the healing of large segmental defects. We hypothesized that bone-healing would be improved by initial, low-stiffness fixation of the defect, followed by high-stiffness fixation during the healing process. We call this reverse dynamization.

Methods: A rat model of a critical-sized femoral defect was used. External fixators were constructed to provide different degrees of stiffness and, importantly, the ability to change stiffness during the healing process in vivo. Healing of the critical-sized defects was initiated by the implantation of 11 μ g of recombinant human BMP (rhBMP)-2 on a collagen sponge. Groups of rats receiving BMP-2 were allowed to heal with low, medium, and high-stiffness fixators, as well as under conditions of reverse dynamization, in which the stiffness was changed from low to high at two weeks. Healing was assessed at eight weeks with use of radiographs, histological analysis, microcomputed tomography, dual x-ray absorptiometry, and mechanical testing.

Results: Under constant stiffness, the low-stiffness fixator produced the best healing after eight weeks. However, reverse dynamization provided considerable improvement, resulting in a marked acceleration of the healing process by all of the criteria of this study. The histological data suggest that this was the result of intramembranous, rather than endochondral, ossification.

Conclusions: Reverse dynamization accelerated healing in the presence of BMP-2 in the rat femur and is worthy of further investigation as a means of improving the healing of large segmental bone defects.

Clinical Relevance: These data provide the basis of a novel, simple, and inexpensive way to improve the healing of critical-sized defects in long bones. Reverse dynamization may also be applicable to other circumstances in which bone-healing is problematic.

Large segmental defects of bone do not heal well and remain a clinical problem. Approaches to treating these defects include the use of autograft and allograft bone¹, distraction osteogenesis², and vascularized bone grafts³, as well as the application of growth factors such as bone morphogenetic protein (BMP)-2 and 7, which are the active ingredients

of INFUSE (Medtronic) and OP-1 (osteogenic protein; Stryker), respectively⁴. There is also interest in using osteoprogenitor cells⁵, induced membranes⁶, and tissue engineering^{7,8}. Gene therapy technologies for bone-healing are in preclinical development⁹. The present study addresses modulation of the ambient mechanical environment as a way of promoting the healing

Disclosure: One or more of the authors received payments or services, either directly or indirectly (i.e., via his or her institution), from a third party in support of an aspect of this work. In addition, one or more of the authors, or his or her institution, has had a financial relationship, in the thirty-six months prior to submission of this work, with an entity in the biomedical arena that could be perceived to influence or have the potential to influence what is written in this work. No author has had any other relationships, or has engaged in any other activities, that could be perceived to influence or have the potential to influence what is written in this work. The complete **Disclosures of Potential Conflicts of Interest** submitted by authors are always provided with the online version of the article.

of large segmental defects experimentally with use of a rat model of a critical-sized femoral defect in conjunction with recombinant human BMP (rhBMP)-2.

Bone is highly responsive to mechanical loading, and there are a substantial number of studies on the effects of different mechanical regimens on fracture-healing^{10,11}. Pioneering studies by Kenwright, Goodship, Perren, Claes, and others¹⁰⁻¹⁵ have identified interfragmentary motion as the most important, mechanically determined parameter of fracture-healing. For instance, small, controlled, cyclic axial compressive displacement (stable fixation) enhances healing through a bigger callus and earlier fracture-bridging. In contrast, high strain forces (inadequate stability) inhibit callus formation. The effects of shear or transverse micromotion remain to be defined with precision.

Because different stages of the healing process respond differently to their mechanical environment, there has been much interest in the concept of dynamization, according to which the stiffness of fixation is reduced at a certain point during the healing process. This increases the interfragmentary motion and has been postulated to lead to more rapid remodeling of the regenerating bone. Dynamization at one week enhances healing of a 2-mm tibial osteotomy in dogs¹⁶ but not a 1-mm femoral osteotomy in rats¹⁷. Using the latter model, however, Claes et al.¹⁸ showed that late dynamization at three and four weeks enhanced healing.

In contrast to the above examples, no previous publications, to our knowledge, have described the influence of the ambient mechanical environment on the healing of critical-sized segmental bone defects. We performed studies using a rat model of a critical-sized femoral defect. These defects do not heal spontaneously, but they heal in response to BMP-2. External fixators were designed to provide different stiffnesses, with the ability to change the stiffness during the healing process. rhBMP-2 was used to stimulate healing of the defects. The literature suggests that large segmental defects in the rat heal in

response to BMP-2 by an endochondral process¹⁹. Because shear forces are known to promote chondrogenesis²⁰, we hypothesized that a low-stiffness fixator would promote the early formation of cartilage. We further hypothesized that a subsequent increase in fixator stiffness would provide the rigidity needed for the efficient ingrowth of blood vessels and other aspects of the endochondral process. Thus, we suggested that healing of a large segmental defect in response to BMP-2 would be improved by early loose fixation followed by subsequent stiff fixation once bone begins to form. We term the transition from a less stiff fixation to stiffer fixation *reverse dynamization*.

Materials and Methods

Study Design

Pilot Study

External fixators of three different stiffnesses were constructed as described previously²¹ and used in a pilot study to determine their influence on the first two weeks of bone-healing in the presence of BMP-2. This study had two aims: (1) to test our hypothesis that the fixator with the least stiffness would promote the most rapid early healing response and (2) to determine a suitable time for increasing fixator stiffness.

Thirty-six rats underwent surgery to create 5-mm femoral defects and were divided into three equal groups of animals that received low, medium, or high-stiffness fixators. All animals received BMP-2. Radiographs of the femoral defects were made after nine and fourteen days. Four rats per group were killed at six, nine, and fourteen days after surgery, and their femora were processed for histological analysis.

The subsequent reverse dynamization protocol was determined by the radiographic and histological data from the pilot study.

Reverse Dynamization

On the basis of the pilot study data, reverse dynamization was implemented by switching from low-stiffness to high-stiffness fixators at day 14. Healing of these animals was compared with that in animals whose low, medium, and high-stiffness fixators were not changed. A small number of control animals that did not receive BMP-2 were included to confirm that the defects did not heal spontaneously. Defects of all animals were monitored with weekly radiographs. At eight weeks, all animals were killed. All specimens were assessed with dual x-ray absorptiometry and microcomputed tomography (micro-CT). Nine

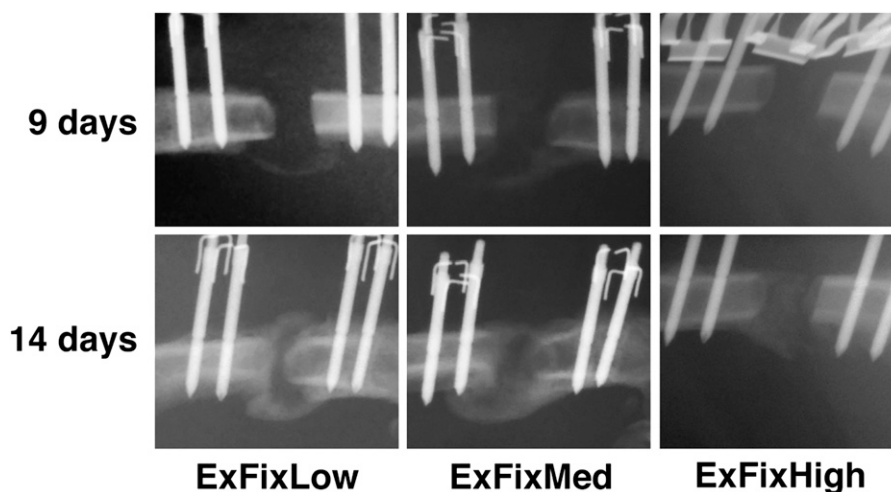


Fig. 1
Radiographs, made at nine and fourteen days, of defects stabilized with low (ExFixLow), medium (ExFixMed), and high-stiffness (ExFixHigh) fixators.

specimens from each group were subjected to mechanical testing, and three were processed for histological analysis.

The design of this experiment is summarized in the Appendix.

Methods

Fixators

Defects were stabilized with custom-made external fixators, as described previously²¹. Their key features are interchangeable connection elements of different stiffnesses. The present work evaluated connection elements with stiffnesses of 114, 185, and 254 N/mm.

Surgery

A 5-mm, critical-sized, midfemoral defect was created in the right hind limb of each rat. We described this model previously, confirming that it does not spontaneously heal but heals when 11 μ g of rhBMP-2 is inserted into the defect^{22,23}. Groups of rats were maintained for eight weeks with each of these fixators. An additional group underwent reverse dynamization, whereby a low-stiffness fixator was applied for the first two weeks and then was switched to high-stiffness fixator (see Appendix). The number of control animals was low because of extensive historical data confirming that these defects do not heal

spontaneously^{22,23}. The numbers of animals in the treatment groups were based on historical data confirming sufficient statistical power^{22,23}.

Animal care and experimental protocols were followed in accordance with National Institutes of Health guidelines and were approved by our institution's Institutional Animal Care and Use Committee.

The surgical procedure has been described in detail previously²¹. Briefly, male Sprague-Dawley rats weighing between 325 and 360 g were anesthetized with isoflurane (2% with 2 L/min O₂ by air mask). Before surgery, each rat was given an antibiotic (20 mg/kg of cefazolin) and the analgesic buprenorphine (0.08 mg/kg) intramuscularly in the left leg. An incision of approximately 3.5 to 4 cm was made through the skin, and the shaft of the femur was exposed.

The external fixator bar was used as a positioning guide to permit reproducible positioning of four drill-holes to accommodate the screws used to secure the fixator. After the fixator was in place, a saw guide was used to make the 5-mm segmental defect with use of a 0.22-mm wire Gigli saw. After the defect was created, the saw guide was removed and a collagen sponge impregnated with rhBMP-2 (11 μ g in 100 μ L of saline solution) was added to the defect area. Control defects received a sponge lacking BMP-2. The wound was closed in layers. On the first three postoperative days, the rat was given analgesic every twelve hours and antibiotic every twenty-four hours.

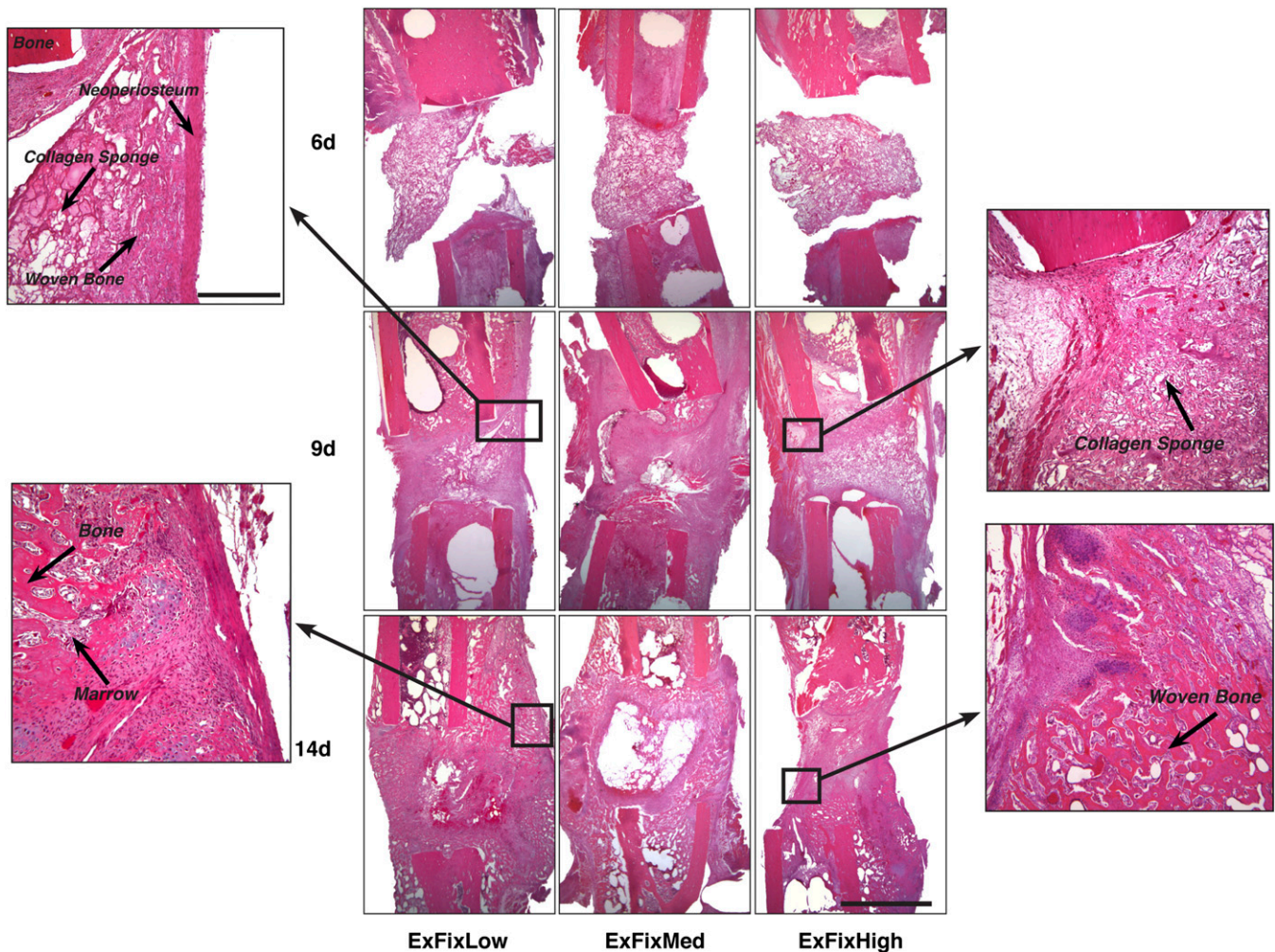


Fig. 2-A

Figs. 2-A and 2-B Histological appearance of defects stabilized with low (ExFixLow), medium (ExFixMed), and high-stiffness (ExFixHigh) fixators at six, nine, and fourteen days. Bars indicate 2 mm in low-magnification images and 0.5 mm in high-magnification images. **Fig. 2-A** Hematoxylin-eosin staining.

Radiographic Evaluation

Bone-healing was evaluated with serial radiography with use of a digital dental x-ray unit (Heliodont DS; Sirona, Bensheim, Germany). While under general anesthesia, the rats were placed in a ventral position and the hind limb was laterally rotated so that the external fixator was not in the path of the x-ray source.

Histological Analysis

Femora were fixed for histological analysis in 4% ice-cold paraformaldehyde and were decalcified for six to eight hours in RDO Rapid Decalcifier (Apex Engineering, Aurora, Illinois), testing with a needle as the decalcification proceeded. Fixed and decalcified tissues were dehydrated in graded ethanol up to 100%, transferred to xylene, and embedded in paraffin. Five-micrometer paraffin sections were placed on poly-L-lysine-coated slides, dried overnight, and evaluated immediately or stored at 4°C. Sections were stained with hematoxylin-eosin or safranin orange-fast green.

Microcomputed Tomography

Femora were scanned with use of a desktop microtomographic imaging system (μ CT40; Scanco Medical, Bassersdorf, Switzerland) equipped with a 10-mm focal spot microfocus x-ray tube. Femora were scanned with use of a 20- μ m isotropic voxel size, at 55 keV of energy, 200-ms integration time, with approximately 720 micro-CT slices per specimen. Evaluation was done only in the

4-mm (200 slices) central defect region to ensure that no preexisting cortical bone was included in the analyses. To evaluate the region of interest, we assessed the following variables: total cross-sectional area or the callus size of the defect (TA in square millimeters), bone area (BA in square millimeters), and bone area over total area (BA/TA in square millimeters). Polar moment of inertia (in millimeters to the fourth power) was also calculated from micro-CT images. Images were thresholded with use of an adaptive-iterative algorithm, and morphometric variables were calculated from the binarized images using direct, three-dimensional techniques that do not rely on any prior assumptions about the underlying structure.

Dual X-Ray Absorptiometry

Bone mineral content (in grams) of the defect region was measured by dual x-ray absorptiometry (Lunar PIXImus II; GE Medical Systems, Madison, Wisconsin). Specimens were placed on a Lucite block during scanning to simulate soft tissue. The scans were acquired with use of the small-animal high-resolution mode.

Ex Vivo Torsion Testing

Specimens were tested to failure in torsion with use of a materials testing system (Synergie 200; MTS Systems, Eden Prairie, Minnesota) to determine the mechanical properties of the healed defect in shear. Before the test, both ends of each specimen were embedded in polymethylmethacrylate to provide a

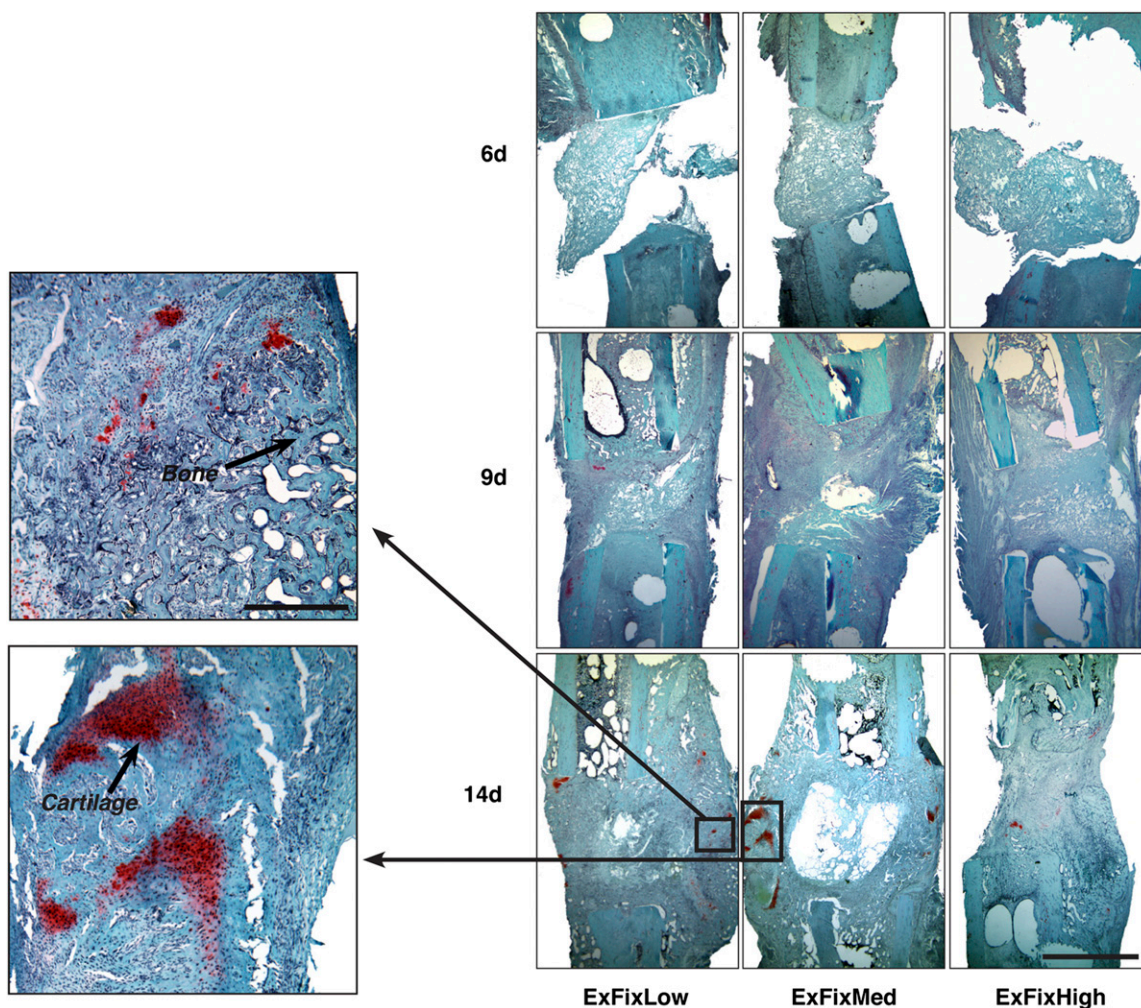


Fig. 2-B
Safranin orange-fast green staining.

reproducible gripping interface with the testing fixture. All femora were tested to failure under regular deformation control and at the constant deformation rate of 5 rad/min. Angular deformation and applied load data were acquired at 10 Hz. The torque and rotation data were used to calculate the torsional stiffness and strength of the healed defect.

Sample Size and Statistical Analysis

The numbers of animals used were determined by our historical data using this model, in which eight to ten animals per group proved adequate²³. A sample-size power analysis showed that the probability of detecting a significant difference with the numbers of animals per group used in our experiments was 95% for all of the imaging (twelve animals) and 85% for mechanical testing data (nine animals). The sample-size study detected a relationship between the independent and dependent variables at a two-sided 5% significance level. The power test confirmed that the animal numbers selected for each modality would be more than sufficient to detect significant differences.

Comparisons of continuous variables between two treatment groups were performed with use of a two-tailed t test, and comparisons between three groups were done with use of one-way analysis of variance. If the difference between the contralateral femur and the treatment groups was significant,

a post hoc (Tukey) test was performed. A power analysis after the study was calculated to determine if we had sufficient animals per group for a significant difference. The power levels for all of the data were found to be from 0.8 to 1. Thus, the numbers of animals per group used in these studies is enough to determine a 5% difference between the test groups. All tests were two-tailed, with differences considered significant at $p < 0.05$. Data are presented as the mean and the standard error of the mean, unless otherwise noted.

Source of Funding

Funding was provided by the AO Foundation (grant S-08-42G), the U.S. Department of Defense (grant W81XWH-10-1-0888), and the National Institute of Arthritis and Musculoskeletal and Skin Diseases, National Institutes of Health (grant R01AR50243).

Results

Pilot Study

To determine a promising time for changing the degree of stiffness and to determine which stiffness fixators to use, we conducted a pilot experiment that focused on the early

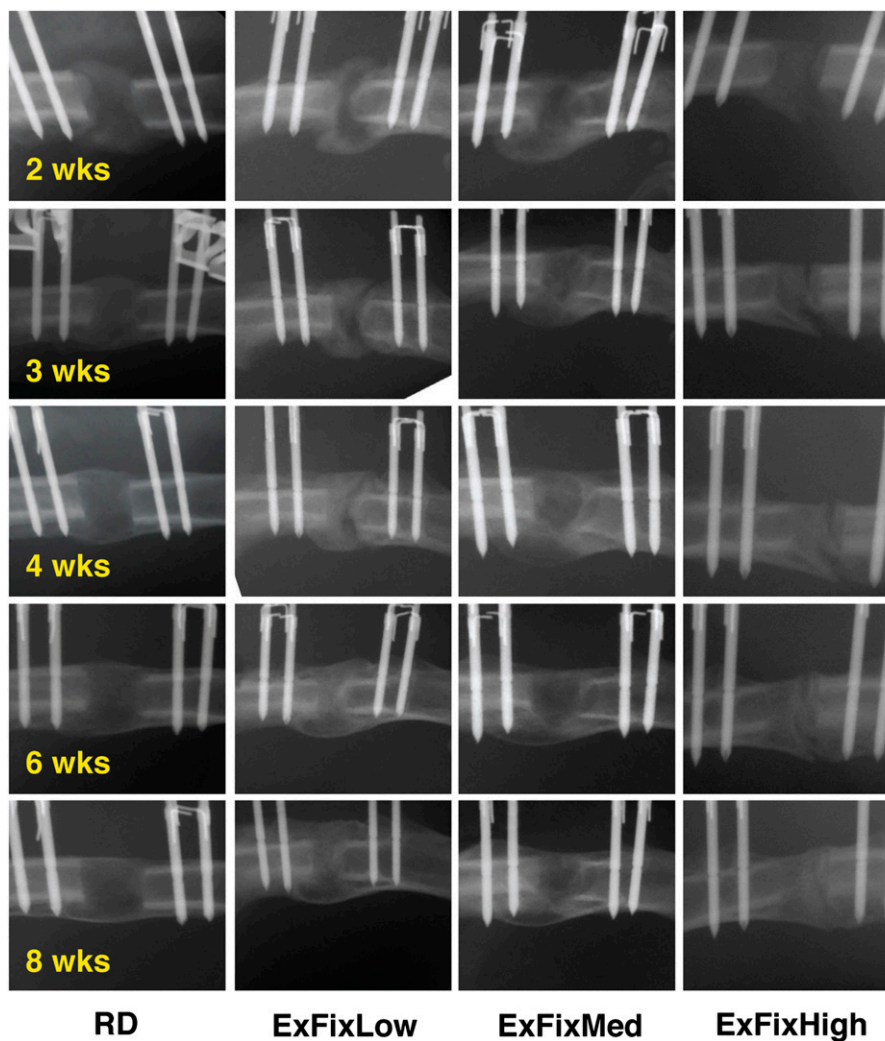


Fig. 3
Serial radiographs of defects stabilized with low (ExFixLow), medium (ExFixMed), and high-stiffness (ExFixHigh) fixators and subjected to reverse dynamization (RD).

events in healing. There were three groups representing rats with segmental defects stabilized by low, medium, or high-stiffness fixators. All experimental defects received BMP-2.

Examination of the radiographic images at day 9 (Fig. 1) shows a faint crescent of radiopacity for the low-stiffness fixator group and, to a lesser degree, the medium-stiffness fixator group in the region opposite to the fixator. Little or no defined radiodensity was evident with the high-stiffness fixator group. At two weeks, this ranking was maintained with diffuse radiopacity in defects stabilized with the high-stiffness fixator and obvious, bridging radiopacity with the low-stiffness and medium-stiffness fixator groups. A visual, qualitative assessment of the radiographs suggested that the size of the radiodense callus was greatest for the low-stiffness fixator group and least for the high-stiffness fixator group.

Qualitative histological examination of the defects during this period was consistent with the radiographic findings (Figs. 2-A and 2-B). Staining with hematoxylin and eosin at six days suggested very little intralesional biological activity, and only the collagen sponge was visible in the defect. In the groups with the two lower-stiffness fixators, there was evidence of a periosteal reaction adjacent to the defect gap around the periosteum.

However, by nine days, the defects were filled with new tissue. In the low-stiffness and high-stiffness fixator groups, there was marked thickening of the periosteum, which appeared

to migrate across the defect forming a bridge of neoperiosteum. This was more prominent on the side opposite to the fixator. With the low-stiffness fixator, and to a lesser extent the medium-stiffness fixator, there was evidence of new bone formation, often around the collagen sponge, with periosteal new bone formation on the bone adjacent to the defect. This presented as the formation of external callus, with the defect gap completely filled with soft tissue. Defects supported by high-stiffness fixators, in contrast, had no external callus and contained only fibrous soft tissue with little evidence of bone. Although, as in the other groups, there was marked woven bone formation along the periosteum adjacent to the defect, bridging did not occur.

At two weeks, qualitative examination of the histological sections suggested there was robust formation of woven bone with the low-stiffness fixator. Defects supported by the high-stiffness fixator appeared to contain only a little bone.

The defects stabilized with the medium-stiffness fixator had a distinctive gap in the middle of the defect. As described in the next section of the Results, the same feature was also observed on histological analysis and micro-CT images at eight weeks. Sections stained with safranin orange-fast green (Fig. 2-B) showed little evidence of cartilage formation, beyond a few isolated flecks, in defects stabilized with any fixator.

On the basis of these data, we decided, for the reverse dynamization stage of this study, to initiate fixation with the

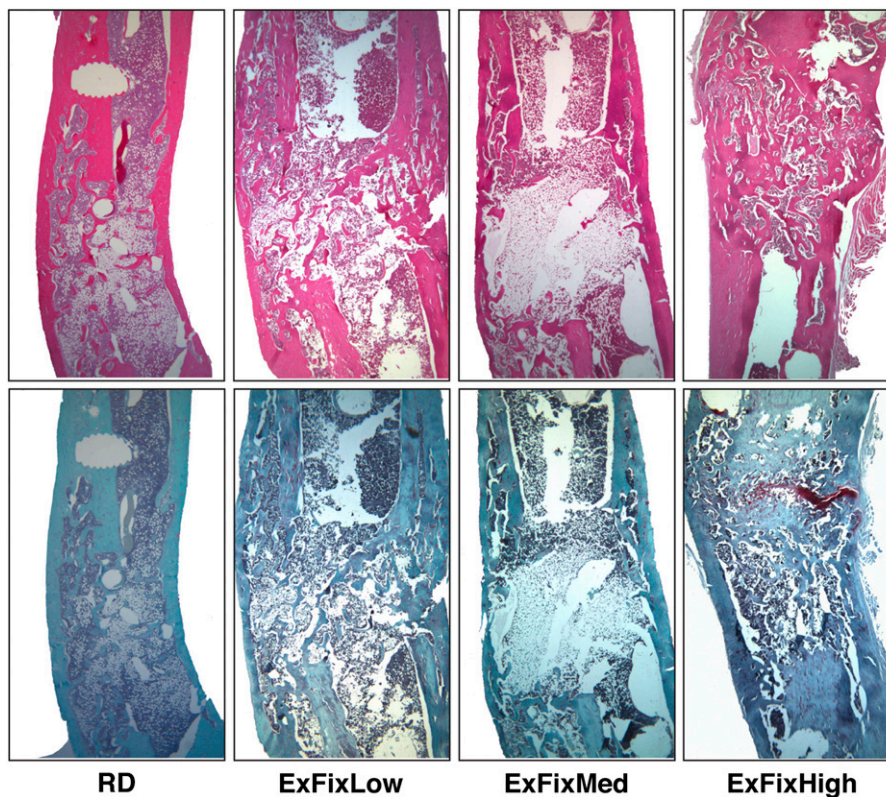


Fig. 4
Histological appearance of defects at eight weeks after stabilization with low (ExFixLow), medium (ExFixMed), and high-stiffness (ExFixHigh) fixators and subjected to reverse dynamization (RD). The top row has hematoxylin and eosin staining, and the bottom row has safranin orange-fast green staining.

low-stiffness fixator because it gave the most rapid early healing and to switch to the high-stiffness fixator at two weeks to promote the subsequent formation and remodeling of bone.

Reverse Dynamization

Control defects that did not receive BMP-2 (see Appendix) did not heal (data not shown). All other groups received BMP-2 (see Appendix) and mounted healing responses that varied

according to the stiffness of the fixator and whether it was dynamized. These responses are described below.

As noted above, two weeks after surgery, the 5-mm defect stabilized with the low-stiffness fixator contained considerable calcified tissue as shown on the radiographs (Figs. 1 and 3). At this point, fixator stiffness was changed from the low-stiffness to the high-stiffness fixator. One week later, the radiographs revealed complete callus bridging with osseous tissue and no

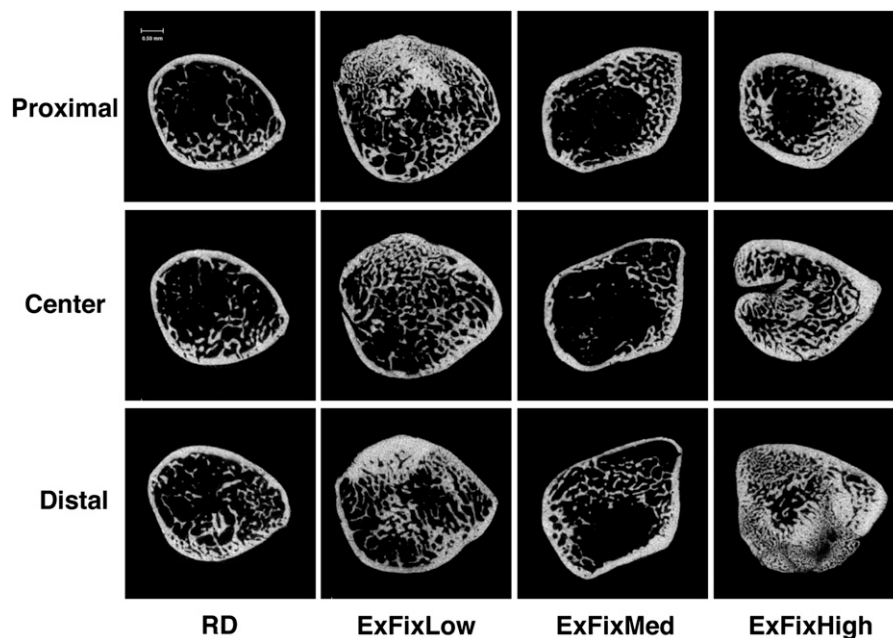


Fig. 5-A

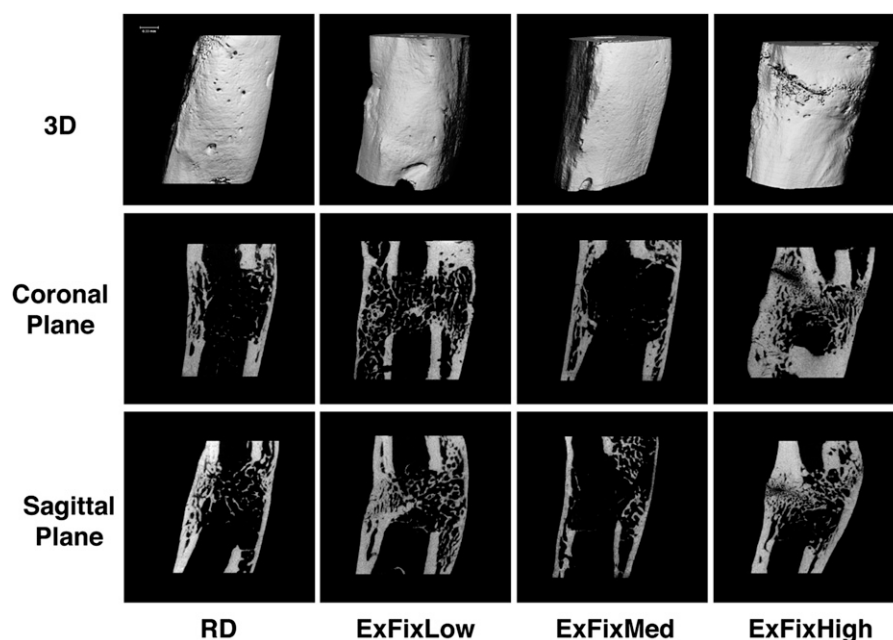


Fig. 5-B

Figs. 5-A and 5-B Microcomputed tomographic images of defects at eight weeks after stabilization with low (ExFixLow), medium (ExFixMed), and high-stiffness (ExFixHigh) fixators and subjected to reverse dynamization (RD). **Fig. 5-A** Cross-sectional images showing the proximal, center, and distal parts of the defect. **Fig. 5-B** Three-dimensional (3D), sagittal, and coronal images.

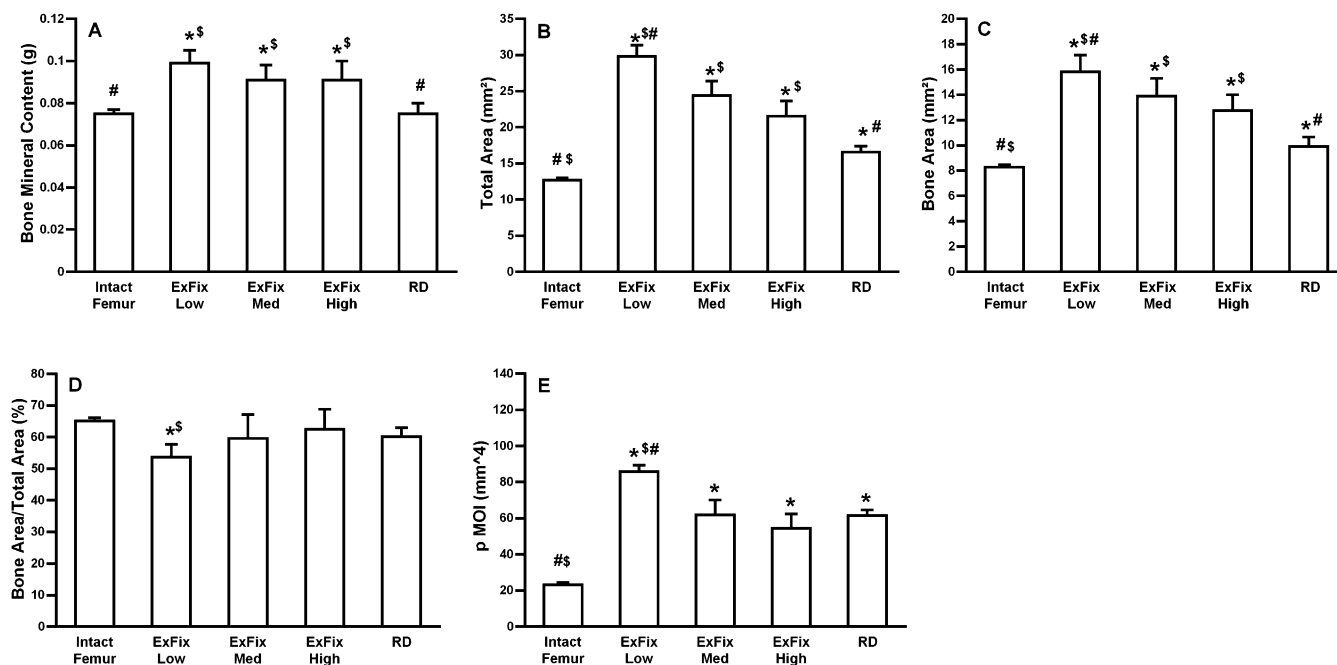


Fig. 6 Effect of low (ExFixLow), medium (ExFixMed), and high-stiffness (ExFixHigh) fixators and reverse dynamization (RD) on dual x-ray absorptiometry and microcomputed tomographic (micro-CT) values at eight weeks. **Fig. 6-A** Bone mineral content (dual x-ray absorptiometry). **Fig. 6-B** Total callus area. **Fig. 6-C** Bone area (micro-CT). **Fig. 6-D** Bone area to total area. **Fig. 6-E** Polar moment of inertia (pMOI; micro-CT). Error bars indicate the standard error of the mean. #Significantly different from ExFixHigh. *Significantly different from intact, contralateral femur. \$Significantly different from reverse dynamization group.

evidence of radiolucent lines in the reverse dynamization group. In contrast, soft tissue persisted until four weeks after the surgery in the defects stabilized with the low-stiffness and medium-stiffness fixators and for at least six weeks after surgery in the defects stabilized with the high-stiffness fixator.

After two weeks, the most obvious radiographic change in the reverse dynamization group was an apparent reduction in the width of the bone in the region of the defect by week 4. This phenomenon was not observed in the low-stiffness and medium-stiffness fixator groups until after six weeks. In the groups with the two lower-stiffness fixators, the width of the bone appeared to increase as healing progressed until the end of treatment, whereas in the group with the most rigid fixator, there was no change throughout the entire experiment.

The radiographs further suggest accelerated formation of new cortices in defects subjected to reverse dynamization. This is supported by the histological findings at eight weeks (Fig. 4). Defects subjected to reverse dynamization appeared to be narrower in cross section and had an organized tissue structure, with better architecture; well-formed, evenly distributed neocortices; and only limited trabecular bone, likely because of advanced remodeling. All other defects had persistent callus and contained disorganized woven bone with poor cortication. Defects stabilized for eight weeks with the medium-stiffness fixator maintained the central gap in the defect that was noted earlier (Figs. 2-A and 2-B) and was surrounded by unmineralized soft tissue. Defects stabilized for eight weeks with the high-stiffness fixator contained a prominent band of car-

tilage (Fig. 4), raising the possibility of development into a nonunion. Cartilage was not seen in any of the other groups at eight weeks.

The main conclusions histologically were confirmed by visual inspection of the high-resolution micro-CT images (Figs. 5-A, 5-B, and 6). The cross-sectional and longitudinal images shown in Figures 5-A and 5-B are consistent with the histological findings in showing more uniform and complete neocortices and less apparent trabecular bone, while appearing smaller in cross section. Reduced cross-sectional area was confirmed quantitatively (Fig. 6). These changes translated into images in which the cortical bone appeared thicker and trabecular bone less abundant compared with the low-stiffness, medium-stiffness, and high-stiffness fixator groups. Furthermore, in the reverse dynamization group, the new cortical bone had an even circumference over the entire length of the healed defect. This was not observed in the groups with constant stiffness.

Quantitative analysis (Fig. 6) confirmed that the bone mineral content of the reversed dynamization group was closer to normal values. The cross-sectional area of bone in the defects healed under reverse dynamization was only 19% higher than normal, whereas the cross-sectional areas in the other groups were considerably higher. The total cross-sectional area of the defects healed under reverse dynamization was also considerably lower. This is consistent with the smaller callus and higher degree of bone formation formed under reverse dynamization. The polar moment of inertia is a quantity used

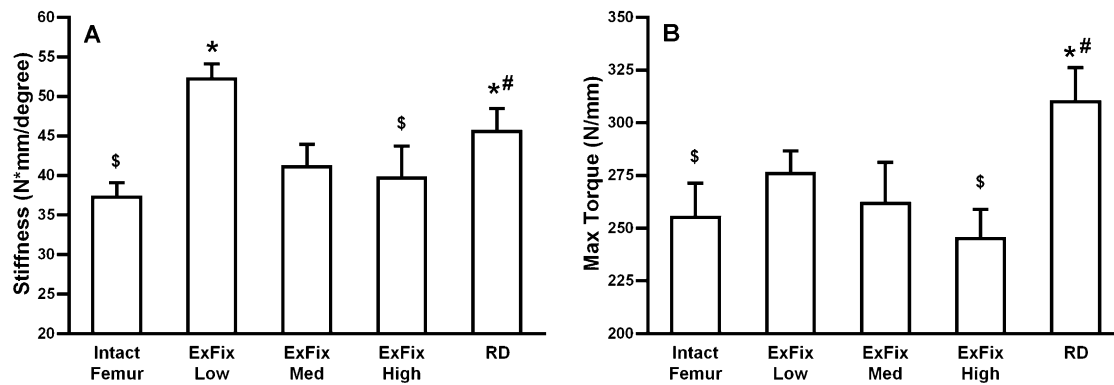


Fig. 7
Effect of low (ExFixLow), medium (ExFixMed), and high-stiffness (ExFixHigh) fixators and reverse dynamization (RD) on mechanical properties at eight weeks, showing data on stiffness (Fig. 7-A) and strength (Fig. 7-B). Error bars indicate the standard error of the mean. #Significantly different from ExFixHigh. *Significantly different from intact, contralateral femur. \$Significantly different from reverse dynamization group.

to predict an object's ability to resist torsion. All experimental groups had polar moment of inertia values greater than those of the control femur.

The femoral defect stiffness following healing under reverse dynamization was significantly higher than that of the intact, contralateral femur and all experimental groups apart from the group stabilized with the low-stiffness fixator (Fig. 7-A). We attribute the high stiffness of the latter to the very large osseous callus (Fig. 4). Although this is disorganized, the sheer mass of bone endows considerable stiffness. Defects healed under conditions of reverse dynamization were considerably stronger than the intact femur and the defects stabilized with low-stiffness, medium-stiffness, and high-stiffness fixators (Fig. 7-B). The combination of high stiffness and unremarkable torque of the defects healed with the low-stiffness fixator means that they are more brittle than normal.

Discussion

These data support our hypothesis that reverse dynamization should improve the healing of a large segmental bone defect, but indicate a different mode of action from the one we suggested. In particular, initial stabilization of the defect with the least stiff of the tested fixators was predicted to promote chondrogenesis. Instead, little evidence of cartilage formation was seen during the first two weeks of healing. It is possible that the times selected for histological analysis (six, nine, and fourteen days) were not appropriate; however, in that case, endochondral bone formation would have to have occurred very rapidly between six and nine days after surgery.

Our erroneous assumption that healing of a large segmental defect in the rat femur in response to BMP-2 would occur via endochondral ossification stems from a report by Yasko et al.¹⁹, who described this process in a similar rat model. Unlike our study, Yasko et al.¹⁹ delivered BMP-2 on a demineralized bone matrix that could have supplied additional growth factors favoring chondrogenesis. Alternatively, mechanical factors may be responsible, given the high sensitivity of this system to the mechanical environment noted in the

present work. Instead of using external fixation, Yasko et al.¹⁹ employed a plate, which was likely quite stiff, although it was not mechanically characterized. In this regard, it is interesting that our stiffest fixator was the only one that led to substantial cartilage deposition.

Histological examination of the early period of healing provided additional valuable information. It was noteworthy that, six days after the insertion of a collagen sponge impregnated with BMP-2, the defects appeared biologically inert and only the sponge was visible. The only obvious biological response was activation of the periosteum adjacent to the cut ends of the defect. It is possible that the sponge prevented the formation of a hematoma and delayed the entry of osteoprogenitor cells. Three days later, the histological findings changed considerably, with defects filled with abundant soft tissue and evidence of osteogenesis in the groups in which low-stiffness and medium-stiffness fixators were used. This is intriguing, given that nearly all of the implanted BMP-2 would have disappeared within the first few days. Further research into the early response of segmental defects to BMP-2 is warranted to provide insight into the mechanism of healing.

The early differences in healing noted with the different fixators were still evident at eight weeks. The low-stiffness fixator produced the largest amount of bone and the high-stiffness fixator, the least. Little or no external callus was visible on radiographs at any time or by micro-CT or histological analysis at eight weeks, and the high-stiffness fixator, unlike the other fixators, generated substantial cartilage. This was evident as a cartilaginous band across the defect at eight weeks and raises concerns about an eventual nonunion. Since this cartilaginous tissue was not seen at the earlier time points (six to fourteen days), its formation appears to be related purely to the mechanical stimuli generated by the fixator and not by the BMP-2, which should have been absent. The medium-stiffness fixator produced the unusual effect of a gap in the center of the defect, which was visible histologically at early time points and was still present at eight weeks, where it could also be seen by micro-CT. This may be related to earlier observations that

healing with BMP-2 produces a “shell” of bone lacking internal osseous structure^{24,25}. Of the fixators used continuously without dynamization during the eight-week experiment, the low-stiffness fixator provided consistently the best healing. This runs counter to the present clinical practice of fixing large segmental bone defects as rigidly as possible.

Reverse dynamization in combination with biological cues (e.g., BMP-2) offers numerous advantages in comparison with traditional bone-grafting techniques. There is no need for microvascular surgery, and donor-site morbidity with vascularized bone transfer and harvesting of cancellous autograft is obviated. Reverse dynamization avoids the pain, discomfort, and prolonged healing with distraction osteogenesis. The proposed method also potentiates the potency of a biological signal delivered to the site of the defect.


Reverse dynamization considerably accelerated maturation of the bone within the defect, which was evidenced on qualitative examination of the histological findings and micro-CT images as advanced formation of neocortices, reduced prominence of trabeculae, uniform contour, and accelerated reduction in apparent callus size. Consistent with these observations, quantitative data confirmed that the bone mineral content and bone area of the defects healed by reverse dynamization was closer to normal and had greater mechanical strength. Only one regimen of reverse dynamization was evaluated in this study, and it is possible that different stiffnesses or timing of reverse dynamization would provide even better results.

Although BMP-2 has shown preclinical efficacy in animal models, the clinical effectiveness of BMP-2 in healing of long bones has been disappointing. Our data suggest that an appropriate mechanical environment is necessary for BMP-2 to be effective, and research into the mechanobiology of cellular responses to BMP-2 could be fruitful. This, in turn, has three main components: mechanosensing, signal transduction, and effector cell response. These have been reviewed recently by Morgan et al.²⁶ in the context of fracture-healing.

Although these experiments used a rat model, the data are clear and unequivocal. The results are likely to be relevant to clinical orthopaedics, and it should be feasible to design and construct variable-stiffness fixators for use in humans. To our

knowledge, we are the first to show that the healing of critical-sized segmental defects is highly responsive to the ambient mechanical environment and does not necessarily follow the same rules as fracture-healing in this regard. Further study of reverse dynamization could lead to improved clinical management of these difficult cases.

Appendix

 A table showing the experimental design is available with the online version of this article as a data supplement at jbjs.org. ■

NOTE: The authors thank Professor Alan Goodship and Professor David Marsh for tea and discussion of this project while in its planning stages. They also thank Professor Frederic Shapiro and Dr. Slobodan Tepic for their review of the data.

Vaida Glatt, PhD
Alan Ivkovic, MD, PhD
Fangjun Liu, MD, PhD
Christopher Evans, PhD
Center for Advanced Orthopaedic Studies,
Beth Israel Deaconess Medical Center,
Harvard Medical School, 330, Brookline Avenue,
RN-115, Boston, MA 02215.
E-mail address for V. Glatt: vglatt@bidmc.harvard.edu

Micah Miller, BS
Mark Vrahas, MD
Harvard Orthopaedic Trauma Service,
Harvard Medical School,
Massachusetts General Hospital,
55 Fruit Street, Boston, MA 02114

Nicola Parry, DVM
Division of Comparative Medicine,
Massachusetts Institute of Technology,
Building 16, Room 825, 77 Massachusetts Avenue,
Cambridge, MA 02139

Damian Griffin, MD
Department of Orthopaedic Surgery,
Warwick University Medical School,
Coventry CV4 7AL, United Kingdom

References

1. Stevenson S. Enhancement of fracture healing with autogenous and allogeneic bone grafts. *Clin Orthop Relat Res.* 1998 Oct;(355 Suppl):S239-46.
2. Watson JT. Distraction osteogenesis. *J Am Acad Orthop Surg.* 2006;14(10 Spec No.):S168-74.
3. Levin LS. Vascularized fibula graft for the traumatically induced long-bone defect. *J Am Acad Orthop Surg.* 2006;14(10 Spec No.):S175-6.
4. Argintar E, Edwards S, Delahay J. Bone morphogenetic proteins in orthopaedic trauma surgery. *Injury.* 2011 Aug;42(8):730-4. Epub 2010 Dec 8.
5. Hernigou P, Poignard A, Beaujean F, Rouard H. Percutaneous autologous bone-marrow grafting for nonunions. Influence of the number and concentration of progenitor cells. *J Bone Joint Surg Am.* 2005 Jul;87(7):1430-7.
6. Masquelet AC, Begue T. The concept of induced membrane for reconstruction of long bone defects. *Orthop Clin North Am.* 2010 Jan;41(1):27-37; table of contents.
7. Khan Y, Yaszemski MJ, Mikos AG, Laurencin CT. Tissue engineering of bone: material and matrix considerations. *J Bone Joint Surg Am.* 2008 Feb;90 Suppl 1:36-42.
8. Quarto R, Mastrogiacomo M, Cancedda R, Kutepov SM, Mukhachev V, Lavroukov A, Kon E, Marcacci M. Repair of large bone defects with the use of autologous bone marrow stromal cells. *N Engl J Med.* 2001 Feb 1;344(5):385-6.
9. Evans C. Gene therapy for the regeneration of bone. *Injury.* 2011 Jun;42(6):599-604. Epub 2011 Apr 13.
10. Perren SM. Evolution of the internal fixation of long bone fractures. The scientific basis of biological internal fixation: choosing a new balance between stability and biology. *J Bone Joint Surg Br.* 2002 Nov;84(8):1093-110.
11. Claes LE, Heigele CA, Neidlinger-Wilke C, Kaspar D, Seidl W, Margevicius KJ, Augat P. Effects of mechanical factors on the fracture healing process. *Clin Orthop Relat Res.* 1998 Oct;(355 Suppl):S132-47.
12. Goodship AE, Cunningham JL, Kenwright J. Strain rate and timing of stimulation in mechanical modulation of fracture healing. *Clin Orthop Relat Res.* 1998 Oct;(355 Suppl):S105-15.
13. Goodship AE, Kenwright J. The influence of induced micromovement upon the healing of experimental tibial fractures. *J Bone Joint Surg Br.* 1985 Aug;67(4):650-5.

- 14.** Kenwright J, Goodship AE. Controlled mechanical stimulation in the treatment of tibial fractures. *Clin Orthop Relat Res.* 1989 Apr;(241):36-47.
- 15.** Perren SM, Rahn BA. Biomechanics of fracture healing. *Can J Surg.* 1980 May;23(3):228-32.
- 16.** Larsson S, Kim W, Caja VL, Egger EL, Inoue N, Chao EY. Effect of early axial dynamization on tibial bone healing: a study in dogs. *Clin Orthop Relat Res.* 2001 Jul;(388):240-51.
- 17.** Claes L, Blakytyn R, Göckelmann M, Schoen M, Ignatius A, Willie B. Early dynamization by reduced fixation stiffness does not improve fracture healing in a rat femoral osteotomy model. *J Orthop Res.* 2009 Jan;27(1):22-7.
- 18.** Claes L, Blakytyn R, Besse J, Bausewein C, Ignatius A, Willie B. Late dynamization by reduced fixation stiffness enhances fracture healing in a rat femoral osteotomy model. *J Orthop Trauma.* 2011 Mar;25(3):169-74.
- 19.** Yasko AW, Lane JM, Fellinger EJ, Rosen V, Wozney JM, Wang EA. The healing of segmental bone defects, induced by recombinant human bone morphogenetic protein (rhBMP-2). A radiographic, histological, and biomechanical study in rats. *J Bone Joint Surg Am.* 1992 Jun;74(5):659-70.
- 20.** Schätti O, Grad S, Goldhahn J, Salzmann G, Li Z, Alini M, Stoddart MJ. A combination of shear and dynamic compression leads to mechanically induced chondrogenesis of human mesenchymal stem cells. *Eur Cell Mater.* 2011 Oct 11;22:214-25.
- 21.** Glatt V, Evans CH, Matthys R. Design, characterisation and in vivo testing of a new, adjustable stiffness, external fixator for the rat femur. *Eur Cell Mater.* 2012 Apr 21;23:289-98; discussion 299.
- 22.** Betz OB, Betz VM, Nazarian A, Pilapil CG, Vrahas MS, Bouxsein ML, Gerstenfeld LC, Einhorn TA, Evans CH. Direct percutaneous gene delivery to enhance healing of segmental bone defects. *J Bone Joint Surg Am.* 2006 Feb;88(2):355-65.
- 23.** Glatt V, Kwong FN, Park K, Parry N, Griffin D, Vrahas M, Evans CH, Harris M. Ability of recombinant human bone morphogenetic protein 2 to enhance bone healing in the presence of tobramycin: evaluation in a rat segmental defect model. *J Orthop Trauma.* 2009 Nov-Dec;23(10):693-701.
- 24.** Lieberman JR, Daluiski A, Stevenson S, Wu L, McAllister P, Lee YP, Kabo JM, Finerman GA, Berk AJ, Witte ON. The effect of regional gene therapy with bone morphogenetic protein-2-producing bone-marrow cells on the repair of segmental femoral defects in rats. *J Bone Joint Surg Am.* 1999 Jul;81(7):905-17.
- 25.** Carragee EJ, Hurwitz EL, Weiner BK. A critical review of recombinant human bone morphogenetic protein-2 trials in spinal surgery: emerging safety concerns and lessons learned. *Spine J.* 2011 Jun;11(6):471-91.
- 26.** Morgan EF, Gleason RE, Hayward LN, Leong PL, Palomares KT. Mechanotransduction and fracture repair. *J Bone Joint Surg Am.* 2008 Feb;90 Suppl 1:25-30.