

First Case Report of SAM® Junctional Tourniquet Use in Afghanistan to Control Inguinal Hemorrhage on the Battlefield

Jeffrey K. Klotz, MD; Maura Leo, BSN, RN, CEN; Brent L. Andersen, Jr.; Adrien A. Nkodo; Gaston Garcia; Amanda M. Wichern; Michael J. Chambers; Ohmar N. Gonzalez; Mason U. Pahle; Joshua A. Wagner; John Robinson, PA; John F. Kragh, Jr., MD

ABSTRACT

Junctional hemorrhage, bleeding that occurs at the junction of the trunk and its appendages, is the most common preventable cause of death from compressible hemorrhage on the battlefield. As of January 2014, four types of junctional tourniquets have been developed and cleared by the U.S. Food and Drug Administration (FDA). Successful use of the Abdominal Aortic Tourniquet (AAT™) and Combat Ready Clamp (CRoC™) has already been reported. We report here the first known prehospital use of the SAM® Junctional Tourniquet (SJT) for a battlefield casualty with inguinal junctional hemorrhage.

KEYWORDS: SAM® Junctional Tourniquet, junctional hemorrhage, prehospital care, hemorrhage control, wounds and injuries

Introduction

In *Black Hawk Down: A Story of Modern War*, Mark Bowden recounts the frantic attempts by Sergeant First Class Kurt Schmid, a highly trained Special Operations Forces (SOF) medic, to save the life of Corporal “Jamie” Smith after he began hemorrhaging on the streets of Mogadishu, Somalia, from a gunshot wound to his proximal thigh in 1993. Despite Schmid’s heroic efforts and aggressive countermeasures to stop the bleeding, Smith eventually exsanguinated from his wound over a few hours. Smith’s death and other tragic, “excruciatingly painful and obviously ineffective” experiences with controlling junctional hemorrhage, specifically bleeding that occurs at the junction of the trunk and its appendages, have been the impetus for the U.S. military to develop interventions to treat these life-threatening injuries.¹⁻³ In the current war in Afghanistan, most casualties with potentially survivable injuries die from hemorrhage.⁴ As the use of extremity tourniquets became widespread, junctional hemorrhage became the most common preventable cause of death on the battlefield.⁵ This urgent operational and clinical capability gap led

to the development of junctional tourniquets to control hemorrhage in this anatomically complex and clinically challenging body region.

As of January 2014, four devices have been cleared by the FDA for junctional hemorrhage control: (1) AAT™, which was recently renamed the Abdominal Aortic and Junctional Tourniquet [AAJT™] (Compression Works, Birmingham, AL, USA; <http://www.compressionworks.net/>); (2) CRoC™ (Combat Medical Systems, Fayetteville, NC, USA; <http://www.combatmedicalsystems.com/>); (3) Junctional Emergency Treatment Tool (JETT™, North American Rescue Products, Greer, SC, USA; <http://www.narescue.com/>); and (4) SJT (SAM Medical Products, Wilsonville, OR; <http://www.sammedical.com/>) (Table 1). The SJT also is cleared by the FDA for the treatment of suspected pelvic fractures. Successful use of both the AAT and the CRoC on casualties with junctional hemorrhage in both military and civilian settings has been reported.⁶⁻⁹ Current U.S. Army Tactical Combat Casualty Care Guidelines recommend the immediate application of a Committee on Tactical Combat Casualty Care (CoTCCC)-recommended junctional tourniquet if the bleeding site is appropriate for its use.¹⁰ We report here the first prehospital use of the SJT with the intent of increasing awareness of this innovative method of junctional hemorrhage control.

Technique of Use:

To Control Difficult Bleeds in the Inguinal Area¹¹

- Slide the belt underneath the patient, positioning the target compression device (TCD) over the area to be compressed (Figure 1).
- Use sterile gauze or hemostatic dressing if targeting directly over a wound.
- For bilateral application, use a second TCD.
- Hold the TCD in place and connect the belt using the buckle (Figure 2).

Report Documentation Page

Form Approved
OMB No. 0704-0188

Public reporting burden for the collection of information is estimated to average 1 hour per response, including the time for reviewing instructions, searching existing data sources, gathering and maintaining the data needed, and completing and reviewing the collection of information. Send comments regarding this burden estimate or any other aspect of this collection of information, including suggestions for reducing this burden, to Washington Headquarters Services, Directorate for Information Operations and Reports, 1215 Jefferson Davis Highway, Suite 1204, Arlington VA 22202-4302. Respondents should be aware that notwithstanding any other provision of law, no person shall be subject to a penalty for failing to comply with a collection of information if it does not display a currently valid OMB control number.

1. REPORT DATE 02 JUN 2014		2. REPORT TYPE N/A		3. DATES COVERED -	
4. TITLE AND SUBTITLE First Case Report of SAM? Junctional Tourniquet Use in Afghanistan to Control Inguinal Hemorrhage on the Battlefield				5a. CONTRACT NUMBER	
				5b. GRANT NUMBER	
				5c. PROGRAM ELEMENT NUMBER	
6. AUTHOR(S) Klotz J. K., Leo M., Anderson B. L., Nkodo A. A., Garcia G., Wichern A. M., Chambers M. J., Gonzalez O. N., Pahle M. U., Wagner J. A., Robinson J., Kragh Jr. J. F.,				5d. PROJECT NUMBER	
				5e. TASK NUMBER	
				5f. WORK UNIT NUMBER	
7. PERFORMING ORGANIZATION NAME(S) AND ADDRESS(ES) United States Army Institute of Surgical Research, JBSA Fort Sam Houston, Tx 78234				8. PERFORMING ORGANIZATION REPORT NUMBER	
9. SPONSORING/MONITORING AGENCY NAME(S) AND ADDRESS(ES)				10. SPONSOR/MONITOR'S ACRONYM(S)	
				11. SPONSOR/MONITOR'S REPORT NUMBER(S)	
12. DISTRIBUTION/AVAILABILITY STATEMENT Approved for public release, distribution unlimited					
13. SUPPLEMENTARY NOTES					
14. ABSTRACT					
15. SUBJECT TERMS					
16. SECURITY CLASSIFICATION OF:			17. LIMITATION OF ABSTRACT UU	18. NUMBER OF PAGES 6	19a. NAME OF RESPONSIBLE PERSON
a. REPORT unclassified	b. ABSTRACT unclassified	c. THIS PAGE unclassified			

Table 1 *SJT Data*

SAM® Junctional Tourniquet manufacturer	SAM Medical Products, Wilsonville, OR
National Stock Number (NSN)	6515-01-618-7475
U.S. Food and Drug Administration clearance date and number	24 July 2013; No. K131561
Indication labeling	Difficult inguinal bleeds; difficult axilla bleeds; pelvic fracture immobilization
Cost (USD, estimated for the U.S. Government)	\$292.50

Figure 1 Slide the belt underneath the patient, positioning the target compression device (TCD) over the area to be compressed.

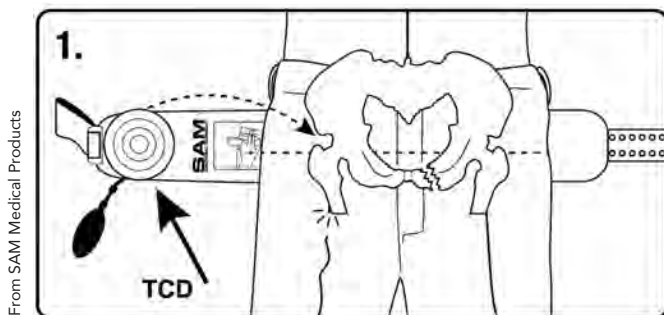
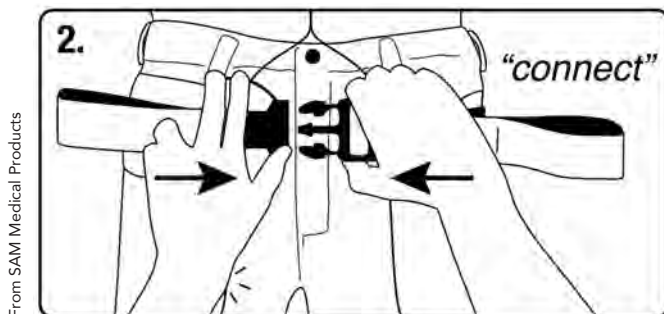


Figure 2 Hold the TCD in place and connect the belt using the buckle.



- Pull the brown handles away from each other until the buckle secures. An audible click will be heard when the buckle secures (Figure 3).
- Fasten excess belt in place by pressing it down on the Velcro.
- A second audible click may be heard once the belt is secure.
- Use the hand pump to inflate the TCD until hemorrhage stops (Figure 4).
- Monitor patient during transport for hemorrhage control and adjust the device if necessary.
- To remove the tourniquet, unbuckle the belt.

Figure 3 Pull the brown handles away from each other until the buckle secures. An audible click will be heard when the buckle secures.

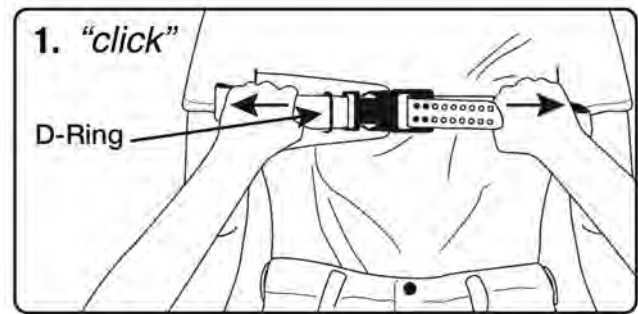
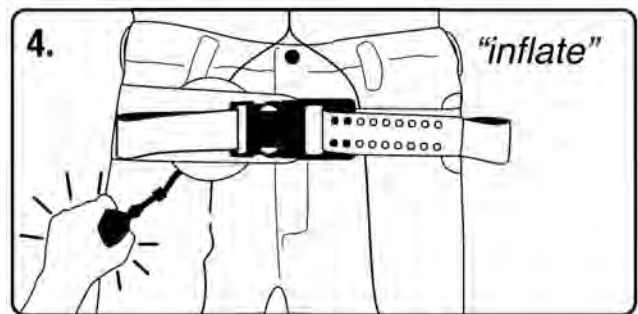


Figure 4 Use the hand pump to inflate the TCD until hemorrhage stops.



Case Presentation

In January 2014, an Afghan National Army (ANA) soldier (approximately 20 years old) sustained a gunshot wound to his left proximal thigh during a firefight with insurgents near a village in Afghanistan. After the firefight ended, he was transported by ground vehicle to the Afghan side of the Combined United States–Afghan National Army Aid Station for further treatment. The casualty was alert and oriented but with mild hypoxia and significant pain. A makeshift cloth bandage and a Combat Application Tourniquet (C-A-T®, Composite Resources, Rock Hill, SC, USA; <http://compositere-sources.com>) were applied directly over the casualty's entry wound. The casualty's pants were soaked in blood with minimal bleeding seen near the edges of the C-A-T. The ANA soldiers who transported him to the Aid Station reported that the time of injury was 1 hour before arrival but did not know the time when the C-A-T was placed. After maximal exposure was achieved, the location of the wound was seen as too proximal on his leg to allow the C-A-T to be placed above the wound.

Because of concern that the C-A-T would not be able to prevent additional blood flow to the wound, it was removed after QuikClot® Combat Gauze™ (Z-Medica, Wallingford, CT, USA; www.z-medica.com/healthcare) and roll gauze dressings were prepared. Within seconds of removal of the C-A-T, a stream of bright red blood

gushed into the air above the entry wound, suggestive of active arterial bleeding. There was no evidence of an exit wound where the C-A-T had been covering the posterior aspect of the upper leg, implying that the bullet remained in the casualty's leg and could possibly have caused a proximal femur fracture or entered the casualty's pelvis. There was no clinical evidence of pelvic instability on physical examination. A medic immediately applied direct manual pressure to the wound (Figure 5) while another medic applied pressure to the left inguinal area with a pressure board, an improvised device consisting of a piece of plywood wrapped in SAM splint secured with duct tape; pressure board use augments application of direct pressure to vascular pressure points. A third medic was dispatched to the American side of the aid station to retrieve the SJT. After approximately 3 minutes of direct manual pressure, the entry wound was packed with Combat Gauze while continued pressure was applied to the femoral area with the pressure board. A pressure dressing using roll gauze and a compression wrap was applied to the packed wound. The casualty was then briefly lifted from the litter to slide the SJT under his pelvis, where it was connected, tightened, and inflated to a sufficient pressure to eliminate peripheral pulses in the left leg (Figure 6).

The time required to apply the SJT was approximately 3 minutes. This reflects the total time from the moment the SJT was brought into the ANA trauma room until it was secured. The small space between the trauma beds required the American medics to take some time to manage the ANA medics who were hovering at their elbows (Figure 5). There was also a brief delay in communication, which went through the interpreter to the ANA medics when the U.S. medics were about to lift the patient to place the SJT, a device with which they were unfamiliar. When the casualty was initially lifted,

Figure 5 Medic applying immediate manual pressure to wound to control heavy arterial bleeding after removal of C-A-T.

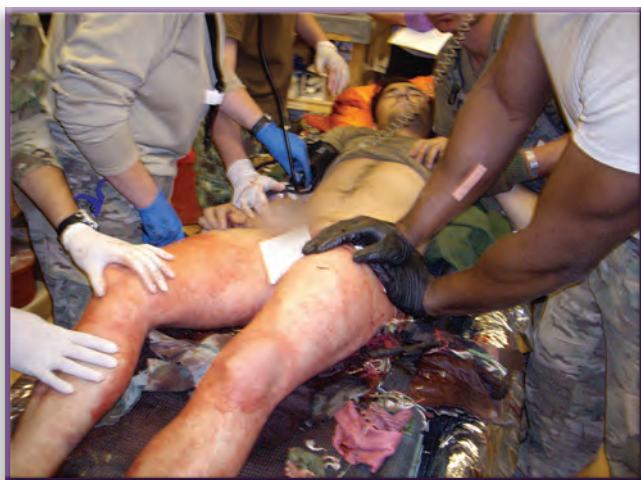
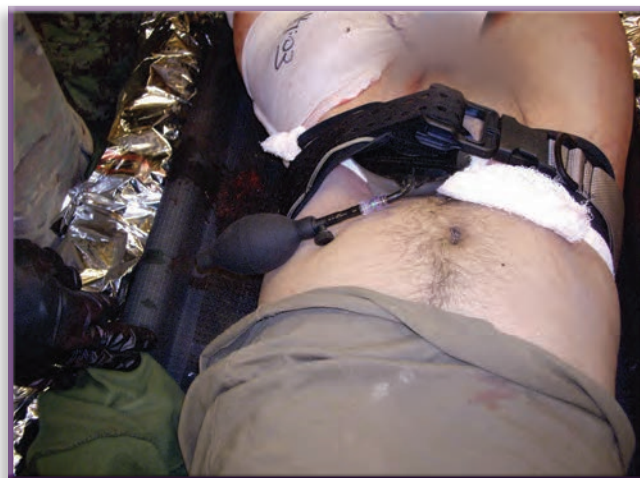
Figure 6 SJT secured and maximally inflated over the left femoral area to control hemorrhage.



the SJT was placed slightly proximal to the position to compress the femoral area. Therefore, the SJT had to be slid down distal to the casualty's pelvis. Also, the casualty himself, while not truly combative, was not particularly cooperative in the process despite the intravenous narcotic analgesics and reassurances from the interpreter and the Afghan medics. Finally, because the hemorrhage had diminished after the Combat Gauze packing and pressure dressing use, there was slightly less urgency to the rapidity of placing the SJT. The actual time to secure the SJT, once properly positioned, was about 60 seconds.

Shortly after the placement of the SJT, the enroute critical care nurse (ECCN) and flight medic arrived at the aid station to prepare the casualty for the MEDEVAC flight. Peripheral intravenous catheter access was established but lost in both the left and right arms during the course of the resuscitation. Right tibial intraosseous access was established using an EZ-IO® Intraosseous Infusion System (Vidacare, San Antonio, TX, USA; <http://www.vidacare.com/>) just before departure of the MEDEVAC flight to an Afghan hospital. During the majority of the 15-minute MEDEVAC flight, the casualty remained hemodynamically stable with a suboptimal oxygen saturation (85–88%) despite supplemental oxygen at 15L/min. Within 5 minutes of landing at the Afghan hospital, the casualty developed increased work of breathing as evidenced by abdominal retractions with a decreased level of consciousness. Radial pulses weakened but the carotid pulse remained strong. The left leg's distal pulses, however, were detected by manual palpation by the ECCN. Reassessment of the wound site and bandage revealed no evidence of hemorrhage, no swelling of the proximal leg, and the SJT remained in place. At that point, blood transfusion was considered prior to landing but the estimated time of arrival to the Afghan hospital was less than 2 minutes. The casualty was

transferred to the care of the Afghan physicians, who performed urgent surgical intervention. He ultimately required 10U of transfused blood and recovered sufficiently to be transferred to another Afghan hospital for further treatment and rehabilitation 5 days after the injury.

Discussion

This case is the first reported use to our knowledge of the SJT being used for life-threatening junctional hemorrhage in the prehospital setting. As use of the various available junctional tourniquets increases, it is essential that the initial experiences with these devices be reported to increase awareness of their availability and capacity to treat these complex casualties. This practical, “real world” experience regarding the advantages and disadvantages of these devices in turn may lead to improved training beyond what can be accomplished in a simulated setting for emergency healthcare personnel who may be required to use a junctional tourniquet on a casualty in either the military or civilian setting¹³⁻¹⁵ (Table 2).

One of the primary advantages of the SJT in the present case was the relative ease in learning how to use the device. The medics who successfully used the SJT had only received the device approximately 1 month prior to using it on this casualty. After simply reading the “Instructions For Use” included with the tourniquet, they were able to master its application and subsequently performed periodic drills to reduce the time required to secure the device. During these drills, they refined their ability to keep the inflatable Target Compression Device (TCD) properly positioned over the common femoral artery where the femoral pulse is palpated. They noted that sometimes the TCD shifted in position as the tourniquet belt handles were pulled asymmetrically to tighten the belt (if the pulls are symmetrically counterbalanced

when tensioning the belt, then the TCD stays in place and this pitfall is avoided).

Regarding the return of distal pulses during the MEDEVAC flight, collateral arterial flow around the common femoral pressure point may occur by way of other arteries to the lower extremity, and such collateral flow may allow the pulse to become palpable distally. Swan et al.¹² described this phenomenon in normal human subjects with pressure point compression, but in the present case hemorrhage control was maintained by such compression while collateral flow was observed. The casualty experienced no complication from either the hemorrhage control or the collateral flow.

Another advantage particularly relevant to this casualty is the SJT’s ability to act as a pelvic splint. Although this casualty did not have obvious pelvic instability by manual assessment to suggest a pelvic fracture, there was no exit wound present. It is possible that the bullet struck the femur and entered the pelvis causing further vascular damage and hemorrhage. If intrapelvic hemorrhage occurred, the SJT’s pelvic splint effect may have diminished further blood loss. In addition to the blood loss from the initial injury, the possibility of intrapelvic hemorrhage may have accounted for the casualty’s persistent mild hypoxia and mild clinical decompensation near the end of the MEDEVAC flight.

The present case reported is similar to that of Corporal “Jamie” Smith except that with the passage of 20 years, dedicated junctional hemorrhage control research has moved the trauma field beyond past ineffective measures toward the current device-based interventions that may lead to saved lives on the battlefield. Future directions for further work include increasing awareness of the capacity to control prehospital junctional bleeding; awareness may be improved by better logistics, refined training, and more research and development.

Table 2 Advantages and disadvantages of interventions learned in initial laboratory use*

Intervention	Advantages	Disadvantages
Digital compression	Fast, easiest to target, one-handed	Smallest muscles tire fastest
Manual compression	Heels of hands work quickly	If two hands are used, no hand is free
Knee compression	Powerful, sustained, no hands	Clumsy, can obscure wound
Kettlebell	Fast, rounded edges, frees one hand	Heavy, tilts, one hand to steady
CRoC	First available, best known device	Disc can fall, has the most steps
SJT	Fast, may use binder on pelvis	Newest, least known device
JETT	Harness may splint a pelvis fracture	Disc can fall, two straps, two discs
AAT	Targets pressure point broadly	May block vena cava

Note: *Adapted from Kragh et al.¹³ with permission.

References

1. Bowden M. *Black Hawk down: a story of modern war*. New York, NY: Penguin Group; 2000.
 2. Blackburne LH, Mabry R, Sebesta J, Holcomb JH. Joseph Lister, non-compressible arterial hemorrhage and the next generation of “tourniquets?” *J Army Med Dept*. 2008;56–69.
 3. Kragh JF Jr, Murphy C, Dubmic MA, et al. New tourniquet concepts for battlefield hemorrhage control. *US Army Med Dept J*. 2011;38–48.
 4. Eastridge BJ, Mabry R, Seguin P, et al. Death on the battlefield (2011–2011): implications for the future of combat casualty care. *J Trauma Acute Care Surg*. 2012;73: S431–S437.
 5. Kotwal RS, Butler FK, Gross KR, et al. Management of junctional hemorrhage in tactical combat casualty care: TCCC guidelines—proposed change 13-03. *J Spec Oper Med*. 2013;13:85–93.
 6. Anonymous. Abdominal Aortic Tourniquet use in Afghanistan. *J Spec Oper Med*. 2013;13:1–2.
 7. Croushorn J, McLester J, Thomas G, McCord SR. Abdominal Aortic Tourniquet controls junctional hemorrhage from a gunshot wound of the axilla. *J Spec Oper Med*. 2013;13:1–4.
 8. Tovmassian RV, Kragh JF Jr, Dubick MA, et al. Combat Ready Clamp medic technique. *J Spec Oper Med*. 2012 12:72–78.
 9. Gates KS, Baer L, Holcomb JB. Prehospital emergency care evaluation of the Junctional Emergency Treatment Tool with a perfused cadaver model. Podium presentation at the Scientific Assembly of the Special Operations Medical Association, Tampa, FL, 2013.
 10. Committee on Tactical Combat Casualty Care, Tactical Combat Casualty Care Guidelines. 28 Oct 2013. http://www.health.mil/Education_And_Training/TCCC.aspx.
 11. SAM Junctional Tourniquet Instructions for Use. <http://www.sammedical.com/wp-content/uploads/2013/11/SJT-207-IFU-01-BW.pdf>.
 12. Swan KG Jr, Wright DS, Barbagiovanni SS, et al. Tourniquets revisited. *J Trauma*. 2009;66:672–675.
 13. Kragh JF, et al. Laboratory assessment of out-of-hospital interventions to control junctional bleeding from the groin in a manikin model. *Am J Emerg Med*. 2013. <http://dx.doi.org/10.1016/j.ajem.2013.03.021>.
 14. Kragh JF, et al. Prehospital emergency inguinal clamp controls hemorrhage in cadaver model. *Mil Med*. 2013; 178:799–805.
 15. Mann-Salinas EA, Kragh JF, Dubick MA, et al. Assessment of users to control simulation junctional hemorrhage with the Combat Ready Clamp (CRoC™). *Int J Burn Trauma*. 2013;3:49–54.
- LTC Klotz** is a hematologist/oncologist at Madigan Army Medical Center, Joint Base Lewis-McChord, Washington. He was deployed in Afghanistan as the surgeon with 3rd Squadron, 2nd Cavalry Regiment from Vilseck, Germany, 2013–2014.
- CPT Leo** is an emergency department nurse at William Beaumont Army Medical Center, Fort Bliss, Texas. She was deployed as an enroute critical care nurse in Regional Command-South, Afghanistan, 2013–2014.
- SSG Andersen** is a medical platoon sergeant. He was deployed in Afghanistan with 3rd Squadron, 2nd Cavalry Regiment from Vilseck, Germany, 2013–2014.
- SGT Nkodo** is a medical treatment team leader. He was deployed in Afghanistan with 3rd Squadron, 2nd Cavalry Regiment from Vilseck, Germany, 2013–2014.
- SGT Garcia** is a flight medic. He was deployed in Afghanistan with 1st Combat Aviation Brigade, 1st Infantry Division from Fort Riley, Kansas, 2013–2014.
- SGT Wichern** is a medical treatment team leader. She was deployed in Afghanistan with 3rd Squadron, 2nd Cavalry Regiment from Vilseck, Germany, 2013–2014.
- SPC Chambers** is a combat medic. He was deployed in Afghanistan with 3rd Squadron, 2nd Cavalry Regiment from Vilseck, Germany, 2013–2014.
- SPC Gonzalez** is a combat medic. He was deployed in Afghanistan with 3rd Squadron, 2nd Cavalry Regiment from Vilseck, Germany, 2013–2014.
- PFC Pahle** is a combat medic. He was deployed in Afghanistan with 3rd Squadron, 2nd Cavalry Regiment from Vilseck, Germany, 2013–2014.
- PFC Wagner** is a combat medic. He was deployed in Afghanistan with 3rd Squadron, 2nd Cavalry Regiment from Vilseck, Germany, 2013–2014.
- MAJ Robinson** is a physician assistant working as the OIC for the Combat Casualty Care Course (C4). He was deployed as the USFOR-Afghanistan pre-hospital coordinator/director for the Joint Theater Trauma System, 2013–2014.
- Dr. Kragh** is a former 3rd Ranger Battalion Surgeon and is now an Army hemorrhage control researcher, Damage Control Resuscitation, U.S. Army Institute of Surgical Research, JBSA Fort Sam Houston, Texas.

Copyright of Journal of Special Operations Medicine is the property of Breakaway Media, LLC and its content may not be copied or emailed to multiple sites or posted to a listserv without the copyright holder's express written permission. However, users may print, download, or email articles for individual use.