

The Potential Utility of Fibrin Sealant Dressing in Repair of Vascular Injury in Swine

Bijan S. Kheirabadi, PhD, Eric M. Acheson, MD, Rodolfo Deguzman, MS, Jacqueline M. Crissey, BS, Angel V. Delgado, PhD, Scot J. Estep, DVM, and John B. Holcomb, MD

Background: A previous study in which fibrin sealant dressing (FSD) secured hemostasis in major arterial hemorrhage for 96 hours suggested the applicability of this dressing in damage control operations after severe trauma. The objective of this study was to determine the effective duration of FSD hemostatic function in vivo and to examine its potential utility for definitive repair of a major arterial injury in swine.

Methods: High pressure bleeding in an infrarenal aortotomy was controlled by placing FSD on the wound with 4-minute compression (n = 15). If hemostasis was achieved, the abdominal cavity was closed. Surviving animals were killed at 2, 4, 6, and 8 weeks and aortotomy sites collected for histology.

Results: FSD stopped arterial hemorrhage after 4-minute compression in 14 of 15 (93%) pigs. Dressings failed in two pigs at 36 and 53 minutes after treatment. Twelve (80%) animals recovered and resumed normal activities. Of the remaining 12, two developed rebleeding at the aortotomy site on days 8 and 11 and were killed; another was killed because of idiopathic low hematocrit on day 10. Nine pigs survived until scheduled to be killed, maintaining hemostasis with stable hematological values. In the surviving animals, serial computed tomography scans showed formation of a pseudoaneurysm at the aortotomy site, which resolved after 2 to 3 weeks. The initial vascular defect and pseudoaneurysm were filled with fibroblast-

myoblast collagen rich tissues covered by endothelium.

Conclusion: FSD can seal an arterial injury, stop high pressure bleeding, and prevent rebleeding for at least 7 days. The dressing may be most beneficial in damage control operations. If combined with an elective interventional radiologic procedure (e.g. embolization or stenting), it may also offer an alternative to suture repair of vascular injuries in cases where profuse bleeding obstructs visualization.

Key Words: Hemostasis, Hemorrhage control, Fibrin sealant, Dressing, Sutureless, Vascular repair, Pseudoaneurysm, Animals, Swine.

J Trauma. 2007;62:94–103.

Hemorrhage control plays a central role in trauma medicine. Researchers have invested substantial effort in developing new strategies to decrease prehospital and in-hospital bleeding in trauma patients. The majority of these modalities amplify the patient's own hemostatic mechanisms. Another group of hemostatic agents stops bleeding by binding to damaged tissues and sealing transected vessels. Unlike the former group, the sealant effects of these agents persist even when the patient's blood coagulation is severely compromised.^{1,2} One example of this group is liquid fibrin sealant (LFS), widely used in elective cardiovascular operations.³ However, the inherent difficulties in the storage and preparation of this agent have made LFS less attractive

for use in trauma care. Alternatively, fibrin sealant dressing (FSD) is a ready-to-use hemostatic product that is stable at room temperature, fully absorbable and requires no mixing or preparation before application.⁴ FSD is suitable for both field medical (prehospital) and conventional surgical applications.^{5,6} Upon contact with blood, the dressing's fibrinogen and thrombin components, derived from human plasma, dissolve rapidly and react to form an adherent fibrin layer that binds tightly to damaged tissues. The dressing is capable of stopping the most profuse and lethal arterial bleeding,^{7,8} as well as high flow venous bleeding from a complex liver injury in large animals with coagulopathy.⁹ Its long-term effects on wound healing have been demonstrated in intra-operative bleeding in a prostatectomy, partial nephrectomy and grade IV kidney stab-wound in large animals.^{10–12}

In a previous study, we examined the ability of FSD to stop a lethal arterial bleeding and to maintain hemostasis in fully conscious and ambulatory swine for 96 hours.¹³ FSD was compared with chitosan dressing, a novel FDA-approved hemostatic dressing that is widely distributed among the armed forces for hemorrhage control of external wounds. Chitosan dressing had previously demonstrated efficacy in severe venous bleeding from a grade V liver injury in swine for 1 hour.¹⁴ In the arterial model, the chitosan dressing stopped hemorrhage in 71% of cases, far better than the Army's standard gauze dressing (0%). However, it failed to

Submitted for publication July 27, 2006.

Accepted for publication October 19, 2006.

Copyright © 2007 by Lippincott Williams & Wilkins, Inc.

From the United States Army Institute of Surgical Research, Fort Sam Houston, Texas.

The opinions or assertions expressed herein are the private views of the authors and are not to be construed as official or as reflecting the views of the United States Department of the Army or the United States Department of Defense.

Presented as a poster at 64th Annual Meeting of the American Association for the Surgery of Trauma, September 22–24, 2005, Atlanta, Georgia.

Address for reprints: Bijan S. Kheirabadi, PhD, United States Army Institute of Surgical Research, 3400 Rawley E. Chambers Avenue, Fort Sam Houston, Texas 78234-6315; email: bijan.kheirabadi@cen.amedd.army.mil.

DOI: 10.1097/01.ta.0000251595.45451.d0

Report Documentation Page

*Form Approved
OMB No. 0704-0188*

Public reporting burden for the collection of information is estimated to average 1 hour per response, including the time for reviewing instructions, searching existing data sources, gathering and maintaining the data needed, and completing and reviewing the collection of information. Send comments regarding this burden estimate or any other aspect of this collection of information, including suggestions for reducing this burden, to Washington Headquarters Services, Directorate for Information Operations and Reports, 1215 Jefferson Davis Highway, Suite 1204, Arlington VA 22202-4302. Respondents should be aware that notwithstanding any other provision of law, no person shall be subject to a penalty for failing to comply with a collection of information if it does not display a currently valid OMB control number.

1. REPORT DATE 12 JAN 2007		2. REPORT TYPE N/A		3. DATES COVERED -	
4. TITLE AND SUBTITLE The potential utility of fibrin sealant dressing in repair of vascular injury in swine				5a. CONTRACT NUMBER	
				5b. GRANT NUMBER	
				5c. PROGRAM ELEMENT NUMBER	
6. AUTHOR(S) Kheirabadi B. S., Acheson E. M., Deguzman R., Crissey J. M., Delgado A. V., Estep S. J., Holcomb J. B.,				5d. PROJECT NUMBER	
				5e. TASK NUMBER	
				5f. WORK UNIT NUMBER	
7. PERFORMING ORGANIZATION NAME(S) AND ADDRESS(ES) United States Army Institute of Surgical Research, JBSA Fort Sam Houston, TX 78234				8. PERFORMING ORGANIZATION REPORT NUMBER	
9. SPONSORING/MONITORING AGENCY NAME(S) AND ADDRESS(ES)				10. SPONSOR/MONITOR'S ACRONYM(S)	
				11. SPONSOR/MONITOR'S REPORT NUMBER(S)	
12. DISTRIBUTION/AVAILABILITY STATEMENT Approved for public release, distribution unlimited					
13. SUPPLEMENTARY NOTES					
14. ABSTRACT					
15. SUBJECT TERMS					
16. SECURITY CLASSIFICATION OF:			17. LIMITATION OF ABSTRACT UU	18. NUMBER OF PAGES 10	19a. NAME OF RESPONSIBLE PERSON
a. REPORT unclassified	b. ABSTRACT unclassified	c. THIS PAGE unclassified			

maintain hemostasis for more than 1.6 hours, with animals exsanguinating between 28 to 102 minutes after treatment. FSD, in contrast, produced initial hemostasis in all the pigs and maintained hemostasis in 5 of 6 animals for 96 hours during which time the animals recovered and resumed normal activities. The computed tomography (CT) images and histologic cross sections of the repaired aorta from surviving animals clearly showed the formation of a growing pseudoaneurysm with the risk of rupturing at the aortotomy site.¹³ The purpose of the current study was to determine the length of time during which FSD can sustain hemostasis in arterial hemorrhage and whether it can be used as a definitive method in repair of a major arterial injury, leading to healing of the vessel. FSD is currently classified as a biological and must be tested for safety and efficacy in clinical trials before receiving FDA approval.

MATERIALS AND METHODS

The FSD for this study was manufactured from human pooled plasma by CSL Bioplasma (Victoria, Australia) for the American Red Cross and United States Army. The 10 cm × 10 cm dressing design consisted of two outer layers of human fibrinogen (13.5 mg/cm²) and a middle layer of human thrombin (40 units activity/cm²) and CaCl₂ (75 μg/cm²), freeze-dried onto an absorbable Dexon mesh backing. The dressing was manufactured sterilely and treated in two steps (solvent detergent and dry heat) for complete viral inactivation.¹⁵

Fifteen immature female Yorkshire pigs, weighing 38.6 ± 3.1 kg were obtained from a local class A dealer (HDH Swine Farm, Boerne, Tex.). Female pigs were selected because the transurethral cannulation of the bladder is very difficult in males; the male's spiral urethra obstructs noninvasive catheter insertion. Animals were housed in a facility accredited by the Association for Assessment and Accreditation of Laboratory Animal Care (AAALAC) and were quarantined for at least 1 week before use. All animals received care in strict compliance with the *Guide for the Care and Use of Laboratory Animals* (National Research Council, 1996). The study protocol was approved by the Animal Care and Use Committee of the United States Army Institute of Surgical Research.

Surgical Preparation and Instrumentation

Preoperation screening blood samples were collected during the quarantine period. Complete blood counts (CBC), coagulation profiles (PT, aPTT, fibrinogen) and serum chemistries were measured to ensure the complete health status of the animals. Pigs were fasted 24 hours before the surgical procedure with free access to water. On the day of surgery, a venous blood sample was collected to verify normal CBC values. The animals were premedicated with glycopyrrolate (Robinul, 0.01 mg/kg) and a combination of tiletamine and zolazepam (Telazol, 4–6 mg/kg) intramuscularly; initial anesthesia was produced with 5% isoflurane using a face mask.

The pigs were then intubated, placed on a positive-pressure ventilator, and end tidal pCO₂ was maintained at 40 mm Hg. The surgical plane of anesthesia was produced by ventilation with 2% to 3% isoflurane in 100% oxygen. The animals' core temperatures were monitored with a rectal probe and maintained at 37°C to 39°C with water-circulating heating pads. To monitor renal function and urine output during the operation and recovery (up to 6 hours), a Foley catheter (10 Fr, Sherwood Medical) was placed in the bladder transurethrally.

Surgical Procedures and Testing of FSD

All surgical procedures were performed using standard aseptic techniques. The ear vein was cannulated with a 21-gauge Teflon catheter and lactated Ringer's (LR) solution was administered (5 mL/kg/h) throughout the operation to compensate for fluid evaporation. The left femoral artery and left external jugular vein were cannulated with extension tubes for arterial blood sample collection, and intravenous (IV) drug and fluid infusion. The ends of the catheters were tunneled subcutaneously, exteriorized between scapulae, and secured. A telemetry device (TL 11M2-D70-PCT, Data Sciences International) was implanted in the right groin of the pig to remotely monitor vital signs. The telemetry gel-filled catheter (OD:1.4 mm, ID:1.1 mm) was placed into a small branch of the right femoral artery, and the electrocardiogram (EKG) leads were tunneled subcutaneously and secured on the left thigh and right side of the chest. The telemetry device and accompanying equipment (receiver and computer system) permitted 24-hour monitoring and recording of blood pressure, heart rate, electrocardiogram, and body temperature of the animals without restricting their movement.

Laparotomy was performed and the pig's spleen was removed after ligating the splenic pedicles. To offset the splenic blood loss, the animals were infused intravenously with warm LR at a volume three times the organ's weight. The splenectomy was deemed necessary because the pig spleen is a large contractile organ storing 20% to 25% of animal's total red blood cells (RBCs). In the event of hemorrhage, this organ is able to contract and autotransfuse the animal, replacing RBCs and maintaining hematocrit at a constant level. Therefore, the spleen could potentially preclude the diagnosis of a small secondary bleeding at the repaired site.

A section of the infrarenal aorta of approximately 10 cm was carefully exposed and prepared for cross-clamping. Before cross-clamping a 10-minute stabilization period allowed continuous monitoring of hemodynamic parameters. During this baseline period, a core temperature of 37°C to 39°C and a stable mean arterial pressure (MAP) of 60 mm Hg or higher were mandated. At the conclusion of baseline, an arterial blood sample was collected and preinjury levels for CBC and blood gases were determined.

To create the hemorrhage, the exposed aortic segment was cross-clamped and a reproducible aortotomy was created using a 4.4 mm diameter aortic punch.¹³ The clamps were

then removed and the wound was permitted to bleed freely for 5 seconds. The blood loss during this period was collected and measured as pretreatment blood loss. The dressing was applied in a small pool of blood and compressed over the wound with sufficient pressure to occlude the vessel for 4 minutes. This time period allowed fibrinogen polymerization and interaction of the dressing's active components resulting in the attachment of the fibrin layer to the tissue. Two attempts were permitted (using up to two dressings) to achieve hemostasis in each experiment. Each attempt included a four minute compression followed by a 10-minute observation period, in which hemostasis was monitored visually. Any bleeding after successful attachment during this 10-minute observation period was quantitated as post-treatment blood loss. Experiments in which animals exsanguinated to death were recorded as failure of the dressing to achieve initial hemostasis. If hemostasis was achieved and was stable for the 10 minute observation period, the animal was resuscitated intravenously with warm LR solution (three-times the volume of pretreatment blood loss at 100 mL/min) and the abdominal incision was closed in layers. Postoperative arterial blood samples were collected to measure CBC, blood gases, and lactate level. The externalized catheters were protected in a secured pocket of a nylon mesh jacket that was placed on the pig.

Postoperative Care and Monitoring

After the surgery, when stable blood pressure was attained, animals were placed in a large metabolic cage and transferred to the animal Intensive Care Unit (ICU) for recovery and continuous observation. The next day, the recovered animals were transferred to regular cages with a closed camera system capability that allowed continuous monitoring of the animals' conditions and their vital signs remotely for 2 weeks. Pigs were also checked closely several times a day by the investigator's team and veterinarian staff. Prophylactic antibiotics (Naxcel, ceftiofur sodium) were given intramuscularly once a day for 3 days. Postoperative pain was relieved by twice-daily injections of buprenorphine (0.05 mg/kg, intramuscular) for 3 days. Arterial blood samples (CBC) were collected daily during the first 48 hours postoperative and weekly thereafter. The measurements such as hematocrit and platelet counts were made to detect any minor rebleeding that might have occurred at the repair site but could not be detected by observing the vital signs. Sudden drops in arterial blood pressure along with an increase in heart rate were perceived as symptoms of dressing failure and internal bleeding. In such cases, midazolam (0.4 mg/kg, IV) was administered rapidly to the animals to relieve any potential stress or discomfort associated with conscious aortic hemorrhage and a blood sample was collected for CBC measurement. Once the secondary bleeding was confirmed by a fall of hematocrit and hemoglobin level, the animal was killed.

The status of the abdominal aorta and progress of the wound in the animals was monitored by weekly computed

tomography (CT) angiography. The animals were anesthetized with an IV bolus injection of a mixture of midazolam (2 mL, 5 mg/mL) and ketamine (2 mL, 100 mg/mL) and prepared for CT scanning. To scan the abdominal aorta, 75 mL of a contrast agent (Conray, Mallinckrodt Inc., St. Louis, Mo.) was infused into the venous jugular line at 3 mL/sec. During this infusion, the lower portion of the pig's body was imaged for ~20 seconds at 16 slices per second (Toshiba Aquilion 1b multislice scanner). The animals were then recovered and infused with 1,000 mL LR solution intravenously to facilitate excretion of the contrast agent from their circulation.

Termination

After the final CT angiography and blood sample collection, the surviving pigs were killed at their designated time points (2, 4, 6, or 8 weeks). The animals were killed with an overdose of barbiturate, and the operated site was carefully exposed and inspected for any signs of secondary bleeding, gastrointestinal track adhesion, and remaining portions of the dressing. The repaired segment of the aorta with the attached dressing (if still present) was isolated and recovered for histologic examination. Tissue samples from kidney, lung, heart, and adrenal gland were also collected for histologic examination. Necropsy was performed on all the animals to include those that were killed because of suspected secondary bleeding or died unexpectedly.

Statistical Analysis

The Kruskal-Wallis test (nonparametric ANOVA) was used for comparison of pre- and postoperative hematological measurements. Dunnett's multiple comparison test was used as the post-test to compare pairs of group means. Data in the tables are expressed as mean \pm SD. Statistical significance was assigned at a greater than 95% confidence level ($p < 0.05$).

RESULTS

Hemostasis

The lethality of the hemorrhage from 4.4 mm aortotomy was demonstrated in previous studies.^{8,13} This hemorrhage cannot be controlled by standard gauze treatment and results in exsanguination of 100% of animals.¹³ The ability of FSD to immediately stop this type of bleeding and to then maintain hemostasis over a long-term was tested in 15 pigs. The pretreatment blood loss ranged from 238 to 412 mL, averaging 325 ± 87 mL. Initial hemostasis was achieved in 93% (14 of 15) of the subjects, using a total of 20 dressings for the experiments (five trials required a second dressing application). The post-treatment bleeding volume was less than 5 mL in total for all the successful experiments. Hemostasis failed in two animals shortly after dressing application (at 36 and 53 minutes post-treatment) and led to exsanguination of the pigs while they were still in the operating room. The rebleeding in both cases occurred during and shortly after fluid replacement when the animals' blood pressure began to increase. The

post-treatment blood loss volumes in these pigs were 914 and 1,330 mL. The percentage of the early failure of FSD treatment (20%, 3 of 15) was similar to those reported in our previous study (17%, 1 of 6).¹³ Hemostasis was stable in the remaining 12 animals with normal surgical recovery the following day. These pigs were divided into four groups (3/group) and followed for 2, 4, 6, and 8 weeks and then terminated for morphologic and histologic examination.

Late hemostatic failure occurred in two animals on days 8 (from 4-week group) and 11 (from 2-week group) postsurgery and resulted in a large retroperitoneal hematoma and intraperitoneal hemorrhage. Bleeding was detected by a sharp increase in heart rate and decline in blood pressure, confirmed by a sudden drop (10%) in hematocrit levels. These animals were killed. A persistent decline in hematocrit was also observed in another pig (from the 2-week group) beginning at day 7, leading to the suspicion of internal bleeding and termination of the animal on day 10. However, the necropsy showed no secondary bleeding or retroperitoneal hematoma around the dressing site. The cause of the reduced hematocrit could not be determined. The remaining nine animals were all categorized as having lived normally for the duration of the experiment until killed. One pig in this group was found dead from unknown causes 6.5 weeks after surgery. Because the necropsy of the animal showed no evidence that could relate this death to the dressing treatment (e.g. secondary bleeding or excessive bowel adhesion) and the aortic injury was completely healed at the time, this experiment was counted as a successful test in the 8-week group. Hemostasis results are summarized in Table 1.

Hematological Measurements

The hematological values of surviving pigs are shown in Table 2. The hematocrit, hemoglobin, and platelet counts

decreased significantly after the injury and hemorrhage. These changes were expected because of the blood loss before dressing treatment (325 ± 87 mL) and fluid administration post-treatment to replace the circulating volume. Excluding the platelet count that returned to preoperative levels 2 days after the surgery, hemoglobin and hematocrit levels remained below baseline levels for at least 1 week postoperation. Large increases in plasma fibrinogen concentration were noted at 2, 4, and 6 weeks but these were not significant because of the small number of samples measured at those time points. The white blood cell counts were within the normal range established at our institute for sexually immature Yorkshire pigs and did not change significantly throughout the study. The coagulation tests also showed similar normal range results at the time that the animals were killed (2, 4, 6, and 8 weeks for each group).

CT Angiography

In two experiments the repaired aorta was imaged right after the surgery. The small dilation of the lumen at the aortotomy site suggested that that dressing had been pushed outward by the high pressure arterial blood flow after the animals' recovery (Figs. 1A, B). The initial aortotomy defect is seen in Figure 1C. The apparent "pseudoaneurysm" increased in size (all three dimensions) and formed a pocket over the injury site that expanded the diameter of the aortic lumen by approximately 50% during 1 week, even though the original aortotomy size (4.4 mm) did not appear to change significantly (Figs. 2A, B). The larger pseudoaneurysms (>10 mm) eventually ruptured at day 8 and day 11 postoperative, causing extensive bleeding and retroperitoneal hematomas with a marked reduction in hematocrit levels in the animals.

Table 1 Hemostatic Outcome of Sutureless Repair of Aortotomy With FSD in Pigs

No. Animals Operated	Hemostasis Not Achieved	Early (hr) Hemostatic Failure	Late (days) Hemostatic Failure	Premature Euthanasia	Long-Term Survival
15	1/15 (7%)	2/15 (13%)	2/15 (13%)	1/15 (7%)	9/15 (60%)

Table 2 Hematological Measurements During the 8 wk Study

Blood Factors	Preoperative	Postoperative	Day 2	Week 1	Week 2	Week 4	Week 6	Week 8
Hb (g/dL)	11.6 ± 0.6^a	9.4 ± 0.9^b	9.6 ± 1.0^c	9.8 ± 0.7^d	10.0 ± 1.0	9.6 ± 0.8	9.6 ± 0.5	11.1 ± 0.9
Hct%	34.3 ± 1.8^e	27.6 ± 2.5^f	28.5 ± 3.0^g	28.8 ± 3.1^h	30.0 ± 3.1	29.2 ± 1.8	29.4 ± 1.0	32.3 ± 2.1
Platelet (K/ μ L)	372 ± 85^i	274 ± 53^j	329 ± 47^k	477 ± 176	472 ± 152	399 ± 88	374 ± 137	408 ± 72
WBC (K/ μ L)	18.6 ± 2.7	19.4 ± 6.8	19.2 ± 5.7	21.4 ± 5.5	20.9 ± 6.4	24.0 ± 6.3	22.6 ± 8.7	20.5 ± 4.0
Fibrinogen (mg/dL)	218.4 ± 40	—	—	—	415	376 ± 152	348 ± 136	233.5 ± 89
PT (second)	9.4 ± 0.2	—	—	—	10.9	10.0 ± 0.1	9.7 ± 0.1	9.8 ± 0.1
aPTT (second)	14.8 ± 2.6	—	—	—	17.6	19.1 ± 3.7	20.3 ± 5.1	21.8 ± 8.7

a versus b, or c, $p < 0.01$; or d, $p < 0.05$.

e versus f, g, or h, $p < 0.01$.

i versus j, $p < 0.05$ and k versus j, $p < 0.05$.

Coagulation tests were measured before surgery and at the specific time points that each pig was killed. The coagulation data represent samples collected from the surviving animals; 1 pig at week 2; 2 pigs at week 4; 3 pigs at week 6; and 2 pigs at week 8.

Post-op

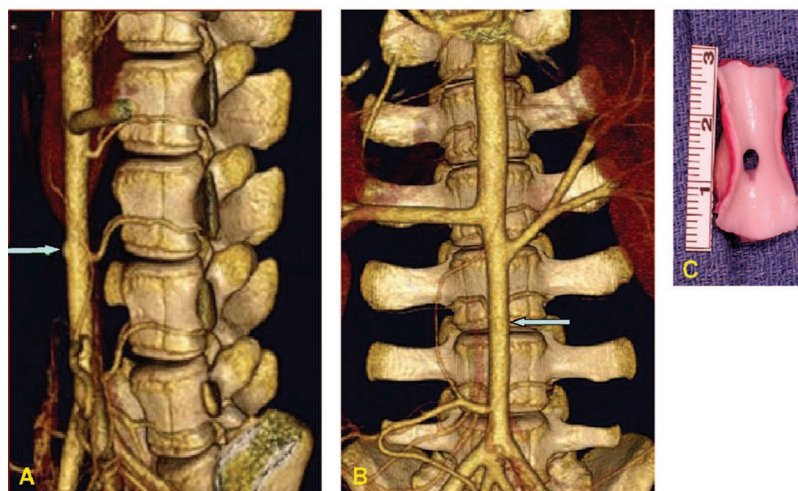


Fig. 1. CT images of the lateral (A) and frontal (B) views of infrarenal aorta of a representative pig shortly after the operation. The aortotomy defect (C) was sealed temporarily with FSD (early failure). Note the initial bulging of the dressing (arrows) caused by high blood pressure in the lumen.

Week 1

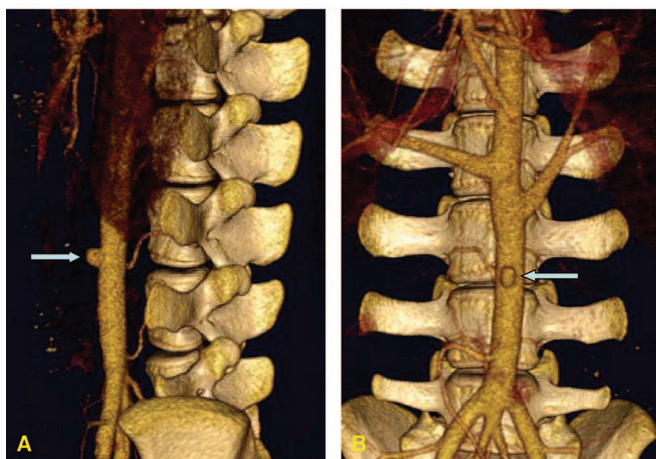


Fig. 2. CT images of the lateral (A) and frontal (B) views of infrarenal aorta of a representative pig 1 week after the operation. Note formation of a growing pseudoaneurysm (arrows) at the repair site that expanded the aortic lumen by ~50%.

The CT images from survivors generally showed contraction and narrowing and in some cases complete disappearance of the pseudoaneurysm 2 weeks after the surgery (Figs. 3A, B). The lumen of the corresponding vessel is shown in Figure 3C. The later weekly images showed normal aortic lumens with little or no indications of the initial injury site on the vessels (Figs. 4A, B and 5A, B).

Necropsy

Gross examination of the wounds after 2 weeks showed a fibrous encapsulation (foreign body reaction) and mild to moderate adhesion of the intestines over the wound area. The

dressing was encapsulated by fibrous tissue (foreign body reaction) and isolated from the peritoneal cavity. Exposure of the dressing showed no signs of secondary bleeding or hematomas around the wound. The dressings appeared to be detached from some of the underlying tissues but remained tightly attached to the vessel wall. The extent of the pseudoaneurysm could not be seen from the outside of the vessel as it was covered by the dressing; however, when the lumen was exposed, the depth of the defect and formation of new tissue in the pseudoaneurysm was clearly visible (Fig. 3C). No blood clot or thrombus was seen in any of the vascular defects.

In the 4 week group, the bowel adhesion and foreign body encapsulation was much less evident than in the 2-week animal. The Dexon backing and a portion of the dense fibrin clot was still present in the wound. Exposure of the lumen showed complete filling of the vascular defect with a thin layer of new tissues and smooth luminal surface (Fig. 4C). The tissue reaction and adhesion nearly resolved in the 6 and 8 week groups. The dressings were mostly (6-week) or completely (8-week) biodegraded and reabsorbed. The new tissue within the injury site had similar thickness to the native aortic wall.

Histology

In the 2-week vessels, an abundant overlying granulation tissue (disorganized matrix and numerous vessels) and granulomatous inflammation surrounding the dressing backing material (Dexon) were observed in the tunica adventitia (Fig. 6A). The tunica media, apparently migrated from the native intimal layer, was composed of disorganized myoblasts and low numbers of fibroblasts (90% cells 10% collagen), intermixed with low to moderate amounts of hemorrhage, neutro-

Week 2

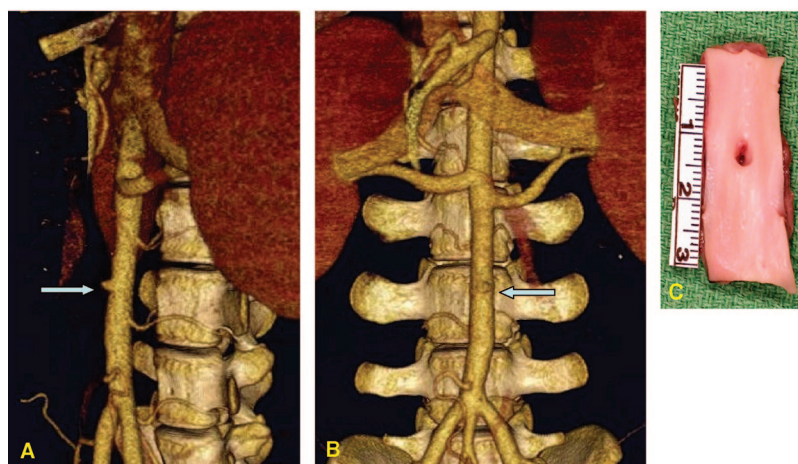


Fig. 3. CT images of the lateral (A) and frontal (B) views of infrarenal aorta of the surviving pig in 2-week group before being killed. Note contraction and narrowing of the pseudoaneurysm (arrows) during the second week of recovery. The exposed lumen of this vessel, recovered after imaging, and formation of new tissues in the defect (C).

Week 4

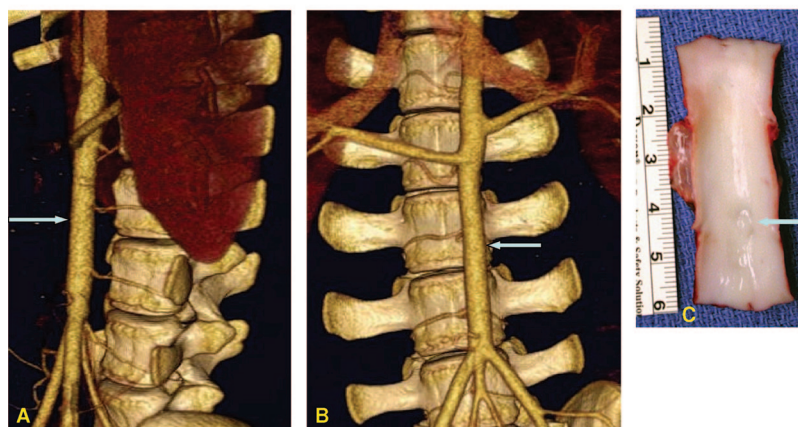


Fig. 4. CT images of the lateral (A) and frontal (B) views of infrarenal aorta of a representative pig from the 4-week group before being killed. Note complete disappearance of pseudoaneurysm at the repair site (arrows). The lumen of the corresponding vessel (C); the aortic defect is filled with a thin layer of the tissue covered by smooth endothelium.

phils, and cellular debris (Fig. 6B). This layer was covered by a single continuous layer of hypertrophic endothelial cells (tunica interna).

In the 4-weeks samples, the tunica adventitia was composed of a thin layer of moderately organized fibroblasts and immature collagen (highly vascularized) forming a linear pattern surrounding multiple foreign body granulomas that contain remnants of the dressing material (Fig. 7A). The tunica media was made of a moderately organized, moderately mature smooth muscle cells and fibroblasts with a 50:50 mix of cells and collagen, covered by a single layer of slightly hypertrophic endothelial cells (Fig. 7B).

The histology of the 6-week and 8-week tissue samples were very similar with progressive improvement in cellular maturation, tissue organization, and absorption of the dressing material. In the 8-week samples, the tunica adventitia

appeared as a highly vascularized thick layer of mature collagen tissue (90% collagen 10% cellular) that surrounded multiple compressed foreign body granulomas (Fig. 8A). The tunica media was composed of moderately organized, mature smooth muscle cells, and fibroblasts with a 75:25 mix of cells and collagen, respectively. This was covered by a single layer of slightly hypertrophic endothelial cells forming tunica interna (Fig. 8B).

The kidney, lung, heart, and adrenal glands from the long-term survival animals ($n = 12$) were examined by independent pathologist. No evidence of tissue abnormality (necrosis or scar tissue) or micro thrombi formation was found.

DISCUSSION

This study examined the ability of FSD to affect both initial and long-term hemostasis in a life threatening vascular

Week 8

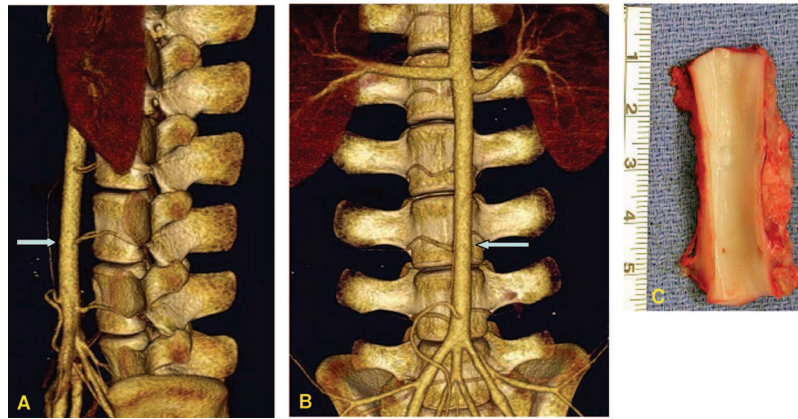


Fig. 5. CT images of the lateral (A) and frontal (B) views of infrarenal aorta of a representative pig from the 8-week group before being killed. The lumen of the corresponding vessel (C); the aortic defect is filled with a layer of the tissue (the same thickness as native vessel) covered by smooth endothelium.

Week 2

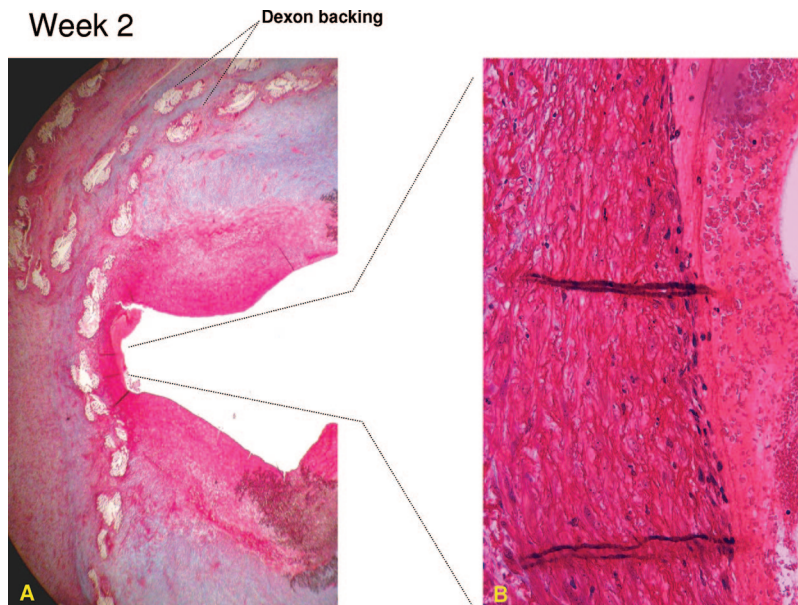


Fig. 6. Cross section of aortotomy site 2 weeks after repairing with FSD (MOVAT staining). There is an outer layer of abundant granulation tissue and granulomatous inflammation surrounding the dressing backing material (Dexon) (A, 2 \times). The tunica media is composed of disorganized myoblasts and fibroblasts covered by a single continuous layer of hypertrophic endothelial cells (tunica interna) and overlaid with hemorrhage and cellular debris (B, 20 \times).

injury in swine. It also evaluated the consequences of using FSD as a definitive method to repair the injury and its effect on tissue healing. The morphologic and histologic observations of the treated vessels recovered from the earliest killed animals indicated that FSD does not promote the formation of a hemostatic clot at the injury site that would be capable of maintaining hemostasis in cases of early dressing failure. The causes for the hemostatic failure of the dressing that occurred shortly after surgery (1 hour postoperative) appeared to be different from those at later times (1 week postoperative). In the early failure, the fibrin clot layer did not seem to adhere strongly to underlying vascular tissues and therefore as the

blood pressure in the lumen increased in the recovering animal, the dressing became detached from the wound and produced catastrophic bleeding and death. The cross-link between fibrin and a number of adhesive glycoproteins in the vascular wall, including fibronectin, von Willebrand factor, and collagen, are responsible for anchoring the fibrin clot to the injured tissues.¹⁶⁻¹⁸ The reasons for weak binding of the fibrin clot layer may have been related to incomplete fibrinogen polymerization that occurred as a result of incomplete dissolving of fibrinogen and thrombin in the blood or poor mixing of these components on the active surface of the dressing when placed over the wound.

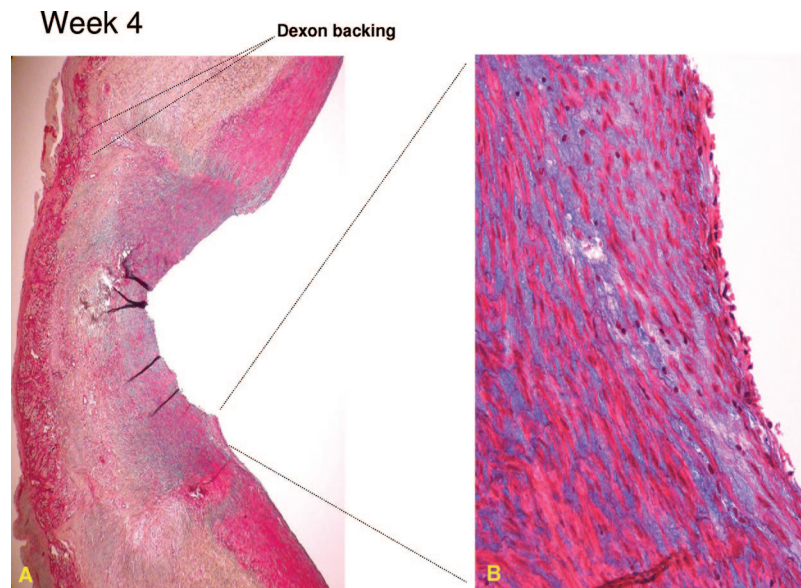


Fig. 7. Cross section of aortotomy site 4 weeks after repairing with FSD (MOVAT staining). The tunica adventitia is composed of a highly vascularized thin layer of moderately organized fibroblasts and immature collagen, lining up and surrounding multiple foreign body granulomas and remnants of the dressing material (A, 2 \times). The tunica media is moderately organized, moderately mature smooth muscle cells and fibroblasts covered by a single layer of slightly hypertrophic endothelial cells forming tunica interna (B, 20 \times).

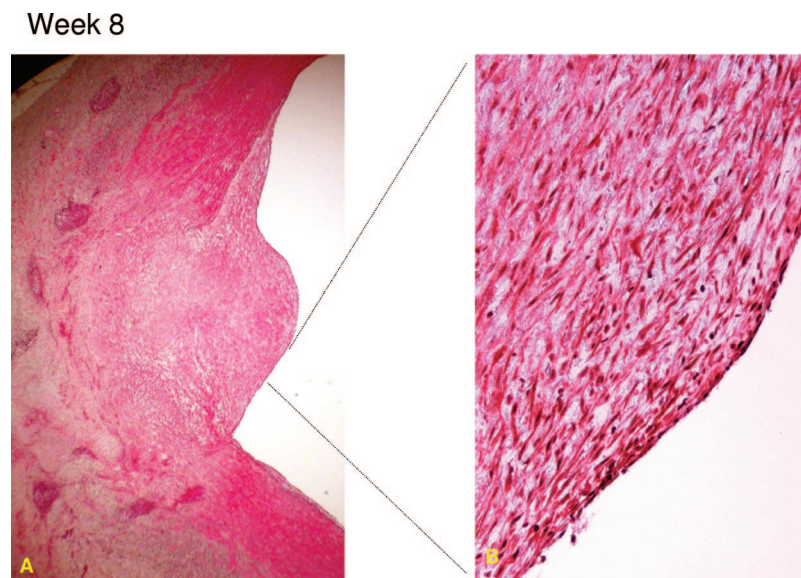


Fig. 8. Cross section of aortotomy site 4 weeks after repairing with FSD (MOVAT staining). The tunica adventitia is a thick, highly vascularized layer of mature collagen tissue surrounding multiple compressed foreign body granulomas (A, 2 \times). The tunica media is composed of moderately organized, mature smooth muscle cells and fibroblasts, and is covered by a single layer of slightly hypertrophic endothelial cells forming tunica interna (B, 20 \times).

The late failure of the dressing was always associated with the formation of a large and expanding pseudoaneurysm on the vessel as seen in the CT angiograms. The defect seemed to form because the dressing was bound to the adventitial layer of the vessel. The high pressure in the aortic lumen gradually pushed the dressing outward and stretched the loose adventitial layer, forming a pocket underneath that resembled a pseudoaneurysm. Active fibrinolysis may have

also played a role in breaking down the binding between the fibrin layer and the vessel wall. In the ruptured aneurysms, a small channel eventually formed beneath the dressing from the original injury site, which caused bleeding to occur away from the injury. The hemorrhage in these cases stopped once a large tamponade clot or hematoma was formed over the wound, creating a tamponade effect. In the successful cases, the pseudoaneurysms were filled with new tissues after 2 to 3

weeks and the aortotomy sites were healed within 4 weeks after the surgery.

In selecting our model and to challenge the efficacy of the dressing, our primary goal was to cause an injury that could produce bleeding potentially *greater* than that typically seen in hypotensive, hypothermic shock patients who might benefit most from this product. The model also permitted recovery of the animals uneventfully and permitted us to follow their survival to examine the long-term efficacy of the dressing. Whereas the fit of animal models to pertinent clinical conditions is often difficult, in the end our model may have actually presented a greater challenge to the dressing than low pressure hemorrhage in shock patients.

The results of this study and our earlier investigation¹³ suggest that FSD provides an easy and rapid method to stop severe arterial bleeding and maintains hemostasis in most cases until the injury is healed. However, the risk of the early or late failure of the dressing (30% to 40%) and consistent pseudoaneurysm formation clearly indicate that FSD should not be used as a singular definitive method for repair of severe arterial injuries. In a consequent investigation in which similar aortic injuries were repaired by suturing, we observed no hemostatic failure or aneurysm in any of the operated animals. The main utility of this type of hemostatic dressing remains in damage control operations in trauma patients. Severe trauma to the torso or extremities often causes significant hemorrhage resulting in death if not controlled. Application of FSD in cases of thoracic or abdominal vascular injuries can rapidly stop hemorrhage and allow restoration of normal physiology by resuscitative measures before patients are taken to the operating room for definitive care. As shown in several long-term experimental studies involving large animals, the dressing can offer an immediate and perhaps permanent modality to stop hemorrhage and support healing of injured organs in cases of severe parenchymal injuries.^{10–12} Because the dressings are fully absorbable, they can potentially replace the current standard of care (gauze packing) for treating liver injuries, eliminating the need for a second operation to remove the gauze and thereby reducing the risk of infection.

FSD may also be justified in vascular procedures when the source of bleeding is inaccessible or cannot be identified well enough for surgical repair or when the vascular tissues are so friable that attempting to place a suture would further aggravate the hemorrhage. In such cases, although we think the model would have to be modified to encompass a greater range of injuries to the vascular wall, FSD could repair the injuries temporarily followed at a later time with a more permanent method such as placement of an intraluminal stent. Other topical hemostatic products are less effective than FSD in these circumstances because they are not likely to hold up against the high-pressure arterial bleeding.⁸ Even liquid fibrin sealant with proven efficacy against potential arterial bleeding requires vascular control and a nonbleeding field for initial application with polymerization to provide subsequent hemostasis.^{19,20}

There are certain risks associated with the use of FSD as a treatment for vascular defects. One danger is the possibility of thrombin diffusing inside the vessel's lumen, causing intravascular thrombosis or immunologic reactions.^{21–23} However, the reported thrombogenicity of some fibrin sealant products may be related to use of bovine thrombin and the impurities (e.g. factors V, X, XI, and kallikrein) present in those preparations.²⁴ The risk of viral transmission (specifically, hepatitis or human immunodeficiency virus) from the use of human plasma products (fibrinogen and thrombin) has been virtually eliminated by stringent screening of blood donors and advancement in viral inactivation methods.²⁵ The use of human derived proteins to produce FSD has also eliminated the abnormal immune responses that have been seen in some fibrin sealant products that contained bovine proteins (e.g. thrombin, aprotinin).^{26–28} The only unexpected death in our study occurred 6.5 weeks after the operation at which time the defect had completely healed and a smooth endothelial layer covered the luminal site. Histologic examination of tissues collected from different organs including the heart and brain showed no evidence of thromboembolism. The exact cause of death in this particular animal could not be conclusively determined. No evidence of microthrombi or disseminated intravascular coagulation (DIC) was found in the lung, heart, kidneys, or adrenal glands of any of the surviving animals.

Pseudoaneurysm formation and the risk of rupture are a major concern if FSD is used as the only tool to repair arterial injuries. Although in this study pseudoaneurysms ruptured only in two subjects they did develop at the repair site in all recovered animals. TachoComb (TC) is a similar product to FSD approved for clinical use in Europe and Japan.²⁹ In a clinical case report pseudoaneurysm was reported 7 days after an operation in which TC was used to repair a small (1 mm diameter) postinfarction epicardial tear. Other TC case studies, however, reported successful use of TC for sutureless repair of a postinfarction cardiac rupture.^{30–32} TC composition, like FSD, consists of fibrinogen, thrombin, and bovine aprotinin integrated into a hemostatic backing (collagen fleece). The FSD differs from TC in the backing material (Vicryl or Dexon mesh instead of collagen fleece) and the higher amounts of fibrinogen and thrombin on each cm² of the dressing. The higher amount of fibrinogen in FSD (15 mg/cm² vs. 4.3–6.7 mg/cm² in TC) correlated to better efficacy of the dressing when tested in a liver hemorrhage model.³³

After two comprehensive efficacy studies,^{8,14} FSD was selected among nine other hemostatic products and distributed among Special Forces medics in Afghanistan and Iraq for treating external wounds in 2002. This was done under an investigational new drug (IND) protocol approved by the FDA. FSD was used only once in a casualty (with successful outcome) before it was replaced with an FDA-approved chitosan dressing (HemCon).³⁴ New efforts are underway to begin clinical trials of FSD to obtain FDA approval for clinical use of this potentially life saving product.

In summary, FSD applied to uncontrolled bleeding caused by a 4.4 mm aortotomy stopped hemorrhage in 93% of anes-

thetized pigs and secured hemostasis for at least 7 days in 80% of fully conscious and normal living animals. By the fourth week, the defects in the aorta were filled with new collagen-rich tissues and covered by an endothelial layer in surviving animals. Based on these preliminary results, we conclude that FSD should not be used as the singular definitive method for repair of severe arterial injuries. It may be justified as an alternative for surgical repair only in the areas of profuse bleeding where visualizing the injury is very difficult or the vessel is too fragile to withstand suturing. Even in such circumstances, combining FSD with elective interventional radiologic procedures (e.g. embolization, stenting) may be advisable to eliminate the potential risk of rebleeding in the later phases. The successful combination of FSD and endoluminal interventions will clearly require more investigations examining more complex vascular injuries. FSD may be most beneficial in trauma care and damage control operations, allowing for temporary cessation of bleeding, resuscitation, and restoration of normal physiology of patients before definitive care can be provided.

REFERENCES

- Codispoti M, Mankad PS. Significant merits of a fibrin sealant in the presence of coagulopathy following paediatric cardiac surgery: randomised controlled trial. *Eur J Cardiothorac Surg.* 2002;22:200–205.
- Tock B, Drohan W, Hess J, et al. Haemophilia and advanced fibrin sealant technologies. *Haemophilia.* 1998;4:449–455.
- Jackson MR, Alving BM. Fibrin sealant in preclinical and clinical studies. *Curr Opin Hematol.* 1999;6:415–419.
- Larson MJ, Bowersox JC, Lim RC Jr, et al. Efficacy of a fibrin hemostatic bandage in controlling hemorrhage from experimental arterial injuries. *Arch Surg.* 1995;130:420–422.
- Holcomb J, MacPhee M, Hetz S, et al. Efficacy of a dry fibrin sealant dressing for hemorrhage control after ballistic injury. *Arch Surg.* 1998;133:32–35.
- Holcomb JB, Pusateri AE, Harris RA, et al. Effect of dry fibrin sealant dressings versus gauze packing on blood loss in grade V liver injuries in resuscitated swine. *J Trauma.* 1999;46:49–57.
- Acheson EM, Kheirabadi BS, Deguzman R, et al. Comparison of hemorrhage control agents applied to lethal extremity arterial hemorrhages in swine. *J Trauma.* 2005;59:865–874; discussion 874–865.
- Sondeen JL, Pusateri AE, Coppes VG, et al. Comparison of 10 different hemostatic dressings in an aortic injury. *J Trauma.* 2003;54:280–285.
- Holcomb JB, Pusateri AE, Harris RA, et al. Dry fibrin sealant dressings reduce blood loss, resuscitation volume, and improve survival in hypothermic coagulopathic swine with grade V liver injuries. *J Trauma.* 1999;47:233–240; discussion 240–232.
- Cornum R, Bell J, Gresham V, et al. Intraoperative use of the absorbable fibrin adhesive bandage: long term effects. *J Urol.* 1999;162:1817–1820.
- Cornum RL, Morey AF, Harris R, et al. Does the absorbable fibrin adhesive bandage facilitate partial nephrectomy? *J Urol.* 2000;164:864–867.
- Morey AF, Anema JG, Harris R, et al. Treatment of grade 4 renal stab wounds with absorbable fibrin adhesive bandage in a porcine model. *J Urol.* 2001;165:955–958.
- Kheirabadi BS, Acheson EM, Deguzman R, et al. Hemostatic efficacy of two advanced dressings in an aortic hemorrhage model in Swine. *J Trauma.* 2005;59:25–34; discussion 34–25.
- Pusateri AE, McCarthy SJ, Gregory KW, et al. Effect of a chitosan-based hemostatic dressing on blood loss and survival in a model of severe venous hemorrhage and hepatic injury in swine. *J Trauma.* 2003;54:177–182.
- Pusateri AE, Kheirabadi BS, Delgado AV, et al. Structural design of the dry fibrin sealant dressing and its impact on the hemostatic efficacy of the product. *J Biomed Mater Res.* 2004;70B:114–121.
- Bockenstedt P, McDonagh J, Handin RI. Binding and covalent cross-linking of purified von Willebrand factor to native monomeric collagen. *J Clin Invest.* 1986;78:551–556.
- Burleson RL, Ennulat N. Fibrin adherence to biologic tissues. *J Surg Res.* 1978;25:523–529.
- Mosher DF. Cross-linking of fibronectin to collagenous proteins. *Mol Cell Biochem.* 1984;58:63–68.
- Doillon CJ, Dion YM. Comparison of a plasma-based composite biologic sealant with fibrin glue (Tisseel) for vascular anastomoses. *Surg Laparosc Endosc Percutan Tech.* 2004;14:335–339.
- Kheirabadi BS, Field-Ridley A, Pearson R, et al. Comparative study of the efficacy of the common topical hemostatic agents with fibrin sealant in a rabbit aortic anastomosis model. *J Surg Res.* 2002;106:99–107.
- Bishoff JT, Cornum RL, Perahia B, et al. Laparoscopic heminephrectomy using a new fibrin sealant powder. *Urology.* 2003;62:1139–1143.
- Frost-Arner L, Spotnitz WD, Rodeheaver GT, et al. Comparison of the thrombogenicity of internationally available fibrin sealants in an established microsurgical model. *Plast Reconstr Surg.* 2001;108:1655–1660.
- Marek CA, Amis LR Jr, Morgan RF, et al. Acute thrombogenic effects of fibrin sealant on microvascular anastomoses in a rat model. *Ann Plast Surg.* 1998;41:415–419.
- Pusateri AE, Holcomb JB, Bhattacharyya SN, et al. Different hypotensive responses to intravenous bovine and human thrombin preparations in swine. *J Trauma.* 2001;50:83–90.
- Joch C. The safety of fibrin sealants. *Cardiovasc Surg.* 2003;11 Suppl 1:23–28.
- Scheule AM, Beierlein W, Wendel HP, et al. Fibrin sealant, aprotinin, and immune response in children undergoing operations for congenital heart disease. *J Thorac Cardiovasc Surg.* 1998;115:883–889.
- Scheule AM, Beierlein W, Wendel HP, et al. Aprotinin in fibrin tissue adhesives induces specific antibody response and increases antibody response of high-dose intravenous application. *J Thorac Cardiovasc Surg.* 1999;118:348–353.
- Schoenecker JG, Johnson RK, Fields RC, et al. Relative purity of thrombin-based hemostatic agents used in surgery. *J Am Coll Surg.* 2003;197:580–590.
- Kimura N, Kawahito K, Murata S, et al. Pitfalls of sutureless repair of a blow-out type left ventricular free wall rupture. *Jpn J Thorac Cardiovasc Surg.* 2005;53:382–385.
- Kudo M, Misumi T, Koizumi K, et al. A surgical case of ventricular septal perforation after repairing left ventricular free wall rupture. *Ann Thorac Cardiovasc Surg.* 2005;11:121–124.
- Muto A, Nishibe T, Kondo Y, et al. Sutureless repair with TachoComb sheets for oozing type postinfarction cardiac rupture. *Ann Thorac Surg.* 2005;79:2143–2145.
- Nishizaki K, Seki T, Fujii A, et al. Sutureless patch repair for small blowout rupture of the left ventricle after myocardial infarction. *Jpn J Thorac Cardiovasc Surg.* 2004;52:268–271.
- Pusateri AE, Holcomb JB, Harris RA, et al. Effect of fibrin bandage fibrinogen concentration on blood loss after grade V liver injury in swine. *Mil Med.* 2001;166:217–222.
- Wedmore I, McManus JG, Pusateri AE, et al. A special report on the chitosan-based hemostatic dressing: experience in current combat operations. *J Trauma.* 2006;60:655–658.