

---

# Burn Center Treatment of Patients With Severe Anhydrous Ammonia Injury: Case Reports and Literature Review

---

Christopher E. White, MD, Myung S. Park, MD, Evan M. Renz, MD,  
Seung H. Kim, MD, Amber E. Ritenour, MD, Steven E. Wolf, MD,  
Leopoldo C. Cancio, MD

Anhydrous ammonia, a widespread industrial chemical, can cause severe inhalation and ophthalmic injuries, as well as cutaneous burns. We present five patients with ammonia injury treated at our burn center after an explosion in a warehouse. The challenges inherent in managing the pulmonary complications of this injury are emphasized. (*J Burn Care Res* 2007;28:922-928)

Anhydrous ammonia (NH<sub>3</sub>) is a widespread industrial chemical, used in the fertilizer, refrigeration, petroleum, and explosives industries. Transported and stored in liquid form under pressure and at low temperatures, it may cause cold injury on initial contact. More importantly, when exposed to water on the skin, in the eyes, or in the aerodigestive tract, it forms ammonium hydroxide (NH<sub>4</sub>). This strong base is in turn responsible for the majority of the resultant damage. In this article we review the clinical courses of five patients injured overseas in a single event involving ammonia. These cases highlight the severity of the pulmonary and ophthalmic injuries that may be caused by this compound, and the value of treatment in a center with expertise in the care of patients with severe inhalation injury. Because ammonia is a common cause of accidents involving toxic industrial chemicals, and because it could be used as a weapon

of opportunity by terrorists or during armed conflict, familiarity with these injuries is important.

## CASE REPORTS

Thirty men working in a warehouse were exposed to anhydrous ammonia when an explosion caused collapse of one of the building's walls, damaging a large ammonia storage tank. A strong odor of ammonia forced evacuation of the warehouse. Seven patients were evacuated to a local hospital with hoarseness and respiratory difficulty; five were intubated for airway obstruction. The symptoms of the two nonintubated patients resolved during the next 24 to 48 hours, and they did not require transfer. The remaining five patients were transferred to the U.S. Army Institute of Surgical Research Burn Center, Fort Sam Houston, Texas, arriving on postburn day (PBD) 4. All patients were diagnosed with inhalation injury by fiberoptic bronchoscopy.

### Case 1

This 32-year-old man sustained 2% total body surface area (TBSA) burns to his face and scrotum, left tympanic membrane perforation, and right corneal injury. He was extubated after passing a spontaneous breathing trial, but required reintubation within 24 hours for hypoxia and aspiration, and was placed on a high-frequency percussive ventilator (Volumetric Diffusive Respiration ventilator, VDR-4<sup>®</sup>; Percussionaire Inc., Sandpoint, ID). He was also treated for pneumonia. On PBD 9, bronchoscopy showed airway sloughing and large amounts of debris. Trache-

*From the United States Army Institute of Surgical Research, Fort Sam Houston, Texas.*

*The opinions or assertions contained herein are the private views of the authors, and are not to be construed as official or as reflecting the views of the Department of the Army, the Department of the Air Force, or the Department of Defense.*

*Address correspondence to Leopoldo C. Cancio, MD, US Army Institute of Surgical Research, 3400 Rawley E. Chambers Ave., Building 3611, Fort Sam Houston, Texas 78234-6315.*

*Address for reprints: Library Branch, US Army Institute of Surgical Research, 3400 Rawley E. Chambers Ave, Building 3611, Fort Sam Houston, Texas 78234-6315.*

*Copyright © 2007 by the American Burn Association.  
1559-047X/2007*

*DOI: 10.1097/BCR.0b013e318159a44e*

# Report Documentation Page

Form Approved  
OMB No. 0704-0188

Public reporting burden for the collection of information is estimated to average 1 hour per response, including the time for reviewing instructions, searching existing data sources, gathering and maintaining the data needed, and completing and reviewing the collection of information. Send comments regarding this burden estimate or any other aspect of this collection of information, including suggestions for reducing this burden, to Washington Headquarters Services, Directorate for Information Operations and Reports, 1215 Jefferson Davis Highway, Suite 1204, Arlington VA 22202-4302. Respondents should be aware that notwithstanding any other provision of law, no person shall be subject to a penalty for failing to comply with a collection of information if it does not display a currently valid OMB control number.

1. REPORT DATE <b>01 NOV 2007</b>		2. REPORT TYPE <b>N/A</b>		3. DATES COVERED <b>-</b>	
4. TITLE AND SUBTITLE <b>Burn center treatment of patients with severe anhydrous ammonia injury: case reports and literature review</b>				5a. CONTRACT NUMBER	
				5b. GRANT NUMBER	
				5c. PROGRAM ELEMENT NUMBER	
6. AUTHOR(S) <b>White C. E., Park M. S., Renz E. M., Kim S. H., Ritenour A. E., Wolf S. E., Cancio L. C.,</b>				5d. PROJECT NUMBER	
				5e. TASK NUMBER	
				5f. WORK UNIT NUMBER	
7. PERFORMING ORGANIZATION NAME(S) AND ADDRESS(ES) <b>United States Army Institute of Surgical Research, JBSA Fort Sam Houston, TX 78234</b>				8. PERFORMING ORGANIZATION REPORT NUMBER	
				10. SPONSOR/MONITOR'S ACRONYM(S)	
9. SPONSORING/MONITORING AGENCY NAME(S) AND ADDRESS(ES)				11. SPONSOR/MONITOR'S REPORT NUMBER(S)	
12. DISTRIBUTION/AVAILABILITY STATEMENT <b>Approved for public release, distribution unlimited</b>					
13. SUPPLEMENTARY NOTES					
14. ABSTRACT					
15. SUBJECT TERMS					
16. SECURITY CLASSIFICATION OF:			17. LIMITATION OF ABSTRACT <b>SAR</b>	18. NUMBER OF PAGES <b>7</b>	19a. NAME OF RESPONSIBLE PERSON
a. REPORT <b>unclassified</b>	b. ABSTRACT <b>unclassified</b>	c. THIS PAGE <b>unclassified</b>			

**Table 1.** Pulmonary function test results

Case	FEV1 (L)	FEV1/ FVC %	Posttreatment FEV1/FVC %	Interval After Exposure
1	1.87	55	42	8 mo
2	2.46	67	67	7 mo
3	1.86	69	70	6 mo
5	2.22	51	NA	9 d

FEV1, forced expired volume over 1 second; FVC, forced vital capacity; NA, not available.

ostomy was performed; heparin and albuterol were given by nebulization. After removal of the tracheostomy tube on PBD 15, he complained of dysphagia, odynophagia, and hoarseness. Nasopharyngoscopy showed supraglottic and arytenoid edema and left true vocal cord paresis. Pulmonary function testing done at 8 months after injury (Table 1) showed obstructive pulmonary disease.

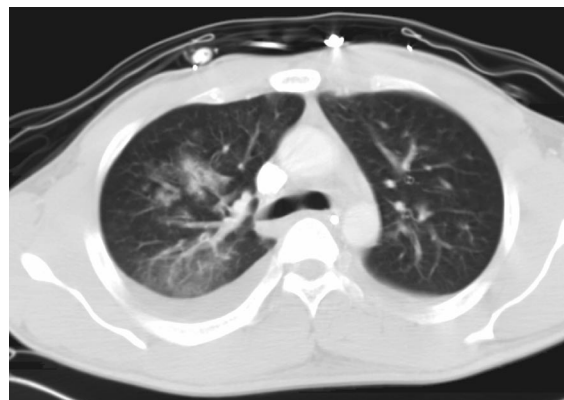### Case 2

This 22-year-old man was admitted with 0.5% TBSA burns to the scrotum and bilateral corneal injuries. A computed tomography (CT) scan of the chest was normal. He was placed on VDR-4 ventilation. On PBD 1 he was diagnosed with tracheobronchitis. Sloughing of the airway was treated with daily bronchoscopy, and nebulized bronchodilators and heparin. Bronchoscopy showed healing of the respiratory epithelium on PBD 18. Pulmonary function test results 7 months after injury are shown in Table 1.

He was discharged without evidence of ophthalmic injury, but at 4-week follow-up he complained of photophobia and decreased vision. He developed bilateral uveitis with stromal vascularization, resulting in stromal haze and scarring, and pigmented keratic precipitates. Prednisolone acetate and homatropine were added. He underwent bilateral corneal transplant, which failed. He is now legally blind.

### Case 3

This 19-year-old man had 0.5% TBSA burns to the face and scrotum and bilateral corneal injuries. A CT scan of the lung 5 days after injury showed ground-glass opacification in the perihilar and posterior regions on the right, as well as peribronchiolar edema (Figure 1). He passed a spontaneous breathing trial. Shortly after extubation, he developed stridor and required reintubation, and was placed on VDR-4 ventilation. He was treated for tracheobronchitis. Mild hypercapnia, most likely related to postinjury reactive airway dysfunction, responded to nebulized bronchodilators. A granuloma on the left true vocal



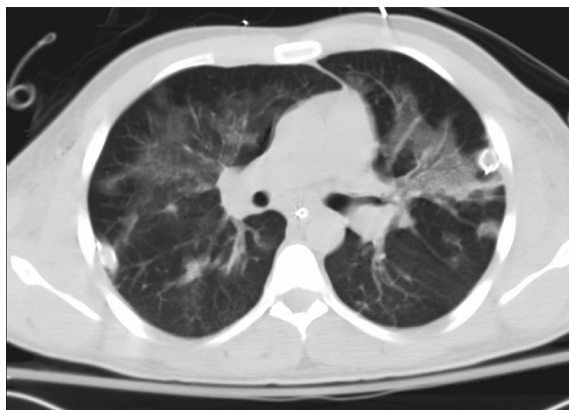
**Figure 1.** Initial computed tomography scan, 5 days after injury—case 3.

cord (TVC) was noted, which remained stable on follow-up examinations. Pulmonary function testing at 6 months showed a relatively fixed obstructive pattern (Table 1), and he reported difficulty performing the various activities of daily living.

### Case 4

This 21-year-old man had 1% TBSA burns to the face, left axilla, and scrotum; and bilateral corneal injuries. Before transport to this center, he underwent a tracheostomy because of airway sloughing and plugging of the endotracheal tube. At one point he needed forceful manual ventilation for several hours to maintain oxygen saturations above 80%. On PBD 1, he was bacteremic and was started on broad-spectrum antibiotics. Before transport he was placed on the VDR-4 ventilator, which permitted a decrease in the inspiratory pressure to 30 cm H<sub>2</sub>O and the FIO<sub>2</sub> to 60% with acceptable blood gases.

CT scan of the lung showed bilateral perihilar ground-glass opacification and peribronchiolar edema (Figure 2). Bronchoscopy showed extensive edema, necrosis, and sloughing down to tertiary bronchioles. Esophagoduodenostomy showed esophagitis at the upper esophageal sphincter, but no injury elsewhere. Progressive hypercapnic failure peaked on PBD 28 with a PaCO<sub>2</sub> of 113 mm Hg. The difference between peak and plateau pressures was 27 cm H<sub>2</sub>O, consistent with increased airway resistance. Corticosteroids and bronchodilators were used with modest success; however, oxygen-helium mixture (heliox) had no effect. Bronchoscopy now showed some healing in the trachea, with islands of pedunculated granulation tissue scattered among areas of denuded epithelium. CT scan revealed worsening bronchiectasis and bleb disease (Figure 3).

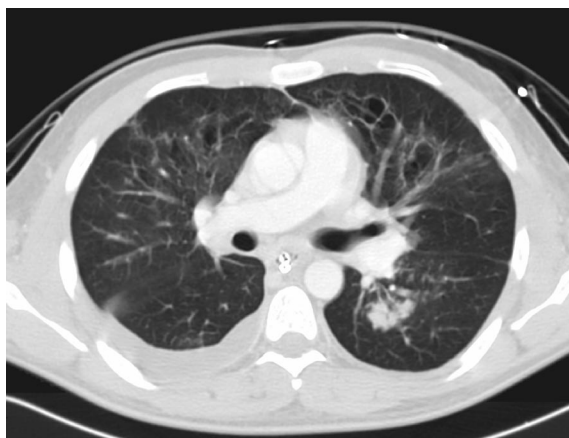


**Figure 2.** Initial computed tomography scan, 7 days after injury—case 4.

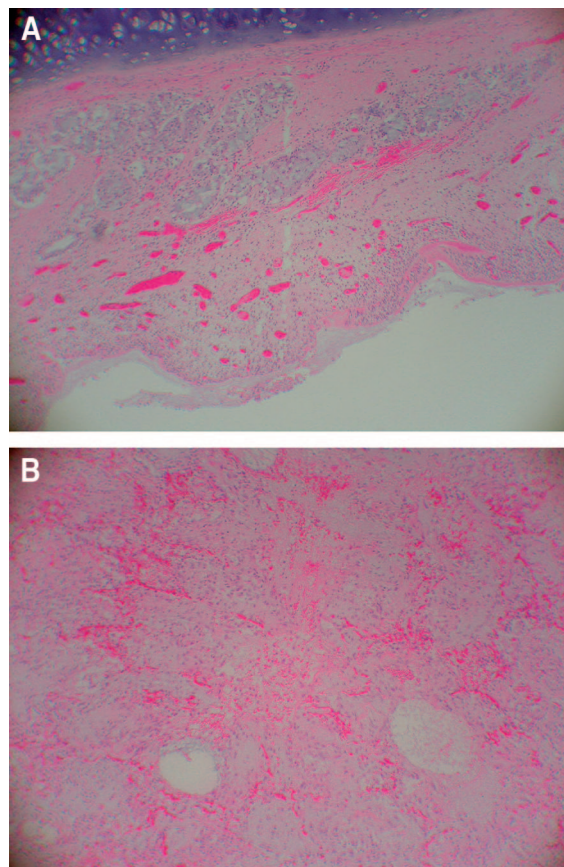
He required multiple thoracostomies for pneumothoraces, and treatment of pulmonary and bloodstream infections. Lung transplant was ruled out because of his infectious burden. He was not a candidate for extracorporeal membrane oxygenation because of the duration of respiratory failure. Given the likelihood of life-long ventilator dependence, he asked us to provide comfort care only. He died on PBD 100. Necropsy showed ulcers and areas of denuded epithelium in the tracheobronchial tree, and interstitial fibrosis and organized pneumonia as well as emphysematous changes in the lungs. Microscopic sections of lung revealed hemorrhage and thickening of alveoli with areas of dense fibrosis (Figure 4A, B).

### Case 5

This 33-year-old man was less severely injured when he attempted to rescue other victims. He was intubated at the referring hospital for respiratory diffi-



**Figure 3.** Computed tomography scan, 29 days after injury—case 4.

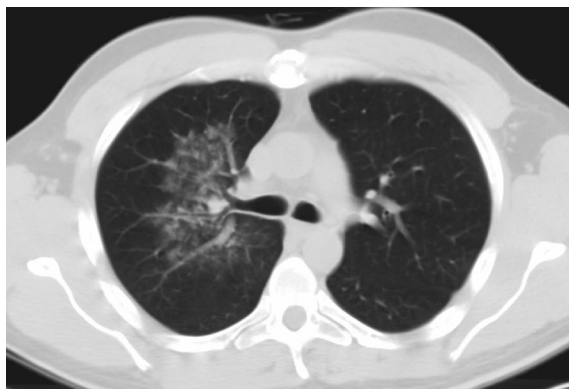

**Figure 4.** Case 4. A. Postmortem examination of trachea. This photomicrograph shows denuded mucosa, severe acute inflammation, and congestion of submucosa with intact submucosal glands and cartilage (magnification,  $\times 250$ ). B. Postmortem examination of lung. This photomicrograph shows remarkable fibrosis and congestion of alveolar septae, hemosiderin-laden macrophages, multinucleated giant cells, and type II pneumocyte hyperplasia (magnification,  $\times 450$ ).

culty, but extubated before transport here. He had no burns to the eyes or skin. CT scan showed perihilar ground-glass opacification and peribronchiolar edema limited to the right lung (Figure 5). Pulmonary function testing on PBD 9 showed a mild to moderate obstructive picture (Table 1). He was discharged on PBD 11 and had no follow-up at this facility.

### DISCUSSION

Anhydrous ammonia ( $\text{NH}_3$ ) is commonly used in farming and industry. Its use as a soil fertilizer has become commonplace in the mid-western United States, and it has been used for many years in refrigeration and air-conditioning systems as well as in the



**Figure 5.** Initial computed tomography scan, 6 days after injury—case 5.

production of explosives, petroleum, plastics, synthetic fibers, and household cleaners.<sup>1</sup> Recently, theft of anhydrous ammonia for use in methamphetamine production has increased.<sup>2</sup> Ammonia burns became more frequent with the widespread use of refrigeration after World War I<sup>3</sup>; clinical series are summarized in Table 2. Currently, ammonia accounts for few admissions to burn centers,<sup>11–13</sup> but it remains a leading cause of industrial and transportation accidents involving toxic chemicals.<sup>14</sup> Furthermore, like chlorine, hydrogen sulfide, and phosgene, this toxic industrial chemical could be used as a weapon of opportunity by terrorists or during armed conflict, underscoring the importance of familiarity with its treatment.<sup>15</sup>

At standard temperature and pressure, anhydrous ammonia is a colorless gas that is lighter than air and has a sharp, pungent odor. It is usually stored in steel tanks and transported under pressure at  $-33^{\circ}\text{C}$ , and acute exposure of skin may cause cold injury.<sup>16</sup> But the significance of the cold injury is minor when compared with the alkali burn. By itself, ammonia is not caustic. It is highly soluble in water, however, and quickly forms ammonium hydroxide ( $\text{NH}_4$ ), a strong base. Thus, burns are more frequent and deepest where body moisture is highest. This explains the

typical pattern of injury that predominantly involves the eyes, the oropharynx, the respiratory tract, and moist areas of the skin.<sup>17</sup> This distribution of injuries was well represented in our case study. Even brief exposure can cause significant injury; the concentration of the hydroxyl ions and the duration of exposure determine the amount of tissue destruction.<sup>9,17</sup>

### Initial Care

In the field and *en route*, rapid airway management and initiation of continuous eye and skin decontamination with water are critical. At the hospital, irrigation of cutaneous wounds should continue for 30 minutes and ocular irrigation should continue for a total of 8 hours.<sup>12</sup> If a definitive airway has not yet been established and there are significant burns to the face or pharynx, immediate endotracheal intubation should be considered because severe laryngeal edema may develop during the first 24 hours. Usually, those with findings on chest physical examination should be admitted for observation regardless of burn size. Chest radiograph and arterial blood gas values correlate poorly with extent of pulmonary injury and should not be relied on to determine which patients may develop respiratory problems.<sup>3,7</sup>

### Pulmonary Injury

After ammonia inhalation, life-threatening upper airway and tracheobronchial damage may progress within minutes. Although low concentrations are usually tolerable for hours without long-term complications, concentrations of 2500 to 4500 ppm can be fatal in 30 minutes, whereas concentrations above 5000 ppm usually produce rapid respiratory arrest.<sup>18</sup> Anhydrous ammonia vapor in high concentrations primarily affects the upper airway.<sup>7</sup> This is likely the result of three factors: stimulation of irritant receptors causing bronchoconstriction,<sup>19</sup> absorption of most of the ammonia by the large, moist surface area of the upper airway,<sup>20</sup> and rapid airway obstruction.<sup>3,21</sup> Prevention of further inhalation of the gas deeper into

**Table 2.** Clinical reports of ammonia injury

Author	Date	No. Casualties	No. Deaths	Number With Long-Term Complications
Slot <sup>4</sup>	1938	6	1	Not available
Caplin <sup>5</sup>	1941	47	13	Not available
Levy et al <sup>6</sup>	1964	4	0	0
Close et al <sup>7</sup>	1980	12	1	3
Montague and Macneil <sup>8</sup>	1980	14	0	Not available
Birken et al <sup>9</sup>	1981	1	1	No survivors
O’Kane <sup>10</sup>	1983	8	0	1
Arwood et al <sup>3</sup>	1985	2	2	No survivors

the lungs may forestall pulmonary sequelae.<sup>6,7</sup> Thus, Close et al described 12 patients from an accident in which a tank truck carrying ammonia exploded.<sup>7</sup> Seven fatalities were recorded at the scene as a result of inhalation. One group of patients who had exposure to high concentrations of ammonia during a brief period of time had upper airway obstruction and required early intubation and tracheostomy, whereas the second group exposed to lower concentrations of the gas during a longer period of time did not have upper airway obstruction. The former group recovered with few pulmonary problems and was in good health at end of follow-up, whereas the latter experienced significant long-term sequelae, namely obstructive pulmonary disease.

Patients who get sprayed with a jet of anhydrous ammonia (eg, sudden decompression of an ammonia tank) but quickly escape may have burns to the face, neck, upper extremities, and eyes without additional injury. Early intubation is life-saving. Because the lower airway is mostly spared, there is not likely to be extensive sloughing of mucosa and therefore tracheostomy may be deferred, as laryngeal edema usually resolves in 2 weeks.<sup>22</sup>

By contrast, victims who breathe lower concentrations of ammonia vapors during longer periods of time may not suffer upper airway obstruction, but will have severe burns throughout their entire tracheal-bronchial tree as a result of increased depth of inhalation.<sup>7,21</sup> This form of pulmonary injury is devastating. After extensive inhalation of ammonia, there is considerable degradation of collagen.<sup>23</sup> This injury is well documented by fiberoptic bronchoscopy, which initially shows erythema, congestion, and hemorrhage followed by extensive desquamation of the epithelium of the trachea. During the early phase of injury, hypoxemia and acute airway obstruction caused by the sloughing of mucosa pose the greatest threat. These patients should be intubated with the largest endotracheal tube practicable because sloughing may quickly occlude a smaller tube. To aid in pulmonary toilet, early tracheostomy should be considered. Based on experience with smoke inhalation injury, in the present study, we used nebulized heparin to facilitate the elimination of intraluminal clots and casts.<sup>24</sup> The dose of heparin is 5000 units/ml, 1 to 2 ml every 6 hours. It may be combined with albuterol, levalbeterol, and/or ipratropium to produce a final volume of 3 to 8 ml. Typically, it is continued until clinical or bronchoscopic airway healing is evident. High-frequency percussive ventilation using the VDR-4, which was also used in the care of these patients, is likely useful for clearing necrotic

debris from the smaller airways.<sup>25</sup> Inhaled corticosteroids have not been shown to decrease mortality from ammonia injury and may actually increase morbidity.<sup>3,26-28</sup>

To our knowledge, our case study represents the first in which CT scans of the chest were obtained soon after ammonia inhalation. These scans demonstrate both parenchymal and airway injury. The scans are also notable for the predominantly perihilar location of the parenchymal injury, suggesting that the alveoli closest to the bronchi are most vulnerable. In ovine models, we used CT scans to grade the severity of smoke inhalation injury,<sup>29</sup> and demonstrated characteristic changes associated with inhalation of chlorine gas.<sup>30</sup> More data on CT scan after ammonia injury would be helpful, because our experience suggests that it may be difficult to gauge severity of injury based on clinical criteria alone.

Following the early phase after injury there may be a lull of improved pulmonary function and decreased ventilator requirements before gradual onset of airway obstruction culminating in irreversible pulmonary failure (case 4). In most patients, this pause begins in the first 48 to 72 hours, depending on the severity of exposure.<sup>3</sup> Later, dead-space ventilation worsens and severe hypercarbia may develop, corresponding to the fibrous obliteration of small airways and bronchiectasis. Given the delayed time course of this phase, whether these lesions are a result of the initial chemical injury, of subsequent bacterial infection, or both is unknown.

In survivors, there may be a small, reversible component of bronchoconstriction related to a "hyperactive" bronchial tree<sup>31</sup>; however, the vast majority of the obstruction is fixed and poorly responsive to bronchodilators. The long-term pulmonary prognosis of those who can be removed from mechanical ventilation is related to the amount of fixed parenchymal scar, and dramatic improvement of this obstructive pathophysiology is unlikely.<sup>20,21,31</sup> These patients may require life-long bronchodilator therapy with intermittent pulsed steroids and antibiotics for pulmonary infections.

Patients who cannot be weaned because of respiratory failure and severe hypercapnia will most likely die of pneumonia despite maximal supportive care. Necropsy findings from victims of ammonia inhalation within minutes to days of injury reveal tracheobronchial ulcerations, denuded epithelium with pseudomembrane formation, as well as pulmonary edema and bronchopneumonia.<sup>5,32</sup> Pathological findings months to years from time of injury show fibrous obliteration of small airways, consistent with late-stage bronchiolitis obliterans, which

may account for the chronic obstructive lung disease seen in survivors of this case study (cases 1, 2, 3).<sup>9,33,34</sup>

### Cutaneous Injury

The hydrophobic/lipophilic epidermis is usually a good barrier against penetration by water-soluble substances, but ammonium hydroxide quickly saponifies epidermal fats and moves into the more hydrophilic dermis. Here, after dissolving the cell membrane, ammonia denatures tissue proteins due to the production of gel-like alkaline proteinates.<sup>22</sup> Destruction of lipids in the cell membrane produces liquefactive necrosis resulting in deeper penetration and depth of injury. Furthermore, alkalis tend to be adherent and to resist irrigation.<sup>12</sup> Therefore, alkaline burns require not only copious irrigation but also mechanical cleansing of the affected area(s) to limit depth and extent of injury.

Ammonia burns may appear as a gray-yellow area with a soft texture, with severe cases appearing black and having a leather consistency. The ultimate depth of injury may not be evident at admission.<sup>9</sup> However, full-thickness burn wounds are the exception in anhydrous ammonia injuries, and the mean burn size is about 10%.<sup>8,17</sup> Few patients require skin grafting, and care of the partial thickness wounds consists of daily debridement and dressing changes with a topical antimicrobial such as silver sulfadiazine.

### Eye Injury

Because of its extreme solubility, ammonium hydroxide rapidly diffuses through ocular tissues and typically causes more corneal endothelial damage, corneal stromal edema, and lens damage than other alkalis.<sup>9</sup> Studies on rabbits have shown detectable amounts of ammonia in the aqueous humor 5 seconds after conjunctival sac instillation.<sup>28</sup> Mild ocular injuries may cause increased lacrimation, conjunctivitis, palpebral edema, blepharospasm, and photophobia, whereas severe injury may lead to atrophy of the iris and cataract formation and signs mimicking acute closed-angle glaucoma, all associated with permanent visual loss.<sup>3,17,35</sup> Attempts at corneal transplantation may fail due to scarring and neovascularization of the cornea, which leaves a poor bed for grafting. Local application of steroids, mydriatic and cycloplegic agents, or antibiotics may reduce inflammatory damage, and acetazolamide may lower intraocular pressures, but rapid evacuation and copious irrigation of the eyes with water or saline are the most important factors in preventing permanent loss of eyesight. This treatment should begin without delay and continue for at least 20 minutes or until the pH of the conjunctival sacs falls

below 8.5.<sup>17</sup> At the level of definitive treatment, irrigation of the eyes should continue and an ophthalmologist should evaluate the patient.

### CONCLUSIONS

Exposure to anhydrous ammonia results in damage to the skin, eyes, and aerodigestive tract. Ocular injuries may result in permanent visual loss. Cutaneous burn wound care is similar to that for other chemical burns. Both can be minimized by prompt identification and copious irrigation of skin and eyes. These five cases demonstrate that injury to the respiratory tract is life-threatening, and may cause long-term obstructive lung disease.

### ACKNOWLEDGMENTS

We are grateful to Ms. Amy Newland for assistance in editing the manuscript.

### REFERENCES

1. Hartle R. Background Information on Ammonia. Government Reports Announcements & Index (GRA&I), Issue 3. Report No. NTIS/PB82-109984. Cincinnati, OH: National Institute for Occupational Health and Safety; 1982.
2. Centers for Disease Control and Prevention. Anhydrous ammonia thefts and releases associated with illicit methamphetamine production—16 states, January 2000–June 2004. *MMWR* 2005;54:359–61.
3. Arwood R, Hammond J, Ward GG. Ammonia inhalation. *J Trauma* 1985;25:444–7.
4. Slot GMJ. Ammonia gas burns: account of six cases. *Lancet* 1938;2:1356–7.
5. Caplin M. Ammonia gas poisoning: forty-seven cases in a London shelter. *Lancet* 1941;2:95–6.
6. Levy DM, Divertie MB, Litzow TJ, et al. Ammonia burns of the face and respiratory tract. *JAMA* 1964;190:95–8.
7. Close LG, Catlin FI, Cohn AM. Acute and chronic effects of ammonia burns on the respiratory tract. *Arch Otolaryngol* 1980;106:151–8.
8. Montague TJ, Macneil AR. Mass ammonia inhalation. *Chest* 1980;77:496–8.
9. Birken GA, Fabri PJ, Carey LC. Acute ammonia intoxication complicating multiple trauma. *J Trauma* 1981;21:820–2.
10. O'Kane GJ. Inhalation of ammonia vapour. A report on the management of eight patients during the acute stages. *Anaesthesia* 1983;38:1208–13.
11. Mazingo DW, Smith AA, McManus WF, et al. Chemical burns. *J Trauma* 1988;28:642–7.
12. Latenser BA, Lucktong TA. Anhydrous ammonia burns: case presentation and literature review. *J Burn Care Rehabil* 2000;21:40–2.
13. Barillo DJ, Cancio LC, Goodwin CW. Treatment of white phosphorus and other chemical burn injuries at one burn center over a 51-year period. *Burns* 2004;30:448–52.
14. Weisskopf MG, Drew JM, Hanrahan LP, et al. Hazardous ammonia releases: public health consequences and risk factors for evacuation and injury, United States, 1993–1998. *J Occup Environ Med* 2003;45:197–204.
15. Cancio LC. Current concepts in the pathophysiology and treatment of inhalation injury. *Trauma* 2005;7:19–35.

16. Wibbenmeyer LA, Morgan LJ, Robinson BK, et al. Our chemical burn experience: exposing the dangers of anhydrous ammonia. *J Burn Care Rehabil* 1999;20:226-31.
17. Millea TP, Kucan JO, Smoot EC 3rd. Anhydrous ammonia injuries. *J Burn Care Rehabil* 1989;10:448-53.
18. Baker DE. Using Anhydrous Ammonia Safely. Report No. GO1920. Columbia, MO: University Extension, University of Missouri. October 1993; available from <http://www.cdc.gov/nasd/docs/d000801-d000900/d000875/d000875.html>; Internet; accessed Nov. 2006.
19. Nadal JA. Parasympathetic nervous control of airway smooth muscle. *Ann NY Acad Sci* 1974;221:99-102.
20. Kass I, Zamel N, Dobry CA, et al. Bronchiectasis following ammonia burns of the respiratory tract. A review of two cases. *Chest* 1972;62:282-5.
21. Leduc D, Gris P, Lheureux P, et al. Acute and long term respiratory damage following inhalation of ammonia. *Thorax* 1992;47:755-7.
22. Amshel CE, Fealk MH, Phillips BJ, et al. Anhydrous ammonia burns: case report and review of the literature. *Burns* 2000;26:493-7.
23. Hatton DV, Leach CS, Beaudet AL, et al. Collagen breakdown and ammonia inhalation. *Arch Environ Health* 1979;34:83-7.
24. Desai MH, Mlcak R, Richardson J, et al. Reduction in mortality in pediatric patients with inhalation injury with aerosolized heparin/N-acetylcysteine therapy. *J Burn Care Rehabil* 1998;19:210-2.
25. Cioffi WG Jr, Rue LW 3rd, Graves TA, et al. Prophylactic use of high-frequency percussive ventilation in patients with inhalation injury. *Ann Surg* 1991;213:575-82.
26. Sjoblom E, Hojer J, Kulling PE, et al. A placebo-controlled experimental study of steroid inhalation therapy in ammonia-induced lung injury. *J Toxicol Clin Toxicol* 1999;37:59-67.
27. Leonard LG, Scheulen JJ, Munster AM. Chemical burns: effect of prompt first aid. *J Trauma* 1982;22:420-3.
28. Boyd EM, MacLachlan ML, Perry WF. Experimental ammonia gas poisoning in rabbits and cats. *J Ind Hygiene Toxicol* 1944;26:29.
29. Park MS, Cancio LC, Batchinsky AI, et al. Assessment of the severity of ovine smoke inhalation injury by analysis of CT scans. *J Trauma* 2003;55:417-27.
30. Batchinsky AI, Martini DK, Jordan BS, et al. Acute respiratory distress syndrome secondary to inhalation of chlorine gas in sheep. *J Trauma* 2006;60:944-957.
31. Flury KE, Dines DE, Rodarte JR, et al. Airway obstruction due to inhalation of ammonia. *Mayo Clin Proc* 1983;58:389-93.
32. Dérobert L, Proteau J, Caroff J. Étude anatomique de quatre cas d'intoxication aiguë par inhalation de gaz ammoniac. *Amm Méd Lég* 1964;44:362.
33. Hoeffler HB, Schweppe HI, Greenberg SD. Bronchiectasis following pulmonary ammonia burn. *Arch Pathol Lab Med* 1982;106:686-7.
34. Sobonya R. Fatal anhydrous ammonia inhalation. *Hum Pathol* 1977;8:293-9.
35. Highman VN. Early rise in intraocular pressure after ammonia burns. *BMJ* 1969;1:359-60.