

Evaluation of Renal Cortical Perfusion by Noninvasive Power Doppler Ultrasound During Vascular Occlusion and Reperfusion

Toshiyuki Kuwa, MD, Leopoldo C. Cancio, MD, Jill L. Sondeen, PhD, Natalya Matylevich, PhD, Bryan S. Jordan, RN, Albert T. McManus, PhD, and Cleon W. Goodwin, MD

Background: Urine output, a frequently used resuscitation end point, is presumed to represent renal cortical perfusion. However, no noninvasive method for direct measurement of renal perfusion exists. Power Doppler ultrasound (PDUS) is a method that reportedly is sensitive to low-velocity and microvascular blood flow and can depict it. This study aimed to develop a quantitative technique for PDUS image analysis, and to evaluate the ability of PDUS to quantify cortical perfusion during renal ischemia induced by vascular occlusion.

Methods: A method was developed to

determine the mean gray-scale intensity of PDUS images from within the renal cortex (PDUS image intensity). This index was hypothesized to represent renal cortical microvascular blood flow. Renal cortical blood flow was determined using fluorescent microspheres in five swine. Renal artery flow was measured with an ultrasonic flow probe. Power Doppler ultrasound was performed at baseline; at 75%, 50%, and 25% of baseline renal artery flow; and during reperfusion.

Results: Subjectively, PDUS images showed decreases in image intensity cor-

responding to renal artery occlusion and increases after reperfusion. Cortical blood flow correlated well with renal artery flow ($n = 25$; $r^2 = 0.868$) and with PDUS image intensity ($n = 25$; $r^2 = 0.844$).

Conclusion: Noninvasive power Doppler ultrasound image intensity correlated well with invasively measured renal cortical blood flow, and may be useful during resuscitation of injured and critically ill patients.

Key Words: Kidney, Regional blood flow, Power Doppler ultrasound, Ischemia, Reperfusion.

J Trauma. 2004;56:618–624.

Power Doppler ultrasound (PDUS) is a relatively new technology in which spectral analysis of the received ultrasonic signal and integration of the resulting amplitude–frequency function permit display of a perfusion index

for each pixel.^{1,2} Color Doppler ultrasound displays mean velocity data and is useful in the study of large-vessel blood flow. In contrast, PDUS displays data influenced by the number of red blood cells moving in the region of interest and purportedly is capable of detecting small-vessel, low-velocity flow.³ However, quantitative assessment of PDUS ability to measure changes in organ perfusion at the capillary level during ischemia or shock states has not been described.

The purpose of this study was to develop a quantitative image analysis method for PDUS, and to determine whether the intensity of the PDUS image correlates with renal cortical blood flow (CORFLO), as quantified by fluorescent microspheres during vascular occlusion in a porcine model. The authors sought to develop a tool for measuring renal CORFLO during shock states.

MATERIALS AND METHODS

This study was approved by the institutional Animal Care and Use Committee. The care of all animals was in accordance with the guidelines set forth by the Animal Welfare Act, other federal statutes and regulations relating to animals and studies involving animals, and the National Research Council's 1996 *Guide for the Care and Use of Laboratory Animals*. All the animals were maintained in a facility approved by the Association for Assessment and Accreditation of Laboratory Animal Care International.

Submitted for publication September 4, 2002.

Accepted for publication April 11, 2003.

Copyright © 2004 by Lippincott Williams & Wilkins, Inc.

From the U.S. Army Institute of Surgical Research, Fort Sam Houston, Texas (L.C.C., J.L.S., N.M., B.S.J., A.T.M., C.W.G.), and the Trauma and Critical Care Center, Hyogo Prefectural Nishinomiya Hospital, Nishinomiya City, Hyogo, Japan (T. Kuwa).

Funded in part by the Combat Casualty Care research program of the U.S. Army Medical Research and Materiel Command, Fort. Detrick, Maryland.

Presented at the 31st Annual Meeting of American Burn Association, March 24–27, 1999, Lake Buena Vista, Florida.

The opinions or assertions contained in this article are the private views of the authors and are not to be construed as official or as reflecting the views of the Department of the Army or the Department of Defense.

The authors have no financial interest in the subject matter or materials discussed in this article, including, but not limited to, employment, consultancies, stock ownership, honoraria, and paid expert testimony. However, Drs. Cancio, Kuwa, and Matylevich are the coinventors of the power Doppler ultrasound image analysis technique described in this article, for which a U.S. Patent has been allowed by the U.S. Patent and Trademark Office. They have assigned the rights to this invention to the U.S. Army, but by regulation would receive from the Army a small fraction of the royalties from any successful commercial application of this technique. The authors, however, are not aware of any planned commercial application at this time.

Address for reprints: Library Branch, U.S. Army Institute of Surgical Research, 3400 Rawley East Chambers Avenue, Fort Sam Houston, TX; email: Lee.Cancio@amedd.army.mil.

DOI: 10.1097/01.TA.0000075331.21241.80

Report Documentation Page

*Form Approved
OMB No. 0704-0188*

Public reporting burden for the collection of information is estimated to average 1 hour per response, including the time for reviewing instructions, searching existing data sources, gathering and maintaining the data needed, and completing and reviewing the collection of information. Send comments regarding this burden estimate or any other aspect of this collection of information, including suggestions for reducing this burden, to Washington Headquarters Services, Directorate for Information Operations and Reports, 1215 Jefferson Davis Highway, Suite 1204, Arlington VA 22202-4302. Respondents should be aware that notwithstanding any other provision of law, no person shall be subject to a penalty for failing to comply with a collection of information if it does not display a currently valid OMB control number.

1. REPORT DATE 01 MAR 2004		2. REPORT TYPE N/A		3. DATES COVERED -	
4. TITLE AND SUBTITLE Evaluation of renal cortical perfusion by noninvasive power Doppler ultrasound during vascular occlusion and reperfusion				5a. CONTRACT NUMBER	
				5b. GRANT NUMBER	
				5c. PROGRAM ELEMENT NUMBER	
6. AUTHOR(S) Kuwa T., Cancio L. C., Sondeen J. L., Matylevich N., Jordan B. S., McManus A. T., Goodwin C. W.,				5d. PROJECT NUMBER	
				5e. TASK NUMBER	
				5f. WORK UNIT NUMBER	
7. PERFORMING ORGANIZATION NAME(S) AND ADDRESS(ES) United States Army Institute of Surgical Research, JBSA Fort Sam Houston, TX 78234				8. PERFORMING ORGANIZATION REPORT NUMBER	
9. SPONSORING/MONITORING AGENCY NAME(S) AND ADDRESS(ES)				10. SPONSOR/MONITOR'S ACRONYM(S)	
				11. SPONSOR/MONITOR'S REPORT NUMBER(S)	
12. DISTRIBUTION/AVAILABILITY STATEMENT Approved for public release, distribution unlimited					
13. SUPPLEMENTARY NOTES					
14. ABSTRACT					
15. SUBJECT TERMS					
16. SECURITY CLASSIFICATION OF:			17. LIMITATION OF ABSTRACT SAR	18. NUMBER OF PAGES 7	19a. NAME OF RESPONSIBLE PERSON
a REPORT unclassified	b ABSTRACT unclassified	c THIS PAGE unclassified			

Operation

Five male Yorkshire swine (mean weight, 18.4 kg; range, 16.4–19.4 kg) were used. After an overnight fast, these swine were sedated with intramuscular tiletamine–zolazepam (3 mg/kg; Fort Dodge Laboratories, NW Fort Dodge, IA) and atropine (0.1 mg/kg; Vedco, St. Joseph, MO). General anesthesia was induced 10 minutes later using isoflurane (Ohmeda Caribe, Gayama, Puerto Rico) administered through a nose cone. The pigs then were intubated with a 6- to 8-mm endotracheal tube (Kendall Company, Mansfield, MA). The right carotid artery was cannulated with a 1.9-mm catheter (Becton Dickinson and Company, Sparks, MD) for blood pressure monitoring. The jugular vein was cannulated with a 7-Fr introducer (Arrow International, Reading, PA) for infusion of drugs and fluids. A 1.9-mm right femoral arterial line (Becton Dickinson) was placed and advanced into the descending aorta to the level of the xiphoid process to remove blood for fluorescent microsphere determination.

A left anterior thoracotomy was performed. A 1.9-mm catheter (Becton Dickinson) was placed into the left atrium for injection of fluorescent microspheres and secured with a purse-string suture. A 12-Fr chest tube (Argyle-Sherwood Medical, St. Louis, MO) was placed and connected to an underwater seal, and the thoracotomy was closed. By a right retroperitoneal approach, the right renal artery was exposed and a vascular occluder (OC3; In Vivo Metric Systems, Healdsburg, CA) together with an ultrasonic flow probe (3RB; Transonic Systems, Ithaca, NY) was placed about the artery. After the retroperitoneal space had been filled with ultrasound transmission gel (Graham-Field, Hauppauge, NY), the wound was closed in layers. The use of this gel was necessary to eliminate air pockets, which otherwise persisted after dissection in this acute experiment, degrading the ultrasound images.

Maintenance

The animals, immobilized in the left lateral decubitus position on a warming blanket, were mechanically ventilated with isoflurane (1–2%), air, and oxygen using an anesthesia machine. Tidal volume was maintained at 13 mL/kg. The fraction of inspired oxygen was maintained at approximately 50%, and the respiratory rate was adjusted to maintain the partial pressure of carbon dioxide at approximately 40 mm Hg. The animals received lactated Ringer's solution (50–100 mL/hour), were continuously sedated with fentanyl citrate (0.02–0.03 mg/kg/hour), and received pancuronium bromide (Gensia Laboratories, Irvine, CA) at a rate of 2 mg every 30 minutes. Arterial blood pressure was monitored, and a systolic pressure greater than 90 mm Hg was maintained.

Vascular Occlusion and Imaging

When the arterial blood pressure stabilized at a systolic pressure exceeding 90 mm Hg, the baseline renal artery flow (RAFLO) was measured with the ultrasonic flow probe.

Gray-scale ultrasonography of the right kidney was performed, a PDUS image was obtained, and fluorescent microspheres were injected, as described later. Then the vascular occluder was inflated until RAFLO, as determined by the ultrasonic flow probe, was reduced to 75% of the baseline value. Another PDUS reading was taken, and injection of fluorescent microspheres was performed again. This procedure was repeated with flow at 50% and 25%, then after release. Images were taken at each of these time points. Several minutes were permitted to elapse after each change in cuff pressure to ensure stable vital signs and arterial flow. The animals were euthanized with sodium pentobarbital (25 mg/kg; Sigma Chemical, St. Louis, MO) and an overdose of a 20% potassium chloride solution (15–20 mL, International Medication Systems, El Monte CA) after the final measurement.

Regional Blood Flow Technique

The following procedure was used to measure regional blood flow by the reference–sample technique using fluorescent microspheres.⁴ Before each measurement, the femoral arterial line was flushed with heparin solution (1,000 units/mL; Elkins-Sinn, Cherry Hill, NJ) and connected to a calibrated Harvard Apparatus (2400–003; Harvard Apparatus, Inc., Holliston, MA). The latter used a 30-mL glass syringe containing heparin (2,000 units). Approximately 5 million 15- μ m fluorescent microspheres (Nu-Flu; Interactive Medical Technology, Los Angeles, CA) diluted in normal saline to a total volume of 10 mL were injected over 60 seconds through the left atrial catheter. Reference–sample blood withdrawal by the Harvard apparatus at a rate of 5 mL/minute began 10 seconds before initiation of microsphere injection, and was completed after a total of 3 minutes and 10 seconds. Altogether, seven microsphere colors were used for each animal. After euthanasia, a portion of the right renal cortex, exclusive of the juxtamedullary cortex, was excised. Microspheres were extracted from the tissue, and regional blood flow was determined by flow cytometry (Interactive Medical Technology, Irvine, CA).⁵

Image Acquisition and Analysis Techniques

Power Doppler sonography was performed by a single examiner using the Powervision system (Powervision SSA-380A, Toshiba Corporation, Tokyo, Japan) and a 3.75-MHz convex transducer (Toshiba Corporation). The image analysis procedure is briefly summarized in Figure 1. A gray-scale ultrasound image depicting a longitudinal section of the kidney in full length was obtained. Because of the limitations imposed by intervening structures such as the ribs, this section typically was oblique rather than strictly sagittal or coronal. The PDUS mode then was activated. Because PDUS image intensity typically fluctuates, PDUS images were obtained and stored continuously over 1 minute. All the stored images were reviewed and, the image with the richest-appearing flow was selected. The gray-scale version of the

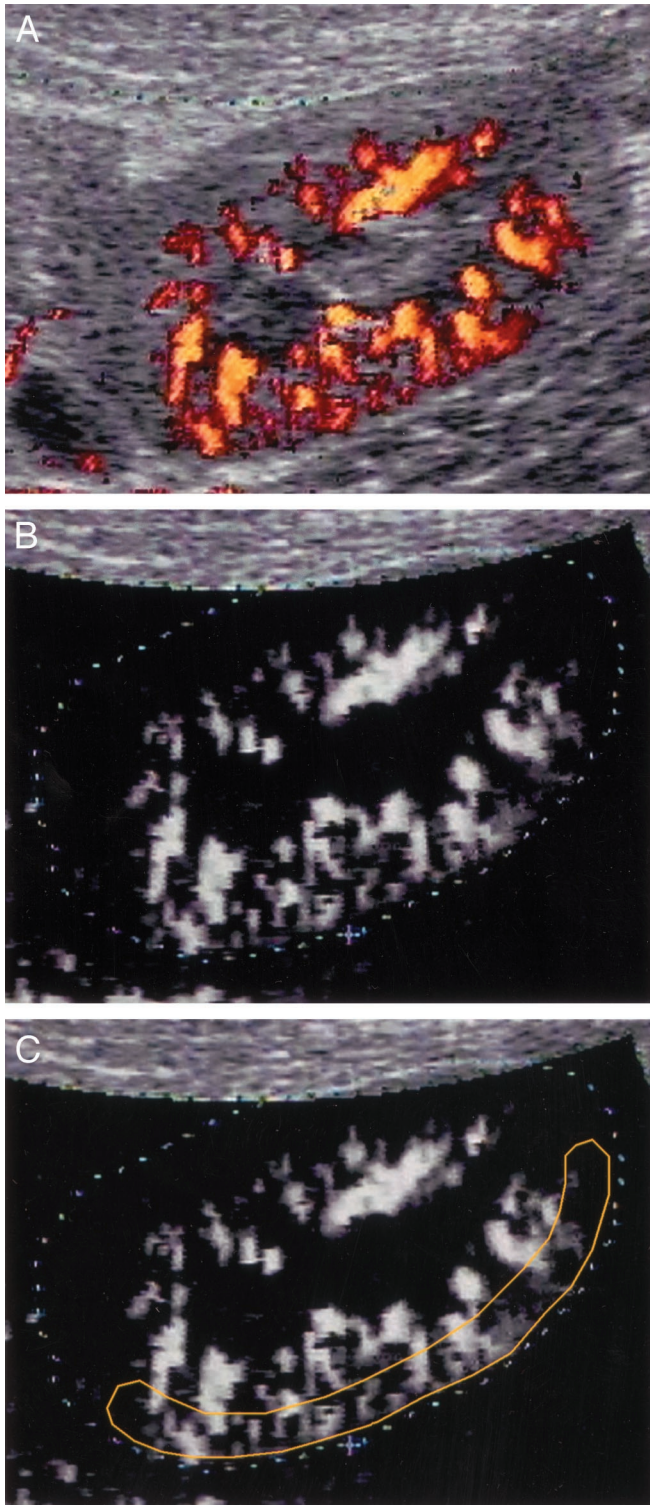


Fig. 1. Summary of analysis procedure for power Doppler ultrasound (PDUS) images. (A) Typical PDUS image involving the porcine kidney. This is an oblique longitudinal section. Perfusion index data are superimposed on a gray-scale ultrasound image of the kidney. In this scheme, brighter PDUS images indicate greater perfusion. Dotted lines, shown in the subsequent images, were traced around the outside of the gray-scale outline of the kidney.

PDUS image, which incorporates PDUS image intensity data but omits gray-scale anatomic details, was saved to a laptop computer (Dell, Austin, TX) as a JPEG file using a Snappy frame grabber (Play, Cordova, CA).

Image analysis was performed offline by a modification of Akiyama's method,⁶ using Adobe Photoshop version 4.01 software (Adobe Systems, San Jose, CA) for image manipulation and Optimas version 5.22 software (Optimas, Bothell, WA) for image analysis. Specifically, the JPEG file was opened in Photoshop. The image background (levels 0 to 30 on this Toshiba system) was deleted using the Adjust Levels function. The image then was opened in Optimas. A region of interest (ROI) comprising approximately one-half of the renal cortex was selected. The mArGVHistogram function was used to generate a scaled gray-value histogram of the pixels within the ROI. These data were saved as an Excel file (Microsoft, Redmond, WA). Each gray-scale level in a range of 1 (black) to 256 (white) was multiplied by the number of pixels with that intensity in the ROI. The sum of these products was divided by the total number of pixels in the ROI as follows:

$$\text{PDUSII} = \frac{\sum (L * P_L)}{\sum P_L}$$

where L is the gray-scale level, P_L is the number of pixels as a function of gray-scale level, and $\sum P_L$ is the total number of pixels in the ROI. The PDUS image intensity (PDUSII) was hypothesized to be an index of the relative perfusion of the ROI.

Statistical Analysis

Statistical analysis was performed with SPSS 10.1 software (SPSS, Chicago, IL). Continuous variables were analyzed using linear regression. Pearson correlation coefficients were calculated where appropriate. One-way analysis of variance (ANOVA) with repeated measures on time was used. If the ANOVA was significant, predetermined post hoc comparisons were made with paired *t* tests. Statistical significance was determined by a *p* value less than 0.05. Data are presented as means \pm standard error of the mean.

RESULTS

In all cases, the power Doppler images showed decreases in qualitative image intensity corresponding to renal artery occlusion as well as increases after reperfusion (Fig. 2). By

(This was done for convenience; exact delineation of the kidney is not a critical element of the method.) (B) Same image with the gray-scale ultrasound data removed. (C) Region of interest (ROI) section consisting of the renal cortex. The mean gray-scale intensity of this ROI, termed "PDUS image intensity" (PDUSII) was taken to indicate cortical perfusion.

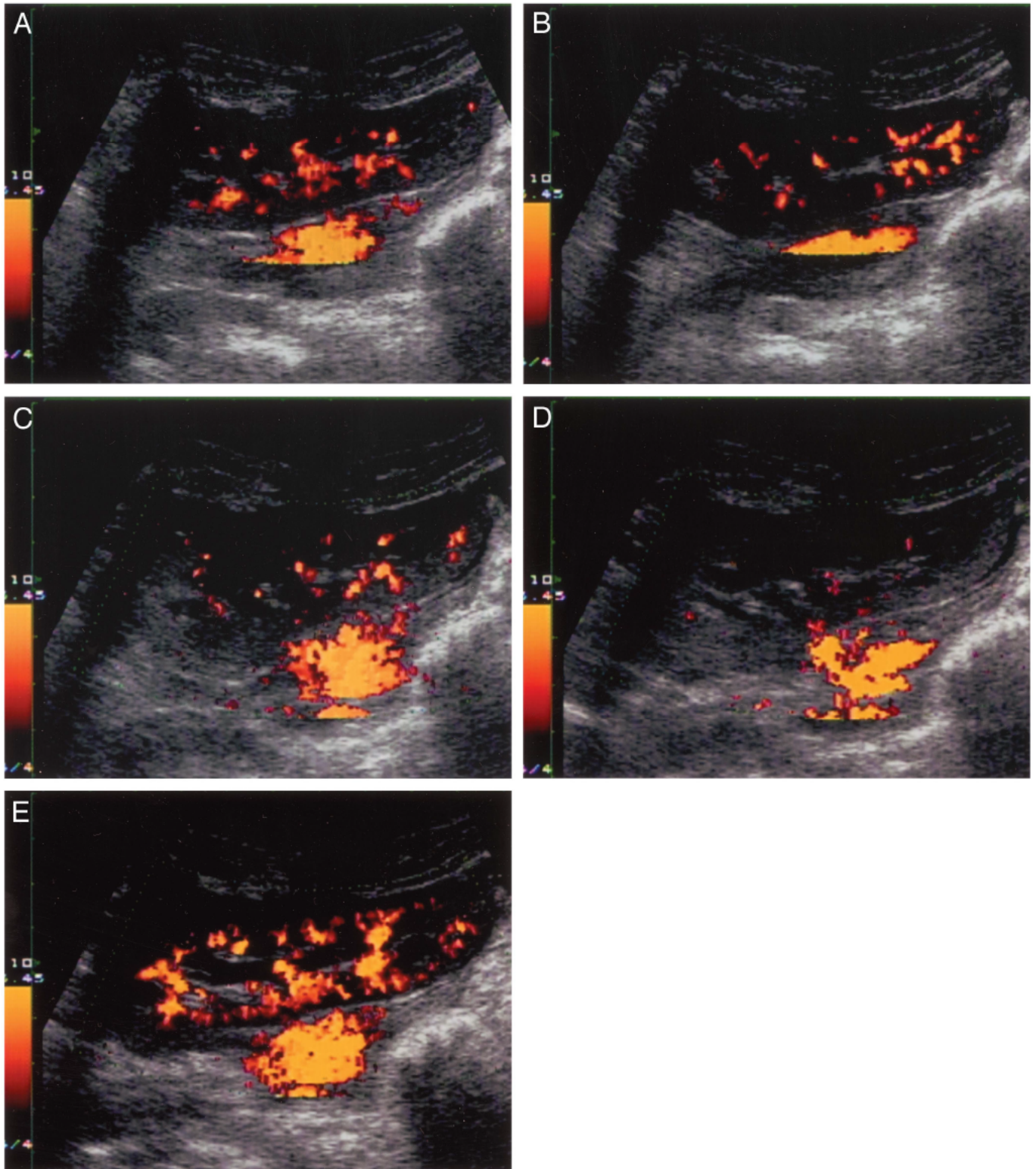


Fig. 2. Characteristic changes in the PDUS images of the kidney during vascular occlusion and after release. (A) Baseline (100%) of renal arterial flow (RAFLO). (B) 75% RAFLO. (C) 50% RAFLO. (D) 25% RAFLO. (E) After release.

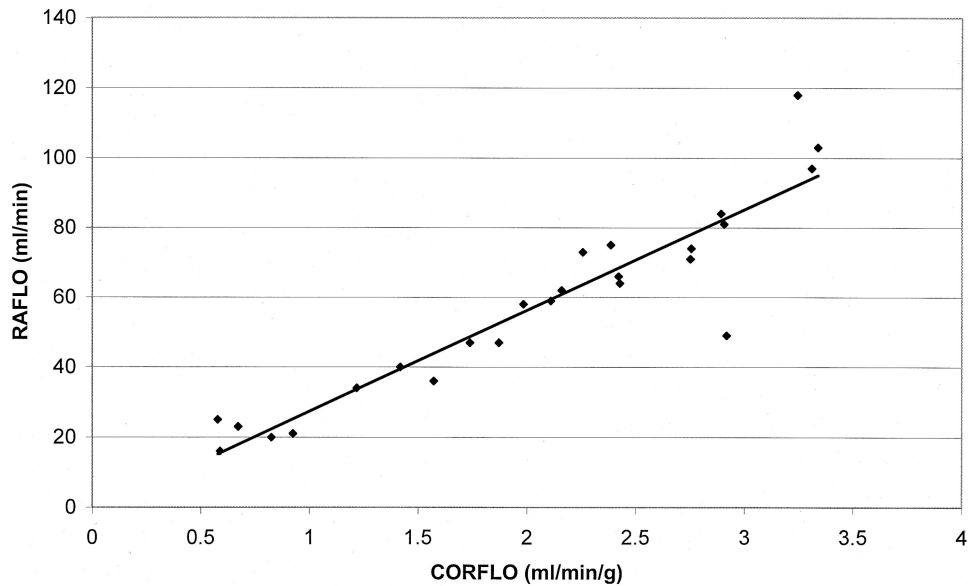


Fig. 3. Vascular occlusion study. Linear regression of renal arterial flow (RAFLO) and cortical blood flow (CORFLO) ($n = 25$; $r^2 = 0.868$). Power Doppler ultrasound image intensity (PDUSII) is expressed in arbitrary units.

linear regression, RAFLO was significantly related to CORFLO ($n = 25$; $r^2 = 0.868$; Fig. 3), and PDUSII was related to CORFLO ($n = 25$; $r^2 = 0.844$; Fig. 4) and RAFLO ($n = 25$; $r^2 = 0.704$).

DISCUSSION

The principal finding in this study was that PDUSII correlates well with invasively measured renal CORFLO during vascular occlusion and reperfusion.

The urine output is a frequently used index for adequacy of resuscitation because it is easily measured and presumed to

reflect renal perfusion. For example, in the case of thermally injured patients, a physiologic crystalloid solution is initiated at a rate predicted by the burn size and body weight, and the rate is titrated primarily on the basis of the urine output.⁷ However, this approach fails on occasion, particularly in massively burned patients. A review at the U.S. Army Burn Center showed that 12 of 93 nonsurviving burn patients (13%) were resuscitation failures, in whom hemodynamic stability could not be achieved.⁸ To salvage such high-risk patients, new monitoring devices that accurately assess tissue perfusion may be necessary. Pulmonary artery catheters often

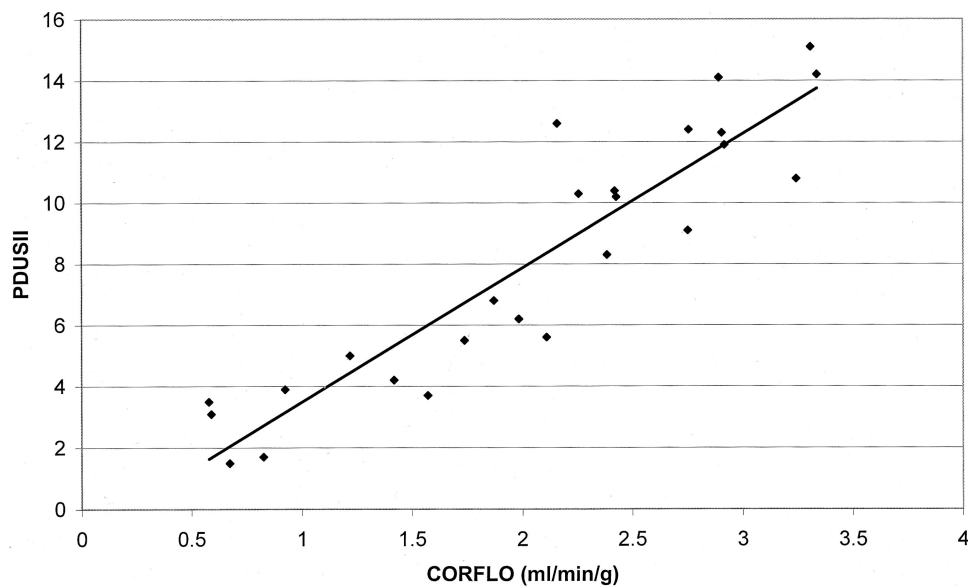


Fig. 4. Vascular occlusion study. Linear regression of cortical blood flow (CORFLO) and power Doppler ultrasound image intensity (PDUSII) ($n = 25$; $r^2 = 0.844$), with PDUSII expressed in arbitrary units.

are placed during complicated resuscitations,⁹ but they carry finite risks such as pneumothorax, pulmonary artery laceration, pulmonary infarction, and line sepsis. Also, data derived from pulmonary artery catheters, arterial blood gases, and so forth address global perfusion but not regional organ perfusion, whereas the latter may be more important in resuscitation.

Furthermore, for patients with acute renal failure, whether oliguric or nonoliguric, urine output does not necessarily reflect renal perfusion or function. This is likewise true of patients who have received a diuretic, whose urine output is driven by glycosuria or nitrogen metabolites, and those in whom alcohol has inhibited antidiuretic hormone release. Also, an intervention intended to improve renal blood flow, such as the institution of an inotropic agent or a bolus of an intravenous crystalloid solution, may affect urine output in a delayed fashion. It is likely that PDUS would have its greatest utility in situations with urine output of questionable significance.

Currently, PDUS is available on most commercial ultrasound systems. In this mode, the ultrasound processor performs spectral analysis of the reflected sound (e.g., via fast-Fourier transformation). The amplitude (or power) of each received frequency is presumably proportional to the number of red blood cells (RBCs) reflecting at that frequency. Frequency, in turn, is proportional to the velocity of the RBCs. Thus, a large number of RBCs moving at a low velocity should generate a high-power, low-frequency signal, whereas a smaller number of RBCs moving at a high velocity should generate a low-power, high-frequency signal. The processor then integrates the power of the received signal over frequency to obtain a perfusion index for each pixel.¹⁰ In vitro phantom studies have shown that PDUS image intensity depends, as expected, on both the velocity and the concentration of reflecting particles. Commercially available ultrasound devices translate these numeric data into color output, in which the magnitude of the perfusion index for a particular pixel is represented by the color intensity of that pixel. This color information is superimposed on the gray scale ultrasound image.¹¹ Thus, PDUS must be distinguished from color Doppler ultrasound, in which mean velocity is displayed whereas amplitude (power) data are lost.

In the current study, an image analysis technique was developed, in which the perfusion index data for all the pixels in a ROI were extracted. This resulted in a new index for the ROI as a whole, which the authors termed PDUSII. Instruments allowing the user to streamline the image analysis process by providing direct access to the perfusion index data may be desirable, but are not currently available.¹¹

One advantage of PDUS is that it can detect slow blood flow such as capillary vessel flow. The slowest flow velocity detected on power flow images is less than 1 cm/second. By contrast, blood flow slower than 4 cm/second may not be detectable in the color mode.⁶ Another advantage of PDUS is that it is not subject to aliasing (a signal wraparound phe-

nomenon seen with color Doppler ultrasonography). The relative angle independence of PDUS makes it less sensitive to inaccurate flow information based on an improper angle of insonation.^{1,12} One disadvantage of PDUS is its longer scanning time, which makes it more susceptible to motion and flash artifacts.¹³⁻¹⁵ This in turn makes PDUS difficult to use for patients who are unable or unwilling to lie still or suspend breathing during scanning,² or for the imaging of organs subject to movement such as the liver, gallbladder, or heart.¹ These limitations were not significant in the current study.

The current study used PDUS imaging of the renal cortex. The renal cortex was chosen because in pilot animals, liver and skeletal muscle were poorly visualized with PDUS. Clinical and animal studies using PDUS have, as in the current study, demonstrated its utility in imaging the kidneys. Bude et al.² demonstrated the increased sensitivity of PDUS over CDUS for depicting intrarenal and renal cortical flow in normal human kidneys, describing the latter as a nonpulsatile "blush." Durick et al.¹⁴ used an image analysis procedure to quantify changes in total renal perfusion as depicted by PDUS after infusion of epinephrine and then papaverine into the renal artery of swine. Taylor et al.¹⁶ used contrast-enhanced PDUS to measure renal cortical perfusion during hemorrhagic hypotension in rabbits and found good correlation with blood flow, as measured by radiolabeled microspheres. In contrast to the current study, this correlation was not found when ultrasonographic contrast injection was not performed. Other uses of PDUS include assessment of renal perfusion in renal transplants,^{6,17} diagnosis of pyelonephritis,^{18,19} and other disorders of renal perfusion.^{3,20} Other clinical reports describe the utility of PDUS for imaging the atherosclerotic carotid artery,^{21,22} the prepubescent testis,²³ ischemic bowel,²⁴ and musculoskeletal inflammatory conditions.²⁵⁻²⁷

The PDUS image analysis technique described in this report involves operator-dependent selection of a single renal ultrasound section during the imaging procedure, followed by offline delineation of a region of interest corresponding to the renal cortex during image analysis. It is possible that this process may be affected by operator error. However, tests of intra- and interoperator reliability were not performed in this study. Such tests would be important before acceptance of the technique in a clinical setting. Three-dimensional reconstruction of a series of PDUS images, as recently described,²⁸ may reduce the variability associated with the method.

CONCLUSION

In conclusion, this study demonstrated that the intensity of power Doppler ultrasound images of the renal cortex correlate well with cortical tissue blood flow measured by fluorescent microspheres during vascular occlusion and reperfusion. This ultrasound technique is easily performed. Currently, the image analysis method is labor intensive, but could be automated. Future studies will be performed to define the utility of this approach in shock models. If vali-

dated in that setting, PDUS may join the armamentarium of ultrasound tools used at the bedside.²⁹

ACKNOWLEDGMENTS

The authors are grateful to George Vaughan, MD, for statistical support and for helpful comments on the manuscript, to Valerie Coppes, Stefan L. Alexander, Karl F. Korpil, and Michelle M. Estrella for technical support, to Kazufumi Ishiyama, Christina Hurst, Michele Smith, and Susan Navarrette (Toshiba America Medical Systems) for imaging support, and to Dr. Bernie Rubal for assistance with the microsphere technique.

REFERENCES

- Rubin JM, Bude RO, Carson PL, Bree RL, Adler RS. Power doppler US: a potentially useful alternative to mean frequency-based color doppler US. *Radiology*. 1994;190:853–856.
- Bude RO, Rubin JM, Adler RS. Power versus conventional color Doppler sonography: comparison in the depiction of normal intrarenal vasculature. *Radiology*. 1994;192:777–780.
- Helenon O, Correias JM, Chabriaes J, Boyer JC, Melki P, Moreau JF. Renal vascular Doppler imaging: clinical benefits of power mode. *Radiographics*. 1998;18:1441–1454, discussion 55–57.
- Glenny RW, Bernard S, Brinkley M. Validation of fluorescent-labeled microspheres for measurement of regional organ perfusion. *J Appl Physiol*. 1993;74:2585–2597.
- Manual for Using Fluorescent Microspheres to Measure Regional Organ Perfusion*. Seattle, WA: Fluorescent Microsphere Resource Center, Division of Pulmonary and Critical Care Medicine, University of Washington; 1995.
- Akiyama T, Ikegami M, Hara Y, et al. Hemodynamic study of renal transplant chronic rejection using power Doppler sonography. *Transplant Proc*. 1996;28:1458–1460.
- Cancio LC, Mazingo DW, Pruitt BA Jr. The technique of fluid resuscitation for patients with severe thermal injuries. *J Crit Illness*. 1997;12:183–190.
- Cioffi WG, Kim SH, Pruitt BA Jr. Cause of mortality in thermally injured patients. In: Lorenz S, Zellner P-R, eds. *Die Infektion beim Brandverletzten Proceedings of the Infektionsprophylaxe und Infektionsbekämpfung beim Brandverletzten*. International Symposium. Darmstadt, Germany: Steinkopff Verlag; 1993:7–11.
- Dries DJ, Waxman K. Adequate resuscitation of burn patients may not be measured by urine output and vital signs. *Crit Care Med*. 1991;19:327–329.
- Dymling SO, Persson HW, Hertz CH. Measurement of blood perfusion in tissue using Doppler ultrasound. *Ultrasound Med Biol*. 1991;19:433–444.
- Parro A, Philpot EF, Czuwala PJ, et al. Amplitude information from Doppler color flow mapping systems: a preliminary study of the power mode. *J Am Coll Cardiol*. 1991;18:997–1003.
- Turetschek K, Nasel C, Wunderbaldinger P, Diem K, Hittmair K, Mostbeck GH. Power Doppler versus color Doppler imaging in renal allograft evaluation. *J Ultrasound Med*. 1996;15:517–522.
- Martinoli C, Pretolesi F, Crespi G, et al. Power Doppler sonography: clinical applications. *Eur J Radiol*. 1998;27:S133–S140.
- Durick JE, Winter TC III, Schmiedl UP, Cyr DR, Starr FL III, Mack LA. Renal perfusion: pharmacologic changes depicted with power Doppler US in an animal model. *Radiology*. 1995;197:615–617.
- Chen P, Maklad N, Redwine M. Color and power Doppler imaging of the kidneys. *World J Urol*. 1998;16:41–45.
- Taylor GA, Barnewolt CE, Adler BH, Dunning PS. Renal cortical ischemia in rabbits revealed by contrast-enhanced power Doppler sonography. *AJR Am J Roentgenol*. 1998;170:417–422.
- Martinoli C, Crespi G, Bertolotto M, et al. Interlobular vasculature in renal transplants: a power Doppler US study with MR correlation. *Radiology*. 1996;200:111–117.
- Winters WD. Power Doppler sonographic evaluation of acute pyelonephritis in children. *J Ultrasound Med*. 1996;15:91–96, quiz 7–8.
- Dacher JN, Pfister C, Monroc M, Eurin D, LeDosseur P. Power Doppler sonographic pattern of acute pyelonephritis in children: comparison with CT. *AJR Am J Roentgenol*. 1996;166:1451–1455.
- Clautice-Engle T, Jeffrey RB Jr. Renal hypoperfusion: value of power Doppler imaging. *AJR Am J Roentgenol*. 1997;168:1227–1231.
- Steinke W, Meairs S, Ries S, Hennerici M. Sonographic assessment of carotid artery stenosis: comparison of power Doppler imaging and color Doppler flow imaging. *Stroke*. 1996;27:91–94.
- Griewing B, Morgenstern C, Driesner F, Kallwellis G, Walker ML, Kessler C. Cerebrovascular disease assessed by color-flow and power Doppler ultrasonography: comparison with digital subtraction angiography in internal carotid artery stenosis. *Stroke*. 1996;27:95–100.
- Luker GD, Siegel MJ. Scrotal US in pediatric patients: comparison of power and standard color Doppler US. *Radiology*. 1996;198:381–385.
- Clautice-Engle T, Jeffrey RB Jr, Li KC, Barth RA. Power Doppler imaging of focal lesions of the gastrointestinal tract: comparison with conventional color Doppler imaging. *J Ultrasound Med*. 1996;15:63–66.
- Breidahl WH, Newman JS, Taljanovic MS, Adler RS. Power Doppler sonography in the assessment of musculoskeletal fluid collections. *AJR Am J Roentgenol*. 1996;166:1443–1446.
- Newman JS, Adler RS, Bude RO, Rubin JM. Detection of soft-tissue hyperemia: value of power doppler sonography. *AJR Am J Roentgenol*. 1994;163:385–389.
- Newman JS, Laing TJ, McCarthy CJ, Adler RS. Power Doppler sonography of synovitis: assessment of therapeutic response: preliminary observations. *Radiology*. 1996;198:582–584.
- Overhoff HM, Mutze S, Teistler M, Ehrhardt J. *Quantification of Renal Partial Volumes From 3D Reconstruction of Power Doppler Ultrasound Scans*. The Institute for Medical Informatics, Technische Universität Carolo-Wilhelmina zu Braunschweig, Braunschweig, Germany. Retrieved March 22, 2003 at <http://www.umi.cs.tu-bs.de/full/archive/niere/>
- Rozycki GS. Surgeon-performed ultrasound: its use in clinical practice. *Ann Surg*. 1998;228:16–28.