

Shortening and Angulation for Soft-Tissue Reconstruction of Extremity Wounds in a Combat Support Hospital

MAJ(P) Joseph R. Hsu, MC USA*; CPT Michael J. Beltran, MC USA†; Skeletal Trauma Research Consortium (STReC)

ABSTRACT Background: Bone and soft-tissue loss are common extremity injuries sustained in current military conflicts. Selected host national patients had their definitive orthopedic care performed at our combat support hospital. Soft-tissue reconstruction can be a challenging task in this environment. There are several situations in which free or rotational flap coverage is not possible, including the presence of a single vessel limb, local muscle damage, and/or nonavailability of an experienced flap surgeon. The technique of shortening and angulation for extremity soft-tissue reconstruction is described using tools available in a theater of operations. Methods: We treated 6 limbs in 5 patients with the technique of shortening and/or angulation to obtain soft-tissue coverage for extremity war wounds at our combat support hospital. Bony stabilization was accomplished using the standard Hoffman II external fixator (Stryker Orthopedics, Mahwah, NJ). The extremities treated included: 2 humerus fractures, 3 tibia fractures, and 1 ankle fracture. Two of the patients required vascular reconstruction. Patients were followed for as long as possible given individual circumstances. Results: One patient in the series died of multiple organ system failure because of intra-abdominal injuries. Average follow-up on the remaining patients was 7.03 weeks (1 to 14 weeks). In the patient with 1-week follow-up, the skin graft had 100% take. All other wounds were healed at the latest follow-up without signs of infection. Conclusion: Shortening and/or angulation of extremities with bone and soft-tissue loss is an effective means of obtaining soft-tissue coverage in a theater of operations.

INTRODUCTION

Extremity injuries sustained during military conflicts are often associated with significant bone and soft-tissue loss.¹⁻⁵ Management of these soft-tissue defects can be a challenging task requiring specialized training and experience with free and rotational tissue transfer.^{3,6-12} There are several situations in which free or rotational flap coverage is not possible, including the presence of a single vessel limb, local muscular damage, and/or nonavailability of an experienced flap surgeon. Other techniques of acute angulation with shortening have been described to allow closure of these soft-tissue defects associated with fractures.¹³⁻¹⁹

In the current conflict in Iraq, wounded American and coalition forces have their initial stabilization and wound management performed at a combat support hospital or forward surgical team in theater. Thereafter, they can be rapidly evacuated to treatment facilities in their respective countries for definitive reconstruction of these bone and soft-tissue injuries. Host nation wounded soldiers and civilians do not have the benefit of evacuating to modern, Western medical centers. They often depend upon the American medical assets in theater for care beyond initial stabilization and acute wound management, because their own health care system has limited resources. These host nation wounded individuals pro-

vide a reconstructive challenge for the deployed orthopedic surgeon.

MATERIALS AND METHODS

During a 6-month period from April to September of 2006, several selected host national soldiers and civilians received their intermediate and sometimes definitive orthopedic care at our combat support hospital in Baghdad, Iraq. Patients were selected on the basis of complexity of injury, potential for reconstruction, and availability of resources at the combat support hospital. The primary limiting resource was bed space. Within this group of patients we treated 6 limbs in 5 patients with the technique of shortening and/or angulation to obtain soft-tissue coverage for extremity war wounds.

Our orthopedic team consisted of 3 orthopedic surgeons. None of us have formal training in flap techniques. One surgeon (J.R.H.) has formal training and experience with the Ilizarov method. The Ilizarov method is a treatment modality utilizing gradual compression and distraction with an external fixator to grow bone and soft tissue. The techniques were developed in Kurgan, Russia by Professor Gavril A. Ilizarov to treat the sequelae of injuries sustained during the Second World War.

Three of the 5 patients were initially treated at outside facilities. All 3 patients had emergent debridement at these outside facilities. Two of the 3 were stabilized with external fixators at American treatment facilities. One of these patients was initially treated at an Iraqi hospital without bony stabilization. The final 2 patients presented acutely to our combat support hospital.

The extremities treated included: 2 humerus fractures, 3 tibia fractures, and 1 ankle fracture. Two of the patients required

*United States Army Institute of Surgical Research, 3851 Roger Brooke Drive, Fort Sam Houston, TX 78234.

†Brooke Army Medical Center, Fort Sam Houston, TX 78234.

Presented as a podium presentation at the 48th Annual Meeting of the Society of Military Orthopaedic Surgeons, December 11-16, 2006, Honolulu, Hawaii.

This manuscript was received for review in November 2008. The revised manuscript was accepted for publication in May 2009.

Report Documentation Page

*Form Approved
OMB No. 0704-0188*

Public reporting burden for the collection of information is estimated to average 1 hour per response, including the time for reviewing instructions, searching existing data sources, gathering and maintaining the data needed, and completing and reviewing the collection of information. Send comments regarding this burden estimate or any other aspect of this collection of information, including suggestions for reducing this burden, to Washington Headquarters Services, Directorate for Information Operations and Reports, 1215 Jefferson Davis Highway, Suite 1204, Arlington VA 22202-4302. Respondents should be aware that notwithstanding any other provision of law, no person shall be subject to a penalty for failing to comply with a collection of information if it does not display a currently valid OMB control number.

1. REPORT DATE 01 AUG 2009	2. REPORT TYPE N/A	3. DATES COVERED -			
4. TITLE AND SUBTITLE Shortening and angulation for soft-tissue reconstruction of extremity wounds in a combat support hospital		5a. CONTRACT NUMBER			
		5b. GRANT NUMBER			
		5c. PROGRAM ELEMENT NUMBER			
6. AUTHOR(S) Hsu J. R., Beltran M. J.,		5d. PROJECT NUMBER			
		5e. TASK NUMBER			
		5f. WORK UNIT NUMBER			
7. PERFORMING ORGANIZATION NAME(S) AND ADDRESS(ES) United States Army Institute of Surgical Research, JBSA Fort Sam Houston, TX 78234		8. PERFORMING ORGANIZATION REPORT NUMBER			
9. SPONSORING/MONITORING AGENCY NAME(S) AND ADDRESS(ES)		10. SPONSOR/MONITOR'S ACRONYM(S)			
		11. SPONSOR/MONITOR'S REPORT NUMBER(S)			
12. DISTRIBUTION/AVAILABILITY STATEMENT Approved for public release, distribution unlimited					
13. SUPPLEMENTARY NOTES					
14. ABSTRACT					
15. SUBJECT TERMS					
16. SECURITY CLASSIFICATION OF:			17. LIMITATION OF ABSTRACT UU	18. NUMBER OF PAGES 6	19a. NAME OF RESPONSIBLE PERSON
a. REPORT unclassified	b. ABSTRACT unclassified	c. THIS PAGE unclassified			

vascular reconstruction. All these fractures were the result of high-energy penetrating trauma either from improvised explosive devices (IED) or military rifles. Four of the injuries were classified according to the system of Gustilo and Anderson as type III-B fractures, meaning they require soft-tissue coverage for definitive closure (Table I). The other 2 were type III-C fractures, meaning they had an associated vascular injury requiring repair or construction.

Surgical technique: Careful vascular examination was documented before surgical intervention. All patients were treated with aggressive surgical debridement of devitalized skin, muscle, and bone. All reasonably accessible foreign bodies were removed. Irrigation was performed with a minimum of 6 liters of normal saline via low-power pulse lavage (Surgilav, Zimmer Inc., Warsaw, IN) with no irrigant additives.

All patients were initially stabilized with the standard Hoffman II external fixator (Stryker Orthopedics).

The 2 patients with ischemic limbs were initially stabilized with their limbs at the approximate normal length before their vascular reconstructions. Their shortening with or without angulation was performed at scheduled subsequent operations.

After placement or revision of the external fixator, the limbs were shortened with or without angulation to allow redundancy in the soft tissue (Fig. 1). Four of the injuries were shortened without angulation. The other 2 were angulated in addition to shortening. Angulation was performed in the larger asymmetrical defects. One patient required partial fibulectomy to perform the shortening and angulation. The resultant soft-tissue redundancy allowed for local skin and muscle recruitment to cover the bone (Fig. 2). Viable skin flaps and edges were sewn together using simple nylon sutures. The remaining soft-tissue defects after partial skin closure were covered with local muscle. The epimysium of these muscles were sewn together over the bone using small, monofilament, resorbable sutures. In all cases, the bone was completely covered by either skin or muscle. None of the wounds had enough skin for complete primary closure. Wound vacs were placed over the muscle. Repeat vascular examination was performed with Doppler confirmation at the conclusion of the procedure to ensure there was no vascular kinking.

All patients returned to the operating room within 48 to 72 hours for completion of the soft-tissue coverage with a split-thickness skin graft. All local muscle and skin were viable at the time of skin grafting.

In this series, none of the patients underwent restoration of their normal limb lengths because of limited technical resources and uncertain follow-up. Angular deformities were gradually corrected.

RESULTS

The patient initially treated at an Iraqi hospital died of multiple organ system failure because of intra-abdominal injuries. Average follow-up on the remaining patients was 7.03 weeks (1 to 14 weeks). In the patient with 1-week follow-up, the skin graft had 100% take when the patient returned to his home in the western part of the country. Two of the patients had small areas (5%) of the wound without take of the skin graft. These were treated with simple wet-to-dry dressing changes with uneventful healing. All other wounds were healed at the latest follow-up without signs of infection.

DISCUSSION

Reconstruction of soft-tissue defects associated with high-energy trauma is a challenging task under the best of circumstances with flap complications and/or failure rates exceeding 20% in some studies.^{9,20,21} Soft-tissue reconstruction is even more challenging in a forward deployed environment with limited resources and varying surgeon experience.

According to a medical liaison in Baghdad, there are more than 30,000 amputees in Iraq as a result of the recent conflicts. Only 300 (1%) of these patients have been fitted with prostheses because of limited resources.²² For this reason, challenging attempts at limb salvage in these host nation patients may be warranted.

Although rotational and free tissue transfer techniques account for a large number of the soft-tissue reconstructions performed for high-energy traumatic wounds,^{3,6-11,23,24} there is growing attention being paid to Ilizarov method external fixator techniques of temporary shortening with or without angulation to reconstruct soft tissue. This soft tissue can be

TABLE I. Classification of Open Fractures

Type	Wound	Level of Contamination	Bone Injury	Soft-Tissue Injury
I	<1cm long	Clean	Minimal comminution	Minimal
II	>1cm long	Moderate	Moderate comminution	Moderate
III-A	>10 cm long	High	Usually comminuted, soft-tissue coverage of bone possible	Severe
III-B	>10 cm long	High	Bone coverage poor; variable, may be moderate to severe comminution	Very severe loss of coverage, usually requires soft-tissue reconstructive surgery
III-C	>10 cm long	High	Bone coverage poor; variable, may be moderate to severe comminution	Severe loss of coverage plus vascular injury requiring repair

Adapted from refs. 46 and 47.

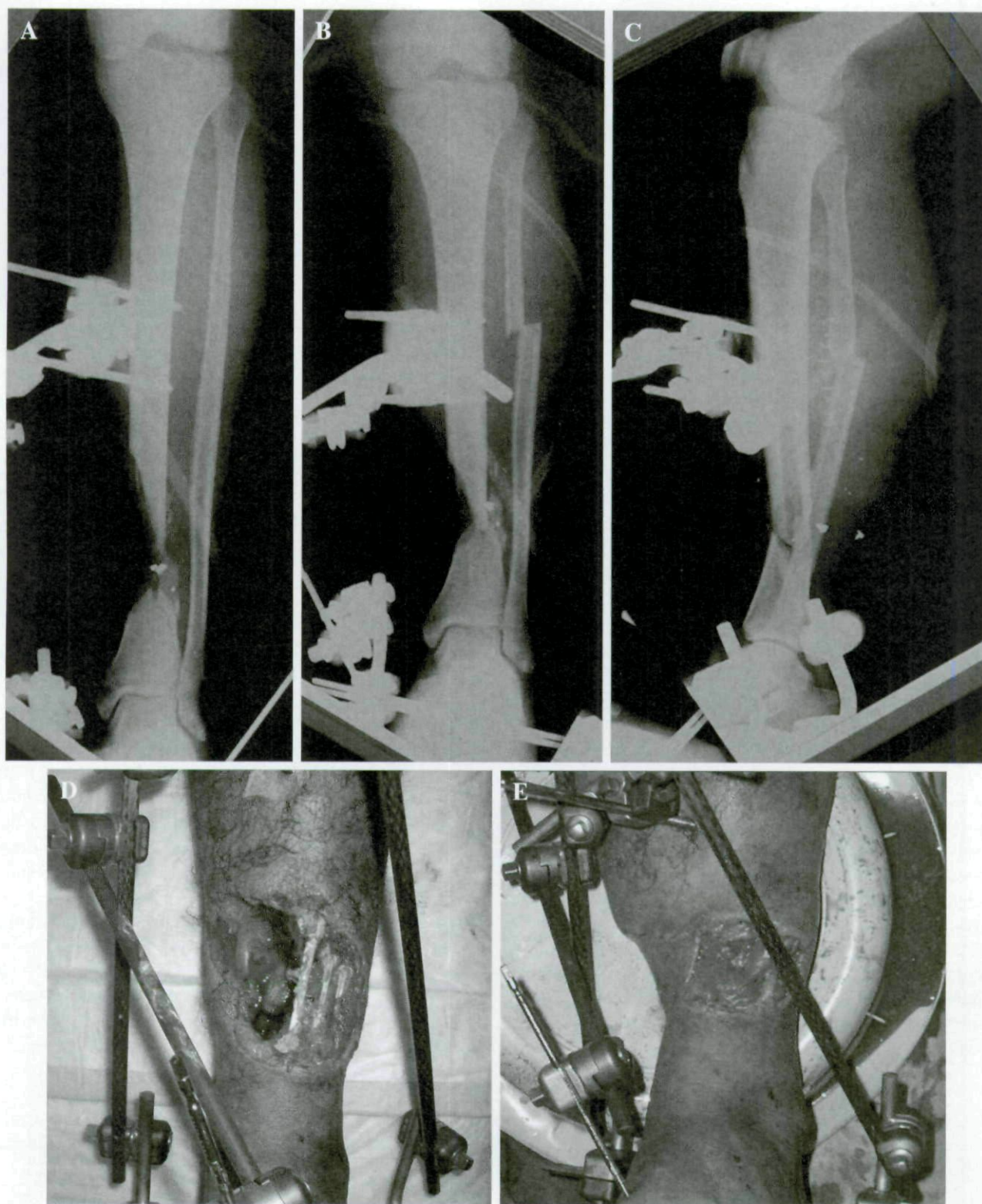


FIGURE 1. (a–e) Radiographs and photographs of open distal tibia fx before and after acute shortening and angulation. Wound was successfully covered with split thickness skin graft alone.

subsequently lengthened as well under the tension-stress effect with expected lengthening of skin, muscles, nerves, and even blood vessels.^{25–36} In fact, this relengthened tissue is durable enough to tolerate a secondary bone-grafting procedure.¹⁹

Restoration of limb length can be challenging and requires specialized training and devices.^{37–45} This may not be possible or appropriate in an austere environment. The benefit of this technique in this environment is that other final reconstruction




FIGURE 2. (a–d) Photographs of an open Grade III-B distal tibia fx with articular bone loss. Wound was treated with acute shortening and ankle fusion followed by split-thickness skin grafting. Lower right image demonstrates healed soft-tissue envelope 12 weeks postoperatively.

possibilities can be considered once the patient has a stable soft-tissue envelope. Later bone grafting with or without conversion to internal fixation may be employed to achieve bony union and restore limb function. Although the final result of a shortened limb, or even some residual angulation, may be unsettling to the patient and physician, the harsh reality is that the host nation patient may never receive a prosthesis if an amputation is performed. Long-term disability is likely to remain a problem for these patients until future definitive reconstructive procedures can be performed. In the setting of an amputation without the aid of a prosthesis, little improvement in functional status seems possible over attempts at limb salvage.

Limitations of this evaluation include small sample size and short follow-up. Patients were followed for as long as possible given their individual circumstances.

CONCLUSION

Shortening with or without angulation of extremities with bone and soft-tissue loss is a safe and effective means of obtaining soft-tissue coverage in a theater of operations.

REFERENCES

1. Atesalp AS, et al: Treatment of tibial bone defects with the Ilizarov circular external fixator in high-velocity gunshot wounds. *Int Orthop* 1998; 22(6): 343–7.
2. Carballedo J, et al: Type III-B open tibial fractures in Mozambique. A prospective study of 50 cases. *Int Orthop* 1996; 20(5): 300–4.
3. Duman H, et al: Lower extremity salvage using a free flap associated with the Ilizarov method in patients with massive combat injuries. *Ann Plast Surg* 2001; 46(2): 108–12.
4. Jorgenson DS, Antoine GS: Advances in the treatment of lower extremity wounds applied to military casualties. *Ann Plast Surg* 1995; 34(3): 298–301 discussion 301–3.
5. Reis ND, et al: A philosophy of limb salvage in war: use of the fixateur externe. *Milit Med* 1991; 156(10): 505–20.
6. Agarwal S, et al: Management of soft-tissue problems in leg trauma in conjunction with application of the Ilizarov fixator assembly. *Plast Reconstr Surg* 2001; 107(7): 1732–8.
7. Feibel RJ, et al: Soft-tissue reconstruction in orthopedic surgery. Secondary procedures. *Orthop Clin North Am* 1993; 24(3): 537–48.
8. Fiebel RJ, et al: Simultaneous free-tissue transfer and Ilizarov distraction osteosynthesis in lower extremity salvage: case report and review of the literature. *J Trauma* 1994; 37(2): 322–7.
9. Gonzalez MH, et al: Free tissue coverage of chronic traumatic wounds of the lower leg. *Plast Reconstr Surg* 2002; 109(2): 592–600.
10. Lowenberg DW, et al: Combined muscle flap and Ilizarov reconstruction for bone and soft tissue defects. *Clin Orthop Relat Res* 1996; (332):37–51.
11. Musharafieh RS, et al: Microvascular soft-tissue coverage and distraction osteosynthesis for lower-extremity salvage. *Microsurgery* 1996; 17(12): 666–73.
12. Naique SB, Pearse M, Nanchahal J: Management of severe open tibial fractures: the need for combined orthopaedic and plastic surgical treatment in specialist centres. *J Bone Joint Surg Br* 2006; 88(3): 351–7.
13. Bundgaard KG, Christensen KS: Tibial bone loss and soft-tissue defect treated simultaneously with Ilizarov-technique—a case report. *Acta Orthop Scand* 2000; 71(5): 534–6.

14. D'Hooghe P, et al: Management of a large post-traumatic skin and bone defect using an Ilizarov frame. *Acta Orthop Belg* 2006; 72(2): 214-8.
15. Mahaluxmivala J, et al: Ilizarov external fixator: acute shortening and lengthening versus bone transport in the management of tibial non-unions. *Injury* 2005; 36(5): 626-8.
16. Rahal SC, Volpi RS, Vulcano LC: Treatment of segmental tibial defects using acute bone shortening followed by gradual lengthening with circular external fixator. *J Vet Med A Physiol Pathol Clin Med* 2005; 52(4): 180-5.
17. Rahal SC, et al: Acute shortening and subsequent lengthening of the radius and ulna for the treatment of an infected nonunion in a dog. *Can Vet J* 2001; 42(9): 724-6.
18. Sen C, et al: Bifocal compression-distraction in the acute treatment of grade III open tibia fractures with bone and soft-tissue loss: a report of 24 cases. *J Orthop Trauma* 2004; 18(3): 150-7.
19. Hsu JR, Ochoa LM, Graves RM: Presentation: Taylor Spatial Frame for Soft Tissue Defects: Technique of Angulation with Shortening, in *Limb Lengthening and Reconstruction Society Annual Meeting 2006*, William Beaumont Army Medical Center, Texas Tech University Health Sciences Center: San Diego, CA.
20. Pollak AN, McCarthy ML, Burgess AR: Short-term wound complications after application of flaps for coverage of traumatic soft-tissue defects about the tibia. The Lower Extremity Assessment Project (LEAP) Study Group. *J Bone Joint Surg Am* 2000; 82-A(12): 1681-91.
21. Redett RJ, et al: Limb salvage of lower-extremity wounds using free gracilis muscle reconstruction. *Plast Reconstr Surg* 2000; 106(7): 1507-13.
22. Jawad S: Prosthetic burden in Iraq. Presented at Grand Rounds, Ibn Sina Hospital. Baghdad, Iraq; 2006.
23. Levin LS: New developments in flap techniques. *J Am Acad Orthop Surg* 2006; 14(10): S90-3.
24. Nanchahal J, Pearse MF: Management of soft-tissue problems in leg trauma in conjunction with application of the Ilizarov fixator assembly. *Plast Reconstr Surg* 2003; 111(3): 1359 author reply 1359-1360.
25. Ilizarov GA: The tension-stress effect on the genesis and growth of tissues. Part I. The influence of stability of fixation and soft-tissue preservation. *Clin Orthop Relat Res* 1989; 238: 249-81.
26. Ilizarov GA: The tension-stress effect on the genesis and growth of tissues: Part II. The influence of the rate and frequency of distraction. *Clin Orthop Relat Res* 1989; 239: 263-85.
27. Ilizarov GA, et al: Reconstruction of large defects of blood vessels on extremities by means of a gradual distraction. (An experimental study). *Acta Chir Plast* 1980; 22(3): 156-65.
28. Kocalkowski A, Marsh DR, Shackley DC: Closure of the skin defect overlying infected non-union by skin traction. *Br J Plast Surg* 1998; 51(4): 307-10.
29. Lenoble E, Lewertowski JM, Goutallier D: Reconstruction of compound tibial and soft tissue loss using a traction histogenesis technique. *J Trauma* 1995; 39(2): 356-60.
30. Lerner A, et al: Using the Ilizarov external fixation device for skin expansion. *Ann Plast Surg* 2000; 45(5): 535-7.
31. Low CK, Looi KP: Ilizarov's technique used to expand skin from a groin flap. *J Hand Surg [Br]* 1999; 24(3): 361-2.
32. Martini Z, Castaman E: Tissue regeneration in the reconstruction of lost bone and soft tissue in the lower limbs: a preliminary report. *Br J Plast Surg* 1987; 40(2): 142-8.
33. Neudeck F, Klaes W: Continuous skin expansion for covering soft tissue defects of the foot sole. *Unfallchirurg* 1995; 98(1): 40-4.
34. Shevtsov VI, et al: Changes in blood flow during tibial thickening by the Ilizarov method. *Bull Exp Biol Med* 2002; 134(6): 525-7.
35. Shevtsov VI, et al: Effect of Ilizarov tibial lengthening on limb blood flow. *Russ Fiziol Zh Im I M Sechenova* 2002; 88(4): 476-84.
36. Topliss C, Jackson M, Atkins RM: Dermal traction on the Ilizarov frame. *Injury* 2005; 36(1): 194-8.
37. Barker KL, Simpson AH, Lamb SE: Loss of knee range of motion in leg lengthening. *J Orthop Sports Phys Ther* 2001; 31(5): 238-44 discussion 245-246.
38. Dahl MT, Gulli B, Berg T: Complications of limb lengthening. A learning curve. *Clin Orthop Relat Res* 1994; 301: 10-8.
39. Galardi G, et al: Peripheral nerve damage during limb lengthening. Neurophysiology in five cases of bilateral tibial lengthening. *J Bone Joint Surg Br* 1990; 72(1): 121-4.
40. Garcia-Cimbrello E, et al: Ilizarov technique. Results and difficulties. *Clin Orthop Relat Res* 1992; 283: 116-23.
41. Herzog R, Hefti F: [Problems and complications of leg lengthening with the Wagner apparatus] *Orthopade* 1992; 21(3): 221-9.
42. Maffulli N: Callotaxis lengthening: a review of some technical aspects. *Bull Hosp Jt Dis* 1996; 54(4): 249-54.
43. Ozaki T, et al: High complication rate of reconstruction using Ilizarov bone transport method in patients with bone sarcomas. *Arch Orthop Trauma Surg* 1998; 118(3): 136-9.
44. Paley D: Problems, obstacles, and complications of limb lengthening by the Ilizarov technique. *Clin Orthop Relat Res* 1990; 250: 81-104.
45. Velazquez RJ, et al: Complications of use of the Ilizarov technique in the correction of limb deformities in children. *J Bone Joint Surg Am* 1993; 75(8): 1148-56.
46. Gustilo RB, Anderson JT: Prevention of infection in the treatment of one thousand and twenty five open fractures of long bones: retrospective and prospective analysis. *J Bone Joint Surg Am* 1976; 58: 453-8.
47. Gustilo RA, et al: Problems in the management of type III (severe) open fractures: a new classification of type III open fractures. *J Trauma* 1984; 24(8): 742-6.

Copyright of *Military Medicine* is the property of Association of Military Surgeons of the United States and its content may not be copied or emailed to multiple sites or posted to a listserv without the copyright holder's express written permission. However, users may print, download, or email articles for individual use.