

UNCLASSIFIED

AD NUMBER
ADB268113
NEW LIMITATION CHANGE
TO Approved for public release, distribution unlimited
FROM Distribution authorized to U.S. Gov't. agencies only; Proprietary Info.; Oct 2000. Other requests shall be referred to U.S. Army Medical Research and Materiel Command, 504 Scott St., Ft. Detrick, MD 21702-5012.
AUTHORITY
USAMRMC ltr, 5 Mar 2002

THIS PAGE IS UNCLASSIFIED

AD _____

Award Number: DAMD17-98-1-8637

TITLE: Novel Fatty Acid Lipoxygenases in the Development of Human and Murine Prostate Cancer

PRINCIPAL INVESTIGATOR: Scott Shappell, M.D., Ph.D.

CONTRACTING ORGANIZATION: Vanderbilt University
Nashville, Tennessee 37232-2561

REPORT DATE: October 2000

TYPE OF REPORT: Final

PREPARED FOR: U.S. Army Medical Research and Materiel
Command, Fort Detrick, Maryland 21702-5012

DISTRIBUTION STATEMENT: Distribution authorized to U.S.
Government agencies only (proprietary information, Oct 00).
Other requests for this document shall be referred to U.S.
Army Medical Research and Materiel Command, 504 Scott Street,
Fort Detrick, Maryland 21702-5012.

The views, opinions and/or findings contained in this report
are those of the author(s) and should not be construed as an
official Department of the Army position, policy or decision
unless so designated by other documentation.

20010716 064

NOTICE

USING GOVERNMENT DRAWINGS, SPECIFICATIONS, OR OTHER DATA INCLUDED IN THIS DOCUMENT FOR ANY PURPOSE OTHER THAN GOVERNMENT PROCUREMENT DOES NOT IN ANY WAY OBLIGATE THE U.S. GOVERNMENT. THE FACT THAT THE GOVERNMENT FORMULATED OR SUPPLIED THE DRAWINGS, SPECIFICATIONS, OR OTHER DATA DOES NOT LICENSE THE HOLDER OR ANY OTHER PERSON OR CORPORATION; OR CONVEY ANY RIGHTS OR PERMISSION TO MANUFACTURE, USE, OR SELL ANY PATENTED INVENTION THAT MAY RELATE TO THEM.

LIMITED RIGHTS LEGEND

Award Number: DAMD17-98-1-8637
Organization: Vanderbilt University
Location of Limited Rights Data (Pages):

Those portions of the technical data contained in this report marked as limited rights data shall not, without the written permission of the above contractor, be (a) released or disclosed outside the government, (b) used by the Government for manufacture or, in the case of computer software documentation, for preparing the same or similar computer software, or (c) used by a party other than the Government, except that the Government may release or disclose technical data to persons outside the Government, or permit the use of technical data by such persons, if (i) such release, disclosure, or use is necessary for emergency repair or overhaul or (ii) is a release or disclosure of technical data (other than detailed manufacturing or process data) to, or use of such data by, a foreign government that is in the interest of the Government and is required for evaluational or informational purposes, provided in either case that such release, disclosure or use is made subject to a prohibition that the person to whom the data is released or disclosed may not further use, release or disclose such data, and the contractor or subcontractor or subcontractor asserting the restriction is notified of such release, disclosure or use. This legend, together with the indications of the portions of this data which are subject to such limitations, shall be included on any reproduction hereof which includes any part of the portions subject to such limitations.

THIS TECHNICAL REPORT HAS BEEN REVIEWED AND IS APPROVED FOR PUBLICATION.

Amelia Ann
07/20/97

REPORT DOCUMENTATION PAGE

Form Approved
OMB No. 074-0188

Public reporting burden for this collection of information is estimated to average 1 hour per response, including the time for reviewing instructions, searching existing data sources, gathering and maintaining the data needed, and completing and reviewing this collection of information. Send comments regarding this burden estimate or any other aspect of this collection of information, including suggestions for reducing this burden to Washington Headquarters Services, Directorate for Information Operations and Reports, 1215 Jefferson Davis Highway, Suite 1204, Arlington, VA 22202-4302, and to the Office of Management and Budget, Paperwork Reduction Project (0704-0188), Washington, DC 20503

1. AGENCY USE ONLY (Leave blank)		2. REPORT DATE October 2000	3. REPORT TYPE AND DATES COVERED Final (1 Oct 98 - 30 Sep 00)	
4. TITLE AND SUBTITLE Novel Fatty Acid Lipoxygenases in the Development of Human and Murine Prostate Cancer			5. FUNDING NUMBERS DAMD17-98-1-8637	
6. AUTHOR(S) Scott Shappell, M.D., Ph.D.				
7. PERFORMING ORGANIZATION NAME(S) AND ADDRESS(ES) Vanderbilt University Nashville, Tennessee 37232-2561 E-MAIL: scott.shappell@mcmail.vanderbilt.edu			8. PERFORMING ORGANIZATION REPORT NUMBER	
9. SPONSORING / MONITORING AGENCY NAME(S) AND ADDRESS(ES) U.S. Army Medical Research and Materiel Command Fort Detrick, Maryland 21702-5012			10. SPONSORING / MONITORING AGENCY REPORT NUMBER	
11. SUPPLEMENTARY NOTES This report contains colored photos				
12a. DISTRIBUTION STATEMENT: Distribution authorized to U.S. Government agencies only (proprietary information, Oct 00). Other requests for this document shall be referred to U.S. Army Medical Research and Materiel Command, 504 Scott Street, Fort Detrick, Maryland 21702-5012.				12b. DISTRIBUTION CODE
13. ABSTRACT (<i>Maximum 200 Words</i>) Identification of novel genes selectively expressed in the prostate and altered in prostate carcinoma may lead to novel therapies or prognostic markers in prostate cancer (Pca). We have utilized a combination of immunohistochemistry, enzyme activity assays, and mRNA analyses to demonstrate that the novel lipoxygenase 15-lipoxygenase-2 (15-LOX-2) is expressed in differentiated secretory cells of benign prostate and reduced in the majority of Pcas. We have demonstrated that the nuclear transcription factor peroxisome proliferator activated receptor gamma (PPAR γ) is present in benign and malignant prostate and Pca cell lines and that the enzymatic product of 15-LOX-2, 15-hydroxyeicosatetraenoic acid (15-HETE), activates PPAR γ and inhibits proliferation of Pca cell lines. Transgenic mouse models of Pca created with the long probasin promoter (LPB) and the SV40 large T-antigen (Tag) progress from precursor lesions to invasive and metastatic carcinoma. Although we have demonstrated that the murine homologue of 15-LOX-2, an 8-LOX, is not expressed in the wild type or LPB-Tag prostate, we have observed other alterations in arachidonic acid metabolizing enzymes that have been reported in human Pca. These mouse models may provide useful information regarding the role of these pathways in Pca development and progression. Our data in human Pca indicates that 15-LOX-2 derived 15-HETE may constitute an endogenous ligand for PPAR γ in human prostate. That 15-LOX-2 is reduced in Pca supports utilization of PPAR γ -agonists in the treatment of Pca.				
14. SUBJECT TERMS Prostate Cancer			15. NUMBER OF PAGES 159	
			16. PRICE CODE	
17. SECURITY CLASSIFICATION OF REPORT Unclassified	18. SECURITY CLASSIFICATION OF THIS PAGE Unclassified	19. SECURITY CLASSIFICATION OF ABSTRACT Unclassified	20. LIMITATION OF ABSTRACT Unlimited	

NSN 7540-01-280-5500

Standard Form 298 (Rev. 2-89)
Prescribed by ANSI Std. Z39-18
298-102

Table of Contents

Cover.....	
SF 298.....	2
Introduction.....	4
Body.....	4
Key Research Accomplishments.....	13
Reportable Outcomes.....	15
Conclusions.....	19
References.....	21
Appendices.....	24

Appendix 1: Shappell, S.B., et al. "15-lipoxygenase-2 (15-LOX-2) is expressed in benign prostatic epithelium and reduced in prostate adenocarcinoma"; Am J Pathol. 155:235-245, 1999.

Appendix 2: Jack, G.S., et al. "Reduced 15-lipoxygenase-2 immunostaining in prostate adenocarcinoma: correlation with grade and expression in high-grade prostatic intraepithelial neoplasia"; Hum Pathol 31:1146-1154, 2000.

Appendix 3: Shappell, S.B., et al. "Alterations in lipoxygenase and cyclooxygenase-2 catalytic activity and mRNA expression in prostate carcinoma"; in preparation.

Appendix 4: Shappell, S.B., et al. "15-hydroxyeicosatetraenoic acid (15-HETE) activates peroxisome proliferator activated receptor gamma (PPAR γ) and inhibits proliferation in PC3 prostate carcinoma cells"; Cancer Res, revised manuscript, submitted.

Introduction

Genes and signaling pathways expressed specifically in prostate are likely crucial in normal prostatic function, and understanding alterations in such control mechanisms may provide fundamental insights into the development and progression of prostate adenocarcinoma (Pca). Recent studies have suggested a possible important role for alterations in arachidonic acid (AA) metabolizing enzymes in Pca. In this funding period, we have utilized immunohistochemistry, enzyme activity assays, and mRNA quantitation in whole mount paraffin sections and snap frozen tissues from radical prostatectomy specimens to investigate the expression of a novel human lipoxygenase, 15-lipoxygenase-2 (15-LOX-2), in the prostate, its possible alteration in Pca, and its mechanisms of action. We have demonstrated that 15-LOX-2 is expressed in the differentiated secretory cells of benign prostate and that 15-LOX-2 expression is reduced in Pca. Enzyme activity assays also allow for investigation of possible alterations in other AA metabolizing enzymes, such as 5-LOX and 12-LOX, which have been suggested to have a role in Pca based on studies by others in cell lines. Increased 12-LOX mRNA, 15-LOX-1 protein, and COX-2 mRNA and protein have recently been reported in high grade human prostate cancers. In incubations of benign and tumor tissues, we have observed that reduced 15-HETE is the most characteristic alteration in AA metabolism in Pca, and have not observed increased 5-LOX or 12-LOX activity in Pca. In prostate cancer cell lines, 15-HETE, the product of 15-LOX-2, induced transcriptional activation by the nuclear receptor peroxisome proliferator activated receptor gamma (PPAR γ). 15-HETE also inhibited the proliferation of PC3 Pca cells. The results indicate that 15-HETE may represent an endogenous ligand for PPAR γ in human prostate and that reduced 15-LOX-2 may contribute to Pca development by reduced expression of PPAR γ -regulated genes. Transgenic mice represent a potentially elegant model for studying alterations in the LOX/PPAR pathways during Pca progression and its therapeutic significance. We have used a combination of immunohistochemistry, mRNA analysis, and enzyme activity assays to investigate AA metabolism in transgenic mouse lines generated with the long probasin promoter (LPB) and the SV40 large T antigen (Tag).

Progress Report Body

I. To define the role of 15-LOX2 in the evolution of human prostate cancer by examining the expression of 15-LOX2 and the production of 15S-HETE and other AA metabolites in normal, premalignant, and malignant prostate tissue.

A) Using frozen tissue from prostatectomy specimens from the Vanderbilt Urology/Pathology and the Baylor College of Medicine Pathology archives, perform 15-LOX2 enzyme assays (HPLC analysis of AA metabolites) on paired normal and malignant tissues from a total of 30 patients, 10 each with well, moderately, and poorly differentiated carcinomas. (months 1-12).

We have successfully developed assays for determining catalytic activity of 15-LOX-2 and other lipoxygenase (LOX) and cyclooxygenase (COX) enzymes in benign

and malignant prostate tissues. ^{14}C [AA] is added to homogenates of prostate tissues, which have been rigorously histologically confirmed as to benign, malignant, or mixed. Extracts are analyzed by reverse phase HPLC with in line radiodetection and addition of non-radiolabelled standards to monitor retention times (1) (attached Appendix 1). We initially utilized fresh (not snap) frozen tissues that had been procured from radical prostatectomy (RP) specimens by the Department of Pathology and the Human Tissue Acquisition and Shared Resource Core of the Vanderbilt Ingram Cancer Center, Vanderbilt University Medical Center. These analyses originally included 8 benign prostate samples and four pairs of pure benign and pure cancer tissue from the same patient, three of which were included in the first manuscript. Benign prostate uniformly synthesizes 15S-HETE from exogenous AA, and 15-HETE is the major metabolite formed under our incubation conditions. The identity of this product was established by retention times on reverse phase HPLC, its characteristic UV spectrum, and its retention time on straight phase HPLC in a subset of samples. In contrast to benign prostate, 15-HETE production was substantially reduced or absent in incubations of prostate carcinoma (Pca) tissue (1) (attached Appendix 1).

We have subsequently extended these studies and broadened the scope to more specifically address formation of other lipoxygenase (LOX) and cyclooxygenase (COX) products utilizing snap frozen prostate tissues obtained in collaboration with Baylor College of Medicine, Houston, TX as outlined in the original grant proposal. These tissues are obtained in the operating room by 6 mm punch biopsies from multiple sites within the prostate, yielding cores approximately 1 to 1.5 cm in length (2). These tissues are processed by us for RNA and enzyme assays as shown in Figure 1 of the manuscript submitted as appendix number 3 (3), with careful correlation to the specific histology of the tissue actually processed for these analyses. Histologic examination includes percent benign, percent malignant, grade of tumor, percent glands and stroma, and any unique histologic features (e.g., atrophy of benign glands). In completed studies (abstract presented; manuscript attached as appendix 3), we processed 60 snap frozen potential pairs of benign and malignant tissue from the same RP specimens. Histologic assessment of portions submitted for RNA and AA incubations has yielded a substantial number of samples adequate for examining potential differences in gene expression and AA metabolism between benign prostate and Pca (Table 1 of attached appendix 3). Initial aims included investigation of different grades of tumor, designated "well, moderately, and poorly differentiated" in the original proposal. This designation usually translates to Gleason score 2-4, 5-7, and 8-10, respectively. Gleason score 2-4 tumors are generally small transition zone (TZ) tumors, which may be discovered incidentally in TURP specimens, in autopsy prostates, or in radical prostatectomies (RP)s performed for higher grade index tumors in the peripheral zone (PZ). In addition, it is clear that Gleason 7 tumors behave more aggressively than Gleason 6 tumors (4). Additionally, as most of the RPs demonstrate index tumors in the peripheral zone (PZ) and have been performed for clinical stage T1c or T2 tumors, we have investigated possible correlation of altered 15-LOX-2 with tumor grade (and other pertinent clinical and pathologic parameters) by dividing tumors into those of Gleason score categories of 5, 6, 7, 8-10. We have found that such rigid correlation of altered 15-LOX-2 expression with grade and other parameters is more readily made by immunohistochemistry, which is described below.

Utilizing these snap frozen tissues, 15-HETE formation was detected from exogenous AA in 23/29 benign samples from 26 patients (3)(attached Appendix 3). 15-HETE production was detected in 6/6 mixed benign and malignant, reflecting either the contribution of the benign portion or retained expression in tumor. In contrast 15-HETE production was detected in only 1 of 4 pure tumor tissues (in which paired benign was not available). In pairs of pure benign and Pca from the same patient, 15-HETE production was reduced in Pca vs. benign in 9/14 ($p < 0/05$) (3) (attached Appendix 3). Others had previously reported increased 12-LOX mRNA in Pca by RT-PCR, particularly in high grade, high stage tumors (5) and studies in cell lines have suggested possible roles for 5-LOX and COX-2 in Pca (6-9). A major advantage of our employed enzyme assay methodology is the ability to simultaneously monitor formation of possible 5-LOX, 12-LOX, and COX-2 metabolites (5-HETE, 12-HETE, and prostaglandins (PGs), respectively) in Pca. Under conditions in which 15-HETE formation is detected in benign, neither 5-HETE nor 12-HETE production was detected in any of 29 benign and 24 tumor samples (6 mixed benign and tumor, 18 pure tumor). Expanded HPLC analyses of higher sample volumes showed occasional trace 5- and 12-HETE, with no discernible differences between benign and tumor (3) (attached Appendix 3). In contrast, addition of exogenous 5- and 12-LOX to prostate homogenates resulted in 5-HETE and 12-HETE formation, respectively (Figure 4, appendix 3). PG production has also not been prominent and is described in attached appendix 3.

B) Using paraffin embedded sections from these same 30 prostatectomies, perform immunohistochemical staining for 15-LOX-2. Additional whole mount sections will be utilized if necessary to examine adequate numbers of low and high grade PIN lesions in association with carcinomas. (months 1-12).

We have used immunohistochemistry on paraffin embedded sections from radical prostatectomies (RP) to characterize the expression of 15-LOX-2 in benign prostate and its possible reduction in Pca. Because of possible heterogeneity in tumor immunostaining and to characterize immunostaining in benign prostate, precursor lesions, and different grades of individual patients, we have employed sections from whole mounted RP specimens procured at Vanderbilt rather than the smaller tissue sections corresponding to the cores processed for enzyme assays and northern blots. As part of his clinical responsibilities and paralleling his interest in genitourinary pathology, Dr. Shappell has signed out the surgical pathology on all the radical prostatectomy specimens at Vanderbilt (beginning Jan. 1998). This has thus far corresponded to approximately 400 totally submitted whole mount embedded RP specimens over the past two years and 10 months. This has allowed for the creation of a data base with uniform assessment of pathologic parameters, such as grade, stage, and margin status, as well as tumor volume determinations by digital planimetry. This has greatly facilitated our studies on AA metabolism in Pca as well as collaborative clinicopathologic projects with members of the Department of Urology. We have used a polyclonal antiserum prepared against purified human 15-LOX-2, generally at a 1:1000 or 1:2500 dilution, and a Ventanna auto-immunostainer, as detailed in our first manuscript (1) (attached Appendix 1). We have demonstrated that this antibody is specific for human 15-LOX-2 (and the murine homologue, 8-LOX, described below) and does not cross react on western blots with human platelet type 12-LOX, 5-LOX, or 15-LOX-1. 15-LOX-2 is uniformly

present in apical or secretory cells of the PZ and secretory cells of prostatic ducts, and is also present (with less intense and less uniform immunostaining) in secretory cells of the TZ and central zone (CZ). It is not present in basal cells, prostatic stroma, transitional epithelium, ejaculatory ducts, or seminal vesicles (1) (attached Appendix 1). 15-LOX-2 immunostaining is reduced to a variable degree in atrophy, generally paralleling the degree of atrophy. In our original report, we characterized possible reduced immunostaining of 15-LOX-2 in Pca utilizing 18 RP cases, three of which matched the samples analyzed by HPLC and an additional 15 cases to reflect varying tumor grades and stages. In contrast to the uniform immunostaining for 15-LOX-2 in benign prostate, 15-LOX-2 was reduced to a variable extent in the majority of Pcas. 14 of 18 cases showed loss of 15-LOX-2 in > 25 % of the tumor (mean 74.9 % negative for 15-LOX-2; range 38.9 – 100 %) and 10/18 cases showed essentially complete loss of 15-LOX-2 immunostaining (1) (attached Appendix 1).

Subsequently, we completed a more comprehensive analysis of reduced 15-LOX-2 expression in Pca, correlating reduced immunostaining in tumors with tumor grade and stage and possible altered expression in high grade prostatic intraepithelial neoplasia within and remote from tumor, utilizing even more cases than proposed in the original grant. A total of 70 cases were selected (from a total of 207 radical prostatectomies during an 18 month period) to give a mixture of tumor grades and stages, as follows: Gleason score 5, 17 cases; Gleason score 6, 23 cases; Gleason score 7, 24 cases; Gleason score \geq 8, 6 cases. 40 cases were organ-confined tumors, 30 had extra-capsular extension, 8 had seminal vesicle invasion, and 4 had positive lymph nodes. Clinical parameters (age, PSA, clinical stage) were obtained from the patient record. 15-LOX-2 immunostaining was markedly reduced in the majority of prostate carcinomas. 15-LOX-2 immunostaining was completely absent in tumors in 23 of 70 cases and substantially reduced (< 50 % tumor 15-LOX-2 immunopositive) in 45 of 70 cases. The extent of absent or reduced 15-LOX-2 immunostaining correlated with tumor differentiation, with retained expression being particularly evident in Gleason grade 5 (either 2 + 3 or 3 + 2) tumors and extensive loss of immunostaining occurring in higher grade lesions (10) (attached Appendix 2). In a subset of 16 cases with spatially distinct tumors of different grade or different grade foci within the same tumor, the higher grade focus had significantly decreased immunostaining of 15-LOX-2 compared to the lower grade focus (10) (attached Appendix 2). In a subset of 27 cases, 15-LOX-2 immunostaining was specifically assessed in HGPIN glands. HGPIN was divided into 2 groups: HGPIN within the borders of tumor foci and HGPIN within benign parenchyma (\geq 2mm away from any tumor glands). Compared to the strongly positive staining observed in the vast majority of benign peripheral zone glands, 15-LOX-2 immunostaining was significantly reduced in HGPIN glands, both within tumor foci and in areas of histologically benign parenchyma (mean percent \pm sd of 15-LOX-2 positive glands: benign = 70 ± 20 %, HGPIN in benign parenchyma = 38 ± 25 %, HGPIN in tumor 20 ± 25 %; $p < 0.01$). The results of this study have been presented in abstract form as well as published recently in manuscript form (10) (attached Appendix 2).

C) Northern blots or RT-PCR and western blots for 15-LOX2 on mRNA and protein from frozen normal and malignant tissue from prostatectomy specimens containing well, moderately, and poorly differentiated carcinoma. Where possible, the same specimens as

in part A will be employed. Sufficient numbers of additional archival cases will be processed if necessary. This material will be utilized in completion of portions of task 2 as well. (months 6-15).

Utilizing homogenates prepared for enzyme assays, 15-LOX-2 protein has been detected by Western blot in 8/9 benign samples. Because of the greater biologic relevance of enzyme activity and the ability to simultaneously monitor catalytic activity of other LOX and COX enzymes we have focused more attention on enzyme assays on these portions of the snap frozen cores and quantitated possible reduced expression of 15-LOX-2 in tumor vs. benign utilizing Northern blots and immunohistochemistry (described above). The snap frozen cores allow isolation of adequate amounts of high quality well preserved RNA for Northern blots. 20 ug total RNA is loaded per sample. Blots are probed simultaneously for 15-LOX-2, using a 1088 bp cDNA, and the house keeping gene GAPDH. Quantitation is performed on a Packard Phosphorimager recently acquired as department core equipment or by standard densitometry on exposed film. 15-LOX-2 mRNA was detected in 21/25 benign samples. In pairs of pure benign and Pca from the same patient, 15-LOX-2 mRNA (normalized to GAPDH) was reduced in Pca vs. benign in 14/17 patients ($p < 0.05$) (3) (attached Appendix 3). These results extend the previous observations of reduced 15-LOX-2 immunostaining and enzyme activity to the transcriptional level. Because of the difficulty of obtaining pure benign and pure tumor from the same patient, correlation with grade and other tumor parameters has been made by immunohistochemistry as described above. In addition, recent efforts have begun employing laser capture microdissection (11), including coupled to quantitative real time RT-PCR (12). Such efforts will constitute a focus of future grant applications.

Paralleling our efforts to analyze PG production in Pca, we have examined the possible expression of COX-2 mRNA in benign and malignant prostate samples by RNase protection assays in collaboration with Dr. Matthew Breyer at Vanderbilt. COX-2 mRNA was detected in 7/16 benign and 5/16 tumors. In benign and tumor pairs from 10 patients, COX-2 was negative in both in 5; positive in benign/ negative in tumor in 3; negative in benign/ positive in tumor in 2. Also in collaboration with Dr. Breyer's laboratory, in situ hybridization for COX-2 mRNA was performed on 32 samples, generally paralleling those in which RNA from adjacent portions had been analyzed for COX-2 mRNA by protection assays. Importantly, the in situ studies allowed for localization of COX-2 expression to both glands and stroma of benign and malignant prostate. Similar to the results of the protection assays, there was no discernible difference between benign and tumor: 5/10 showed essentially similar levels of expression in both benign and malignant, 3/10 showed a greater degree of expression in benign vs. tumor, and 2/10 showed greater expression in tumor vs. benign (3) (attached Appendix 3). Recent studies published by others have suggested increased COX-2 immunostaining in Pca vs. benign (13, 14). COX-2 immunostaining will allow for better morphological localization of expression and possible correlation with specific tumor parameters, such as microvessel density paralleling the proposed possible role of COX-2 in tumor angiogenesis (15, 16). Given past concerns regarding specificity of COX-2 immunostaining, it is crucial to validate results with other techniques, such as in situ hybridization with riboprobes specific for COX-2 vs. COX-1. We have begun an immunohistochemical analysis for COX-2 on a large number (approximately 100) of radical prostatectomy specimens, with serial sections stained for the endothelial specific

marker CD-31. Similar to high COX-2 expression in the rodent vas deferens (see below), strong immunostaining is seen in ejaculatory duct near the terminal vas in prostate base portions (not shown). Specificity of immunostaining will be confirmed on a subset of these cases by in situ analysis on identical sections, similar to the approach utilized by us in studies reporting increased COX-2 expression in high grade bladder carcinomas (17). Studies on COX-2 expression and possible correlation with tumor angiogenesis in human RP specimens parallel investigations in transgenic mouse models described below and our recently submitted grant proposal to utilize novel COX-2 inhibitors as anti-angiogenic agents in the mouse models.

II. To establish the presence of PPAR subtypes in benign and malignant human prostate and evaluate the activity of 15-HETE in activation of these PPAR subtypes.

A) Northern blots or PCR for PPAR subtypes in paired benign and malignant tissue from archival prostatectomy samples. In general, the same specimens as in Task 1, part C above will be utilized. If necessary, additional specimens will be processed. (months 9-18).

By RT-PCR, PPAR α , PPAR β (δ), and PPAR γ mRNA were present in 18/18 benign prostate specimens and 9/9 pure prostate tumor specimens (including 6 paired benign and malignant from the same patients), snap frozen, identified and processed as described above (18) (attached as appendix 4). By RT-PCR, constitutive expression of PPAR α , PPAR β (δ), and PPAR γ mRNA was also detected in the prostate cancer cell line LNCaP, and PPAR β (δ) and PPAR γ mRNA in PC3 and DU-145 cells (18) (attached as appendix 4). As 15-HETE may activate transcription via PPAR γ (19) and synthetic ligands for PPAR γ inhibit PC3 proliferation (20), we have focused more attention on PPAR γ and employed PC3 cells for mechanistic *in vitro* studies.

B) Examination of 15S-HETE vs. other AA metabolites to activate PPAR subtypes identified in part A, using reporter assays available through Dr. DuBois' laboratory (months 18-30).

We have investigated the ability of 15-HETE to activate PPAR γ dependent transcription and modulate proliferation of the Pca cell line PC3. In contrast to benign prostate and similar to results in most actual Pca tissues, 15-LOX-2 mRNA was not detected in PC3 cells (by Northern blot or RT-PCR) and these cells did not produce detectable 15-HETE. Similar to previous reports, the synthetic PPAR γ ligand BRL 49653 caused a dose-dependent inhibition of PC3 proliferation in a 14 day soft agar colony forming assay. Similarly, addition of exogenous 15S-HETE caused a dose dependent inhibition of PC3 proliferation, with an IC50 of approximately 30 μ M (18) (attached as appendix 4). 10 μ M 15S-HETE caused greater inhibition than 10 μ M 15R-HETE. At 3 days, BRL 49653 and 15-HETE caused a slight delay in cell cycle as determined by flow cytometry. In PC3 cells transiently transfected with a luciferase reporter linked to a PPAR response element (PPRE), 1 μ M BRL 49653 and 10 μ M 15S-HETE caused approximately 3-fold and 2-fold induction of PPAR-dependent transcription, respectively (18) (attached as appendix 4). By real time RT-PCR and Northern blots, BRL 49653 and 15-HETE caused upregulation of the PPAR γ regulated adipocyte-type fatty acid binding protein (aP2) in PC3 cells (18) (attached as appendix 4).

These results support the hypothesis that 15-LOX-2 derived 15S-HETE may constitute an endogenous ligand for PPAR γ in the prostate. These results were presented in abstract form (21) and have been submitted for publication as a manuscript (18) (attached as appendix 4). Support for portions of these experiments which fall beyond the scope of this original proposal has been obtained via an Intramural Interdisciplinary Discovery Grant to Dr. Shappell.

III. To delineate the role of the murine homologue of 15-LOX2, a novel 8-lipoxygenase (8-LOX), in prostate cancer development in the LPB-Tag transgenic mouse.

A) Immunohistochemistry for 8-LOX in paraffin embedded prostate tissues of normal mice and LPB-Tag mouse lines 12T-11, 12T-5, and 12T-7(f). 5 mice at each of 2 different time points for each line as indicated in proposal. These time points correspond to times sampled for enzyme assays described below. Additional sections are available at other time points, if necessary (months 3-12). By paraffin immunoperoxidase, we have investigated the possible expression of murine 8-LOX, platelet type 12-LOX, leukocyte 12-LOX (the murine homologue of human 15-LOX-1), and COX-2 in wild type mice and multiple LPB-Tag lines over wide age ranges encompassing a spectrum of precursor and invasive neoplastic proliferations. Our 15-LOX-2 antibody cross reacts with the murine 8-LOX and as expected from previous demonstrations of increased 8-HETE and expression of 8-LOX in mouse skin treated with phorbol esters, such skin specimens (formalin fixed and paraffin embedded) have served as positive controls, with strong and consistent immunostaining. We have performed 8-LOX immunostaining on the dorsolateral prostate of 3-4 12T7-f mice each at 6, 9, 12, 15, 18, and 21 weeks and additional mice at 33 weeks and have not detected any appreciable 8-LOX immunostaining. In addition, we performed immunostaining on the prostates of 12T-5 mice at 12 and 16 weeks and 12T-11 mice at 12 and 30 weeks and also have not seen 8-LOX expression. 8-LOX immunostaining is also not detected in wild type mice at 7, 10, 13, 17, 18, and 42 weeks (not shown). These specific Tag lines were originally selected as targets of study because they represented different rates of growth of the prostate (22). However, these lesions are characterized histologically by proliferation of cytologically malignant epithelial cells within pre-existing duct and gland structures (analogous to human HGPIN) or in expanded lobular units, without frequent unequivocal stromal invasion or metastases. As we are studying true invasive carcinoma in the human (in addition to attention to the precursor lesion HGPIN), we have sought additional models to better represent HGPIN, invasive, and metastatic carcinoma analogous to human Pca and to allow study of changes in AA metabolism between benign or precursor lesions and frankly invasive tumors. As part of our ongoing collaboration with Dr. Matusik's laboratory, further characterization of LPB-Tag mice has demonstrated invasive and metastatic carcinoma with neuroendocrine differentiation developing in castrated 12T-5, 12T-7s, and 12T-7f mice maintained for subsequent outgrowth of androgen insensitive tumors (23) (manuscript in preparation).

In addition, the 12T-10 line, not previously characterized, shows tremendous promise as a model of evolving prostate carcinoma, including progression to androgen insensitive metastatic disease, with NE differentiation (24, 25). Similar to other LPB-Tag lines, the prostate in the 12T-10 mouse shows epithelial proliferation with features compatible with low and subsequent HGPIN. However, the epithelial proliferation

appears to conform much more to normal gland profiles, without prominent lobular expansion, and stroma hypercellularity is not conspicuous. As such, the initial lesions are much more morphologically analogous to human HGPIN. In contrast to some of the other LPB-Tag lines, prostate enlargement in the 12T-10 line is slower, as previously reported (22). However, the HGPIN lesion predictably progresses to microinvasive disease and more extensive foci of invasive carcinoma, both with and without definitive glandular differentiation. Essentially all of these animals develop metastatic disease by 44 weeks of age in lymph nodes, lung, and liver. The more extensive locally invasive tumors and the metastatic lesions show histologic features of NE differentiation, including scant cytoplasm, granular ("salt and pepper") chromatin, and rosette formation. NE differentiation has been confirmed by immunohistochemical studies (e.g., chromogranin) and ultrastructurally, and is present in a progressively greater fraction of cells with progression of HGPIN. Overall, in a characterization of 52 mice aged 2 to 12 months, 100 % of the mice \geq 2 months had HGPIN, with foci of microinvasion noted in 20, 40, 80, and 100 % in mice 4, 5, 6, and \geq 7 months, respectively. Definitive foci of invasion, with glandular or neuroendocrine differentiation, were present in 40 % of mice 6-7 months of age, and in $>$ 80 % of mice \geq 8 months of age. Metastases were present in 66 % of mice \geq 6 months and 88 % of mice \geq 9 months, correlating with the presence of histologically similar invasive tumor in the prostate (24, 25). Recent and ongoing studies on AA metabolism in the Tag mouse will include time course studies in this very promising 12T-10 line as well as castrated mice from the other lines.

B) AA metabolism assays on prostate tissue from specific mouse lines at time points indicated above, using HPLC as in human prostate studies (Task 1, part A) (months 3-12).

Corroborating our lack of detection of 8-LOX immunostaining in the prostate of the Tag mouse, 8-HETE formation has been detected in AA incubations of wild type or Tag mouse prostates from 13 to 19 weeks (not shown). Similar to this approach in analysis of human prostate tissues, these assays allow for possible detection of other AA metabolites. The most prominent alteration in AA metabolism identified thus far is in 12-HETE formation. Wild type prostate synthesizes 12-HETE from exogenous AA, particularly the anterior prostate. 12-HETE formation is much less pronounced in the dorsolateral lobe (DLP, most analogous to human peripheral zone) in wild type mice (1.06 ± 0.90 % conversion from exogenous AA, mean \pm S.D.). In contrast, 12-HETE formation is markedly increased in incubations of DLP from 12T-7f LPB-Tag mice (8.03 ± 4.43 % AA conversion). Results from immunohistochemical studies on more than 50 Tag mouse prostate sections support the identity of this 12-LOX activity as being that of the murine leukocyte 12-LOX, rather than platelet type 12-LOX (not shown). This has been supported by quantitative real time RT-PCR utilizing a Roche LightCycler with the double stranded DNA binding fluorescent probe SYBR Green (26), with standard curves and confirmation of amplicon specificity by melting curve analysis (27) (not shown). The murine leukocyte 12-LOX is the presumed homologue of the human 15-lipoxygenase-1 (15-LOX-1), which has recently been reported by immunohistochemistry to be increased in some human prostate cancers, correlating with grade and p53 mutations (28). In our mouse prostate AA incubations, formation of more polar lipid peroxidation products is

more characteristic of this enzyme. Although 15-HETE formation has not accompanied the 12-HETE formation in our assay conditions, recent data has indicated that the murine 12/15-LOX (leukocyte 12-LOX) can make substantially more 12-HETE than 15-HETE in some tissues (e.g., 97:3 in murine reticulocytes (29)). Hence, the Tag mouse may be useful in delineating the possible mechanism whereby increased 15-LOX-1 may contribute to human prostate cancer progression.

In addition, we have observed increased cyclooxygenase activity and COX-2 expression in the Tag mouse. Increased hydroxyheptadecatrienoic acid (HHT) has been noted in AA incubations of the DLP of 12T-7f vs. wild type mice (4.50 ± 2.16 % AA conversion in 12T-7f vs. 0.14 ± 0.33 % in wild type). Preliminary message analyses and especially immunohistochemical studies support increased COX-2 in the Tag mouse prostate tumors. COX-2 mRNA was not detected by RT-PCR in wild type or in 4 12T-7f mice 13-16 wks old, but was detected in 2/5 12T-7f mice 17-18 wks old. Increased COX-2 immunostaining has been noted in HGPIN in 12T-7f and even more prominently in the 12T-10 mouse. Specificity of the immunostaining has been demonstrated by negative results in the vas deferens of COX-2 knockout mice vs. the expected strong staining in vas of wild type mice (30) (not shown). With this specific COX-2 antibody, very focal immunostaining was detected in 2/11 12T-7f mice 6-12 wks old, with more extensive focal staining in 3/7 mice 14-16 wks old, and even greater staining (25-75 % epithelium positive) in HGPIN in 4/8 mice 17-22 wks old. Following castration, in addition to marked epithelial atrophy, focal epithelial stratification and PCNA immunostaining is noted (not shown). Focal to extensive COX-2 immunostaining was noted in stratified epithelium in 10/14 12T-5, 12T-7s, 12T-7f, and 12T-11 mice castrated from ages 16 to 25 wks. and maintained for 6 to 32 wks. post-castration (not shown). In contrast, COX-2 was not noted in any of 5 primary or metastatic poorly differentiated carcinomas with NE differentiation in these mice. Increased COX-2 is even more pronounced in HGPIN in 12T-10 mice (Table 1).

Table 1: Increased COX-2 immunostaining in Epithelium of HGPIN in 12T-10

<u>Mouse</u>	<u>AGE (mos)</u>	<u>LOBE</u>	<u>COX-2 in HGPIN</u>
6		DP,LP	0 ^a , 1+, 2+
		VP	3+, 2+, 4+
7		DP,LP	1+, 1+, 1+, 3+
		VP	3+, 3+, ND, 4+
8-9		DP,LP	3+, 2+, 4+
		VP	4+, 4+, ND
10-12		DP, LP	3+, 1+
		VP	4+ ^b , 3+ ^b

^a0, neg.; 1+, < 5 %; 2+, 10-25 % cells or 50 % cells in 10-25 % glands; 3+, 25-50 % cells/glands; 4+, diffuse (> 50%)

^bneg. in associated invasive/metastatic NE carcinoma (Fig 2e)

Key Research Accomplishments:

- Use of northern blots, western blots, and tissue incubations with HPLC to demonstrate the uniform presence in benign prostate of 15-LOX-2 mRNA, protein, and enzyme activity.
- Use of paraffin immunohistochemistry to characterize the distribution of 15-LOX-2 in normal prostate. 15-LOX-2 is expressed in apical or secretory cells, particularly in the peripheral zone.
- Use of immunohistochemistry and enzyme assays in fresh tissues to demonstrate a marked reduction or loss of 15-LOX-2 expression in prostate adenocarcinoma compared to benign prostate.
- Demonstration by immunohistochemistry that reduced 15-LOX-2 correlates with grade, with retained expression in Gleason score 5 tumors vs. significant reduction in Gleason score 6, 7, and ≥ 8 . Within individual heterogeneous tumors, 15-LOX-2 is significantly reduced in high grade vs. lower grade foci. 15-LOX-2 is reduced in high grade prostatic intraepithelial neoplasia, suggesting reduced expression may be an early alteration in prostate cancer development.
- Utilization of snap frozen prostate tissues to further show that reduced 15-LOX-2 catalytic activity in tumor vs. benign is a statistically significant alteration in prostate cancer. Utilization of snap frozen prostate tissues to extend studies to RNA analysis. Demonstration by Northern blots that 15-LOX-2 mRNA is reduced in prostate cancer compared to benign in the vast majority of cases, which was also statistically significant.
- Use of enzyme assays (tissue incubation and RP-HPLC) to demonstrate that significant 5-HETE or 12-HETE production is not observed in benign or malignant prostate tissues, with good positive controls utilizing exogenous enzyme sources in prostate homogenates.
- Use of Rnase protection assays and in situ hybridization to detect COX-2 in snap frozen prostate tissues, demonstrating that COX-2 is sometimes expressed in benign prostate, with reduction in prostate carcinoma and sometimes increased in prostate carcinoma relative to benign. These results, recently extended to a large number of radical prostatectomy cases, challenge recent observations of general increased COX-2 in prostate cancer utilizing less specific immunohistochemical assays.
- Use of RT-PCR to demonstrate constitutive expression of PPAR α , PPAR β , and PPAR γ in benign prostate and prostate adenocarcinoma. PPAR γ was detected in 18/18 benign and 9/9 tumor samples, including 6 benign/tumor pairs from the same patients, and the prostate carcinoma cell lines PC3, DU-145, and LNCaP.

Key Research Accomplishments - continued:

- Demonstration in soft agar colony forming assays that 15-HETE, as well as a synthetic PPAR γ agonist, inhibits proliferation of prostate carcinoma cell line PC3. Demonstration that 15-HETE, as well as a synthetic PPAR γ agonist, induces PPAR γ -dependent transactivation in PC3 and DU-145 cells transiently transfected with a PPAR-response element (PPRE) linked to a luciferase reported construct. 15-HETE and a synthetic PPAR γ agonist upregulated expression of known PPRE containing gene, adipocyte-type fatty acid binding protein (aFABP), in PC3 cells.
- Establishment of paraffin immunohistochemistry assays for murine 8-LOX, platelet type 12-LOX, leukocyte type 12-LOX (12/15 LOX), and COX-2. The specificity of the assay for COX-2 was confirmed by absence of detection in the COX-2 knockout mouse.
- Acquisition of a Roche LightCyclerTM Fluorimeter Real Time RT-PCR system (purchased with funds not included in grant), and establishment of quantitative real-time RT-PCR assays for human 15-LOX-2, β -actin, PSA, PPAR γ , and aFABP, and murine platelet 12-LOX and leukocyte 12-LOX.
- Demonstration by immunohistochemistry, RT-PCR, and enzyme assays that the 8-LOX murine homologue of 15-LOX-2 is not expressed in wild type or the 12T-7f and other lines of the LPB-Tag transgenic mouse model of prostate adenocarcinoma.
- Demonstration by enzyme assay that 12-HETE formation is the most characteristic aspect of AA metabolism in the 12T-7f Tag mouse prostate.
- Demonstration by a combination of immunohistochemistry and real time quantitative RT-PCR that the 12-LOX catalytic activity is due to the murine leukocyte 12-LOX (homologue of human 15-LOX-1). Preliminary studies, that leukocyte 12-LOX is increased in HGPIN and invasive carcinoma in Tag mice.
- Demonstration by immunohistochemistry that COX-2 is upregulated in HGPIN in the LPB-Tag mouse, especially line 12T-10, where it appears in preliminary studies, to be lost in progression to invasive poorly differentiated carcinoma with neuroendocrine differentiation.
- Establishment of a data base of totally submitted whole mount processed radical prostatectomy specimens (approximately 400 cases) and a snap frozen tissue bank of prostates from radical prostatectomies performed at Vanderbilt University Medical Center (approximately 1200 samples from 150 patients).

Reportable outcomes:

Manuscripts:

- **Shappell, S.B.**, Boeglin, W.E., Olson, S.J., Kasper, S., Brash, A.R.: 15-Lipoxygenase-2 (15-LOX-2) is expressed in benign prostatic epithelium and reduced in prostate adenocarcinoma. *Am. J. Pathol.*, 155:235-245, 1999. (attached)
- Brash A. R., Jisaka, J., Boeglin, W. E., Chang, M. S., Keeney, D. S., Nanney, L. B., Kasper, S., Matusik, R.J., Olson, S.J., **Shappell, S. B.** (1999) Investigation of a second 15S-lipoxygenase in humans and its expression in epithelial tissues. *Adv Exp Med Biol* 469:83-89, 1999.
- Matusik, R.J., Masumori, N., Thomas, T., Case, T., Paul, M., Kasper, S., **Shappell, S.B.**: Transgenic mouse models of prostate cancer. *In* *Transgenics in Endocrinology*, edited by Matzuk, M.M., Brown, C.W., and Kumar, T.R., Humana Press, Inc., Totowa, N.J., in press.
- Jack, G.S., Brash, A.R., Olson, S.J., Manning, S., Coffey, C.S, Smith, J.A., Jr., **Shappell, S.B.**: Reduced 15-lipoxygenase-2 immunostaining in prostate adenocarcinoma: Correlation with grade and expression in high grade prostatic intraepithelial neoplasia. *Hum Pathol* 31:1146-1154, 2000. (attached)
- Masumori, N., Thomas, T.Z., Chaurand, P., Case, T., Paul, M., Kasper, S., Caprioli, R.M., Tsukamoto, T., **Shappell, S.B.**, Matusik, R.J.: A probasin-large T antigen transgenic mouse line develops metastatic neuroendocrine prostate cancer. *Cancer Res.* Submitted.
- **Shappell, S.B.**, Masumori, N., Thomas, T., Case, T., Paul, M., Kasper, S., Matusik, R.J.: Transgenic mouse models of prostate carcinoma: Anatomic, histopathologic, and molecular considerations. *In* *Prostate Cancer: Scientific and Clinical Aspects. Bridging the Gap*, edited by Abel, P.D., Lalani, E-N., Imperial College Press, in press.
- **Shappell, S.B.**, Keeney, D.S., Zhang, J., Page, R., Boeglin, W.E., Olson, S.J., Brash, A.R.: Expression of 15-lipoxygenase-2 (15-LOX-2) in benign and neoplastic sebaceous glands. *J Invest Dermatol.*, accepted with minor revision.
- Carter, B.A., Brash, A.R., Page, D.L., Olson, S.J., **Shappell, S.B.**: 15-lipoxygenase-2 expression in human breast. Correlation with apocrine differentiation. *Lab Invest.* In preparation.
- **Shappell, S.B.**, Manning, S., Boeglin, W.E., Jack, G.S., Guan, Y., Breyer, M.D., Wheeler, T.M., Brash, A.R. Alterations in lipoxygenase and cyclooxygenase-2 catalytic activity and mRNA expression in prostate carcinoma. In preparation (attached).
- **Shappell, S.B.**, Gupta, R.A., Manning, S., Whitehead, R., Boeglin, W.E., Schneider, C., Case, T., Price, J., Jack, G.S., Wheeler, T.M., Matusik, R.J., Brash, A.R., DuBois, R.N. 15S-HETE activates peroxisome proliferator activated receptor gamma and inhibits proliferation of prostate carcinoma PC3 cells. *Cancer Res.*, accepted with minor revision; revised version, submitted (attached).
- Jack, G.S., Olson, S.J., Manning, S., Brash, A.R., Darrisaw, L., Vader, V., Case, T., Smith, J.A., Jr., Matusik, R.J., Peehl, D.M., **Shappell, S.B.**: Developmental and hormonal regulation of 15-lipoxygenase-2 in human prostate epithelium. *Endocrinol*, in preparation.

Reportable outcomes - continued:

Abstracts:

- **Shappell, S.B.**, Boeglin, W.E., Olson, S.J., Brash, A.R. 15-lipoxygenase-2 (15-LOX-2) is expressed in benign prostatic epithelium and reduced in prostate adenocarcinoma. *Lab. Invest.* 79:107a, 1999.
- Brash, A.R., Boeglin, W.E., Schoenhard, J.A., Keeney, D.S., Carter, B., **Shappell, S.B.** 15-lipoxygenase-2 in human epithelial cells and its reduced expression in cancer. *Eicosanoids and Other Bioactive Lipids in Cancer, Inflammation, and Related Diseases*, 6th International Conference, Boston, MA, 1999.
- Masumori, N., Vaikunth, S., Thomas, T.Z., Thomas, J., Tsukamoto, T., Case, T., Paul, M., Lee, H., Price, R.R., Chaurand, P., Caprioli, R., Kasper, S., **Shappell, S.**, Matusik, R.J. Regrowth of prostate tumor after castration in probasin-large T antigen transgenic mice - longitudinal study with MRI. American Urological Association, 95th Annual Meeting, Atlanta, GA, 2000.
- Masumori, N., Thomas, T.Z., Kasper, S., Chaurand, P., Caprioli, R., Tsukamoto, T., **Shappell, S.**, Matusik, R.J. A probasin-large T antigen transgenic mouse line develops neuroendocrine and metastatic prostate cancer. American Urological Association, 95th Annual Meeting, Atlanta, GA, 2000.
- **Shappell, S.B.**, Manning, S., Boeglin, W.E., Jack, G.S., Guan, Y., Breyer, M.D., Wheeler, T.M., Brash, A.R. Alterations in lipoxygenase and cyclooxygenase-2 catalytic activity and mRNA expression in prostate carcinoma. *Advances in Prostaglandin and Leukotriene Research*, 11th International Conference, Florence, Italy, June 2000.
- Jack, G.S., Brash, A.R., Olson, S.J., Manning, S., Coffey, C.S., Smith, J., Jr., **Shappell, S.B.** Reduced 15-lipoxygenase-2 in prostate carcinoma: correlation with tumor grade and high grade prostatic intraepithelial neoplasia. *Advances in Prostaglandin and Leukotriene Research*, 11th International Conference, Florence, Italy, June 2000.
- **Shappell, S.B.**, Gupta, R., Manning, S., Boeglin, W.E., Cates, T., Jack, G.S., Whitehead, R., Price, J., Matusik, R.J., Brash, A.R., DuBois, R.N. 15S-HETE activates peroxisome proliferator activated receptor gamma and inhibits proliferation of prostate carcinoma PC3 cells. *Advances in Prostaglandin and Leukotriene Research*, 11th International Conference, Florence, Italy, June 2000.

Presentations (not including from submitted abstracts, above):

- **Shappell, S.B.** Arachidonic Acid Metabolism in Prostate Adenocarcinoma. Clinical Pharmacology Seminar Series, Vanderbilt University Medical Center, March, 1999.
- **Shappell, S.B.** Arachidonic Acid Metabolism in Human and Murine Models of Prostate Adenocarcinoma. Investigative Pathology Research in Progress Seminar Series, Vanderbilt University Medical Center, April, 1999.

Reportable outcomes - continued:

Tissue repository: Tissue bank of snap frozen prostate for molecular biology studies, joint effort of the Vanderbilt-Ingram Cancer Center, Human Tissue Acquisition and Shared Resources and Dr. Shappell. Based on our success with the snap frozen cores obtained from Baylor College of Medicine, we have instituted a similar program of obtaining tissue intraoperatively, adequate for molecular biologic studies. Nine 6 mm core biopsies are taken in each case from: TZ, mid to apex, right; TZ, mid to apex, left; PZ, mid to apex, right; PZ, mid to apex, left; TZ, mid to base, right; TZ, mid to base, left; PZ, mid to base, right; PZ, mid to base, left; Seminal vesicle. The cores are identified as to benign, tumor, and percent tumor based on correlation with histopathologic findings in whole mount sections and this information is entered into a data base. Thus far, over 1200 samples from more than 150 radical prostatectomies have been successfully procured.

Database: Radical prostatectomy pathology data base, with clinical and pathological parameters from all radical prostatectomy cases submitted in their entirety for whole mount sections and signed out by Dr. Shappell. This was begun Jan. 1998 and currently contains over 390 cases. Histopathologic parameters recorded include tumor location, grade, stage status of margins and location of positive margins, total tumor volume determined by digitized planimetry, and other unique histologic findings.

Funding applied for based on work supported by award:

Awarded:

- Discovery Grant in Prostate Cancer Research; The Vanderbilt Cancer Center; **Principal Investigator:** Scott B. Shappell, M.D., Ph.D.; 04/01/99 - 03/31/00, \$23,500.00 (total).
- 15-LOX-2 and PPARs in regulation of prostate carcinoma cell growth and differentiation; Vanderbilt University Medical Center Intramural Interdisciplinary Discovery Grant; **Principal Investigator:** Scott B. Shappell, M.D., Ph.D.; 07/01/99 - 06/30/01, \$110,455.00 (total); 5 % salary support.
- Growth inhibitory and stimulatory signals in prostate cancer; Dept. of Defense Prostate Cancer Center Grant; Principal Investigator, Robert J. Matusik; **Pathology Core Director:** Scott B. Shappell, M.D., Ph.D.; 03/01/00 - 02/28/03; \$548,000.00/yr, Pathology Core \$155,000.00/yr; 25 % effort

Submitted:

- Modulation of 15-lipoxygenase-2 by hormonal therapy and the role of lipoxygenases and cyclooxygenases in prostate adenocarcinoma: A combined immunohistochemical and laser capture microdissection RT-PCR analysis; NIH Finasteride Chemoprevention Trial / Southwest Oncology Group; **Principal Investigator:** Scott B. Shappell, M.D., Ph.D.; 07/01/99 - 06/30/0, \$165,958.00 (total); 10 % effort-**no grants awarded**; pending end of trial; resubmission requested
- Arachidonic acid metabolism and peroxisome proliferator activated receptors in prostate carcinoma; Charles E. Culpeper Foundation Scholarship in Medical Science; **Principal Investigator:** Scott B. Shappell, M.D., Ph.D.; 07/01/00 - 06/30/03; 99,925.00/yr (direct); 25 % effort.-**not funded**

Reportable outcomes, grants submitted - continued:

- MMC/VICC Minority Prostate Cancer Initiative; NIH P20 (RFA: CA-01-003); Principal Investigator: Bruce Roth, M.D., Dept. of Medicine; **Co-Leader:** Scott B. Shappell, M.D., Ph.D.; **Pilot Project:** Utilization of a Snap Frozen Prostate Tissue Bank for cDNA Microarray Analysis of Gene Expression Profiles, Comparative Chromosomal Alterations and Characterization of Novel Nuclear Receptor Pathways in African American Male and Caucasian American Male Prostate Cancer; 03/01/01 - 02/28/04; \$584,484.00 (total); 5 % effort.-**pending**
- Novel Lipoygenases and Peroxisome Proliferator Activated Receptor Gamma in the Development of Human and Murine Prostate Carcinoma; Department of Defense Grant, New Investigator Award, Phase II; **Principal Investigator:** Scott B. Shappell, M.D., Ph.D; 11/01/00 - 10/31/02, \$440,388.00 (total); 30 % effort.-**not funded** (ouch)
- Novel Anti-angiogenesis Treatment Strategies in a Well Characterized Transgenic Mouse Model of Prostate; CaP CURE; **Principal Investigator:** Scott B. Shappell, M.D., Ph.D; \$150,000.00 (total).-**pending**

Personnel receiving pay from the research effort:

Scott B. Shappell, M.D., Ph.D. - Assistant Professor, Principal Investigator

Suzanne Manning - Research Assistant III

Conclusions:

Development of new diagnostic strategies for better establishing prognosis in patients with prostate carcinoma and new treatment approaches will be facilitated by discovering novel pathways regulating prostate cell growth and differentiation and understanding how these are altered in prostate cancer development and progression. By a combination of immunohistochemistry, enzyme activity assays, and mRNA analysis, we have demonstrated that the novel lipoxygenase, 15-lipoxygenase-2 (15-LOX-2), is selectively expressed in the human prostate. 15-LOX-2 is expressed in differentiated apical secretory cells. In contrast, 15-LOX-2 is reduced in the vast majority of prostate carcinomas. This reduced expression correlates with tumor differentiation or grade and occurs in HGPIN, suggesting it may be an early alteration in prostate carcinoma development. We have demonstrated that the nuclear receptor peroxisome proliferator activated receptor gamma (PPAR γ) is present in benign and malignant prostate tissues and prostate cancer cell lines. Further, we have shown that the enzymatic product of 15-LOX-2, 15-hydroxyeicosatetraenoic acid (15-HETE), activates PPAR γ -dependent transcription and inhibits proliferation of prostate cancer cells. These results support the hypothesis that 15-LOX-2 critically contributes to prostate cell differentiation, that its product 15-HETE represents an endogenous ligand for PPAR γ in the prostate, and that loss of 15-LOX-2 may contribute to development or progression of prostate cancer by reduced transcription of PPAR γ -regulated genes. These observations are particularly important now, as synthetic ligands for PPAR γ are available and are being used in clinical trials, including for prostate cancer. Understanding the relationship between androgens, 15-LOX-2, and PPAR γ in benign and malignant prostate may help identify prostate cancer patients who are particularly likely to benefit from these novel treatment strategies.

Transgenic mouse models of prostate carcinoma represent potentially valuable tools for further elucidating changes leading to prostate cancer and for testing pharmacologic agents. We have been actively engaged in the characterization of novel transgenic mouse models, including those generated with the long probasin promoter (LPB) and the SV40 large T antigen (Tag). LPB-Tag mice develop HGPIN, and some lines progress to invasive and metastatic carcinoma, either with castration or spontaneously. It is unlikely that any one mouse model will be able to address all relevant genetic and other subsequent molecular alterations implicated in human prostate cancer. In wild type or LPB-Tag mouse, we did not detect expression of the 8-lipoxygenase, which is most closely related to human 15-LOX-2 (presumed homologue of 15-LOX-2), and the product of which (8-HETE) may be a ligand for PPAR α in other organ systems (e.g., skin). However, as the 12T-10 mouse progresses from HGPIN, to microinvasive carcinoma, more extensive invasive carcinoma with both glandular and neuroendocrine differentiation, and metastatic neuroendocrine carcinoma paralleling loss of androgen dependence (analogous to important stages in the spectrum of human prostate cancer), we feel this model may still be useful in future studies to indicate at what stages PPAR γ agonists may be beneficial. This is a valid direction for future research, as these drugs are being explored for treatment of many epithelial carcinomas (e.g., breast, urinary bladder), in which endogenous ligands have not been identified. In addition, some changes identified in AA metabolism in the Tag mouse have been

described in at least a subset of human prostate carcinomas, such as increased expression of murine 12/15-LOX (human 15-LOX-1) and COX-2. Hence, the observations made herein indicate that this mouse model may be useful for elucidating the role of these genes in human prostate cancer. Future studies can also employ cross breeding of LPB-Tag or other mouse lines with transgenic mice in which these genes or PPAR γ are knocked out, including selectively in the prostate.

References:

1. Shappell, S. B., Boeglin, W. E., Olson, S. J., Kasper, S., and Brash, A. R. 15-lipoxygenase-2 (15-LOX-2) is expressed in benign prostatic epithelium and reduced in prostate adenocarcinoma, *Am J Pathol.* 155: 235-245, 1999. (attached)
2. Wheeler, T. M. and Lebovitz, R. M. Fresh tissue harvest for research from prostatectomy specimens, *Prostate.* 25: 274-279, 1994.
3. Shappell, S. B., Manning, S., Boeglin, W. E., Guan, Y., Davis, L., Jack, G. S., Roberts, R. L., Coffey, C. S., Wheeler, T. M., Breyer, M. D., and Brash, A. R. Alterations in lipoxygenase and cyclooxygenase-2 catalytic activity and mRNA expression in prostate carcinoma, *Neoplasia. (in preparation):*, 2000. (attached)
4. Epstein, J. I., Partin, A. W., Sauvageot, J., and Walsh, P. C. Prediction of progression following radical prostatectomy. A multivariate analysis of 721 men with long-term follow-up, *Am J Surg Pathol.* 20: 286-292, 1996.
5. Gao, X., Grignon, D. J., Chbihi, T., Zacharek, A., Chen, Y. Q., Sakr, W., Porter, A. T., Crissman, J. D., Pontes, J. E., Powell, I. J., and Honn, K. V. Elevated 12-lipoxygenase mRNA expression correlates with advanced stage and poor differentiation of human prostate cancer, *Urology.* 46: 227-237, 1995.
6. Ghosh, J. and Myers, C. E. Arachidonic acid stimulates prostate cancer cell growth: critical role of 5-lipoxygenase, *Biochem Biophys ResComm.* 235: 418-423, 1997.
7. Anderson, K. M., Seed, T., Vos, M., Mulshine, J., Meng, J., Alrefai, W., Ou, D., and Harris, J. E. 5-lipoxygenase inhibitors reduce PC-3 cell proliferation and initiate nonnecrotic cell death, *Prostate.* 37: 161-173, 1998.
8. Tjandrawinata, R. R., Dahiya, R., and Hughes-Fulford, M. Induction of cyclooxygenase-2 mRNA by prostaglandin E2 in human prostatic carcinoma cells, *Br J Cancer.* 75: 1111-1118, 1997.
9. Liu, X.-H., Yao, S., Kirschenbaum, A., and Levine, A. C. NS398, a selective cyclooxygenase-2 inhibitor, induces apoptosis and down-regulates bcl-2 expression in LNCaP cells, *Cancer Res.* 58: 4245-4249, 1998.
10. Jack, G. S., Brash, A. R., Olson, S. J., Manning, S., Coffey, C. S., Smith, J. A., Jr., and Shappell, S. B. Reduced 15-lipoxygenase-2 immunostaining in prostate adenocarcinoma: Correlation with grade and expression in high grade prostatic intraepithelial neoplasia, *Hum Pathol.* 31: 1146-1154, 2000. (attached)
11. Emmert-Buck, M. R., Bonner, R. F., Smith, P. D., Chuaqui, R. F., Zhuang, Z., Goldstein, S. R., Weiss, R. A., and Liotta, L. A. Laser capture microdissection, *Science.* 274: 998-1001, 1996.
12. Goldsworthy, S. M., Stockton, P. S., Trempus, C. S., Foley, J. F., and Maronpot, R. R. Effects of fixation on RNA extraction and amplification from laser capture microdissected tissue, *Mol Carcinog.* 25: 86-91, 1999.
13. Gupta, S., Srivastava, M., Ahmad, N., Bostwick, D. G., and Mukhtar, H. Over-expression of cyclooxygenase-2 in human prostate adenocarcinoma, *Prostate.* 42: 73-78, 2000.
14. Yoshimura, R., Sano, H., Masuda, C., Kawamura, M., Tsubouchi, Y., Chargui, J., Yoshimura, N., Hla, T., and Wada, S. Expression of cyclooxygenase-2 in prostate carcinoma, *Cancer.* 89: 589-596, 2000.

15. Sawaoka, H., Tsuji, S., Tsujii, M., Gunawan, E. S., Sasaki, Y., Kawano, S., and Hori, M. Cyclooxygenase inhibitors suppress angiogenesis and reduce tumor growth in vivo, *Lab Invest.* 79: 1469-1477, 1999.
16. Liu, X. H., Kirschenbaum, A., Yao, S., Lee, R., Holland, J. F., and Levine, A. C. Inhibition of cyclooxygenase-2 suppresses angiogenesis and the growth of prostate cancer in vivo, *J Urol.* 164: 820-825, 2000.
17. Komhoff, M., Guan, Y., Shappell, H. W., Davis, L., Jack, G., Shyr, Y., Koch, M. O., Shappell, S. B., and Breyer, M. D. Enhanced expression of cyclooxygenase-2 in high grade human transitional cell bladder carcinomas, *Am J Pathol.* 157: 29-35, 2000.
18. Shappell, S. B., Gupta, R. A., Manning, S., Whitehead, R., Boeglin, W. E., Schneider, C., Case, T., Price, J., Jack, G. S., Wheeler, T. M., Matusik, R. J., Brash, A. R., and DuBois, R. N. 15-hydroxyeicosatetraenoic acid (15-HETE) activates peroxisome proliferator activated receptor gamma and inhibits proliferation in PC3 prostate carcinoma cells, *Cancer Res.* *accepted with minor revision*, 2000. (attached)
19. Nagy, L., Tontonoz, P., Alvarez, J. G. A., Chen, H., and Evans, R. M. Oxidized LDL regulates macrophage gene expression through ligand activation of PPARgamma, *Cell.* 93: 229-240, 1998.
20. Kubota, T., Koshizuka, K., Williamson, E. A., Asou, H., Said, J. W., Holden, S., Miyoshi, I., and Koeffler, H. P. Ligand for peroxisome proliferator-activated receptor gamma (Troglitazone) has potent antitumor effect against human prostate cancer both in vitro and in vivo, *Cancer Res.* 58: 3344-3352, 1998.
21. Shappell, S. B., Gupta, R., Manning, S., Boeglin, W. E., Case, T., Jack, G. S., Whitehead, R., Price, J., Matusik, R. J., Brash, A. R., and DuBois, R. N. 15-hydroxyeicosatetraenoic acid (15-HETE) activates peroxisome proliferator activated receptor gamma and inhibits proliferation in PC3 prostate carcinoma cells, 11th International Conference on Advances in Prostaglandin and Leukotriene Research: Basic Science and New Clinical Applications. *Florence, Italy: (Abstract)*, 2000.
22. Kasper, S., Sheppard, P. C., Yan, Y., Pettigrew, N., Borowsky, A. D., Prins, G. S., Dodd, J. G., Duckworth, M. L., and Matusik, R. J. Development, progression and androgen-dependence of prostate tumors in transgenic mice: A model for prostate cancer, *Lab Invest.* 78: 319, 1998.
23. Masumori, N., Vaikunth, S., Thomas, T. Z., Thomas, J., Tsukamoto, T., Case, T., Paul, M., Lee, H., Price, R. R., Caurand, P., Caprioli, R., Kasper, S., Shappell, S., and Matusik, R. J. Regrowth of prostate tumor after castration in probasin-large T antigen transgenic mice - longitudinal study with MRI, *J Urol. (abstract):*, 2000.
24. Masumori, N., Thomas, T. Z., Kasper, S., Chaurand, P., Caprioli, R., Tsukamoto, T., Shappell, S., and Matusik, R. J. A probasin-large T antigen transgenic mouse line develops neuroendocrine and metastatic prostatic cancer, *J Urol. (abstract):*, 2000.
25. Masumori, N., Thomas, T. Z., Case, T., Paul, M., Kasper, S., Chaurand, P., Caprioli, R. M., Tsukamoto, T., Shappell, S. B., and Matusik, R. J. A probasin-large T antigen transgenic mouse line develops prostate adeno- and neuroendocrine-carcinoma having metastatic potential, *Cancer Res.* *submitted:*, 2000.
26. Kofron, M., Demel, T., Xanthos, J., Lohr, J., Sun, B., Sive, H., Osada, S. I., Wright, C., Wylie, C., and Heaseman, J. Mesoderm induction in *Xenopus* is a zygotic event regulated by maternal VegT via TGFbeta growth factors, *Development.* 126: 5759-5770, 1999.

27. Bohling, S. D., Wittwer, C. T., King, T. C., and Elenitoba-Johnson, K. S. J. Fluorescence melting curve-based analysis for the detection of the bcl-1/JH translocation in mantle cell lymphoma, *Lab Invest.* 79: 337-345, 1999.
28. Kelavkar, V. P., Cohen, C., Kamitani, H., Eling, T. E., and Badr, K. F. Concordant induction of 15-lipoxygenase-1 and mutant p53 expression in human prostate adenocarcinoma: correlation with Gleason staging, *Carcinogenesis.* 21: 1777-1787, 2000.
29. Kuhn, H., Heydeck, D., Brinckman, R., and Trebus, F. Regulation of cellular 15-lipoxygenase activity on pretranslational, translational, and posttranslational levels, *Lipids.* 34: S273-S279, 1999.
30. McKanna, J. A., Zhang, M. Z., Wang, J. L., Cheng, H., and Harris, R. C. Constitutive expression of cyclooxygenase-2 in rat vas deferens, *Am J Physiol.* 275: R227-33, 1998.

15-Lipoxygenase-2 (15-LOX-2) Is Expressed in Benign Prostatic Epithelium and Reduced in Prostate Adenocarcinoma

Scott B. Shappell,* William E. Boeglin,[†]
Sandy J. Olson,* Susan Kasper,[‡] and
Alan R. Brash[†]

From the Department of Pathology,* Division of Clinical Pharmacology, Department of Pharmacology,[†] and Department of Urology,[‡] Vanderbilt University School of Medicine, Nashville, Tennessee

Human 15S-lipoxygenase-2 (15-LOX-2) is a recently identified lipoxygenase that has approximately 40% sequence identity to the known human 5S-, 12S-, and 15S-lipoxygenases. 15-LOX-2 has a limited tissue distribution, with mRNA detected in prostate, lung, skin, and cornea, but not in numerous other tissues, including peripheral blood leukocytes. In the current study, we have characterized the distribution of 15-LOX-2 in the human prostate by immunohistochemistry, demonstrated the ability of benign prostate tissue to form 15S-hydroxyicosatetraenoic acid (15S-HETE) from exogenous arachidonic acid (AA), and begun characterizing possible alterations in 15-LOX-2 in prostate adenocarcinoma. Incubation of benign prostate tissue with [¹⁴C]AA resulted in formation of [¹⁴C]15-HETE, as determined by reverse- and straight-phase high-performance liquid chromatography. 15-HETE was the major AA metabolite formed. By immunohistochemistry, 15-LOX-2 is located in secretory cells of peripheral zone glands and large prostatic ducts and somewhat less uniformly in apical cells of transition and central zone glands. 15-LOX-2 was not detected in the basal cell layer, stroma, ejaculatory ducts, seminal vesicles, or transitional epithelium. Immunostaining of 18 radical prostatectomy specimens showed a loss of 15-LOX-2 in the majority of prostate adenocarcinomas; 14 of 18 cases showed loss of 15-LOX-2 in >25% of the tumor (mean, 74.9% negative for 15-LOX-2; range, 38.9% to 100%). Incubation of paired pure benign and pure malignant prostate tissue from the same radical prostatectomies showed that 15-HETE formation was markedly reduced (>90%) or undetectable in incubations of prostate adenocarcinoma. 15-LOX-2 is a novel human lipoxygenase with a limited tissue distribution that is strongly expressed in benign prostate glandular epithelium and lost to a variable degree in the majority of

prostate adenocarcinomas. (*Am J Pathol* 1999, 155:235-245)

Arachidonic acid (AA) metabolites are important mediators of a variety of physiological processes and inflammatory reactions. In addition, alterations in AA metabolism may potentially mediate key steps in certain neoplastic processes.¹⁻³ AA is metabolized via cyclooxygenase to prostaglandins, prostacyclin, and thromboxane,⁴ and via lipoxygenases (LOX) to hydroxyicosatetraenoic acids (HETEs) or leukotrienes (5-LOX pathway).^{5,6} Until recently, three lipoxygenases were recognized in humans: a 5S-LOX found in leukocytes, a 12S-LOX found in platelets and certain epithelia, and a 15S-LOX in reticulocytes, eosinophils, macrophages, and skin.⁷ Recently, in studying lipoxygenase expression in human skin, Brash et al⁸ discovered a second 15S-lipoxygenase (herein referred to as 15-LOX-2). The cDNA-derived amino acid sequence of 15-LOX-2 showed only 44% identity to 5-LOX and 38% to 39% identity to 12-LOX and the reticulocyte type of 15-LOX (herein referred to as 15-LOX-1).

In addition to structural differences, 15-LOX-2 exhibits differences in certain enzymatic characteristics. In contrast to the reticulocyte type of 15S-lipoxygenase (15-LOX-1), 15-LOX-2 converts AA exclusively to 15S-hydroperoxyicosatetraenoic acid (15-HPETE); this hydroperoxide is reduced by cellular peroxidases to 15S-hydroxyicosatetraenoic acid (15-HETE). Also unlike 15-LOX-1, this newly characterized enzyme metabolizes linoleic acid poorly compared with AA.⁸ The 15-LOX-2 cDNA was cloned from human hair roots.⁸ In addition, 15-LOX-2 mRNA was detected in a limited number of tissues, including prostate, lung, and cornea. In contrast to the distribution of 15-LOX-1, 15-LOX-2 was not detected in peripheral blood leukocytes, nor was it detected in liver, kidney, spleen, thymus, testis, ovary, skeletal muscle, heart, brain, or intestinal tissue.⁸

Supported in part by National Institutes of Health grant GM-53638 (A.R. Brash). S.B. Shappell is the recipient of a Department of Defense Prostate Cancer Research Program New Investigator Award (PC970260).

Accepted for publication March 20, 1999.

Address reprint requests to Dr. Scott B. Shappell, Department of Pathology, C-3322 Medical Center North, Vanderbilt University Medical Center, Nashville, TN 37221-2562. E-mail: scott.shappell@mcmail.vanderbilt.edu.

The limited tissue distribution of 15-LOX-2 suggests a possible role in regulation of organ-specific functions or differentiation or possible alterations in disease states. In continuing efforts to elucidate potentially important molecular alterations in prostate cancer development or progression, a limited number of recent investigations using both human tissues and prostate carcinoma cell lines have begun focusing on AA-metabolizing enzymes, including cyclooxygenase,⁹ 12-LOX,¹⁰ 5-LOX,¹¹ and 15-LOX-1.¹² In the current study, we have characterized the expression of 15-LOX-2 in benign prostate by immunohistochemistry, demonstrated the ability of benign prostate to form the enzymatic product of 15-LOX-2 (15-HETE) from AA, and begun exploring the possible altered expression of 15-LOX-2 and 15-HETE formation in prostate adenocarcinoma.

Materials and Methods

Case Selection and Histology

Fresh tissue was procured from radical prostatectomy or cystoprostatectomy specimens accessioned in the Surgical Pathology Laboratory at the Vanderbilt University Medical Center. For prostatectomies, the external aspects (surgical margins) were inked according to standard protocols and whole cross sections (perpendicular to the apex-base axis) were made. Based on gross examination, possible benign and tumor regions were separately excised in such a manner as to not compromise surgical pathological evaluation of the specimen. Fresh tissues were placed in liquid nitrogen or immediately placed in a -80°C freezer. Before utilization in enzyme assays, thin sections parallel to the longest axis of the tissue were removed, and frozen or routine formalin-fixed paraffin-embedded H&E-stained sections were prepared. The samples were assessed as to percentage of benign glandular, stromal, and adenocarcinoma tissue present. Although numerous samples of benign tissue were thus generated, owing to the known difficulty of recognizing prostate carcinoma grossly, only a subset of presumably malignant tissues so procured turned out to be 100% tumor. For enzyme assays, frozen normal tissue samples and pairs of pure benign glands and pure carcinoma admixed with stroma were used according to availability.

Whole-mount sections were processed for histology and subjected to standard surgical pathology evaluation. Cases that were used for AA incubations were also used for 15-LOX-2 immunohistochemistry. Additional random cases were selected to give a representative mixture of tumor grades with various combinations of organ-confined disease and extra-capsular extension (ECE) with or without seminal vesicle (SV) and margin involvement: five cases of Gleason grade 5 or 6 without ECE or SV involvement, three cases of Gleason grade 6 with ECE or SV involvement, four cases of Gleason grade 7 without ECE or SV involvement, three cases of Gleason grade 7 with ECE or SV involvement, and three cases of Gleason grade 8 to 10 with ECE or SV involvement. Numerous foci

of well differentiated carcinoma (Gleason patterns 1 and 2) were also included (generally incidental in transition zone).

Preparation of 15-LOX-2 for Antibody Production

cDNA encoding the open reading frame of 15-LOX-2 was cloned into the pET3a vector and expressed in phage-induced *Escherichia coli* (HMS174 cells). Ten milliliters of overnight culture of HMS174 cells transformed with pET3a/15-LOX-2 in LB medium containing 50 $\mu\text{g/ml}$ ampicillin was used to inoculate a fresh 500-ml culture of LB/ampicillin. Incubation was continued at 37°C until the absorbance at 600 nm reached 0.9 A. One hundred milliliters of phage culture (CE6, expressing T7 RNA polymerase) was then added together with 5 ml of 1 mol/L MgSO_4 , and incubation was continued for 3 hours at 37°C . Under these incubation conditions, overexpression of the 15-LOX-2 protein gave a catalytically inactive lipoxygenase, comprising 25% to 50% of the cellular protein. The bacterial pellets were collected by centrifugation, washed with phosphate-buffered saline (PBS), and resuspended in 40 ml of PBS, and the cells were disrupted by sonication. The insoluble fraction containing the majority of the lipoxygenase protein was collected by centrifugation and washed once with 1.5 mol/L NaCl followed by a wash with 1% Triton X-100 in PBS. The pellet was again washed in PBS, dissolved in 8 ml of loading buffer, and subjected to semipreparative sodium dodecyl sulfate polyacrylamide gel electrophoresis (SDS-PAGE) on 7.5% polyacrylamide gels with 4% stacking gels. The clearly visible band of 15-LOX-2 protein was cut from Coomassie-blue-stained gels, placed in a dialysis bag, and electroeluted. The protein was lyophilized, and an aliquot was quantified by its appearance on SDS-PAGE using bovine serum albumin as standard.

Preparation and Characterization of Polyclonal Antibody to 15-LOX-2

Rabbits were injected at six sites of back skin using an initial 0.1 mg of 15-LOX-2 per animal in 1:1 PBS/Freund's complete adjuvant. A booster injection of 0.1 mg using PBS/Freund's incomplete adjuvant was given 19 days later, and blood serum was collected beginning 14 days later. High-titer bleeds from a single rabbit were used for the Western analyses and immunohistochemistry reported herein.

The specificity of the rabbit antibody for 15-LOX-2 and possible cross-reactivity to other human lipoxygenases was examined by Western blotting using five human lipoxygenases. 15-LOX-1, 15-LOX-2, and 12R-LOX¹³ were prepared by bacterial expression, each including an amino-terminal histidine tag. The proteins were recovered using a nickel affinity column (Qiagen, Chatsworth, CA) essentially according to the manufacturer's instructions. Purified human 5-lipoxygenase was a generous gift from Dr. Denis Reindeau (Merck-Frosst). Aliquots of these four

lipoxygenase proteins were run on SDS-PAGE, and after staining with Ponceau S, the samples were quantified by visual inspection relative to dilutions of a standard of bovine serum albumin. Aliquots of 50 or 5 ng were used for Western analysis. A partially purified preparation of human platelet 12-lipoxygenase from Oxford Biomedical Research (Oxford, MI) was used as a source of human 12S-LOX (platelet 12-LOX). For Western blots employing 5 ng of purified lipoxygenases, 8 μ g of protein of the partially purified 12S-LOX was used, which, assuming the 12-LOX comprises at least 0.1% of the extract, corresponds to at least 8 ng of 12S-LOX protein. Adequate protein loading of this sample was further confirmed by staining of gels and visual inspection. Proteins were separated by 12% SDS-PAGE electrophoresis and transferred to nitrocellulose membranes using standard conditions.

The Western analyses were carried out using 15-LOX-2 polyclonal antibody (1:6000) and an alkaline-phosphatase-conjugated affinity-purified donkey anti-rabbit IgG (Jackson ImmunoResearch, West Grove, PA; 1:7500 in bovine serum albumin/Tris-buffered saline/0.1% Tween-20) and Tris-buffered levamisole (Sigma Chemical Co., St. Louis, MO) followed by nitroblue tetrazolium/5-bromo-4-chloro-3-indolylphosphate for development.¹⁴

Immunohistochemistry and Quantitation of 15-LOX-2 Immunostaining

Whole-mount sections that contained adequate benign tissue and tumor typical of the overall specimen were selected. In general, both right and left halves of the respective whole-mount sections were recut onto separate immuno-slides for subsequent immunohistochemical staining. In some cases, multiple whole-mount blocks were used for immunostaining. Paraffin immunoperoxidase studies were performed using a 1:2500 dilution of either primary rabbit antisera for 15-LOX-2 or preimmune sera on an automated immunostainer (Ventana 320 automated immunohistochemistry system, Ventana Medical Systems, Tucson, AZ) with an avidin-biotin complex method without antigen retrieval techniques.¹⁵ 15-LOX-2 immunostaining in benign prostate tissue was uniform and is expressed descriptively or semiquantitatively as 0 to 4+: 0, no staining; 1+, focal weak staining; 2+, weak to moderate intensity staining in up to one-half of the cells in most glands or most cells in up to one-half of the glands; 3+, moderate to intense staining in greater than one-half of the cells or one-half of the glands but less than strong, uniform staining; 4+, strong uniform staining in essentially all cells. 15-LOX-2 immunostaining was quantitated in tumor portions by carefully mapping out with ink on the glass slides the areas of tumor that were positive and negative and then by making enlarged photocopies of such outlines. Areas were determined using a digitized graphics tablet (WACOM) and NIH Image Analysis software. Results are expressed as the percentage of tumor negative for 15-LOX-2 immunostaining.

Tissue Incubations and HPLC Analysis

A 50- to 100-mg amount of benign or tumorous prostate tissue was homogenized in 4 vol of buffer (50 mmol/L Tris with 100 mmol/L NaCl and 100 μ mol/L CaCl_2 , pH 7.4). Incubations were begun by addition of 50 μ mol/L [$1\text{-}^{14}\text{C}$]arachidonic acid (final concentration; New England Nuclear, Boston, MA) in $\leq 1\%$ (final v/v) ethanol. Samples were incubated for 1 hour at 37°C with continual agitation and terminated by addition of 2.5 vol of cold methanol. After addition of 1.25 vol of dichloromethane, the sample was centrifuged to remove the protein precipitate, and the products were recovered in the mixed phase of methanol/water/dichloromethane. The sample was evaporated under a stream of nitrogen to remove most of the dichloromethane and methanol, water was added, and the products were recovered by C18 Sep-Pak extraction.⁸ The extracts were analyzed by reversed-phase HPLC using a Beckman Ultrasphere 5- μ m ODS column (25 \times 0.46 cm) with a solvent of methanol/water/glacial acetic acid, either 90:10:0.01 (by volume) at a flow rate of 1.1 ml/minute (retention time of 15-HETE was approximately 5 minutes) or 80:20:0.01 at 1.1 ml/minute (retention time of 15-HETE approximately 15 minutes). Unlabeled HETEs (5-, 8-, 9-, 11-, 12-, and 15-HETEs) were added to each sample before HPLC analysis; this permitted an exact determination of the retention times of each HETE product within each individual chromatographic run. Ultraviolet (UV) spectra and the profiles at 205, 220, 235, and 270 nm were recorded using a Hewlett-Packard 1040A diode array detector, and radioactivity was monitored on-line using a Radiomatic Instruments Flo-One detector. Product formation in some incubations of benign and malignant prostate tissue pairs was also analyzed in more detail using reverse-phase HPLC with a solvent system of methanol/water/glacial acetic acid (75:25:0.01, by volume) at a flow rate of 1.01 ml/minute (retention time of 15-HETE approximately 31.5 minutes), with collection of 0.5-minute fractions and 10-minute scintillation counting of all fractions. In some samples, the main radiolabeled peaks were further characterized by normal-phase HPLC using a Beckman Ultrasphere 5- μ m silica column (25 \times 0.46 cm) and a solvent of hexane/isopropyl alcohol/glacial acetic acid 100:1:0.1 (by volume) at a flow rate of 1.1 ml/minute with UV detection using the diode array detector and on-line radioactive detection.

Results

15-HETE Formation by Benign Prostate Tissue

Incubations of benign prostate tissue homogenates with [^{14}C]AA resulted in the formation of 15-HETE in all cases examined ($n = 8$; Figure 1). Identity of this product was demonstrated by its precise co-elution on reverse-phase HPLC (and on straight-phase HPLC in selected samples) with co-injected unlabeled 15-HETE (see Materials and Methods). The addition of a mixture of unlabeled HETEs to each sample allowed an exact definition of the reten-

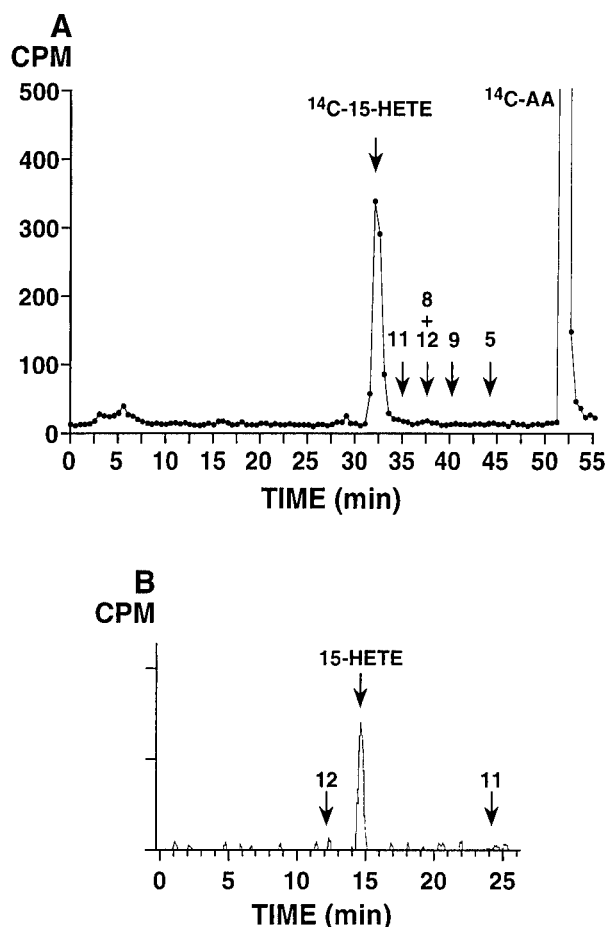


Figure 1. [^{14}C]AA metabolism in benign prostate tissue, showing prominent formation of [^{14}C]15-HETE. **A:** Reverse-phase HPLC analysis using a Beckman Ultrasphere 5- μm ODS column (25 \times 0.46 cm) with a solvent of methanol/water/glacial acetic acid (75:25:0.01, by volume) at a flow rate of 1.01 ml/minute switched to 100% methanol at 40 minutes; 0.5-minute fractions were collected and subjected to scintillation counting. **Arrows** show retention times of unlabeled HETE standards co-injected with the ^{14}C sample. The experiment shown is representative of eight individual benign specimens analyzed. **B:** Normal-phase HPLC analysis of fractions 63 through 66 (31.5 to 33 minutes) from reverse-phase analysis in **A**, using a Beckman Ultrasphere 5- μm silica column (25 \times 0.46 cm), a solvent system of hexane/isopropanol/glacial acetic acid (100:1:0.1, by volume) with a flow rate of 1.1 ml/minute and on-line detection of radiolabeled products using a Packard Flo-One Radiomatic detector. **Arrows** indicate retention times of co-injected unlabeled HETE standards.

tion times within each chromatographic run. The identity of the radiolabeled product as 15-HETE was further confirmed by the characteristic UV spectrum of the mixture of [^{14}C]15-HETE and the co-injected authentic standard¹⁶; the UV absorbance of the 15-HETE peak was distinctly elevated by the contribution from the [^{14}C]15-HETE. The amount of 15-HETE produced under these incubation conditions was variable. However, in all cases, 15-HETE was the major product detected, with variably sized peaks in the prostaglandin region (Figures 1 and 3). From analysis of these eight samples of benign prostate, minor amounts of other hydroxyeicosatetraenoates were occasionally detected; the most prominent of these additional HETE peaks, present in only one sample, was the one, tentatively identified as 12-HETE, eluting at 36 minutes in Figure 3B.

15-LOX-2 Immunostaining in Benign Prostate

The polyclonal antibody prepared against purified 15-LOX-2 was demonstrated to be specific for 15-LOX-2 and to not cross-react with other pertinent lipoxygenases by Western blotting. Whereas a strong immunoreactive band was obtained with purified 15-LOX-2 protein (5 ng), no immunoreactivity was seen with purified 15-LOX-1 or 5-LOX (5 or 50 ng) or a sample of partially purified 12S-LOX (not shown). Weak immunostaining was seen with a purified preparation of a recently identified 12*R*-LOX,¹³ which may be expected, given the greater percentage of identity between 15-LOX-2 and 12*R*-LOX (approximately 50%) than between 15-LOX-2 and 5-LOX, 12S-LOX, and 15-LOX-1 (approximately 40%).^{8,13} However, unlike 12S-LOX, which has been reported in prostate (see Discussion), 12*R*-LOX has not been identified in prostate. Hence, minimal cross-reactivity of a 15-LOX-2 antibody with a 12*R*-LOX is not an issue in prostate immunostaining, as benign prostate makes large amounts of 15-HETE (as reported herein), and prostate has not been observed to make 12*R*-HETE.

The cellular location of 15-LOX-2 was identified as ductal and acinar epithelium by immunohistochemistry. Benign prostatic epithelium consistently stained strongly and uniformly with the polyclonal antiserum against human 15-LOX-2 by paraffin immunoperoxidase (Figure 2A). Stromal, vascular, and inflammatory cells were uniformly negative (Figure 2B). The distribution of immunostaining was carefully examined in the benign portions of prostate sections from radical prostatectomies performed for prostate adenocarcinoma. There was strong uniform staining of apical (secretory) cells in peripheral zone glands, with essentially all cells staining in all glands (Figure 2, A and C). The pattern of staining was predominantly cytoplasmic granular, with frequent nuclear staining also evident (Figure 2C). Occasional detached cells in glandular and ductal lumens showed immunostaining, but corpora amylacea were negative. Basal cells did not stain (Figure 2C); this lack of staining was evident also in areas of basilar hyperplasia (not shown). Strong uniform 15-LOX-2 immunostaining was present in columnar secretory cells of large periurethral ducts and secondary prostatic ducts (Figure 2, D and E). In contrast, transitional epithelium of the prostatic urethra, periurethral ducts, and areas of transitional metaplasia was completely negative (Figure 2E).

Some variability in the intensity and extent of prostate glandular epithelial staining was noted in different anatomical zones and benign histological alterations. Although most glands in the transition zone showed moderately intense staining in the majority of cells, staining was appreciably less uniform and less intense than seen in peripheral zone glands (Figure 2F). This slightly reduced 15-LOX-2 immunostaining was noted in variably prominent nodules of transition zone glandular hyperplasia (the histological correlate of benign prostatic hyperplasia, or BPH), including in cystically dilated hyperplastic glands. In general, staining was stronger in glands in the periphery of such nodules, with lesser staining, including negative glands, in the center of hyperplastic

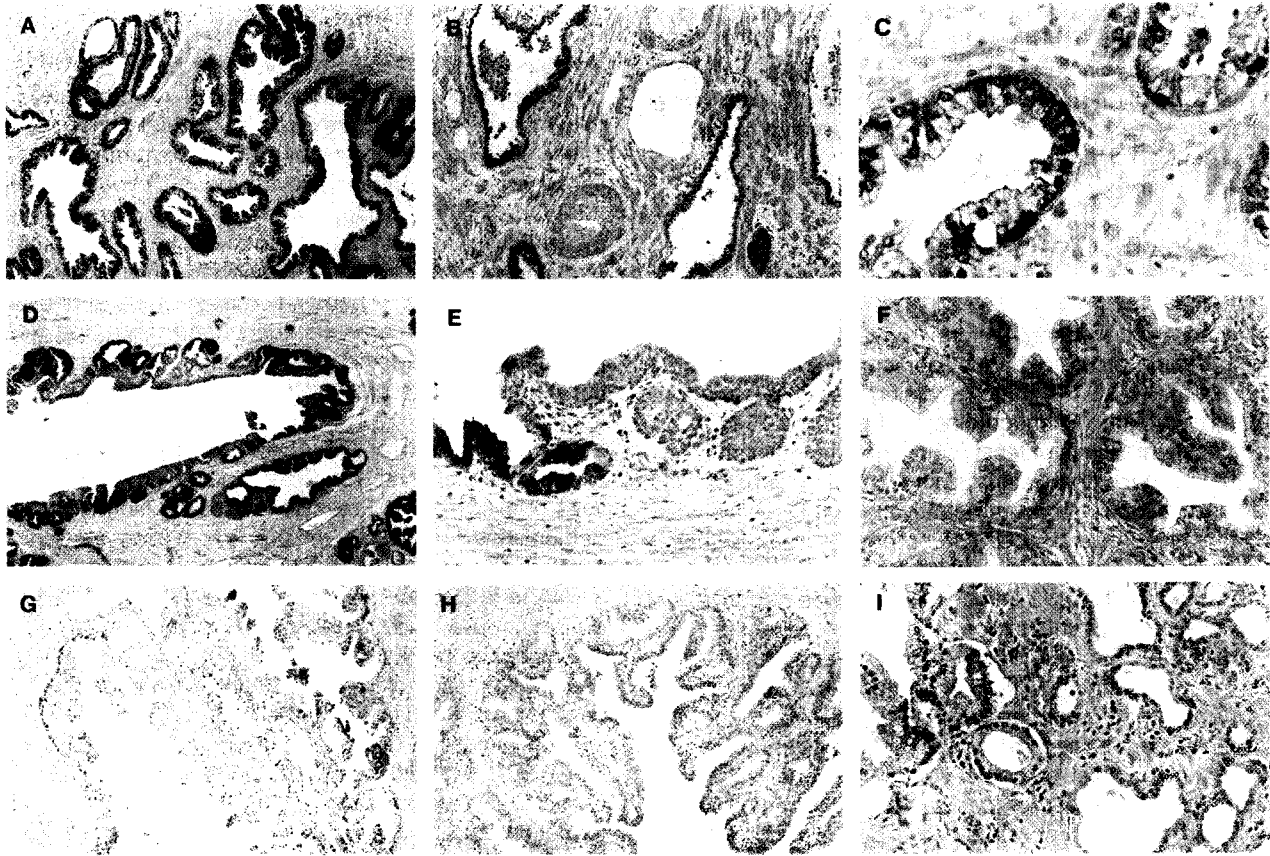


Figure 2. 15-LOX-2 immunostaining in benign prostate. **A:** Uniform strong staining of glandular epithelium (original magnification, $\times 200$). **B:** Absent immunostaining in vein and artery (middle), fibromuscular stroma, and admixed chronic inflammatory cells. Strong staining of glands in right and left of field ($\times 100$). **C:** Higher magnification showing cytoplasmic granular and focal nuclear staining of apical (secretory) epithelial cells ($\times 400$). **D:** Staining of secretory cells in large prostatic duct ($\times 100$). **E:** Higher magnification showing positive staining in columnar secretory cells (left) and lack of staining in transitional epithelium (right) of prostatic duct ($\times 200$). **F:** Non-uniform and reduced intensity staining in hyperplastic glands in transition zone ($\times 200$). **G:** Focal staining of glands in central zone (region around ejaculatory ducts toward base of gland; $\times 100$). **H:** Complete absence of staining of ejaculatory duct (lumen toward lower right; $\times 100$). **I:** Absent staining in atrophic glands (right). Compare with positive immunostaining of more normal-appearing glands, with ample cytoplasm, in left of photomicrograph ($\times 200$). Paraffin immunoperoxidase staining using rabbit polyclonal anti-15-LOX-2, 1:2500.

nodules. Compared with the completely uniform strong staining in essentially all peripheral zone glands, benign glands in the central zone (surrounding the ejaculatory ducts) also showed slightly reduced intensity and frequency of 15-LOX-2 immunostaining (Figure 2G). Ejaculatory ducts and seminal vesicles were uniformly negative (Figure 2H). Reduced and even absent immunostaining was also noted in atrophic glands in the peripheral zone (Figure 2I), with intermediate staining intensity occasionally noted in partially atrophic glands. No immunostaining was detected in any glandular elements (or any other tissue compartment) with negative preimmune serum

controls ($n = 5$; data not shown). In addition, staining of benign prostate glands was eliminated by preincubation of antisera with purified 15-LOX-2 protein⁸ (not shown). A summary of the semiquantitative 15-LOX-2 immunohistochemical staining in benign prostate is shown in Table 1.

Decreased or Absent 15-LOX-2 Enzyme Activity in Prostate Adenocarcinoma

15-LOX-2 activity was assessed in benign prostate tissue and prostate adenocarcinoma frozen from the same rad-

Table 1. 15-LOX-2 Immunostaining in Benign Prostate

Prostate compartment	15-LOX-2 Immunostaining (0-4+)	Number of informative cases
Peripheral zone glands	4+	18
Atrophic glands	0-2+	9
Transition zone glands (BPH)	2+	7
Central zone glands	2-3+	4
Periurethral/prostatic ducts*	4+	7
Stroma and inflammatory cells	0	18
Transitional epithelium; ejaculatory ducts; seminal vesicles	0; 0; 0	6; 4; 5

*Columnar/secretory (not transitional) epithelial cells.

ical prostatectomy specimens. In all benign samples, incubation with [14 C]AA resulted in formation of 15-HETE as detected by reverse-phase HPLC analysis. In contrast, markedly reduced or no 15-HETE production was detected in simultaneously incubated samples of prostate adenocarcinoma ($n = 3$; Figure 3).

Reduced 15-LOX-2 in Prostate Adenocarcinoma by Immunohistochemistry

In contrast to the strong, uniform 15-LOX-2 immunostaining in benign prostate glands (particularly in the peripheral zone), 15-LOX-2 immunostaining was markedly reduced in prostate adenocarcinoma (Figure 4). 15-LOX-2 immunostaining was at least focally absent in essentially all tumors, with the vast majority showing substantial portions of tumor that were negative on immunostaining. In 14 of 18 cases, 15-LOX-2 was absent in more than 25% of the tumor examined by immunohistochemistry. In these cases, 15-LOX-2 immunostaining was negative in $74.9 \pm 24.4\%$ of the tumor. 15-LOX-2 was absent in $>50\%$ of the tumor in 10 of 18 cases and essentially completely absent in 8 of 18 of the tumors.

Correlation of reduced 15-LOX-2 with other known prognostic factors in prostate cancer, such as grade and stage, and clinical outcome will require analysis of a much larger number of cases, which currently is in progress. However, possible correlation of reduced 15-LOX-2 immunostaining with increased tumor grade or biological aggressiveness was indicated in several individual cases. In one case of a Gleason 3 + 3 = 6 adenocarcinoma with absent immunostaining in greater than one-half of the tumor assessed by immunohistochemistry, there was strong residual 15-LOX-2 immunopositivity in a Gleason pattern 2 tumor focus in the transition zone (Figure 4, C and D). In two cases of overall Gleason 7 adenocarcinoma (one 3 + 4 and one 4 + 3), areas of Gleason pattern 2 and 3 were 15-LOX-2 immunopositive, whereas other areas of Gleason patterns 3 and 4 were negative, including in one case areas where the tumor was penetrating beyond the prostate capsule (Figure 4, E-G). These two cases were among those assessed by HPLC, the tumor tissue for which was taken from the posterior peripheral zone (see also Figure 5, A and B). Lack of 15-HETE formation from this tumor tissue likely correlates with the reduced 15-LOX-2 immunostaining in more peripheral (and higher-grade) portions of the tumor. Another example of possible tumor heterogeneity with regard to 15-LOX-2 expression was seen in a case with a mixed ductal and acinar pattern. Whereas the more peripherally located acinar carcinoma was largely 15-LOX-2 immunopositive, the more centrally located ductal carcinoma was negative (Figure 4, H and I). Examples of the degree of heterogeneity of loss of 15-LOX-2 immunostaining within individual tumors are shown in Figure 5, in which parts A-C correspond to the tumor cases analyzed by HPLC (as shown in Figure 3). Figure 5D shows an extreme example of the multifocal or heterogeneous nature of 15-LOX-2 negativity seen in some cases with only partial loss of 15-LOX-2 immunostaining.

Discussion

As discussed more fully below, there have been a few previous reports on the occurrence of AA-metabolizing enzymes in benign prostate and prostatic neoplasia. These include the arachidonate 5-lipoxygenase,¹¹ 12-lipoxygenase,¹⁰ and reticulocyte type of 15-lipoxygenase (15-LOX-1).¹² In this study we have used assays of enzyme activity and immunohistochemistry to document expression of the recently described 15-lipoxygenase enzyme 15-LOX-2⁸ in benign human prostate epithelium and its reduction in prostate adenocarcinoma. One clear advantage of the methodological approach in our study is the ability to correlate enzyme protein with actual functional activity.

Characterization of the 15-lipoxygenase metabolism and its designation as 15-LOX-2 is based on the following lines of evidence. 1) Previous multitissue Northern blots demonstrated 15-LOX-2 mRNA expression in benign prostate,⁸ and we have recently detected 15-LOX-2 mRNA in individual benign prostates on Northern Blots (S. B. Shappell, unpublished observations). 2) Analysis of lipoxygenase product formation by HPLC identifies the specific formation of 15-HETE in all of our incubations of benign prostate. Typically, the reticulocyte type of 15-lipoxygenase, 15-LOX-1, forms a mixture of 15-HETE and 12-HETE,¹⁷ whereas 15-LOX-2 oxygenates AA solely at C-15.⁸ In our experiments the characteristics of 15-HETE formation matched the catalytic activities of 15-LOX-2 (eg. Figure 1 and Figure 3, A and C). The exception, when both 12- and 15-HETE formation was evident (Figure 3B), might be accounted for by co-expression of 12-LOX and a 15-lipoxygenase. 3) An additional feature of the 15-lipoxygenase metabolism in prostate, again characteristic of 15-LOX-2, was the greater formation of 15-HETE from AA than of 13-hydroxyoctadecadienoic acid (13-HODE) from linoleic acid in side-by-side incubations of the same benign prostate tissue (not shown); this correlates with the substrate specificity of 15-LOX-2⁸ and contrasts with the known preference of 15-LOX-1 for linoleic over arachidonic acid.¹⁸ 4) The antibody used in the current immunohistochemical studies specifically detects 15-LOX-2 and does not cross-react with 15-LOX-1,¹⁹ 12S-LOX, or 5-LOX (results herein). Furthermore, there was complete suppression of the positive reactions in the immunohistochemical staining by pre-absorption with purified 15-LOX-2 protein. The specificity of our antibody for 15-LOX-2 versus 15-LOX-1 was also supported by the staining of the prostatic epithelium with concomitant lack of staining of inflammatory cells, including macrophages, which might be expected to stain for 15-LOX-1.²⁰ Although inflammation was variable and generally mild in the sections examined, one benign prostate examined by both enzyme assay and immunostaining was a cystoprostatectomy specimen containing granulomatous inflammation secondary to previous BCG instillation therapy for bladder transitional cell carcinoma. In addition to formation of large amounts of 15-HETE on incubation of this prostate tissue with AA, by immunohistochemistry, the anti-15-LOX-2 antibody uniformly stained benign prostate epithelium but did not stain the

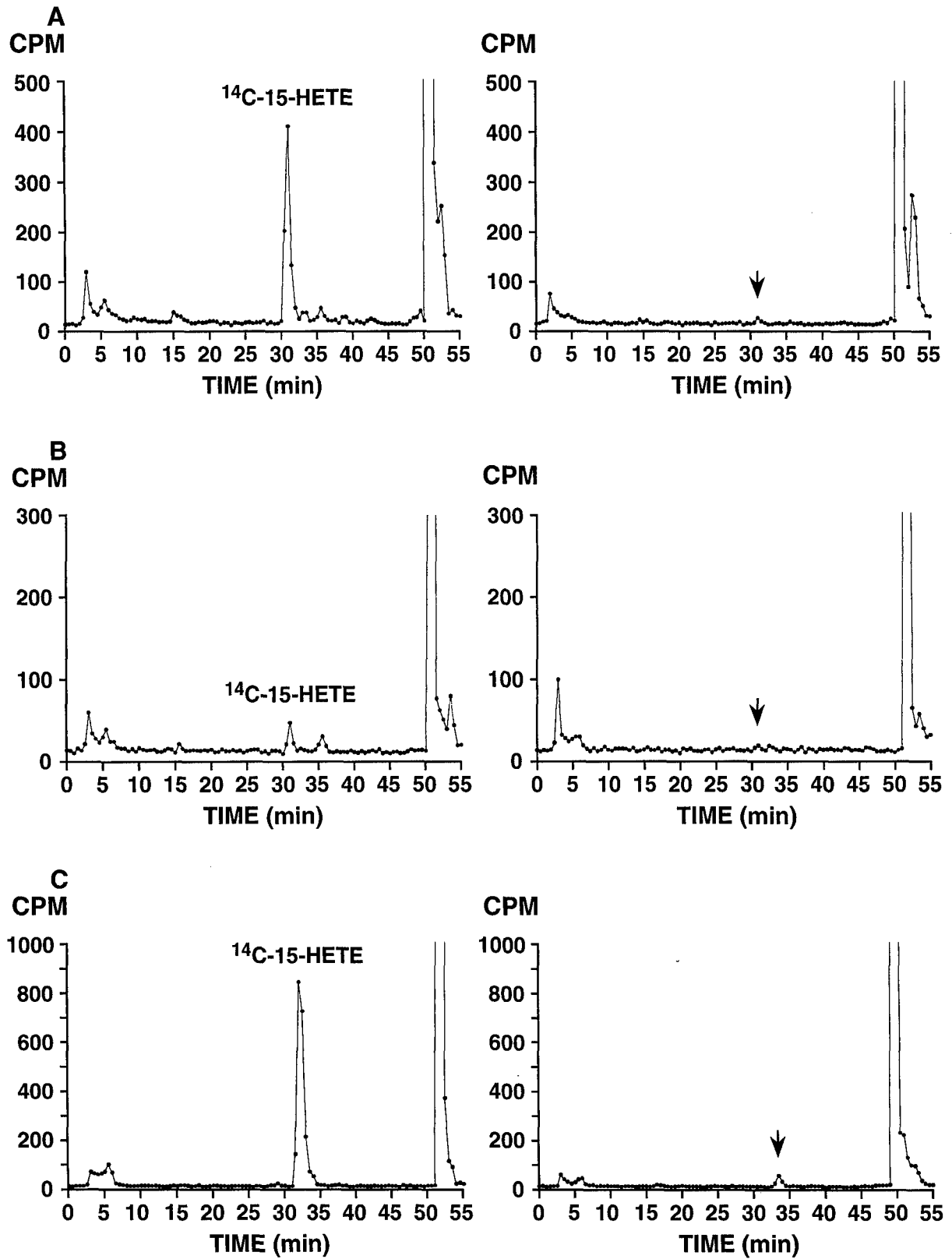


Figure 3. 15-HETE formation by benign (left) and malignant (right) prostate tissue from three different radical prostatectomy specimens. A: Benign and Gleason grade 3 + 4 = 7, with extra-capsular extension; B: Benign and Gleason grade 4 + 3 = 7, confined to prostate; C: Benign and Gleason grade 3 + 2 = 5, confined to prostate (with incubated tumor tissue from Gleason pattern 3 tumor in peripheral zone). Incubation with [14 C]AA and extraction were performed as described in Materials and Methods. Product analysis was by reverse-phase HPLC using a Beckman Ultrasphere 5- μ m ODS column (25 \times 0.46 cm) with a solvent of methanol/water/glacial acetic acid (75:25:0.01, by volume) at a flow rate of 1.01 ml/minute switched to 100% methanol at 40 minutes; 0.5-minute fractions were collected and subjected to scintillation counting. [14 C]15-HETE peaks are indicated in benign incubations and arrows corresponding to substantially reduced or undetected [14 C]15-HETE in tumor incubations based on retention time of unlabeled HETE standards co-injected with 14 C samples.

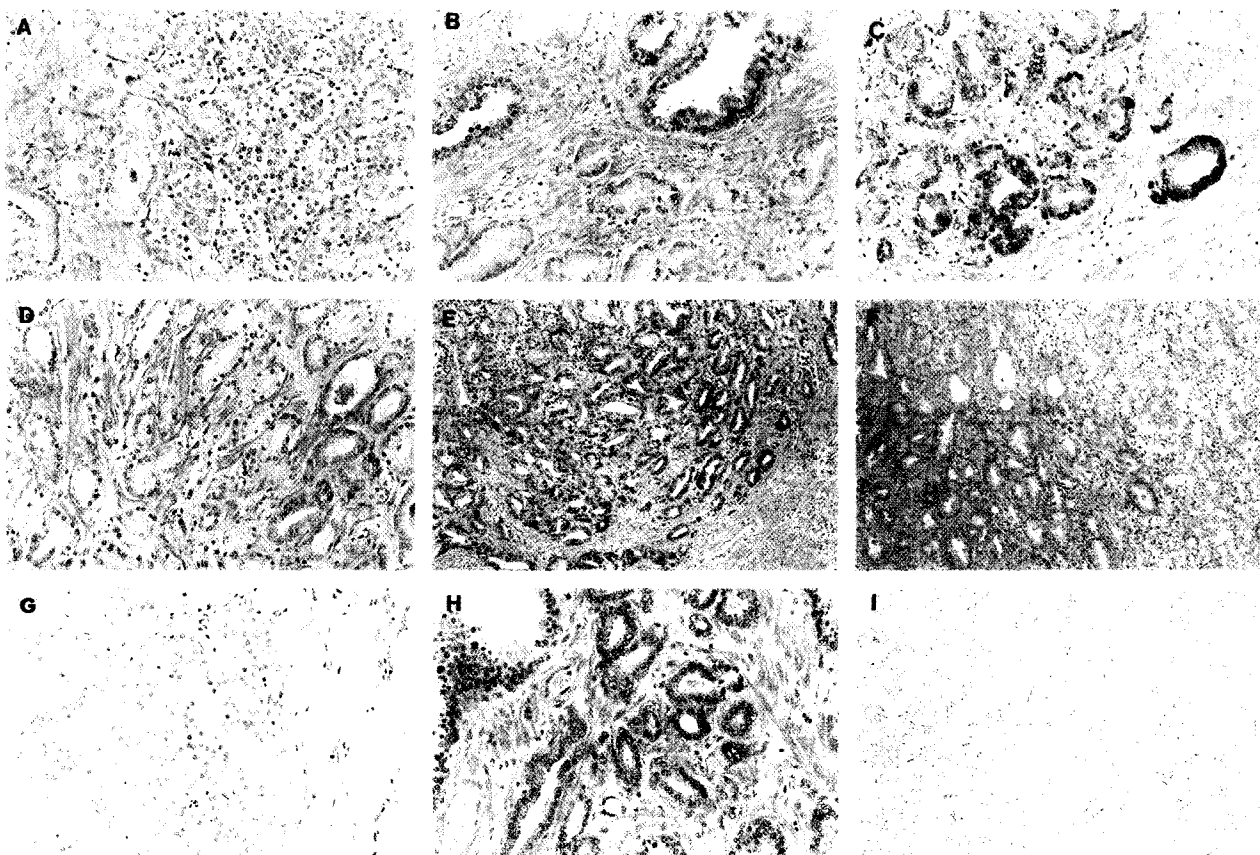


Figure 4. Reduced 15-LOX-2 immunostaining in prostate adenocarcinoma. **A:** Absent immunostaining in adenocarcinoma, from tumor that was overall 39% negative for 15-LOX-2 immunostaining (original magnification, $\times 200$). **B:** Absent 15-LOX-2 immunostaining in adenocarcinoma, bottom, compared with strong staining in adjacent benign glands (top), from a case in which most of the tumor was higher grade than that illustrated and in which the tumor was overall 94% 15-LOX-2 negative ($\times 200$). **C:** Strong 15-LOX-2 immunostaining in Gleason pattern 2 tumor in transition zone ($\times 200$). **D:** Markedly reduced and absent 15-LOX-2 immunostaining in Gleason pattern 3 adenocarcinoma from same case as **C**, which was overall 58.8% 15-LOX-2 tumor negative ($\times 200$). **E:** Positive 15-LOX-2 immunostaining in transition zone Gleason pattern 2 adenocarcinoma ($\times 100$). **F:** Transition between focal weakly positive adenocarcinoma, left, and 15-LOX-2 negative tumor, right, in Gleason pattern 3 and transition to area of Gleason pattern 4, respectively, from same case as **E** ($\times 100$). **G:** 15-LOX-2-negative adenocarcinoma in area of extracapsular extension, from same case as in **E** and **F**, which was overall Gleason 3 + 4 and 44.2% 15-LOX-2 tumor negative ($\times 200$). **H:** Positive 15-LOX-2 immunostaining in acinar adenocarcinoma from case of mixed ductal and acinar tumor ($\times 200$). **I:** Negative 15-LOX-2 immunostaining in ductal adenocarcinoma, same case as in **H**, which was overall 45% 15-LOX-2 tumor negative ($\times 100$).

large numbers of histiocytes (macrophages) forming the granulomas (not shown).

Few studies have examined the possible significance of AA metabolism or the presence of cyclooxygenase or lipoxygenase enzymes in benign prostate and prostatic neoplasia. Chaudry et al⁹ reported prostaglandin E₂ (PGE₂) synthesis to be 10-fold higher in carcinoma tissue compared with benign prostatic hyperplasia (BPH) tissue. Whether the enzymes responsible for PGE₂ synthesis were epithelial, stromal, or vascular was not elucidated. Increased formation of PGE₂ has been demonstrated previously in human cancer cell lines, including human prostate cancer cell lines.²¹

More recently, multiple reports have described the presence of lipoxygenase enzymes in prostate cancer and prostatic carcinoma cell lines. Gao et al¹⁰ reported that 12-lipoxygenase (12-LOX) mRNA was elevated in 46 of 122 (38%) prostate tumor samples compared with normal tissue from the same patient. They found that 12-LOX mRNA was more likely to be elevated in tumor versus control tissue in patients with extracapsular extension (T3), positive lymph nodes, higher-grade lesions

(Gleason score ≥ 8), and positive surgical margins. By *in situ* hybridization they detected 12-LOX mRNA within epithelial cells of the prostate, including basal cells of normal prostate tissue. Secretory cells were generally negative in normal tissue. This basal cell distribution of 12S-LOX in benign prostate tissue contrasts with the apical cell distribution of 15-LOX-2 in benign prostate demonstrated by immunohistochemistry herein. In contrast to benign glands, Gao et al reported that tumor epithelial cells demonstrated heterogeneous and occasionally marked expression of 12-LOX mRNA.¹⁰ Biological effects of 12-HETE include promotion of tumor cell adhesion and endothelial cell contraction, indicating a potential contribution to tumor cell metastasis^{2,22,23} and possible modulation of tumor growth by induction of angiogenesis.²⁴ 12-LOX enzyme activity has not been reported in actual prostate tissues or prostate cancers, however. We did not observe detectable 12-HETE accumulation in most incubations of benign prostate tissue with exogenous arachidonic acid. We also did not observe 12-HETE formation in similar incubations with prostate adenocarcinoma. However, although the cases ex-

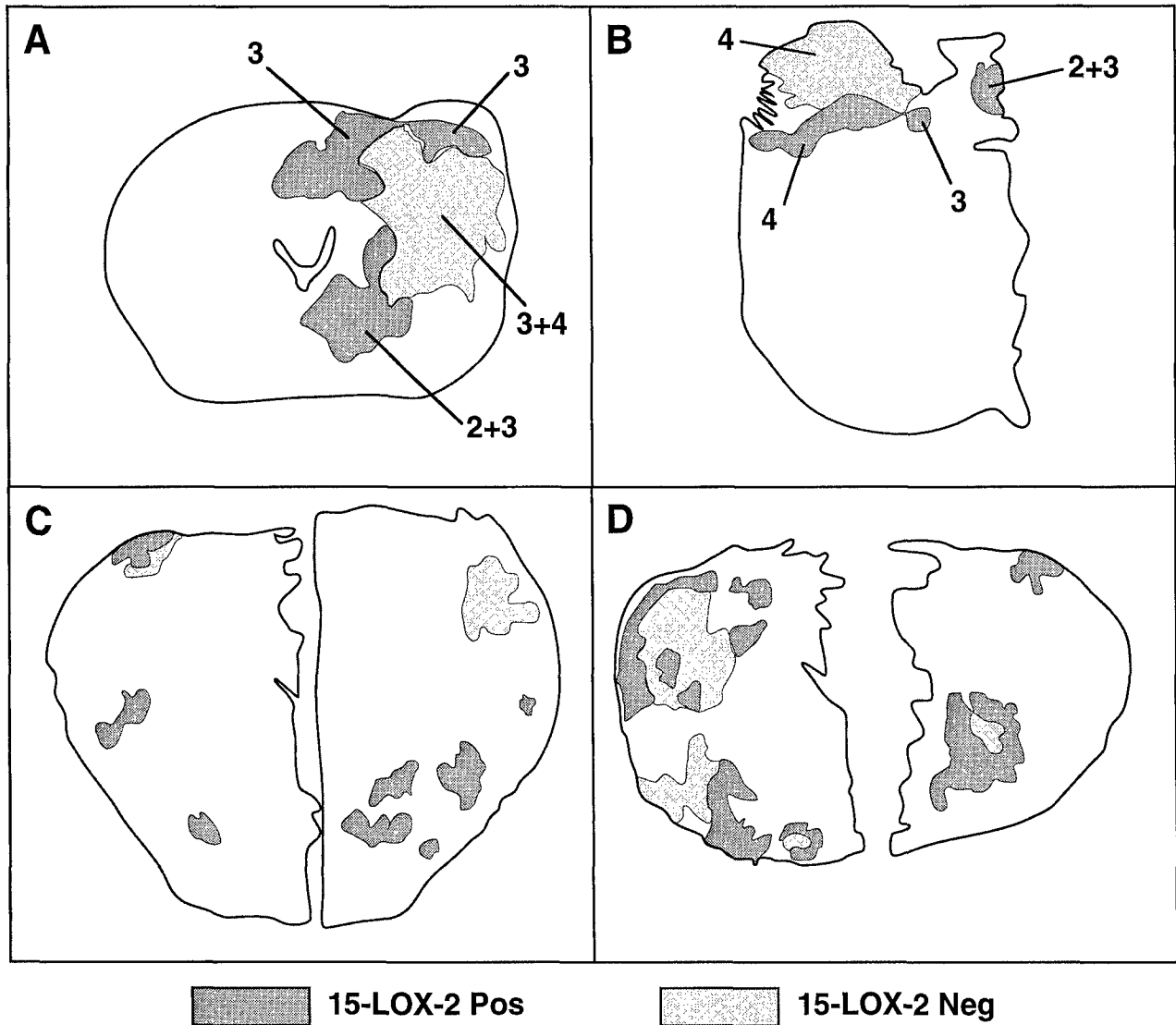


Figure 5. Heterogeneity of absent 15-LOX-2 immunostaining in prostate tumors. Immunostained entire whole-mount sections or right and/or left halves from four representative cases are outlined, with posterior toward top of figure. Benign glands stained uniformly, and stroma was negative as described in Results. Shaded outlines correspond only to actual tumor portions, with positive staining in dark gray and absent immunostaining areas in lighter shade. Numbers correspond to Gleason pattern of indicated areas (in tumors with more than one pattern). A through C correspond to cases A through C in Figure 3 (in which portions were also examined by HPLC assay). A: Gleason 3 + 4 = 7, overall 44.2% 15-LOX-2 negative. B: Gleason 4 + 3 = 7, overall 60.6% 15-LOX-2 negative. C: Gleason 3 + 3 = 6, overall 40% 15-LOX-2 negative. D: Gleason 3 + 3 = 6, overall 45% 15-LOX-2 negative.

amined for 15-LOX-2 immunostaining included multiple examples of high-grade (Gleason ≥ 8) and T3 carcinoma, only one of the cases examined by HPLC was positive for extracapsular extension (T3), and none had positive surgical margins or lymph node metastases. Hence, the possibility of detecting 12-HETE formation and possible simultaneous decreased 15-HETE and increased 12-HETE formation under the experimental conditions used will require examination of higher-grade and higher-stage lesions.

A possible role for 5-LOX in modulation of growth of the prostate cancer cell line PC-3 was reported by Ghosh and Myers.¹¹ Arachidonic acid stimulated PC-3 cell growth, which was inhibited by selective 5-LOX inhibitors but not by 12-LOX or cyclooxygenase inhibitors. Furthermore, 5-HETE was produced from exogenous AA in PC-3

cells.¹¹ More recently, these investigators and others have demonstrated induction of apoptosis in PC-3 and LNCaP cell lines by inhibitors of 5-LOX and 5-LOX-activating protein (FLAP).^{25,26} Again, we did not observe 5-HETE production from exogenous AA in benign prostate or a limited number of fresh-frozen prostate tumors. Given the known chromosomal and other possible genetic abnormalities of established prostate carcinoma cell lines, whether AA metabolic pathways in these cultured cells generated from individual tumors reflect similar alterations in actual cancers *in vivo* will require correlative studies, with analysis of high-grade and high-stage cancers, perhaps including metastatic tumors.

Spindler et al¹² recently provided evidence for a possible 15-lipoxygenase in the human prostate cancer cell lines LNCaP and PC-3, which they indicated as the same

as the rabbit reticulocyte 15-lipoxygenase (designated herein as 15-LOX-1). These findings may require re-evaluation in light of the recent discovery of 15-LOX-2. However, based on the evidence we have obtained in human prostate cancer samples, transformed prostate carcinoma cell lines, such as LNCaP and PC-3 cells, would not be expected to express 15-LOX-2. The reported detection of 13-HODE in a single specimen of human prostate carcinoma by frozen-section immunohistochemistry (and its absence in surrounding benign epithelium)¹² does not correlate with the patterns of 15-LOX-2 expression observed in the series of samples we have examined, although 15-LOX-2 was still present to some degree by immunohistochemistry in a significant percentage of tumor cases. Certainly the origins of immunodetectable 13-HODE in tumor tissue might include its production through non-enzymatic mechanisms.

The biological significance of 15-LOX-2 expression in benign prostatic epithelium is not clear. The uniform expression in prostate apical or secretory cells suggests a possible role of this novel enzyme in secretory function. Reduced expression in atrophic prostate glands and prostate adenocarcinoma may thus parallel less secretory differentiation. However, given our demonstration of the loss of this protein and its associated enzymatic activity in prostate carcinoma, it is possible that reduction or loss of 15-LOX-2 and 15-HETE formation is a crucial event in the development or progression of prostate adenocarcinoma. In this regard, it is noteworthy that the murine homologue of 15-LOX-2, a recently identified 8S-lipoxygenase (8-LOX), is up-regulated in benign squamous papilloma of mouse skin induced by phorbol ester treatment and lost with progression to frank squamous cell carcinoma with additional treatments.^{19,27} It is possible that the products of these related enzymes (15S-HETE and 8S-HETE, respectively) regulate aspects of cellular proliferation or differentiation and that the loss of this function is associated with development or progression of a malignant phenotype. The recent description of the activation of transcription-regulating PPAR receptor subtypes (peroxisome proliferator-activated receptors) by various AA-related products, including HETEs, indicates one potential mechanism of action.²⁸⁻³¹ This is a particularly intriguing hypothesis in light of the evidence that the synthetic activators of PPAR, the aromatic fatty acids phenyl acetate and phenyl butyrate, inhibit prostate cancer cell line growth *in vitro* and show activity against hormone-insensitive prostate cancer *in vivo*.³²⁻³⁴ More recently, Kubota et al³⁵ demonstrated expression of PPAR γ in PC-3, DU-145, and LNCaP cells and inhibition of PC-3 cell proliferation by PPAR γ ligands, including the thiazolidinedione troglitazone and 15-deoxy- $\Delta^{12,14}$ -prostaglandin J₂. The recent demonstration of activation of PPAR γ -dependent transcription by a variety of oxidized lipids, including specifically 15-HETE,³⁶ suggests a possible role of reduced 15-HETE activation of PPAR γ in prostate carcinogenesis or progression. Whether this signaling pathway or some other mechanism of cell regulation is affected by alterations of prostate 15-LOX-2 expression remains to be further clarified.

Acknowledgments

We thank Kim Johnson for help in fresh tissue procurement, Jean McClure and Brent Weedman for help with figures, and Caroline Nolen and the VUMC Histology Laboratory for cutting prostate whole mounts for immunohistochemical staining.

References

1. Marnett LJ: Aspirin and the potential role of prostaglandins in colon cancer. *Cancer Res* 1992, 52:5575-5589
2. Tang DG, Honn KV: 12-Lipoxygenase, 12(S)-HETE, and cancer metastasis. *Ann NY Acad Sci* 1994, 744:199-215
3. Sheng H, Shao J, Kirkland SC, Isakson P, Coffey RJ, Morrow J, Beauchamp RD, DuBois RN: Inhibition of human colon cancer cell growth by selective inhibition of cyclooxygenase-2. *J Clin Invest* 1997, 99:2254-2259
4. Smith WL, Garavito RM, DeWitt DL: Prostaglandin endoperoxide H synthases (cyclooxygenases)-1 and -2. *J Biol Chem* 1996, 271:33157-33160
5. Samuelsson B, Dahlen SE, Lindgren JA, Rouzer CA, Serhan CN: Leukotrienes and lipoxins: structures, biosynthesis, and biological effects. *Science* 1987, 237:1171-1176
6. Lewis RA, Austen KF, Soberman RJ: Leukotrienes and other products of the 5-lipoxygenase pathway. *Mech Dis* 1990, 323:645-655
7. Funk CD: The molecular biology of mammalian lipoxygenases and the quest for eicosanoid functions using lipoxygenase-deficient mice. *Biochim Biophys Acta* 1996, 1304:65-84
8. Brash AR, Boeglin WE, Chang MS: Discovery of a second 15S-lipoxygenase in humans. *Proc Natl Acad Sci USA* 1997, 94:6148-6152
9. Chaudry AA, Wahle KWJ, McClinton S, Moffat LEF: Arachidonic acid metabolism in benign and malignant prostatic tissue *in vitro*: effects of fatty acids and cyclooxygenase inhibitors. *Int J Cancer* 1994, 57:176-180
10. Gao X, Grignon DJ, Chbithi T, Zacharek A, Chen YQ, Sakr W, Porter AT, Crissman JD, Pontes JE, Powell IJ, Honn KV: Elevated 12-lipoxygenase mRNA expression correlates with advanced stage and poor differentiation of human prostate cancer. *Urology* 1995, 46:227-237
11. Ghosh J, Myers CE: Arachidonic acid stimulates prostate cancer cell growth: critical role of 5-lipoxygenase. *Biochem Biophys Res Commun* 1997, 235:418-423
12. Spindler SA, Sarkar FH, Sakr WA, Blackburn ML, Bull AW, LaGattuta M, Reddy RG: Production of 13-hydroxyoctadecadienoic acid (13-HODE) by prostate tumors and cell lines. *Biochem Biophys Res Commun* 1997, 239:775-781
13. Boeglin WE, Kim RB, Brash AR: A 12R-lipoxygenase in human skin: mechanistic evidence, molecular cloning, and expression. *Proc Natl Acad Sci USA* 1998, 95:6744-6749
14. Blake MS, Johnston KH, Russell-Jones GJ, Gotschlich EC: A rapid, sensitive method for detection of alkaline phosphatase-conjugated anti-antibody on Western blots. *Anal Biochem* 1984, 136:175-179
15. Hammer RD, Scott M, Shahab I, Casey TT, Cousar JB, Macon WR: Latent membrane protein antibody reacts with normal hematopoietic precursor cells and leukemic blasts in tissues lacking Epstein-Barr virus genome by polymerase chain reaction. *Am J Clin Pathol* 1996, 106:469-474
16. Ingram CD, Brash AR: Characterization of HETEs and related conjugated dienes by UV spectroscopy. *Lipids* 1988, 23:340-344
17. Bryant RW, Bailey JM, Schewe T, Rapoport SM: Positional specificity of a reticulocyte lipoxygenase: conversion of arachidonic acid to 15S-hydroperoxy-eicosatetraenoic acid. *J Biol Chem* 1982, 257:6050-6055
18. Soberman RJ, Harper TW, Betteridge D, Lewis RJ, Austen KF: Characterization and separation of the arachidonic acid 5-lipoxygenase and linoleic acid ω -6 lipoxygenase (arachidonic acid 15-lipoxygenase) of human polymorphonuclear leukocytes. *J Biol Chem* 1985, 260:4508-4515
19. Jisaka M, Kim RB, Boeglin WE, Nanney LB, Brash AR: Molecular

- cloning and functional expression of a phorbol ester-inducible 8S-lipoxygenase from mouse skin. *J Biol Chem* 1997, 272:24410-24416
20. Yla-Herttuala S, Rosenfeld ME, Parthasarathy S, Sigal E, Sarkioja T, Witztum JL, Steinberg D: Gene expression in macrophage-rich human atherosclerotic lesions: 15-lipoxygenase and acetyl low density lipoprotein receptor messenger RNA colocalize with oxidation specific lipid-protein adducts. *J Clin Invest* 1991, 87:1146-1152
 21. Hubbard WC, Alley MC, Mclemore TL, Boyd MR: Profiles of prostaglandins in sixteen established cell lines derived from human lung, colon, prostate, and ovarian tumors. *Cancer Res* 1988, 48:4770-4775
 22. Honn KV, Tang DG, Grossi I, Duniec ZM, Timar J, Renaud C, Leithauer M, Blair IA, Johnson CR, Diglio CA, Kimler VA, Taylor JD, Marnett LJ: Tumor derived 12(S)-hydroxyeicosatetraenoic acid induces microvascular endothelial cell retraction. *Cancer Res* 1994, 54:565-574
 23. Chen YQ, Duniec ZM, Liu B, Hagmann W, Gao X, Shimoji K, Marnett LJ, Johnson CR, Honn KV: Endogenous 12S-HETE production by tumor cells and its role in metastasis. *Cancer Res* 1994, 54:1574-1579
 24. Nie D, Hillman GG, Geddes T, Tang K, Pierson C, Grignon DJ, Honn KV: Platelet-type 12-lipoxygenase in a human prostate carcinoma stimulates angiogenesis and tumor growth. *Cancer Res* 1998, 58:4047-4051
 25. Ghosh J, Myers CE: Inhibition of arachidonate 5-lipoxygenase triggers massive apoptosis in human prostate cancer cells. *Proc Natl Acad Sci USA* 1998, 95:13182-13187
 26. Anderson KM, Seed T, Vos M, Mulshine J, Meng J, Alrefai W, Ou D, Harris JE: 5-Lipoxygenase inhibitors reduce PC-3 cell proliferation and initiate nonnecrotic cell death. *Prostate* 1998, 37:161-173
 27. Lehmann WD, Stephan M, Furstenberger G: Profiling assay for lipoxygenase products of linoleic and arachidonic acid by gas chromatography-mass spectrometry. *Anal Biochem* 1992, 204:158-170
 28. Yu K, Bayona W, Kallen CB, Harding HP, Ravera CP, McMahon G, Brown M, Lazar MA: Differential activation of peroxisome proliferator-activated receptors by eicosanoids. *J Biol Chem* 1995, 270:23975-23983
 29. Devchand PR, Keller H, Peters JM, Vazquez M, Gonzalez FJ, Wahli W: The PPAR α -leukotriene B4 pathway to inflammation control. *Nature* 1996, 384:39-43
 30. Forman BM, Tontonoz P, Chen J, Brun RP, Spiegelman BM, Evans RM: 15-Deoxy- Δ 12,14-prostaglandin J2 is a ligand for the adipocyte determination factor PPAR γ . *Cell* 1995, 83:803-812
 31. Kliewer SA, Lenhard JM, Wilson TM, Patel I, Morris DC, Lehmann JM: A prostaglandin J₂ metabolite binds peroxisome proliferator-activated receptor γ and promotes adipocyte differentiation. *Cell* 1995, 83:813-819
 32. Pineau T, Hudgins WR, Liu L, Chen L, Sher T, Gonzalez FJ, Samid D: Activation of a human peroxisome proliferator-activated receptor by the antitumor agent phenylacetate and its analogs. *Biochem Pharmacol* 1996, 52:659-667
 33. Thibault A, Cooper MR, Figg WD, Venzon DJ, Sartor AO, Tompkins AC, Weinberger MS, Headless DJ, McCall NA, Samid D, Myers CE: A phase I and pharmacokinetic study of intravenous phenylacetate in patients with cancer. *Cancer Res* 1994, 54:1690-1694
 34. Thibault A, Samid D, Cooper MR, Figg WD, Tompkins AC, Patronas N, Headless DJ, Kohler DR, Venzon DJ, Myers CE: Phase I study of phenylacetate administered twice daily in patients with cancer. *Cancer* 1995, 75:2932-2938
 35. Kubota T, Koshizuka K, Williamson EA, Asou H, Said JW, Holden S, Miyoshi I, Koeffler HP: Ligand for peroxisome proliferator-activated receptor γ (Troglitazone) has potent antitumor effect against human prostate cancer both in vitro and in vivo. *Cancer Res* 1998, 58:3344-3352
 36. Nagy L, Tontonoz P, Alvarez JGA, Chen H, Evans RM: Oxidized LDL regulates macrophage gene expression through ligand activation of PPAR γ . *Cell* 1998, 93:229-240

Reduced 15-Lipoxygenase-2 Immunostaining in Prostate Adenocarcinoma: Correlation With Grade and Expression in High-Grade Prostatic Intraepithelial Neoplasia

GREGORY S. JACK, BA, ALAN R. BRASH, PhD, SANDRA J. OLSON, MS, SUZANNE MANNING, BS, CHRISTOPHER S. COFFEY, PhD, JOSEPH A. SMITH, JR, MD, AND SCOTT B. SHAPPELL, MD, PhD

Arachidonic acid (AA) metabolites are implicated in the oncogenesis of several tumors, including prostate cancer. 15-Lipoxygenase-2 (15-LOX-2) is a novel AA-metabolizing enzyme with a limited tissue distribution, which includes prostate, lung, skin, and cornea. Previous studies have shown that 15-LOX-2 is present in benign prostate secretory cells and reduced in prostate adenocarcinoma and that production of the 15-LOX-2 metabolite 15S-hydroxyeicosatetraenoic acid is reduced in malignant compared with benign prostate. The objective of this study was to determine the frequency with which 15-LOX-2 immunostaining is reduced in prostate carcinoma and to correlate reduced expression with tumor differentiation (grade) and other pathologic parameters in radical prostatectomy specimens. Paraffin immunoperoxidase with a polyclonal antibody specific for 15-LOX-2 was performed on tumors and benign portions from 70 cases, and the percentage of tumor immunostaining for 15-LOX-2 was assessed. Whereas uniform 15-LOX-2 immunostaining was observed in secretory cells of benign glands, it was markedly reduced or absent in most adenocarcinomas: 23 of 70 tumors showed completely absent 15-LOX-2 immunostaining, and 45 of 70 cases showed negative immunostaining in more than 50% of the tumor. The extent of reduced 15-LOX-2 immunostaining correlated with tumor differentiation, with retained expression particularly in Gleason score 5 tumors versus a significant reduction of 15-LOX-2 in higher-grade tumors (mean \pm SD tumor 15-LOX-2 positive: Gleason score 5 = 67% \pm 30%, Gleason score 6 = 16% \pm 30%, Gleason score 7 = 23% \pm 28%,

Arachidonic acid (AA) metabolites are implicated in the development or progression of several carcinomas, including colon, breast, lung, and bladder.¹⁻⁵ AA is metabolized by cyclo-oxygenases (COXs) to produce prostaglandins (PGs), prostacyclin, and thromboxane⁶

Gleason score \geq 8 = 41% \pm 46%). In 16 cases with multifocal tumors or different foci of the same tumor with different grades, the higher-grade foci had significantly reduced 15-LOX-2 expression compared with the lower-grade foci. In peripheral zone tumors without complete loss of 15-LOX-2 expression, there was a significant inverse relationship between 15-LOX-2 immunostaining and tumor volume. There was not a significant correlation between 15-LOX-2 immunostaining and serum PSA or pathologic stage. In a subset of 27 cases, 15-LOX-2 expression in high-grade prostatic intraepithelial neoplasia (HGPIN) glands was significantly reduced compared with benign glands. These data show that in contrast to the uniform expression of 15-LOX-2 in differentiated secretory cells of benign prostate, reduced 15-LOX-2 is a common alteration in prostate carcinoma, and this correlates with tumor cell differentiation. That reduced expression is seen in HGPIN suggests that this may be an early alteration in carcinoma development. HUM PATHOL 31:1146-1154. Copyright © 2000 by W.B. Saunders Company

Key words: prostate cancer, lipoxygenase, arachidonic acid.

Abbreviations: AA, arachidonic acid; COX, cyclo-oxygenase; PG, prostaglandin; LOX, lipoxygenase; HETE, hydroxyeicosatetraenoic acid; PPAR γ , peroxisome proliferator activated receptor gamma; HGPIN, high-grade prostatic intraepithelial neoplasia; PSA, prostate-specific antigen; H&E, hematoxylin and eosin; PZ, peripheral zone; TZ, transition zone.

and by lipoxygenases (LOXs) to produce hydroxyeicosatetraenoic acids (HETEs) or leukotrienes.⁷ Possible mechanisms whereby eicosanoids contribute to tumor formation or progression include regulation of cell growth and differentiation or prevention of apoptosis,^{8,9} tumor cell invasion or metastasis,^{10,11} and induction of angiogenesis.^{12,13} A limited number of recent investigations have focused on the possible role of AA-metabolizing enzymes in prostate cancer. Studies in prostate cancer cell lines have suggested possible roles for COX-2^{14,15} and 5-LOX¹⁶⁻¹⁸ in regulating cell proliferation or apoptosis. Studies in actual prostate tissues have included demonstration of 12-LOX mRNA up-regulation in high-grade, high-stage tumors¹⁹ and increased PGE₂ in cancer versus benign prostatic hyperplasia.²⁰

15-Lipoxygenase-2 (15-LOX-2) is a novel lipoxygenase recently cloned from human hair rootlets by Brash and colleagues.²¹ 15-LOX-2 has only approximately 40% sequence identity to the previously characterized human 5-LOX, platelet type 12-LOX, and 15-

From the Department of Pathology, Department of Pharmacology, Vanderbilt-Ingram Cancer Center, Vanderbilt Prostate Cancer Center, Department of Preventive Medicine, and Department of Urology, Vanderbilt University Medical Center, Nashville, TN. Accepted for publication June 14, 2000.

Supported in part by Department of Defense Grant PC970260 (S.B.S.), a Prostate Cancer Discovery Grant from the Vanderbilt-Ingram Cancer Center (S.B.S., A.R.B.), and National Institutes of Health Grant GM-53638 (A.R.B.). Gregory S. Jack is the recipient of a Vanderbilt Medical Scholars Fellowship.

Address correspondence and reprint requests to Scott B. Shappell, MD, PhD, Department of Pathology, C-3321, Medical Center North, Vanderbilt University Medical Center, Nashville, TN 37232-2561.

Copyright © 2000 by W.B. Saunders Company
0046-8177/00/3109-0024\$10.00/0
doi: 10.1053/hupa.2000.16670

LOX (15-LOX-1). 15-LOX-2 appears to have a limited tissue expression, with mRNA detected in prostate, lung, and cornea.^{21,22} We have recently shown by immunostaining that 15-LOX-2 is uniformly expressed in benign prostate secretory cells, whereas it is not expressed in prostate basal cells, stroma, urothelium, ejaculatory ducts, or seminal vesicles.²³ Furthermore, benign prostate tissue synthesizes the 15-LOX-2 metabolite 15-S-HETE from AA.²³ In contrast, 15-LOX-2 immunostaining was substantially reduced or absent in most prostate adenocarcinomas, and in incubations of paired benign and malignant tissues from the same patients, 15-HETE production was reduced or absent in prostate carcinomas.²³ More recently, we have also shown uniform expression of 15-LOX-2 in other androgen regulated tissues, including secretory cells of cutaneous sebaceous and apocrine glands and in certain benign and malignant breast lesions, particularly with apocrine differentiation (Shappell SB, unpublished observations).

The limited tissue distribution of 15-LOX-2, particularly in differentiated secretory cells such as prostate epithelium, suggests a possible role for 15-LOX-2 and 15-S-HETE in the regulation of tissue-specific functions, including cellular differentiation. Studies unrelated to prostate cancer in other laboratories have indicated that 15-HETE, similar to other AA metabolites, may be able to activate gene transcription by peroxisome proliferator activated receptor gamma (PPAR γ).²⁴ These results are paralleled by the demonstration that synthetic PPAR γ -agonists can inhibit proliferation and induce differentiation of prostate cancer cell lines,²⁵ as well as breast cancer cell lines.²⁶ Hence, loss of 15-LOX-2 expression may correlate with or contribute to reduced cellular differentiation in prostate carcinoma. The goal of the current study was to characterize the possible reduced expression of 15-LOX-2 in prostate carcinoma by using immunohistochemistry in radical prostatectomy (RP) specimens and to correlate expression with cell differentiation (as reflected by tumor grade) and other clinicopathologic parameters. To gain further insight into the possible role of reduced 15-LOX-2 in prostate cancer development or progression, immunostaining in high-grade prostatic intraepithelial neoplasia (HGPIN) was also examined and compared with benign and carcinoma.

METHODS

Case Selection and Pathology Evaluation

Cases were retrieved from the Surgical Pathology files of Vanderbilt University Medical Center. Radical prostatectomy specimens were submitted in their entirety for whole-mount processing, with transverse 5-mm slices cut perpendicular to the rectal surface processed for histology for subsequent 5- μ m sections. Microscopic examination was performed on all specimens by a single pathologist (S.B.S). Tumor grade was assigned by using the Gleason grading system (Gleason score),²⁷ and staging (presence or absence of extracapsular extension, seminal vesicle invasion, and lymph node metastases) was performed by using standard criteria.²⁸ Tumor vol-

ume (mL) was determined by planimetry, with areas determined on outlined tumor foci by using a digitized graphics tablet (WACOM) and NIH Image Analysis software. Patients who had undergone prior androgen deprivation therapy or who had received prior radiation therapy were excluded. A total of 70 cases were selected (from a total of 207 radical prostatectomies during an 18-month period), to give a mixture of tumor grades and stages as follows: Gleason score 5, 17 cases; Gleason score 6, 23 cases; Gleason score 7, 24 cases; Gleason score 8 or above, 6 cases. Forty cases were organ-confined tumors, 30 had extracapsular extension, 8 had seminal vesicle invasion, and 4 had positive lymph nodes. Clinical parameters (age, prostate-specific antigen [PSA]) were obtained from the patient record. Mean patient age was 59 years (range, 44 to 73). The serum PSA level drawn closest before surgery was used for statistical analysis.

Immunohistochemistry and Quantitation of 15-LOX-2 Immunostaining in Tumor

Whole-mount sections that contained adequate tumor and benign glands typical of the overall specimen were selected for immunohistochemical analysis and were recut onto standard-sized charged slides for immunohistochemistry. The 15-LOX-2 rabbit polyclonal antibody was prepared against purified 15-LOX-2 protein as previously described.²³ This antibody is specific for 15-LOX-2, without appreciable cross-reactivity to 5-LOX, 12-LOX, or 15-LOX-1 on Western blots.²³ Immunostaining of prostatic epithelium is eliminated by prior absorption with purified 15-LOX-2 protein.²³ Paraffin immunoperoxidase studies were performed by using a 1:1,000 dilution of 15-LOX-2 antibody on an automated immunostainer (Ventana ES automated immunohistochemistry system, Ventana Medical Systems, Tucson, AZ), employing an avidin-biotin method without antigen retrieval techniques.²³ As observed previously,²³ 15-LOX-2 immunostaining in normal benign glands was uniform in all glands and used as an internal control. Immunostaining of glands within tumor was quantitated by a single individual (G.S.J.) blinded to the reported tumor grade, stage, and clinical data. Tumor foci on the immunostained slides were carefully outlined and compared with the original tumor maps of the whole-mount sections. Using benign glands as a baseline for strongly positive immunostaining, tumor cell staining was assigned a score ranging from 0 to 4+ (0: absent; 1+: scant, weakly positive rare cells, almost indistinguishable from background; 2+: faint, but definitely positive immunostaining in 10% to 50% of cells in a gland; 3+: moderate to strongly positive in 50% to 75% of cells in a gland; 4+: strong positive, essentially equivalent to benign epithelium). Non-gland-forming higher-grade tumors were evaluated for definitive staining of tumor cells above background, and scored similarly 0 to 4+ based on intensity of immunostaining. Under 100 \times magnification, tumor foci with a staining score of 2 to 4+ were considered 15-LOX-2 immunopositive, and foci with a score of 0 and 1+ were considered 15-LOX-2 negative. Foci of 15-LOX-2-positive and negative tumor were specifically outlined. Tumor maps were enlarged (200%), and areas of positive and negative tumor were determined by using a digitized graphics tablet and NIH Image Analysis software. Area of 15-LOX-2-positive tumor was divided by total area of tumor to give percentage of tumor positive for 15-LOX-2. In the cases with multifocal tumors with different Gleason scores on immunostained slides, the percentage of 15-LOX-2-positive was calculated individually for each foci.

Evaluation of 15-LOX-2 Immunostaining in HGPIN Glands

In a subset of 27 cases, individual HGPIN glands were marked on a hematoxylin and eosin (H&E)-stained slide recut at the same time as the immuno-slides. PIN was graded as high grade according to established criteria.^{29,30} 15-LOX-2 immunostaining in benign and HGPIN glands was quantitated by counting the number of immunopositive and immunonegative glands.³¹ The HGPIN glands were further divided into those that were within the tumor borders and those that were 2 mm or more away from any tumor. For a case to be included in the analysis, it had to have 5 or more distinct HGPIN glands inside the tumor foci or 5 or more distinct HGPIN glands outside the tumor. For each case, 25 benign nonatrophic peripheral zone (PZ) glands were assessed for immunostaining. After all glands of interest were marked on the H&E slides, the markings were traced onto the corresponding 15-LOX-2 immunoslides, and the marked HGPIN and benign glands were analyzed for 15-LOX-2 expression. A gland was counted as positive if it had an immunostaining score (as described above) of 4+, 3+, or 2+, and was counted as negative if it had a staining score of 1+ or 0.

Statistical Analysis

Percent of 15-LOX-2 immunostaining within tumors was recorded as a linear variable ranging from 0 to 100%. 15-LOX-2 is completely absent in some tumors, whereas in those with some immunostaining, it is highly variable. To properly account for this in examining the relationship between tumor 15-LOX-2 expression and the variables of interest (Gleason score, pathologic stage, tumor volume, and [PSA]), prostate adenocarcinomas were divided into 2 groups: tumors negative for 15-LOX-2 (ie, 0% expression) and tumors with positive expression (ranging from 1% to 100% immunostaining). Comparisons of categorized 15-LOX-2 expression (0% *v* >0%) with Gleason score and pathologic stage were performed by use of the Cochran Mantel-Haenszel chi-square statistic with integer scores. Comparisons with volume and PSA were performed by using logistic regression. Among tumors expressing any 15-LOX-2 (>0%), 15-LOX-2 expression and Gleason score were compared by using analysis of variance, stage comparisons were made by using a Kruskal-Wallis test, and tumor volume and PSA relationships were examined by using Kendall's rank correlation.

In a subset of 16 cases with distinct tumors of different grade or different grade foci within the same tumor, differences in 15-LOX-2 immunostaining within the same specimen were compared with a paired Student's *t*-test. Similarly, in the subset of 27 cases in which immunostaining was assessed in HGPIN, mean differences between immunostaining of 15-LOX-2 in benign glands and HGPIN were examined by

using paired *t*-tests. The kappa statistic was used to determine whether the percentage of glands immunostaining for 15-LOX-2 in HGPIN away from and within tumors were in agreement with the percent of 15-LOX-2 immunostaining in the tumor.

RESULTS

Reduced 15-LOX-2 Immunostaining in Prostate Carcinoma and Correlation With Gleason Grade

Strong uniform 15-LOX-2 cytoplasmic and nuclear immunostaining was seen in secretory cells of nonatrophic benign glands, particularly in the PZ (Fig 1A, B). In contrast, 15-LOX-2 immunostaining was markedly reduced in the majority of prostate carcinomas (Fig 1A, B). 15-LOX-2 immunostaining was completely absent in tumors in 23 of 70 cases and substantially reduced (<50% tumor 15-LOX-2 immunopositive) in 45 of 70 cases. The extent of absent or reduced 15-LOX-2 immunostaining correlated with tumor differentiation, with retained expression being particularly evident in Gleason grade 5 (either 2 + 3 or 3 + 2) tumors (Fig 1C, D) and extensive loss of immunostaining occurring in higher-grade lesions (Fig 1E-G, Table 1).

Possible correlation of 15-LOX-2 immunostaining with grade or progressively reduced expression with less tumor differentiation was further assessed in a subset of 16 cases with spatially distinct tumors of different grade (*n* = 8) or different grade foci within the same tumor (*n* = 8). As shown in Figures 2 and 3, the higher-grade focus (mean Gleason score, 7; median, 7; range, 6 to 8) had significantly decreased immunostaining of 15-LOX-2 compared with the lower-grade focus (mean Gleason score, 6; median, 6; range, 4 to 7). These differences were more pronounced in the group with apparently distinct tumors (not shown).

15-LOX-2 in Relation to Tumor Volume, Pathologic Stage, and PSA

Tumor stage was divided into 3 categories: organ confined (\leq pT2), extracapsular extension (pT3a,b), and seminal vesicle or lymph node invasion (\geq pT3c). Although there was not a significant difference between the 15-LOX-2 expression of these 3 groups, there was a downward trend in the mean percent tumor immunopositive with advancing pathologic stage (Table 2).

FIGURE 1. 15-LOX-2 immunostaining in benign prostate glands and prostate adenocarcinoma (Pca): Correlation with grade. (A) Typical strong uniform 15-LOX-2 immunostaining in benign glands, with completely negative immunostaining in invasive acinar Gleason pattern 3 Pca (center and left). (Original magnification $\times 100$.) (B) Higher magnification of portion in A, showing usual cytoplasmic and some nuclear 15-LOX-2 immunostaining of secretory cells in benign gland (top), with completely absent immunostaining in small tumor glands (bottom). (Original magnification $\times 400$.) (C) Positive 15-LOX-2 immunostaining in admixed large and small gland profiles in a Gleason score 5 Pca, which was overall 100% 15-LOX-2 immunopositive. (Original magnification $\times 100$.) (D) Heterogeneous staining of 15-LOX-2 in a Gleason score 5 Pca, with admixed immunopositive glands (eg, left and bottom right) and immunonegative glands (eg, top center) in a tumor that was overall 87% 15-LOX-2 positive. (Original magnification $\times 100$.) (E-G) Completely negative 15-LOX-2 expression in representative fields of Gleason score 6 (E), Gleason score 7 (F), and Gleason score 9 (G) tumors, that were overall 0%, 17%, and 0% 15-LOX-2 immunopositive, respectively. (Original magnifications 100 \times , 100 \times , 400 \times .) (H) Strong 15-LOX-2 immunostaining in a predominantly cribriform Gleason score 8 Pca that was overall 96% 15-LOX-2 immunopositive. (Original magnification $\times 40$.) (A-H) Paraffin immunoperoxidase with rabbit polyclonal anti-human 15-LOX-2, 1:1,000.

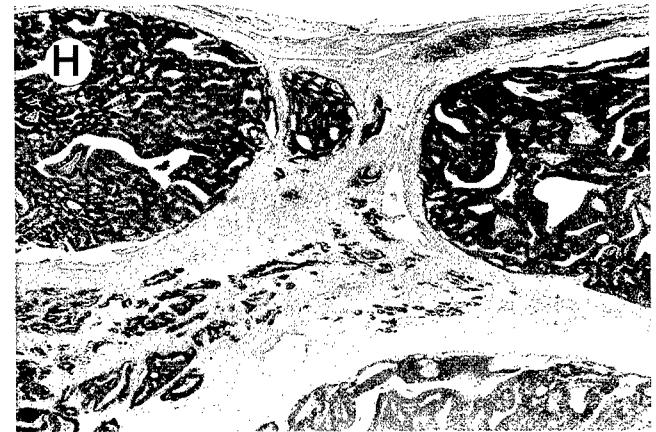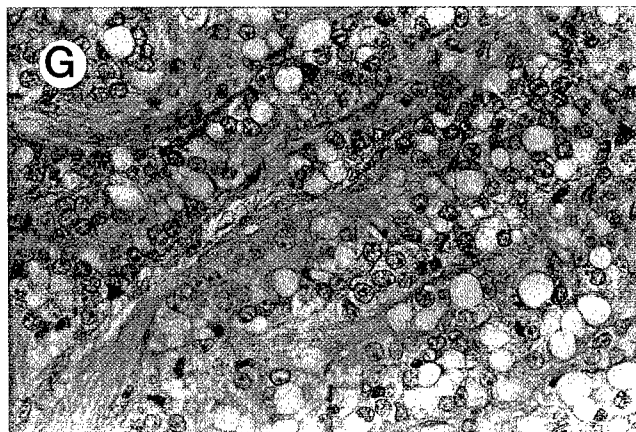
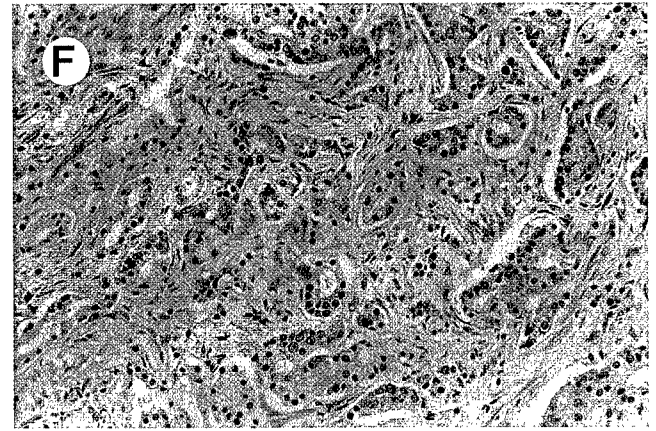
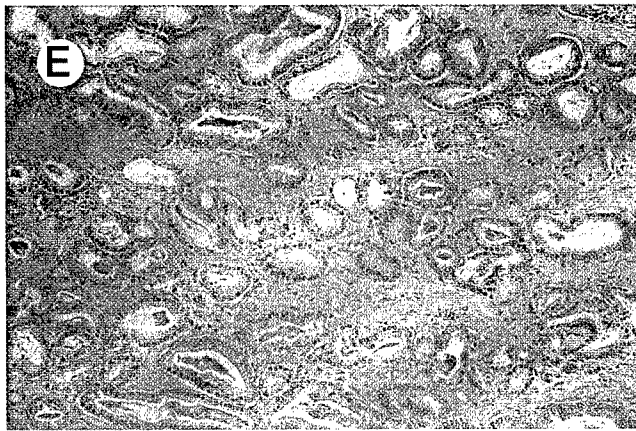
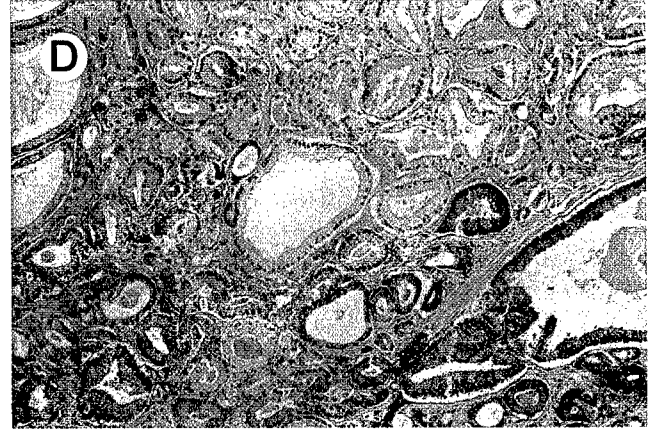
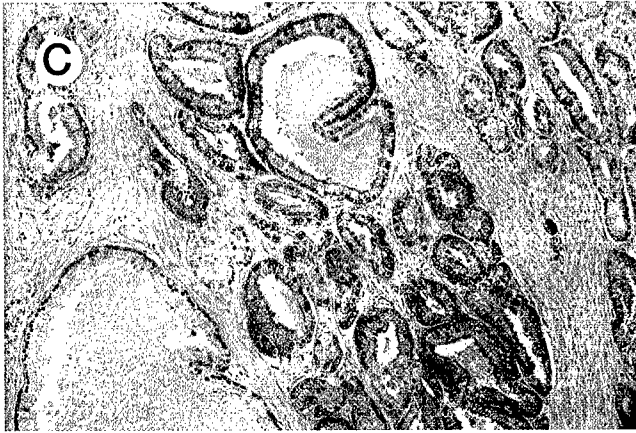
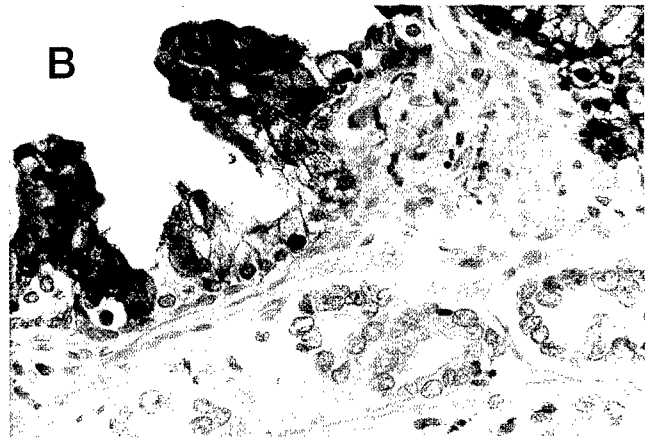

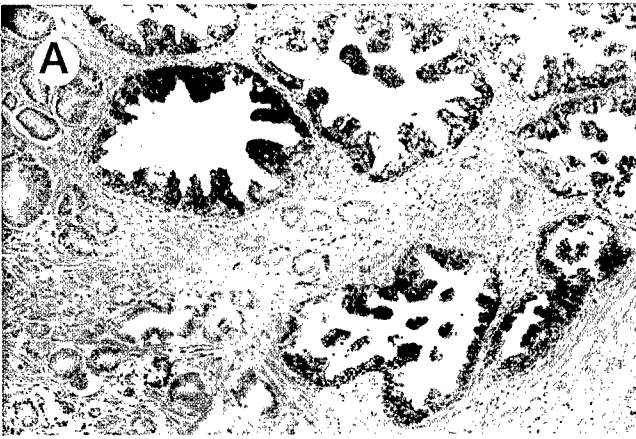
TABLE 1. 15-LOX-2 Expression in Relation to Gleason Grade

Gleason Score	Tumors With 15-LOX-2 Present	Tumors With 15-LOX-2 Reduced	Tumors With 15-LOX-2 Absent	Mean ± SD 15-LOX-2 Expression*
Grade 5 (n = 17)	14 (82%)	2 (11%)	1 (6%)	67% ± 30%†
Grade 6 (n = 23)	3 (13%)	8 (35%)	12 (52%)	16% ± 30%
Grade 7 (n = 24)	5 (21%)	11 (46%)	8 (33%)	23% ± 28%
Grade 8 (n = 6)	3 (50%)	1 (16%)	2 (33%)	41% ± 46%

NOTE. 15-LOX-2 present = positive immunostaining in >50% of tumor; 15-LOX-2 reduced = positive immunostaining in 1% to 50% of tumor; 15-LOX-2 absent = positive immunostaining in 0% of tumor.

* Mean ± standard deviation of percentage 15-LOX-2 immunostaining of all tumors of that grade.

† $P < 0.05$ for Gleason grade 5 vs. Gleason grades 6, 7, and ≥8. The differences in 15-LOX-2 expression between Grades 6, 7, and ≥8 tumors were not significant.

Neither controlling for Gleason score nor considering tumors with extracapsular extension, seminal vesicle invasion, or positive lymph nodes together yielded significant ($P < .05$) relationships (not shown).

In this series of radical prostatectomy specimens subjected to 15-LOX-2 immunostaining analysis, mean and median tumor volumes were 2.65 and 1.91 mL, respectively (range, 0.13 to 12.1 mL). Considering tumors with complete loss of 15-LOX-2 immunostaining (0% expression) versus those with any positive immunostaining (>0% 15-LOX-2 immunopositive), there was no statistically significant relationship between 15-LOX-2 expression and tumor volume. In tumors with less than complete loss of 15-LOX-2 (>0% 15-LOX-2 immunopositive), there was a suggestion of an inverse relationship between volume and 15-LOX-2 immunostaining, but this did not reach statistical significance ($P = .08$), when all cases were included in the analysis. When tumors confined to the peripheral zone with less than complete loss of 15-LOX-2 were examined ($n = 37$), there was a statistically significant inverse relationship between volume and 15-LOX-2 immunostaining ($P < .01$). No relationship was observed between serum PSA and 15-LOX-2 immunostaining.

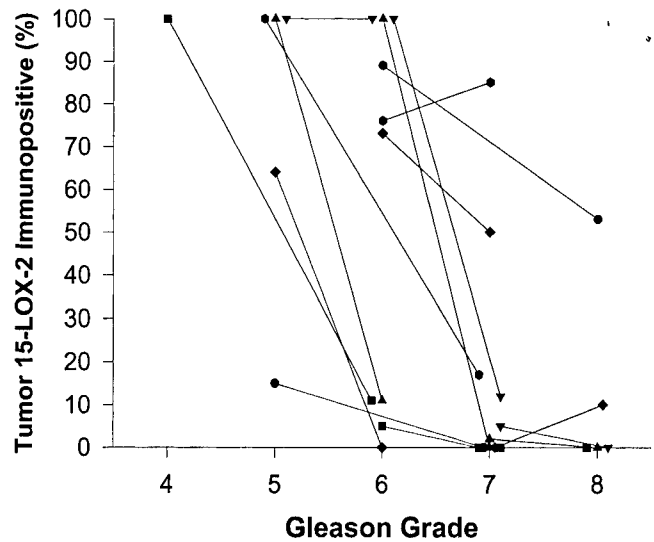


FIGURE 2. 15-LOX-2 immunostaining in different grade tumors and different grade foci of same tumor in individual patients. Data are expressed as percentage of 15-LOX-2 immunostaining of tumor, with each line connecting the 2 grades of individual patients. 15-LOX-2 was significantly reduced in higher-grade versus lower-grade foci ($P < .05$).

15-LOX-2 Immunostaining in HGPIN

Many tumors in this study had varying degrees of focally retained 15-LOX-2 immunostaining, which may indicate that loss of 15-LOX-2 occurs at stages of tumor progression after invasion from precursor lesions. However, complete loss in many tumors could indicate that loss of 15-LOX-2 occurs before the stage of invasion. To address these issues, 15-LOX-2 immunostaining was specifically assessed in HGPIN glands. Because HGPIN is often a multifocal process and HGPIN within tumor may theoretically be considered to more likely represent the precursor lesion giving rise to spatially associated invasive tumor, HGPIN was divided into into 2 groups: HGPIN within the borders of tumor foci and HGPIN within benign parenchyma (≥2 mm away from any tumor glands). Benign glands were assessed for 15-LOX-2 immunostaining in a similar quantitative manner for comparison. Reduced 15-LOX-2 immunostaining was indeed observed in glands with HGPIN (Fig 3). Compared with the strongly positive staining observed in most benign peripheral zone glands, 15-LOX-2 immunostaining was reduced in HGPIN glands,

FIGURE 3. Reduced 15-LOX-2 immunostaining in higher grade tumors or foci and reduced expression in HGPIN. (A) Strong immunostaining in representative field from 100% immunopositive Gleason 6 tumor. (Original magnification ×200). (B) Same patient as A, showing completely negative 15-LOX-2 expression in area of Gleason pattern 4 (with cribriform architecture and some ductal carcinoma features) in overall completely immunonegative Gleason score 7 tumor. (Original magnification ×200). (C) 15-LOX-2 immunostaining in representative field of Gleason score 5 prostate adenocarcinoma that was overall 100% 15-LOX-2 immunopositive. (Original magnification ×200). (D) Generally negative glands in Gleason score 6 carcinoma from same patient as in C. This tumor was overall 11% 15-LOX-2 immunopositive. (Original magnification ×200). (E) Strong 15-LOX-2 immunostaining in benign glands (left and right), with completely negative HGPIN (top center) and tumor (Gleason 7, bottom). (Original magnification ×40.) (F) Strong 15-LOX-2 in benign glands (left and top), with completely negative HGPIN gland (right, mid) and invasive Gleason 3 + 3 = 6 Pca (center and bottom). (Original magnification ×100.) (G) Completely 15-LOX-2 negative HGPIN in focus located away from invasive tumor. (Original magnification ×200.) (H) 15-LOX-2 immunonegative HGPIN located amongst invasive tumor (not shown). (Original magnification ×400.)

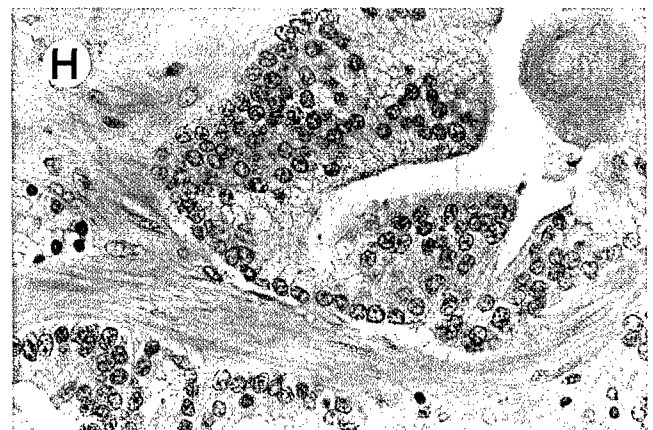
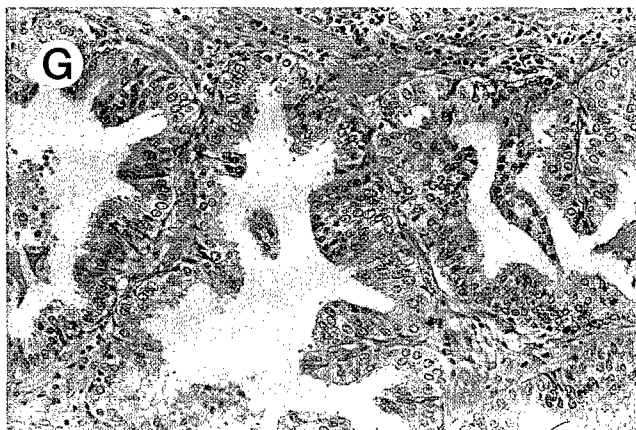
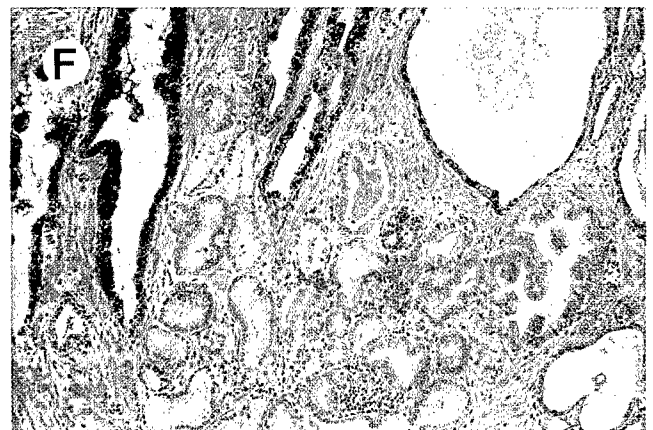
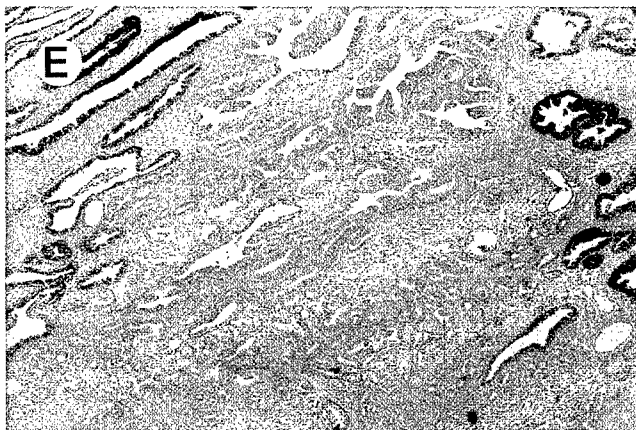
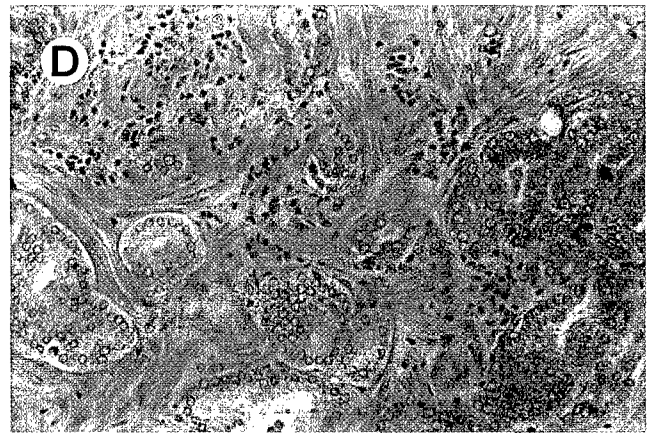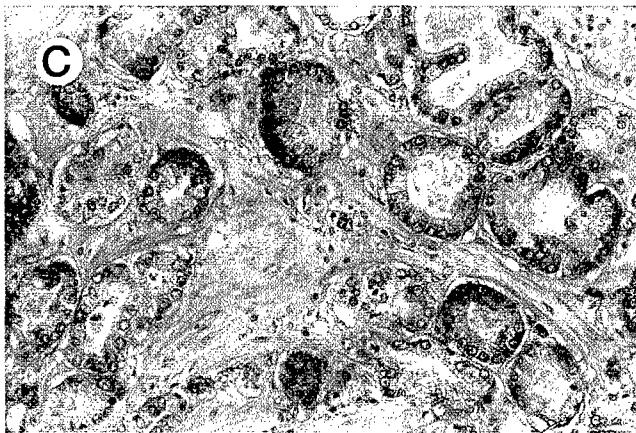
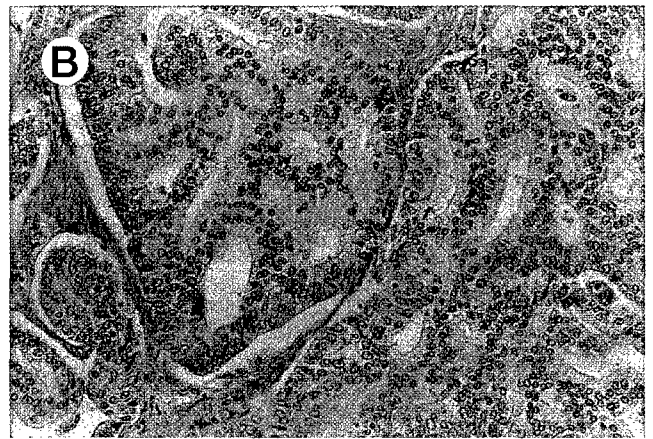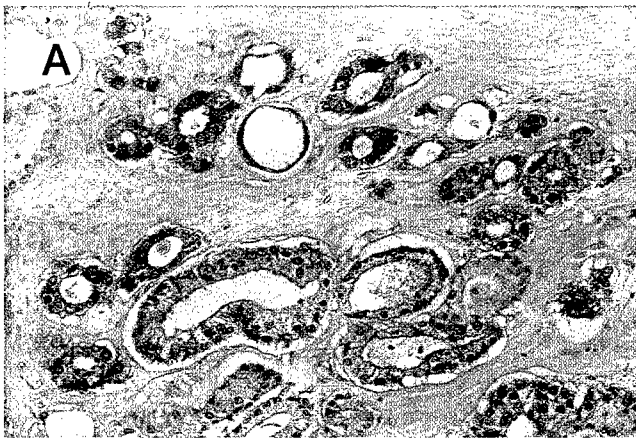


TABLE 2. 15-LOX-2 Expression in Relation to Tumor Stage

Stage	Tumors With 15-LOX-2 Present	Tumors With 15-LOX-2 Reduced	Tumors With 15-LOX-2 Absent	Mean \pm SD 15-LOX-2 Expression*
Organ Confined (n = 40)	18 (45%)	10 (25%)	12 (30%)	37% \pm 38%
Extracapsular Extension (n = 20)	7 (35%)	6 (30%)	7 (35%)	33% \pm 35%
Seminal Vesicle \pm Lymph Node Involvement (n = 10)	2 (20%)	4 (40%)	4 (40%)	17% \pm 32%

NOTE. 15-LOX-2 present = positive immunostaining in >50% of tumor; 15-LOX-2 reduced = positive immunostaining in 1% to 50% of tumor; 15-LOX-2 absent = positive immunostaining in 0% of tumor.

* Mean \pm standard deviation of percentage 15-LOX-2 immunostaining of all tumors of that grade.

both within tumor foci and in areas of histologically benign parenchyma. Overall, there was a significant difference in 15-LOX-2 immunostaining of the 3 groups (Mean percent \pm SD of 15-LOX-2-positive glands: benign = 70 \pm 20%, HGPIN in benign parenchyma = 38 \pm 25%, HGPIN in tumor 20 \pm 25%; $P < .01$). The results, broken down by grade of invasive tumor, are summarized in Figure 4.

To address whether tumors that were negative for 15-LOX-2 had HGPIN negative for 15-LOX-2, HGPIN and tumor were divided into those that were 15-LOX-2 negative (0% expression), and those that were 15-LOX-2 positive (1% to 100% expression). A kappa statistic was used to measure agreement between the HGPIN and tumor groups. There was a significant agreement between the tumor and tumor-HGPIN groups ($P < .01$, kappa 0.47), but not between tumor and benign-HGPIN groups ($P = .37$, kappa = .05).

DISCUSSION

15-Lipoxygenase-2 (15-LOX-2) is a recently identified arachidonic acid (AA) metabolizing enzyme, with only approximately 40% sequence identity with previously characterized human lipoxygenases.^{21,32} 15-LOX-2 was originally cloned from human hair rootlets²¹ and has an apparently limited pattern of tissue expression, with mRNA detected in prostate, cornea, and lung.^{21,22} In contrast to the previously identified human 15-lipoxygenase (15-LOX-1), it is not found in peripheral blood leukocytes.²¹ It also has different enzymatic properties than 15-LOX-1, including greater specificity in incorporation of oxygen at the 15-carbon position (with formation only of 15-HETE) and substrate preference.^{21,33} These differences in tissue distribution and enzymatic properties suggest unique functions of 15-LOX-2 in normal prostate biology and possible contributions of altered expression of 15-LOX-2 to prostate cancer development. In the current

study, we have shown that, in contrast to the essentially uniform immunostaining in benign prostate glands, 15-LOX-2 immunostaining was markedly reduced in 45 of 70 and completely absent in 23 of 70 cases of prostate adenocarcinoma.

Reduced 15-LOX-2 in prostate carcinoma correlated with tumor differentiation, because 15-LOX-2 tended to be retained in Gleason score 5 tumors but was reduced or absent in most tumors with Gleason score of 6 or greater. Despite the potential poor reproducibility in distinguishing Gleason score 5 and 6 tumors on biopsy and similar favorable prognosis of organ-confined Gleason 5 and 6 tumors treated by prostatectomy,³⁴ we believe the tumors assigned such grades in the current RP series are quite morphologically, as well as potentially biologically, distinct. All of the Gleason score 5 tumors in our cases had a component of Gleason pattern 2 (ie, 2 + 3 = 5 or 3 + 2 = 5). We tend to reserve Gleason pattern 2 designations for transition zone (TZ) tumors, with a somewhat circumscribed growth and typical histology, including closely spaced admixed small and larger gland profiles, with generally ample cytoplasm.^{35,36} Many of these Gleason score 5 tumors are either confined to the TZ or involve both the TZ and PZ, with the pattern 3 in these cases reflecting the infiltrative growth pattern at the periphery of the lesion or a more usual Gleason pattern 3 component in the PZ. In addition to the distinct histology of TZ tumors, histologic and even genetic data support the possibility of origin from different precur-

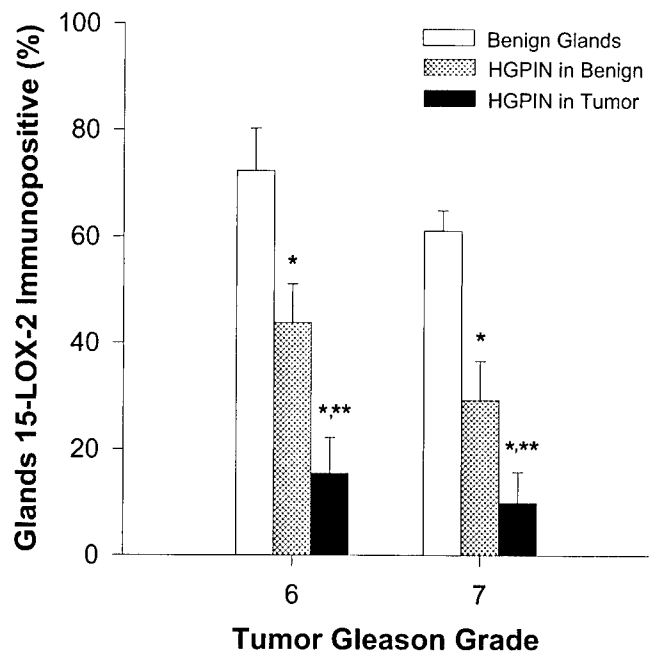


FIGURE 4. 15-LOX-2 immunostaining in HGPIN. Results are expressed as percentage of benign and HGPIN glands showing positive immunostaining and are separated by grade of the associated invasive tumor for Gleason score 6 and 7 tumors. HGPIN in Benign = HGPIN > 2 mm away from the invasive tumor; HGPIN in Tumor = HGPIN located within tumor. * $P < .05$ compared with benign; ** $P < .05$ compared with HGPIN away from tumor.

sor lesions than PZ tumors (ie, atypical adenomatous hyperplasia *v* PIN).³⁷ However, it is unlikely that the differences in 15-LOX-2 expression in Gleason 5 versus Gleason ≥ 6 tumors is related to these theoretical differences in nature of tumor origin alone, because 15-LOX-2 is normally expressed in benign PZ glands even greater than those in the TZ²³ and 15-LOX-2 expression was retained to a variable degree in a significant number of typical PZ tumors.

We believe the data showing reduced 15-LOX-2 in Gleason score ≥ 6 versus 5 tumors thus support the conclusion that loss of 15-LOX-2 correlates with or contributes to reduced tumor differentiation. This was supported further by results in those cases with multiple distinct tumor foci or distinct Gleason patterns in the same tumor, in which greater loss of 15-LOX-2 immunostaining was generally observed in the higher-grade or less differentiated regions. Reduced 15-LOX-2 immunostaining did not correlate with serum PSA or pathologic stage in this series of cases. In PZ tumors without complete loss of 15-LOX-2 immunostaining, the degree of retained expression correlated inversely with tumor volume. This is intriguing given the concept proposed by McNeal and colleagues that PZ tumors of increasing volume tend to become less differentiated (or have higher grades).^{38,39} Whether reduced 15-LOX-2 immunostaining in larger tumors reflects the likelihood of the additional alteration in malignant cells of reduced 15-LOX-2 expression as the tumor grows with time or a selective growth advantage of 15-LOX-2-negative tumor cells, or both, is not known. The latter hypothesis is supported by our recent observations that the addition of exogenous 15S-HETE inhibits proliferation of prostate cancer cell lines that are 15-LOX-2 negative and do not make detectable 15-HETE (Shappell SB, manuscript submitted).

That reduced 15-LOX-2 correlated inversely with tumor differentiation supports our emerging concepts and hypotheses of a contribution of 15-LOX-2 and 15-HETE in prostate secretory cell differentiation and decreased 15-LOX-2 in reduced differentiation in tumor cells. Although the overall results showed reduced 15-LOX-2 immunostaining in Gleason grade ≥ 6 tumors compared with Gleason 5 tumors, there were several cases of high-grade (Gleason grade ≥ 8) tumors that were strongly 15-LOX-2 immunopositive (eg, Fig 1H). The light microscopic features of these tumors were not discernibly different from similar grade tumors that were 15-LOX-2 negative. We also have observed such high-grade tumors that have high 15-LOX-2 mRNA expression and prominent formation of 15S-HETE from exogenous AA (Shappell SB, unpublished observations). The striking difference in immunophenotype and gene expression patterns between histologically similar tumors is intriguing and may provide useful cases for discerning other components of 15-LOX-2-related signaling pathways controlling tumor cell differentiation. Alternatively, given the extremely complex and heterogeneous genetic and other molecular alterations in prostate carcinoma,⁴⁰ similar

histologic and tumor behavior patterns could be achieved by independent genetic changes.

Regardless, loss of 15-LOX-2 appears to be an extremely common alteration in prostate carcinoma. That some tumors remain focally positive for 15-LOX-2 suggests that this reduced expression could occur within tumors after invasive prostate carcinoma has developed from a precursor lesion. However, completely negative tumors and reduction in 15-LOX-2 immunostaining in HGPIN observed herein would indicate that loss of 15-LOX-2 can occur early in tumor development (ie, before invasive disease), at least in some cases. Our results showed that 15-LOX-2 was significantly reduced in HGPIN glands compared with benign glands. Furthermore, the 15-LOX-2 immunostaining of HGPIN located in a tumor focus was generally equivalent to the 15-LOX-2 expression of the invasive tumor (ie, negative tumors were associated with negative HGPIN, positive tumors with positive HGPIN). This association did not hold true for HGPIN located away from the tumor. Although HGPIN located 2 mm or more from tumor still had significantly reduced 15-LOX-2 compared with benign glands, the presence or absence of 15-LOX-2 in these HGPIN glands appeared to be independent of the 15-LOX-2 expression in the overall tumor. These results correlate with other data regarding multiclonality or differences in phenotype of HGPIN⁴¹ and suggest that loss of 15-LOX-2 may be an early event in the pathogenesis of prostate carcinoma. Changes in a variety of genes or biomarkers altered in prostate carcinoma have been noted in prostatic intraepithelial neoplasia.⁴² These alterations may be crucial for tumor development or contribute to tumor phenotype after invasion, but other alterations are likely essential for development of invasion.

In the current study, although loss of 15-LOX-2 correlated with tumor grade, it did not correlate with stage, suggesting that it is likely that even if 15-LOX-2 regulates differentiation, other changes are necessary for development of tumor cell invasion through the prostate capsule or into lymphovascular spaces. However, because these later stages in tumor aggressiveness are more likely to develop in larger and less differentiated tumors, therapies based on driving tumor differentiation or slowing growth are extremely reasonable in prostate carcinoma. Such strategies may effectively prolong the natural history of prostate carcinoma, reducing tumor-associated mortality during expected lifetimes of individual patients. Because AA-metabolizing enzymes and PPARs are already targets for existing and potential pharmacologic agents, further characterization of the contribution of these pathways to prostate carcinoma development and behavior will potentially open new avenues for treatment.

Acknowledgment. The authors thank Kimberly Newsome-Johnson for cutting whole-mount sections for immunohistochemistry, Brent Weedman for help with figures, and Dr Kay Washington for useful discussions and critique of the manuscript.

REFERENCES

1. Marnett LJ: Aspirin and the potential role of prostaglandins in colon cancer. *Cancer Res* 52:5575-5589, 1992
2. Eberhart CE, Coffey RJ, Radhika A, et al: Upregulation of cyclooxygenase-2 gene expression in human colorectal adenomas and adenocarcinomas. *Gastroenterology* 107:1183-1188, 1994
3. Hwang D, Scollard D, Byrne J, et al: Expression of cyclooxygenase-1 and cyclooxygenase-2 in human breast cancer. *J Natl Cancer Inst* 90:455-460, 1998
4. Wolff H, Saukkonen K, Anttila S, et al: Expression of cyclooxygenase-2 in human lung carcinoma. *Cancer Res* 58:4997-5001, 1998
5. Mohammed SI, Knapp DW, Bostwick DG, et al: Expression of cyclooxygenase-2 (COX-2) in human invasive transitional cell carcinoma (TCC) of the urinary bladder. *Cancer Res* 59:5647-5650, 1999
6. Smith WL, Garavito RM, DeWitt DL: Prostaglandin endoperoxide synthases (cyclooxygenases)-1 and -2. *J Biol Chem* 271:33157-33160, 1996
7. Samuelsson B, Dahlen SE, Lindgren JA, et al: Leukotrienes and lipoxins: Structures, biosynthesis, and biological effects. *Science* 237:1171-1176, 1987
8. Sheng H, Shao J, Kirkland SC, et al: Inhibition of human colon cancer cell growth by selective inhibition of cyclooxygenase-2. *J Clin Invest* 99:2254-2259, 1997
9. Tsujii M, DuBois RN: Alterations in cellular adhesion and apoptosis in epithelial cells overexpressing prostaglandin endoperoxide synthase 2. *Cell* 83:493-501, 1995
10. Honn KV, Tang DG, Grossi I, et al: Tumor derived 12(S)-hydroxycycosetetraenoic acid induces microvascular endothelial cell retraction. *Cancer Res* 54:565-574, 1994
11. Tsujii M, Kawano S, DuBois RN: Cyclooxygenase-2 expression in human colon cancer cells increases metastatic potential. *Proc Natl Acad Sci U S A* 94:3336-3340, 1997
12. Nie D, Hillman GG, Geddes T, et al: Platelet-type 12-lipoxygenase in a human prostate carcinoma stimulates angiogenesis and tumor growth. *Cancer Res* 58:4047-4051, 1998
13. Tsujii M, Kawano S, Tsuji S, et al: Cyclooxygenase regulates angiogenesis induced by colon cancer cells. *Cell* 93:705-716, 1998
14. Tjandrawinata RR, Dahiya R, Hughes-Fullford M: Induction of cyclo-oxygenase-2 mRNA by prostaglandin E₂ in human prostatic carcinoma cells. *Br J Cancer* 75:1111-1118, 1997
15. Liu X-H, Yao S, Kirschenbaum A, et al: NS398, a selective cyclooxygenase-2 inhibitor, induces apoptosis and down-regulates bcl-2 expression in LNCaP cells. *Cancer Res* 58:4245-4249, 1998
16. Ghosh J, Myers CE: Arachidonic acid stimulates prostate cancer cell growth: Critical role of 5-lipoxygenase. *Biochem Biophys Res Commun* 235:418-423, 1997
17. Ghosh J, Myers CE: Inhibition of arachidonate 5-lipoxygenase triggers massive apoptosis in human prostate cancer cells. *Proc Natl Acad Sci U S A* 95:13182-13187, 1998
18. Anderson KM, Seed T, Vos M, et al: 5-Lipoxygenase inhibitors reduce PC-3 cell proliferation and initiate nonnecrotic cell death. *Prostate* 37:161-173, 1998
19. Gao X, Grignon DJ, Ghibi H, et al: Elevated 12-lipoxygenase mRNA expression correlates with advanced stage and poor differentiation of human prostate cancer. *Urology* 46:227-237, 1995
20. Chaudry AA, Wahle KWJ, McClinton S, et al: Arachidonic acid metabolism in benign and malignant prostatic tissue in vitro: Effects of fatty acids and cyclooxygenase inhibitors. *Int J Cancer* 57:176-180, 1994
21. Brash AR, Boeglin WE, Chang MS: Discovery of a second 15S-lipoxygenase in humans. *Proc Natl Acad Sci U S A* 94:6148-6152, 1997
22. Kilty I, Logan A, Vickers PJ: Differential characteristics of human 15-lipoxygenase isozymes and a novel splice variant of 15S-lipoxygenase. *Eur J Biochem* 266:83-93, 1999
23. Shappell SB, Boeglin WE, Olson SJ, et al: 15-Lipoxygenase-2 (15-LOX-2) is expressed in benign prostatic epithelium and reduced in prostate adenocarcinoma. *Am J Pathol* 155:235-245, 1999
24. Nagy L, Tontonoz P, Alvarez JGA, et al: Oxidized LDL regulates macrophage gene expression through ligand activation of PPARgamma. *Cell* 93:229-240, 1998
25. Kubota T, Koshizuka K, Williamson EA, et al: Ligand for peroxisome proliferator-activated receptor gamma (Troglitazone) has potent antitumor effect against human prostate cancer both in vitro and in vivo. *Cancer Res* 58:3344-3352, 1998
26. Mueller E, Sarraf P, Tontonoz P, et al: Terminal differentiation of human breast cancer through PPARgamma. *Mol Cell* 1:465-470, 1998
27. Gleason D: Histologic grading and clinical staging of carcinoma of the prostate, in Tannenbaum M (ed): *Urologic Pathology: The Prostate*. Philadelphia, PA, Lea & Febiger; 1977, pp 171-198
28. Bostwick DG, Myers RP, Oesterling JE: Staging of prostate cancer. *Semin Surg Oncol* 10:60-72, 1994
29. Bostwick DG, Amin MB, Dundore P, et al: Architectural patterns of high-grade prostatic intraepithelial neoplasia. *HUM PATHOL* 24:298-310, 1993
30. Epstein JI, Grignon DJ, Humphrey PA, et al: Interobserver reproducibility in the diagnosis of prostatic intraepithelial neoplasia. *Am J Surg Pathol* 19:873-886, 1995
31. Tambolini P, Amin M, Xu HJ, et al: Immunohistochemical expression of retinoblastoma and p53 tumor suppressor genes in prostatic intraepithelial neoplasia: Comparison with prostatic adenocarcinoma and benign prostate. *Mod Pathol* 11:247-252, 1998
32. Funk CD: The molecular biology of mammalian lipoxygenases and the quest for eicosanoid functions using lipoxygenase-deficient mice. *Biochim Biophys Acta* 1304:65-84, 1996
33. Bryant RW, Bailey JM, Schewe T, et al: Positional specificity of a reticulocyte lipoxygenase: Conversion of arachidonic acid to 15S-hydroperoxy-cycosetetraenoic acid. *J Biol Chem* 257:6050-6055, 1982
34. Epstein JI, Partin AW, Sauvageot J, et al: Prediction of progression following radical prostatectomy: A multivariate analysis of 721 men with long-term follow-up. *Am J Surg Pathol* 20:286-292, 1996
35. Greene DR, Wheeler TM, Egawa S, et al: A comparison of the morphological features of cancer arising in the transition zone and in the peripheral zone of the prostate. *J Urol* 146:1069-1076, 1991
36. McNeal JE, Redwine EA, Freiha FS, et al: Zonal distribution of prostatic adenocarcinoma: Correlation with histologic pattern and direction of spread. *Am J Surg Pathol* 12:897-906, 1988
37. Bostwick DG: Prospective origins of prostate carcinoma: Prostatic intraepithelial neoplasia and atypical adenomatous hyperplasia. *Cancer* 78:330-336, 1996
38. McNeal JE, Villers AA, Redwine EA, et al: Histologic differentiation, cancer volume, and pelvic lymph node metastasis in adenocarcinoma of the prostate. *Cancer* 66:1225-1233, 1990
39. McNeal JE: Cancer volume and site of origin of adenocarcinoma in the prostate: Relationship to local and distant spread. *HUM PATHOL* 23:258-266, 1992
40. Ruijter E, Van De Kaa C, Miller G, et al: Molecular genetics and epidemiology of prostate carcinoma. *Endoc Rev* 20:22-45, 1999
41. Yasunaga Y, Shin M, Fujita MQ, et al: Different patterns of p53 mutations in prostatic intraepithelial neoplasia and concurrent carcinoma: Analysis of microdissected specimens. *Lab Invest* 78:1275-1279, 1998
42. Bostwick DG, Pacelli A, Lopez-Beltran A: Molecular biology of prostatic intraepithelial neoplasia. *Prostate* 29:117-134, 1996

**Alterations in Lipoxygenase and Cyclooxygenase-2 Catalytic Activity and mRNA
Expression in Prostate Carcinoma**

Scott B. Shappell^{1,2,3}, Suzanne Manning^{1,3}, William E. Boeglin⁴, You-Fei Guan⁵,
Linda Davis⁵, Gregory S. Jack¹, Christopher S. Coffey⁶, Thomas M. Wheeler⁷,
Matthew D. Breyer^{2,5}, Alan R. Brash^{2,4}

Department of Pathology¹, Vanderbilt Ingram Cancer Center², Vanderbilt Prostate Cancer
Center³, Department of Pharmacology, Division of Clinical Pharmacology⁴, Department of
Medicine, Division of Nephrology and Veterans Affairs Hospital⁵, Department of Preventive
Medicine⁶, Vanderbilt University Medical Center, Nashville, TN and Departments of Pathology
and Urology, Baylor College of Medicine⁷, Houston, TX

Running Title: Arachidonate Metabolism in Prostate Cancer

Supported in part by Department of Defense Grant DAMD17-98-1-8637 (S.B.S.), a VUMC
Intramural Interdisciplinary Grant (S.B.S.), a Discovery Grant in Prostate Cancer Research from
the Vanderbilt Ingram Cancer Center (S.B.S., A.R.B.), National Institutes of Health Grant GM-
53638 (A.R.B.), and by a Specialized Program of Research Excellence (SPORE) Grant (NCI-
CA58204) (T.M.W.)

Corresponding Author: Scott B. Shappell, M.D., Ph.D.
Dept. of Pathology, C-3321 Medical Center North
Vanderbilt University Medical Center
Nashville, TN, 37232-2561
Phone: 615-343-2338
Fax: 615-343-7023
e-mail: scott.shappell@mcmail.vanderbilt.edu

ABSTRACT

Recent studies in human prostate tissues and prostate carcinoma cell lines have suggested possible roles for arachidonic acid (AA) metabolizing enzymes in prostate adenocarcinoma (Pca) development or progression. The goal of this study was to more fully characterize AA metabolism and lipoxygenase (LOX) and cyclooxygenase-2 (COX-2) gene expression in benign and malignant prostate tissues. Portions of snap frozen 6 mm tissue cores obtained intraoperatively during radical prostatectomy were examined histologically, by Northern analysis and/or Rnase protection assay and in situ hybridization, and by enzyme assay (incubation with [¹⁴C]AA and reversed-phase HPLC analysis of the metabolites). Formation of 15-hydroxyecosatetraenoic acid (15-HETE) was detected in 23/29 benign samples from 26 patients and 15-LOX-2 mRNA was detected by Northern analysis in 21/25 benign samples. In pairs of pure benign and Pca from the same patients, 15-HETE production and 15-LOX-2 mRNA (normalized to GAPDH) were reduced in Pca vs. benign in 9/14 and 14/17, respectively (p=0.04 and p=0.002, respectively). Under the same conditions, neither 5-HETE nor 12-HETE formation was detectable in 29 benign and 24 tumor samples; with a more sensitive assay, traces were detected in some samples, but there was no clear association with tumor tissue. COX-2 mRNA was detected by nuclease protection assay in 7/16 benign samples and 5/16 tumors. In a comparison of benign and tumor pairs from 10 patients, COX-2 was negative in both in five, positive in benign/ negative in tumor in three, and negative in benign/ positive in tumor in two. By in situ hybridization, COX-2 mRNA expression was essentially equal in five of 10 benign-tumor pairs, greater in benign in three, and greater in tumor in only two. In conclusion, reduced 15-LOX-2 expression and 15-HETE formation is the most characteristic alteration of AA

metabolism in Pca. Increased 12-HETE and 5-HETE formation in Pca were not discernible. Increased COX-2 expression may occur in some Pcas, but it is not a frequent or characteristic abnormality.

Abbreviations:

AA = arachidonic acid; COX-2 = cyclooxygenase 2; 15-HETE = 15-hydroxyeicosatetraenoic acid; 5-LOX = 5-lipoxygenase; 12-LOX = 12-lipoxygenase; 15-LOX-2 = 15-lipoxygenase-2; Pca = prostate carcinoma

Key words: arachidonic acid; eicosanoids; HETEs; 15-lipoxygenase-2; 5-lipoxygenase; 12-lipoxygenase; cyclooxygenase

INTRODUCTION

Factors involved in normal growth and differentiation of the prostate include androgens, stromal-epithelial interactions, and a variety of polypeptide growth factors (Bonkhoff and Remberger, 1996; Cunha, 1996; Lee, 1996; Steiner, 1993). Mediators derived from membrane lipids may also contribute to normal prostate differentiation and function. Understanding how factors responsible for normal prostate cellular differentiation are changed in cancer or how abnormal regulatory pathways are acquired in malignant cells is crucial to the development of novel treatment strategies in prostate cancer (Pca). Recent studies have suggested possible roles for altered arachidonic acid (AA) metabolism in abnormal growth and differentiation of Pca cells and in tumor cell invasion, metastasis, and stimulation of angiogenesis. By immunohistochemistry, we have previously demonstrated the uniform expression of 15-LOX-2 in differentiated secretory cells of benign prostate and reduction of 15-LOX-2 in most Pcas (Shappell et al, 1999). Utilizing fresh (not snap) frozen tissues, we have shown that benign prostate synthesized 15-HETE from exogenous AA and 15-HETE formation was reduced in Pca vs. benign in a small number of pairs of benign and tumor from the same radical prostatectomy (RP) specimens (Shappell et al, 1999). A recent study also showed that reduced 15-LOX-2 immunostaining in tumor correlated with grade, with retention in most Gleason score 5 tumors (most of which included at least a component of transition zone Gleason pattern 2 tumor) vs. a significant reduction in Gleason score ≥ 6 . 15-LOX-2 immunostaining was also reduced in high grade prostatic intraepithelial neoplasia compared to benign glands, suggesting that this may be an early alteration in Pca development, at least in some cases (Jack et al, 2000).

Others have reported increased platelet type 12-LOX mRNA by semi-quantitative RT-PCR in Pca vs. benign, particularly in high grade, high stage tumors (Gao et al, 1995). Studies

in Pca cell lines have demonstrated a possible role for 12-HETE in tumor angiogenesis (Nie et al, 1998). Experiments by other investigators in cell lines have also suggested a possible role for 5-LOX in Pca cell proliferation (Anderson et al, 1998; Ghosh and Myers, 1997; Ghosh and Myers, 1998). To our knowledge, increased 5-HETE or 12-HETE formation has not been reported in Pca tissues (as opposed to cell lines). In addition to these investigations on lipoxygenases, recent studies in cell lines have also suggested a role for COX-2 in Pca cell proliferation (Liu et al, 1998; Tjandrawinata et al, 1997).

Prostate cancer is clinically, genetically, and molecularly heterogeneous (Ruijter et al, 1999). It is crucial to validate that changes in pathways studied in cell lines occur in human tumor tissues. The goal of the current study was to utilize histologically well characterized snap frozen prostate tissues, with good RNA and enzyme function preservation, to further explore the changes in AA metabolism characteristic of Pca.

RESULTS

Histologic examination of snap frozen prostate samples: Snap frozen prostate tissues were obtained intraoperatively using 6 mm punch biopsies as described (Wheeler and Lebovitz, 1994). In 60 patients, two of the eight cores collected from each prostate were selected as benign or tumor based on correlation with the pathology in whole mount sections (Wheeler and Lebovitz, 1994). These cores were processed for RNA, formalin fixation and paraffin embedding, and AA incubation enzyme assays as shown in Figure 1. The length of each biopsy processed for the studies reported herein was approximately 5 mm, or roughly the thickness of tissue submitted for routine light microscopic sections. The histology of the middle portion was thus taken as indicative of tissue processed for RNA and enzyme assays. The results of

histologic examination of the pairs of tissues utilized are summarized in Table 1. A total of 22 of the 60 pairs were composed of pure benign and pure tumor from individual patients (See Methods for criteria for classification). Other benign, tumor, and mixed tissues were also utilized as indicated in the Results below.

15-LOX-2 expression in benign and malignant prostate: By Northern analysis, 15-LOX-2 mRNA was detected in 21/25 benign samples. In 17 pairs of pure benign and Pca from the same patient, 15-LOX-2 mRNA was detected in 15/17 benign samples and 12/17 tumor samples. 15-LOX-2 mRNA (normalized to GAPDH) was significantly reduced in tumor vs. benign ($p=0.002$), with 14/17 pairs having reduced 15-LOX-2 levels in tumor, two pairs in which 15-LOX-2 was not detected in either benign or malignant, and one case with higher 15-LOX-2 in tumor (Figure 2). In the 14 pairs in which message was reduced in tumor, 15-LOX-2 mRNA was present in benign but not detectable in tumor in three. In the other 11, 15-LOX-2 was an average of 5.3-fold higher in benign (range 1.02 – 17.8 fold).

15-HETE formation in benign and malignant prostate: 15-HETE formation from exogenous AA was detected in 23/29 incubations of benign prostate from 26 patients (including those in which paired benign and tumor tissues were incubated, as described below). As observed previously with fresh (not snap) frozen prostate, 15-HETE was the major AA metabolite formed under these conditions. In the positive benign incubations, the conversion of 50 μ M exogenous AA to 15-HETE was 2.95 ± 2.95 % (mean \pm S.D.; range 0.74 to 11.8 %). 15-HETE formation was also detected in incubations of 6/6 samples of mixed benign and tumor; the percent conversion of exogenous AA in these mixed samples was 3.16 ± 5.12 % (mean \pm S.D.; range 0.61 to 13.5 %). 15-HETE formation was detected in only 1/4 pure tumors in which benign tissue was not available from the same patient. Of the six negative benign samples, one

had transitional metaplasia and one had atrophy, conditions known to be negative for 15-LOX-2 by immunohistochemistry (Shappell et al, 1999). Three of the other four were composed predominantly (greater than half) of stroma, also known to be negative for 15-LOX-2 (Shappell et al, 1999). The one positive pure tumor (without a paired benign sample) had particularly prominent 15-HETE formation (14.8 % conversion). This level of catalytic activity was even greater than that in benign samples in the current series. This tumor also had prominent 15-LOX-2 mRNA expression (not shown). Histologically, this tumor (at least the portion incubated and analyzed for RNA) was composed of cribriform Gleason pattern 4 (Gleason score 4 + 4 = 8) (not shown). Several tumors with this morphology have been previously observed to have positive 15-LOX-2 immunostaining in contrast to the usual reduction or loss of 15-LOX-2 immunostaining in Pca (Jack et al, 2000).

In pairs of pure benign and Pca from the same patient, 15-HETE production from AA was present in 9 of 14 benign samples and 5 of 14 tumor samples. The mean \pm S.D. for percent AA conversion was 2.79 ± 3.7 % for benign and 0.37 ± 0.60 % for tumor, considering all 14 cases. 15-HETE formation was significantly reduced in tumor vs. benign ($p=0.04$), with 9/14 pairs having reduced 15-HETE in tumor, three pairs with 15-HETE detected in tumor but not benign, and two pairs for which 15-HETE was not detected in either (Figure 3). Of the nine pairs for which 15-HETE was reduced in tumor, seven also had reduced 15-LOX-2 mRNA. (No 15-LOX-2 mRNA was detected in benign or tumor in one pair; northern data was not generated in one pair). For the two pairs in which 15-HETE was not detected in either benign or tumor, Northern blot data for 15-LOX-2 was not generated for one, and only faint 15-LOX-2 mRNA was detected in the other pair (benign > malignant). For the three pairs in which 15-HETE was detected in tumor but not benign, one found no 15-LOX-2 mRNA in benign or tumor, one had

increased 15-LOX-2 mRNA in benign, and no northern data was generated for the third. The data as presented is not adjusted for glandular content of the incubated specimen. As 15-LOX-2 is present in benign glands and in malignant epithelium in those tumors which are 15-LOX-2 positive (Shappell et al, 1999) and stroma may contribute to the total amount of protein incubated per sample, the differences between benign and tumor may be even more pronounced as the gland content is generally higher in the tumor portions (greater gland content in tumor vs. benign in 13/14 incubated pairs; essentially equal in 1/14; not shown). Whereas several negative benign samples were composed predominantly (> 50 %) of stroma, all of the incubated tumors, were composed predominantly (greater than one half) of glandular epithelium.

Analysis of possible 5- and 12-lipoxygenase activity in benign and malignant prostate:

The methodology employed in the tissue incubations allows for the simultaneous detection of other AA metabolites besides 15-HETE. Under assay conditions in which 15-HETE production is readily apparent in the majority of benign prostate incubations, there was no detectable 5-HETE or 12-HETE production in benign prostates (n=29). The reports suggesting possible increased platelet type 12-LOX in Pcas have shown a correlation with high tumor grade (Gao et al, 1995) and most of the data suggesting a potential role for 5- and 12-LOX has been generated in cancer cell lines, which are established from high grade/advanced tumors. Hence we anticipated the possible production of these metabolites primarily in tumor incubations, and therefore we included a number of high grade tumors in the analyses (Gleason score ≥ 7). Under the usual HPLC conditions (injection of one-fifth of incubation extracts) in which 15-HETE is readily detectable in benign prostate, neither 5-HETE nor 12-HETE production were detected in any of 24 tumor AA incubations (6 mixed benign and tumor, 18 pure tumor).

In order to examine the samples for possible low levels of 5-HETE or 12-HETE, we re-analyzed a subset of the same samples (5 benign-tumor pairs and 3 additional tumors) by injection of the remaining four-fifths of the incubation extracts. The tumor samples included one each of Gleason score 5, 6, and 7, and five of Gleason score 8. Trace levels of 5-HETE (<0.25 % AA conversion) were formed in two of five benign and two of eight tumor samples. Trace levels of 12-HETE (<0.5 % AA conversion) were detected in one of five benign and two of eight tumor samples. In paired samples, there was no indication of increased 5-HETE or 12-HETE in tumor versus benign.

In order to be certain that our assay conditions were adequate to detect 5-HETE and 12-HETE formation and that no inhibiting effect of the prostate homogenates was present, prostate homogenates negative for 5- and 12-HETE production were incubated with purified recombinant human platelet-type 12-LOX and with leukocyte extracts as a source of 5-LOX. As shown in Figure 4, these positive controls showed 12-HETE and 5-HETE formation, overall similar in magnitude to buffer incubations without prostate homogenate (> 75 % equivalent peak heights in spiked prostate homogenates compared to control buffer). These results confirm the ability to detect 5- and 12-HETE formation when enzyme activity is present and show that prostate homogenates have any necessary co-factors for enzyme activity and do not possess inhibiting substances for these LOX enzymes.

COX-2 mRNA in benign and malignant prostate: COX-2 mRNA analysis by multiple methods showed no consistent difference between benign peripheral zone prostate and prostate adenocarcinoma. COX-2 mRNA was detected by Rnase protection assays in 7/16 benign and 5/16 tumors samples. In benign and tumor pairs from 10 patients, COX-2 was negative in both

in 5; positive in benign/ negative in tumor in 3; negative in benign/ positive in tumor in 2 (Figure 5).

In situ hybridization for COX-2 mRNA was performed on formalin-fixed paraffin-embedded portions of 32 snap frozen samples (15 benign and 17 tumor samples, including paired benign and tumor from 10 patients). COX-2 mRNA expression was detected in both glands and stroma (including vessels) of benign and malignant prostate. Similar to the protection assays, however, there was no discernable consistent difference in COX-2 expression between benign and malignant prostate. Of 15 benign prostate samples, 8 showed at least focal (> 25 %) expression in epithelium of benign glands (Figure 6); 3 showed only rare (approximately 5 %) positive glands, and 4 were negative. Of 17 tumor samples, 7 showed at least focal (> 25 %) COX-2 expression in malignant epithelium, 7 showed only rare or scattered epithelial expression, and 3 were negative (Figure 6). In 10 pairs of benign and tumor, 5/10 showed essentially similar levels of expression in both benign and malignant, 3/10 showed a greater degree of expression in benign vs. tumor, and only 2/10 showed greater expression in tumor vs. benign (Figure 6).

Correlation of COX-2 expression and PG formation: Prostaglandin (PG) production was not generally conspicuous in benign and tumor samples under our usual HPLC conditions. In a subset of cases subjected to an expanded HPLC analysis of a greater sample volume (see methods), trace PGE₂ formation (< 0.25 % AA conversion) and hydroxyheptadecatrienoic acid (HHT) formation (<0.5 % AA conversion) were detected in two of three separate tumors, in one tumor of a benign-tumor (Gleason score 7) pair (<0.5 % AA conversion) and in the benign of a separate benign-tumor (Gleason score 9) pair (< 1.0 % AA conversion). One tumor case (patient 3 in Table 2) for which benign tissue was not available showed particularly strong COX-2

expression, both by in situ hybridization (Figure 6G) and protection assay (not shown). This tumor, a Gleason 4 + 4 = 8, is the same case as that described above that showed prominent 15-LOX-2 mRNA expression and 15-HETE formation from exogenous AA. This tumor made trace amounts of PGE₂ and HHT (<0.5 % AA conversion) under our assay conditions. Two other tumors which formed detectable PGE₂ and HHT had positive COX-2 mRNA, whereas two additional tumors with COX-2 mRNA expression did not form detectable COX metabolites. In general, no clear correlation existed between the presence of mRNA for COX-2 and COX metabolite formation under assay conditions employed. These results are summarized in Table 2.

DISCUSSION

Alterations in expression and activity of AA metabolizing enzymes may be fundamentally important in the development and/or progression of Pca. These enzymes or the receptors for their products also represent attractive targets for existing or potential future pharmacologic agents. Although data from cell lines suggests possible roles of lipoygenases and COX-2 in regulating neoplastic prostate cell growth, very little information exists regarding these pathways in prostate tissues. Utilizing snap frozen prostate tissues, we have demonstrated that benign prostate characteristically synthesizes 15-HETE from exogenous AA. Almost all of the examined benign samples made 15-HETE, and 15-HETE was the major AA metabolite formed. Similar to our previous observations with fresh (not snap) frozen prostate (Shappell et al, 1999), the enzymatic properties of this 15-LOX activity, including specific oxygenation at the 15-carbon without appreciable simultaneous formation of 12-HETE, are characteristic of 15-LOX-2 vs. the 15-LOX-1 typical of peripheral blood leukocytes (Brash et al, 1997; Bryant et al,

1982). Furthermore, by immunohistochemistry 15-LOX-2 is expressed in differentiated secretory cells of benign prostate glands (Shappell et al, 1999), and in the current study, 15-LOX-2 mRNA was detected in the vast majority of benign prostate samples. Occasional negative benign samples might be attributed to a greater proportion of stroma in the specimen (as 15-LOX-2 is not expressed in the prostatic stroma) or benign changes in sampled glandular tissue, such as transitional metaplasia or atrophy, which are also negative for 15-LOX-2 by immunostaining (Shappell et al, 1999). The results of the current study also extend previous observations of reduced 15-LOX-2 immunostaining in Pca vs. benign (Jack et al, 2000; Shappell et al, 1999), as 15-LOX-2 mRNA and 15-HETE formation were reduced in snap frozen Pca vs. benign in a high percentage of cases. These results would indicate that reduction or loss of 15-LOX-2 in Pca occurs at the transcriptional level. The function of 15-LOX-2 derived 15-HETE in benign prostate and the mechanism whereby its reduction contributes to Pca remain to be fully determined. 15-HETE activated transcription by the nuclear receptor PPAR γ in *in vitro* transfection assays (Nagy et al, 1998), and studies in murine macrophages have shown that a 12/15-LOX is involved in PPAR γ activation by IL-4 (Huang et al, 1999). We have recently shown that 15-HETE activates PPAR γ transcription and inhibits proliferation in PC-3 Pca cells (Shappell et al, 2000). Hence, reduced 15-LOX-2 may contribute to Pca development or progression by altered expression of PPAR γ -regulated genes.

Kelavkar et al. recently observed increased 15-LOX-1 immunostaining in Pca, with possible correlation with tumor grade and p53 accumulation (Kelavkar et al, 1999). As benign prostate expresses such an abundant 15-lipoxygenase activity (15-LOX-2), it is crucial to compare any 15-LOX activity in malignant tissues to benign tissues in the same patient. In our previous study employing fresh (not snap) frozen tissues, trace 15-HETE was detected in only

one tumor in three benign-tumor pairs (Shappell et al, 1999). In our current study, we did observe 15-HETE formation by a similar percentage of tumors. 15-HETE formation in six admixed benign and tumor tissues may represent the contribution of benign glands or subtotal loss of activity in cancer portions. 15-HETE formation was detected in 1 of 4 pure tumors without benign counterparts and 5 of 14 tumors in benign-tumor pairs. Hence, overall 6 of 18 pure tumors made 15-HETE. Whether this was due to 15-LOX-1 or 15-LOX-2 was not specifically addressed, as we did not examine 15-LOX-1 expression in the current series. However, as in benign samples, the product profiles in tumors are more consistent with 15-LOX-2, and 15-LOX-2 mRNA was detected in at least some such tumors (Figure 2), including very strongly in a high grade tumor that made prominent 15-HETE. If reduced 15-LOX-2 is characteristic of Pca and if some such tumors also upregulate 15-LOX-1, it will be important to determine what pathways may be regulated by 15-HETE in benign and malignant prostate cells. 15-HETE formed in benign and malignant cells could exert different functions depending on what other changes have occurred in tumor cells or in the tumor microenvironment.

Recent studies in Pca cell lines indicated a possible contribution of 5-LOX and 5-HETE to cancer cell growth. Low levels of 5-HETE production were detected in PC-3 cells exposed to exogenous AA, which was inhibited by 5-LOX inhibitors. Exogenous AA stimulated cell growth, which was also blocked by 5-LOX inhibitors (Ghosh and Myers, 1997). Subsequent studies have demonstrated detection of 5-LOX and 5-lipoxygenase activating protein (FLAP) in Pca cell lines by PCR and inhibition of proliferation and induction of apoptosis with selective 5-LOX and FLAP inhibitors (Anderson et al, 1998; Ghosh and Myers, 1998). To our knowledge, however, 5-LOX mRNA, protein, or activity have not been reported in actual Pca tissues. In our current study, only trace levels of 5-HETE were detected in occasional benign and tumor

samples, and increased 5-LOX activity was not detected as a characteristic alteration in Pca vs. benign.

Utilizing RT-PCR techniques, Gao et al. (Gao et al, 1995) reported that 12-LOX mRNA was elevated in 46 of 122 (38 %) prostate tumor samples compared to normal tissue from the same patient. 12-LOX mRNA was more likely to be elevated in tumor vs. control tissue in patients with extracapsular extension (T3), positive lymph nodes, higher grade lesions (Gleason score 8), and positive surgical margins (Gao et al, 1995). Substantial *in vitro* data suggests that 12-HETE in cell lines may function in tumor cell invasion and metastasis (Chen et al, 1994; Honn et al, 1994; Tang and Honn, 1994). Data in cell lines and nude mice suggests that 12-HETE may contribute to tumor growth and angiogenesis (Nie et al, 1998). The RT-PCR results in actual prostate tissues is supported by in situ hybridization studies (Gao et al, 1995), but to our knowledge no data on 12-LOX protein or enzyme activity have been published in prostate tissues. In our study, increased 12-HETE formation was not a detectable alteration in Pca under our usual assay conditions. With a more sensitive assay, trace amounts of 12-HETE were detected in occasional benign and tumor tissues (which included a number of high grade tumors), with no discernible alteration in Pca vs. benign. It remains to be demonstrated whether levels of 5-LOX and 12-LOX too low to lead to detectable catalytic activity in our assays may be expressed in high grade Pcas in a manner sufficient to contribute to tumor growth, invasion, or angiogenesis.

The role for altered COX-2 in human carcinoma has been most supported by studies in colon cancer, including epidemiologic studies showing reduced colon cancer incidence and mortality with NSAIDs capable of inhibiting COX-2 (Giardiello et al, 1993; Rosenberg et al, 1991; Thun et al, 1991). Studies in human colon cancer tissues and cell lines and mouse models

of colon cancer have supported a role for COX-2 upregulation in colon carcinogenesis (Eberhart et al, 1994; Kargman et al, 1995; Kutchera et al, 1996; Oshima et al, 1996; Sheng et al, 1997; Williams et al, 1996). Data also exists indicating COX-2 upregulation in carcinomas of the stomach (Ristimaki et al, 1997), lung (Wolff et al, 1998), breast (Hwang et al, 1998), and urinary bladder (Komhoff et al, 2000; Mohammed et al, 1999). The mechanisms by which COX-2 derived prostaglandins or other AA metabolites might contribute to carcinoma development or progression are not precisely defined, but potentially include protection against apoptosis (Tsuji and DuBois, 1995) and contribution to tumor angiogenesis (Masferrer et al, 2000; Sawaoka et al, 1999; Tsujii et al, 1998). Few data exist on COX-2 expression in benign and malignant prostate. COX-2 mRNA has been reported in Pca cell lines (Liu et al, 1998; Tjandrawinata et al, 1997). A study in the LNCaP Pca cell line showed induction of apoptosis with high concentrations of a selective COX-2 inhibitor, although actual inhibition of enzyme activity was not demonstrated (Liu et al, 1998).

It is crucial to validate pathways in cell lines with expression patterns in benign and tumor tissues. Gupta et al. recently reported COX-2 mRNA upregulation in snap frozen malignant vs. benign prostate from the same patients utilizing RT-PCR (Gupta et al, 2000). In our study increased COX-2 was not a characteristic alteration in Pca by nuclease protection assays and in situ hybridization. Differences between our results for COX-2 mRNA in pairs of benign and malignant prostate from the same radical prostatectomies and those recently published by Gupta et al. (Gupta et al, 2000) are likely due at least in part to differences in the methodologies employed. Although less sensitive than RT-PCR, nuclease protection assays are more sensitive than Northern blots and are quantitative. We only detected COX-2 mRNA utilizing this technique in approximately half of the samples analyzed (benign or malignant).

However, in those pairs of benign and tumor in which COX-2 was detected, increased COX-2 was not a common or uniform alteration in Pca. When mRNA expression is potentially limited to a fraction of the cell population, in situ hybridization may be more sensitive than nuclease protection assay. By in situ hybridization, we observed that COX-2 is often expressed in benign prostate glands and may be unaltered or actually decreased in tumor compared to benign. Gupta et al. reported that COX-2 was expressed in benign prostate by immunohistochemistry and was increased in Pca (Gupta et al, 2000). Some controversy exists regarding the specificity of COX-2 antibodies in immunohistochemistry (McKanna et al, 1998). This issue of specificity was addressed in the current study by employing riboprobes for in situ hybridization based on sequences unique to COX-2 vs. COX-1 (Komhoff et al, 2000). Although COX-2 mRNA was often reduced or similar in tumor compared to benign, it was increased in some tumors. No precise correlation existed between the presence of mRNA for COX-2 and COX metabolite formation under assay conditions employed. Whether COX-1 contributes to product formation in some cases is not known, but likely. Regardless, message analysis would indicate that increased COX-2 in tumor vs. benign is not a typical change in prostate cancer. These results challenge the emerging view that COX-2 upregulation is a common manifestation of malignancy (in the prostate).

The lack of a consistent alteration in COX-2 expression does not mean that up-regulation is not important in those specific cases in which COX-2 is elevated in tumors. Strong message and modest product formation were detected in some cases. Prostate cancer is remarkably heterogeneous (Ruijter et al, 1999). It will be crucial in the future to correlate altered expression of these enzymes with histopathologic features or other molecular phenotypic or genetic changes to potentially uncover a subset of prostate cancers which may benefit from COX-2

inhibition. A recent study demonstrated focal increased COX-2 in a high percentage of spontaneous adenocarcinomas in the dog (Tremblay et al, 1999). In a transgenic mouse model of Pca generated with a long probasin promoter and the SV40 large T-antigen (Kasper et al, 1998), we have observed focal COX-2 immunostaining in a lesion analogous to human HGPIN (manuscript in preparation) in a specific mouse line which progresses from HGPIN, to microinvasive carcinoma, to invasive and metastatic poorly differentiated carcinoma with neuroendocrine differentiation (Masumori et al, 2000). Identifying specific subsets of human Pca in which COX-2 is altered will potentially allow for the applications of these animal models in delineating mechanisms whereby such changes affect malignant cells and for testing pharmacologic interventions.

MATERIALS AND METHODS

Tissue procurement, processing, histologic characterization, and RNA extraction: Snap frozen tissues were obtained intraoperatively during radical prostatectomy as described previously (Wheeler and Lebovitz, 1994). 6 mm punch biopsies from multiple transition zone and peripheral zone sites within the prostate (right and left, mid to apex and mid to base) yield cores approximately 1 to 1.5 cm in length, which are immediately placed in liquid nitrogen. Cores are correlated with pathology findings in whole mount processed totally embedded prostates (Wheeler and Lebovitz, 1994). Pairs of possible benign and tumor containing cores from the peripheral zone of individual patients were retrieved from a maintained data base. For the current study, 60 pairs of these tissues were processed for RNA and enzyme assays as shown in Figure 1, with careful correlation to the specific histology of the tissue actually processed for these analyses. The 1-2 mm thick transverse section for histology (portion 2 in Figure 1) was

immediately placed in 10 % buffered formalin for routine processing and paraffin embedding. 5 um cross sections were stained with H & E and assessed for benign, tumor, or mixed and amount of glands and stroma (both estimated as percent of tissue section). Greater or equal to 85 % benign was considered benign, greater or equal to 85 % tumor was considered tumor, and all other combinations of benign and tumor were considered mixed. Grade of tumor was recorded to verify that it corresponded to the index tumor of the radical prostatectomy surgical pathology report, and any unique features of benign glands were noted.

For RNA isolation, two to three mm transverse slices (approximately 50 mg) (Portion 1 in Figure 1) were diced with fine scissors in 1 ml Tri Reagent (Molecular Research Center, Inc., Cincinnati, OH). Approximately 100 microliters of autoclaved 200 micron glass beads (BioSpec Products, Bartlesville, OK) were added and tissue was further disrupted by two 20 second periods of agitation on a Mini-Beadbeater (BioSpec Products), placing the specimen on ice in between cycles. RNA was then extracted using the Tri Reagent protocol according to manufacturer's instructions. RNA was quantitated by determining optical density at 260 and 280 nm. This procedure generally yielded 50-100 ug RNA per sample, which was uniformly intact based on ethidium bromide stained gels and visualization of ribosomal RNA bands.

15-lipoxygenase-2 Northern blots: 20 ug total RNA per sample was electrophoresed in 1.2 % agarose/formaldehyde gels and transferred to Nylon membranes (Nytran SuPerCharge, 0.45 um pore size, Schleicher & Schuell, Keene, N.H.). Membranes were pre-hybridized for ≥ 1 hour at 42 °C in ULTRAhyb (Ambion, Austin, TX). Blots were hybridized overnight at 42 °C with 1×10^6 cpm/ml each of ^{32}P -labeled cDNA probes for 15-LOX-2 and GAPDH in ULTRAhyb. The 15-LOX-2 probe was a 1088 bp cDNA amplified by PCR from a partial cDNA in pcDNA3 (Stratagene, La Jolla, CA), with primers 5'-TG-CCT-CTC-GCC-ATC-CAG-CT-3'

and 5'-TGG-GAT-GTC-ATC-TGG-GCC-TGT-3'. The GAPDH probe was an 1100 bp cDNA (Clontech, Palo Alto, CA). Probes were labeled by Rediprime II random priming (Amersham, Arlington Heights, IL). After hybridization, membranes were washed twice for 5 minutes in 2x SSC with 0.05 % SDS and twice for 15 minutes in 0.1 x SSC with 0.1 % SDS. Blots were exposed to a phosphorimaging screen (Super resolution screen, Packard Instrument Co., Inc., Meriden, CT) for 1 to 4 hrs. at room temperature and imaged on a Cyclone Storage Phosphor System (Packard) and/or exposed to Kodak X-OMAT film at - 80 °C for 1 to 3 days. Band intensities were determined using OptiQuant software (for phosphorimager) or by scanning and utilization of NIH Image Analysis software (for film). The Wilcoxon Signed Rank test was used to compare the ratio of 15-LOX-2 band intensity to that of the housekeeping gene GAPDH in groups of benign and malignant from the same patients (run and blotted at the same time).

Cyclooxygenase-2 mRNA analysis: COX-2 mRNA expression in benign or tumor was assessed by nuclease protection assays (Komhoff et al, 2000). The radioactive riboprobe for COX-2 was a 471 bp fragment from the 3' untranslated region (specific for COX-2 vs. COX-1), synthesized from 1 ug of linearized plasmid using the MAXIscript™ kit (Ambion) for one hour at 37 °C in a total volume of 20 µl. The reaction buffer contained 10 mM dithiothreitol, 0.5 mM ATP, 0.5 mM CTP, 0.5 mM GTP, 2.5 mM UTP, and 5 µl of 800 Ci/mmol of [α -³²P] UTP at 10 mCi/ml. Hybridization was performed with the RPA II kit (Ambion) with a buffer of 80 % deionized formamide, 100 mM sodium citrate, pH 6.4, and 1 mM EDTA using 10 ug total RNA and 5 x 10⁴ cpm labelled COX-2 and beta actin probes for 12 hours at 45 °C. Subsequent ribonuclease digestion was performed at 37 °C for 30 min. and precipitated, protected fragments were separated on 4 % polyacrylamide gels at 200 V for 3 hours. Gels were exposed to Kodak XAR-5 film overnight at -80 °C.

In situ hybridization was performed on formalin-fixed paraffin embedded sections (portion 2 of the cores, processed for histology as in Figure 1). A riboprobe specific for COX-2 vs. COX-1 was employed as described (Komhoff et al, 2000). Briefly, sections were deparaffinized, refixed in paraformaldehyde, treated with proteinase K (20 µg/ml), washed with phosphate-buffered saline, refixed in 4 % paraformaldehyde, treated with triethanolamine plus acetic anhydride (0.25 % by volume), and dehydrated with 100 % ethanol. The 471 basepair ³⁵S-labeled antisense and sense riboprobes from the COX-2 specific 3'-untranslated region of the cDNA were hybridized to the sections for 18 hours at 55 °C. Sections were then washed x1 with 5x SSC plus 10 mM β-mercaptoethanol at 65 °C, x1 in 50 % formamide in 2X SSC with 100 mM β-mercaptoethanol for 30 min., and x3 in 10 mM Tris, 5 mM EDTA, and 500 mM NaCl (TEN) at 37 °C. Sections were subsequently treated with Rnase A (10 ug/ml) at 37 °C for 30 min, followed by wash x1 with TEN at 37 °C and x2 in each of 2X SSC and 0.1X SSC at 65 °C. Slides were dehydrated with graded ethanols with 300 mM ammonium acetate and dipped in photoemulsion (Ilford k5, Knutsford, Cheshire, England) diluted 1:1 with 2 % glycerol, and exposed for 4 days at 4 °C. Slides were developed in Kodak D-19 and counterstained with hematoxylin. Slides were reviewed blindly (including without knowledge of being parts of benign-tumor pairs) with a Zeiss Axioskop microscope using bright field and dark field optics, and areas of benign and tumor on each slide were assessed as to negative for COX-2, rare positive, focal (> 25 %) positive, and diffuse (> 75 %) positive.

Arachidonic acid incubations and reverse-phase HPLC analysis: To approximately 50 mg of the snap frozen cores (portion 3 in Figure 1) 4 volumes of ice cold buffer was added (50 mM Tris, pH 7.4, containing 150 mM NaCl and 100µM CaCl₂), and the samples were then diced with fine scissors, sonicated for 10 sec using the microprobe of a Virtis VirSonic 100 at a setting

of 5, and further homogenized on ice using a hand-held Dounce homogenizer designed to fit an Eppendorf tube. After centrifugation at 5000 rpm for 1 min in a benchtop centrifuge, the supernatant was retained and protein concentration determined by the method of Bradford (Bio-Rad, Hercules, CA). 700 ug protein of each sample was incubated in 100 μ l of the same buffer, begun by addition of 50 μ M (final concentration) [$1\text{-}^{14}\text{C}$]AA (New England Nuclear, Boston, MA) in ethanol, with final solvent concentration less than or equal to 1 %. Samples were incubated for 45 min. at 37 °C with continual agitation and terminated by addition of 2.5 volume ice cold methanol. Lipid extraction and C18 Sep-Pak extraction were performed as previously described (Shappell et al, 1999). The extracts were analyzed by reverse phase HPLC using a Beckman Ultrasphere 5- μ m ODS column (25 x 0.46 cm). Simultaneous injection of unlabeled 5-, 8-, 9-, 11-, 12-, and 15-HETE allowed exact determination of retention times of each HETE. UV spectra and the profiles at 205, 220, 235, and 270 nm were recorded using a Hewlett-Packard 1040A diode array detector. Radioactivity was generally monitored with an on-line Radiomatic Instruments Flo-One detector (Shappell et al, 1999). The usual RP-HPLC assay conditions were injection of one-fifth of the incubated sample, with a solvent system of methanol/water/glacial acetic acid at 80:20:0.01 (by vol.), a flow rate of 1.1 ml/min.. This results in a retention time for 15-HETE of approximately 15 min. and adequate resolution of the other HETEs (Shappell et al, 1999). The Wilcoxon Signed Rank test was used to compare the ratio of 15-HETE formation in groups of benign and malignant from the same patients (incubated and run at the same time). In a subset of benign and tumor pairs, to detect possible low levels of other HETEs, a solvent system of methanol/water/glacial acetic acid at 77.5:22.5:0.01 (by vol.) was employed at a flow rate of 1.0 ml/min with collection of 0.5 min fractions and 10 min. scintillation counting (to increase the signal to noise ratio).

Although possible prostaglandin production may be suggested by the presence of more polar metabolites eluting early in the reverse phase HPLC run, the above solvent systems do not allow for adequate separation of individual cyclooxygenase metabolites, such as PGE₂, from other prostaglandins or other possible polar products not derived from COX metabolism. In a subset of tumors and benign-tumor pairs, attention was focused on possible prostaglandin formation using a solvent system of acetonitrile/water/glacial acetic acid (35:65:0.01, by vol.) 0-20 min., acetonitrile/water/glacial acetic acid (60:40:0.01, by vol.) 20-40 min., 100 % methanol 40-60 min. at 1.1 ml/min, with coinjection of cold TxB₂, 6-keto-PGF_{1α}, PGF_{2α}, PGE₂, PGD₂, HHT, 15-HETE, 11-HETE, 8-HETE, 12-HETE, 9-HETE, and 5-HETE and in-line radiodetection.

Incubations of exogenous platelet-type 12-LOX and 5-LOX with prostate homogenates used pure recombinant 12-LOX (Oxford Biochemicals, Oxford, MI), 2 μl of 0.21 mg/ml enzyme added to 50 μl of prostate homogenate, or sonicates of a human granulocyte/platelet preparation. In each case the amount of the exogenous source of LOX enzyme(s) was tested beforehand for activity in buffer alone. An amount sufficient to give 10-20% metabolism of added arachidonic acid was then added to fresh prostate homogenates which were prepared from an aliquot of frozen tissue that had been assayed previously for enzyme activity.

REFERENCES

Anderson KM, Seed T, Vos M, Mulshine J, Meng J, Alrefai W, Ou D, and Harris JE (1998). 5-lipoxygenase inhibitors reduce PC-3 cell proliferation and initiate nonnecrotic cell death.

Prostate 37:161-173

Bonkhoff H and Remberger K (1996). Differentiation pathways and histogenetic aspects of normal and abnormal prostatic growth: a stem cell model. Prostate 28:98-106

Brash AR, Boeglin WE, and Chang MS (1997). Discovery of a second 15S-lipoxygenase in humans. Proc Natl Acad Sci USA 94:6148-6152

Bryant RW, Bailey JM, Schewe T, and Rapoport SM (1982). Positional specificity of a reticulocyte lipoxygenase. Conversion of arachidonic acid to 15S-hydroperoxy-eicosatetraenoic acid. J Biol Chem 257:6050-6055

Chen YQ, Duniec ZM, Liu B, Hagmann W, Gao X, Shimoji K, Marnett LJ, Johnson CR, and Honn KV (1994). Endogenous 12S-HETE production by tumor cells and its role in metastasis.

Cancer Res 54:1574-1579

Cunha GR (1996). Growth factors as mediators of androgen action during male urogenital development. Prostate Suppl 6:22-25

Eberhart CE, Coffey RJ, Radhika A, Giardiello FM, Ferrenbach S, and DuBois RN (1994).

Upregulation of cyclooxygenase-2 gene expression in human colorectal adenomas and adenocarcinomas. *Gastroenterology* 107:1183-1188

Gao X, Grignon DJ, Chbihi T, Zacharek A, Chen YQ, Sakr W, Porter AT, Crissman JD, Pontes JE, Powell IJ, and Honn KV (1995). Elevated 12-lipoxygenase mRNA expression correlates with advanced stage and poor differentiation of human prostate cancer. *Urology* 46:227-237

Ghosh J and Myers CE (1997). Arachidonic acid stimulates prostate cancer cell growth: critical role of 5-lipoxygenase. *Biochem Biophys Res Com* 235:418-423

Ghosh J and Myers CE (1998). Inhibition of arachidonate 5-lipoxygenase triggers massive apoptosis in human prostate cancer cells. *Proc Natl Acad Sci USA* 95:13182-13187

Giardiello FM, Hamilton SR, Krush AJ, Piantadosi S, Hylind LM, Celano P, Booker SV, Robinson CR, and Offerhaus GJ (1993). Treatment of colonic and rectal adenomas with sulindac in familial adenomatous polyposis. *N Engl J Med* 328:1313-1316

Gupta S, Srivastava M, Ahmad N, Bostwick DG, and Mukhtar H (2000). Over-expression of cyclooxygenase-2 in human prostate adenocarcinoma. *Prostate* 42:73-78

Honn KV, Tang DG, Grossi I, Duniec ZM, Timar J, Renaud C, Leithauser M, Blair IA, Johnson CR, Diglio CA, Kimler VA, Taylor JD, and Marnett LJ (1994). Tumor derived 12(S)-

hydroxyeicosatetraenoic acid induces microvascular endothelial cell retraction . *Cancer Res* 54:565-574

Huang JT, Welch JS, Ricote M, Binder CJ, Willson TM, Kelly C, Witztum JL, Funk CD, Conrad D, and Glass CK (1999). Interleukin-4-dependent production of PPAR-gamma ligands in macrophages by 12/15-lipoxygenase. *Nature* 400:378-382

Hwang D, Scollard D, Byrne J, and Levine E (1998). Expression of cyclooxygenase-1 and cyclooxygenase-2 in human breast cancer. *J Natl Cancer Inst* 90:455-460

Jack GS, Brash AR, Olson SJ, Manning S, Coffey CS, Smith J, Jr., and Shappell SB (2000). Reduced 15-lipoxygenase-2 immunostaining in prostate adenocarcinoma: Correlation with grade and expression in high grade prostatic intraepithelial neoplasia. *Hum Pathol* (in press)

Kargman SL, O'Neill G, Vickers PJ, Evans JF, Mancini JA, and Jothy S (1995). Expression of prostaglandin G/H synthase-1 and -2 protein in human colon cancer. *Cancer Res* 55:2556-2559

Kasper S, Sheppard PC, Yan Y, Pettigrew N, Borowsky AD, Prins GS, Dodd JG, Duckworth ML, and Matusik RJ (1998). Development, progression and androgen-dependence of prostate tumors in transgenic mice: A model for prostate cancer. *Lab Invest* 78:319

Kelavkar UP, Cohen C, Eling TE, and Badr KF (1999). 15-lipoxygenase-1 expression in prostate cancer: correlation with mutant p53 and histologic grade. 6th International Conference on Eicosanoids and Other Lipids in Cancer, Inflammation and Related Diseases. Boston: (Abstract)

Komhoff M, Guan Y, Shappell HW, Davis L, Jack G, Shyr Y, Koch MO, Shappell SB, and Breyer MD (2000). Enhanced expression of cyclooxygenase-2 in high grade human transitional cell bladder carcinomas. *Am J Pathol* 157:29-35

Kutchera W, Jones DA, Matsunami N, Groden J, McIntyre TM, Zimmerman GA, White RL, and Prescott SM (1996). Prostaglandin H synthase 2 is expressed abnormally in human colon cancer: evidence for a transcriptional effect. *Proc Natl Acad Sci USA* 93:4816-4820

Lee C (1996). Role of androgen in prostate growth and regression: stromal-epithelial interaction. *Prostate Suppl* 6:52-56

Liu X-H, Yao S, Kirschenbaum A, and Levine AC (1998). NS398, a selective cyclooxygenase-2 inhibitor, induces apoptosis and down-regulates bcl-2 expression in LNCaP cells. *Cancer Res* 58:4245-4249

Masferrer JL, Leahy KM, Koki AT, Zweifel BS, Settle SL, Woerner BM, Edwards DA, Flickinger AG, Moore RJ, and Seibert K (2000). Antiangiogenic and antitumor activities of cyclooxygenase-2 inhibitors. *Cancer Res* 60:1306-1311

Masumori N, Thomas TZ, Kasper S, Chaurand P, Caprioli R, Tsukamoto T, Shappell S, and Matusik RJ (2000). A probasin-large T antigen transgenic mouse line develops neuroendocrine and metastatic prostatic cancer. *J Urol* 163:96a (abstract)

McKanna JA, Zhang MZ, Wang JL, Cheng H, and Harris RC (1998). Constitutive expression of cyclooxygenase-2 in rat vas deferens. *Am J Physiol* 275:R227-233

Mohammed SI, Knapp DW, Bostwick DG, Foster RS, Khan KNM, Masferrer JL, Woerner BM, Snyder PW, and Koki AT (1999). Expression of cyclooxygenase-2 (COX-2) in human invasive transitional cell carcinoma (TCC) of the urinary bladder. *Cancer Res* 59:5647-5650

Nagy L, Tontonoz P, Alvarez JGA, Chen H, and Evans RM (1998). Oxidized LDL regulates macrophage gene expression through ligand activation of PPARgamma. *Cell* 93:229-240

Nie D, Hillman GG, Geddes T, Tang K, Pierson C, Grignon DJ, and Honn KV (1998). Platelet-type 12-lipoxygenase in a human prostate carcinoma stimulates angiogenesis and tumor growth. *Cancer Res* 58:4047-4051

Oshima M, Dinchuk JE, Kargman SL, Oshima H, Hancock B, Kwong E, Trzaskos JM, Evans JF, and Taketo MM (1996). Suppression of intestinal polyposis in *Apc delta716* knockout mice by inhibition of cyclooxygenase 2 (COX-2). *Cell* 87:803-809

Ristimaki A, Honkanen N, Jankala H, Sipponen P, and Harkonen M (1997). Expression of cyclooxygenase-2 in human gastric carcinoma. *Cancer Res* 57:1276-1280

Rosenberg L, Palmer JR, Zauber AG, Warshauer ME, Stolley PD, and Shapiro S (1991). A hypothesis: nonsteroidal anti-inflammatory drugs reduce the incidence of large-bowel cancer. *J Natl Cancer Inst* 83:355-358

Ruijter E, Van De Kaa C, Miller G, Ruiter D, Debruyne F, and Schalken J (1999). Molecular genetics and epidemiology of prostate carcinoma. *Endocrine Rev* 20:22-45

Sawaoka H, Tsuji S, Tsujii M, Gunawan ES, Sasaki Y, Kawano S, and Hori M (1999). Cyclooxygenase inhibitors suppress angiogenesis and reduce tumor growth in vivo. *Lab Invest* 79:1469-1477

Shappell SB, Boeglin WE, Olson SJ, Kasper S, and Brash AR (1999). 15-lipoxygenase-2 (15-LOX-2) is expressed in benign prostatic epithelium and reduced in prostate adenocarcinoma. *Am J Pathol* 155:235-245

Shappell SB, Gupta R, Manning S, Boeglin WE, Case T, Jack GS, Whitehead R, Price J, Matusik RJ, Brash AR, and DuBois RN (2000). 15-hydroxyeicosatetraenoic acid (15-HETE) activates peroxisome proliferator activated receptor gamma and inhibits proliferation in PC3 prostate carcinoma cells. 11th International Conference on Advances in Prostaglandin and Leukotriene Research: Basic Science and New Clinical Applications. Florence, Italy:(Abstract)

Sheng H, Shao J, Kirkland SC, Isakson P, Coffey RJ, Morrow J, Beauchamp RD, and DuBois RN (1997). Inhibition of human colon cancer cell growth by selective inhibition of cyclooxygenase-2. *J Clin Invest* 99:2254-2259

Steiner MS (1993). Role of peptide growth factors in the prostate: A review. *Urology* 42:99-110

Tang DG and Honn KV (1994). 12-lipoxygenase, 12(S)-HETE, and cancer metastasis. *Ann NY Acad Sci* 744:199-215

Thun MJ, Namboodiri MM, and Heath CW, Jr. (1991). Aspirin use and reduced risk of fatal colon cancer. *N Engl J Med* 325:1593-1596

Tjandrawinata RR, Dahiya R, and Hughes-Fulford M (1997). Induction of cyclo-oxygenase-2 mRNA by prostaglandin E2 in human prostatic carcinoma cells. *Br J Cancer* 75:1111-1118

Tremblay C, Dore M, Bochsler PN, and Sirois J (1999). Induction of prostaglandin G/H synthase-2 in a canine model of spontaneous prostatic adenocarcinoma. *J Natl Cancer Inst* 91:1398-1403

Tsujii M and DuBois RN (1995). Alterations in cellular adhesion and apoptosis in epithelial cells overexpressing prostaglandin endoperoxide synthase 2. *Cell* 83:493-501

Tsuji M, Kawano S, Tsuji S, Sawaoka H, Hori M, and DuBois R (1998). Cyclooxygenase regulates angiogenesis induced by colon cancer cells. *Cell* 93:705-716

Wheeler TM and Lebovitz RM (1994). Fresh tissue harvest for research from prostatectomy specimens. *Prostate* 25:274-279

Williams CS, Luongo C, Radhika A, Zhang T, Lamps LW, Nanney LB, Beauchamp RD, and DuBois RN (1996). Elevated cyclooxygenase-2 levels in Min mouse adenomas. *Gastroenterology* 111:1134-1140

Wolff H, Saukkonen K, Anttila S, Karjalainen A, Vainio H, and Ristimaki A (1998). Expression of cyclooxygenase-2 in human lung carcinoma. *Cancer Res* 58:4997-5001

TABLE 1

<u>Histologic classification of paired snap frozen tissues *</u>	<u>n</u>
Benign + Benign	15
Benign + Mixed	13
Mixed + Mixed	4
Benign + Tumor	22
Mixed + Tumor	2
Tumor + Tumor	2
<u>Other (including seminal vesicle)</u>	<u>2</u>
TOTAL	
60	

* Benign = > 85 % benign, Tumor = > 85 % tumor, mixed = all other combinations

TABLE 2

Correlation of COX-2 mRNA and Enzyme Activity in Select Samples

<u>Tissue Histology</u> ¹	<u>COX-activity (PGE2/HHT)</u>	<u>COX-2 mRNA Protection assay</u>	<u>COX-2 mRNA In situ hybrid.</u>
Benign - pt. 1	Pos	Neg	Neg
Tumor - pt. 1	Neg	Neg	Pos (diffuse glands)
Benign - pt. 2	Neg	Neg	N/D
Tumor - pt . 2	Pos	Neg	Pos (rare glands)
Tumor - pt. 3	Pos	Pos	Pos (diffuse glands)
Tumor - pt. 4	Pos	Pos	Pos (focal glands)
Tumor - pt. 5	Neg	Neg	+/- (rare glands)

¹ Patient numbers are arbitrary, to indicate paired samples, and do not correlate with numbers in Figure 2.

Figure Legends

Figure 1: Processing of 6 mm diameter snap frozen prostate cores for RNA extraction, histology, AA incubation enzyme assays, and OCT-embedded frozen sections.

Figure 2: Northern blots for 15-LOX-2 in benign and malignant prostate. Pairs of snap frozen histologically confirmed pure benign (**B**) and pure tumor (**T**) from radical prostatectomy specimens (subset of total cases examined). Simultaneously probed for housekeeping gene GAPDH. 15-LOX-2/GAPDH mRNA ratios indicated above individual lanes.

Figure 3: 15-HETE formation in pairs of snap frozen histologically confirmed pure benign and pure tumor from radical prostatectomy specimens. 45 min. incubations with 50 μ M [14 C]AA and RP-HPLC analysis with in line radiodetection and simultaneous injection of cold HETE standards. **A)** 15-HETE formation in representative benign prostate. **B)** Absent 15-HETE formation in tumor from same patient as in A. (Solvent system for A and B methanol/water/glacial acetic acid at 80:20:0.01, a flow rate of 1.1 ml/min, with retention time of 15-HETE approx. 17 min.) **C)** Composite results for 14 pairs of pure benign and pure tumor analyzed. Data are shown as percent of AA converted into 15-HETE. **D)** Prominent 15-HETE formation by a high grade tumor (cribriform Gleason 4 + 4 = 8). (Solvent system methanol/water/glacial acetic acid at 85:15:0.01, with retention time of 15-HETE approx. 10 min.). No benign tissue from the same patient was analyzed. This tumor had prominent 15-LOX-2 mRNA (not shown) and also expressed COX-2 mRNA (Panel G in Figure 6).

Figure 4: Detection of exogenously added 12-LOX (top) and 5-LOX (bottom) enzyme activity in prostate homogenates. **A)** 12-HETE formation from [¹⁴C]AA by purified recombinant human platelet 12-LOX in 45 min. incubation in buffer. **B)** RP-HPLC chromatogram of a prostate tumor homogenate incubated for 45 min. with [¹⁴C]AA showing trace formation of 15-HETE (Note different scale compared to A and C). **C)** Identical prostate homogenate as in B with added 12-LOX as in A, incubated for 45 min. with [¹⁴C]AA, showing prominent formation of 12-HETE (similar to buffer control). **D)** Peripheral blood leukocyte extract incubated in buffer for 45 min. with [¹⁴C]AA, showing expected mixture of 15-HETE, 12-HETE, and 5-HETE. **E)** RP-HPLC chromatogram of a prostate tumor homogenate incubated for 45 min. with [¹⁴C]AA, showing lack of detectable HETE formation. **F)** Identical prostate homogenate as in E with added leukocyte extract as in D, incubated for 45 min. with [¹⁴C]AA, showing prominent formation of 5-HETE (as well as 15- and 12-HETE).

Figure 5: COX-2 mRNA in benign and malignant prostate. Nuclease protection assays on pairs of snap frozen histologically confirmed pure benign (**B**) and pure tumor (**T**) from radical prostatectomy specimens (subset of total cases examined). Simultaneously analyzed for housekeeping gene β -actin.

Figure 6: In situ hybridization for COX-2 in benign and malignant prostate tissue sections. Formalin-fixed paraffin embedded sections of snap frozen cores were employed with a riboprobe specific for COX-2. **A)** Expression of COX-2 in benign prostate. Strong signal in benign gland, with focal negative areas within the gland corresponding to transitional metaplasia (on H & E stained adjacent section, not shown). **B)** Lack of detection of COX-2 in tumor (different case

from A). Cribriform high grade (Gleason pattern 4) portion shown. This case was also negative by protection assays. **C,D**) COX-2 expression in benign prostate (C) vs. lack of COX-2 expression in tumor (D) from same patient. **E,F**) Focal COX-2 expression in benign prostate (E) vs. stronger more diffuse expression in tumor (F) from same patient. **G**) Strong COX-2 expression in high grade tumor (Gleason pattern 4 portion shown). This tumor also showed strong 15-LOX-2 expression and formed prominent 15-HETE and detectable prostaglandins from exogenous AA. **H**) Lack of detectable COX-2 expression in a different high grade tumor (Gleason pattern 5 portion shown). No stronger signal in diffusely infiltrating tumor vs. scattered entrapped benign glands.

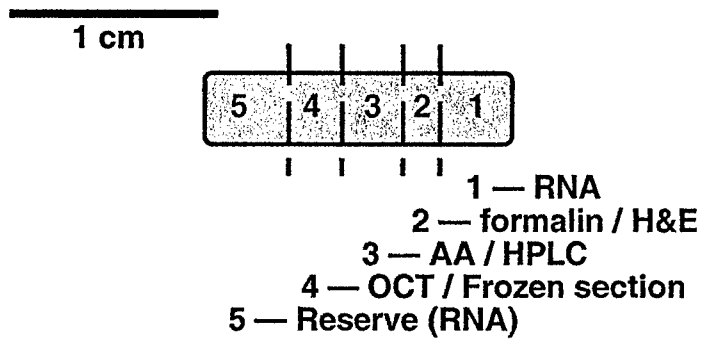
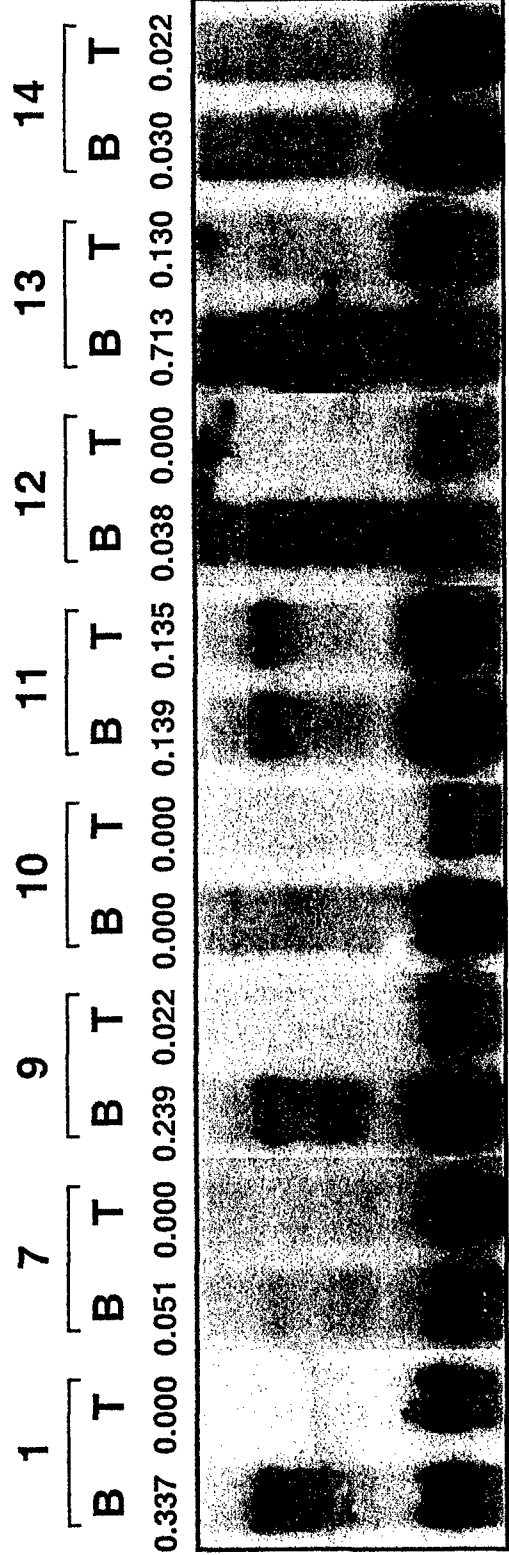
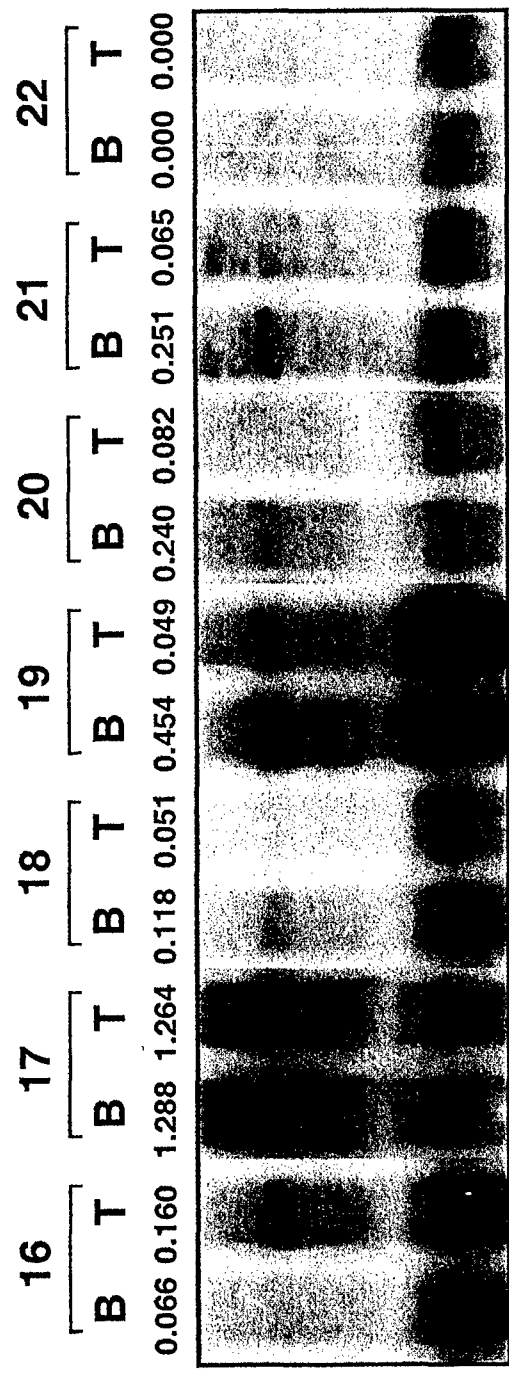


FIGURE 1



15-LOX-2
GAPDH



15-LOX-2
GAPDH

FIGURE 2

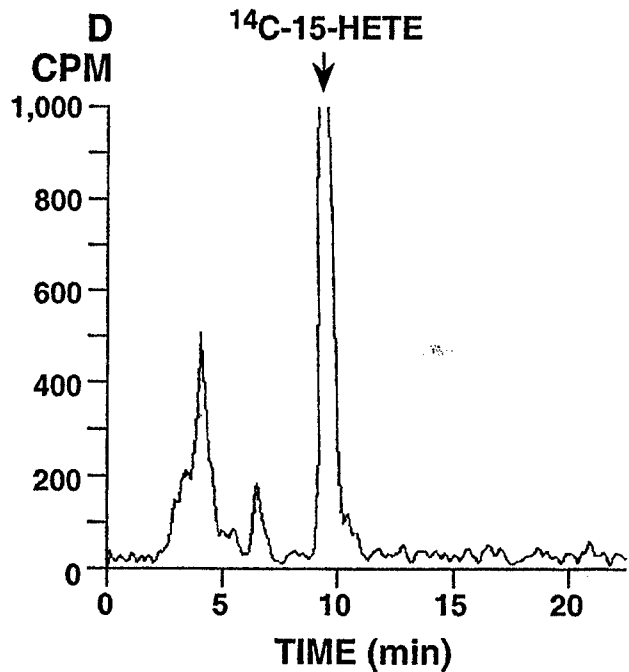
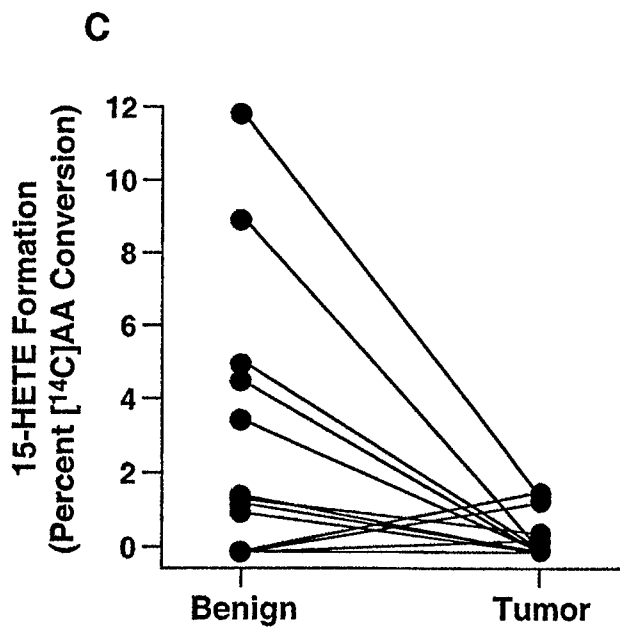
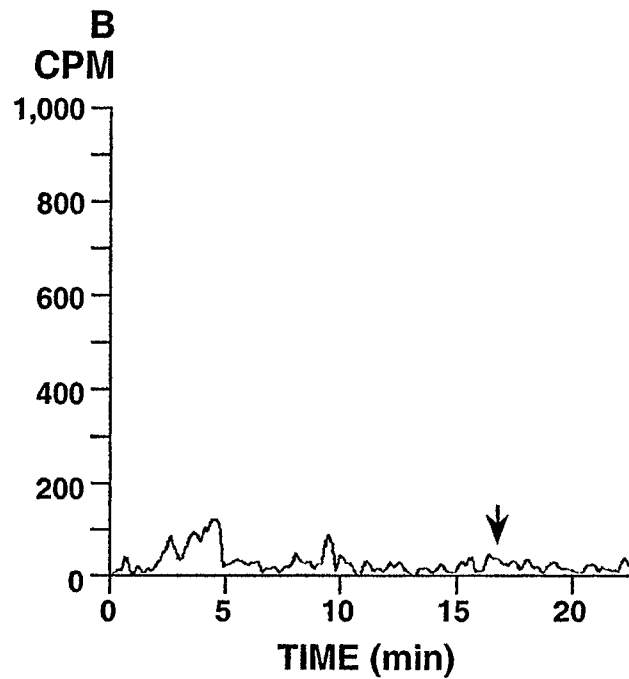
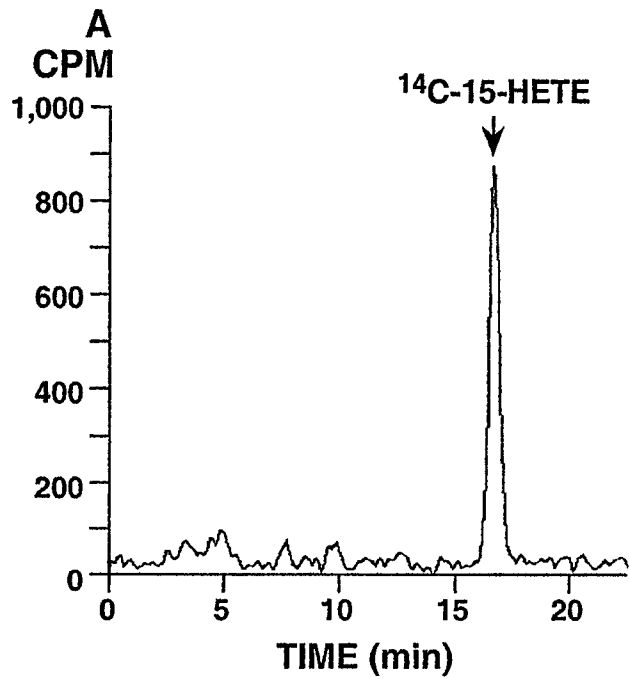


FIGURE 3

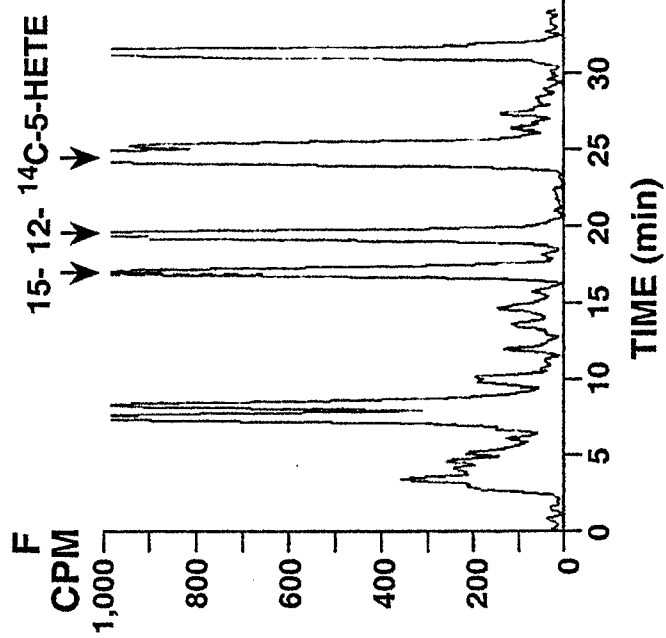
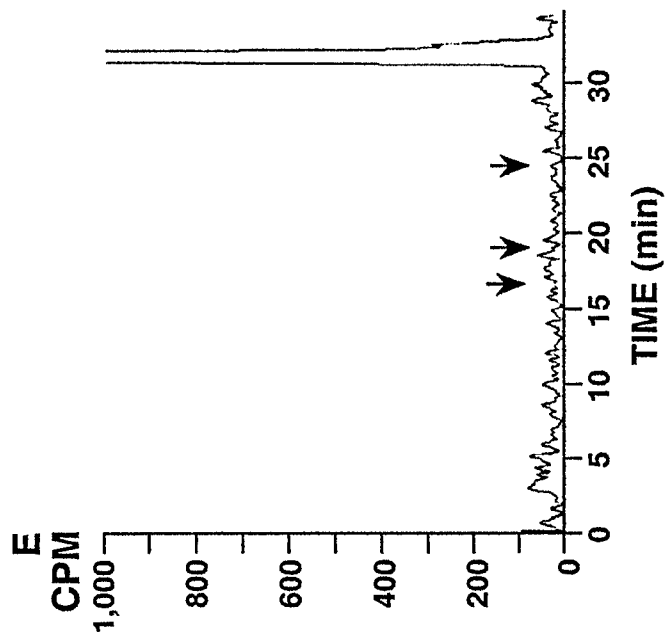
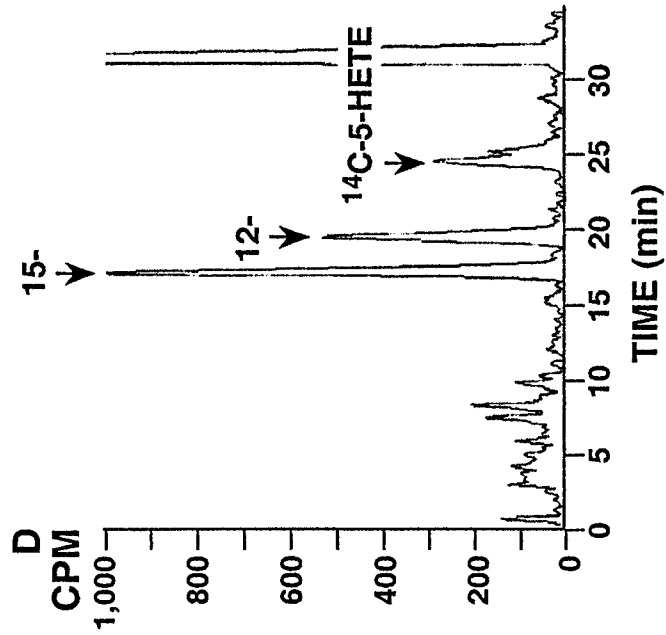
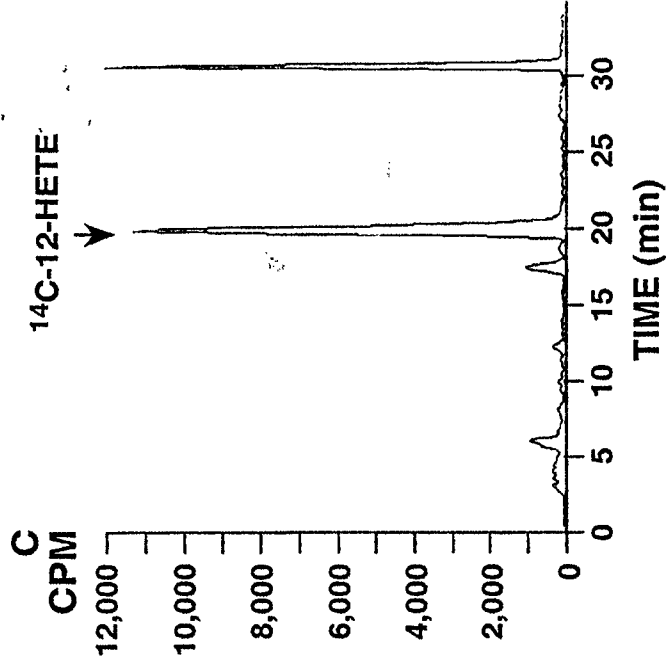
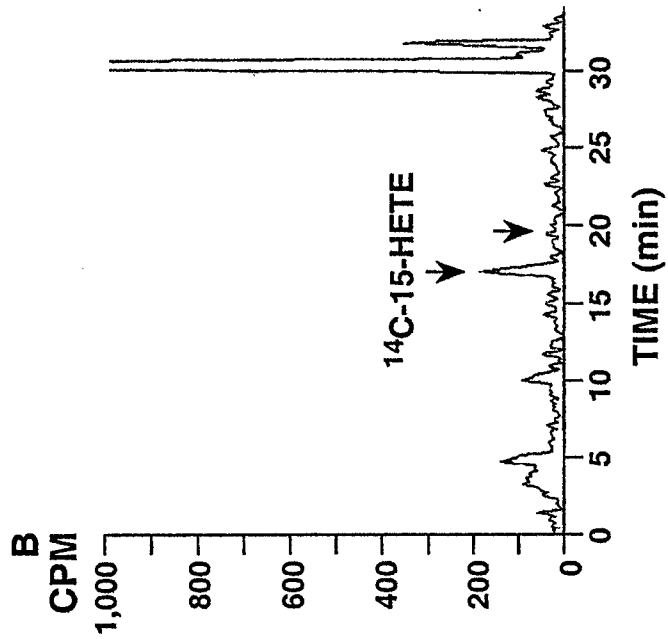
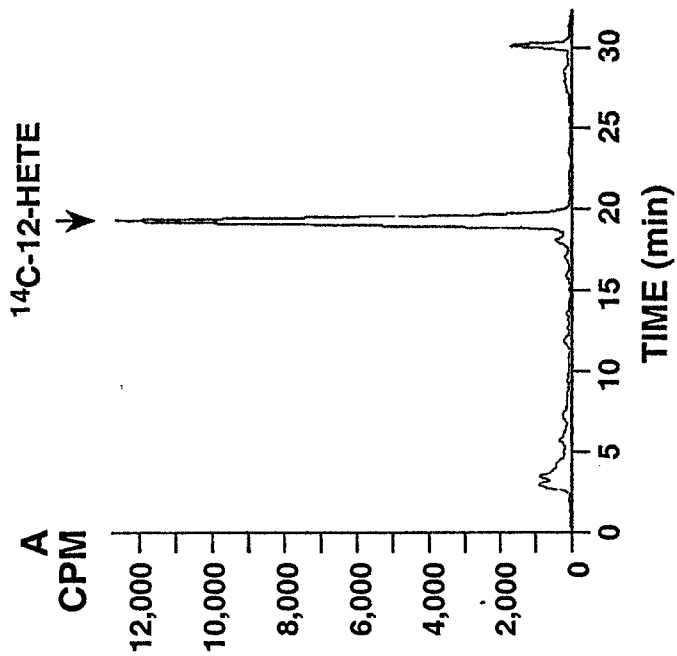


FIGURE 4



FIGURE 5

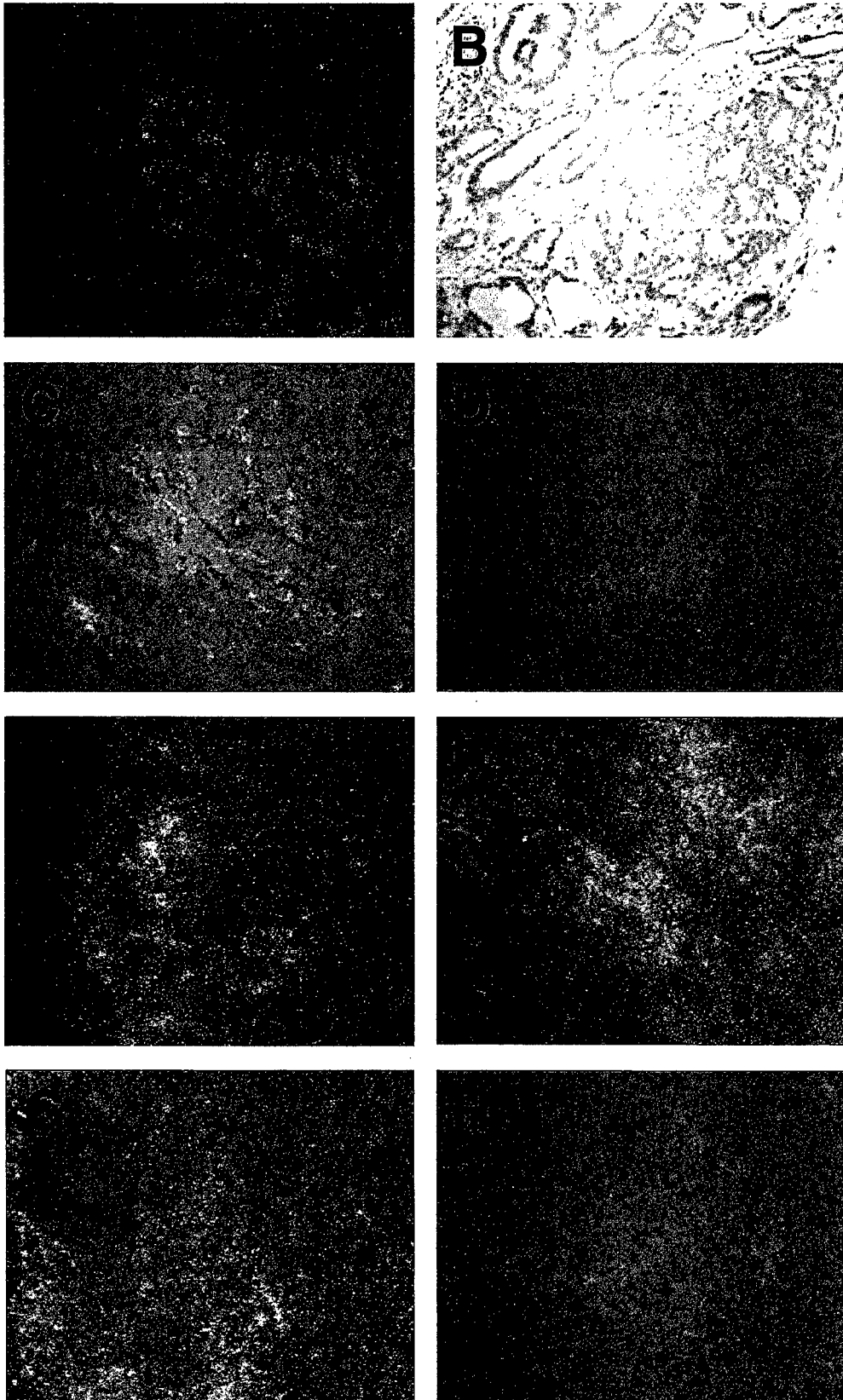


FIGURE 6

15-Hydroxyeicosatetraenoic acid (15-HETE) Activates Peroxisome Proliferator Activated Receptor Gamma (PPAR γ) and Inhibits Proliferation in PC3 Prostate Carcinoma Cells¹

Scott B. Shappell, Rajnish A. Gupta, Suzanne Manning, Robert Whitehead,

William E. Boeglin, Claus Schneider, Tom Case, James Price, Gregory S. Jack, Thomas M.

Wheeler, Robert J. Matusik, Alan R. Brash, Raymond N. DuBois

Department of Pathology (S.B.S., S.M., J.P., G.S.J.), Vanderbilt Prostate Cancer Center (S.B.S., S.M., R.J.M.), Vanderbilt-Ingram Cancer Center (S.B.S., R.W., R.J.M., A.R.B., R.N.D.), Department of Cell Biology (R.G., R.J.M., R.N.D.), Department of Medicine, Division of Gastroenterology (R.G., R.W., R.N.D.), Department of Pharmacology, Division of Clinical Pharmacology (W.E.B., C.S., A.R.B.), Department of Urology (T.C., R.J.M.), Vanderbilt University Medical Center; Department of Pathology and Laboratory Medicine, Veterans University Medical Center (J.P.), Nashville, TN; Departments of Pathology and Urology, Baylor College of Medicine and The Methodist Hospital, Houston, TX (T.M.W.)

Running Title: 15-HETE activates PPAR γ in PC3 Cells

Key words: Arachidonic acid; 15-lipoxygenase-2; prostate carcinoma; adipocyte type fatty acid binding protein

Footnotes

¹ Supported in part by Department of Defense Grant PC970260 (S.B.S.), a Vanderbilt University Intramural Interdisciplinary Discovery Grant (S.B.S.), a Discovery Grant from the Vanderbilt Ingram Cancer Center (S.B.S., A.R.B.), National Institutes of Health grant GM-53638 (A.R.B.), and a Specialized Program of Research Excellence (SPORE) grant (CA58204) from the National Cancer Institute (T.M.W.)

² To whom requests for reprints should be addressed, at Department of Pathology, C-3321 Medical Center North, Vanderbilt University Medical Center, Nashville, TN 37232-2561. Phone: 615-343-2338; Fax: 615-343-7023; e-mail: scott.shappell@mcmail.vanderbilt.edu

³ Abbreviations: AA, arachidonic acid; Pca, prostate carcinoma; 15-HETE, 15-hydroxyeicosatetraenoic acid; 15-LOX-2, 15-lipoxygenase-2; PG, prostaglandin; PPAR γ , peroxisome proliferator activated receptor; a-FABP, adipocyte type fatty acid binding protein; RP, radical prostatectomy.

Abstract

15-Lipoxygenase-2 (15-LOX-2) is expressed in benign prostate secretory cells and benign prostate produces 15-hydroxyeicosatetraenoic acid (15S-HETE) from exogenous arachidonic acid (AA). In contrast, 15-LOX-2 and 15-HETE formation are reduced in prostate carcinoma (Pca). The mechanisms whereby reduced 15-LOX-2 may contribute to Pca development or progression are not known. We investigated the expression of PPAR γ in benign and malignant prostate tissues and the ability of 15-HETE to activate PPAR γ dependent transcription and modulate proliferation of the Pca cell line PC3. In contrast to benign prostate and similar to most Pca tissues, 15-LOX-2 mRNA was not detected in PC3 cells and they did not produce detectable 15-HETE from [¹⁴C]AA. By RT-PCR, PPAR γ mRNA was present in 18/18 benign and 9/9 tumor specimens. The PPAR γ ligand BRL 49653 and 15-HETE caused a dose-dependent inhibition of PC3 proliferation in a 14 day soft agar colony forming assay (IC₅₀ of 3 and 30 μ M, respectively). 10 μ M 15S-HETE caused greater inhibition than 10 μ M 15R-HETE. At three days, BRL 49653 and 15S-HETE caused a slight increase in cells in G0/G1 and a corresponding decrease in cells in S-phase. In PC3 cells transiently transfected with a luciferase reporter linked to a PPAR response element (PPRE), 1 μ M BRL 49653 and 10 μ M 15S-HETE caused approximately 3-fold and greater than 2-fold induction of PPAR-dependent transcription, respectively. By quantitative real time RT-PCR and Northern analysis, three day treatment with BRL 49653 and 15S-HETE caused a reduction of PPAR γ expression but a marked upregulation of the PPRE containing adipocyte type fatty acid binding protein. These results support the hypothesis that 15-LOX-2 derived 15S-HETE may constitute an endogenous ligand for PPAR γ in the prostate and that loss of this pathway by reduced expression of 15-LOX-2 may contribute to increased proliferation and reduced differentiation in prostate carcinoma.

Introduction

Recent studies have supported the possible biologic significance of alterations in arachidonic acid (AA) metabolizing enzymes in prostate carcinoma (Pca). Studies in cell lines have indicated a possible contribution of 5-lipoxygenase (5-LOX) (1, 2) and cyclooxygenase-2 (COX-2) (3, 4) to Pca cell proliferation. Alterations in 5-LOX expression or 5-HETE formation have not been reported in actual Pca tissues, but recent studies have suggested possible increased expression of COX-2 in Pca (5). Increased 12-LOX mRNA has been reported in Pca compared to benign prostate (6), although increased 12-HETE levels or catalytic activity have not been reported in actual Pca tissues thus far.

We have previously demonstrated that the recently described 15-lipoxygenase-2 (15-LOX-2) (7) is uniformly expressed in the differentiated apical or secretory cells of benign prostate (8). Benign prostate tissue samples synthesize 15S-HETE as the major eicosanoid product from exogenous AA. In contrast, by immunostaining and enzyme activity assays, 15-LOX-2 and 15-HETE formation were reduced in Pca (8). More recently, utilizing paired snap frozen benign and malignant prostate tissue obtained intraoperatively (9), we have shown that 15-LOX-2 mRNA is reduced in tumor compared to benign in the majority (> 80 %) of patients and confirmed that reduced 15-HETE formation in tumor is indeed a common alteration (> 60 %) in Pca (Shappell, S.B., manuscript submitted). In addition, by immunostaining, reduced 15-LOX-2 correlated inversely with the degree of tumor differentiation, with retained expression in the majority of Gleason score 5 tumors compared to a statistically significant reduction in Gleason 6, 7, and 8-10 tumors (10). 15-LOX-2 was reduced in high grade prostatic intraepithelial neoplasia (HGPIN) compared to benign glands, indicating that this may be an early alteration in Pca development (10). The goal of the current study was to examine if loss of

15-LOX-2 expression may contribute to the malignant phenotype in Pca, by examining its effects on Pca cell proliferation. Studies examining oxidized low density lipoprotein and foam cell formation from macrophages have shown that 15-HETE may activate transcription by the nuclear receptor peroxisome proliferator activated receptor gamma (PPAR γ) (11) and other studies have shown inhibition of Pca cell line PC3 proliferation by synthetic PPAR γ agonists (12). Therefore, we compared the effects of 15-HETE to known PPAR γ agonists on PC3 cell proliferation and investigated the ability of 15-HETE to activate PPAR γ -dependent transcription in Pca cell lines.

Materials and Methods

Materials: PC-3 cells were obtained from the American Type Culture Collection (Rockville, MD) and cultured in Hams FK12 with 10 % FCS according to recommendations. Snap frozen human prostate tissues were obtained intraoperatively during radical prostatectomy (RP) as described previously (9). 6 mm punch biopsies from multiple transition zone and peripheral zone sites within the prostate yield cores approximately 1 to 1.5 cm in length, which are immediately placed in liquid nitrogen. 2-3 mm from one end of the cores were processed for RNA and the immediately adjacent 1-2 mm was processed for histology in order to be representative of the portion processed for RNA. The 1-2 mm thick transverse section for histology was immediately placed in 10 % buffered formalin for routine processing and paraffin embedding. 5 μ m cross sections were stained with H & E and assessed as benign, tumor, or mixed, with \geq 85 % benign glands considered benign, \geq 85 % tumor glands considered tumor.

BRL 49653 was synthesized by Glaxo Welcome. (PPRE) β -tk-luciferase (13) was provided by Dr. Ron Evans (The Salk Institute, San Diego, CA). The 15S-HETE was prepared

using the soybean lipoxygenase, as described (14). The 15R-HETE was prepared from 15S-HETE methyl ester by the following sequence: (i) stirring with activated manganese dioxide (10 mg/ml) in methylene chloride at room temperature for 2 hours, giving the 15-keto analogue in 20-30% yield, (ii) filtration through a silica column in 5% methanol in methylene chloride and isolation of the 15-ketoeicosatetraenoate product by normal phase HPLC (Alltech 5 μ silica column, solvent hexane/isopropanol, 100/1, by volume), (iii) reduction of the 15-keto derivative using sodium borohydride in methanol, (iv) isolation of the 15R and 15S enantiomers by chiral column chromatography using a Chiralpak AD column (Chiral Technologies, Inc, Exton, PA) and a solvent of hexane/ethanol (100:2, by volume), (v) saponification in aqueous 1M KOH/methanol (1:1) for two hours at room temperature, followed by (vi) repurification of the 15R-HETE by normal phase HPLC (hexane/isopropanol/glacial acetic acid (100/1/0.1, by volume). The 15R- and 15S-HETEs were quantified by uv spectroscopy using a molar extinction coefficient of 23,000 at 235 nm and stored in ethanol at -20°C at a concentration of 10 or 100 mM.

Northern blots and RT-PCR for 15-LOX-2 and PPAR γ mRNA: Subconfluent or confluent cultured cells were examined for 15-LOX-2 mRNA by Northern blot and RT-PCR (with benign prostate as positive control). Benign and malignant prostate tissues from RP specimens and cell lines were examined for PPAR γ mRNA by RT-PCR. For RNA isolation from prostate tissues, approximately 50 mg were diced with fine scissors in 1 ml Tri Reagent (Molecular Research Center, Inc., Cincinnati, OH). Approximately 100 microliters of autoclaved 200 micron glass beads (BioSpec Products, Bartlesville, OK) were added and tissue was further disrupted by two 20 second periods of agitation on a Mini-Beadbeater (BioSpec Products, Bartlesville, OK), placing the specimen on ice in between cycles. RNA was extracted from these homogenates and

cultured cells in T75 flasks using the Triazol reagent (Molecular Research Center, Inc., Cincinnati, Ohio), according to the manufacturer's instructions. For Northern blots, 20 ug total RNA was utilized and blots were hybridized overnight at 42 °C with 1×10^6 cpm/ml each of ^{32}P -labeled cDNA probes for 15-LOX-2 and GAPDH (prostate tissues and PC3 cells) or adipocyte type fatty acid binding protein (a-FABP) and GAPDH (untreated or treated PC3 cells) in ULTRAhyb (7). The 15-LOX-2 probe was a 1088 bp cDNA amplified by PCR from a partial cDNA in pcDNA3 (Stratagene, La Jolla, CA), with primers 5'-TGC-CTC-TCG-CCA-TCC-AGC-T-3' and 5'-TGG-GAT-GTC-ATC-TGG-GCC-TGT-3'. The GAPDH probe was an 1100 bp cDNA (Clontech, Palo Alto, CA). The a-FABP probe was a 500 bp fragment released by BamH I and Xho I digestion of a cDNA cloned into pBlueScript SK (-) (Stratagene, La Jolla, CA) (15). Blots were exposed to Kodak X-OMAT film at - 80 °C for 1 to 3 days or to a phosphorimaging screen (Super resolution screen, Packard Instrument Co., Inc., Meriden, CT) for 1 to 4 hours at room temperature and imaged on a Cyclone Storage Phosphor System (Packard).

1 ug total RNA was used for conventional RT-PCR reactions with the Promega Access RT-PCR System (Promega, Madison, WI), generally according to the manufacturer's instructions. For 15-LOX-2, the primers employed were 5'-GCC-TCT-CGC-CAT-CCA-GCT-3' (forward), 5'-TGC-CGA-GTT-CTC-CTT-CCA-TGA-3' (reverse), which gives a 126 base pair (bp) amplified product. For PPAR γ , the primers were 5'-GAG-TTC-ATG-CTT-GTG-AAG-GAT-GC-3' (forward), 5'-CGA-TAT-CAC-TGG-AGA-TCT-CCG-CC-3' (reverse), which generate a 233 bp amplicon corresponding to portions of exon 2 and 3 contained in both PPAR γ 1 and PPAR γ 2 isoforms (16). Primers to amplify both isoforms were chosen as the relative expression in prostate is not definitively established (17) and both contain the same

ligand binding domain which would potentially bind 15-HETE (16). 15-LOX-2 and PPAR γ primers span intron-exon boundaries (7, 16), obviating the need for inclusion of DNase treatment during RNA extraction protocols. 30 cycles of reaction at 94 °C for 30 s, 60 °C for 30 s, and 72 °C for 60 s, respectively, were carried out on a thermal cycler (Perkin-Elmer Cetus).

Quantitative real time RT-PCR for PPAR γ and α -FABP: PPAR γ and α -FABP mRNA copy numbers in untreated and treated PC3 cells were determined by real time quantitative RT-PCR using a LightcyclerTM fluorescence temperature rapid-air cycler (Roche Molecular Biochemicals, Indianapolis, IN) with cDNA standard curves and the double stranded DNA binding fluorescent probe SYBR Green (18-21). Amplifications were done in glass capillary tubes using a 20 ul reaction of 100 ng total PC3 RNA, 5 mM magnesium chloride, 11 ng/ul TaqstartTM antibody (Clonetech Laboratories, Palo Alto, CA), 2.0 ul 1x SYBR Green RNA master-mix (Roche Molecular Biochemicals), 0.4 ul reverse transcriptase enzyme (Roche Molecular Biochemicals), and 1.0 uM each primer. The cDNA template for PPAR γ consisted of a 761 bp fragment inserted into PCRII (Stratagene, La Jolla, CA). The primers were identical to those listed above. The α -FABP template for standard curves consisted of a 500 bp fragment, released by BamHI and XhoI digestion from a full length (619 bp) cDNA inserted into pBlueScriptSK(-) (Stratagene, La Jolla, CA). The primers were 5'-TCA-GTG-TGA-ATG-GGG-ATG-TGA-3' (forward) and 5'-TCA-ACG-TCC-CTT-GGC-TTA-TGC-3' (reverse), which generate a 288 base pair amplicon. The 1-step real time RT-PCR reactions consisted of the following steps: reverse transcription at 55 °C for 15 minutes, denaturation at 95°C for 1 minute, amplification for 45 cycles, and melting curve analysis from 95°C to 65°C at a rate of 0.1°C/s under continuous fluorescence monitoring. The amplification programs consisted of heating at 20°C/s to 95°C, cooling at 20°C/s to 53°C, annealing at 53°C for 5s, heating at 20°C/s to 72°C, elongation at

~~72°C for either 12-sec (for PPAR γ) or 16-sec (for a-FABP), and heating at 5°C/s to either 84°C~~

(PPAR γ) or 83 °C (a-FABP) for fluorescence acquisition. The specificity of the amplifier in each reaction was confirmed by the melting curve analysis, with initial gel confirmation that this large peak corresponded to the expected amplifier (18, 21-23). The contribution to fluorescence signal of any non-specific products and/or primer dimers was eliminated by increasing the temperature to 2 degrees below the melting temperature of the specific product, which eliminated any other minor cDNAs (which have lower melting temperatures) (19). Copy numbers of mRNA were calculated from serially diluted standard curves generated from purified cDNA template (24). 1:10 serial dilutions over a 4 to 5 orders of magnitude range were used to generate the standard curves ($10^{10} - 10^6$ copies for PPAR γ ; $10^{10} - 10^7$ copies for a-FABP). The serially diluted standards were simultaneously amplified with the unknown samples to generate a linear standard curve using the fit points method of analysis with four points. Standard curves for both PPAR γ and a-FABP had correlation coefficients of 1.00. Control samples run in triplicate had a variance of approximately 10 %. All biologic samples fell on the standard curves, and copy numbers of the unknown samples were calculated using the lightcycler software (version 3).

Enzyme assay for 15-S-HETE formation: Control samples of benign prostate were homogenized as previously described (8). For determination of possible 15-HETE formation from cell lysates, cultured cells 80 - 100 % confluent in T75 flasks were removed by trypsinization, pelleted, and washed. The entire pellet was resuspended in 100 ul of Dulbecco's phosphate buffered saline (PBS), pH 7.4, and sonicated for 3 seconds. 100 ul (equal or greater to protein amount routinely incubated from positive prostate tissues) was transferred to a new tube and incubated with 50 uM [1-¹⁴C]AA for 45 min. 250 ul methanol was added, followed by

addition of 125 ul dichloromethane, vortex mixing, and evaporation under nitrogen. After resuspension in 50 ul methanol, the sample was collected on a C18 Bond Elute cartridge. One fifth and subsequent four-fifth fractions were analyzed by reverse phase HPLC with radioactivity monitored with an on-line Radiomatic Instrument Flo-One detector as described, using a solvent system of methanol:water:acetic acid (80:20:0.01) at a flow rate of 1.1 ml/min and addition of cold HETE standards to monitor retention times (8). In additional experiments, formation of possible AA metabolites was assessed using intact monolayers incubated with labelled AA and calcium ionophore. 80 – 100 % confluent PC3 cells in T75 flasks were incubated in 5 ml PBS, with 2 uCi [¹⁴C] AA with or without cold AA (50 uM total) and 5 uM calcium ionophore A23187 for 15 minutes at 37 C.

Soft agar colony assay: Effects of BRL 49653 and 15-HETE on PC3 proliferation were assessed using an agar cloning technique. An underlay of 0.5% agar in Hams F12 containing 5% FCS was prepared by mixing equal volumes of 1% agar and 2x Hams F12 plus 10% FCS. Two ml of this mixture was pipetted into the wells of 6 well plates and allowed to set. PC3 cells, 70 – 100 % confluent, were trypsinized, the cells resuspended in growth medium and counted with a hemocytometer. The cells were then diluted to a final concentration of 2000 per ml in a mixture of 0.7% agar and 2x Hams F12. BRL 49653 and 15-HETE were added from appropriate stock solutions in 50 % Etoh/50 % DMSO to achieve indicated final concentrations and a final solvent concentration of 0.5 %. Vehicle controls received similar volumes of solvent alone. 2 ml of the cell suspension was aliquoted into each well. The agar was allowed to set and the plates were incubated in a humidified chamber at 37 °C for 14 days. Colonies were counted in a blinded manner using a 4x objective on a Zeiss inverted microscope. Data are expressed as percent of control.

~~*Cell cycle analysis:*~~ 5×10^5 PC3 cells were seeded into T-75 flasks and 24 hours later, media was replaced with 10 ml fresh media (Hams F12K with 10 % FBS), with or without indicated final concentrations of BRL 49653 or 15-HETE added in 50 % EtOH/50 % DMSO (final solvent concentration < 1 %). Vehicle controls received equal volumes of solvent alone. After 72 hours, cells were removed by trypsin-EDTA, washed, pelleted and resuspended in 300 μ l of 1X-PBS with subsequent drop wise addition of 700 μ l ice-cold 100 % EtOH (final concentration 70 %). Fixed cells were stored at -20°C until stained with propidium iodide with Rnase, using standard methods. Cell cycle analysis was performed using a Becton Dickinson FACScan and linked Modfit cell cycle analysis and Winlist software (Verity Software House, Topsham, Maine).

Cell transfections and luciferase assays: PC3 and DU-145 cells (5.0×10^5) were transfected using FUGENE 6 at a lipid:DNA ratio of 3:1. Cells were exposed to a mix containing containing 150 ng/ml of (PPRE)3-tk-luc (a gift from R. Evans, Salk Institute, La Jolla, CA), 150 ng/ml pCDNA3.1, 1.0 ng/ml pRL-SV40 in Opti-MEM (Life Technologies). The transfection mix was replaced after 5 h with 10% charcoal stripped FBS (Hyclone)-containing media supplemented with either 0.1% vehicle (DMSO or Ethanol) or the indicated concentrations of BRL 49653 and 15-HETE. After 24 hr, cells were harvested in 1 X luciferase lysis buffer. Relative light units from firefly luciferase activity were determined using a luminometer (MGM Instruments) and normalized to the relative light units from renilla luciferase using the Dual Luciferase kit (Promega).

Results

Prostate cancer cell lines lack detectable 15-LOX-2 mRNA and catalytic activity:

PC-3 cells were selected for the majority of studies based on the previous demonstration of constitutive expression of PPAR γ mRNA and protein and the susceptibility to growth inhibition by known PPAR γ agonists (12). As 15-LOX-2 mRNA and enzyme activity are reduced in most prostate cancers compared to benign tissue, we investigated whether this is a property of PC3 cells and if these cells are a valid model for 15-LOX-2 negative prostate tumors. Compared to the usual benign prostate tissue, 15-LOX-2 mRNA was not detected in PC3 cells by either Northern blots or RT-PCR (Figure 1). Similarly, compared to the usual presence of 15-LOX-2 catalytic activity in benign prostate (8), 15-HETE formation from exogenous AA was not demonstrated in similar incubations of PC3 cells (Figure 1). DU-145 cells were also negative for 15-LOX-2 mRNA by Northern blot and RT-PCR. LNCaP cells were negative for 15-LOX-2 mRNA by Northern blot and showed only a faint band by RT-PCR compared to benign prostate. Neither DU-145 nor LNCaP cells synthesized detectable 15-HETE from exogenous AA (not shown).

Benign and malignant prostate and cancer cell lines constitutively express PPAR γ

mRNA: RNA from histologically documented pure benign (n=18) and pure tumor (n=9) specimens snap frozen intraoperatively during radical prostatectomy (including 6 pairs of benign and tumor from the same patients) were examined for the presence of PPAR γ by RT-PCR. PPAR γ mRNA was detected in all benign and malignant prostate tissues examined, as well as in PC3 carcinoma cells (Figure 2). PPAR γ was also detected in DU-145 and LNCaP cells (not shown). PPAR α and PPAR β (δ) were also detected by RT-PCR in all benign and malignant

prostate tissues. PPAR β (δ) was also detected in PC-3, DU-145, and LNCaP cells, whereas PPAR α mRNA was detected in LNCaP but not in PC-3 or DU-145 cells (not shown).

15-HETE inhibits PC3 proliferation in soft agar: Similar to results previously reported by others (12), the synthetic PPAR γ agonist BRL 49653 caused inhibition of PC-3 cell proliferation in a soft agar colony forming assay. A dose dependent effect was achieved over the 10 nM to 10 μ M range tested, with an IC₅₀ of approximately 3 μ M (Figure 3a). Similarly, exogenous 15S-HETE caused a dose-dependent inhibition of PC3 colony formation, with an IC₅₀ of approximately 30 μ M (Figure 3a). These levels are similar to those that have achieved PPAR γ mediated effects in other cell types (25) and were clearly not toxic to cells based on flow cytometric and ultrastructural analyses (not shown). Inhibition was clearly evident at 10 μ M of 15-HETE and was essentially complete at 100 μ M. In addition to fewer colonies, formed colonies were discernibly smaller at the higher concentration ranges (not shown). Possible stereospecificity of the 15-HETE effect was examined by comparing exogenous 15S vs. 15R-HETE. In each of four different experiments, the inhibition of colony formation was greater for 15S-HETE than 15R-HETE (Fig 3b).

Effects of 15S-HETE and BRL 49653 on PC3 cell cycle: Possible effects of exogenously added BRL 49653 and 15S-HETE on the cell cycle in PC3 cells were examined by flow cytometry. At three days of treatment, 3 μ M BRL 49653 caused a slight increase in the G0/G1 fraction, with a similar reduction in the S-phase fraction (Figure 4). 30 μ M 15S-HETE (which causes a similar degree of growth inhibition in the soft agar assay) produced a similar slight increase in the G0/G1 fraction (Figure 4), whereas 3 and 10 μ M were without discernible effect (not shown).

BRL 49653 and 15S-HETE activate PPAR γ -dependent transcription in PC3 cells:

Although the inhibition of PC3 proliferation by BRL 49653 and other known PPAR γ agonists has been reported (12, 17), the ability of these agents to actually activate PPAR γ -dependent transcription in these cells, supporting mechanism of action, has not been reported. The functional status of endogenous PPAR γ in PC3 cells was determined using luciferase reporter assays. Concentrations of BRL 49653 inhibiting PC3 proliferation caused PPAR γ -dependent transcription in PC3 cells transiently transfected with a PPRE-luciferase reporter construct (Figure 5a). Similarly, concentrations of 15S-HETE inhibiting PC3 proliferation also caused PPAR γ -dependent transactivation (Figure 5a). BRL 49653 (1 μ M) and 15-HETE (10 and 30 μ M) caused approximately 3-fold and greater than 2-fold increase in luciferase activity, respectively (n=3). Similarly, BRL 49653 caused PPAR γ -dependent transactivation in DU-145 cells. 10 μ M 15S-HETE caused greater than 2.5-fold increase in luciferase activity in similarly transfected DU-145 cells (n=3, not shown).

In addition to transactivation of the reporter construct, the ability of these agents to upregulate expression of native genes regulated by PPAR γ was investigated. The gene for adipocyte type fatty acid binding protein (a-FABP) contains PPRE elements in its promoter and is upregulated by PPAR γ agonists in adipocytes (26). Whereas a-FABP mRNA was not detected by Northern blots in untreated or vehicle treated control cells at three days, concentrations of BRL 49653 and 15-HETE inhibiting proliferation of PC3 cells caused upregulation of a-FABP mRNA expression at 3 days (Figure 5b).

Treatment of the breast cancer cell line 21PT with synthetic PPAR γ agonists increased expression of PPAR γ mRNA (27) and the PPAR γ agonist 15-deoxy- $\Delta^{12,14}$ -PGJ₂ increased PPAR γ 2 but not PPAR γ 1 protein in Pca cell lines (17). Whether changes in a-FABP in BRL

49653 and 15-HETE treated cells may be due in part to increases in PPAR γ was investigated. PPAR γ mRNA was not detected by Northern analysis in control or treated cells (not shown). By quantitative real time RT-PCR, we observed a reduction in PPAR γ mRNA in PC3 cells treated for 3 days with either BRL 49653 or 15-HETE, utilizing primers detecting both isoforms. PPAR γ mRNA copy numbers were 3.2- and 2.7-fold greater in vehicle control than 3 μ M BRL 49653 and 30 μ M 15-HETE treated PC3 cells, respectively. In contrast, this was accompanied by a marked upregulation in a-FABP mRNA copy number, which was 19.5-fold and 2.7-fold higher in 3 μ M BRL 49653 and 30 μ M 15-HETE treated cells, respectively, compared to vehicle controls. These results further support that a-FABP upregulation was due to ligand-dependent activation of PPAR γ mediated transcription, rather than due to increases in PPAR γ itself.

Discussion

15-LOX-2 is uniformly expressed in differentiated secretory cells of benign prostate and 15-HETE is formed by benign prostate tissues from exogenous AA as the major eicosanoid detected (8). In contrast, 15-LOX-2 expression and 15-HETE formation are reduced in the majority of Pcas (8, 10). In the current study, we have shown that PPAR γ mRNA is uniformly present in benign and malignant prostate, and that 15-HETE, similar to synthetic PPAR γ agonists, activates PPAR γ -dependent transcription in and inhibits proliferation of PC3 Pca cells. 15-HETE also activated PPAR γ -dependent transcription in DU-145 cells, and others have recently reported inhibition of DU-145 proliferation by multiple PPAR γ agonists (17, 28). These results support the hypothesis that reduced 15-LOX-2 may etiologically contribute to Pca development or progression by reduced expression of PPAR γ -regulated genes.

PPAR γ agonists have been shown to inhibit proliferation and potentially induce differentiation in carcinoma cell lines from multiple organs, including breast (27), colon (13), and bladder (15), in addition to their ability to promote adipocytic differentiation in benign adipocytes (26), and liposarcomas (29). Although these studies suggest PPAR γ agonists as potential therapeutic agents in these malignancies, possible endogenous ligands in many, if not all, of these other organs have not been identified. The uniform expression of 15-LOX-2 and formation of 15-HETE in benign prostate and the ability of 15-HETE to activate PPAR γ -dependent transcription in Pca cells indicates that 15-HETE may represent a true endogenous ligand for PPAR γ in prostate. Although concentrations of 15-HETE added exogenously in the current study and a previous study showing PPAR γ activation (25) represent essentially pharmacologic doses, the actual concentrations reaching the nucleus under these conditions or formed intracellularly *in vivo* are unknown.

The mechanisms whereby 15-HETE activation of PPAR γ -dependent transcription leads to growth inhibition remain to be characterized. PPAR γ -mediated terminal differentiation in adipocytes leads to cell cycle arrest (30). In the current studies, BRL 49653 and 15-HETE caused a slight delay in cell cycle progression in liquid cultures. The degree of these changes may be sufficient to account for the prominent effect observed in soft agar colony forming assays. In previous studies, inhibition of PC3 proliferation by synthetic PPAR γ agonists was not accompanied by detectable effects on the cell cycle at 4 days in liquid culture (12), whereas Butler et al. recently reported that 15-deoxy- $\Delta^{12,14}$ -PGJ₂ induced cell death in Pca cell lines with accumulation in S-phase at 48 hours (17). Whether this result reflects an agonist specific effect or some other mechanism besides PPAR γ activation for 15-deoxy- $\Delta^{12,14}$ -PGJ₂ is not clear. The activation of PPAR γ by PGJ₂ in Pca cell lines has not been demonstrated in prior studies (12,

17), and a more direct effect at the plasma membrane of added exogenous oxidized lipids cannot be excluded. PGJ_2 is not a natural prostaglandin product, such that any demonstrated effects are more pharmacologic than potentially physiologic *in vivo*. This is in contrast to 15-HETE, as there is a high level of 15-LOX-2 catalytic activity in the benign prostate (8, 31). In contrast, inhibition of colon cancer cell lines in soft agar was accompanied by a more prominent increase in the G0/G1 fraction than observed herein (13). Inhibition of bladder cancer cell lines by troglitazone in mitogenic assays was accompanied by possible G1 arrest, as indicated by increased expression of cyclin-dependent kinase inhibitors, p21^{WAF1/CIP1} and p16^{INK4}, and decreased expression of cyclin D1 (15). The differential effects of PPAR γ agonists on cell cycle and possible induction of differentiation are likely dependent on specific tumor cell lines studied.

The function of 15-HETE formed from the previously characterized 15-LOX-1 has been uncertain. 15-LOX-1 is able to oxygenate polyunsaturated fatty acids esterified to phospholipids in cell membranes and to catalyze oxygenation at other positions, with formation of 12-HPETE and other lipid hydroperoxides. This has led to the speculation of its function in degradation of cell organelles by initiating lipid peroxidation as in maturation of reticulocytes and in oxidation of LDL during atherogenesis (32). However, this latter function may also depend at least in part by activation of PPAR γ in macrophages (11, 25). We believe that the highly specific formation of 15-HETE from phospholipase A2-released AA by 15-LOX-2 is in keeping with a ligand function dependent on structure and stereoconfiguration (7). Previous stereospecificity has been demonstrated for 8S- vs. 8R-HETE activation of PPAR α (33). In the current study, 10 μM 15S-HETE demonstrated a modestly greater ability to inhibit PC3 proliferation compared to 10 μM 15R-HETE. However, the pharmacologic concentrations employed in the current study are the final concentrations added to the media. Concentrations actually achieved at the nucleus where

PPARs are located are unknown, such that stereospecificity of PPAR γ activation may be greater than indicated in the current studies. This remains to be demonstrated in cell free systems. There are inherent limitations of adding exogenous lipophilic agents to cells in culture. 15-HETE made by benign prostate epithelial cells (8, 31) could get secreted and function in a paracrine manner. However, as 15-LOX-2, similar to other lipoxygenases, appears to undergo translocation to cell membranes upon activation (31), it is unlikely that adding exogenous 15-HETE completely mimics the intracellular sites of formation under more physiologic conditions. 15-HETE made at the nuclear membrane could function as a PPAR γ ligand within the same cell it is formed in. We have recently identified several cell strains established from prostatectomy specimens, which in contrast to commercially available tumor cell lines, express high levels of 15-LOX-2 mRNA and form 15-HETE from exogenous AA (Shappell, S.B., Peehl, D.M.; unpublished observations). Future studies selectively eliminating expression of 15-LOX-2 and PPAR γ in 15-LOX-2 positive cells may shed more insight on other aspects of this signaling pathway in prostate.

The limited tissue distribution of 15-LOX-2 strongly suggests that its biology is crucial to normal prostate function and that its reduced expression is critical to Pca development. The mechanisms whereby 15-LOX-2 and PPAR γ contribute to prostate cell function and how reductions in these pathways contribute to the malignant phenotype need clarification. 15-HETE increased expression of the PPAR γ -regulated α -FABP, an effect which was not previously observed in PPAR γ -agonist treated breast cancer or PGJ₂ treated prostate cancer cell lines (17, 27). The activation of PPAR γ -dependent transcription was not demonstrated in these latter prostate cancer cell studies (17). In contrast, we readily demonstrated upregulation of α -FABP by both a synthetic PPAR γ -agonist and 15-HETE in PC3 Pca cells by Northern analysis and real

time RT-PCR. Although a-FABP expression is associated with adipogenesis, it is clearly not limited in its expression to adipocytes. Its expression includes epithelial cells, such as urothelium (15, 34). The function of this gene in prostate remains to be established, but it may contribute to secretory cell differentiation.. As FABP over-expression inhibits proliferation in breast cancer cell lines (35), it is tempting to speculate that reduced expression in prostate due to reduced 15-LOX-2/15-HETE activation of PPAR γ could directly contribute to altered tumor cell proliferation or differentiation. Whether this or changes in expression of other PPAR γ -regulated genes are more crucial in Pca development and progression remains to be established. In the current studies, increase in a-FABP expression was not attributed to increase in PPAR γ , as BRL 49653 and 15-HETE caused downregulation of PPAR γ under our experimental conditions. Concordant with these observations and further supporting a connection between these pathways in vivo, in a subset of 8 snap frozen benign and tumor pairs in which 15-LOX-2 mRNA was reduced in tumor vs. benign, PPAR γ mRNA quantitated by real time RT-PCR was higher in tumor vs. benign in 7 of 8 (Shappell, S.B., unpublished observations). These results indicate that 15-HETE activation of PPAR γ in benign may result in downregulation of PPAR γ (or alternatively, that loss of the endogenous ligand results in "compensatory" upregulation of this nuclear receptor in at least some tumors).

PPAR γ is expressed in other tissues that express 15-LOX-2, further supporting a role for 15-HETE formation in modulating expression of PPAR γ -regulated genes. In addition to prostate, 15-LOX-2 mRNA is detected in skin, lung, and cornea (7, 31). 15-LOX-2 was cloned originally from human hair rootlets (7), and in the skin, 15-LOX-2 is expressed strongly in sebaceous glands (Shappell, S.B., manuscript submitted). Interestingly, PPAR γ is also expressed in skin sebaceous glands, and synthetic PPAR γ agonists are additive with androgens in inducing

sebocyte differentiation (36). Hence, a 15-LOX-2- PPAR γ pathway may contribute to differentiation in other tissues besides prostate. That 15-LOX-2 is reduced in Pca and 15-HETE may be an endogenous ligand for PPAR γ in prostate as demonstrated herein further supports the rationale for evaluation of PPAR γ -agonists in the treatment and/or prevention of prostatic carcinoma. During the preparation of this manuscript, Mueller et al. reported encouraging results from a phase II clinical study in which the synthetic PPAR γ -agonist troglitazone resulted in serum PSA decreases in 33 % of patients with androgen-dependent Pca and 14 % of patients with androgen-independent Pca (28). Further understanding the relationship between androgens, 15-LOX-2, and PPAR γ in the prostate may help identify patient subsets who are particularly likely to benefit from such novel therapies.

Acknowledgements

The authors wish to thank Dr. You-fei Guan for providing PPAR γ and a-FABP probes and Jean McClure and Brent Weedman for help with figures.

References

1. Anderson, K. M., Seed, T., Vos, M., Mulshine, J., Meng, J., Alrefai, W., Ou, D., and Harris, J. E. 5-lipoxygenase inhibitors reduce PC-3 cell proliferation and initiate nonnecrotic cell death. *Prostate*, 37: 161-173, 1998.
2. Ghosh, J. and Myers, C. E. Inhibition of arachidonate 5-lipoxygenase triggers massive apoptosis in human prostate cancer cells. *Proc. Natl. Acad. Sci. USA*, 95: 13182-13187, 1998.
3. Tjandrawinata, R. R., Dahiya, R., and Hughes-Fulford, M. Induction of cyclo-oxygenase-2 mRNA by prostaglandin E2 in human prostatic carcinoma cells. *Br. J. Cancer*, 75: 1111-1118, 1997.
4. Liu, X.-H., Yao, S., Kirschenbaum, A., and Levine, A. C. NS398, a selective cyclooxygenase-2 inhibitor, induces apoptosis and down-regulates bcl-2 expression in LNCaP cells. *Cancer Res.*, 58: 4245-4249, 1998.
5. Gupta, S., Srivastava, M., Ahmad, N., Bostwick, D. G., and Mukhtar, H. Over-expression of cyclooxygenase-2 in human prostate adenocarcinoma. *Prostate*, 42: 73-78, 2000.
6. Gao, X., Grignon, D. J., Chbihi, T., Zacharek, A., Chen, Y. Q., Sakr, W., Porter, A. T., Crissman, J. D., Pontes, J. E., Powell, I. J., and Honn, K. V. Elevated 12-lipoxygenase mRNA expression correlates with advanced stage and poor differentiation of human prostate cancer. *Urology*, 46: 227-237, 1995.
7. Brash, A. R., Boeglin, W. E., and Chang, M. S. Discovery of a second 15S-lipoxygenase in humans. *Proc. Natl. Acad. Sci. USA*, 94: 6148-6152, 1997.
8. Shappell, S. B., Boeglin, W. E., Olson, S. J., Kasper, S., and Brash, A. R. 15-lipoxygenase-2 (15-LOX-2) is expressed in benign prostatic epithelium and reduced in prostate adenocarcinoma. *Am. J. Pathol.*, 155: 235-245, 1999.

9. Wheeler, T. M. and Lebovitz, R. M. Fresh tissue harvest for research from prostatectomy specimens. *Prostate*, 25: 274-279, 1994.
10. Jack, G. S., Brash, A. R., Olson, S. J., Manning, S., Coffey, C. S., Smith, J. A., Jr., and Shappell, S. B. Reduced 15-lipoxygenase-2 immunostaining in prostate adenocarcinoma: Correlation with grade and expression in high grade prostatic intraepithelial neoplasia. *Hum. Pathol.*, 31: 1146-1154, 2000.
11. Nagy, L., Tontonoz, P., Alvarez, J. G. A., Chen, H., and Evans, R. M. Oxidized LDL regulates macrophage gene expression through ligand activation of PPARgamma. *Cell*, 93: 229-240, 1998.
12. Kubota, T., Koshizuka, K., Williamson, E. A., Asou, H., Said, J. W., Holden, S., Miyoshi, I., and Koeffler, H. P. Ligand for peroxisome proliferator-activated receptor gamma (Troglitazone) has potent antitumor effect against human prostate cancer both in vitro and in vivo. *Cancer Res.*, 58: 3344-3352, 1998.
13. Brockman, J. A., Gupta, R. A., and DuBois, R. N. Activation of PPARgamma leads to inhibition of anchorage independent growth of human colorectal cancer cells. *Gastroenterology*, 115: 1049-1055, 1998.
14. Brash, A. R. and Song, W. C. Detection, assay, and isolation of allene-oxide synthase. *Methods Enzymol.*, 272: 250-259, 1996.
15. Guan, Y., Zhang, Y., Breyer, R. M., Davis, L., and Breyer, M. D. Expression of peroxisome proliferator-activated receptor gamma (PPARgamma) in human transitional bladder cancer and its role in inducing cell death. *Neoplasia*, 1: 330-339, 1999.
16. Fajas, L., Auboeuf, D., Raspe, E., Schoonjans, K., Lefebvre, A.-M., Saladin, R., Najib, J., Laville, M., Fruchart, J.-C., Deeb, S., Vidal-Puig, A., Flier, J., Briggs, M. R., Staels, B., Vidal,

H., and Auwerx, J. The organization, promoter analysis, and expression of the human PPARgamma gene. *J. Biol. Chem.*, 272: 18779-18789, 1997.

17. Butler, R., Mitchell, S. H., Tindall, D. J., and Young, C. Y. F. Nonapoptotic cell death associated with S-phase arrest of prostate cancer cells via the peroxisome proliferator-activated receptor gamma ligand, 15-deoxy-delta12,14-prostaglandin J2. *Cell Growth Diff.*, 11: 49-61, 2000.

18. Woo, T. H. S., Patel, B. K. C., Cinco, M., Smythe, L. D., Symonds, M. L., Norris, M. A., and Dohnt, M. F. Real-time homogeneous assay of rapid cycle polymerase chain reaction product for identification of *Leptonema illini*. *Anal Biochem.*, 259: 112-117, 1998.

19. Kofron, M., Demel, T., Xanthos, J., Lohr, J., Sun, B., Sive, H., Osada, S. I., Wright, C., Wylie, C., and Heaseman, J. Mesoderm induction in *Xenopus* is a zygotic event regulated by maternal VegT via TGFbeta growth factors. *Development*, 126: 5759-5770, 1999.

20. Steuerwald, N., Cohen, J., Herrera, R. J., and Brenner, C. A. Analysis of gene expression in single oocytes and embryos by real-time rapid cycle fluorescence monitored RT-PCR. *Mol. Hum. Reprod.*, 5: 1034-1039, 1999.

21. Bohling, S. D., Wittwer, C. T., King, T. C., and Elenitoba-Johnson, K. S. J. Fluorescence melting curve-based analysis for the detection of the bcl-1/JH translocation in mantle cell lymphoma. *Lab. Invest.*, 79: 337-345, 1999.

22. Pals, G., Pindolia, K., and Worsham, M. J. A rapid and sensitive approach for mutation detection using real-time polymerase chain reaction and melting curve analysis, using BRCA 1 as an example. *Mol. Diag.*, 4: 241-246, 1999.

23. Aslanidis, C., Nauck, M., and Schmitz, G. High-speed prothrombin G A 20210 and methylenetetrahydrofolate reductase C T 677 mutation detection using real-time fluorescence PCR and melting curves. *BioTechniques*, 27: 234-238, 1999.
24. Hartel, C., Bein, G., Kirchner, H., and Kluter, H. A human whole-blood assay for analysis of T-cell function by quantification of cytokine mRNA. *Scand. J. Immunol.*, 49: 649-654, 1999.
25. Huang, J. T., Welch, J. S., Ricote, M., Binder, C. J., Willson, T. M., Kelly, C., Witztum, J. L., Funk, C. D., Conrad, D., and Glass, C. K. Interleukin-4-dependent production of PPAR-gamma ligands in macrophages by 12/15-lipoxygenase. *Nature*, 400: 378-382, 1999.
26. Spiegelman, B. M. and Flier, J. S. Adipogenesis and obesity: rounding out the big picture. *Cell*, 87: 377-389, 1996.
27. Mueller, E., Sarraf, P., Tontonoz, P., Evans, R. M., Martin, K. J., Zhang, M., Fletcher, C., Singer, S., and Spiegelman, B. M. Terminal differentiation of human breast cancer through PPARgamma. *Mol. Cell*, 1: 465-470, 1998.
28. Mueller, E., Smith, M., Sarraf, P., Kroll, T., Aiyer, A., Kaufman, D. S., Oh, W., Demetri, G., Figg, W. D., Zhou, X. P., Eng, C., Spiegelman, B. M., and Kantoff, P. W. Effects of ligand activation of peroxisome proliferator-activated receptor gamma in human prostate cancer. *Proc. Natl. Acad. Sci. USA*, 97: 10990-10995, 2000.
29. Demetri, G. D., Fletcher, C. D., Mueller, E., Sarraf, P., Naujoks, R., Campbell, M., Spiegelman, B. M., and Singer, S. Induction of solid tumor differentiation by the peroxisome proliferator-activated receptor-gamma ligand troglitazone in patients with liposarcoma. *Proc. Natl. Acad. Sci. USA*, 96: 3951-3956, 1999.

30. Atiok, S., Xu, M., and Spiegelman, B. M. PPARgamma induces cell cycle withdrawal: inhibition of E2F/DP DNA binding activity via downregulation of PP2A. *Genes Dev.*, *11*: 1987-1998, 1997.
31. Kilty, I., Logan, A., and Vickers, P. J. Differential characteristics of human 15-lipoxygenase isozymes and a novel splice variant of 15S-lipoxygenase. *Eur. J. Biochem.*, *266*: 83-93, 1999.
32. Kuhn, H., Heydeck, D., Brinckman, R., and Trebus, F. Regulation of cellular 15-lipoxygenase activity on pretranslational, translational, and posttranslational levels. *Lipids*, *34*: S273-S279, 1999.
33. Yu, K., Bayona, W., Kallen, C. B., Harding, H. P., Ravera, C. P., McMahon, G., Brown, M., and Lazar, M. A. Differential activation of peroxisome proliferator-activated receptors by eicosanoids. *J. Biol. Chem.*, *270*: 23975-23983, 1995.
34. Celis, J., Ostergaard, M., Basse, B., Celis, A., Lauridsen, J. B., Ratz, G. P., Andersen, I., Hein, B., Wolf, H., Orntoft, T. F., and Rasmussen, H. H. Loss of adipocyte-type fatty acid binding protein and other protein biomarkers is associated with progression of human bladder transitional cell carcinomas. *Cancer Res.*, *56*: 4782-4790, 1996.
35. Huynh, H. T., Larsson, C., Narod, S., and Pollack, M. Tumor suppressor activity of the gene encoding mammary-derived growth inhibitor. *Cancer Res.*, *55*:, 1995.
36. Rosenfield, R. L., Deplewski, D., Kentsis, A., and Ciletti, N. Mechanisms of androgen induction of sebocyte differentiation. *Dermatology*, *196*: 43-46, 1998.

Figure Legends:

Figure 1: Absent 15-LOX-2 mRNA and catalytic activity in PC3 cells. A) Northern blot for 15-LOX-2 and GAPDH showing typical strong 15-LOX-2 mRNA expression in benign prostate tissue and absence in PC3 cells. B) RT-PCR showing expected 126 bp amplicon for 15-LOX-2 in benign prostate tissue RNA, but no signal in PC3 cells. C) RP-HPLC chromatogram with in line radiodetection from incubation of benign prostate tissue homogenate with [¹⁴C]-AA, showing typical prominent ¹⁴C-15-HETE formation. D) Lack of 15-HETE formation in similarly incubated PC-3 cells.

Figure 2: PPAR γ expression in benign and malignant prostate tissues. Top: RT-PCR for PPAR γ in representative benign (B) and tumor (T) samples, with and without reverse transcriptase (RT), showing expected PCR product in all samples. Bottom: RT-PCR for PPAR γ in paired benign and tumor from subset of patients (only incubations with RT shown), showing detection of expected amplicon in all samples. PCR amplifications without RT negative (not shown).

Figure 3: A) Dose dependent inhibition of PC3 proliferation in soft agar by BRL 49653 and 15S-HETE. B) Effects of 10 μ M 15S- vs. 10 μ M 15R-HETE in 14 day soft agar colony forming assay.

Figure 4: Effect on cell cycle of PC3 cells treated for 3 days with BRL 49653 and 15S-HETE. Percent change from control of cells in G0/G1 and S-phase as determined by flow cytometry.

Figure 5: Activation of PPAR γ -dependent transcription in PC3 cells by 15S-HETE and BRL 49653. **A)** Relative luciferase activity in PC3 cells transiently transfected with (PPRE)₃-tk-luciferase and stimulated with indicated concentrations of BRL 49653 and 15-HETE for 24 hours. **B)** Northern blots for adipocyte-type fatty acid binding protein (FABP) and GAPDH in PC3 cells treated for 3 days with 3 μ M BRL 49653 and 30 μ M 15S-HETE .

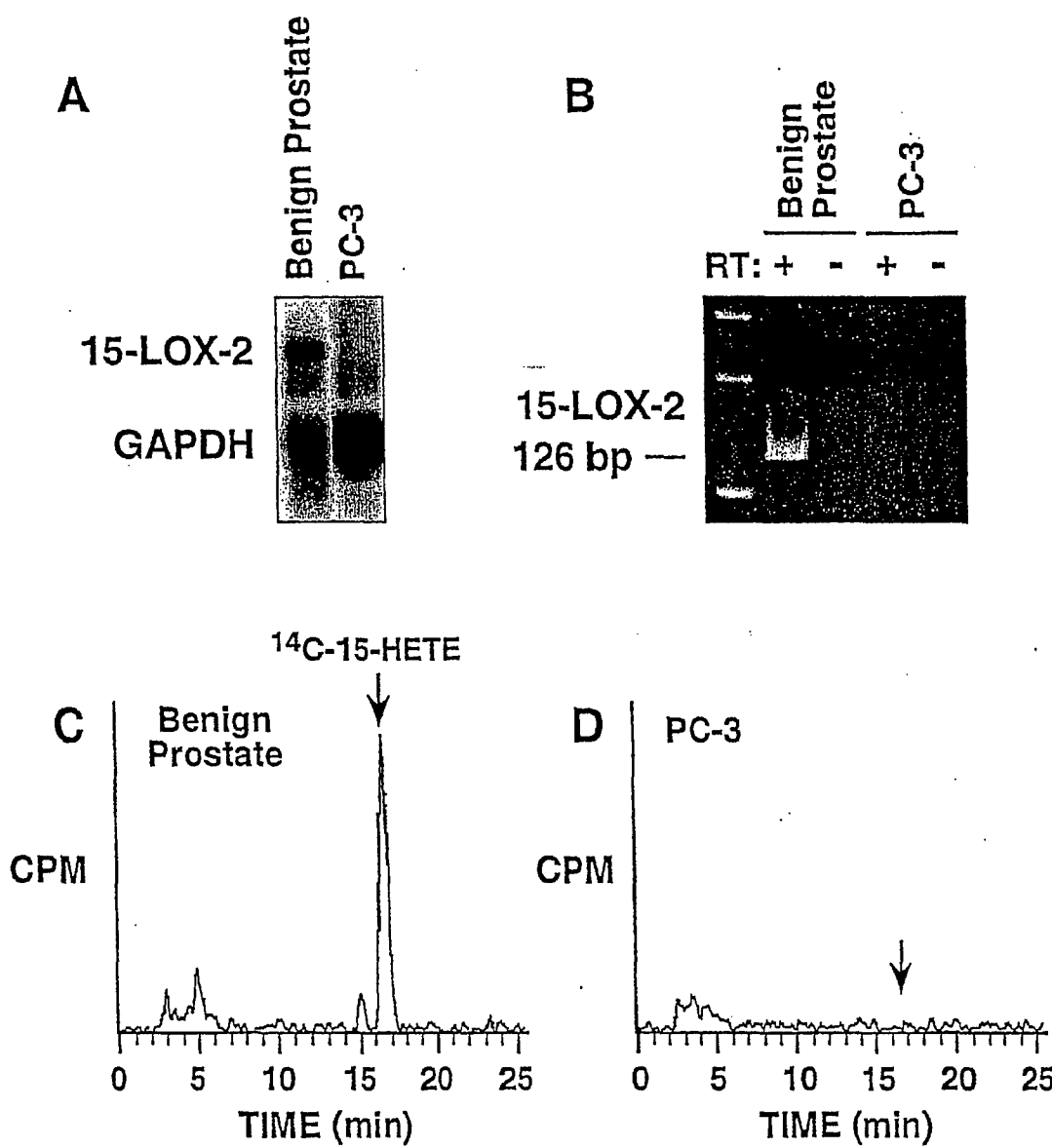


FIGURE 1





FIGURE 2

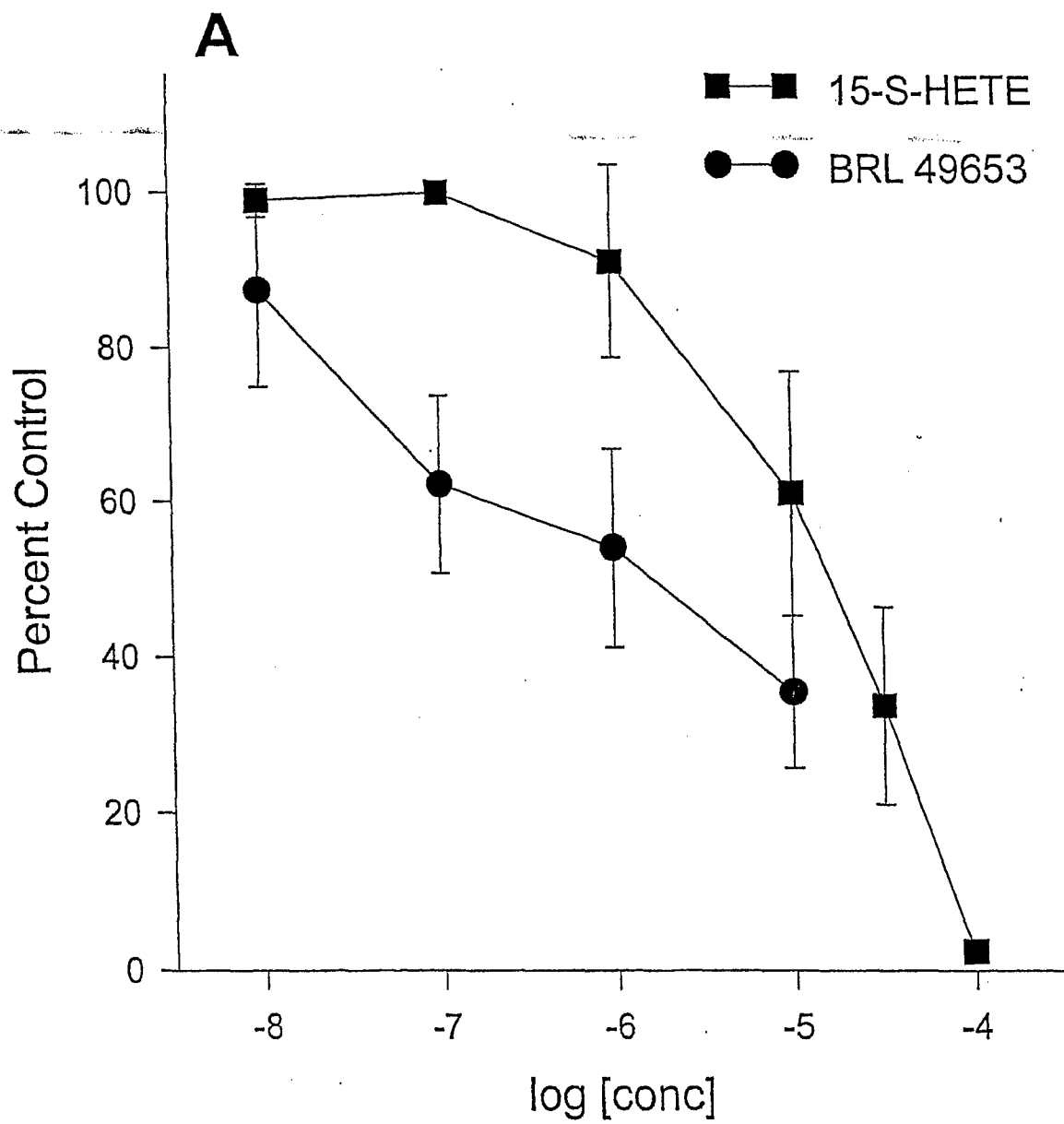


FIGURE 3A

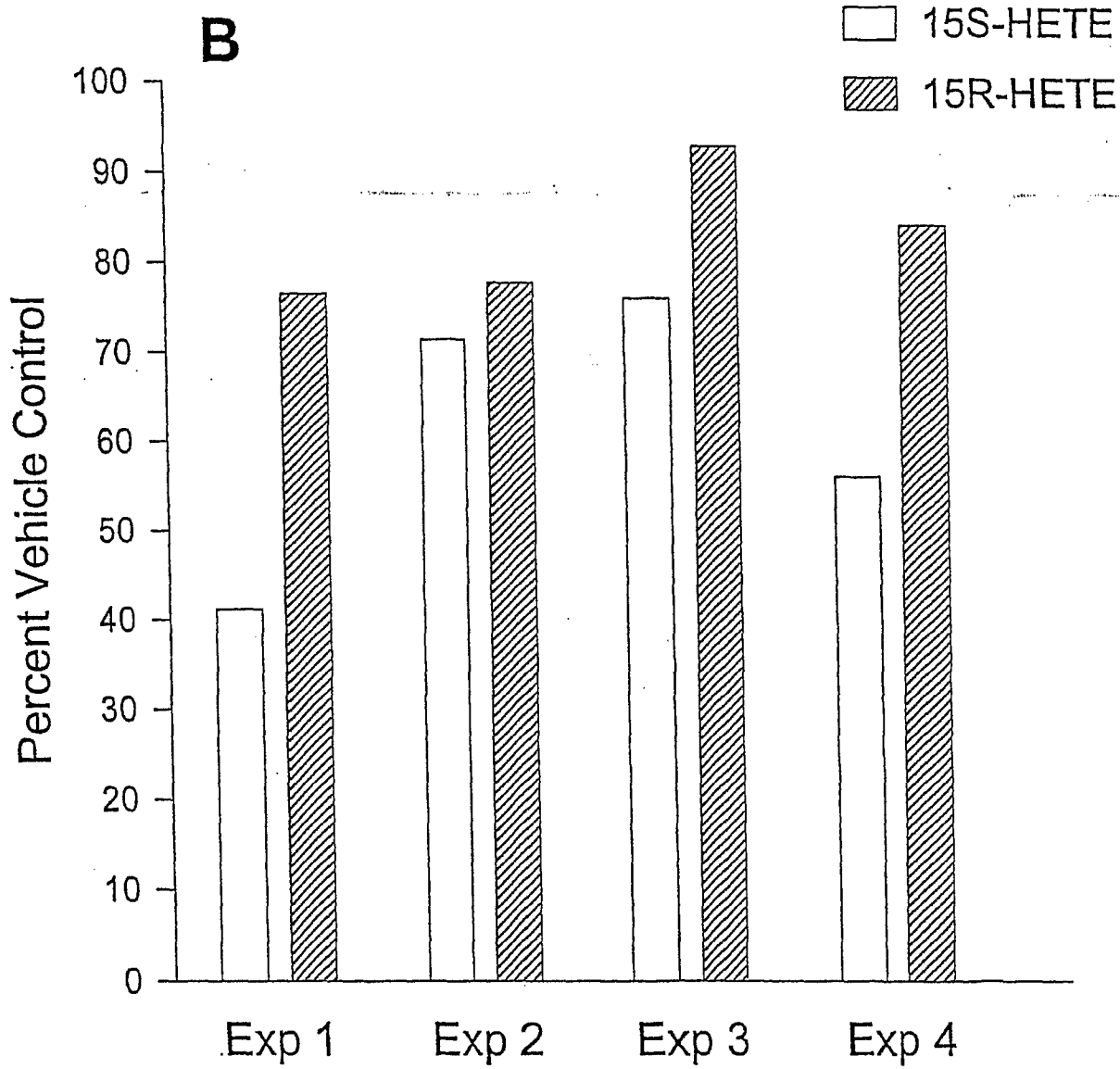


FIGURE 3B

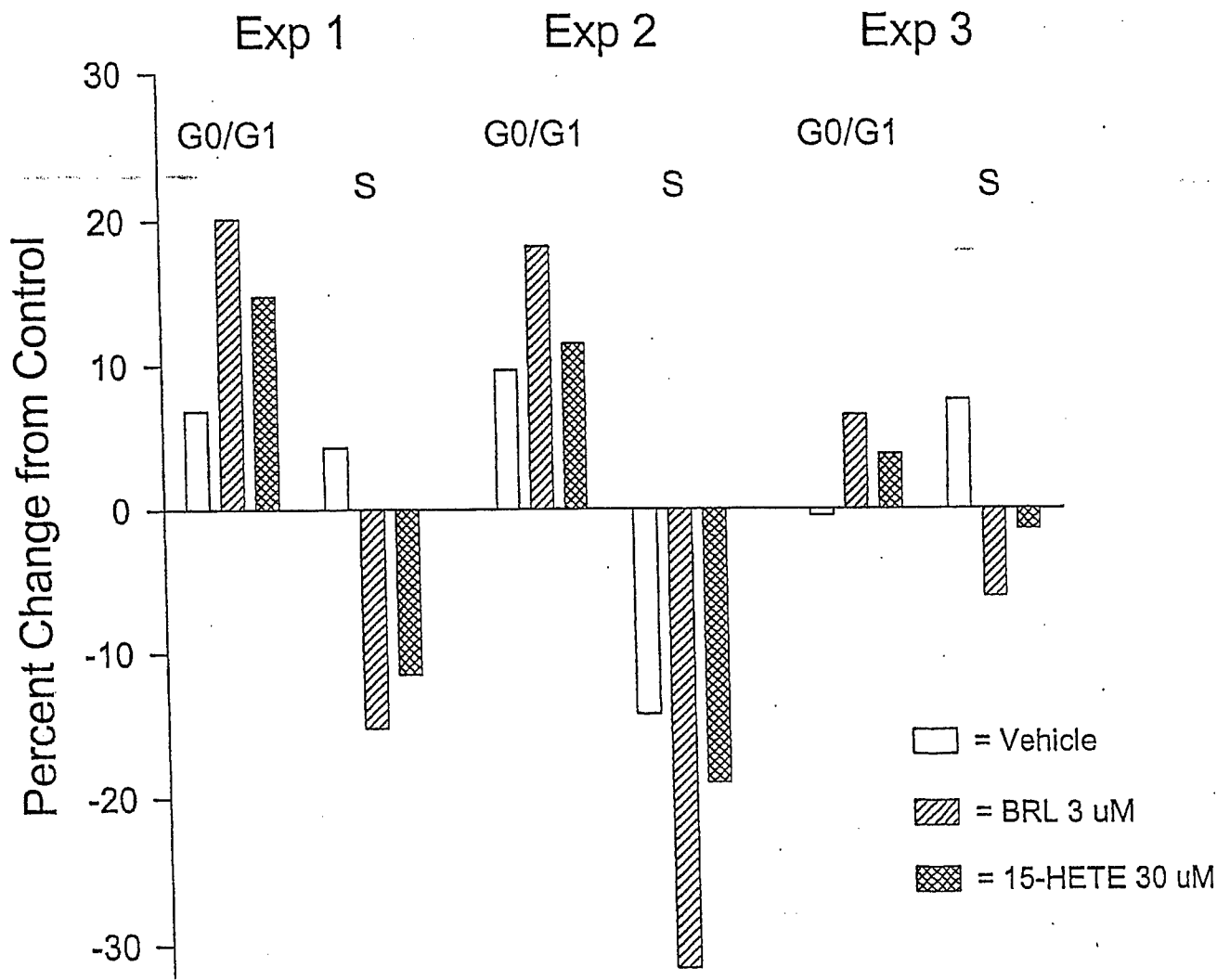


FIGURE 4

A

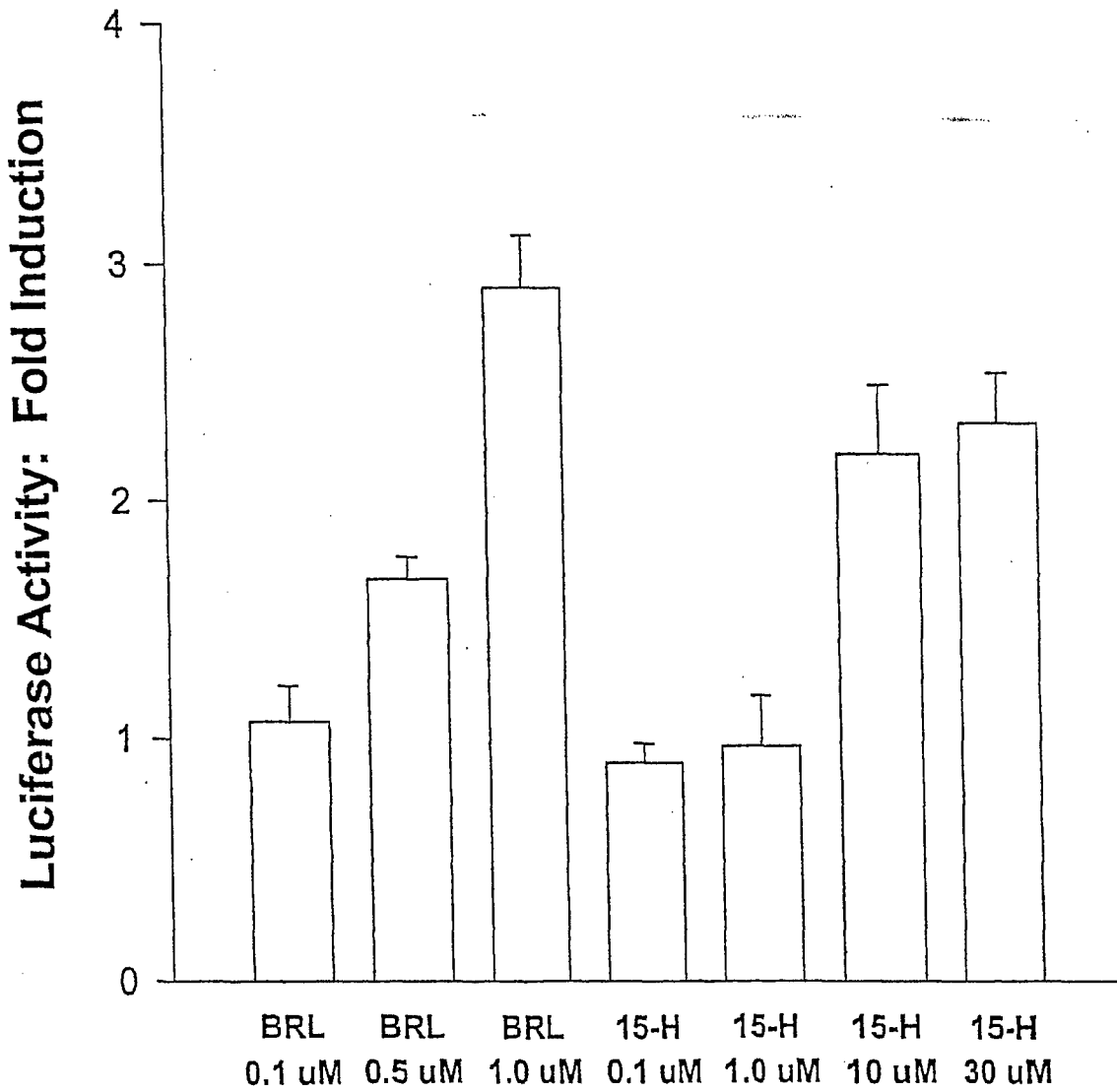


FIGURE 5A

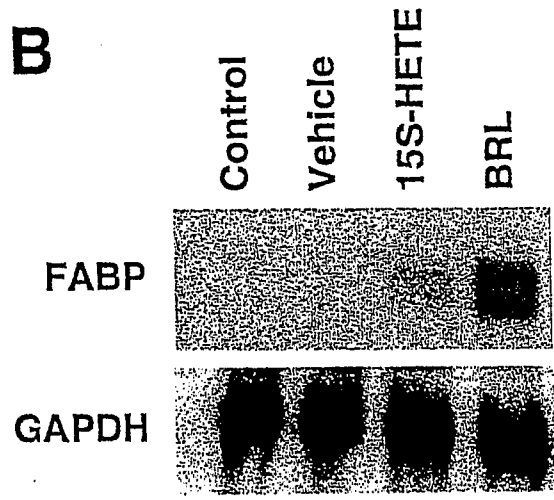


FIGURE 5B



DEPARTMENT OF THE ARMY
US ARMY MEDICAL RESEARCH AND MATERIEL COMMAND
504 SCOTT STREET
FORT DETRICK, MARYLAND 21702-5012

REPLY TO
ATTENTION OF:

MCMR-RMI-S (70-1y)

5 Mar 02

MEMORANDUM FOR Administrator, Defense Technical Information
Center (DTIC-OCA), 8725 John J. Kingman Road, Fort Belvoir,
VA 22060-6218

SUBJECT: Request Change in Distribution Statements

1. The U.S. Army Medical Research and Materiel Command has reexamined the need for the limitation assigned to technical reports written for grants. Request the limited distribution statements for Accession Documents listed at enclosure be changed to "Approved for public release; distribution unlimited." These reports should be released to the National Technical Information Service.

2. Point of contact for this request is Ms. Judy Pawlus at DSN 343-7322 or by e-mail at judy.pawlus@det.amedd.army.mil.

FOR THE COMMANDER:

PHYLLIS M. RINEHART
Deputy Chief of Staff for
Information Management

Encl

DISTRIBUTION TO BE CHANGED TO UNLIMITED,
APPROVED FOR PUBLIC RELEASE

ACCESSION DOCUMENT NUMBERS

ADB267943	ADB267947
ADB257308	ADB268439
ADB233733	ADB242952
ADB263445	ADB248375
ADB258807	ADB240661
ADB257354	ADB271166
ADB240907	ADB258706
ADB270764	ADB244250
ADB241926	ADB258773
ADB246527	ADB254490
ADB268422	ADB268189
ADB252915	ADB270793
ADB258877	ADB266144
ADB268117	ADB236672 ADB 263677
ADB267884	ADB259031
ADB254260	ADB270765
ADB268296	ADB270785
ADB258930	ADB268113
ADB271098	ADB270791